

See discussions, stats, and author profiles for this publication at: <https://www.researchgate.net/publication/329980902>

# MYXOSARCOMA IN A DWARF HAMSTER (*Phodopus sungorus*)

Preprint · December 2018

CITATIONS

0

READS

62

5 authors, including:



**Mazlina Mazlan**

Universiti Putra Malaysia

18 PUBLICATIONS 20 CITATIONS

[SEE PROFILE](#)



**gayathri thevi Selvarajah**

Universiti Putra Malaysia

38 PUBLICATIONS 248 CITATIONS

[SEE PROFILE](#)

Some of the authors of this publication are also working on these related projects:



Molecular Epidemiology Study of Japanese encephalitis virus (JEV) Isolated from Dogs, Cats, Pigs and Wild Birds in High Risk Areas in Peninsular Malaysia [View project](#)

*Jurnal Veterinar*

*Malaysia*

ISSN 9128-2506

**Vol. 30 No. 2 (Dec) 2018**



**Veterinary Association Malaysia**

*Veterinarian is a profession of distinction for the well-being of society*

## MYXOSARCOMA IN A DWARF HAMSTER (*Phodopus sungorus*)

Y.L. Chong<sup>1</sup>, M. Mazlan<sup>1\*</sup>, G.T. Selvarajah<sup>1</sup> and H.L. Law<sup>2</sup>

<sup>1</sup>Faculty of Veterinary Medicine, Universiti Putra Malaysia, UPM Serdang, Selangor, Malaysia

<sup>2</sup>Hand 'n' Paws, Block C, Japan P/JU 1/45, Petaling Jaya, Selangor, Malaysia

### SUMMARY

A 1.5 years old female Russian dwarf hamster (*Phodopus sungorus*) was presented with a large mass at right caudal ventral abdomen. Lumpectomy was performed to remove the growth mass and subjected to histopathological examination. The encapsulated mass was 3 cm x 4 cm, grossly solitary, non-ulcerated and pinkish in colour with presence of mucous-like substances on cut surface. Routine histopathology using hematoxylin and eosin staining revealed presence of pleomorphic, loosely arranged stellate to spindle shaped cells, angiogenesis, abundant neutrophils, necrotized tissues and high number of mitotic figures. Tumour tissue was positive for Alcian blue (pH 2.5) stain but negative for Periodic acid-Schiff (PAS) staining which suggests presence of acid mucin which confirmed the diagnosis of myxosarcoma. One month post-surgery, the hamster showed absence for local recurrence of the tumour, but it died a few months later due to unrelated cause.

Keywords: hamster, histopathology, myxosarcoma, Alcian blue stain, Periodic acid-Schiff stain

### INTRODUCTION

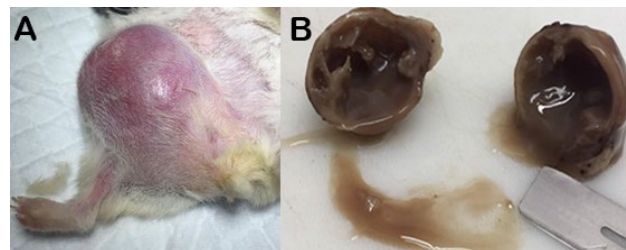
Myxosarcoma, also known as fibromyxosarcoma is a rare malignant neoplasm which arise from fibroblasts and typically composed of stellate to spindle fibroblast cells which is loosely arranged in a myxoid matrix with mucopolysaccharide-rich stroma (Headley *et al.*, 2011; Cagnini *et al.*, 2011). It consists of muco-proteinaceous fluid and highly infiltrative to adjacent tissues (Headley *et al.*, 2011). Myxosarcoma are soft, ill-defined masses of variable sizes with partial alopecia and secondary ulceration may be present in larger lesions and this neoplasm can occur at any sites including the heart, liver, spinal canal and mesentery by which the skin and subcutaneous tissues are commonly affected in dogs (Gross *et al.*, 2005; Cagnini *et al.*, 2011).

Dwarf hamster is smaller than the Syrian hamster (*Mesocricetus auratus*) and possesses the unusual characteristic of ventral sebaceous gland, also known as mid-ventral scent gland (Sunderkotter *et al.*, 1990). There are mainly five types of dwarf hamsters namely the Campbell dwarf, Chinese dwarf, Roborovski dwarf, Winter dwarf, and Russian dwarf hamsters. Myxosarcoma has been reported in a Syrian hamster (Cagnini *et al.*, 2011), European hedgehog (Singh *et al.*, 2006), bearded dragon (Gardhouse *et al.*, 2014), and rabbits (Bomhard *et al.*, 2007). This is a case worthy to be reported involving a Russian dwarf hamster which developed myxosarcoma that was managed surgically and diagnosed on histopathology.

### CASE REPORT

A one year and 6 months old, 51 grams, adult female Russian dwarf hamster was presented with a mass on the

abdomen. The owner, the mass was noted initially, one month prior to the presentation to the veterinarian which was found to be rapidly increasing in size. The subcutaneous rounded mass was approximately 3 cm by 4 cm in diameter, partly pinkish and reddish in colour, non-ulcerated, firm and solid. (Figure 1A). The differential diagnoses for this mass were neoplasia, abscess or granuloma. The mass was surgically debulked and sent for histopathological examination.



**Figure 1. (A) Solitary, non-ulcerated mass at caudoventral abdomen and (B) cut surface of the mass containing greyish mucoid material**

The dwarf hamster was pre-medicated with tramadol HCl 0.5% (Tracidol, Y.S.P, Malaysia) at a dosage of 3 mg/kg, subcutaneously and mask induction was done with 3% isoflurane. Anaesthesia was maintained between 1.5% to 2% isoflurane in oxygen (1 L/min). A total of 2.55 mL fluids (3 parts of Lactated Ringer's solution: 1 part of 5% Dextrose) was given at flank, subcutaneously, intraoperatively. For a lumpectomy procedure, an elliptical incision was made with less than 0.5 cm margin from the palpable base of tumour and the mass was excised. Minimal bleeding was observed during the procedure. Surgical site was closed with 5-0 taper point round bodied monofilament, absorbable needle (Vicryl, Johnson & Johnson International, Belgium) in a simple continuous pattern. A prophylaxis broad spectrum antibiotic was given post-operatively with Enrofloxacin

\*Corresponding author: Mazlina Mazlan (M. Mazlina).

Phone Number: +603-86093467;

Email address: [m\\_mazlina@upm.edu.my](mailto:m_mazlina@upm.edu.my)

(BAYTRIL<sup>®</sup>, Bayer Korea Ltd, Korea) 0.5%, 5 mg/kg twice daily orally for 7 days and Papase (non-steroidal anti-inflammatory) (Beazyme, UPHA Pharmaceutical Mfg., Malaysia) once a day, orally for 5 days. The hamster experienced uneventful recovery and fed with wholesome diet made up of fruits, vegetables, oats and bread mixed with hamster feed.

The whole mass was immediately fixed in 10% neutral buffered formalin for 2 days. Following fixation, cut surface of the mass revealed that it was encapsulated containing a large amount of greyish mucous-like substance which oozed out from the internal core of the mass (Figure 1B). The mass was trimmed, embedded in paraffin wax, sectioned to 4  $\mu$ m thickness, and stained with hematoxylin and eosin (H&E) stain.

Histopathological finding was a neoplasm of high cellularity with increased pleomorphism of stellate to spindle shaped fibroblasts in a loosely arranged myxoid matrix. There was presence of fine collagen fibers in some parts of the tumour with abundant angiogenesis. High numbers of mitotic figures were observed in the mass with the mitotic score of 26 per 10 high-power fields (400x). There were also presence of numerous neutrophils and necrotized tissues noted at the center of the mass (Figure 2) which was almost 50% of the whole mass. Additionally, the tissue was further subjected to a few special stainings such as Alcian blue and Periodic acid-

Schiff (PAS) stains. The tissue was found to be positive towards the Alcian blue but showed no reactions towards PAS staining. (Figure 3).

Overall, Grade III soft tissue sarcoma was highly suggested based on the grading system described by Dennis *et al.* (2011) for soft tissue sarcomas in dogs, a modified version developed by Trojani *et al.*, 1984 for soft tissue sarcomas of adult humans. This was based on the sarcoma showing poor tumour differentiation characteristics (score 2), high mitotic score (score 3 with >19 mitoses per 10 high-power fields (hpf)) and tumour necrosis (score 1 with  $\leq$  50% necrosis) which gives the total histologic grade of III (total score of 6). In addition, the tissues were positive to Alcian blue, negative to PAS stain, and positive to acid muco-substances. Hence, myxosarcoma was diagnosed. Complications were not observed during the post-operative recovery period in this hamster. There was no local recurrence and the hamster was nursed back to health. Although Grade III tumours are often associated with high tendency for recurrence and metastasis, recurrence of Grade III soft tissue sarcomas in dogs is infrequent following surgery with complete margins (Dennis *et al.*, 2011). However, this has to be further evaluated since Grade III tumours are least common and therefore data are not representative and are not the precise estimates.

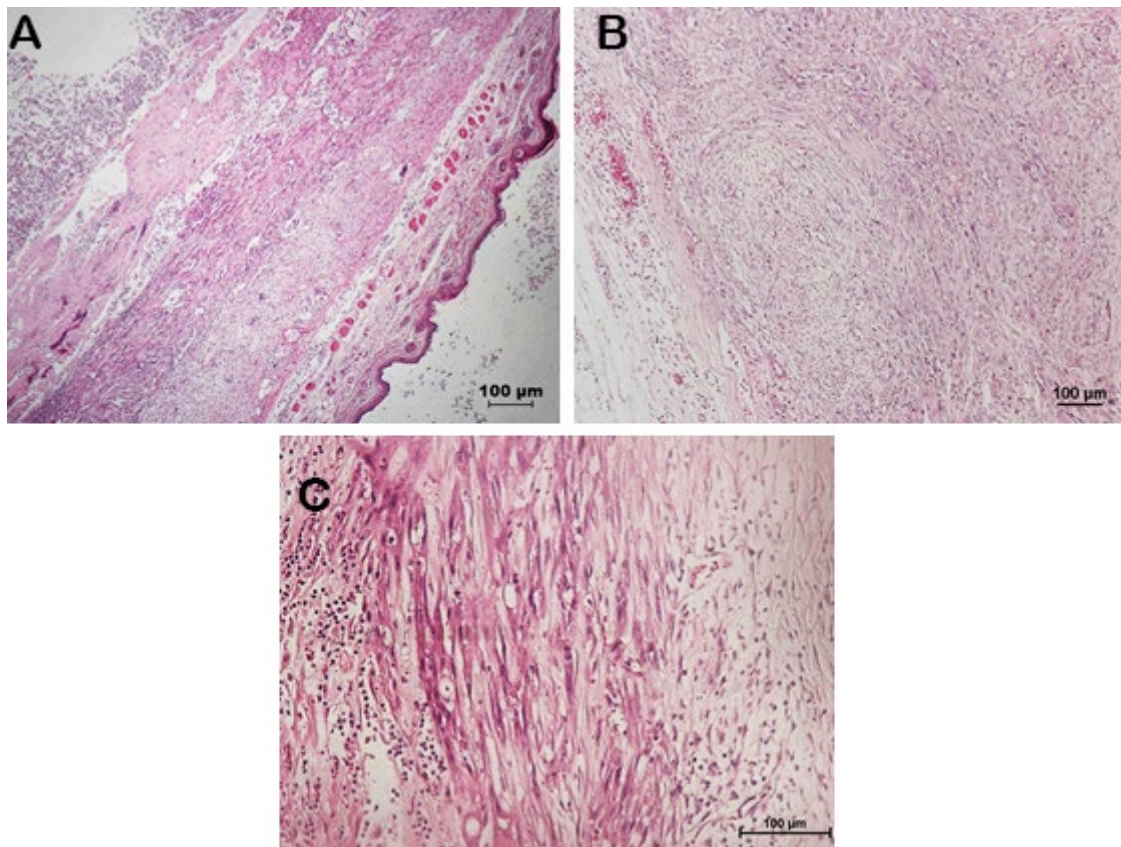
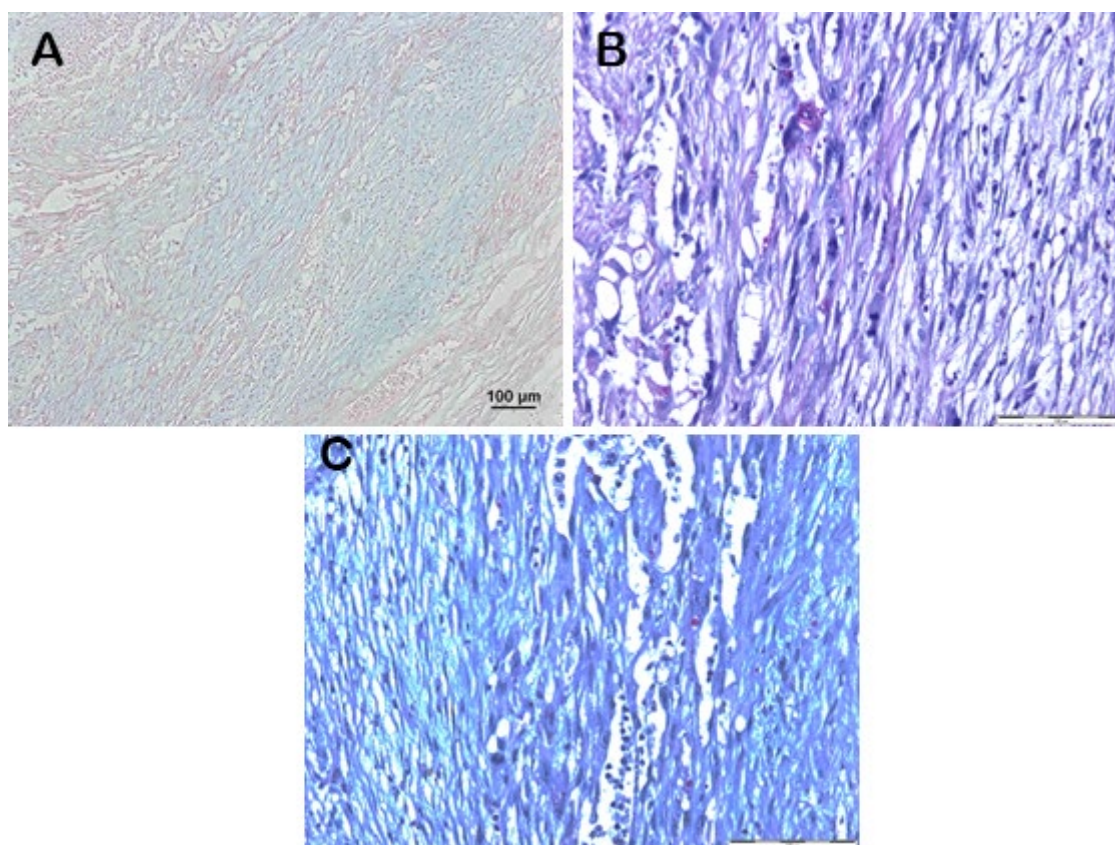


Figure 2. (A) Subcutaneous mass composed of pleomorphic stellate to spindle shaped fibroblasts in myxoid matrix with appreciable collagen fibers (H&E, 40x); (B) Pleomorphic neoplastic cells in loosely arranged myxoid matrix (H&E, 100x); (C) Mitotic figures with abundant neutrophils among loosely aggregated stellate to spindle shaped fibroblasts in myxomatous stroma (H&E, 200x)



**Figure 3. (A) mucopolysaccharide matrix in the neoplastic cells (Alcian blue, 100x); (B) cytoplasmic granules within neoplastic cells stain negative for complex carbohydrates (PAS, 200x); (C) positive to acid mucosubstances (Alcian Blue – PAS, 200x)**

## DISCUSSION

Myxosarcoma is a rare neoplasm in dwarf hamsters. According to Kondo *et al.* (2008), various types of integument neoplasm most frequently reported in dwarf hamsters are of mesenchymal and mammary in origin. However, there is thus far no reported cases of myxosarcoma in this species. Myxosarcoma are usually encapsulated, poorly circumscribed neoplasms involving the sub-cutis and/or dermis (Gross *et al.*, 2005). In this case, the stellate to spindle shaped cells are distributed throughout with presence of collagen fibers (Figure 2) and mucin (Figure 3).

Diagnosis is an important feature when identifying neoplasms in animals usually with the aid of histopathology, and/or immunohistochemistry. This helps in differentiating myxoma and myxosarcoma, as both have similar clinical presentation and histological appearance such as stellate to spindle cells distributed in myxomatous matrix, which is characterized by vacuolated, and mucinous stroma. Benign tumour or myxoma tends to have low cellularity, rare mitoses, and no marked atypia where in contrast, malignant tumour such as myxosarcoma, tends to show high cellularity, pleomorphism, and presence of mitotic figures (Goldschmidt and Hendrick, 2002; Thelma *et al.*, 2008). In this case, the histopathology revealed that there are presence of highly pleomorphic neoplastic cells which mainly consist of stellate to spindle shaped fibroblasts, plentiful mitotic figures, and abundant blood vessels in loosely arranged myxoid matrix.

These are the same findings in others case reports such as in Syrian hamster (Cagnini *et al.*, 2011), European hedgehog (Singh *et al.*, 2006), and bearded dragon (Gardhouse *et al.*, 2014) and also in dog (Jeong, 2014). Due to presence of mucous-like substance oozing out from the cut surface of the mass, Alcian blue (pH 2.5) stain was used. Alcian blue (pH 2.5) staining was positive and similar as in the case reported in the Syrian hamster (Cagnini *et al.*, 2011), and European hedgehog (Singh *et al.*, 2006). The purpose of the Alcian blue is to stain the acid mucosubstances and acetic mucins produced by the cells. By using Alcian blue stain (pH 2.5), acidic mucosubstances will be stained blue, nuclei will be stained pink to red, and cytoplasm will be stained pale pink.

In addition, PAS stain was used to stain complex carbohydrate. This is important as myxosarcoma does not stain with PAS stain. Furthermore, a combination of Alcian blue with PAS stain is used to differentiate between neutral or acid mucosubstances. According to Pernick (2017), mucins can be differentiated into acid or neutral mucins. In this case, the combination of Alcian-blue and PAS stain was used and result revealed that this tumour produced acid mucins (Figure 3C). Overall, results showed that this tumour is classified acid-simple tissue stroma and commonly associated with sarcomas.

Based on histopathology, the differential diagnoses for myxosarcoma includes muco-epidermal carcinoma, hemagiopericytoma, myxoid liposarcoma, and malignant peripheral nerve sheath tumour (Head *et al.*, 2002; Goldschmidt and Hendrick, 2002). On histopathology, muco-epidermal carcinoma is usually arranged in a solid

mass that forms lining of cysts, and may have protruding papillae into cystic lumens. These features were not observed in this case. For hemangiopericytoma, there will be presence of intra-cytoplasmic filaments (Xu, 1986) and presence of abundant pleomorphic adipocyte and lipoblasts containing large lipid droplets with multiple nuclei and prominent nucleoli would be suggestive of myxoid liposarcoma (Messick and Radin, 1989); and malignant peripheral nerve sheath tumour should contain

prominent basal lamina (Goldschmid and Hendrick, 2002); which of all the aforementioned histopathology features were not observed in this case.

There is no established histopathology grading system for soft tissue sarcoma in exotic animals and thus, the grading system described for cutaneous and subcutaneous soft tissue sarcoma in canine tumours (Dennis *et al.*, 2011) as shown in Table 1 was adopted for this case.

**Table 1. Grading system for cutaneous and subcutaneous soft tissue sarcoma in the dog<sup>a</sup>**

Differentiation score	1	Sarcomas most closely resembling normal adult mesenchymal tissue
	2	Sarcomas for which histologic type can be determined although differentiation is poor
	3	Undifferentiated sarcomas, sarcomas of unknown type
Mitotic score: mitoses per 10 hpf (400x)	1	0-9
	2	10-19
	3	>19
Tumour necrosis score	1	No necrosis
	2	≤ 50% necrosis
	3	> 50% necrosis
Histologic grade: total score <sup>b</sup>	1	≤ 3
	2	4-5
	3	≥ 6

<sup>a</sup> From Trojani *et al.* (1984)

<sup>b</sup> Combined differentiation, mitotic and tumour necrosis scores (Dennis *et al.*, 2011)

In this case, there were presence of abundant neutrophils and necrotized tissues, which is highly suggestive of secondary bacterial infection. Due to the location of the neoplasm at ventral abdomen, it created friction against the bedding, or due to insanitary environmental condition. Hence, it led to a localized infection most likely by the normal flora of the dwarf hamster or environmental bacteria namely *Pasteurella spp.*, *Staphylococcus spp.*, *Pseudomonas spp.*, and *Escherichia coli* (Harkness *et al.*, 2010). According to Harkness *et al.* (2010), hamster neutrophils have no lysozyme activity. The purpose of lysozyme activity is attacking the cell wall polysaccharide of different bacterial species and eventually breaking down the cell wall and killing the microorganisms. Due to absence of lysozyme activity, the infection tends to be encapsulated due to the body response to contain the infection. In this case, it can be as observed as the possible encapsulated abscess on cut surface of the mass. (Figure 1B).

For cases of myxosarcoma, treatment approaches include surgical resection alone, surgical resection followed by radiotherapy, and surgical resection followed by chemotherapy (Forrest *et al.*, 2000). In this case, surgical resection alone was opted without neither radiotherapy nor chemotherapy. In surgical resection of soft tissue sarcoma, it is recommended that resection should be made 30 mm laterally and 1 fascia plane or 30 mm in depth from the demarcation of the mass (Dennis *et al.*, 2011). However, due to the small size of the dwarf hamster, this wide excision was infeasible. Fortunately, there is no local recurrence at the incision site reported by the owner up until the death of the hamster which was most probably due to natural causes or old age (average life span of captive hamster between 1.5 to 2 years).

## CONCLUSION

In summary, myxosarcoma is a rare neoplasm in dwarf hamster. Histopathology is an important diagnostic tool in order to provide a probable prognosis apart from confirming the diagnosis. The diagnosis of this case was further supported by the histochemical findings as Alcian blue (pH 2.5) and PAS stains were used to identify myxosarcoma (Gross *et al.*, 2005; Cagnini *et al.*, 2011; Pernick, 2017). In this case, the clinical outcome is good, as there is no local recurrence 1 month post-surgical resection.

## CONFLICT OF INTEREST

All authors declare no conflict of interest.

## ACKNOWLEDGEMENTS

The author would like to express their appreciation to the staff of Hand 'n' Paws Clinic for their assistance in managing this case and staff of the Veterinary Histopathology Laboratory, Faculty of Veterinary Medicine, Universiti Putra Malaysia particularly, Mrs. Latifah Mohd. Hanan for her assistance in preparing the histopathology slides.

## REFERENCES

- Cagnini, D.Q., Heckler, M.C.T., Moya-Araujo, C.F., Araújo, G.H.M., and Amorim, R.L. (2011). Cutaneous myxosarcoma in a Syrian hamster (*Mesocricetus auratus*). *Semina: Ciências Agrárias, Londrina.* 32(3): 1145-1150.
- Dennis, M.M., McSparran, K.D., Bacon, N.J., Schulman, F.Y., Foster, R.A., and Powers, B.E. (2010). Prognostic factors for cutaneous

- and subcutaneous soft tissue sarcomas in dogs. *Veterinary Pathology*. 48(1): 73-84
- Forrest, L.J., Chun, R., Adams, W.M., Cooley, A.J. and Vail, D.M. (2000). Postoperative radiotherapy for canine soft tissue sarcoma. *Journal of Veterinary Internal Medicine*. 14: 578-582.
- Gardhouse, S., Eshar, D., Lee-Chow, B., Foster, R.A., Ingraio, J.C., and Poirier, V.J. (2014). Diagnosis and treatment of a periocular myxosarcoma in a bearded dragon (*Pogona vitticeps*). *The Canadian Veterinary Journal*. 55(7): 663-666.
- Goldschmidt M.H., Hendrick M.J. (2002): Tumours of skin and soft tissues. In: *Tumours in domestic animals*. Meuten D.J. (Ed.) 4th ed., Iowa State Press, Ames, IA. pp. 91-99.
- Gross, T.L., Ihrke, P.J., Walder, E.J., and Affolter, V.K. (2005): Mesenchymal neoplasms and other tumours. *Fibrous Tumors In: Skin diseases of the dog and cat: clinical and histopathologic diagnosis*. 2nd. ed., Blackwell Science, Denmark. pp. 710-734.
- Harkness, J.E., Turner, P.V., Vande Woude, S., and Wheler, C.L. (2010): Clinical procedures. *Leukocytes In: Biology and Medicine of Rabbits and Rodents*. 5th. ed., Blackwell Science, Oxford. pp. 125-126.
- Head, K.W., Else, R.W., and Dubielzig, R.R. (2002): Tumours of alimentary tract. In: *Tumours in domestic animals*. Meuten, D.J. (Ed.) 4th. ed., Iowa State Press, Ames, IA. pp. 401-483.
- Headley, S.A. Faria Dos Reis, A.C., and Bracarense, A.P. (2011). Cutaneous myxosarcoma with pulmonary metastases in a dog. *Journal of Comparative Pathology*. 145(1): 31-34.
- Jeong, K.S. (2014): Myxosarcoma. Section 2 (Dermis) In: *Surgical pathology of canine neoplasms*. 1st. ed., Gomundang printing Inc., Daegu City. pp. 88-89.
- Kondo, H., Onuma, M., Shibuya, H., and Sato, T. (2008). Spontaneous tumours in domestic hamsters. *Veterinary Pathology*. 45(5): 674-680.
- Messick, J.B. and Radin, M.J. (1989). Cytologic, histologic, and ultrastructural characteristics of a canine myxoid liposarcoma. *Veterinary Pathology*. 6: 520-522.
- Pernick, N. (2017). *Pathology Outlines-Mucins*. Retrieved June 20, 2017, from <http://www.pathologyoutlines.com/topic/stainmucins.html>
- Singh, K., Blas-Machado, U., Cooper, E.J., Caseltine, S. L., and Nordhausen, R. (2016). Spontaneous subcutaneous myxosarcoma in captive European Hedgehog (*Eriopsis europaeus*). *Journal of Veterinary Diagnostic Investigation*. 18(6): 627-631.
- Sunderkotter, C., Wittkowski, W., and Hoffmann, K. (1990). Fenestrated capillaries in the ventral sebaceous gland of the Djungarian hamster, *Phodopus sungorus*. *Acta Anatomica (Basel)* 139(1): 45-48.
- Thelma, L.G., Peter, J.I., Emily, J.W., and Verena, K.A. (2008): Mesenchymal neoplasms and other tumours. *Myxosarcoma In: Skin Diseases of the Dog and Cat: Clinical and Histopathologic Diagnosis*. Blackwell, Iowa. pp. 738-730.
- Trojani, M., Contesso, G., Coindre, J.M., Rouesse, J., Bui, N.B., de Mascarel, A., Goussot, J.F., David, M., Bonichon, F., and Lagarde, C. (1984). Soft-tissue sarcomas of adults: study of pathological prognostic variables and definition of a histopathological grading system. *International Journal of Cancer* 33(1): 37-42.
- Xu, F.N. (1986). Ultrastructure of canine hemangiopericytoma. *Veterinary Pathology*. 23: 643-645.