

Could This Child Have Schistosomiasis? When to Suspect It and What to Do About It

Amaya L. Bustinduy^{1,2}, Andrew Edielu^{1,3}, Amy S. Sturt¹

¹ Department of Clinical Research, London School of Hygiene & Tropical Medicine, Keppel Street, London UK

² Department of Paediatrics, St George's NHS trust, London, UK

³ MRC/UVRI & LSHTM Uganda Research Unit, Entebbe

Corresponding author

Amaya Bustinduy
Keppel Street
London WC1 7HT
UK
Amaya.Bustinduy@lshtm.ac.uk

Keywords: schistosomiasis, pediatrics, children, praziquantel

Word count: 2025 (excluding references and title page)

Table:1

Figure:1

References: 10

Introduction

Schistosomiasis, also known as Bilharzia, is a waterborne parasitic disease that affects over 230 million people worldwide accounting for 1.44 million disability-adjusted life years lost.(1, 2) It is caused by trematode parasites of the genus *Schistosoma*, which have intricate life cycles requiring human freshwater contact and the presence of a suitable snail vector. Transmission occurs during freshwater contact, as cercariae penetrate human skin and migrate via major blood vessels to final venous plexuses. The lifespan of a schistosome ranges between 3-10 years but can live up to 40 years. (1)

Table 1 summarizes the major species are relevant to human populations. The most prevalent are *Schistosoma (S.) haematobium* and *S. mansoni*, in sub-Saharan Africa and *S. japonicum* in Asia.(1)

Schistosomiasis, the disease caused by *Schistosoma* infection, is comprised of two clinical syndromes; intestinal schistosomiasis or urogenital schistosomiasis, depending on the parasite's vascular home (Table 1). Morbidity relates to a hyper-immune response to egg antigen release, causing a granulomatous reaction impairing organ functioning.(1, 3)

This review aims to summarize the most common clinical manifestations of schistosomiasis in different populations of children (migrants vs. returned travelers after short stays) with a proposed screening and treatment algorithm (Figure 1).

Epidemiology

Schistosomiasis, is as ancient as humankind and still dangerously modern, with 78 countries currently endemic. (1) In endemic settings, a child's initial infection can occur as early as their first bath if the water, commonly fetched by mothers from rivers or

lake shores, is infested with cercariae.(1, 3) Classically, the highest prevalence and intensity of active infections occur in young adolescents and decrease in adulthood.(1) High intensity infections usually correlate with more overt morbidity outcomes, but more sensitive diagnostic tools are now revealing important morbidities associated with lower worm burdens, particularly relevant for children.(3, 4) Isolating schistosomiasis as the attributable diagnosis becomes a challenge, as these morbidities are often confounded by other endemic conditions including malaria, soil-transmitted helminths, food scarcity, and social neglect. (1)

Could this child have schistosomiasis?

The clinician should start by obtaining a thorough clinical history with special attention to travel history and an emphasis on *exposure*; where and how. Has the child travelled in, lived in, or migrated from an area that is endemic for schistosomiasis? The clinician should access information on country-specific parasite prevalence (https://www.who.int/gho/neglected_diseases/schistosomiasis/en/) (Table 1).(1) Importantly, has the child been in contact with freshwater bodies (swimming, boating, wading, washing) in rivers, lakes, waterfalls or ponds? A common misconception is that transmission does not occur in rapidly flowing water—disproven by recent epidemics among white water rafting and kayaking expeditions. The *length* of exposure and frequency of reinfections also matters. Intensity of infection will be greater with more prolonged water contact, including recurrent exposures, but there is no minimum exposure time for transmission to occur; a few minutes is all that is needed for cercariae (emerging from the snail host), to penetrate human skin.(1)

The second important factor to consider is *clinical presentation*. Children's signs and symptoms can be remarkably different from those found in adults and adolescents, and

these signs and symptoms vary by species. Further, clinical features will often differ between children born and raised in endemic countries compared to those experienced by returning travelers. Lastly, in either setting, clinicians should still have a high index of suspicion even if the clinical picture is not congruent with a 'classic' diagnosis of schistosomiasis. In particular, ectopic site presentations are commonly found in returned travelers or those with only brief exposure histories.

Acute (Early) schistosomiasis

For this review, we define early schistosomiasis as any clinical presentation within the first two to three months after exposure. This definition is based on timing of adult worm maturation and initial egg-shedding, which occurs approximately 4-6 weeks after infection, triggering an initial hyper-immune host response. A full antibody response can take up to two to three months from initial cercarial penetration, making a serological diagnosis of acute schistosomiasis challenging.⁽⁵⁾ Early schistosomiasis has important diagnostic and treatment limitations and relies on clinical diagnosis and supportive treatment.

Two non-species-specific clinical presentations comprise early schistosomiasis; *cercarial dermatitis* and *acute schistosomiasis*, also known as Katayama Syndrome.⁽⁶⁾ Among residents in endemic settings, cercarial dermatitis, also known as 'swimmers itch', is not a common early presentation and could be easily overlooked. In returned travelers, a history of self-limited urticarial rash minutes to hours after freshwater exposure is highly suggestive of cercarial dermatitis.

Katayama Syndrome, or *acute schistosomiasis*, is a serum-sickness-like syndrome with acute onset of fever, abdominal pain, rash and eosinophilia 4-6 weeks after freshwater exposure. It is primarily seen in returned travelers or immigrants to

endemic areas whose initial exposure to schistosome antigens occurs at an age older than first exposure among local residents.(6) A differential diagnosis should rule out alternative entities, particularly malaria, which is often co-endemic with schistosomiasis.(5)

Chronic (Late) schistosomiasis

The most common manifestation of schistosomiasis, both in returned travelers and residents from endemic areas, is fatigue, likely occurring one to two months from initial infection. This symptom is non-specific and challenging to dissociate from other causes of asthenia.(3, 7)

After initial childhood infection, reinfection occurs frequently for children living in endemic settings, leading to chronic manifestations with increasing levels of organ fibrosis. (7)The tissue findings of chronic schistosomiasis range from a 'soft' polyp that reverses easily with anti-parasitic therapy, to a calcified granuloma that is more intractable to treatment.(1) The chronic manifestations detailed in this section are more likely to be found in children who are residents or migrants from an endemic area than in short-stay returned travelers. However, an untreated returned traveler can also present with some of the signs and symptoms detailed below.

Insult to children's growth and development

Prolonged pro-inflammatory states are deleterious for a child's normal growth and development. The cumulative effect of schistosome infections at younger ages has been shown to cause growth stunting via inhibition of the growth hormone-insulin growth factor axis, responsible for linear bone growth. This effect is mediated by pro-inflammatory cytokines.(3) Schistosomiasis-associated anemia has a multifactorial

etiology; 'iron trapping' via the release of the hepatic hormone, hepcidin and iron deficiency anemia, as a direct manifestation of iron loss from active bleeding. Downstream clinical manifestations of depleted tissue oxygenation include decreased aerobic capacity(1) and cognitive deficits.(7, 8)

Intestinal and hepatosplenic schistosomiasis

Parasites living in the mesenteric veins (*S. mansoni*, *S. japonicum*) excrete eggs into the intestinal lumen and the eggs induce perforations as they exit, causing local inflammation and bleeding that can be detected as blood in the stool. (1) About half of the eggs excreted fail to exit and remain entrapped in the intestinal mucosa, evolving into eosinophilic granulomas.

Adult worm pairs circulate between the mesenteric plexus and the portal vein, allowing their eggs to flow along the portal system into the liver. There, trapped eggs induce local scarring, yielding peri-portal fibrosis, also known as Symmers fibrosis, which disseminates radially into the periphery of the liver. The gallbladder is frequently involved and can sometimes precede liver fibrosis. Young children were not thought to be affected by liver fibrosis until late adolescence, but recent population surveys have disproven this fact.(3)

The hepatic parenchyma remains normal in uncomplicated cases, preserving liver function until the late fibrotic stages. Late complications include portal hypertension leading to congestive splenomegaly, esophageal varices and upper gastrointestinal bleeding. These complications are infrequently seen in children. However if present, other comorbidities should be considered and in particular portal vein thrombosis, and hepatitis due to HBV, HCV and others. Because the progression of disease is a function of both the duration and cumulative intensity of infection, children who have lived for

one year or longer in an endemic area (especially with prolonged freshwater exposure) are more likely to suffer from late complications than children returning from a short stay trip.

Urogenital schistosomiasis

Adult *S. haematobium* worm pairs reside in the vesicular plexus draining blood from the genitourinary system. Eggs entrapped in the pelvic organs, cause both acute and chronic inflammation. In children, the defining symptom for urogenital schistosomiasis is hematuria, which often presents with suprapubic pain, dysuria, urinary frequency, or burning during micturition.(1) Advanced urinary manifestations can present with obstructive uropathy (hydroureter and/or hydronephrosis), which can lead to ascending bacterial superinfection and renal dysfunction. There is a well-established link between prolonged exposure to *S. haematobium* and squamous cell carcinoma of the bladder, presenting at a younger age than common bladder neoplasms but not usually seen in children.(1)

Until recently, genital schistosomiasis has been a neglected morbidity, partly due to cultural challenges and difficulties in diagnosis. External genital granulomas can be found in both boys and girls and symptoms can present before sexual debut. Symptoms are indistinguishable from those of sexually transmitted infection (STI), highlighting the need for a high index of suspicion for genital schistosomiasis in the management of suspected STI. Female genital schistosomiasis has been linked to increased prevalence of HIV and possibly to increased risk of cervical cancer.(9)

Ectopic sites

Through the circulation, both eggs and worm pairs can lodge in ectopic sites. Common locations include the lungs and the central nervous system, but schistosomes have been found in the pericardium, the appendix, and in cutaneous tissues. Myelopathy, presenting as transverse myelitis, is most commonly seen in *S. japonicum* and *S. mansoni*, and less frequently in *S. haematobium* infections. Cerebral schistosomiasis can present with seizures and symptoms of a space-occupying lesion caused by local granulomatous inflammation. (1)

Diagnosis of Schistosome Infection

In acute (early) schistosomiasis, the diagnosis is clinical and is based on exposure history, signs, and symptoms, because early laboratory testing is often unrevealing. (6)

In chronic schistosomiasis, *Schistosoma* eggs are detected by microscopy in urine or stool, depending on the species. Parasitology egg-counting methods are helpful, albeit insensitive, in quantifying the intensity of infection.(1) *S. mansoni* and *S. japonicum* can be diagnosed by urine circulating cathodic antigen (CCA) detection. (5)

For all *Schistosoma* species infections, the circulating anodic antigen (CAA) from blood or urine can detect as little as one worm pair, but is not yet commercially available. CAA is particularly useful in returned travelers classically harboring light infections.(5)

Serology for anti-schistosome antibody is helpful in returned travelers, as a definite measure of exposure. However, it remains positive after treatment and is therefore not useful to measure treatment efficacy.(5)

Diagnosis of Disease

Schistosoma infection-related morbidity should be suspected if the history suggests a possible freshwater exposure. Functional morbidities due to schistosomiasis in children are easily overlooked and are often confounded by the presence of other ailments.(3, 7) For different schistosome species, the morbidity assessment should particularly focus on manifestations in organs drained by the parasite's preferred venous plexus.

In urogenital schistosomiasis caused by *S. haematobium*, a urinary tract ultrasound can reveal bladder polyps or bladder wall irregularities and findings related to ureteral outlet obstruction and subsequent hydronephrosis. Bladder calcifications may be noted, but are better seen on standard x-ray. (1) Genital tract changes cannot be diagnosed by ultrasound. Colposcopy can reveal pathognomonic lesions. Boys may have hematospermia or a change of sperm consistency. While symptoms are indistinguishable from STI, if caused by schistosomiasis, they may improve with praziquantel therapy. (9)

For intestinal schistosomiasis, non-specific proxy markers of inflammation, fecal occult blood and calprotectin, can be utilized to monitor disease severity.(1) Advanced stages of hepatosplenic disease can be diagnosed by liver ultrasound.

Management

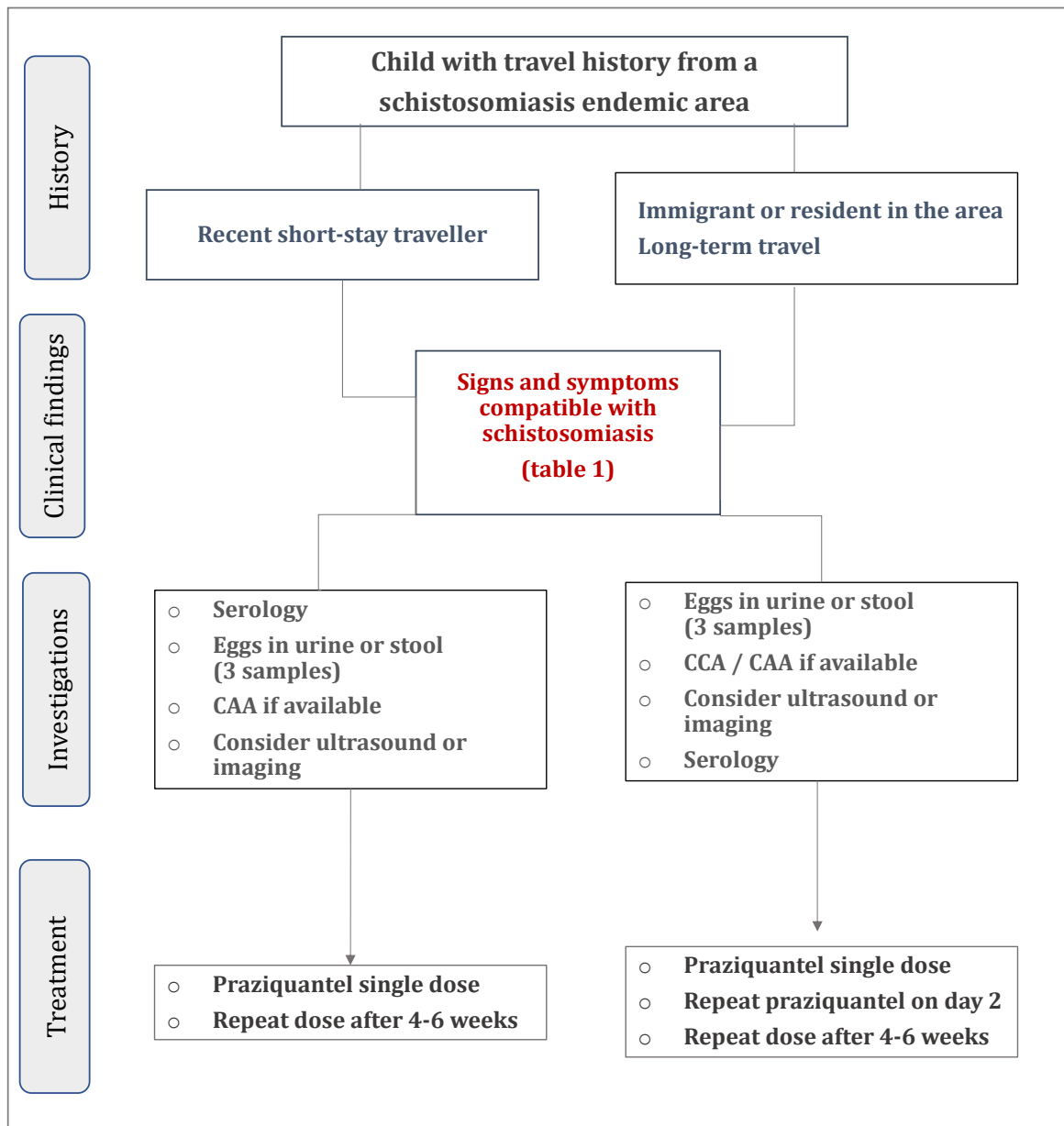
For cercarial dermatitis, anti-pruritic agents may help symptoms. Steroids may play a role in reducing inflammation in Katayama syndrome.(6) Praziquantel, the only available drug to treat schistosomiasis, targets only adult worms and is therefore not effective in early disease. A second dose can be given after juvenile worms fully mature.

(Table 1) WHO recommends praziquantel at a dose of 40-60 mg/kg, but the best drug regimen for individual schistosome species is still not known.(3) Tablet crushing remains the only viable option for under-fives, provided there is a safe monitoring environment, until a pediatric formulation becomes available.(10)

Conclusions

In summary, clinicians should have a high index of suspicion in returned travelers or migrants presenting from a schistosomiasis endemic area with reported freshwater exposure. Functional morbidities are important to recognize in children, albeit possibly confounded by other infections or co-morbidities. However, this should not preclude thorough investigation and treatment for schistosomiasis as indicated.

Figure 1- Flow chart of management of a child with suspected schistosomiasis.



<i>Schistosoma</i> spp.	Transmission	Geographic distribution	Clinical Presentation	Diagnosis	Treatment
<i>Schistosoma mansoni</i>	Through skin in fresh water contaminated by feces; Intermediate host: freshwater <i>Biomphalaria</i> snail	Africa Middle East Caribbean Latin America	Early : urticarial rash abdominal pain, fever blood in stools, anemia Late: growth retardation, blood in stools, anemia decreased fitness, impaired cognition, fatigue portal hypertension transverse myelitis seizures	Infection: Eggs in stool by microscopy CCA in urine CAA in plasma or urine Stool PCR Serology Disease: Blood in stool Calprotectin Abdominal ultrasound Colonoscopy	Early: Supportive Late: Praziquantel 40 mg/kg/day PO for 1 or 2 days Repeat after 4-6 weeks
<i>Schistosoma haematobium</i>	Through skin in fresh water contaminated by urine; Intermediate host: freshwater <i>Bulinus</i> snail	Africa Middle East	Early: urticarial rash abdominal pain, fever dysuria, hematuria, genitourinary symptoms Late: growth retardation, anemia, decreased fitness, impaired cognition, renal failure, hydroureter/hydronephrosis, dyspareunia, infertility, genital pain, discharge, granulomas, polyps bladder carcinoma	Infection: Eggs in urine by microscopy CAA in plasma or urine Urine PCR Genital lavage/swabs PCR Serology Disease: Blood in urine Renal ultrasound Cystoscopy Colposcopy	Early: Supportive Late: Praziquantel 40 mg/kg/day PO for 1 or 2 days Repeat after 4-6 weeks
<i>Schistosoma japonicum</i>	Through skin in fresh water contaminated by feces; Intermediate host: freshwater <i>Oncomelania</i> snail	China Southeast Asia The Philippines	Early: urticarial rash abdominal pain, fever blood in stools, anemia Late: growth retardation, blood in stools, anemia decreased fitness, impaired cognition, fatigue	Infection: Eggs in stool by microscopy CCA in urine CAA in plasma or urine Stool PCR Serology Disease: Blood in stool	Early: Supportive Late: Praziquantel 60 mg/kg/day divided tid PO for 1 or 2 days Repeat after 4-6 weeks

			portal hypertension transverse myelitis seizures	Calprotectin Abdominal Ultrasound Colonoscopy	
<i>Schistosoma mekongi</i>	Through skin in fresh water contaminated by feces; Intermediate host: freshwater <i>Trichula</i> snail	Southeast Asia	Early: urticarial rash abdominal pain, fever blood in stools, anemia Late: growth retardation, blood in stools, anemia decreased fitness, impaired cognition, fatigue portal hypertension transverse myelitis seizures	Infection: Eggs in stool by microscopy CCA in urine CAA in plasma or urine Stool PCR Serology Disease: Blood in stool Calprotectin Abdominal Ultrasound Colonoscopy	Early: Supportive Late: Praziquantel 60 mg/kg/day divided in three doses PO for 1 or 2 days Repeat after 4-6 weeks
<i>Schistosoma intercalatum</i>	Through skin in fresh water contaminated by feces; Intermediate host: freshwater <i>Bulinus</i> snail	Central and West Africa	Early: urticarial rash abdominal pain, fever blood in stools, anemia Late: growth retardation, blood in stools, anemia decreased fitness, impaired cognition, fatigue portal hypertension transverse myelitis seizures	Infection: Eggs in stool by microscopy CCA in urine CAA in plasma or urine Stool PCR Serology Disease: Blood in stool Calprotectin Abdominal Ultrasound Colonoscopy	Early: Supportive Late: Praziquantel 40 mg/kg/day PO for 1 or 2 days Repeat after 4-6 weeks

*Early: 0-2 months after exposure

*Late: > 2 months after exposure

Table 1: Human relevant *Schistosoma spp.* with their geographical distribution, clinical presentation, and suggested treatment.

REFERENCES

1. Colley DG, Bustinduy AL, Secor WE, King CH. Human schistosomiasis. *Lancet*. 2014.
2. DALYs GBD, Collaborators H. Global, regional, and national disability-adjusted life-years (DALYs) for 333 diseases and injuries and healthy life expectancy (HALE) for 195 countries and territories, 1990-2016: a systematic analysis for the Global Burden of Disease Study 2016. *Lancet*. 2017;390:1260-1344.
3. Bustinduy AL, Wright S, Joeke EC, et al. One hundred years of neglect in paediatric schistosomiasis. *Parasitology*. 2017;144:1613-1623.
4. Stothard JR, Sousa-Figueiredo JC, Betson M, Bustinduy A, Reinhard-Rupp J. Schistosomiasis in African infants and preschool children: let them now be treated! *Trends Parasitol*. 2013;29:197-205.
5. Utzinger J, Becker SL, van Lieshout L, van Dam GJ, Knopp S. New diagnostic tools in schistosomiasis. *Clin Microbiol Infect*. 2015;21:529-542.
6. Ross AG, Vickers D, Olds GR, Shah SM, McManus DP. Katayama syndrome. *Lancet Infect Dis*. 2007;7:218-224.
7. King CH, Dangerfield-Cha M. The unacknowledged impact of chronic schistosomiasis. *Chronic Illn*. 2008;4:65-79.
8. Ezeamama AE, Bustinduy AL, Nkwata AK, et al. Cognitive deficits and educational loss in children with schistosome infection-A systematic review and meta-analysis. *PLoS Negl Trop Dis*. 2018;12:e0005524.
9. Kjetland EF, Leutscher PD, Ndhlovu PD. A review of female genital schistosomiasis. *Trends Parasitol*. 2012;28:58-65.
10. Bustinduy AL, Friedman JF, Kjetland EF, et al. Expanding Praziquantel (PZQ) Access beyond Mass Drug Administration Programs: Paving a Way Forward for a Pediatric PZQ Formulation for Schistosomiasis. *PLoS Negl Trop Dis*. 2016;10:e0004946.