



This item was submitted to Loughborough's Institutional Repository by the author and is made available under the following Creative Commons Licence conditions.



CC creative commons
COMMONS DEED

Attribution-NonCommercial-NoDerivs 2.5

You are free:

- to copy, distribute, display, and perform the work

Under the following conditions:

BY: **Attribution.** You must attribute the work in the manner specified by the author or licensor.

Noncommercial. You may not use this work for commercial purposes.

No Derivative Works. You may not alter, transform, or build upon this work.

- For any reuse or distribution, you must make clear to others the license terms of this work.
- Any of these conditions can be waived if you get permission from the copyright holder.

Your fair use and other rights are in no way affected by the above.

This is a human-readable summary of the [Legal Code \(the full license\)](#).

[Disclaimer](#) 

For the full text of this licence, please go to:
<http://creativecommons.org/licenses/by-nc-nd/2.5/>

THE ROLE OF ULTRASOUND IN BREAST SCREENING

Stephen Chambers & Alastair Gale

*Applied Vision Research Centre, Ergonomics and Safety Research Institute,
Loughborough University, Loughborough, LE11 3TU, UK*

Ultrasound is a valuable diagnostic tool commonly used by Radiologists in breast screening. The current paper outlines the main functions that Ultrasound performs, differences between mammography and Ultrasound and why it is a topic worthy of ergonomic and psychological research. Finally, a summary of the various methodological approaches to studying Ultrasound usage and interpretation are outlined which will be used to inform the development of a new Ultrasound training application to be used by trainee radiologists.

Introduction

Breast Screening in the UK has developed steadily from its humble beginnings almost 20 years ago. From the initial recommendations in the Forrest report in 1986, to the first round of screening invitations in 1988 numbering just over 110,700, the NHS now invites over 2 million women to be screened annually. In total, over 19 million women have been screened to date and over 117,000 cancers have been found and an estimated 1,400 lives per year are now saved (Patnick, 2006).

From the data in Figure 1, the need for such a screening programme is obvious. One in nine women will develop breast cancer at some point in their lives. The chance of developing breast cancer also increases with age with a greater occurrence in women over 50 although factors such as previously family history, obesity, use of hormone replacement therapy and having the BRCA1 and/or BRCA2 genes can also be significant predictive factors.

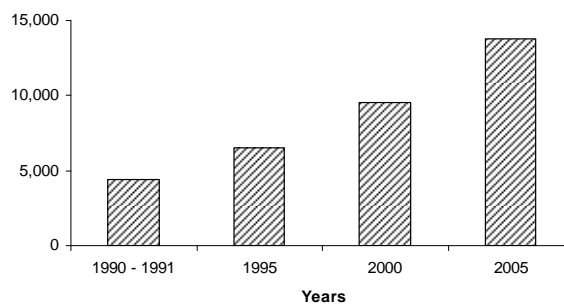


Figure 1. Breast Cancers Detected in the UK

With increased budgetary restraints and an ever increasing work load, quality assurance programmes and effective training are key concerns within the NHS. The use of modern day computer-based training applications is one way to provide trainee radiologists with the

necessary exposure to a wide range of cases and to ensure an appropriate learning environment at the same time (e.g. Sharples, Jeffery, du Boulay, Teather, Teather, & du Boulay, 2000). The current paper describes the main uses of Ultrasound (US) in today's screening environment, key differences between it and the common mammogram modality, why it is important as a research topic and a description of the research being currently undertaken to inform the development of a new Ultrasound training application.

Ultrasound in Breast Screening

What is Ultrasound used for in screening?

In a typical screening scenario a woman will undergo an US scan if a lesion is detected on their mammogram that warrants further investigation. It can increase the rate of classification specificity, help plan patient care more effectively or can assess the extent which malignancy may have spread. US is considered an important adjunct to mammographic film reading. Most modern US transducers now operate at a minimum of 7.5MHz using sound waves to allow the generation of images which have significant clarity compared to those from previous years. Typically in the past the role of sonography was to simply confirm the presence of a benign cyst. More recently however, Stavros (1998) has argued that US can be used as a means of classifying lesions of many different types although only a highly skilled practitioner may be able to achieve such high levels of performance. US is often used to scan the axilla and check for the spread of cancer to the ducts. While it can also be used to stage cancer progression in a way that mammography is incapable of. Finally, patients with highly dense tissue often have little value from mammography, as the X-ray cannot penetrate the tissue well, and US is often advised. It is particularly important for women under the age of 35 years whose breasts often contain denser tissue (e.g. Bassett, Ysrael, Gold & Ysrael, 1991) and for the evaluation of breast implants (DeBruhl, Gorczyca, Ahn et al., 1993; Caskey, Berg, Anderson et al., 1994).

Like mammography, US analysis of a possible lesion must then be categorized according to the Breast Imaging Reporting and Data System Atlas (BI-RADS). Table 1 below shows the available classifications for lesions found prior to any biopsy or histology results. This classification system becomes important for the later discussion. While mammographic

Table 1. BI-RADS Ultrasound Lesion Categorization

Category	Assessment Conclusions
1	Negative Finding
2	Benign Finding
3	Probably Benign Finding—Short-interval Follow-Up Suggested
4	Suspicious Abnormality—Biopsy Should be Considered
5	Highly Suggestive of Malignancy—Appropriate Action Should be Taken

What are the Differences between Ultrasound and Mammography?

With mammography, interpretation has a larger visual component, rather than cognitive (although they are not separate). The use and interpretation of Ultrasound information would appear to have a particularly large cognitive or decision making component combined with

the practical skill needed to conduct the exam. A good image can be difficult to acquire with mammography and interpretation can be either an impossible task or highly demanding on the visual system to try and make sense of what is being viewed. As figures 2a and 2b show the appearance of the breast and its structures varies greatly between the two imaging modalities. A difficult to view lesion in one modality does not necessarily mean a difficult to view lesion in the other. It may also follow that an expert in one modality may not necessarily equate to being an immediate expert in the other, although this is as yet unknown.

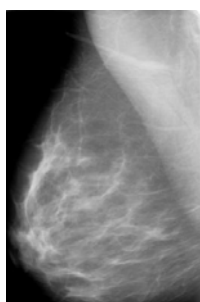


Figure 2a. MLO Mammogram View

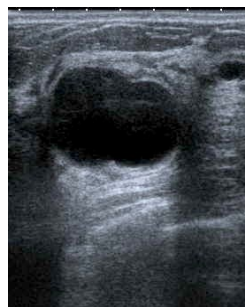

Figure 2b. A typical Ultrasound image

In contrast to mammography, Ultrasound image generation in the hands of an experienced practitioner can usually ensure the generation of a highly definitive view of the region of interest (ROI). Ultrasound, unlike mammography is a dynamic medium and reactive to the manipulation of the transducer (see Figure 3 below) by the radiologist. Applying different levels of pressure during scanning, changing the scan plane and adjusting the grayscale settings on an Ultrasound machine can all radically change the quality of the Ultrasound output. With this constant ebb and flow of visual information the implications for image interpretation are difficult to predict and drawing inferences from static imaging modalities may be ill-advised.



Figure 3. A typical Ultrasound transducer used during scanning

Once the practicalities of conducting an exam have been suitably mastered, the skill then becomes interpreting the US image and drawing the correct inferences based on all the available information from not only the clinical exam but the combination of information from the mammographic and Ultrasound scans to classify the lesion into the correct diagnostic BI-RADS category. The more definitive the category classification, the better quality of care a woman can receive.

Why is Ultrasound an Important Research Topic?

The importance of human factors in radiology has long been established. The study of expertise in any domain has the advantage of furthering our understanding of the processes

that underlie expertise in the domain, can have significant implications for the teaching of a skill to trainees and in the current case may radically inform the design of a training application. For example, Norman, Brooks, Coblenz & Babcock (1992) found that providing even a little patient history was enough to increase a radiologist's rating of likelihood of illness and to increase their identification of features from an X-ray by as much as 50%. Such a finding has implications for the provision of patient history in conjunction with Ultrasound images or video in the current application. Existing findings from radiological film reading also typically show that there are large perceptual differences in the strategies used by experts when compared with novice radiologists (e.g. Krupinski, 1996; Carmody, Kundel, & Nodine, 1984; Hu, Kundel, Nodine, Krupinski, & Toto, 1994). An experienced reader will often demonstrate the ability to disregard an area that is unlikely to yield an incidence of cancer quicker than an inexperienced reader. Take the Ultrasound examples in Figure 4a and 4b below for example. No research has been carried out that could predict which features of these two images will draw novice or expert radiologist attention the most, what features will be examined or disregarded almost immediately or differences between the skill levels.

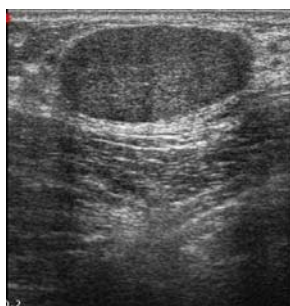

Figure 4a. Benign Lesion

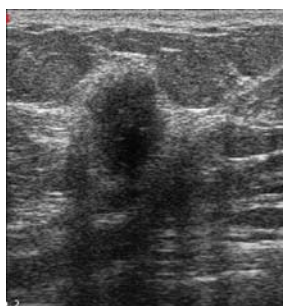


Figure 4b. Malignant Lesion

There is also evidence that indicates it is often not a question of having attended to an area of concern that causes a cancer to be missed but rather a breakdown in the reasoning process (Manning, Ethell & Donovan, 2004). Increased understanding of expert reasoning processes from the available information would allow a specific learning tool to actively promote expert type reasoning in trainees to improve their medical diagnoses and support active engagement in the learning process.

Current Project Status

Several research studies are being designed and setup at the current time. Below is a brief overview of progress and future plans:

- A validated US case archive is currently being developed. Information such as woman's age, clinical history, mammograms and Ultrasound video and/or images and histology are being collected to provide a rounded learning experience on a case by case basis.
- Eye tracking experiments with novice and expert trainee radiologists will be conducted to provide insight into the perceptual processes during Ultrasound image interpretation.

- A verbal protocol methodology will be used to examine the incorporation and use of all available information to inform the application development and construct important learning events for trainee radiologists. It is also critical that we increase our understanding of expert reasoning in relation to how lesions are assigned to the correct BI-RADS category.
- An Ultrasound Computer Aided Detection (CAD) algorithm will be incorporated into the application as an additional diagnostic tool. Ultrasound images collected during the course of the project will be used to train the algorithm.

Conclusions

The use of ergonomic and psychological research methods has an important role in furthering our understanding of human perception and decision making processes in diagnostic radiology. Only by fully examining the respective processes and their interactions can we fully develop a model of sonographic expertise in breast screening. The likely impact of increased understanding has many implications for the implementation of the current Ultrasound training application and also for how image interpretation is taught to trainee radiologists as well as opening further avenues of research in the field.

Acknowledgements

Funded by the NHS Breast Screening Programme. US images by Dr. J. James.

References

- Bassett, L.W., Ysrael, M., Gold, R.H. & Ysrael, C. 1991, Usefulness of mammography and sonography in women less than 35 years of age, *Radiology*, 180, 831 – 835
- Carmody D. P., Kundel H. L. & Nodine, C. F. (1984). Comparison scans while reading chest images: taught but not practiced. *Investigative Radiology*, 19, 462-466
- Caskey, C. I., Berg, W. A., Anderson, N. D., et al. (1994). Breast implant rupture diagnosis with US. *Radiology*, 190(3), 819 – 823.
- DeBruhl, N. D., Gorczyca, D. P., Ahn, C. Y., et al (1993). Silicone breast implants: US evaluation. *Radiology*, 189(1), 95 – 98.
- Hu, C. H., Kundel, H. L., Nodine, C. F., Krupinski, E. A. & Toto, L. C. (1994). Searching for bone fractures : a comparison with pulmonary nodule search. *Academic Radiology*, 1, 25-32.
- Krupinski, E.A. (1996) Visual scanning patterns of radiologists searching mammograms. *Academic Radiology*, 3, 137-144.
- Manning, D. J., Ethell, S. & Donovan, T. (2004). Detection or decision errors? Missed lung cancers from the PA chest radiograph. *British Journal of Radiology*, 77, 231 – 235.
- Norman, G. R., Brooks, L. R., Coblenz, C. L., & Babcock, C. J. (1992). The correlation of feature identification and category judgements in diagnostic radiology. *Memory & Cognition*, 20(4), 344 – 355.
- Patnick J. (ed). (2006) NHS Breast Screening Programme Annual Review 2006.
- Sharples, M., Jeffery, N.P., du Boulay, B., Teather, B.A, Teather, D. and du Boulay, G.H. (2000) Structured Computer-based Training in the Interpretation of Neuroradiological Images. *International Journal of Medical Informatics*, 60, 3, pp. 263-280.
- Stavros, A. T. (1998). *Breast Ultrasound*. Lippincott Williams and Wilkins.