

A perceptual aid to delineating the extent of potential mammographic abnormalities

Arul N. Selvan¹, Yan Chen², Hossein Nevisi², Leng Dong², Chris Wright¹ & Alastair Gale²

Sheffield Hallam University¹, Loughborough University²

Email: y.chen@lboro.ac.uk



Abstract

Being able to accurately determine the extent of a possible malignancy on a mammogram is an important task as this can affect the potential follow up surgical treatment that a woman receives after breast screening. It is known that this can be a difficult task, particularly where the lesion has diffuse abnormalities.

A potential computer-aided approach is to employ Hierarchical Clustering-based Segmentation (HCS) and this interactive educational exhibit dynamically demonstrates this technique. HCS is an unsupervised segmentation process that when applied to an image yields a hierarchy of segmentations based on image pixel dissimilarities and so can be used to highlight areas in the mammographic image to aid interpretation.

Introduction

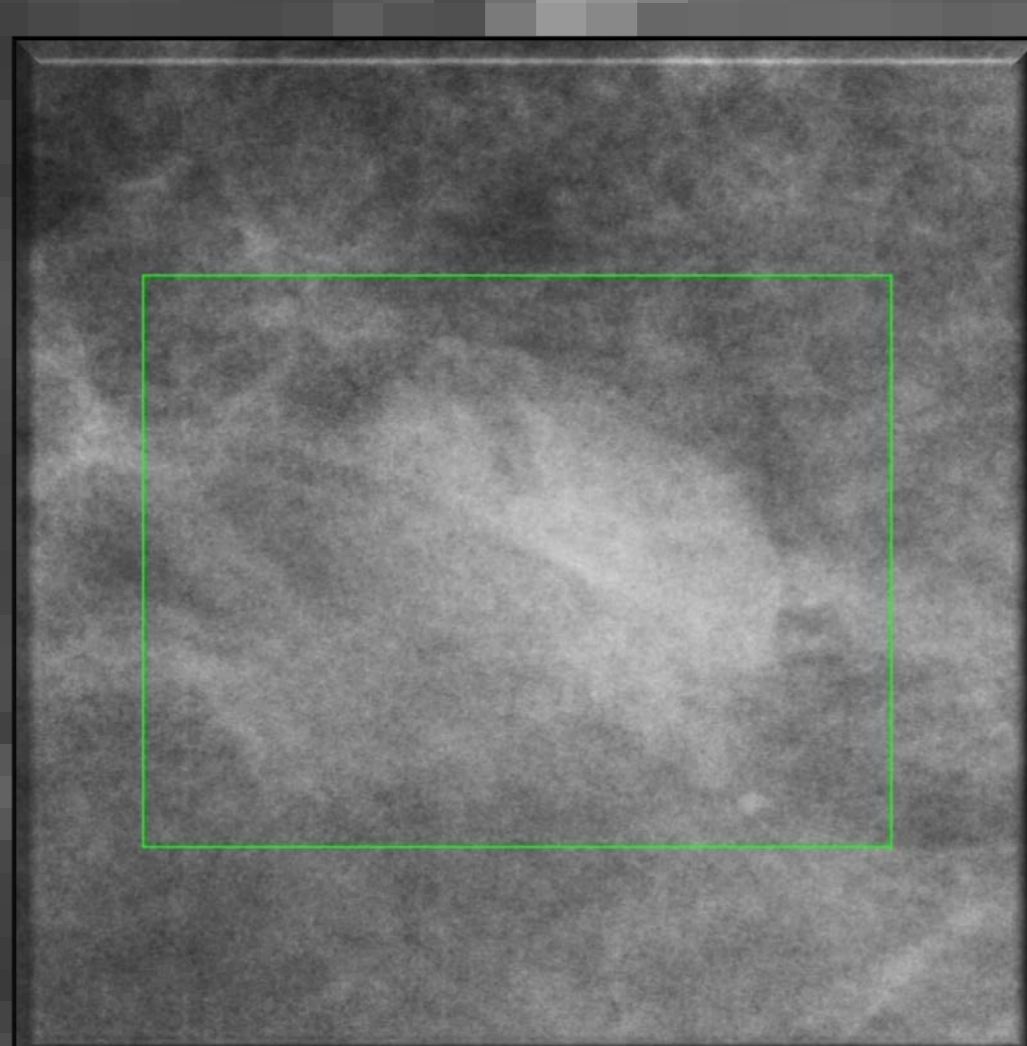
In the UK when an abnormality is identified by a radiologist on a breast screening mammogram then this case is discussed in detail at a multidisciplinary team (MDT) meeting to determine appropriate follow up. It is important that the lesion extent is appropriately understood and delineated at the MDT in the communication between radiologist and surgeon concerning such abnormal cases which requires some form of region excised. It is well known that disagreements exist concerning the definition of lesion extent and the accurate specification of the location of lesion edges. This issue is important because (1) the potential extent of treated abnormal area can determine what type of subsequent surgical intervention the woman has and (2) surgeons typically excise more breast material surrounding a lesion to ensure that they have fully removed any malignancy.

We set out to determine whether a Hierarchical Clustering-based Segmentation (HCS) method would be useful in this situation and offer a potential computer based decision aid. HCS is useful in that it can identify the appropriate edges of a lesion and heterogeneous regions within that lesion area.

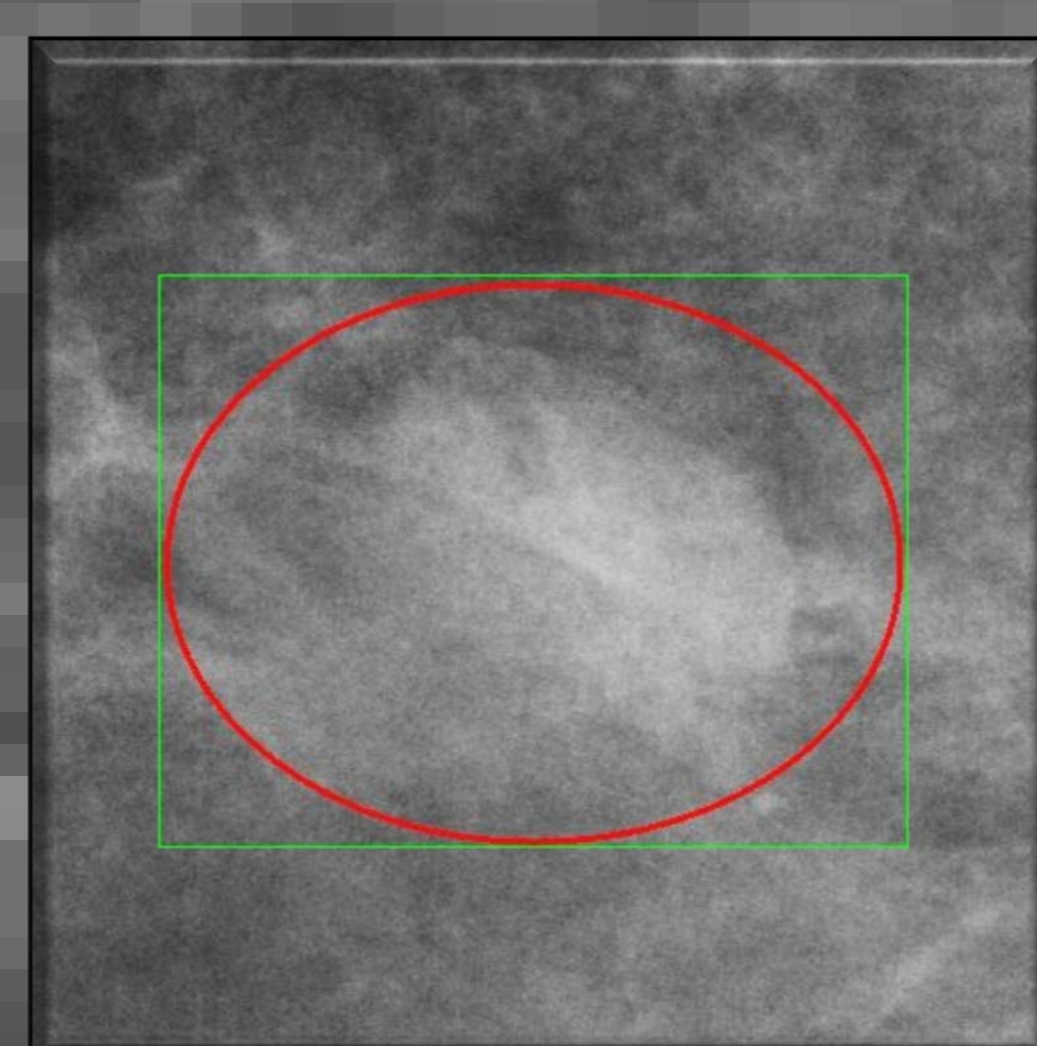
Method

A set of 10 recent FFDM screening cases were selected which each contain a known abnormality which has been shown to be difficult to identify appropriately (A). The location of a lesion within each case was defined by an experienced radiologist (B). Using this location information an area of interest around that lesion was then defined as a box region of interest (green) (B). This pixel area was then processed using HCS, which is an unsupervised image segmentation process that yields a hierarchy of segmentation results, which can then be used to highlight dissimilarities in mammographic images which may aid interpretation (C & D different levels of HCS processed images). Do such HCS processed images aid in delineating the size of a lesion in the accompanying interactive exhibit?


Example of a case




A: original image



B: marked lesion



C: HCS processed lesion



D: HCS processed lesion

Interactive exhibit

In the accompanying interactive exhibit the 10 original FFDM lesion areas and the corresponding HCS processed image areas are presented separately.

You are asked to mark the extent of the lesion within these areas using the mouse.

After marking all 10 images and their processed counterparts then you are presented with pairs of the original and processed images and asked to indicate whether you think in each case the processed images help you delineate the lesion better than in the original FFDM images.

It is intended that the information gleaned from this exhibit will help us decide whether HCS is a viable decision aid