



Metastatic gastric signet-ring cell carcinoma: A rare cause of acute appendicitis

Candaş Erçetin¹, Ahmet Cem Dural², Yaşar Özdenkaya³, Özlem Dural⁴, Huriye Gözde Muhafız Dada⁵, Gülçin Yeğen⁶, Yersu Kapran⁶, Yeşim Erbil⁷

ABSTRACT

We report a 32-year-old patient who underwent laparoscopy with classical symptoms and signs of acute appendicitis. An inflamed, edematous and non-perforated appendix, also a large amount gelatinous ascites, omental and peritoneal implants were seen. Appendectomy was performed and multiple biopsies were taken from omentum and peritoneum for definitive diagnosis. Histopathologic diagnosis was a metastatic gastric signet-ring cell carcinoma (GSRCC) involving appendix and other specimens. A flat lesion involving corpus to antrum was diagnosed by gastroscopy and GSRCC was verified histopathologically in a tertiary centre and the case evaluated as stage IV gastric carcinoma. This case with no sign of gastric cancer was presented as an acute appendicitis. Metastatic carcinoma to the appendix, causing acute appendicitis is extremely rare in clinical practice and usually associated with high morbidity and mortality.

Keywords: Acute appendicitis, gastric signet-ring cell carcinoma, metastasis

INTRODUCTION

Acute appendicitis (AA) is the most common intra-abdominal surgical emergency. The etiology usually includes luminal obstruction of the appendix caused by faecalith, lymphoid hyperplasia or a tumor lesion. Metastatic tumor of the appendix is rarely reported, while metastasis-induced AA is even more rare (1).

Approximately 3.4-39% of patients with gastric cancer may have a gastric signet-ring cell carcinoma (GSRCC) (2), and most commonly occurs in female and young patients (1). GSRCC usually infiltrates the omentum, colon, pancreas and spleen. Most common sites for distant metastases include liver, peritoneum, lungs, adrenal glands and ovaries (2). Metastasis to the appendix is quite rare and only a few case reports are available in the literature (3-5). We report a case of metastatic GSRCC, diagnosed after an emergency surgery for AA.

CASE PRESENTATION

A 32-year-old female patient was admitted to Iğdır State Hospital, emergency department with a 2-day history of abdominal pain, nausea and vomiting. At presentation, the patient's vital signs were as follows: Temperature, 37.4°C; heart rate, 96 beats/min; respiratory rate, 18 breaths/min; blood pressure, 120/80 mm-Hg. Physical examination revealed right lower quadrant tenderness, muscular defense, rebound tenderness, hypo-active bowel sounds, tenderness over the McBurney's point and costovertebral angle tenderness (-/-). Rectal examination disclosed an empty ampulla. Patient's laboratory work revealed as: WBC: 14 x 10³/μL, Hb: 10.7 g/dL, creatinine: 0.61 mg/dL, AST: 16 U/L, ALT: 14 U/L and C-reactive protein: 20 mg/dl. Colonic gas and air-fluid levels in small bowel were detected in abdominal X-ray. Abdominal ultrasound findings included an appendix with a diameter of 7.8 mm, presence of free fluid between bowel loops and in the perihepatic area, suggesting a perforated appendix. Adnexal masses were not thoroughly evaluated. Medical history did not reveal any previous disease.

The patient underwent emergency surgery with a pre-operative diagnosis of AA. Laparoscopic appendectomy was planned during laparoscopy, presence of extensive serous fluid collections in the abdomen, adhesion of the colon to the anterior wall of the abdomen, extensive fragility of tissues, a thickened gastric wall and a fibrotic omentum was found on the proximal transverse colon. Laparoscopy was converted to laparotomy because of these findings. Gelatinous ascites was observed in the abdomen and especially in the pelvic space. Pale white nodular lesions with hard consistency along the mesenteric serous surface of the stomach and small bowel were detected. Gastric wall was diffusely thickened.

¹Clinic of General Surgery, Bağcılar Training and Research Hospital, İstanbul, Turkey

²Clinic of General Surgery, Bakırköy Dr. Sadi Konuk Training and Research Hospital, İstanbul, Turkey

³Department of General Surgery, Medipol University School of Medicine, İstanbul, Turkey

⁴Department of Gynecology and Obstetrics, İstanbul University İstanbul School of Medicine, İstanbul, Turkey

⁵Clinic of Pathology, Iğdır Public Hospital, Iğdır, Turkey

⁶Department of Pathology, İstanbul University İstanbul School of Medicine, İstanbul, Turkey

⁷Department of General Surgery, İstanbul University İstanbul School of Medicine, İstanbul, Turkey

Address for Correspondence
Candaş Erçetin

e-mail: ercetin@istanbul.edu.tr

Received: 12.08.2014

Accepted: 26.09.2014

Available Online Date: 19.06.2015

©Copyright 2016
by Turkish Surgical Association
Available online at
www.uluscerrahidergisi.org

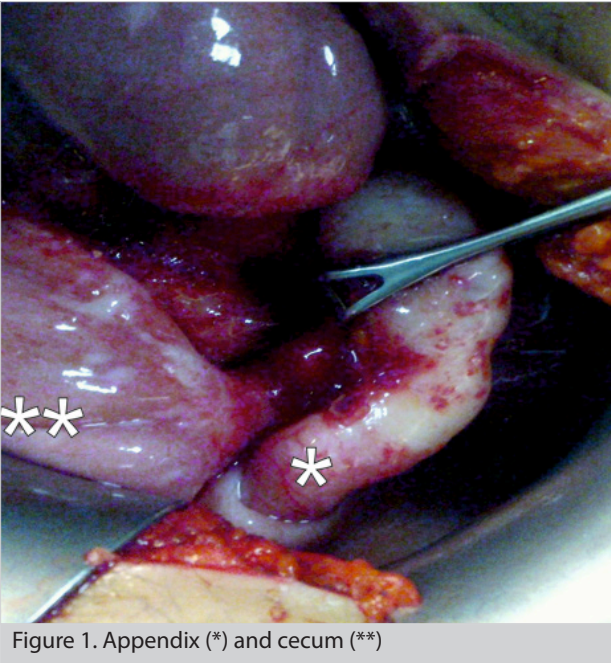


Figure 1. Appendix (*) and cecum (**)

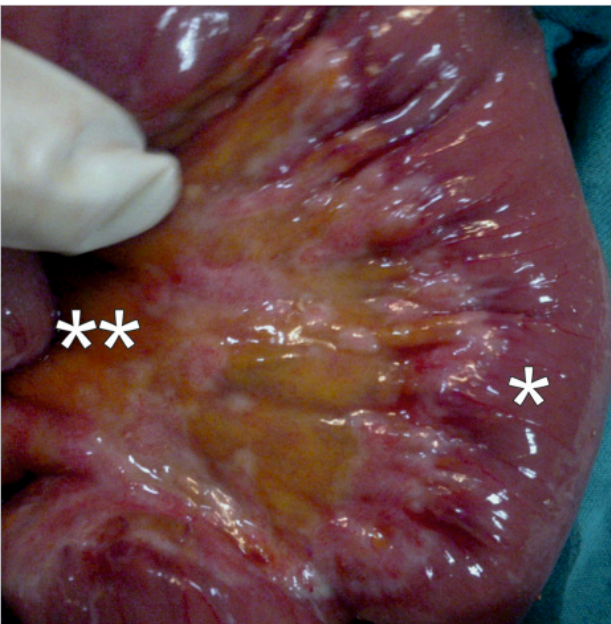


Figure 2. Small bowel (*) and mesentery of the small bowel (**); pale white nodular lesions

Meso-colon was thickened and very fibrotic with white nodules. There was no palpable or serosal extension of any lesion in the abdominal cavity. Appendix was inflamed and fragile. Masses like the ones found on meso-colon were also observed on the appendix. Appendectomy was performed. Frozen examination could not be performed due to time of surgery and hospital conditions. An attending gynecologist joined the surgical team and observed no pathology in the ovaries or in the uterus. Several fluid and tissues samples were obtained intraoperatively for pathological evaluation with a potential diagnosis of abdominal tuberculous peritonitis, gynecologic malignancy, stomach tumor or gastrointestinal tract lymphoma (Figures 1-3).

The patient developed postoperative subileus and was successfully treated conservatively. A liquid oral diet was intro-

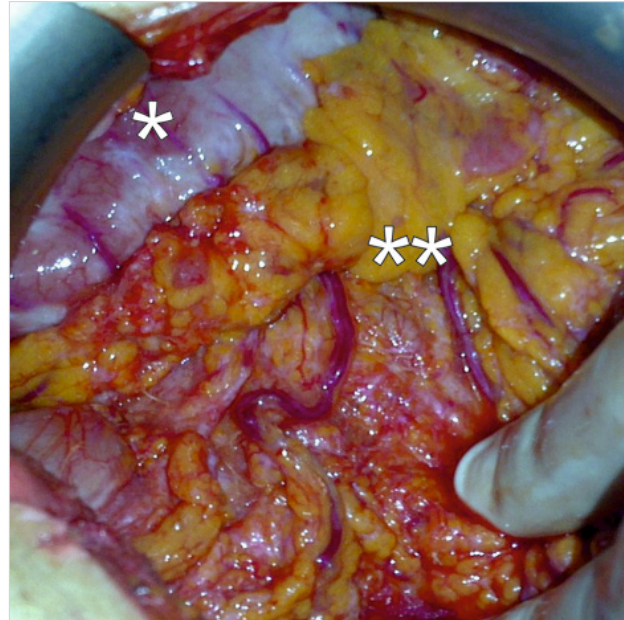


Figure 3. Greater curvature of the stomach (*) and greater omentum (**); pale white fibrotic, hard tissue lesions in the greater curvature of the stomach, fibrotic omentum located proximally

duced on the sixth day postoperatively. Gastroscopy was delayed due to prolonged postoperative subileus, which was performed 12 days postoperatively, revealed increased diffused wall thickness in the stomach corpus and antrum. Therefore, samples were collected again. Afterwards, the patient was discharged.

Postoperative laboratory evaluation of fluid samples from the stomach were negative for gram staining, acid resistant staining and anaerobic and aerobic cultures. Tuberculin purified protein derivative (PPD) skin-test and sputum culture results were also negative. Among the tumor markers only CA125 was 22.2 U/mL (range: 1.9-16.3 U/mL), the rest of the markers were within the normal levels (CEA 1.23 ng/mL; CA15-3 13.1 U/mL; CA19-9 <2.5 U/mL; AFP 1.37 IU/mL).

Postoperative pathological evaluation of tissue samples revealed AA and metastatic GSRCC on the serous surface of appendix in the samples obtained from appendix. Moreover, samples from inside the stomach, peritoneal surface, mesentery of the small bowel and omentum revealed metastatic GSRCC as well (Figures 4-6). Gastroscopic biopsy of the patient confirmed the GSRCC diagnosis (Figures 7, 8). The patient was referred to a tertiary hospital to have her oncologic treatment. Four weeks postoperatively, the patient started to receive chemotherapy as part of her therapy. Patient died on the second day of chemotherapy from complications associated with tumor lysis syndrome.

DISCUSSION

Appendectomy due to AA accounts for approximately 55% of emergency surgeries. Neoplasms of the appendix are detected pathologically in 0.9-1.4% of the obtained samples, while their age-adjusted incidence is 0.12 cases per one million annually. Epithelial neoplasms of the appendix account for less than 1% of colorectal cancers. Although secondary tumor of

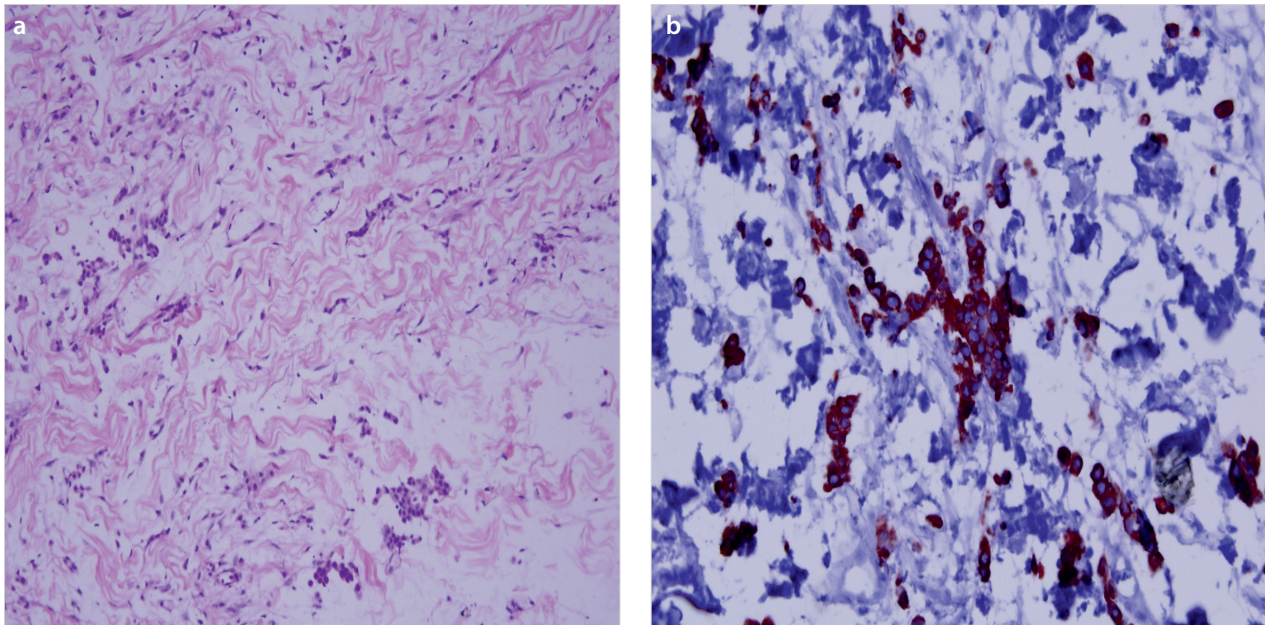


Figure 4. a, b. Sections of the peritoneal biopsies showed infiltrative neoplastic cells with eosinophilic cytoplasm, eccentric hyperchromatic nuclei (a). Neoplastic cells were positive with pancytokeratin (b)

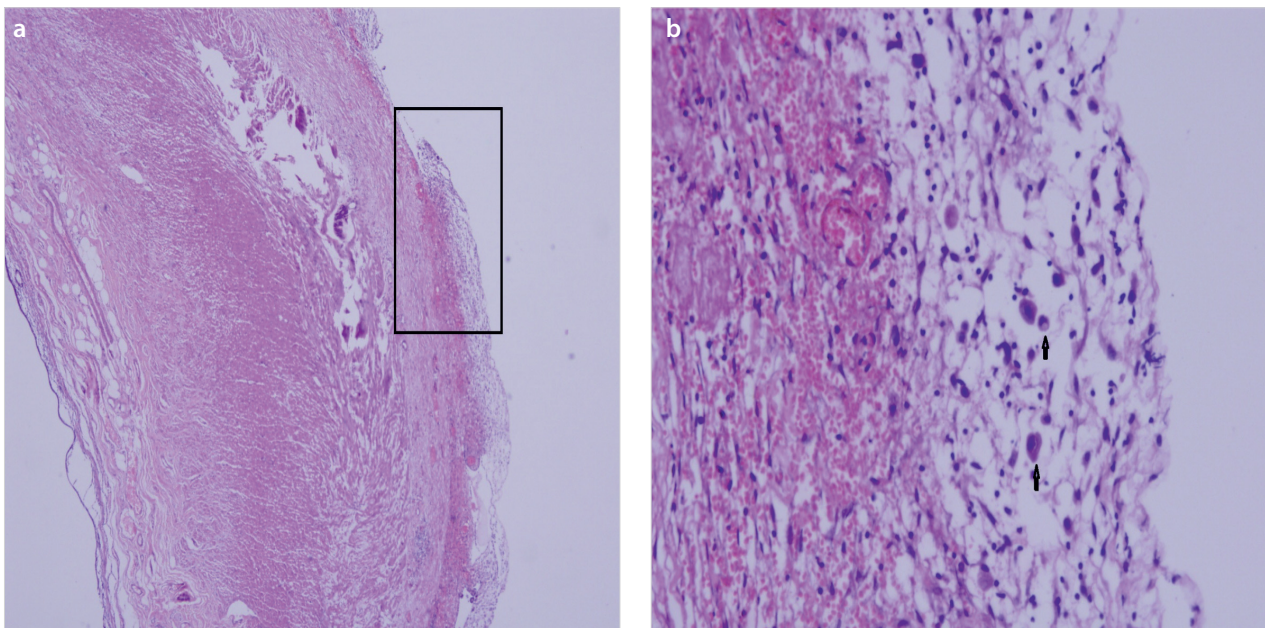


Figure 5. a, b. Sections of the appendectomy specimen showed neoplastic cell infiltration in subserosa and serosa (H&E 4X) (a). Arrows show infiltrative neoplastic cells [higher magnification of the area signed in (b)]

the appendix is rare, it usually develops because of the metastasis of the primary tumor (6).

Fifty cases of metastatic carcinoma to the appendix have been reported in the literature in which metastasis as a result of the primary breast carcinoma was the most common (7). Other metastatic cancers to the appendix recently reported are urogenital, gastrointestinal and respiratory cancers (8). As in our report, metastasis of gastric carcinoma to appendix is very rare and has been reported only in a few case reports in the literature (3-5).

Obstruction and perforation are detected commonly in patients with metastatic breast cancer, while inflammation is de-

tected in less than half of them. Partly due to sporadic use of steroid or cytotoxic drugs, clinical manifestations occur usually in the advanced stage of the disease (8).

A comprehensive study by Schmutzer et al. (9), analyzed tumors of the appendix in 8699 appendectomies performed over 23 years. Authors observed secondary tumor of the appendix only in 15 cases (12 metastatic carcinomas, and three lymphomas).

A recent study by Yoon et al. (10), consisted of 139 cases with secondary tumor of the appendix, revealed that secondary tumor of the appendix accounted for 77.2% of all pathologically

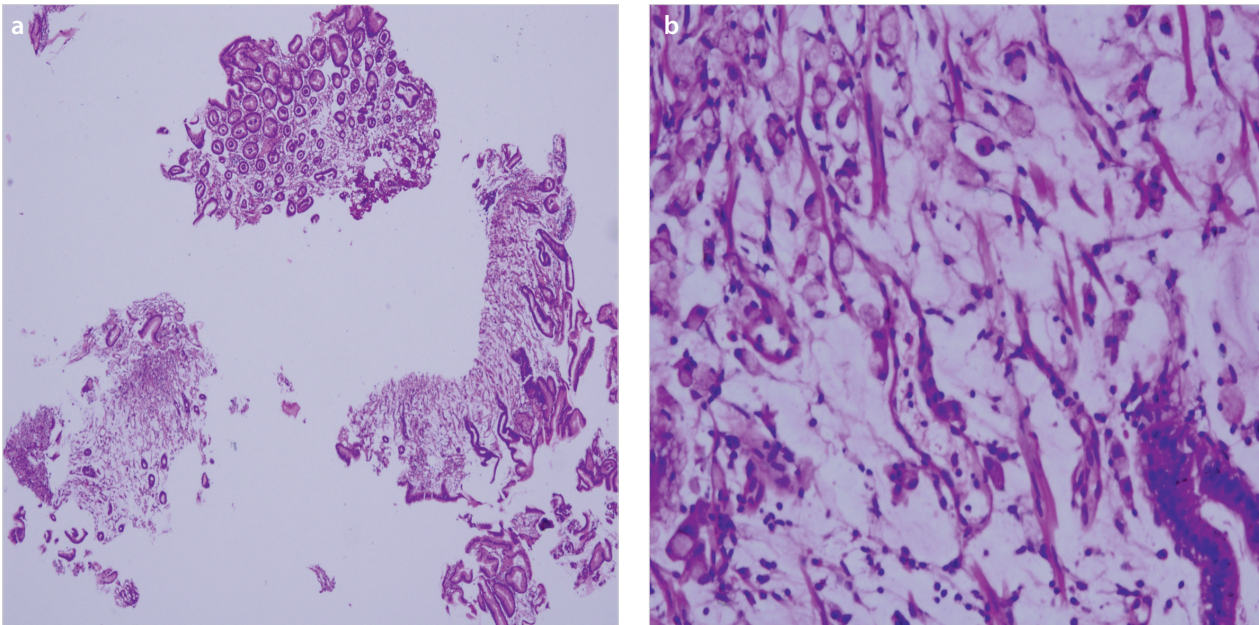


Figure 6. a, b. Two of five endoscopic biopsies showed infiltrative neoplastic cells (a) with signet cell morphology (b)

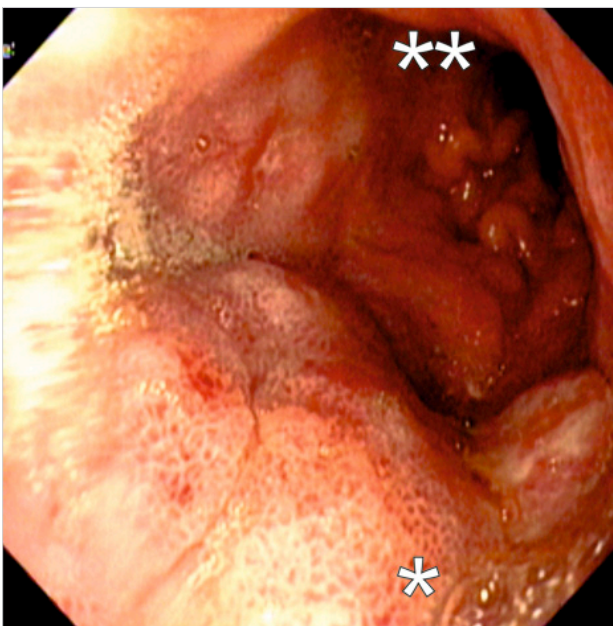


Figure 7. Increased diffuse wall thickness in the corpus (*) and antrum (**) of stomach at gastroscopy

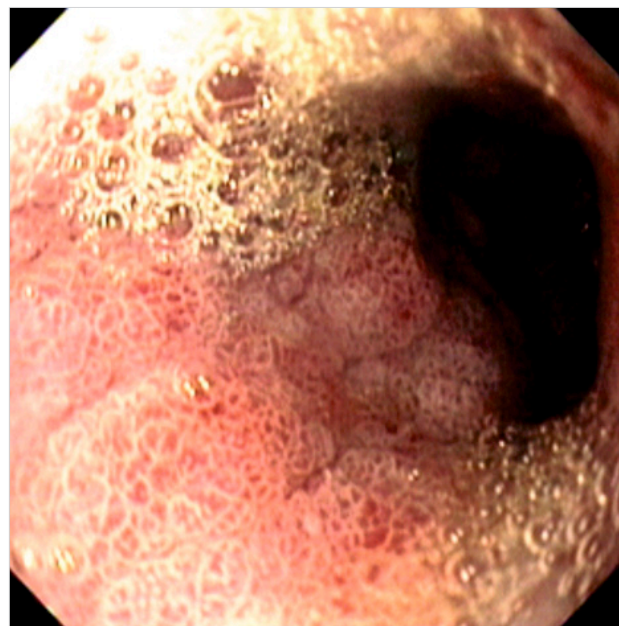


Figure 8. Increased diffuse wall thickness in the corpus of stomach at gastroscopy

diagnosed malignancies of the appendix, while the most common primary origin was the ovary followed by colorectal and digestive tracts. Only four cases presented with AA. Secondary tumor of appendix was detected intra-operatively in these patients, while subsequent work up revealed the primary tumor. Moreover, most of the patients with secondary tumor of the appendix were female in the study (79.9% synchronous tumor, 20.1% metachronous tumor with 79.1% peritoneal diffusion). Wall involvement of the appendix was mostly at the serosa level. The median survival after diagnosis of the secondary tumor of appendix was 22.6 months.

Patient had an operation in emergency conditions due to diagnosis of acute appendicitis and was evaluated for secondary pathologies. Frozen section examination could not be performed

in our hospital in emergency conditions. Incisional biopsies were performed for suspicious lesions in the abdominal cavity. In postoperative period, a deep investigation was performed for the diagnosis of the primary lesion. Patient was referred to senior center for advanced examination and therapy. Acute appendicitis is a very common emergency condition. The point is; like our case, sometimes metastatic lesions can cause the symptoms of acute appendicitis. Postoperative pathologic examination of the resected specimen must be evaluated carefully.

In some malignancies, resection of the second organ that is involved is known to improve the survival rates (i.e. metastatic colorectal liver cancer, pancreatic metastasis of renal cell tu-

mor, etc.). On the other hand, appendectomy does not seem to improve the survival rate in patients with secondary tumor of appendix (10).

CONCLUSION

Metastatic gastric carcinoma may rarely manifest itself with AA. While appendectomies are commonly performed in patients with acute abdomen, they may rarely serve as a differential diagnostic tool for detecting metastasis to distant organs.

Informed Consent: The patient was informed about all surgical and invasive procedures before surgery and during follow up. She was also expected to sign a form of approval.

Peer-review: Externally peer-reviewed.

Author Contributions: Concept - C.E., A.C.D., Y.Ö., Ö.D., H.G.M.D., G.Y., Y.K., Y.E.; Design - C.E., A.C.D., Y.Ö., Ö.D., H.G.M.D., G.Y., Y.K., Y.E.; Supervision - C.E., A.C.D., Y.Ö., Ö.D., H.G.M.D., G.Y., Y.K., Y.E.; Funding - C.E., Y.Ö., H.G.M.D., G.Y., Y.K.; Materials - C.E., Y.Ö., H.G.M.D., G.Y., Y.K.; Data Collection and/or Processing - C.E., A.C.D., Ö.D.; Analysis and/or Interpretation - C.E., Ö.D., H.G.M.D., Y.K., Y.E.; Literature Review - C.E., A.C.D., G.Y., Y.E.; Writer - C.E., A.C.D.; Critical Review - C.E., Y.Ö., Ö.D., Y.K., Y.E.

Conflict of Interest: No conflict of interest was declared by the authors.

Financial Disclosure: The authors declared that this study has received no financial support.

REFERENCES

1. Kim DY, Park YK, Joo JK, Ryu SY, Kim YJ, Kim SK, et al. Clinicopathological characteristics of signet ring cell carcinoma of the stomach. *ANZ J Surg* 2004; 74: 1060-1064. [\[CrossRef\]](#)
2. Rosai J. *Gastrointestinal tract carcinoma*. Surgical Pathology. Philadelphia, Mosby; 2004.
3. Lin CY, Huang JS, Jwo SC, Chen HY. Recurrent gastric adenocarcinoma presenting as acute appendicitis: a case report. *Int J Clin Pract Suppl* 2005; 147: 89-91. [\[CrossRef\]](#)
4. Gillesse EG, Mud HJ, Prins ME. An unusual cause of acute appendicitis. *Neth J Surg* 1987; 39: 153-154.
5. Møller P, Lohmann M. Acute appendicitis as primary symptom of gastric cancer. *Ann Chir Gynaecol* 1984; 73: 241-242.
6. O'Donnell ME, Carson J, Garstin WIH. Surgical treatment of malignant carcinoid tumours of the appendix. *Int J Clin Pract* 2007; 61: 431-437. [\[CrossRef\]](#)
7. Burney RE, Koss N, Goldberg IS. Acute appendicitis secondary to metastatic carcinoma of the breast. *Arch Surg* 1974; 108: 872-875. [\[CrossRef\]](#)
8. Bair MJ, Lee PH, Chan YJ. Urologic manifestations of acute appendicitis secondary to metastatic cervical cancer. *J Formos Med Assoc* 2007; 106: 784-787. [\[CrossRef\]](#)
9. Schmutzer KJ, Bayar M, Zaki AE, Regan JF, Poletti JB. Tumors of the appendix. *Dis Colon Rectum* 1975; 18: 324-331. [\[CrossRef\]](#)
10. Yoon WJ, Yoon YB, Kim YJ, Ryu JK, Kim YT. Secondary appendiceal tumors: a review of 139 cases. *Gut Liver* 2010; 4: 351-356. [\[CrossRef\]](#)