

Are radio-contrast agents commonly used in discography toxic to the intact intervertebral disc tissue cells?

Numan Karaarslan¹ | Ibrahim Yilmaz² | Hanefi Ozbek² | Duygu Yasar Sirin³ |
Necati Kaplan⁴ | Tezcan Caliskan¹ | Cigdem Ozdemir⁵ | Yener Akyuva⁶ | Ozkan Ates⁷

¹Department of Neurosurgery, Namik Kemal University School of Medicine, Tekirdag, Turkey

²Department of Medical Pharmacology, Istanbul Medipol University School of Medicine, Istanbul, Turkey

³Department of Molecular Biology and Genetics, Faculty of Arts and Sciences, Namik Kemal University, Tekirdag, Turkey

⁴Department of Neurosurgery, Corlu Reyap Hospital, Istanbul Rumeli University, Tekirdag, Turkey

⁵Department of Pathology, School of Medicine, Afyon Kocatepe University, Afyonkarahisar, Turkey

⁶Department of Neurosurgery, Gaziosmanpasa Taksim Training and Research Hospital, Istanbul, Turkey

⁷Department of Neurosurgery, Esencan Hospital, Istanbul Esenyurt University, Istanbul, Turkey

Correspondence

Numan Karaarslan, Department of Neurosurgery, Namik Kemal University School of Medicine, Tekirdag, Turkey.
Email: numikara@yahoo.com

Abstract

In the literature, there have been no studies showing clear results on how radio-contrast pharmaceuticals would affect intact disc tissue cells. In this context, it was aimed to evaluate the effects of iopromide and gadoteric acid, frequently used in the discography, on intact lumbar disc tissue in pharmaco-molecular and histopathological level. Primary cell cultures were prepared from the healthy disc tissue of the patients operated in the neurosurgery clinic. Except for the control group, the cultures were incubated with the indicated radio-contrast agents. Cell viability, toxicity and proliferation indices were tested at specific time intervals. The cell viability was quantitatively analysed. It was also visually rechecked under a fluorescence microscope with acridine orange/propidium iodide staining. Simultaneously, cell surface morphology was analysed with an inverted light microscope, while haematoxylin and eosin (H&E) staining methodology was used in the histopathological evaluations. The obtained data were evaluated statistically. Unlike the literature, iopromide or gadoteric acid did not have any adverse effects on the cell viability, proliferation and toxicity ($P < 0.05$). Although this study reveals that radio-contrast pharmaceuticals used in the discography, often used in neurosurgical practice, can be safely used, it should be remembered that this study was performed in an in vitro environment.

KEYWORDS

cytotoxicity, discography, intact intervertebral disc, primary cell culture, radio-contrast agents

1 | INTRODUCTION

Low back pain stemming from the intervertebral disc is described by two separate but related aetiologies: disc herniation and discogenic pain.¹ A definitive diagnosis of lumbar discogenic pain is difficult. It cannot be diagnosed using conventional computerized tomography where the contrast medium is not used. However, it can be diagnosed by provocative discography or magnetic resonance imaging (MRI). In some studies, with a high-evidential value, it is

emphasized that MRI can determine how serious the disc degeneration is, while it can be insufficient to determine the degree of pain in the degenerated disc. In addition, it has been reported that there may be no linear relationship between the degree of disc degeneration and the symptoms of the patient.^{2,3}

To assist treatment management, discography, also known as a discogram, is a diagnostic procedure used to determine whether low back pain originates from one or several discs. In the provocative discography, the contrast

medium is injected into the disc and the discogenic pain sensation is regenerated with increasing intradiscal pressure.⁴

After the patient is laid down on a table, which has a fluoroscopic unit, on prone or side position, it is entered up to the outer edge of the disc with the guide needle using the fluoroscopy. A thinner needle is inserted through the guide needle into the centre of the disc. This process can be repeated for multiple discs. When all the needles are placed, the pressure is applied to the discs with a contrast medium injection. With each injection, the patient feels pain or pressure. If the pain is felt, it is demanded to compare this pain with the patient's previous pain. If the pain level is the same, this may reveal diseased disc. After checking each disc, the images are taken in the fluoroscopy unit. Computed tomography (CT) may be taken to obtain additional images of the discs. However, numerous studies have found that provocative discography has a relatively high false-positive rate and that this may accelerate degenerative changes due to the morbidity associated with needle penetration into the disc.³⁻⁶

In addition, studies⁷⁻¹¹ with a high-evidential value regarding degenerated nucleus pulposus (NP) tissue have been reported in the literature. However, there have been no published studies displaying the exact results of how the pharmacological agents to be applied in this method would exert an effect on the intact lumbar disc tissue. In this study, which is the first in the literature, it was aimed to evaluate the effects of the pharmaceuticals frequently applied in the discography, on the intact lumbar disc tissue at pharmaco-molecular and histopathological level.

2 | MATERIALS AND METHODS

2.1 | Ethical approval

The study was carried out with the approval of the local ethics board (Istanbul Medipol University School of Medicine, Local Ethic Committee, 29.11.2017-10840098/604.01.01/E.44192).

The researchers were blind to the applied drug and the dose of the drug. The analyses were performed by the same researchers to minimize experimental errors. All the analysis and experiments were repeated at least three times.

2.2 | Study design and the in vitro experiment set-up

Standard primary cell cultures were prepared from the intervertebral disc tissue obtained from six patients.^{12,13} Drugs used in the routine discography were added to the cell culture dishes after adding Dulbecco's modified Eagle's medium (DMEM Cat#41965062; Gibco, USA) solution at appropriate concentrations. Subsequently, molecular and histopathological analyses were performed simultaneously.

2.3 | Selection criteria for the inclusion of the cases, whose tissues were used in the cell culture, in the study

The study comprised 11 volunteers admitted to the emergency department after spinal trauma. The tissues of the patients with a history of smoking (n = 2) and alcohol consumption (n = 1) and the patients with rheumatological disease (n = 1) and using antidepressant drugs (n = 1) inhibiting the cytochrome CYP3A4 group were not used in the preparation of cell cultures. A lumbar MRI evaluation was performed on the patients applied to our emergency department with the complaint of spinal trauma. After this evaluation, it was planned to operate on the patients diagnosed with spinal instability and spinal cord compression originating from traumatic intervertebral disc herniation. The intact intervertebral disc tissues of six patients (average age: 39.41 ± 9.16 years), who had posterior transpedicular stabilization, lumbar laminectomy and discectomy as a surgical modality, were included in the study.

2.4 | Preparation of human primary lumbar disc tissue cell cultures

Disc and granulation tissues were transferred to the laboratory under a temperature of 40°C in DMEM solution containing 1% penicillin-streptomycin (Cat#: 15140122, Gibco), 15% foetal bovine serum (FBS; Cat#10082147) and 1% L-glutamine (Cat# 25030081, Gibco). The samples taken in the laminar flow cabinet (Air Flow-NUVE/NF-800 R, Ankara, Turkey) were irrigated with 0.9% isotonic sodium chloride solution to remove the red blood cells and artefacts. After the tissues were broken up into the pieces that had approximately 0.3-0.4 cm³ size, they were transferred to the Falcon tubes containing 0.425 mg collagenase type II enzyme (1 mg/mL; Invitrogen Corp., Sigma Chemical, St. Louis, MO, USA) solubilized in the Hank's Balanced Salt Solution (HBSS-1X, 14025, Gibco). These samples were incubated overnight in an incubator (NUVE, 06750, Ankara, Turkey) which was set to a temperature of 37°C and 5% CO₂. The samples were then centrifuged at 4°C and 1.200 rpm for 10 minutes. After this process, freshly prepared cell culture medium was added to the cell pellets found at the bottom of the tube, and the cells, which were transferred to T75 flasks, were incubated.

Confluent primary cell cultures were passaged and in the third passage, the cells stained with Trypan blue were counted under an inverted light microscope (Olympus CKX41, Germany). The counted cells were seeded at 1.3 x 10⁴ cells per well for MTT [3-(4,5-dimethylthiazol-2-yl)-2,5-diphenyltetrazolium bromide (MTT), Vybrant MTT Cell Proliferation Assay, Cat#V13154, Thermo Fisher Scientific, Waltham, MA, USA.] viability proliferation and

toxicity analysis. For inverted light microscopy and acridine orange/propidium iodide staining (AO/PI) assays, the cells were seeded at 3.3×10^4 cells per well in 96-well plates. The counted cells were also seeded at 4.3×10^6 cells in each Petri dish in Petri dishes (35 mm^2) for histopathological evaluation. After overnight incubation, drugs were added to perform experiments on the cell cultures that became confluent and adhered to the floor.

2.5 | Preparation of the pharmaceutical preparations routinely used in the discography and their addition to the cell culture medium

Group I, referred to as the control group, consisted of pure human primary intact annulus fibrosus (AF)—NP cell cultures where no drug was administered.

The pharmaceutical preparations, prepared by adding the DMEM medium separately in the laminar flow cabinet, were taken in dark bottles, and the letter coding was performed. Subsequently, they were added to the cells, which were seeded in the wells, called group I, II and III, respectively (Table 1).

2.6 | Performed molecular analysis

Cell viability, toxicity and proliferation indices were quantitatively investigated through MTT-ELISA (Mindray MR 96A, PRC, Georgia Tech, Atlanta, GA, USA) assays at 0th, 2nd and 6th hours. In addition, MTT-ELISA assays were confirmed with microphotographing by simultaneous AO/PI staining analysis. The cell surface morphologies of the samples in all groups were evaluated with an inverted light microscope.

During the analysis carried out with the inverted light microscope, the cells and surrounding microcircuit organizations were displayed in various magnifications such as confocal scanning, $\times 4$, $\times 10$, $\times 20$ and $\times 40$. In the evaluation process, Olympus Cell Soft Imaging Program was used.

TABLE 1 Drugs, commercial stock solution concentration and application dose

Groups	Drugs	Stock solution concentration	Application dose
Group I (n = 6)	None		-
Group II (n = 6)	Iopromide (Ultravist [®])	0.769 g/mL	0.0025 mmol/mL
Group III (n = 6)	Gadoxetic acid (Primovist [®])	181.43 mg/mL	0.39 mg/mL

2.6.1 | AO/PI staining

To determine cell viability and confirm MTT results, nucleic acid-binding dyes AO and PI were used. AO stain all nucleated cells, whether alive or dead, producing green fluorescence. PI enters only dead cells with poor membrane integrity and stains nucleated cells to generate red fluorescence. When stained with both AO and PI, all live nucleated cells produce green fluorescence, and all dead nucleated cells produce red fluorescence. To prepare the AO/PI stain, 4-mg AO (dissolved in 2-mL 99% ETOH), 10-g sodium-ethylenediaminetetraacetic acid, 4-mg PI and 50 mL FBS were mixed well and sterile distilled water was added to reach a 200-mL final volume.¹⁴⁻¹⁷

2.6.2 | MTT-ELISA assays

The viability tests were performed using an MTT commercial kit which inhibits formazan crystal formation in dead cells. Absorbances were recorded at 570 nanometre (nm)s. The viability of the control group prior to contrast agent addition was accepted as 100%. After the proliferation and the inhibition of the proliferation were calculated using following formulas, respectively, “Test OD/Control ODX100” and “1- Test OD/Control OD,” data were recorded for statistical analysis. Cell viability absorbances were recorded at 2nd and 6th hours.

2.6.3 | Haematoxylin and eosin staining of cells for histopathological examination after fixation

The cells taken in special Petri dishes for histopathological evaluation were fixed with a mixed solution prepared with glutaraldehyde (8%) and cacodylate buffer (25%). The cells, which were washed three times with phosphate-buffered saline, were then stained with H&E, and they were evaluated under the inverted light microscope at various magnifications such as $\times 4$, $\times 10$, $\times 20$ and $\times 40$. Four fields were counted randomized at $\times 10$ magnification, and the average number of the chondrocytes was taken.

2.7 | Statistical evaluation of the obtained data

The results were evaluated using the cell numbers and proliferation. Statistical analyses were performed using Minitab v 16.0 software. The results were expressed as mean \pm standard deviation. One-way analysis of variance (ANOVA) was used for statistical comparisons among the groups. When the variances were equal, Tukey's honestly significant difference test, one of the post hoc tests, was performed since the numbers of samples in the groups were

equal after ANOVA. The alpha significance level was accepted as <0.05 .

3 | RESULTS

After evaluating the radio-contrast agents applied to primary cell cultures at the pharmaco-molecular level within the dose-time relationship, the relationship between drug concentration and proliferation was reported to be statistically significant ($P < 0.05$). When the proliferation was evaluated according to the time from 0th to 48th hours, the results were found to be statistically insignificant ($P > 0.05$) (Figure 1).

It was observed that the proliferation in Group II, to which iopromide was applied, decreased in the 48th-hour measurements compared to Group I—the control group—and to which no drug was applied, and to Group III to which Gadoxetic acid was applied. However, this situation was not evaluated as a suppression of the proliferation of the intervertebral disc tissue cells by iopromide. No images were observed, which were considered as evidence of the cytotoxicity with altered morphology through the inverted light microscope and in the AO/PI stainings examined with fluorescence microscope (Leica DM 2500, Germany) (Figure 2). Cell cultures were further analysed after H&E staining where the results were the same (Figure 3).

In the microphotograph shown in Figure 2(E), only one cell was found to be red fluorescent, because the cell was about to die, and the other cells were healthy and proliferated. Analyses carried out by an inverted light microscope revealed that the cells to which the radio-contrast preparations were applied, compared to the control group, were adhered to the adhesive surface, their proliferation continued, and they were healthy.

In all groups, fibrous bands with the regular settlement and healthy chondrocytes were observed in NF, while the

continuity of AF remained unchanged and homogenization did not disappear.

Histopathologically, it was observed that there was no difference to support the disc degeneration between the drug-administered groups and the non-drug-administered control groups (Figure 3).

It was observed that there were similar images between the control group and the drug-treated groups and that the environmental structures were not deteriorated. In addition, it was noted that the chondrocytes count in the control group samples and drug-administered samples were approximately the same.

4 | DISCUSSION

Currently, CT and especially MRI are used extensively in the evaluation of mechanical low back pain. These tests provide anatomically correct and accurate information about disc morphology, dural sac and nerve root pressures. However, the success of imaging is based on determining the relationship between the anatomical features of the pain and the radiological findings.

Brain, spinal cord and nerve surgery are rapidly developing; thanks to the innovations in medical technology, and in parallel, various radiological imaging techniques are used to make an accurate diagnosis before starting appropriate treatment. Discography has been used extensively in the detection of the level of symptomatic disc degeneration in low back pain originating from the degenerative disc disease. Thus, this procedure and the related researches have gained popularity again in recent years.

Discography is the only procedure where the symptomatic level can be determined through pain provocation during injection. In diverse studies, it has been reported that discography is a valuable procedure that should be used with limited indications in the imaging of the disc

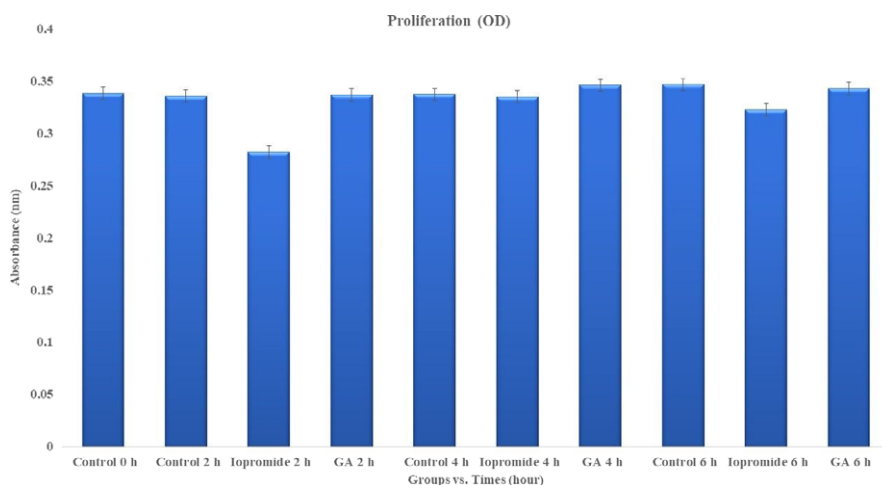


FIGURE 1 Assessment of the data obtained from iopromide and gadoxetic acid-applied intact tissue by means of the post hoc Turkey pairwise comparison test after one-way ANOVA (grouping information using the Tukey method and 95% confidence interval). GA, gadoxetic acid and OD, optical density

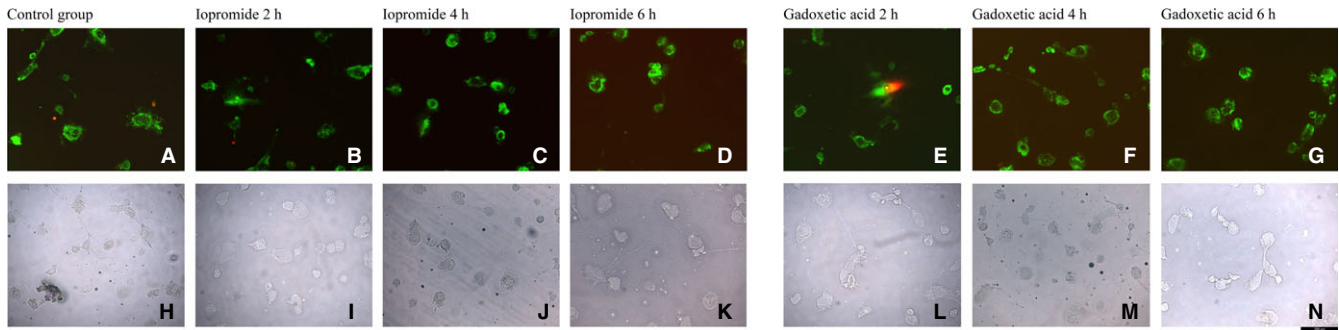


FIGURE 2 AO/PI staining images of primary cell cultures isolated from human intervertebral disc tissue. These are the images (A and H) of the control group samples and where the radio-contrast agents were not administered. These are fluorescent microimages displayed at 2nd (E), 4th (F) and 6th (G) hour in the gadoxetic acid-administered culture samples. These are the AO/PI staining-fluorescence images displayed at 2nd (B), 4th (C) and 6th h after iopromide was administered to the culture samples, (I-k) are the images from the inverted light microscope in iopromide-administered culture samples. In the same time periods, (E-G) are the fluorescence images obtained after AO/PI staining in cultures where gadoxetic acid preparation was applied, and (L-N) are inverted light microscope images of the samples treated with gadoxetic acid

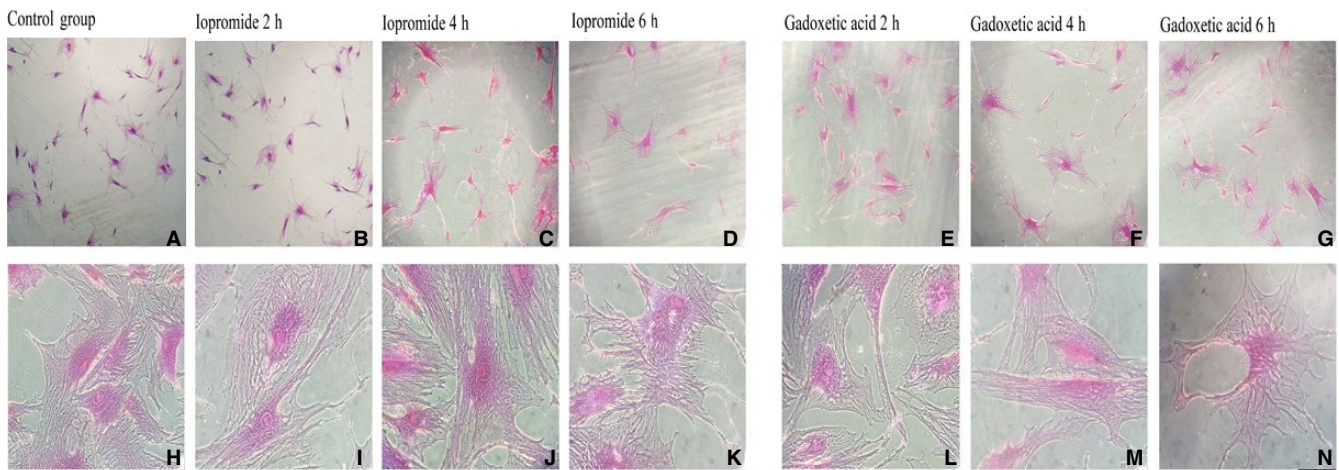


FIGURE 3 H&E staining. It was observed that the homogenization of matrix structures similar to the extracellular structure in the microenvironment of the non-drug-administered cells in the control group was not affected after the administration of different drugs containing radio-contrast

degeneration and in the evaluation of mechanical low back pain.^{5,18}

In the patients with discogenic back pain, MRI, CT and/or myelography are used for diagnosis. After failed lumbar surgery, these imaging studies may be inadequate in distinguishing recurrent disc herniation from the epidural scar. Sometimes, the results of these tests leave the clinician in doubt. If the patient is presenting with persistent pain after surgery, discography may be preferred for the evaluation and the diagnosis prior to the application of the treatments such as chemonucleolysis, fusion or analgesic injection into the disc space. However, the most important and frequently used indication is the detection of the symptomatic level in cases of disc degeneration in many levels revealed by CT and MRI.¹⁹

Thanks to this procedure, conventional discography, CT discography and lumbar MRI are used in the patients with low back pain that is thought to be discogenic. MRI can be generally performed on the same day as discography and before the discography. The discography is performed using various classifications such as Modified Dallas Classification in evaluating the annular tear and extravasations of the intervertebral disc. C-arm digital fluoroscopy is used during this process. In the patients, the antisepsis of the paravertebral region is followed by the spinous process marking at the level of the discography. The level is then identified. In the presence of the fluoroscope, the targeted intervertebral disc is entered by following a paramedian, oblique and extradural route using a 20-gauge *Chiba* needle. Water-based, non-ionic, iodinated contrast substances such as 1-1.5-cc Iopromide are injected through a 2-cc

injector connected to *Chiba* needle. Whether the contrast medium reached the AF tissue is controlled with the fluoroscope. After injection, the graphs are taken on anteroposterior and lateral projections, which centralize the examination level. After the discography, the patient can be assessed, at the latest within half an hour, by performing CT analyses where the sections are taken from the injected intervertebral disc levels.¹⁹

Norman et al²⁰ reported in a study that gadopentetic acid-derived paramagnetic contrast products such as gadoxetic acid containing gadolinium ion were used in MRI in radiology clinics when it was needed for lesion detection and diagnostic evaluation and that the preparations containing gadolinium were highly toxic when used alone and it might cause tissue necrosis by dispersing to the bone or liver tissue.²⁰

Rohrer et al²¹ reported that such contrast agents were converted into a complicated structure with other molecules called *chelates* in the pharmaceutical industry, to avoid high toxicity of gadolinium-containing preparations. They indicated that gadolinium chelates were two different structural categories, the first of which were cyclic chelates such as gadoteridol and gadoterate meglumine, and that Gd^{+3} was trapped in a cavity in these preparations. They also expressed that the second one was linear chelate preparations such as gadodiamide and gadopentetate dimeglumine.²¹

Schmitt-Willich et al²² pointed out that the stability of gadolinium chelates might differ from their linearity or cyclicity. They reported that cyclic molecules were more tightly bound to Gd^{+3} than linear molecules and had a more stable structure. They emphasized that ionic cyclic chelates were the least prone to release of free Gd^{+3} and had the longest dissociation half-life. In addition, they underlined that nonionic linear gadolinium chelates were the most susceptible agents for the release of free Gd^{+3} in the body.²²

Literature searches were carried out using the keywords "Lumbar discography," "cell culture," either individually or combined ("OR" and "AND"), in Cochrane Collaboration, the Cochrane Library, Ovid MEDLINE, ProQuest, the National Library of Medicine and PubMed electronic databases, without language and country restrictions. Only five studies with high-evidential value were found.⁷⁻¹¹

Kim et al⁷ indicated that iodinated contrast media (CM) was commonly used for various intradiscal injections such as in discography and endoscopic spinal surgery. However, they reported that the CM was known to be toxic to renal tissues due to ionic strength, osmolarity and/or iodine-induced cytotoxicity and that there were concerns about whether there were similar negative effects on the disc cells.⁷ In this *in vitro* design study, they aimed to identify the least cytotoxic iodinated CM to the human disc cell

among four different physiochemical iodinated contrast dyes.⁷

In doing this, they obtained intervertebral disc tissue by discectomy from a total of 10 lumbar disc patients undergoing surgery and disc cells were isolated. They added CM solution at different doses to cell cultures. They also added mannitol solution instead of CM to the control group cell cultures. After analysing the live cells with Trypan blue staining, they performed fluorescence-activated cell sorting analysis using Annexin V and PI staining to identify live, apoptotic and necrotic cells. They reported that human disc cell death was time- and dose-dependent in response to CM. However, they emphasized that non-ionic dimeric CM showed the least toxic effect on human disc cells. They concluded that careful attention should be paid to the type of CM picked for discography and endoscopic spinal surgery.⁷

Kim et al¹⁰ indicated that ioxitalamate, an ionic iodinated contrast medium, was commonly used for discography or percutaneous endoscopic lumbar discectomy (PELD), even though it had side effects such as anaphylactic shock and renal toxicity. They stated that the indigo carmine, a dye with a distinctive blue colour, was commonly used to stain degenerated NP cells during PELD and that it was widely used in spinal surgery. In this study,¹⁰ where they investigated the toxic effects of these substances, frequently used in practice, on NP cells, they isolated NP cells obtained from the tissues of the lumbar disc patients through discectomy. They evaluated the effects of these substances, which were applied at different concentrations, on NP cells for up to 72 hours. They used the Trypan blue staining to analyse whether the cells were healthy and alive. They carried out fluorescence-activated cell sorting analysis using Annexin V and PI staining to identify apoptotic and necrotic cells. They stated that the toxic effects of the pharmaceuticals administered *in vitro* varied increasingly depending on the time and dose concentration. They suggested that ioxitalamate and indigo carmine should be used carefully at low concentrations in patients undergoing discography and PELD. More importantly, they underlined that ioxitalamate, indigo carmine and their combination caused statistically NP cell injury that was both time- and dose-dependent.¹⁰

Gruber et al¹¹ referred to the study of Carragee et al, where they indicated that modern discography injections were associated with subsequent acceleration of disc degeneration, herniation and loss of disc height. Furthermore, they pointed out that the pressure produced by needles and injections caused trauma, which might create disc degeneration in animal models in which live mammal subjects were used. However, they underlined that the other possible cause of clinical discography-associated degeneration was the direct effect of contrast media on disc cells.¹¹

In this *in vitro* study,¹¹ in which the deleterious effects of the discography contrast solution on human AF cells were investigated, cell cultures were prepared from the patients' (n = 8) surgical disc samples. In normal culture conditions, they used two separate control groups: cell cultures without added drugs and cell cultures with added glucose to adjust the osmolarity. In cell cultures supplemented with iopamidol, after 24 hours of incubation, the percentage of dead cells was determined with the Trypan blue staining. They reported a significant increase in the percentage of dead cells with increasing iopamidol compared to the control cells.¹¹

In this study,¹¹ they stated that disc degeneration and low back pain were observed in almost 80% of the general human population, and therefore, discography might apply to many patients. They noted that the proliferation of cells exposed to radio-contrast agents with adjustment for osmolarity decreased and many cells died due to the increase in apoptosis. In the light of the degeneration-related decrease in disc cell numbers, they concluded that the exposure to radio-contrast might cause significant loss of disc cells.¹¹

The cells used in such studies^{7,10,11} have been isolated from degenerated intervertebral disc tissue. In this circumstance, the viability, proliferation and health of the cells are doubtful. The addition of medication to a degenerated tissue will further complicate the situation and raise doubts as to whether the cytotoxicity they indicated has originated from the radio-contrast drug or from local anaesthetics that have been repeatedly proven to be toxic to tissues. More importantly, cell cultures are an experimental set-up carried out outside the body in a laboratory environment, in which there are no compensatory mechanisms that defend and protect the tissues in the body. Therefore, it is also possible that the applied drug may exhibit pseudo-toxic effects in the degenerated tissues already taken outside the body, which cause a vulnerability.

We believe that the results we obtained may be more reliable because, in our own research, we have investigated the toxicity of drugs in primary cell cultures obtained from healthy tissues, not from degenerated tissues.

Iwasaki et al⁸ indicated that a small dose of local anaesthetics was injected into the analgesic discography to diagnose or treat discogenic low back pain. They stated by referring to the literature that local anaesthetic agents were reported to be toxic to cells in many tissues, including intervertebral disc cells. In this study, they used an organotypic culture model and *in vivo* long-term follow-up model.⁸ They applied lidocaine (1%) and bupivacaine (0.5%) to the established cultures. On the one hand, they investigated the destructive effects of these pharmaceuticals on cultured intervertebral disc cells, and on the other hand, they investigated the deleterious effect of the injection. To

accomplish this, they tested the NP cell deaths by histological analysis using a confocal microscopy. They injected each local anaesthetic agent into rabbit intervertebral discs under a fluoroscope. Six or 12 months after the injection, they prepared intervertebral disc cells for MRI and histological analysis. They expressed that they could not detect too much change with MRI. However, they indicated that in the organotypic culture model, compared to the control group, there was no strong evidence that the anaesthetic agents were toxic to the intervertebral disc cells, except for the initial mechanical damage due to pressurized injection. They finally underlined that further studies should be performed to investigate the deteriorative effects of the local injection of analgesic agents on degenerated intervertebral disc cells.⁸

In a similar study,⁹ they reported an accelerated progression of lumbar intervertebral disc degeneration after discography. In this study, where local anaesthetics and contrast agents were shown to exhibit toxicity to cardiac, renal and neuronal cells and to cells located in the disc tissue, they used AF and NP cells in a three-dimensional (3D) culture system. In this way, they investigated the effects of contrast agents used in combination with local anaesthetics on the intervertebral disc tissue cells *in vitro* to guide their usage in future clinical trials.⁹ They used bovine NP and AF cells cultured in a 3D system. They added local anaesthetics and contrast agents used commonly used in discography to the culture cells. After adding two different dilutions (1:2 and 1:4) of nonionic contrast agents, iohexol and iopamidol, to the culture medium, they performed analysis at 2nd, 6th and 16th hours. They visualized live cells (fluorescing green) and dead cells (fluorescing red) using fluorescent microscopy. They observed more cell death when NP and AF cells were incubated with local anaesthetics than contrast agents at the concentrations tested. They reported that diluted iopamidol (1: 2) caused less cell death than iohexol. They underlined the need for further studies regarding the effects of these contrast agents in organ culture or animal models.⁹

As it is seen in the literature, experimental set-ups are generally established using animal tissues as live mammalian subjects in the studies of toxicity or cytotoxicity. As it is known that the sensitivity of human and animal tissues is different, therefore, the results obtained can be different and misleading as well.^{23–28} In many studies where animal tissues are not used, commercial cell lines are used.^{16,23,24,27–30}

In addition, in systems such as cell lines, one type of cell is used. Apart from this, there are no complicated coordination mechanisms with the microcircles of the cells in such commercial cell lines. As a result, the *in vitro* test results, which are difficult to comply with *in vivo* conditions, may become even more controversial since the cell does not interact with formations such as extracellular

matrix structure. Besides, since the genetic structure of the cells in the cell line has been modified, they will not carry the genotypic and/or phenotypic characteristics that they have in the human body.^{14-17,23-25,29,30}

As a result of MTT-ELISA viability, proliferation and toxicity analyses, there was no significant difference between the control group and the groups in which iopromide and gadoteric acid drugs were administered in the cell cultures of the intervertebral disc tissues and these results were reported to be statistically significant ($P < 0.05$). In addition, no images were observed, which were considered as evidence of the cytotoxicity in the AO/PI staining results obtained through the inverted light microscope or fluorescence microscope and in the microimages from the inverted light microscope obtained after H&E staining. In all groups, fibrous bands with the regular settlement and healthy chondrocytes were observed in NF, while the continuity of AF remained unchanged and homogenization did not disappear. Histopathologically, it was observed that there was no difference that supported the disc degeneration between the drug-administered groups and the non-drug-administered control groups. All these qualitative microimages made our statistically meaningful results ($F = 8.3$; $P = 0.001$) of quantitative proliferation assays more reliable.

In conclusion, unlike the literature, we did not observe, molecularly or histopathologically, any adverse effect of iopromide or gadoteric acid on cell health or proliferation when applied to nondegenerate, intact AF/NP primary cell cultures. As it is known, the grading of the toxic effect of the drug is associated with the idiosyncratic and genetic difference-related reactions in the subject. The drug which is toxic to any person or race may not be toxic to another person and/or race.

In summary, if a drug is administered to a patient and there is another accompanying disease in this patient, the disease may increase the side effects of the administered drug, as it is known that drugs may cause more adverse reactions depending on the food consumption, smoking and alcohol use.^{14-17,24,25,29,30} Therefore, in this study, we selected the patients, whose tissues were used in the preparation of primary cell cultures, who did not smoke, did not use alcohol or did not use drugs that inhibited the CYP3A4 group.

The real limitation of this study was not only that it had an in vitro experimental set-up. The real limitation was the establishment of cultures from tissues obtained from a total of six patients. The limited number of samples and the fact that tissues were taken from the patients of the same race were limitations of this study. However, at least three cultures of each case were established and at least 3 techniques were repeated in all experiments. As it is known, gene expression is also caused by individual differences, so

it is necessary to study with mechanisms that involve more number of cases, where more races will exist.

5 | CONCLUSION

The cytotoxicity of radio-contrast pharmaceuticals used in the discography, which is a minimally invasive method used in the diagnosis and treatment of chronic discogenic pain, has been investigated at the pharmaco-molecular level in this study. The evidence obtained after the research was the result of a design study carried out via an in vitro experimental set-up. Although this study revealed that radio-contrast pharmaceuticals used in the discography, often used in neurosurgical practice, can be safely used, it should be remembered that this study was performed in an in vitro environment. It is also another important issue that the clinician should always consider the fact that any drug may be toxic to tissues due to the risk that any drug may suppress cell proliferation and differentiation.

ACKNOWLEDGEMENT

None.

CONFLICT OF INTEREST

The authors report no conflict of interests.

CONSENT

Informed consent for the use of their cells was obtained from patients attending the Neurosurgery Clinic.

REFERENCES

1. Peng B, Fu X, Pang X, et al. Prospective clinical study on natural history of discogenic low back pain at 4 years of follow-up. *Pain Physician*. 2012;15(6):525-532.
2. Lotz JC, Haughton V, Boden SD, et al. New treatments and imaging strategies in degenerative disease of the intervertebral disks. *Radiology*. 2012;264(1):6-19.
3. Carragee EJ, Hannibal M. Diagnostic evaluation of low back pain. *Orthop Clin North Am*. 2004;35(1):7-16.
4. Carragee EJ, Lincoln T, Parmar VS, Alamin T. A gold standard evaluation of the "discogenic pain" diagnosis as determined by provocative discography. *Spine (Phila Pa 1976)*. 2006;31(1):2115-2123.
5. Carragee EJ, Paragioudakis SJ, Khurana S. 2000 Volvo Award winner in clinical studies: lumbar high-intensity zone and discography in subjects without low back problems. *Spine (Phila Pa 1976)*. 2000;25(23):2987-2992.
6. Zheng Y, Liew SM, Simmons ED. Value of magnetic resonance imaging and discography in determining the level of cervical discectomy and fusion. *Spine (Phila Pa 1976)*. 2004;29(19):2140-2145.

7. Kim KH, Park JY, Park HS, et al. Which iodinated contrast media is the least cytotoxic to human disc cells? *Spine J.* 2015;15(5):1021-1027.
8. Iwasaki K, Sudo H, Yamada K, et al. Effects of single injection of local anesthetic agents on intervertebral disc degeneration: ex vivo and long-term in vivo experimental study. *PLoS ONE.* 2014;9(10):e109851.
9. Chee AV, Ren J, Lenart BA, Chen EY, Zhang Y, An HS. Cytotoxicity of local anesthetics and nonionic contrast agents on bovine intervertebral disc cells cultured in a three-dimensional culture system. *Spine J.* 2014;14(3):491-498.
10. Kim KH, Kim YS, Kuh SU, et al. Time- and dose-dependent cytotoxicities of ioxitalamate and indigocarmine in human nucleus pulposus cells. *Spine J.* 2013;13(5):564-571.
11. Gruber HE, Rhyne AL 3rd, Hansen KJ, et al. Deleterious effects of discography radiocontrast solution on human annulus cell in-vitro: changes in cell viability, proliferation, and apoptosis in exposed cells. *Spine J.* 2012;12(4):329-335.
12. Karaarslan N, Yilmaz I, Ozbek H, Sirin Yasar D, Kaplan N, Akyuva Y, Gonultas A, Ates O. Are specific gene expressions of extracellular matrix and nucleus pulposus affected by primary cell cultures prepared from intact or degenerative intervertebral disc tissues? *Turk Neurosurg.* 2018; <https://doi.org/10.5137/1019-5149.JTN.22210-17.2> Accessed 22 January.
13. Akyuva Y, Karaarslan N, Yilmaz I, et al. How scaffolds, which are polymeric drug delivery systems allowing controlled release, can be tested in human primary nucleus pulposus and annulus fibrosus cell culture? *Merit Res J Med Med Sci.* 2017;5(10):477-487.
14. Sirin DY, Kaplan N, Yilmaz I, et al. The association between different molecular weights of hyaluronic acid and CHAD, HIF-1 α , COL2A1 expression in chondrocyte cultures. *Exp Ther Med.* 2018;15:4205-4212.
15. Karaarslan N, Sirin DY. Evaluation of the effects of pregabalin on chondrocyte proliferation and CHAD, HIF-1 α , and COL2A1 gene expression. *Arch Med Sci.* <https://doi.org/10.5114/aoms.2018.73134>. Accessed February 2, 2018.
16. Karaarslan N, Batmaz AG, Yilmaz I, et al. Effect of naproxen on proliferation and differentiation of primary cell cultures isolated from human cartilage tissue. *Exp Ther Med.* 2018;16(3):1647-1654.
17. Karaarslan N, Yilmaz I, Sirin DY, et al. Pregabalin treatment for neuropathic pain may damage intervertebral disc tissue. *Exp Ther Med.* 2018;16(2):1259-1265.
18. Aprill C, Bogduk N. High-intensity zone: a diagnostic sign of painful lumbar disc on magnetic resonance imaging. *Br J Radiol.* 1992;65(773):361-369.
19. Jarvik JG, Devo RA. Imaging of lumbar intervertebral disk degeneration and aging, excluding disk herniations. *Radiol Clin North Am.* 2000;38(6):1255-1266.
20. Normann PT, Hals PA. In vivo stability and excretion of gadodi- amide (GdDTPA-BMA), a hydrophilic gadolinium complex used as a contrast enhancing agent for magnetic resonance imaging. *Eur J Drug Metab Pharmacokinet.* 1995;20(4):307-313.
21. Rohrer M, Bauer H, Mintorovitch J, Requardt M, Weinmann HJ. Comparison of magnetic properties of MRI contrast media solutions at different magnetic field strengths. *Invest Radiol.* 2005;40(11):715-724.
22. Schmitt-Willich H. Stability of linear and macrocyclic gadolinium based contrast agents. *Br J Radiol.* 2007;80(955):581-582.
23. Komur B, Akyuva Y, Karaslan N, et al. Can a biodegradable implanted bilayered drug delivery system loaded with BMP-2/ BMP-12 take an effective role in the biological repair process of bone-tendon injuries? A preliminary report *J Pharm (Cairo).* 2017;2017:7457865.
24. Oznam K, Sirin DY, Yilmaz I, et al. Iopromide- and gadopentetic acid-derived prepartes used in MR arthrography may be harmful to chondrocytes. *J Orthop Surg Res.* 2017;12(1):98.
25. Gumustas F, Yilmaz I, Sirin DY, et al. Chondrocyte proliferation, viability and differentiation is declined following administration of methylphenidate utilized for the treatment of attention-deficit/ hyperactivity disorder. *Hum Exp Toxicol.* 2017;36(9):981-992.
26. Growney Kalaf EA, Flores R, Bledsoe JG, Sell SA. Characteriza- tion of slow-gelling alginate hydrogels for intervertebral disc tis- sue-engineering applications. *Mater Sci Eng C Mater Biol Appl.* 2016;63:198-210.
27. van den Akker GG, Surtel DA, Cremers A, et al. Novel immortal human cell lines reveal subpopulations in the nucleus pulposus. *Arthritis Res Ther.* 2014;16(3):R135.
28. Liu MC, Chen WH, Wu LC, et al. Establishment of a promising human nucleus pulposus cell line for intervertebral disc tissue engineering. *Tissue Eng Part C Methods.* 2014;20(1):1-10.
29. Isyar M, Yilmaz I, Yasar Sirin D, Yalcin S, Guler O, Mahi- rogullari M. A practical way to prepare primer human chondro- cyte culture. *J Orthop.* 2016;13(3):162-167.
30. Guzelant AY, Isyar M, Yilmaz İ, Sirin DY, Cakmak S, Mahi- rogullari M. Are chondrocytes damaged when rheumatologic inflammation is suppressed? *Drug Chem Toxicol.* 2017;40(1):13-23.

How to cite this article: Karaarslan N, Yilmaz I, Ozbek H, et al. Are radio-contrast agents commonly used in discography toxic to the intact intervertebral disc tissue cells?. *Basic Clin Pharmacol Toxicol.* 2019;124:181–189. <https://doi.org/10.1111/bcpt.13112>