

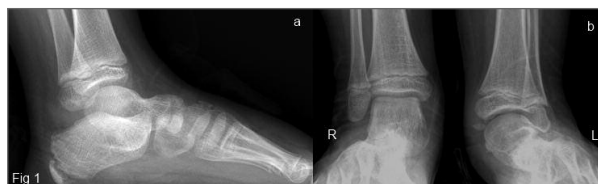## A pictorial view to tarsal coalition: the presentation of two children with foot pain

Ormeci T<sup>1</sup>, Kilicarslan R<sup>1</sup>, Durmus O<sup>2</sup>, Malkoc M<sup>3</sup>, Cakar E<sup>2</sup>

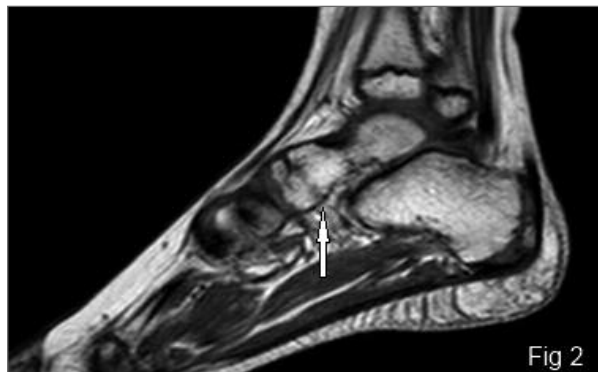
ACTA REUMATOL PORT. 2014;39:347-348

Two male patients aged 9 and 16 years were admitted with complaints of ankle pain and intoeing. There was no history of trauma and arthritis. In the first case, radiography examination revealed a “C sign” (a cortical continuity from the medial portion of the talus to the sustentaculum tali), a narrowing in the middle subtalar joint space, and convexity in the lower margin of the sustentaculum tali (Figure 1). Magnetic resonance imaging (MRI) showed triple coalition in the anterior subtalar joint (talocalcaneonavicular joint) in the first case (Figures 2 and 3) and fibrocartilaginous coalition at the posterior subtalar joint in the second case (Figure 4). Narrowing in the joint spaces, findings of early degeneration, and medullary edema in the adjacent bone were observed at the sites of coalition (Figures 3 and 4). Nonoperative treatment, such as physical therapy, exercises, and analgesic medication were applied.

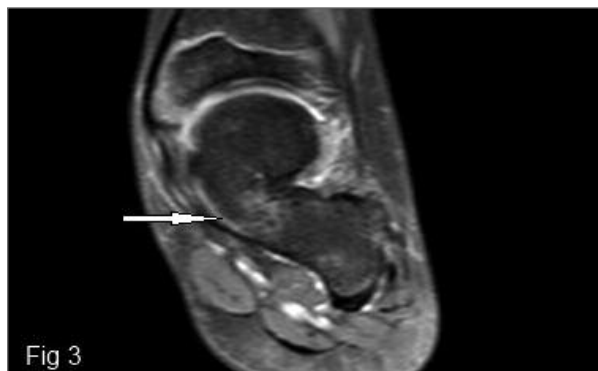
Tarsal coalition is one of the most important causes of pes planus and may cause foot pain in children. Tarsal coalition is the congenital or acquired fibrous, cartilaginous or osseous fusion of one or more tarsal bones. Although the described incidence of this condition is approximately 1% of the population<sup>1,2</sup>, the proportion of asymptomatic cases is much higher<sup>1</sup>. The most common coalitions are talocalcaneal and calcaneonavicular coalitions, which account for 90% of the observed cases<sup>1-3</sup>. Talocalcaneal coalition is observed in approximately half of the cases and often involves the middle subtalar joint, a finding similar to that observed in the first case<sup>2,3</sup>. Fusion at the level of the posterior subtalar joint, as observed in the second case, is an extremely uncommon occurrence<sup>3</sup>. Most cases are asymptomatic in the first years of life; however, the pathology progresses gradually because of biomecha-



**FIGURE 1.** A) Lateral radiograph of the left ankle shows the talocalcaneal C sign, suggesting subtalar coalition across the middle subtalar joint. B) Deformed talus of the left foot is displaced in the antero-posterior view



**FIGURE 2.** Sagittal T1 weighted spin-echo (TSE) image shows talonavicular osseous coalition (arrow)

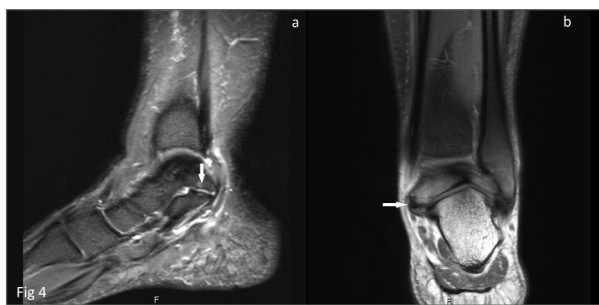

**FIGURE 3.** Coronal proton density (PD) fat saturated TSE image demonstrates the osseous connection with continuity of marrow fat from the talus to the calcaneus. There is mild bone marrow edema at the site of coalition (arrow)

1. Department of Radiology/Istanbul Medipol University, Faculty of Medicine, Istanbul

2. Department of Physical Medicine and Rehabilitation/Istanbul Medipol University, Faculty of Medicine, Istanbul

3. Department of Orthopedics and Traumatology/Istanbul Medipol University, Faculty of Medicine, Istanbul



**FIGURE 4.** A) Coronal and B) Sagittal FS TSE PD images of the second patient show fibrocartilaginous talocalcaneal coalition (arrow) involving posterior facets of the subtalar joints. Minimal degenerative are changes associated with the coalition

nical stress during physical activity. The coalition becomes osseous due to repetitive injury and remodeling, resulting in rigidity or instability<sup>2,4</sup>. Ankle pain and stiffness are the most common complaints in patients with tarsal coalition. The limited movement of the affected ankle, in particular the impairment of subtalar inversion or eversion, is the most common physical examination finding. The coalition leads to peroneal spasm or adaptive peroneal shortening, peroneal spastic flat foot or rigid flat foot deformity<sup>2</sup>. Direct radiography is the first diagnostic method of choice for patients with suspected talocalcaneal coalition<sup>1</sup>. The most useful radiological indicator for tarsal coalition is the “C sign” observed in lateral radiographs and the talar beak sign<sup>1,3</sup>. The absence of the subtalar facet and dysmorphic sustentaculum tali in lateral radiographs are other useful findings for the diagnosis of talocalcaneal coalition<sup>1,2</sup>. The visualization of talocalcaneal coalition on direct graphs is sometimes difficult due

to superposition of complex structures; thus, multiplanar imaging may be necessary<sup>3,4</sup>. Particularly, MRI provides valuable information in diagnosing nonosseous coalition, articular fusion, reactive changes such as arthritis, and periarticular bone marrow edema, as well as in detecting secondary degenerative changes that are important for surgery planning<sup>2,4</sup>. Computed tomography is described as the gold standard and is a more cost-effective diagnostic method<sup>5</sup> however, MRI can also be preferred for the initial diagnosis to avoid x-ray exposure, particularly in children.

#### CORRESPONDENCE TO

O Durmus  
Istanbul Medipol Universitesi Hastanesi,  
Fiziksel Tıp ve Rehabilitasyon Klinigi  
TEM Avrupa Otoyolu Goztepe Cikisi, No 1,  
Bagcilar Istanbul - TURKEY. 34214  
E-mail: durmusoguz@gmail.com

#### REFERENCES

1. Lawrence DA, Rolen MF, Haims AH, Zayour Z, Moukaddam HA. Tarsal Coalitions: Radiographic, CT, and MR Imaging Findings. *HSS J* 2014;10:153-166.
2. Newman JS, Newberg AH. Congenital tarsal coalition: multimodality evaluation with emphasis on CT and MR imaging. *Radiographics* 2000;20:321-332.
3. Staser J, Karmazyn B, Lubicky J. Radiographic diagnosis of posterior facet talocalcaneal coalition. *Pediatr Radiol* 2007;37:79-81.
4. Sijbrandij ES, van Gils AP, de Lange EE, Sijbrandij S. Bone marrow ill-defined hyperintensities with tarsal coalition: MR imaging findings. *Eur J Radiol* 2002;43:61-65.
5. Emery KH, Bisset GS 3rd, Johnson ND, Nunan PJ. Tarsal coalition: a blinded comparison of MRI and CT. *Pediatr Radiol* 1998;28: 612-616.