



ELSEVIER

Available online at www.sciencedirect.com

ScienceDirect

journal homepage: www.elsevier.com/locate/jor

Original Article

Efficacy of periarticular injection applied through knee other than posterior capsule in simultaneous bilateral total knee arthroplasty



Olcay Guler ^{a,*}, Serhat Mutlu ^b, Mehmet Isyar ^a, Harun Mutlu ^c,
Ahmet M. Bulbul ^a, Mahir Mahirogullari ^a

^a Medipol University Medical Faculty, Orthopedics and Traumatology Department, 34083, Istanbul, Turkey

^b Orthopedics and Traumatology Department, Kanuni Sultan Suleyman Training Hospital, 34303, Istanbul, Turkey

^c Orthopedics and Traumatology Department, Gaziosmanpaşa Taksim Training Hospital, 34200, Istanbul, Turkey

ARTICLE INFO

Article history:

Received 14 May 2015

Accepted 24 May 2015

Available online 13 June 2015

Keywords:

Periarticular drug injection

Total knee arthroplasty

Range of motion

Visual analog scale scores

Postoperative pain management

ABSTRACT

Background: We aimed to evaluate periarticular multimodal drug injection (PMDI) in bilateral total knee arthroplasty.

Methods: In 154 knees of 77 patients, PMDI was administered intraoperatively through the regions other than posterior capsule to one knee; other knee was control.

Results: Drug-injected knees had lower visual analog scale scores and higher passive range of motion postoperatively ($p < 0.05$). The active straight leg raise was higher in drug-injected knees (47 [61%] vs 19 [24.7%], $p = 0.001$).

Conclusions: PMDI is a safe and effective method of early postoperative pain management in total knee arthroplasty when applied through regions other than posterior capsule.

Copyright © 2015, Professor P K Surendran Memorial Education Foundation. Publishing Services by Reed Elsevier India Pvt. Ltd. All rights reserved.

1. Introduction

Postoperative pain is a major concern after total knee arthroplasty (TKA). Many patients experience moderate to severe postoperative pain, which leads to prolonged hospitalization and increased postoperative complications.^{1,2} A new pain control technique is periarticular injection of a large volume of low concentrations of local anesthetics, epinephrine, and anti-inflammatory agents such as nonsteroidal anti-inflammatory drugs or steroids, which is termed periarticular

multimodal drug injection (PMDI). Recent studies show that using this approach is effective in controlling pain and improving range of motion (ROM) after surgery.^{3,4} Several studies have reported that PMDI provides additional pain relief during the early postoperative period in TKA patients.^{5–7}

PMDI is generally performed through knee regions that have increased neurosensory perception and an elevated concentration of mechanoreceptors such as posterior capsule, collateral ligaments, quadriceps tendon, medial-lateral retinaculum, patellar tendon, and posterior cruciate ligament

* Corresponding author. Medipol University Medical Faculty, Orthopedics and Traumatology Department, Atatürk Bulvarı. No:27 Unkapani, 34083, Fatih, Istanbul, Turkey. Tel.: +90 212 444 8544; fax: +90 212 5317555.

E-mail address: olcayguler77@gmail.com (O. Guler).

<http://dx.doi.org/10.1016/j.jor.2015.05.012>

0972-978X/Copyright © 2015, Professor P K Surendran Memorial Education Foundation. Publishing Services by Reed Elsevier India Pvt. Ltd. All rights reserved.

tibial attachment.⁸ However, popliteal neurovascular structures are located very close to posterior capsule, which make them vulnerable to injury during PMDI. Previous anatomic studies indicated that terminal branches of popliteal artery branch at levels higher than tibial plateau in 1.2–16.4% cases.^{9,10} Furthermore, the tibial nerve and the common peroneal nerve, which are terminal branches of sciatic nerve, have been shown to have variant anatomy in popliteal region.^{11–14} Although these anatomic variations are well known, PMDI has been routinely applied through posterior capsule and PMDI applications from other knee regions have not been studied so far. To prove that PMDI is also effective when applied through regions other than posterior capsule is important to decrease risk of injury associated with PMDI through posterior capsule.

In this study, we aimed to evaluate the effects of a PMDI formulation applied through regions other than posterior capsule on postoperative pain, function, and adverse effects of surgery in patients undergoing simultaneous bilateral TKA, using the contralateral knee as a control.

2. Materials and methods

2.1. Study design and population

This was a retrospective, case–control study. Case group constituted of PMDI-injected knees of patients who had bilateral TKA. Control group included the contralateral non-PMDI injected knees. We evaluated 84 patients undergoing primary simultaneous bilateral TKA with epidural anesthesia from September 2011 to August 2013 to enroll in this study. The inclusion criteria were a diagnosis of primary varus osteoarthritis of the knee; flexion deformity of less than 15°, age less than 80 years, good mental function, and agreement to participate. We excluded seven patients for the following reasons: failure of installing epidural catheter ($n = 3$), discontinued epidural analgesia ($n = 3$), rheumatoid arthritis ($n = 1$). The study was continued with 77 patients (female/male, 67/10; mean age, 67.8 years; age range, 55–78 years) and 154 knees (77 control [37 right, 30 left]; 77 PMDI [30 right, 37 left]). All of the surgical and postoperative follow-up procedures were performed under routine clinical practice of our clinic. The study was approved by the Institutional Ethics Committee, all patients gave written consent for surgical intervention.

2.2. Arthroplasty and PMDI

Intraoperative PMDI was performed on one knee of each patient; the other knee served as control. The PMDI mixture contained 100-mg bupivacaine (0.5%, 20 mL), 40-mg methylprednisolone (2 mL), 300- μ g 1:1000 epinephrine (0.3 mL), 1000-mg ceftriaxone (10 mL), and 50 μ g fentanyl citrate (0.1 mL). These were mixed with sterile normal saline solution to a combined volume of 60 mL. The first 20 mL were injected into the soft tissue around the medial (10 mL) and lateral (10 mL) collateral ligaments after implantation of the arthroplasty components. The second 20 mL were injected into the retinacular tissues, pes anserinus, and suprapatellar and

infrapatellar fat pads after implantation, and after the capsule was closed, the remainder was administered to the quadriceps muscle, joint capsule, and subcutaneous tissues.

Following tourniquet application, a standard medial parapatellar arthrotomy, medial release, and a posterior-stabilized prosthesis were used in all patients. Arthrotomy was performed by one of two surgeons with minimum 6 years of experience (O.G. or S.M.). For 24 h postoperatively, a solution containing 2% prilocain HCl (3 mL), bupivacaine 0.5% (3 mL), 50 μ g fentanyl (1 mL), and saline (1 mL) was given via epidural bolus injection every 6 h or when the pain starts. After 24 h, epidural catheter was removed. In addition, 1000-mg acetaminophen (intravenous infusion every 8 h) and 75-mg diclofenac (intramuscular every 12 h) were administered on the first day after surgery. Between the second and fifth days, 500-mg oral paracetamol (every 8 h) and 75-mg intramuscular naproxen sodium (every 12 h) were administered. Thromboembolism prophylaxis consisted of anti-embolic stockings and subcutaneous administration of 4000 IU enoxaparin. Intravenous antibiotic prophylaxis with cefazolin sodium (1 g) was administered preoperatively and continued for two days postoperatively. Epidural catheters were removed after the first postoperative day. A continuous passive motion (CPM) machine was used after surgery to promote recovery of motion of the knee joint. On the first postoperative day, all patients were mobilized with the assistance of a walker.

2.3. Evaluation criteria

Pain intensity was self-reported using the visual analog scale (VAS), ranging from 0 mm (indicating no pain) to 10 mm (indicating extreme pain) in 1-mm increments. Other data collected included blood loss, ROM, and whether patients could complete an active straight leg raise (tested each day from postoperative day one to the day of discharge).

VAS pain scores were collected on postoperative days 0 (6 and 12 h), 1, 2, 3, 4, and 5. On the first, second, third, fourth, and fifth postoperative days, VAS pain scores were measured while patients were resting, walking, and on the CPM, separately. In addition, VAS pain scores were measured at the second and fourth postoperative weeks.

Active ROM of the both knee joints was measured preoperatively and at second and fourth weeks postoperatively. Passive ROM was measured at the first, second, third, fourth, and fifth days postoperatively.

2.4. Statistical analysis

Study data were summarized with descriptive statistics (mean, standard deviation, etc.). We used the paired-samples *t* test to compare VAS scores, ROM, and blood loss. The chi-square test was used to compare positivity of the active straight leg raise test between injected and non-injected knees. The level statistical significance was predefined as $p < 0.05$. The SPSS software package for Windows (Statistical Package for Social Sciences, version 17.0, SPSS Inc., Chicago, IL, USA) was used for all analyses.

3. Results

Knees treated with PMDI had significantly lower mean VAS pain scores up to the second to third day after surgery at all assessments—overall, on walking, on rest, or on CPM ($p < 0.05$ for all comparisons) (Table 1, Fig. 1). However, no statistically significant differences in VAS scores were found between injected and non-injected knees on postoperative day 4 or 5, week 2, or week 4 (Table 1, Fig. 1). Thus, PMDI is associated with lower pain on the day of surgery and up to third day after surgery.

There was no difference in mean active ROM values preoperatively between the two groups ($p = 0.931$). Similarly, we found no statistically significant differences in active ROM between the two groups at 2 and 4 weeks after surgery ($p = 0.541$, $p = 0.261$, respectively) (Table 2). However, drug-injected knees had significantly higher passive ROM values on CPM than non-injected knees for 1–3 days postoperatively (Table 2, Fig. 2). Passive ROM values measured at the 1–5 days postoperatively were given in Table 2.

The number of patients able to perform an active straight leg raise was significantly higher in drug-injected than in non-injected knees ($n = 47$ [61%] and $n = 19$ [24.7%], respectively, $p = 0.001$).

The average estimated blood loss was 302 mL in drug-injected and 293 mL in non-injected knees. While the mean estimated blood loss for drug-injected knees was higher than for non-injected, the difference was not statistically significant ($p = 0.075$).

No clinically detectable, serious drug-related adverse effects and no wound-related or neurovascular complications were observed.

4. Discussion

Postoperative pain is a critical consideration in patients who undergo TKA and has been a focus of recent investigations.

Adequate pain control allows faster rehabilitation, reduces complications, and is correlated with greater patient satisfaction.^{15–18} PMDI, which has come into use in recent years, appears to provide better pain control.^{4,10,19–21} Multimodal pain management utilizes multiple agents with different mechanisms to modulate nociceptors and multiple regions of common pain pathways.¹⁶

PMDI is commonly applied through posterior capsule, which covers popliteal neurovascular structures with varying anatomic locations such as popliteal artery and sciatic nerve that can be injured with serious consequences.²² Thus, we hypothesized that PMDI applied through regions other than posterior capsule is effective in decreasing postoperative pain without any risk of injury to structures in the popliteal region. We had not recorded any postoperative neurovascular complications, showing that this injection location is safe.

For management of postoperative pain of TKA, pharmacological and non-pharmacological techniques such as femoral block, epidural analgesics, oral analgesics, periarticular injection, patient-controlled analgesia, have been used in unilateral TKA^{3,4,23,24} and simultaneous bilateral trials.^{5–7,25} In our study, patients experienced less pain in injected knees on the day of surgery and up to third day after surgery, but this difference was lost after third day postoperatively. Our findings are similar to those of other recent studies,^{3–7,23,24} which found lower pain scores in patients who received the injection group in the early postoperative period.^{4,19–21}

Inhibition of nociceptors is augmented by local anesthetics such as bupivacaine. Some previous studies used bupivacaine,^{7,20,21,26} while others used ropivacaine.^{3,6,12,27} Ropivacaine has a similar efficiency to that of bupivacaine, but is longer acting and associated with fewer complications in the nervous and cardiovascular systems.^{4,28–30} We used bupivacaine in our study, and none of our patients showed signs of or had symptoms consistent with systemic bupivacaine toxicity. Epinephrine has been suggested to localize the anesthesia and

Table 1 – Comparison of mean VAS between the two groups.

	Postoperative time	Group 1 (PMDI) n = 77	Group 2 (control) n = 77	p
Mean VAS	6 h	7.3 ± 1.8	8.8 ± 2.3	<0.001
	12 h	7.2 ± 1.9	8.9 ± 2.1	<0.001
	2 weeks	2.9 ± 0.6	2.9 ± 0.5	0.495
	4 weeks	2 ± 0.3	2 ± 0.4	1
Mean VAS on rest	1 day	6.4 ± 1.4	7.6 ± 1.7	<0.001
	2 days	6.1 ± 1.3	7.4 ± 1.8	<0.001
	3 days	5.6 ± 1.3	6.3 ± 1.5	0.022
	4 days	5.1 ± 0.8	5.3 ± 1.1	0.708
	5 days	3.8 ± 0.7	3.7 ± 0.6	0.208
Mean VAS on walking	1 day	6.8 ± 1.3	8 ± 1.7	<0.001
	2 days	6.5 ± 1.5	7.6 ± 1.7	<0.001
	3 days	5.7 ± 1.5	6.5 ± 1.8	0.014
	4 days	5.4 ± 1.1	5.6 ± 1.2	0.836
	5 days	4 ± 0.7	4.1 ± 0.9	0.567
Mean VAS on CPM	1 day	7.1 ± 1.5	8.2 ± 2.1	<0.001
	2 days	6.8 ± 1.4	8 ± 2	<0.001
	3 days	5.9 ± 1.2	7.1 ± 1.6	<0.001
	4 days	5.7 ± 1.4	5.8 ± 1.2	0.442
	5 days	4.3 ± 0.7	4.4 ± 0.8	0.059

PMDI, periarticular multimodal drug injection; VAS, visual analog scale; CPM, continuous passive motion.

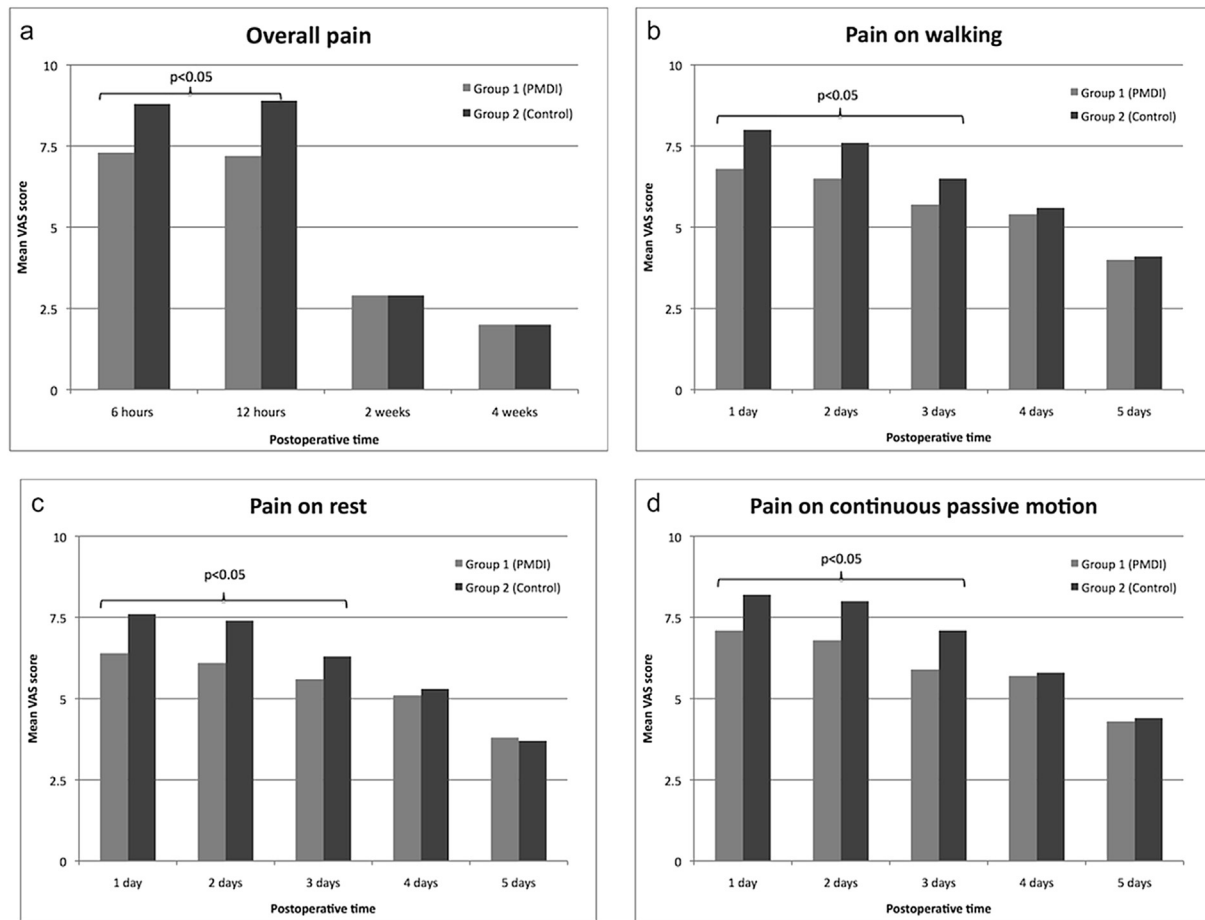


Fig. 1 – Postoperative pain after bilateral total knee arthroplasty as assessed by visual analog scale (VAS) scores of knees that were applied periarticular multimodal drug injection (PMDI, Group 1) and contralateral knees without injection (Control, Group 2) in general (a), on walking (b), on rest (c), and on continuous passive motion (d).

minimize the risk of systemic toxicities^{3,31}; our PMDI injection mixture contained epinephrine.

In the short-term, periarticular steroid injections have been shown to improve pain relief, functional recovery, and complications.^{32–34} Previous studies on PMDI included corticosteroids in the injection mixture,^{7,20,21,26} as did we.

To assess knee functional recovery, previous studies used the straight leg raise test and reported that more patients receiving the drug injection could perform this task from

postoperative day 1 to the day of discharge.^{3,7,20,21,27} In our study, the proportion of patients able to perform the active straight leg raise in the injected knees was significantly larger. Knee functional recovery has also been measured by ROM and knee flexion in previous studies.^{18–20,23} Fu et al²¹ reported significantly greater ROM for the first 15 days after surgery, while Joo et al²⁶ found no significant difference after 2 months postoperatively, and Busch et al³ also found no difference at 6 months after surgery. When we considered active and passive

Table 2 – Comparison of mean active and passive ROM between the two groups.

	Evaluation time	Group 1 (PMDI) n = 77	Group 2 (control) n = 77	p
Active ROM	Preoperative	106.4°±14°	106.3°±16°	0.931
	Postoperative week 2	94.3°±15°	94°±13°	0.541
	Postoperative week 4	103.3°±16°	103.8°±14°	0.261
Passive ROM on CPM	Preoperative 1 day	59°±10°	51°±8°	<0.05
	Preoperative 2 days	67°±8°	56°±6°	<0.05
	Preoperative 3 days	74°±6°	64°±5°	<0.05
	Preoperative 4 days	77°±7°	73°±8°	0.521
	Preoperative 5 days	81°±8°	79°±10°	0.701

PMDI, periarticular multimodal drug injection; ROM, range of motion; CPM, continuous passive motion.

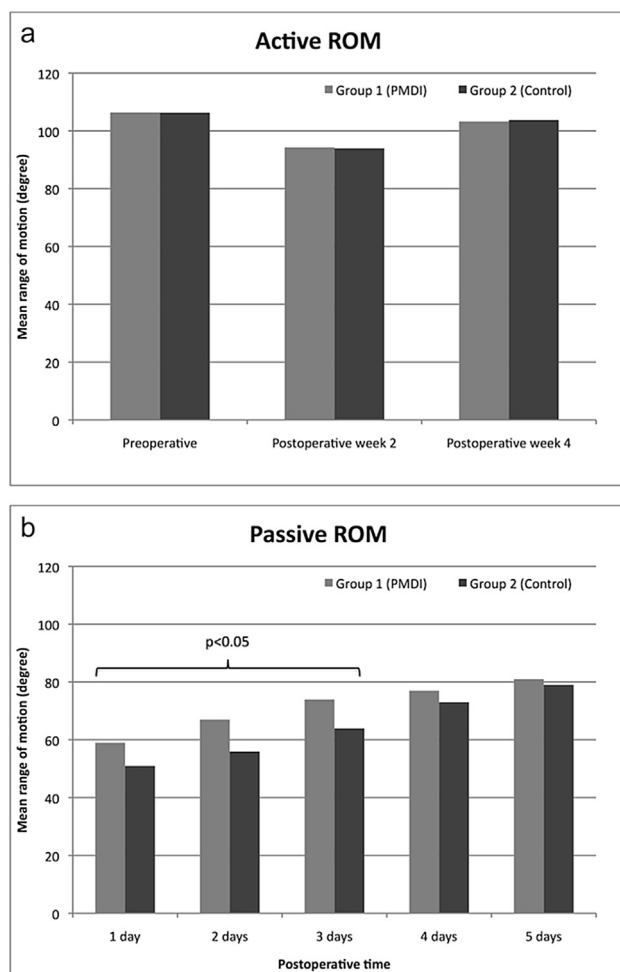


Fig. 2 – Active (a) and passive (b) range of motion (ROM) of knees that were applied periarticular multimodal drug injection (PMDI, Group 1) and contralateral knees without injection (Control, Group 2) in patients who underwent bilateral total knee arthroplasty.

ROM in injected and non-injected knees, we found that although active ROM did not change with drug injection, passive ROM values on CPM were significantly higher in drug-injected knees than non-injected knees for 1–3 days postoperatively.

The main limitation of the present study was its small sample size. Other limitations that need to be noted were retrospective design that does not allow placebo injection in the control side and blinding of either the surgeon or the patient, which can lead to significant bias. Nevertheless, this study showed the efficacy of PMDI in TKA, for both pain management and functionality.

5. Conclusion

PMDI is a simple procedure, and should be considered safe and effective for early postoperative pain management in TKA, facilitating early physical therapy. For the surgeons who

want to avoid the risk of injury to the structures in the popliteal region when injecting through the posterior capsule, PMDI can be alternatively applied through the regions other than posterior capsule.

Conflicts of interest

All authors have none to declare.

REFERENCES

- Browne C, Copp S, Reden L, Pulido P, Colwell Jr C. Bupivacaine bolus injection versus placebo for pain management following total knee arthroplasty. *J Arthroplast.* 2004;19:377–380.
- Sinatra RS, Torres J, Bustos AM. Pain management after major orthopaedic surgery: current strategies and new concepts. *J Am Acad Orthop Surg.* 2002;10:117–129.
- Busch CA, Shore BJ, Bhandari R, et al. Efficacy of periarticular multimodal drug injection in total knee arthroplasty. A randomized trial. *J Bone Jt Surg Am.* 2006;88:959–963.
- Vendittoli PA, Makinen P, Drolet P, et al. A multimodal analgesia protocol for total knee arthroplasty. A randomized, controlled study. *J Bone Jt Surg Am.* 2006;88:282–289.
- Andersen LØ, Husted H, Otte KS, Kristensen BB, Kehlet H. High-volume infiltration analgesia in total knee arthroplasty: a randomized, double-blind, placebo-controlled trial. *Acta Anaesthesiol Scand.* 2008;52:1331–1335.
- Koh IJ, Kang YG, Chang CB, et al. Additional pain relieving effect of intraoperative periarticular injections after simultaneous bilateral TKA: a randomized, controlled study. *Knee Surg Sports Traumatol Arthrosc.* 2010;18:916–922.
- Mullaji A, Kanna R, Shetty GM, Chavda V, Singh DP. Efficacy of periarticular injection of bupivacaine, fentanyl, and methylprednisolone in total knee arthroplasty: a prospective, randomized trial. *J Arthroplast.* 2010;25:851–857.
- Guild 3rd GN, Galindo RP, Marino J, Cushner FD, Scuderi GR. Periarticular regional analgesia in total knee arthroplasty: a review of the neuroanatomy and injection technique. *Orthop Clin North Am.* 2015;46:1–8.
- Calisir C, Simsek S, Tepe M. Variations in the popliteal artery branching in 342 patients studied with peripheral CT angiography using 64-MDCT. *Jpn J Radiol.* 2015;33:13–20.
- Kil SW, Jung GS. Anatomical variations of the popliteal artery and its tibial branches: analysis in 1242 extremities. *Cardiovasc Intervent Radiol.* 2009;32:233–240.
- Adibatti M, Sangeetha V. Study on variant anatomy of sciatic nerve. *J Clin Diagn Res.* 2014;8:AC07–09.
- Vloka JD, Hadzić A, April E, Thys DM. The division of the sciatic nerve in the popliteal fossa: anatomical implications for popliteal nerve blockade. *Anesth Analg.* 2001;92:215–217.
- Saleh HA, El-fark MM, Abdel-Hamid GA. Anatomical variation of sciatic nerve division in the popliteal fossa and its implication in popliteal nerve blockade. *Folia Morphol Warsz.* 2009;68:256–259.
- Schwemmer U, Markus CK, Greim CA, Brederlau J, Kredel M, Roewer N. Sonographic imaging of the sciatic nerve division in the popliteal fossa. *Ultraschall Med.* 2005;26:496–500.
- Brokelman RB, van Loon CJ, Rijnberg WJ. Patient versus surgeon satisfaction after total hip arthroplasty. *J Bone Jt Surg Br.* 2003;85:495–498.
- Hollmann MW, Wiczorek KS, Smart M, Durieux ME. Epidural anesthesia prevents hypercoagulation in patients undergoing

- major orthopedic surgery. *Reg Anesth Pain Med*. 2001;26:215–222.
17. Parvizi J, Miller AG, Gandhi K. Multimodal pain management after total joint arthroplasty. *J Bone Jt Surg Am*. 2011;93:1075–1084.
 18. Tali M, Maarros J. Lower limbs function and pain relationships after unilateral total knee arthroplasty. *Int J Rehabil Res*. 2010;33:264–267.
 19. Essving P, Axelsson K, Kjellberg J, Wallgren O, Gupta A, Lundin A. Reduced morphine consumption and pain intensity with local infiltration analgesia (LIA) following total knee arthroplasty. *Acta Orthop*. 2010;81:354–360.
 20. Fu PL, Wu Y, Wu H, Li X, Qian Q, Zhu Y. Efficacy of intra-articular cocktail analgesic injection in total knee arthroplasty—a randomized controlled trial. *Knee*. 2009;16:280–284.
 21. Fu PL, Xiao J, Zhu YL, et al. Efficacy of a multimodal analgesia protocol in total knee arthroplasty: a randomized, controlled trial. *J Int Med Res*. 2010;38:1404–1412.
 22. Shin YS, Hwang YG, Savale AP, Han SB. Popliteal artery pseudoaneurysm following primary total knee arthroplasty. *Knee Surg Relat Res*. 2014;26:117–120.
 23. Kerr DR, Kohan L. Local infiltration analgesia: a technique for the control of acute postoperative pain following knee and hip surgery: a case study of 325 patients. *Acta Orthop*. 2008;79:174–183.
 24. Toftdahl K, Nikolajsen L, Haraldsted V, Madsen F, Tønnesen EK, Søballe K. Comparison of peri- and intraarticular analgesia with femoral nerve block after total knee arthroplasty: a randomized clinical trial. *Acta Orthop*. 2007;78:172–179.
 25. Korean Knee Society. Guidelines for the management of postoperative pain after total knee arthroplasty. *Knee Surg Relat Res*. 2012;24:201–207.
 26. Joo JH, Park JW, Kim JS, Kim YH. Is intra-articular multimodal drug injection effective in pain management after total knee arthroplasty? A randomized, double-blinded, prospective study. *J Arthroplast*. 2011;26:1095–1099.
 27. Koh IJ, Kang YG, Chang CB, Do SH, Seong SC, Kim TK. Does periarticular injection have additional pain relieving effects during contemporary multimodal pain control protocols for TKA?: a randomised, controlled study. *Knee*. 2012;19:253–259.
 28. Qian WW, Weng XS, Fei Q, Li Y, Zhai JL, Bian YY. Application study of periarticular multimodal drug injection in total knee arthroplasty. *Zhonghua Yi Xue Za Zhi*. 2010;90:2593–2596.
 29. Knudsen K, Beckman Suurküla M, Blomberg S, Sjövall J, Edvardsson N. Central nervous and cardiovascular effects of i.v. infusions of ropivacaine, bupivacaine and placebo in volunteers. *Br J Anaesth*. 1997;78:507–514.
 30. Mather LE. The acute toxicity of local anesthetics. *Expert Opin Drug Metab Toxicol*. 2010;6:1313–1332.
 31. Solanki DR, Enneking FK, Ivey FM, Scarborough M, Johnston RV. Serum bupivacaine concentrations after intraarticular injection for pain relief after knee arthroscopy. *Arthroscopy*. 1992;8:44–47.
 32. Ikeuchi M, Kamimoto Y, Izumi M, et al. Effects of dexamethasone on local infiltration analgesia in total knee arthroplasty: a randomized controlled trial. *Knee Surg Sports Traumatol Arthrosc*. 2014;22:1638–1643.
 33. Ng YC, Lo NN, Yang KY, Chia SL, Chong HC, Yeo SJ. Effects of periarticular steroid injection on knee function and the inflammatory response following unicondylar knee arthroplasty. *Knee Surg Sports Traumatol Arthrosc*. 2011;19:60–65.
 34. Pang HN, Lo NN, Yang KY, Chong HC, Yeo SJ. Peri-articular steroid injection improves the outcome after unicondylar knee replacement: a prospective, randomised controlled trial with a two-year follow-up. *J Bone Jt Surg Br*. 2008;90:738–744.