



# Necessity of Suction Drains in Gynecomastia Surgery

Mustafa Keskin, MD; Mustafa Sutcu, MD; Bulent Cigsar, MD; and Naci Karacaoglan, MD

Aesthetic Surgery Journal  
2014, Vol. 34(4) 538–544  
© 2014 The American Society for  
Aesthetic Plastic Surgery, Inc.  
Reprints and permission:  
[http://www.sagepub.com/  
journalsPermissions.nav](http://www.sagepub.com/journalsPermissions.nav)  
DOI:10.1177/1090820X14526598  
[www.aestheticsurgeryjournal.com](http://www.aestheticsurgeryjournal.com)



## Abstract

**Background:** The aim of gynecomastia surgery is to restore a normal chest contour with minimal signs of breast surgery.

**Objective:** The authors examine the rate of complications in gynecomastia surgery when no closed-suction drains are placed.

**Methods:** One hundred thirty-eight consecutive male patients who underwent gynecomastia surgery without drains were retrospectively analyzed to determine whether the absence of drains adversely affected patient outcomes. Patients were managed by ultrasonic-assisted liposuction both with and without the pull-through technique.

**Results:** The mean age of the patients was 29 years, and the mean volume of breast tissue aspirated was 350 mL per breast. Pull-through was needed in 23 cases. There was only 1 postoperative hematoma.

**Conclusions:** These results are comparable with previously published data for gynecomastia surgery in which drains were placed, suggesting that the absence of drains does not adversely affect postoperative recovery. Routine closed-suction drainage after gynecomastia surgery is unnecessary, and it may be appropriate to omit drains after gynecomastia surgery.

## Level of Evidence: 4

## Keywords

breast surgery, gynecomastia, drains, suction, hematoma, complications

Accepted for publication July 30, 2013.



Gynecomastia is a benign enlargement of the male breast. In gynecomastia surgery, which is highly successful in improving this aesthetic problem, the primary concerns are to avoid contour irregularities, infection, hematoma, seroma, skin injuries, and extensive scarring. The aim of gynecomastia surgery is to restore a normal chest contour with minimal signs of breast surgery.

Suction drains traditionally have been placed after gynecomastia surgery. They are thought to aid the removal of undesirable postoperative matter and minimize tissue dead space. These drains are costly not only in economic terms but also in terms of recordkeeping, nursing time, and postoperative care. Patients often report discomfort associated with drains, and drain sites can leave conspicuous scars and may represent potential sources of tract formation or infection. Outpatient management of drains can present a source of concern for patients who have shorter hospital stays and therefore must care for the drain site at home.<sup>1</sup> The effectiveness of surgical drains in reducing postoperative hematomas also has been questioned in other breast-related surgeries.

In this study, we retrospectively analyzed the results of surgeries performed for different grades of gynecomastia without drains to determine whether this practice had any adverse effect on patient outcomes.

## METHODS

We retrospectively analyzed the charts of 138 consecutive male patients who underwent bilateral gynecomastia

From the Plastic and Aesthetic Surgery Department, Istanbul Medipol University, Istanbul, Turkey.

### Corresponding Author:

Dr Mustafa Keskin, Istanbul Medipol Hastanesi Kosuyolu, Kadikoy, 34718 Istanbul, Turkey.

E-mail: [mustafa.keskin@medipol.com.tr](mailto:mustafa.keskin@medipol.com.tr)



Scan this code with your smartphone to see the operative video. Need help? Visit [www.aestheticsurgeryjournal.com](http://www.aestheticsurgeryjournal.com).

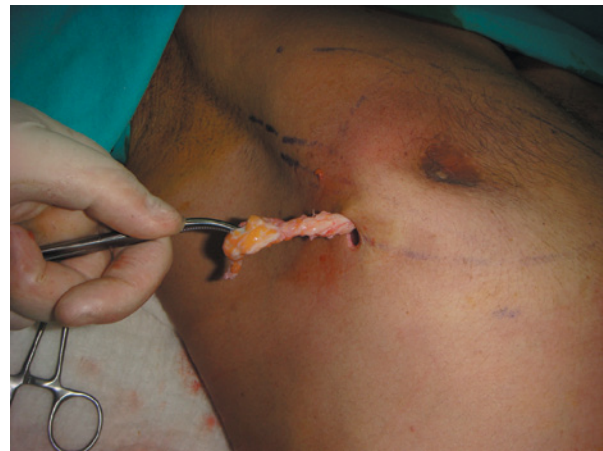surgery without the use of drains between January 2006 and September 2012. Patient age, grade of gynecomastia, volume of liposuction, and hematoma rate were recorded.

## Surgical Technique

The preoperative preparation for gynecomastia included a physical examination and laboratory work appropriate to the age of the patient. None of the patients in the study had any coagulation disorder, and none were taking medication that could affect bleeding. However, prothrombin time (PT) and partial thromboplastin time (PTT) tests were conducted. Patients were reminded preoperatively to stop taking aspirin, ibuprofen, alcohol, and vitamin E and to stop smoking 10 days prior and 10 days after the surgery.

All patients received general anesthesia. An antibiotic was administered intravenously immediately before the surgery. Depending on breast size and the extent of the fatty component, between 500 and 1000 mL of a warm tumescent solution was infused into each breast. The solution comprised 1000 mL Ringer's lactate, 20 mL of 2% lidocaine, and 1 ampoule of epinephrine 1:1000. A stab incision was made about 2 to 3 cm below the inferior margin of the areola. Using a standard infiltration pump and a 3-mm-wide/20-cm-long blunt cannula, the wetting solution was uniformly administered in multiple subcutaneous layers. The right breast was infused first, followed by the left breast. The infiltration of both breasts was completed in 15 to 20 minutes, which provided sufficient time for the adrenaline to work before applying ultrasonic energy to each breast.<sup>2</sup> To prevent friction injuries at the entrance site, a plastic skin protector was inserted. In all the patients, glandular and fat tissues were removed with ultrasonic-assisted liposuction (VASER Shape; Sound Surgical, Denver, Colorado), with or without the pull-through technique. A 3.7-mm solid probe with 2 grooves was used at 80% of total power in continuous mode. The duration of the cavitation was approximately 1 minute per each 100 mL of infiltration. The cannula, with ultrasound assistance, was passed through multiple times in a fanlike pattern to separate the more fibrous breast tissue. After the application of the ultrasound energy, the emulsified fat was evaluated using a standard procedure with a 3.7-mm triple-hole cannula. Final contouring of the thorax was not just limited to the breast but extended to the lateral axillary component and below the inframammary line.

The residual glandular tissue, located mostly in the sub-areolar area, was pinched after completing the liposuction to evaluate volume; it was then removed by the pull-through technique using the same incision employed for the liposuction.<sup>3</sup> To surgically excise the gland, it first was pinched between the thumb and the index finger, grasped using a Mosquito forceps, and then passed through the skin incision made for the liposuction. When the forceps was pulled, the edge of the glandular tissue was exposed. The gland was freed from the surrounding tissue by cutting with scissors in different directions (Figure 1). This maneuver was repeated



**Figure 1.** Removal of the glandular tissue with the pull-through technique via a liposuction incision.

**Table 1.** Volume of Breast Tissue Aspirated

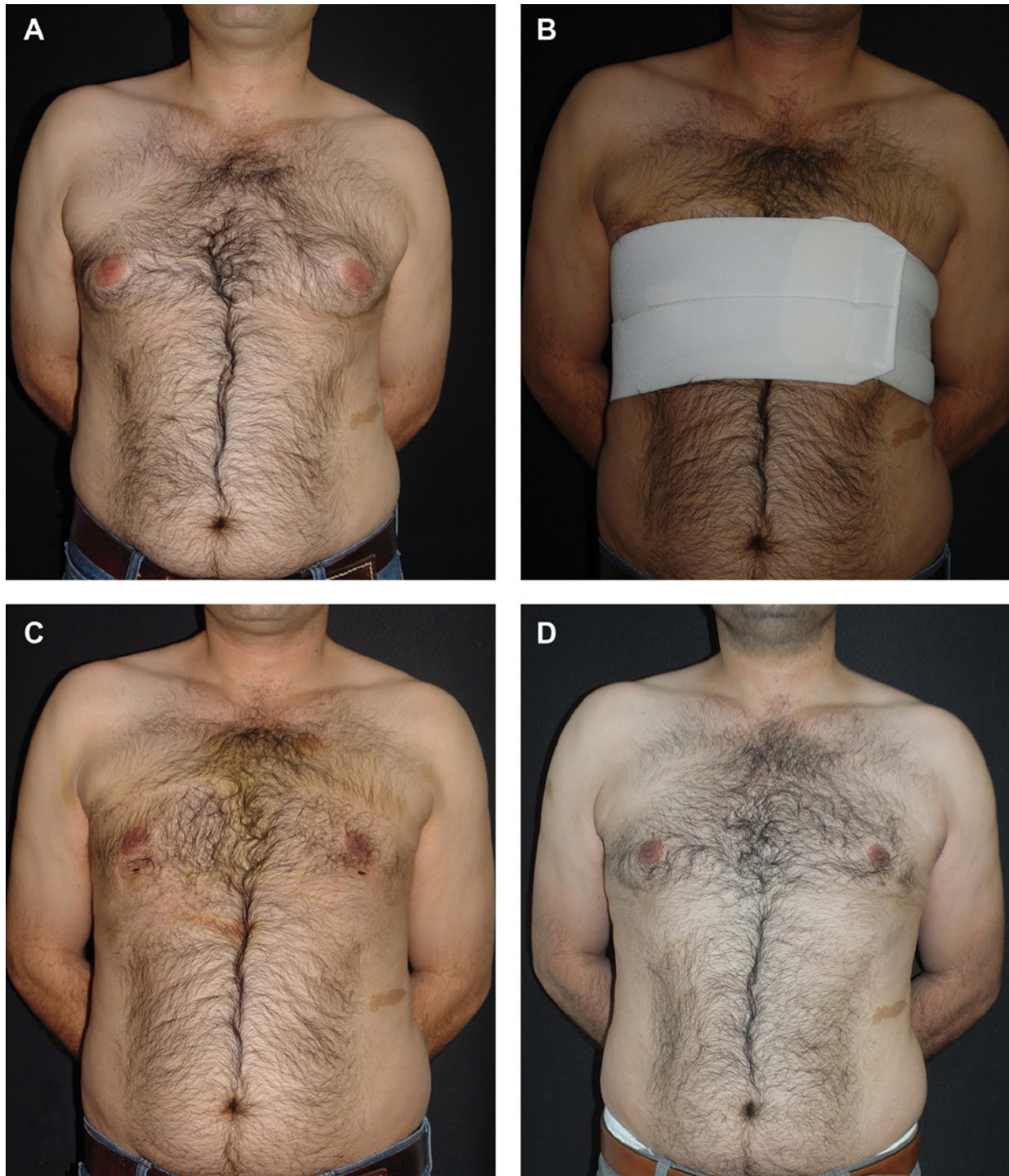Volume of Tissue Aspirated, mL	Number of Breasts
<250	119
250-500	130
>500	27

until the gland was completely separated. It was then removed, and any remaining gland was palpated after each removal. Leaving a small amount of gland behind the areola prevented skin depression. The incision sites were closed in layers subcutaneously and intracutaneously with a continuous Monocryl 5-0 suture (Ethicon, Inc, Somerville, New Jersey). A video of the procedure is available online at [www.aestheticsurgeryjournal.com](http://www.aestheticsurgeryjournal.com). You may also scan the code on the first page of this article with any smartphone to be taken directly to the video at [www.YouTube.com](http://www.YouTube.com).

Postoperatively, a compression garment was applied to each patient's torso. The garment was composed of a 9-inch waist binder (VOE, Barcelona, Spain) with 2 independent bands and an adjustable Velcro closure system. Special care was taken to apply the binder smoothly to the skin. The surgery was performed on an ambulatory or same-day basis, and the patients were examined within the first 24 postoperative hours to determine potential abnormalities. Patients were instructed to wear the binder continuously, except while showering, for the subsequent 2 weeks. They were also asked to refrain from any strenuous activity for 3 weeks, after which they could resume activity if they felt comfortable.

## RESULTS

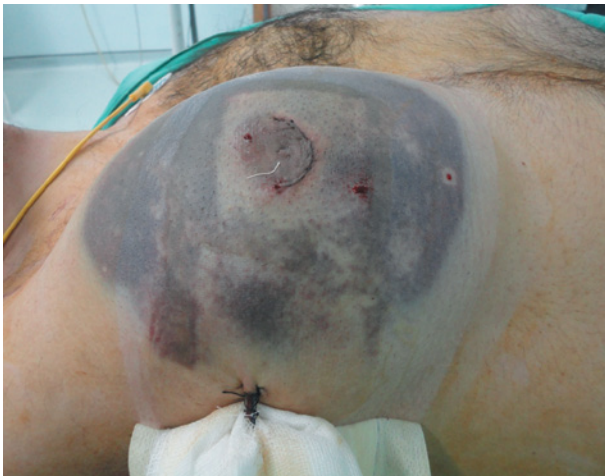Gynecomastia was deemed to be idiopathic in all cases. A total of 276 breasts of 138 patients were operated on during the study period. The mean age of our patients was 29 years



**Figure 2.** (A) A 31-year-old man with grade II gynecomastia. (B) After 6 minutes of cavitation, total of 600 mL liposuction was carried out. One week after the surgery with compression garment. (C) Without compression garment. (D) Postoperative month 17.

(range, 17-55 years), and their mean body weight was 64 kg (range, 58-88 kg). The distributed severity of gynecomastia was as follows: 41 patients were classified as grade 1, 85 patients were classified as grade 2, and 12 patients were classified as grade 3 (Table 1). In 23 patients, the glandular tissue

was removed with the pull-through technique. None of the patients in this series required skin resection or areola transposition. Ecchymosis was present for 1 to 2 weeks, disappearing gradually. Some operative field swelling also persisted for several weeks postoperatively. However, in all cases, the skin



**Figure 3.** Postoperative hematoma after removal of the breast tissue through the subareolar incision was not prevented with a closed-suction drain.

appeared to drape normally after the compression garment was removed (Figure 2). Clinical examination of all 276 breasts revealed only 1 postoperative hematoma. This was a hematoma on a single breast, and only liposuction was performed. All patients were tracked postoperatively, with an average follow-up time of 14 months.

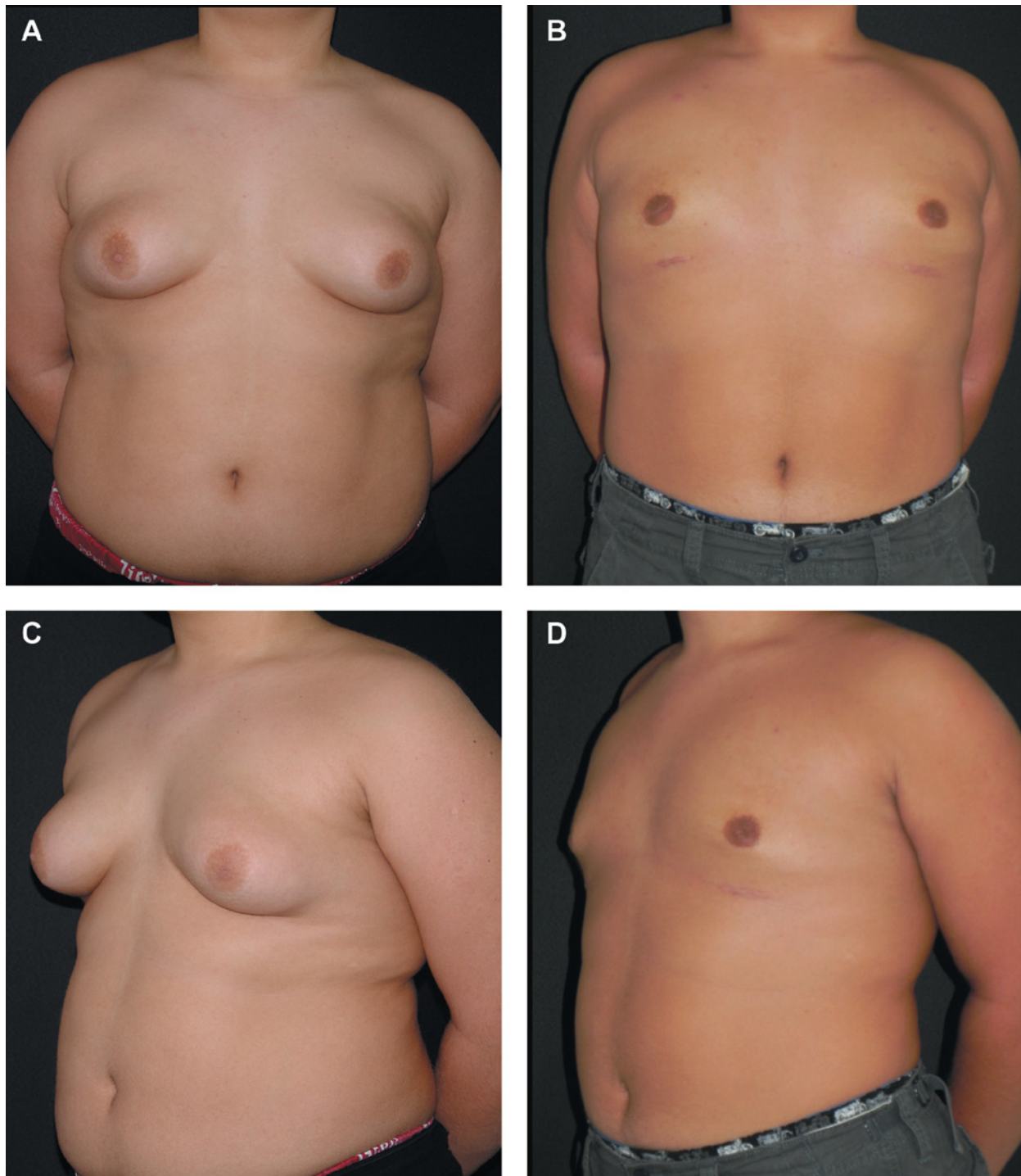
## DISCUSSION

Early reports described gynecomastia surgery techniques with placement of closed-suction drains,<sup>4</sup> which were conventionally used to minimize the amount of fluid at the operative site and the dead space between tissues. However, the reasons for drain use have not been studied, and the criteria for using them are not clear. While closed-suction drains are generally believed to help prevent possible complications, there is no evidence that the drainage is beneficial in all cases or that closed-suction drainage has particular benefits after gynecomastia surgery (Figure 3).

**Table 2.** A Review of the Current Literature Concerning Gynecomastia Surgery

Series	Year	Number of Patients	Technique	Hematoma (Patients)	Drain vs Compression Garment
Varma and Henderson <sup>8</sup>	1990	20	OE	2 breast	Closed-suction drain
Persichetti et al <sup>9</sup>	2001	29	OE	1 seroma	Closed-suction drain
Fruhstorfer and Malata <sup>10</sup>	2003	29	L ± OE	None	Compression garment
Hammond et al <sup>11</sup>	2003	15	PT + UAL	None	Compression garment
Bracaglia et al <sup>12</sup>	2004	45	L + PT	2	Compression garment
Tashkandi et al <sup>13</sup>	2004	24	OE	0	Drains with compression garment
Wiesman et al <sup>14</sup>	2004	174	L ± OE	48 (with seroma)	Not reported
Walden et al <sup>15</sup>	2004	34	L ± OE	1	Compression garment
Aslan et al <sup>16</sup>	2005	15	OE + L	2	Drains with compression garment
Ramon et al <sup>17</sup>	2005	17	PAL + PT (endoscopic assisted)	0	Compression garment
Filho et al <sup>18</sup>	2006	12	OE + L	1 hematoma 1 seroma	Compression garment
Mentz et al <sup>19</sup>	2007	200	PT	2	Compression garment
Cordova and Moschella <sup>20</sup>	2008	121	L ± OE	6	Not defined
Lista and Ahmad <sup>21</sup>	2008	99	PAL + PT	1 (seroma)	Compression garment
Benito-Ruiz et al <sup>22</sup>	2009	40	Liposuction with arthroscopic shaver	3	Drains with compression garment
Ratnam <sup>23</sup>	2009	42	L ± OE	2	Compression garment
Al-Allak et al <sup>24</sup>	2011	224	OE	26	Not defined
Cigna et al <sup>25</sup>	2011	37	OE + PAL	1	Drains with compression garment
Jose and Thomas <sup>26</sup>	2011	73	PAL ± OE	5	Compression garment
Petty et al <sup>27</sup>	2011	227	L ± OE (arthroscopic shaver)	4	Compression garment
Morselli and Morellini <sup>28</sup>	2012	260	L + PT	%1	Suction drain

Abbreviations: L, liposuction; PAL, power-assisted liposuction; OE, open excision; UAL, ultrasound-assisted liposuction.



**Figure 4.** (A, C) Preoperative image of a 16-year-old boy with grade 3 gynecomastia. (B, D) Postoperative images of the same patient 6 months after treatment with liposuction and the pull-through technique without a drain.

A review of the literature does not support the use of drains, nor does it indicate that drains prevent hematomas. The use of adrenaline in local tissue infiltration to produce preoperative vasoconstriction has been shown to reduce blood loss significantly in operations on breast tissue.<sup>4</sup>

Ultrasound evaluation of surgical wounds has shown that hematomas can occur at least 10 days postoperatively.<sup>5</sup> Theoretically, prolonged drainage throughout the postoperative period may reduce the incidence of hematoma development, but it can increase significantly the risk of

infection. Bacteria, especially skin commensals, migrate along the drain tube and have been cultured from drain tips as early as 48 hours after surgery.<sup>6</sup>

Closed-suction drains present other potential disadvantages in addition to possible infection. The percutaneous draining tubes often present a source of pain and discomfort for patients. Drains may be inserted through a liposuction-access incision, but sometimes an additional incision may be required. Additional cuts carry the possibility of additional scarring.

Also, ambulatory, nonhospital admissions for gynecomastia surgery are increasingly common. These patients need additional care when they are discharged with drains, and this increases the costs of the treatment and places a further burden on the patients.<sup>1</sup> Finally, removal of the drainage tubes is often associated with a great deal of patient anxiety.<sup>7</sup> A review of the current literature suggests omitting closed-suction drainage in gynecomastia surgery does not increase postoperative complications (Table 2).<sup>8-28</sup> Eliminating drainage tubes may be beneficial, given that the literature review does not either confirm their value or suggest they contribute positively to patient outcomes.

Observation suggests that ultrasound-assisted liposuction is an insufficient treatment for glandular gynecomastia. The glandular tissue is too dense and fibrous to be amenable to suction alone. Therefore, liposuction should be combined with some kind of surgical excision if the breast is purely fatty. The pull-through technique, which allows glandular tissue to be removed through the liposuction incision, is our suggested method. Even when the pull-through technique is used, a closed-suction drain is unnecessary. Drains are rarely used in bodybuilding-related gynecomastia, which is considerably more prone to hematoma complications.<sup>29</sup> In certain situations, drainage may be necessary; however, usage is determined by an individual patient's case, rather than on the breasts' glandular nature. For example, if the surgeon determines intraoperatively that the surgical site is oozing blood uncontrollably, then a drain might be considered.

In this particular series, none of the patients needed nipple-areola complex (NAC) repositioning, not even the 12 patients who were classed as having grade 3 gynecomastia (Figure 4). NAC repositioning should be considered a last resort and, if needed, performed in a second surgery. Patients who have lost extensive weight present a special situation in which NAC repositioning and skin excision are usually needed. However, even in NAC repositioning cases, closed-suction drains are unnecessary because—as in a comparable example—breast reduction surgeries performed on women omit closed drains. Reduction mammoplasties in which NAC repositioning and skin excision are done without drains have been demonstrated to be safe, without increased complications.<sup>30-33</sup> Additionally, the pain and discomfort associated with wound drainage are avoided, and nursing time involved with drain care is minimized.

## CONCLUSIONS

When intraoperative tumescent fluid and a postoperative compression garment are used, omitting the placement of closed-suction drainage increases patient comfort without the risk of increasing complications from gynecomastia surgery. Drainage is not needed when combining the pull-through technique with suction-assisted lipectomy. The findings of the current study and of a literature review demonstrate the advantage of omitting drains following gynecomastia surgery.

## Disclosures

The authors declared no potential conflicts of interest with respect to the research, authorship, and publication of this article.

## Funding

The authors received no financial support for the research, authorship, and publication of this article.

## REFERENCES

1. Matarasso A, Wallach SG, Rankin M. Reevaluating the need for routine drainage in reduction mammoplasty. *Plast Reconstr Surg*. 1998;102:1917-1921.
2. McKee DE, Lalonde DH, Thoma A, Glennie DL, Hayward JE. Optimal time delay between epinephrine injection and incision to minimize bleeding. *Plast Reconstr Surg*. 2013;131:811-814.
3. Karameşe M, Keskin M, Sutcu M, et al. Pull-through technique combined with liposuction in gynecomastia. *Turk Plast Surg*. 2011;19:78-81.
4. Teimourian B, Perlman R. Surgery for gynecomastia. *Aesthetic Plast Surg*. 1983;7:155-157.
5. Samdal F, Serra M, Skolleborg KC. The effects of infiltration with adrenaline on blood loss during reduction mammoplasty. *Scand J Plast Reconstr Surg Hand Surg*. 1992;26:211-215.
6. Varley GW, Milner S, Turner GM, Crisp AJ, Szypryt EP. Ultrasound assessment of the efficacy of wound drains. *J R Coll Surg Edinb*. 1994;39:97-99.
7. Watson JD, Smith G, Forrest H, Quin RO. Contamination of suction drainage systems in vascular surgery. *J R Coll Surg Edinb*. 1988;33:130-131.
8. Varma SK, Henderson HP. A prospective trial of adrenaline infiltration for controlling bleeding during surgery for gynaecomastia. *Br J Plast Surg*. 1990;43:590-593.
9. Persichetti P, Berloco M, Casadei RM, et al. Gynecomastia and the complete circumareolar approach in the surgical management of skin redundancy. *Plast Reconstr Surg*. 2001;107:948-954.
10. Fruhstorfer BH, Malata CM. A systematic approach to the surgical treatment of gynaecomastia. *Br J Plast Surg*. 2003;56:237-246.
11. Hammond DC, Arnold JF, Simon AM, Capraro PA. Combined use of ultrasonic liposuction with the pull-through technique for the treatment of gynecomastia. *Plast Reconstr Surg*. 2003;112:891-895.

12. Bracaglia R, Fortunato R, Gentileschi S, Seccia A, Farallo E. Our experience with the so-called pull-through technique combined with liposuction for management of gynecomastia. *Ann Plast Surg.* 2004;53:22-26.
13. Tashkandi M, Al-Qattan MM, Hassanain JM, Hawary MB, Sultan M. The surgical management of high-grade gynecomastia. *Ann Plast Surg.* 2004;53:17-20.
14. Wiesman IM, Lehman JA Jr, Parker MG, et al. Gynecomastia: an outcome analysis. *Ann Plast Surg.* 2004;53:97-101.
15. Walden JL, Schmid RP, Blackwell SJ. Cross-chest lipoplasty and surgical excision for gynecomastia: a 10-year experience. *Aesthetic Surg J.* 2004;24:216-223.
16. Aslan G, Tuncali D, Terzioglu A, Bingul F. Periareolar-transareolar-perithelial incision for the surgical treatment of gynecomastia. *Ann Plast Surg.* 2005;54:130-134.
17. Ramon Y, Fodor L, Peled IJ, et al. Multimodality gynecomastia repair by cross-chest power-assisted superficial liposuction combined with endoscopic-assisted pull-through excision. *Ann Plast Surg.* 2005;55:591-594.
18. Filho DH, Arruda RG, Alonso N. Treatment of severe gynecomastia (grade III) by resection of periareolar skin. *Aesthetic Surg J.* 2006;26:669-673.
19. Mentz HA, Ruiz-Razura A, Newall G, Patronella CK, Miniel LA. Correction of gynecomastia through a single puncture incision. *Aesthetic Plast Surg.* 2007;31:244-249.
20. Cordova A, Moschella F. Algorithm for clinical evaluation and surgical treatment of gynaecomastia. *J Plast Reconstr Aesthetic Surg.* 2008;61:41-49.
21. Lista F, Ahmad J. Power-assisted liposuction and the pull-through technique for the treatment of gynecomastia. *Plast Reconstr Surg.* 2008;121:740-747.
22. Benito-Ruiz J, Raigosa M, Manzano M, Salvador L. Assessment of a suction-assisted cartilage shaver plus liposuction for the treatment of gynecomastia. *Aesthetic Surg J.* 2009;29:302-309.
23. Ratnam BV. A new classification and treatment protocol for gynecomastia. *Aesthetic Surg J.* 2009;29:26-31.
24. Al-Allak A, Govindarajulu S, Shere M, et al. Gynaecomastia: a decade of experience. *Surgeon.* 2011;9:255-258.
25. Cigna E, Tarallo M, Fino P, De Santo L, Scuderi N. Surgical correction of gynecomastia in thin patients. *Aesthetic Plast Surg.* 2011;35:439-445.
26. Jose RM, Thomas S. Gynaecomastia correction—the role of power-assisted liposuction. *Eur J Plast Surg.* 2011;34:187-191.
27. Petty PM, Solomon M, Buchel EW, Tran NV. Gynecomastia: evolving paradigm of management and comparison of techniques. *Plast Reconstr Surg.* 2011;125:1301-1308.
28. Morselli PG, Morellini A. Breast reshaping in gynecomastia by the “pull-through technique”: considerations after 15 years. *Eur J Plast Surg.* 2012;35:365-371.
29. Babigian A, Silverman RT. Management of gynecomastia due to use of anabolic steroids in bodybuilders. *Plast Reconstr Surg.* 2001;107:240-242.
30. Wrye SW, Banducci DR, Mackay D, Graham WP, Hall WW. Routine drainage is not required in reduction mammoplasty. *Plast Reconstr Surg.* 2003;111:113-117.
31. Arrowsmith J, Eltigani E, Krarup K, Varma S. An audit of breast reduction without drains. *Br J Plast Surg.* 1999;52:586-588.
32. Corion LU, Smeulders MJ, van Zuijlen PP, van der Horst CM. Draining after breast reduction: a randomised controlled inter-patient study. *J Plast Reconstr Aesthetic Surg.* 2009;62:865-868.
33. Ngan PG, Iqbal HJ, Jayagopal S, et al. When to use drains in breast reduction surgery? *Ann Plast Surg.* 2009;63:135-137.