




Contents lists available at ScienceDirect

Acta Orthopaedica et Traumatologica Turcica

journal homepage: <https://www.elsevier.com/locate/aott>

Minimally invasive plate osteosynthesis for tibial derotation osteotomies in children with cerebral palsy

Ilker Abdullah Sarikaya ^a, Ali Seker ^b, Ozan Ali Erdal ^{a,*}, Mehmet Ali Talmac ^c,
Muharrem Inan ^a

^a Ortopediatri Istanbul, Istanbul, Turkey

^b Istanbul Medipol University Department of Orthopaedics and Traumatology, Istanbul, Turkey

^c Istanbul Sisli Etfal Training and Research Hospital, Department of Orthopaedics and Traumatology, Istanbul, Turkey



ARTICLE INFO

Article history:

Received 23 February 2017

Received in revised form

24 November 2017

Accepted 11 February 2018

Available online 14 August 2018

Keywords:

Tibial osteotomy

Cerebral palsy

Derotation

Intoeing

Minimal invasive

ABSTRACT

Objective: Tibial derotation osteotomy can be used in the treatment of rotational deformities in case of ineffective conservative management. Our aim was to evaluate the results of the patients who underwent minimal invasive plate osteosynthesis for tibial derotation osteotomies.

Methods: Total of 16 patients (17 procedures) were included in this study. Mean age was 11.5 (3–25) years. We clinically assessed the tibial torsion by measuring the thigh-foot angle (TFA). No immobilization was used postoperatively and range of motion exercises were begun immediately. The patient was allowed weight-bearing activity, as tolerated, when callus formation was seen on the radiographs, at approximately three to four weeks after surgery.

Results: The mean follow-up time was 27.5 months. Mean preoperative and follow up TFA were 27° of internal rotation and 3.74° of external rotation, respectively. A mean of 22.3° improvement was achieved postoperatively. There was only one wound detachment, which was accepted as a complication and healed with local wound care.

Conclusions: The recurrence risk and correction loss can be decreased with plate-screw fixation. Minimal invasive surgery would also decrease the risk of wound complications.

Level of evidence: Level IV, Therapeutic study.

© 2018 Turkish Association of Orthopaedics and Traumatology. Publishing services by Elsevier B.V. This is an open access article under the CC BY-NC-ND license (<http://creativecommons.org/licenses/by-nc-nd/4.0/>).

Introduction

Rotational deformities of the tibia are common pathologies that adversely affect the gait function in children with cerebral palsy (CP).^{1–3} Tibial derotation osteotomy (TDO) has been accepted as a safe and effective method for the correction of rotational tibial deformities, when conservative treatment with bracing, shoe modifications, or soft tissue procedures are inefficient.^{4–7} Several surgical techniques had been defined in the literature for TDO, with varying success rates, but significant complications can occur, such as loss of reduction, nonunion, malunion, compartment syndrome, nerve palsy, pin tract infections, and pressure sores in the cast.^{1,8–10}

Therefore, we began to perform supramalleolar osteotomy and fixation of the correction with minimally invasive plating, to prevent these complications.

Our primary aim in this research was to describe this method, and evaluate the results of the patients who underwent this procedure.

Patients and methods

We designed a retrospective review of ambulatory patients with spastic CP, who had increased tibial torsion and underwent minimally invasive plate osteosynthesis for supramalleolar tibial derotation osteotomy between 2013 and 2014.

A total of 16 patients (6 females, 10 males) with 17 surgical procedures were included in this study. The mean age of the participants at the time of surgery was 11.5 ± 6 (3–25) years. The concomitant surgical procedures were also recorded. The time frame of patients is given in [Table 1](#).

* Corresponding author. Dikilitas Mah. Hakki Yeten Cad, Suleyman Seba Kompleksi, No 10 34343 Besiktas, Istanbul, Turkey. Tel.: +90 535 8356626. Fax: +90 212 2321034.

E-mail address: ozanaerdal@yahoo.com (O.A. Erdal).

Peer review under responsibility of Turkish Association of Orthopaedics and Traumatology.

Table 1

The time frame of patients. M: Male, F: Female, R: Right, L: Left.

Patient	Age (Years) when the patients were operated	Gender	Side	Follow-up (Months)
AB	5	M	L	27
DIT	25	F	L	29
ENA	14	F	R	20
EE	7	F	L	38
ED	15	M	L	33
EYO	15	M	R	24
MNK	14	F	L	33
MM	10	M	L	23
NY	6	F	L	22
PE	3	M	L	25
RD	17	F	L	22
SE	14	M	R	37
SCT	13	M	R	27
SD	12	M	R	25
UBÖ	4	M	R + L	27
TG	11	M	R	25

Increased tibial torsion was defined through a comprehensive assessment that included a clinical history of gait difficulty (ie, frequent trips and falls or pain) and abnormal foot progression angles as determined in the visual gait analysis. We clinically assessed the tibial torsion by measuring the thigh-foot angle (TFA).¹¹ These assessments were made using a goniometer, while the patient was in a prone position with his/her hips extended; the knee was flexed to 90°, and the ankle was positioned in neutral dorsiflexion/plantar flexion and neutral pronation/supination. The intraoperative TFA was measured in a similar way, but in the supine position with the hip and knee flexed.

The anteroposterior (AP) and lateral radiographs were examined periodically for union, any loss of correction, and any angulation at the site of the osteotomy. Bone union was defined by signs of a bridging callus and the ability to bear weight without pain.

The senior author performed all procedures, under general anesthesia. A 2.0 mm Kirschner wire was passed from medial to lateral at the level of the distal end of the tibial tuberosity, parallel to the tibial plateau. Another Kirschner wire was passed parallel to the ankle joint at the level of the medial malleoli from medial to lateral to describe rotational deformity. A 3-cm transverse skin incision was made on the medial side of the tibia, 2 cm proximal to the distal tibial epiphyseal plate (Fig. 1). The periosteum was explored longitudinally. Multiple drill holes, typically six to ten, using a 2.7 mm drill bit, were made on the transverse plane for the osteotomy under fluoroscopy with a drill sleeve introduced into the wound at the level of metaphyseal–diaphyseal junction (Fig. 2). The osteotomy procedure was completed with an osteotome

cutting circumferentially only the cortex. Fibula was kept intact. Derotation was performed by slowly rotating the foot until the desired amount of the derotation was given (All TFA's were corrected to 15° of external rotation). Degree of given rotation was followed by observing the relative positions of the Kirschner wires (Fig. 3). The proximal site of osteotomy line was tunneling with a blunt instrument. Then, a 120-degree pediatric locking plate (LCP) (TST, Istanbul, Turkey) was subcutaneously inserted proximally through incision (Fig. 4). The plate was positioned on the anteromedial aspect of the tibia. The plate was centered in the middle of the tibia on the sagittal plane. After the plate was properly positioned; the first screw fixation was performed by direct visualization distal to osteotomy site in order to the distal tibial segment to the plate. For the screw fixation proximal to osteotomy site, the screw holes were found with the help of a Kirschner wire inserted percutaneously into the screw hole under fluoroscopic control. A 0.5 cm skin incision was then made alongside the Kirschner wire and a drill sleeve was inserted into the screw hole over the Kirschner wire and secured to the plate. Then the Kirschner wire was extracted and a 3.5 mm locking screw was applied after drilling with a 2.7 mm drill (Fig. 5). The amount of correction was controlled by comparing Kirschner wires.

In an isolated distal tibial osteotomy, the ankle is not immobilized postoperatively and range of motion exercises are begun immediately. We used intravenous patient-controlled analgesia postoperatively. Moreover, the patient was allowed weight-bearing activity as tolerated. When the formation of the callus was seen on the radiographs, at approximately three to four weeks after the operation full weight bearing was allowed (Fig. 6).

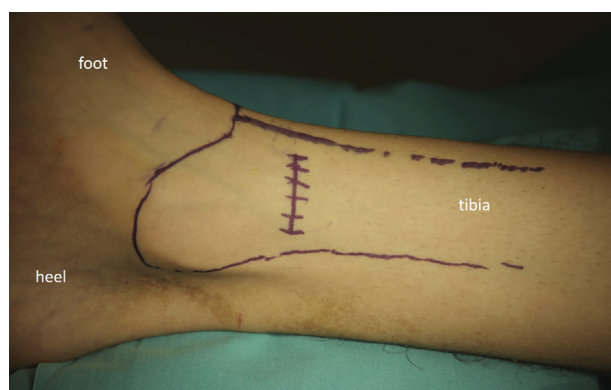
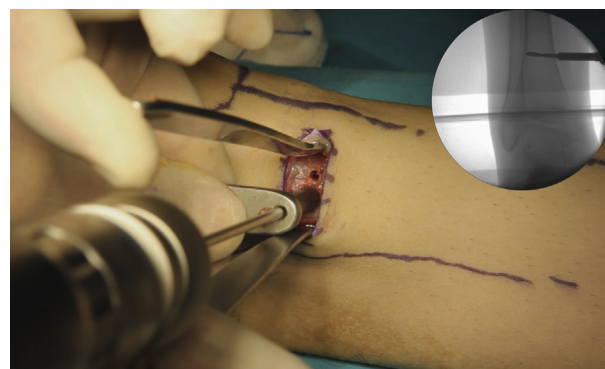
**Fig. 1.** Skin incision could be either transverse or longitudinal.**Fig. 2.** The osteotomies were performed using multiple drill hole technique.

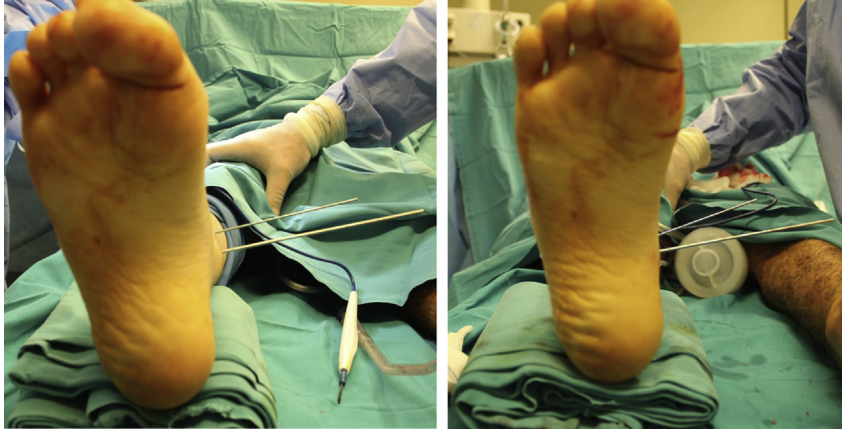

Fig. 3. Kirschner wires were used for determination of amount of correction.

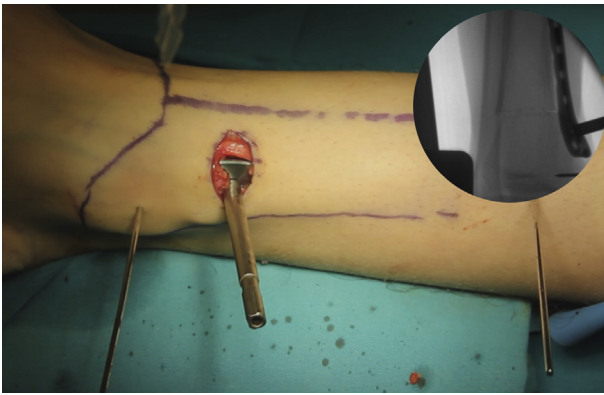


Fig. 4. Advancement of 120° pediatric proximal femur locking plate.

The mean duration of surgery was derived from data of the patients who underwent isolated ankle procedures (isolated TDO and/or TDO + ipsilateral and/or contralateral gastrocnemius tenotomy). Furthermore, the complications such as wound infections, nonunions, loss of correction and angulation at the osteotomy site were recorded.

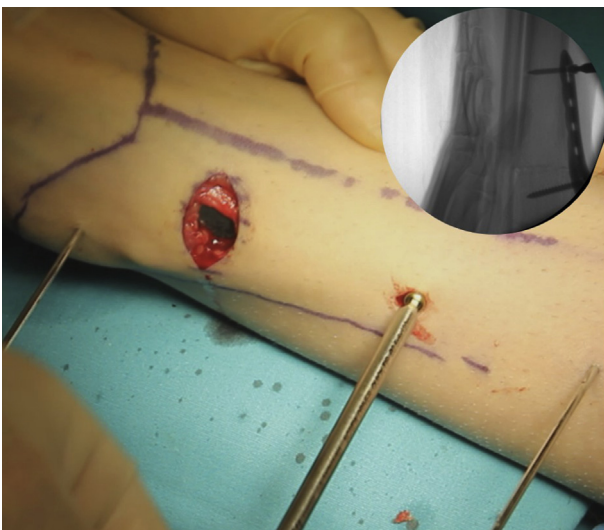

Fig. 5. Proximal screws insertion.

Results

The mean follow-up time was 27.5 ± 5.3 (range, 20–38) months. Other concomitant surgical procedures were performed in 15 of the 16 patients (94%). Total of 15 gastrocnemius tenotomies, two hamstring lengthening procedures, six proximal femur varisation/derotation osteotomies and one corrective osteotomy for hallux valgus deformity were performed.

Overall, we performed 11 external rotation osteotomies for internal tibial torsion. A mean $22.3^\circ \pm 3^\circ$ (range, 17° – 28°) improvement was achieved postoperatively in the TFA, while the mean preoperative TFA was $27^\circ \pm 3^\circ$ of internal rotation. At the final follow-up, the mean TFA was $3.74^\circ \pm 1^\circ$ of external rotation in this group. Additionally, 5 internal rotation osteotomies were performed for external tibial torsion. In this group TFA average was $28^\circ \pm 4^\circ$ external rotation preoperatively, and $5.4^\circ \pm 1^\circ$ external rotation at the last follow up.

The mean duration of surgery recorded from the 8 isolated ankle procedures (isolated TDO and/or TDO + ipsilateral and/or contralateral gastrocnemius tenotomy) was 42.5 ± 15.5 (range, 17–70) minutes. Furthermore, there were no wound infection, nonunion, loss of correction or angulation at the osteotomy site. There was only one wound detachment, which was accepted as a complication and healed with local wound care.

Discussion

Rotational deformities of the tibia may cause functional gait impairments, commonly requiring correction with surgery, especially in the presence of neuromuscular diseases such as CP.^{10,12,13} Several reports have shown that TDO is an effective treatment option for the correction of rotational deformities of the tibia in children with CP, but significant complications have been reported.^{8,9} We achieved an average of 22.3° improvement in the thigh-foot angle (TFA) through supramalleolar osteotomy with minimally invasive plate osteosynthesis, without any significant complication.

There are many fixation methods that can be used to stabilize the osteotomy site, like casting, Kirschner wires, pins incorporated into the cast, and plate-screw fixation.^{1,3,14,15} Bennett et al., who used a distal transverse osteotomy of the tibia and casting alone, detected a 9% loss of correction.⁴ Moreover, up to a 17% need for repeat manipulation has been reported in the literature when using only a cast to stabilize the osteotomy.^{16–20} Manouel et al. used pin fixation and casting, and reported a 10% recurrence.¹⁹ However, recurrence rates after osteotomies stabilized with internal fixation have been reported to be relatively low.²¹ The major advantages of the plate-screw construct are earlier range of motion exercises, and earlier

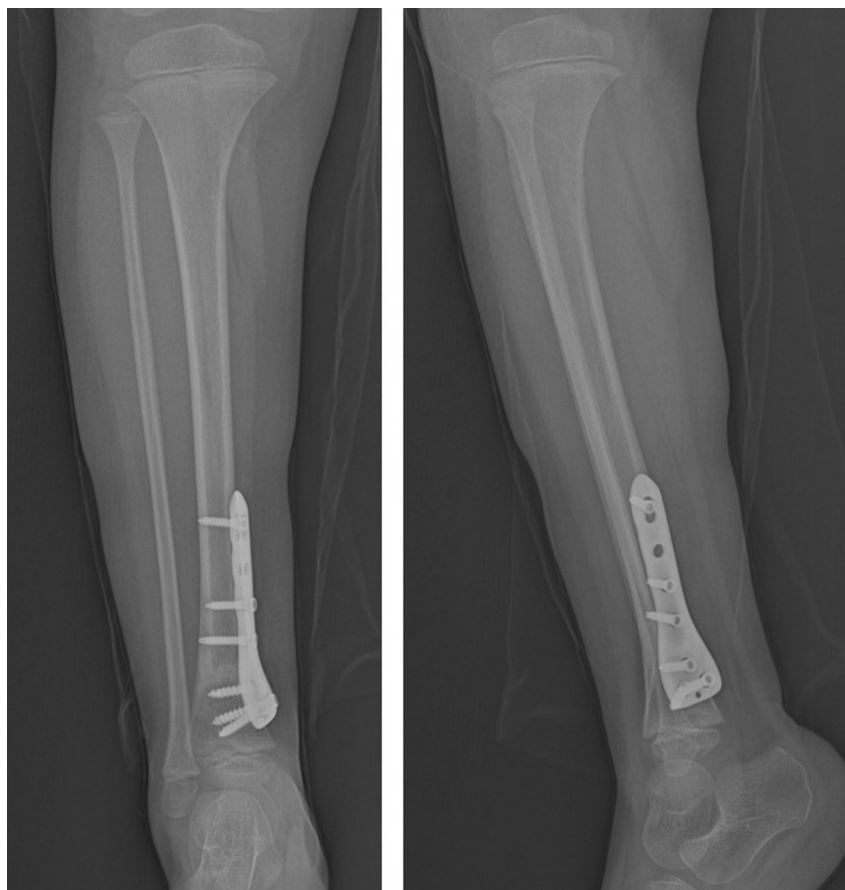

Fig. 6. Follow up radiographs show level of osteotomy and bone fusion.

weight-bearing, since it provides a more stable fixation than pin fixation or casting alone.¹⁴ At this point, de Rodde compared the outcomes of percutaneous pin fixation and the plate-screw construct. They showed that recurrence of deformity occurred rarely when a plate-screw was used to stabilize the osteotomy.³ However, the skin incision that they used was long, to accommodate the 6-hole plate, along with the wide exploration of the periosteum. They experienced compartment syndrome and wound dehiscence/infection which should be treated surgically, and many minor complications. Our primary skin incision was as short as 3 cm and we used a minimally invasive technique to secure the proximal screws. Thus, we caused less damage to periosteal circulation of the tibia and to the surrounding soft tissue and bone. Although the conventional internal fixation technique may result in wound healing problems or infections, we did not experience any superficial or deep wound infections or healing problems.^{9,14,19} While keeping in mind the future possibility of needing a revision after any corrective procedure in a growing child, our surgical experience suggests that this technique provides stable fixation with no loss of correction and less damage to the surrounding tissues.

There is a controversy about the level used for a corrective osteotomy in the tibia.^{1,10,14,15,17,22} A tibial osteotomy can be performed at either the proximal tibia, diaphysis, or distally at the supramalleolar region.^{15,22} The proximal tibia has been used commonly in the treatment of genu valgum or varum.¹⁵ Recent studies have demonstrated high complication rates after proximal osteotomies, including loss of fixation, peroneal nerve injury, and compartment syndrome.^{23–26} Krengel and Staheli compared the results of proximal and distal tibial osteotomies for the correction of

rotational deformities and determined that there was an increased incidence (13%) of complications with proximal rotational osteotomies.²¹ They highly recommended distal osteotomies for the correction of rotational deformities. Diaphyseal osteotomies can lead to delayed union or nonunion, and repeat surgical procedures are often required for these complications.¹ Therefore, several authors have reported that the supramalleolar region is the most appropriate choice for a derotation osteotomy of the tibia.^{4,5,14,15,19} We agree with the authors, and recommend the supramalleolar osteotomy for tibial derotation, due to its low complication rates.

The need for an additional fibular osteotomy has been another controversial topic in the treatment of tibial rotational deformities. Some authors have reported that leaving the fibula intact may cause recurrence of the deformity, and have recommended an additional fibular osteotomy to obtain maximal derotation and avoid mechanical disorders at the ankle joint.^{15,19,27,28} However, recent studies have claimed that an intact fibula provides additional stability, while preventing sagittal plane angulation and loss of fixation.^{8,19,28} Roode, who used an additional fibular osteotomy for corrections that are not easily obtained with tibial osteotomy alone, claimed that the recurrence of torsion is independent of fibular integrity, whereas it is a function of the underlying disorder, and the nature of torsional deformities in a growing child.³ Ryan et al. evaluated the effectiveness of a tibial derotational osteotomy without an additional fibular osteotomy in children with CP, and reported statistically significant improvements in the TFA in all cases.¹⁰ Likewise, in our study, we achieved significant improvement in the TFA but experienced no recurrence of deformity through tibial osteotomy with intact fibula.

Thigh-foot angle (TFA) has been widely used in studies about tibial torsion in CP patients.^{1,11,14} Following the presentation of TFA for tibial torsion by Staheli,¹¹ numerous authors analyzed these measurement and showed their adequacy.^{29–31} Stuberger compared the physical examination and CT findings³¹ and stated that the difference between the two methods was statistically not significant. We also believed like the other authors that the TFA is the practical measurement for the torsional deformities in CP patients and sufficient unless complex torsional deformities, such as the torsion associated with a club foot, are encountered.

Several limitations were present in this study due to its retrospective nature. Moreover, the low number of included patients and short follow-up time were additional limitations. Hence, studies that include more patients with longer follow-up would provide more reliable results.

Finally, we conclude that supramalleolar TDO with minimally invasive plate osteosynthesis is an effective procedure, with low complication rates, for the treatment of rotational pathologies of the tibia in children with CP.

Ethical approval

All procedures performed in studies involving human participants were in accordance with the ethical standards of the institutional and/or national research committee and with the 1964 Helsinki declaration and its later amendments or comparable ethical standards.

Funding

There is no funding source.

Conflicts of Interest

The authors declare that they have no conflict of interest.

Informed consent

Informed consent was obtained from all individual participants included in the study.

References

- Inan M, Ferri-de Baros F, Chan G, Dabney K, Miller F. Correction of rotational deformity of the tibia in cerebral palsy by percutaneous supramalleolar osteotomy. *J Bone Jt Surg Br.* 2005;87:1411–1415.
- Rethlefsen SA, Healy BS, Wren TA, Skaggs DL, Kay RM. Causes of intoeing gait in children with cerebral palsy. *J Bone Jt Surg Am.* 2006;88:2175–2180.
- Roode CP, Hung M, Stevens PM. Supramalleolar osteotomy: a comparison of fixation methods. *J Pediatr Orthop.* 2013;33(6), 672–627.
- Bennett JT, Bunnell WP, MacEwen GD. Rotational osteotomy of the distal tibia and fibula. *J Pediatr Orthop.* 1985;5:294–298.
- Charki E, Pilliard D, Taussig G. Supramalleolar derotation osteotomy for torsion of the leg in children and adolescents: techniques and results. *Ann Chir.* 1992;46:501–506.
- King HA, Staheli LT. Torsional problems in cerebral palsy. *Foot Ankle.* 1984;4:180–184.
- Staheli LT. Torsion: treatment indications. *Clin Orthop.* 1989;247:61–66.
- Banks SW, Evans EA. Simple transverse osteotomy and threaded-pin fixation for controlled correction of torsion deformities of the tibia. *J Bone Jt Surg [Am].* 1955;37-A:193–195.
- Payman KR, Patenall V, Borden P, Green T, Otsuka NY. Complications of tibial osteotomies in children with comorbidities. *J Pediatr Orthop.* 2002;22:642–644.
- Ryan DD, Rethlefsen SA, Skaggs DL, Kay RM. Results of tibial rotational osteotomy without concomitant fibular osteotomy in children with cerebral palsy. *J Pediatr Orthop.* 2005;25:84–88.
- Staheli LT, Corbett M, Wyss C, King H. Lower-extremity rotational problems in children: normal values to guide management. *J Bone Jt Surg [Am].* 1985;67-A:39–47.
- Dunteman RC, Vankoski SJ, Dias LS. Internal derotation osteotomy of the tibia: pre- and postoperative gait analysis in persons with high sacral myelomeningocele. *J Pediatr Orthop.* 2000;20:623–628.
- Rethlefsen SA, Kay RM. Transverse plane gait problems in children with cerebral palsy. *J Pediatr Orthop.* 2013;33:422–430.
- Selber P, Filho ER, Dallalana R, Pirpiris M, Natttrass GR, Graham HK. Supramalleolar derotation osteotomy of the tibia, with T plate fixation. Technique and results in patients with neuromuscular disease. *J Bone Jt Surg Br.* 2004;86:1170–1175.
- Dodgin DA, De Swart RJ, Stefko RM, Wenger DR, Ko JY. Distal tibial/fibular derotation osteotomy for correction of tibial torsion: review of technique and results in 63 cases. *J Pediatr Orthop.* 1998;18:95–101.
- Rathey T, Hyndman J. Rotational osteotomies of the leg: tibia alone versus both tibia and fibula. *J Pediatr Orthop.* 1994;14:615–618.
- Stefko RM, de Swart RJ, Dodgin DA, et al. Kinematic and kinetic analysis of distal derotational osteotomy of the leg in children with cerebral palsy. *J Pediatr Orthop.* 1998;18:81–87.
- Jackson JP, Waugh W. The technique and complications of upper tibial osteotomy: a review of 226 operations. *J Bone Jt Surg [Br].* 1974;56:236–245.
- Manouel M, Johnson LO. The role of fibular osteotomy in rotational osteotomy of the distal tibia. *J Pediatr Orthop.* 1994;14:611–614.
- Nicol RO, Menelaus MB. Correction of combined tibial torsion and valgus deformity of the foot. *J Bone Jt Surg [Br].* 1983;65:641–645.
- Krengel 3rd WF, Staheli LT. Tibial rotational osteotomy for idiopathic torsion. A comparison of the proximal and distal osteotomy levels. *Clin Orthop Relat Res.* 1992;283:285–289.
- Walton DM, Liu RW, Farrow LD, Thompson GH. Proximal tibial derotation osteotomy for torsion of the tibia: a review of 43 cases. *J Child Orthop.* 2012;6:81–85.
- Curley P, Eyres K, Brezinova V, Allen M, Chan R, Barnes M. Common peroneal nerve dysfunction after high tibial osteotomy. *J Bone Jt Surg [Br].* 1990;72:405–408.
- Martin SD, Moran MC, Martin TL, Burke SW. Proximal tibial osteotomy with compression plate fixation for tibia vara. *J Pediatr Orthop.* 1994;14:619–622.
- Schrock RD. Peroneal nerve palsy following derotation osteotomies for tibial torsion. *Clin Orthop.* 1969;62:172–177.
- Slawski DP, Schoenecker PL, Rich MM. Peroneal nerve injury as a complication of pediatric tibial osteotomies: a review of 255 osteotomies. *J Pediatr Orthop.* 1994;14:166–172.
- Magnusson R. Rotation osteotomy; a method employed in cases of congenital club-foot. *J Bone Jt Surg Am.* 1946;28:262–264.
- Asirvatham R, Watts HG, Rooney RJ. Rotation osteotomy of the tibia after poliomyelitis: a review of 51 patients. *J Bone Jt Surg [Br].* 1990;72-B:409–411.
- Eckhoff DG, Johnson KK. Three-dimensional computed tomography reconstruction of tibial torsion. *Clin Orthop Relat Res.* 1994;302:42–46.
- Jakob RP, Haertel M, Stussi E. Tibial torsion calculated by computerized tomography and compared to other methods of measurement. *J Bone Jt Surg [Br].* 1980;62:238–242.
- Stuberger W, Temme J, Kaplan P, Clarke A, Fuchs R. Measurement of tibial torsion and thigh-foot angle using goniometry and computed tomography. *Clin Orthop Relat Res.* 1991;272:208–212.