

This is a provisional PDF only. Copyedited and fully formatted version will be made available soon.



**ISSN:** 0015-5659

**e-ISSN:** 1644-3284

## **Macroanatomical and histological study of the structure of intercornual gland in Abaza (*Capra Aegagrus*) and Georgian (*Capra Falconeri*) goats breeds**

**Authors:** S. Dalga, S. İlhan Aksu, K. Aslan, T. Deprem

**DOI:** 10.5603/FM.a2020.0028

**Article type:** ORIGINAL ARTICLES

**Submitted:** 2020-01-10

**Accepted:** 2020-02-18

**Published online:** 2020-03-03

This article has been peer reviewed and published immediately upon acceptance. It is an open access article, which means that it can be downloaded, printed, and distributed freely, provided the work is properly cited. Articles in "Folia Morphologica" are listed in PubMed.

# **Macroanatomical and histological study of the structure of intercornual gland in Abaza (Capra Aegagrus) and Georgian (Capra Falconeri) goats breeds**

Intercornual gland

**S. Dalga<sup>1</sup>, S. İlhan Aksu<sup>2</sup>, K. Aslan<sup>1</sup>, T. Deprem<sup>2</sup>**

<sup>1</sup>Kafkas University, Faculty of Veterinary Medicine, Department of Anatomy, Kars, Turkey

<sup>2</sup>Kafkas University, Faculty of Veterinary Medicine, Department of Histology and Embriology, Kars, Turkey

Address for correspondence: Semine Dalga, Kafkas University, Faculty of Veterinary Medicine, Kars, Turkey, 36100, tel +905415820218, e-mail: sdalga91@gmail.com

## **Abstract**

The anatomical localization of the odor glands, which increase activity during the reproduction period and help goat species to find each other, varies. In our study, the anatomical and histological structures of the glands around the horn were examined in the Georgian and Abaza goats, which are native breeds. In this study a total of 12 Abaza and Georgian goat heads were used. The area between the two horns and area at the back of the horns were shaved to remove all hair. The distance between the horns of both goat breeds was measured using an electronic caliper. The mean distance between the horns of the Abaza goats was determined as  $36.80 \pm 8.62$  mm while this distance was  $39.63 \pm 4.10$  mm for the Georgian goats. Gland tissue that could not be seen anatomically under the skin was examined histologically. For the histological examination, skin samples were taken from the anterior, middle, right posterior and left posterior of the area between the two horns of both breeds. Crossman triple staining and Hematoxylin & Eosin (H&E) staining were applied to the samples. Glandula intercornualis was found to be slightly caudal between the horns in both breeds and normal sebaceous glands were almost absent in the areas where these glands were found. Lobes and branched alveolar glands were located around the hair follicles.

**Key words: Horn gland, Abaza goat, Georgian goat**

## INTRODUCTION

Abaza goats are farmed in the province of Artvin in Turkey and are generally bronze, white, black or brown. Their mouths, horns, legs and the area around their eyes are generally black. They have a thin body structure and therefore likened to gazelles. The bucks have sword-like flat broad horns, while the females may or may not have horns. It is also known that Abaza goats are of *Capra aegagrus* origin (Batu 1951).

Georgian goats, also known as Tbilisi goats or Caucasian goats, are originally from the Caucasus and are bred in the North-Eastern region of Turkey, especially in the province of Kars and Ardahan. Georgian goats, which are mostly black, gray or white, originate from the auger horned goat *Capra falconeri*, and are particularly similar to Abaza goats reared in Şavşat or Borçka (Batu, 1951; Sezgin et al., 2010). Georgian goats have long and straight horns that meet at the end which distinguishes them from hair goats. Georgian goats can also be hornless (Batu, 1951; Yalçın, 1990).

The horn glands in the horn roots of goats are sebaceous glands and the goats emit an odor through these glands to find their mates during breeding periods (Erençin Z., 1958). The secretion of the modified sebaceous glands was also believed to be involved in the production of this fragrance (Brouwerand Nijkamp, 1952; Sar and Calhoun, 1966; Jenkinson et al., 1967; Bal and Ghoshal, 1976). French (1970) stated that the presence of horns in male goats was a characteristic of Italian goats. Sar and Calhoun (1966) reported large, branched, alveolar and sebaceous glands at the base of the horns and ears of American goats. Jenkinson et al. (1967) reported that the odor of British Saanen goats mainly comes from enlarged sebaceous glands located in the head and neck. According to Bal and Ghoshal (1976), American goats in the glands of the fat cells in the cross-sectional diameter of males in females and castrated males are larger than men and reported that the glands are more active during the breeding season. Sar and Calhoun (1966) and Bal and Ghoshal (1976) described the sebaceous glands between the horn glands as being simple, branched or alveolar. According to Bal and Ghoshal (1976), although females had sebaceous glands, they had no characteristic odor. In other studies in the literature, it has been reported that testosterone increases the size and activity of the sebaceous glands (Ebling, 1957; Strauss et al., 1962).

Various anatomical and histological studies have been conducted on the horn glands and sebaceous glands of goats found in various different parts of their bodies (Chukwu et al., 1989, Lancker et al., 2005).

Various studies have been conducted on goat breeds native to Turkey (Kuru et al., 2017, Dalga, 2019). However, no anatomical and histological studies have been conducted on Abaza and Georgian goats. Thus, in the present study, the glandula intercornualis, special skin glands located between the two horns of Abaza and Georgian goats, was studied.

## **MATERIALS AND METHODS**

This study was approved by the local Ethics Commission of Experimental Animals of Kafkas University. A total of 12 Abaza and Georgian goat heads were used in the present study (regardless of gender). The materials were supplied during the sale of the Abaza and Georgian goat herd sacrificial and forbearance from Kafkas University Education, Research and Application Farm. The head samples were obtained between June and December. Firstly, the anterior and posterior of the heads and the area between the two horns were shaved to remove all hair. The distance between the two horns of both goat breeds was then measured using an electronic caliper. The left and right horn lengths and the transverse surface of the horns of both goat breeds were measured using a tape measure. Subsequently, for the histological examination, skin samples of approximately 1x1 size were taken from the anterior, middle, right posterior and left posterior of the area between the two horns of both breeds. The skin samples were kept in 10% formaldehyde for 24 hours and then underwent routine histological follow-up (alcohol-xylol) series and paraffin-blocked. Crossman triple staining and Hematoxylin & Eosin (H&E) staining were applied to the samples by taking 5-6 sections with microtome from these blocks. After the staining, the samples were examined under a light microscope (Olympus Bx51, Japan). The locations of the horn glands detected in both goat breeds were photographed.

## **RESULTS**

### **Macroanatomic findings**

The distance between the horns of the Abaza and Georgian goat was measured using an electronic caliper. The mean distance between the horns of the Abaza goats was  $36,80 \pm 8,62$  mm while this distance was  $39,63 \pm 4,10$  mm for the Georgian goats. The mean horn lengths for the Abaza and Georgian goats were 276.66 mm and 288.66 mm, and the transverse surface lengths of the horns were 193.33 mm and 218.33 mm, respectively.

Similarly, the mean horn lengths of the right and left horns of the Georgian goats were 382.5 mm and 395 mm and their transverse surface lengths were 170 mm and 175 mm, respectively. As a result of the macro-anatomical analyses performed, the presence of glandula intercornualis, which can be seen in various goat breeds macroscopically, was not found in the samples used in this study (Figure 1, 2).

### **Histological findings**

As a result of the light microscopic examinations conducted on the skin samples, it was observed that both goat breeds contained layers of epidermis, dermis and muscle (Figure 3). The epidermis layer was found to be multi-layered and have a flat epithelium and a microscopic papillae. Under the epidermis, there were the stratum papillare (str. Superficiale) and stratum reticular (str. profundum) substrates of the dermis, as well as the connective tissue of the dermis, vessels, veins, hair roots and hair muscles (Figure 4,5). It was seen that the sebaceous glands that have a plurivacuolar structure and contain oil droplets were open at the hair roots (Figure 6). In addition, the presence of sweat gland drainage duct structure was determined in both goat breeds (Figure 5).

After the gland structures of the two goat breeds were determined, normal sebaceous gland structure (Figure 7) was observed to be intense behind the horn and less localized in the anterior parts. In the present study, it was observed that these gland structures were in the back part of the middle part of the horn as we thought that there might be horn glands. It was determined that these gland structures were located parallel to the epidermis in the stratum superficiale layer of the dermis in both goat breeds (Figures 8 and 9). In the Abaza goats, these gland structures were found in the middle part of the superficiale region of the dermis layer, in a more regular and broadly located lobed form (Figure 10). In the Georgian goats, the localization of these glands was more superficial, in other words, close to the epidermis and had a narrower structure with more lobes (Figure 11). In both breeds, it was observed that the normal sebaceous glands were negligible in the regions containing this gland structure. It was thought that these glands, which had more lobes and branched alveolar structures, may be the horn glands as they were different from the typical sebaceous glands found around the hair root. In some cases, these glands which were thought to be the horn glands and the sebaceous glands were found together, however they contained cells with different structures and staining properties (Figure 12). In addition, when the sebaceous gland structures of the two

breeds were examined, it was observed that the fat cells in the Georgian goats were structurally smaller than those of the Abaza goats.

## **DISCUSSION**

In the present study, morphologically similar, but two different breeds of the Abaza, Georgian goat breeds the front, back, side of the horn glands were determined by cross-section.

In a study reported that the horned glands of the polled goat breeds were located on the caudal surface of the head under the skin folds (Lancker et al. 2005) This, however, was not observed in the present study for the Abaza goats or the Georgian goats.

In a study conducted on the horn glands of West African dwarf goats (WADG) and red Sokoto goats (RSG), in Nigeria, the horn glands were reported to be simple or branched alveolar sebaceous glands. It was stated that the horn glands were structurally similar to the sebaceous glands located in other parts of the body in both the males and the females. As with other sebaceous glands, the horn glands are often said to be associated with hair follicles. However, in a few cases, it has been reported that one or more sebaceous glands are associated with a hair follicle, and each of these glands has a separate secretion portion, as well as a separate secretory channel opening to the hair follicle. In the Abaza and Georgian goats, it was observed that the glands were simply branched and alveolar, and their secretions were drained through the hair follicles (Chukwu et al., 1989). The structures specified as horn glands in the present study were found to be similar to the glands of the Nigerian goat breeds. However, unlike the breeds in Nigeria, a secretion channel was not found in the Abaza and Georgian goats.

It reported that two sebaceous glands associated with a single hair follicle had two lobes (Jenkinson et al. 1967, Bal and Ghoshal 1976). This was found to be similar for the Abaza goats examined in the present study, however more lobed glands were found around a hair follicle in the Georgian goats.

In a study conducted on American goats, horn glands and other sebaceous glands were compared and it was reported that the sebaceous glands had larger alveoli (Sar et al., 1966). In the present study, it was seen that the sebaceous glands had more alveoli than the horn glands

in the goat breeds, and that the structures that were thought to be horn glands in both of the goat breeds were more than the sebaceous glands.

WADG are found in the tropical forest areas of Southern Nigeria, while RSG are found in the savannah regions of Northern Nigeria. It was reported that climate can have an impact on the glands of these goats, and that seasonal changes alter the size of the British and American goat horn glands (Jenkinson et al., 1967; Bal and Ghosal, 1976).

It reported that the differences in the cross-sectional area of the horn glands and other sebaceous glands were more prominent in male Nigerian goats than the female ones and that these glands were involved in odor production (Chukwu et al. 1989). In the present study, the reason for the glands being larger and more active was thought to be because the samples used were collected during the breeding season of the goats.

In the present study, horn glands could not be detected macroanatomically in the Abaza and Georgian goat breeds, however they were found histologically and their structure were seen to be similar to those mentioned in the literature. This study can help guide future studies.

### **Conflict of interest**

The authors declare that they have no conflict of interest.

### **REFERENCES**

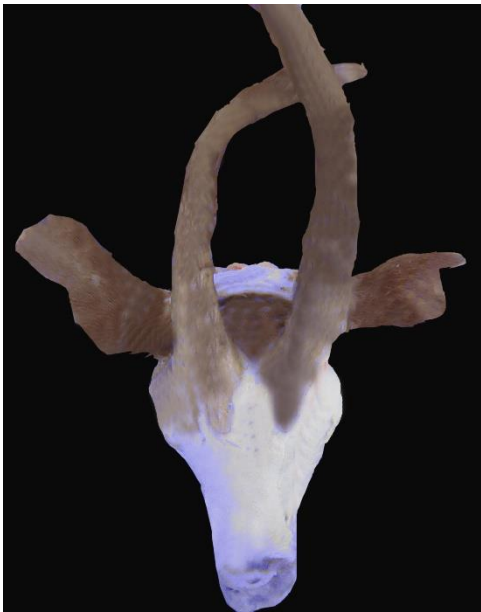- Anonim. Abaza keçisi koruma altında, Artvin İl Gıda Tarım ve Hayvancılık Müdürlüğü (28.11.2016).
- Bal, HS, Ghoshal, NG. (1976): The scent glands of the goat (*Capra hircus*). *Zentralbl. Veterinirmed., C, 5: 104.*
- Batu, S., (1951): Türkiye Keçi Irkları. Ankara Üniversitesi Veteriner Fakültesi Yayınları, Ankara.
- Brouwer, F. and Nijkamp, HJ. (1952): Volatileacids in these cretion products (hair grease) of the skin. *Biochem. J., 52: 54-58.*

- DO, Chukwuand. EC, Ihemelandu. (1989): Morphometric Studies on Horn Glands of Nigerian Breeds of Goat. *Small Ruminant Res*, 2, 367-374 367.
- Dalga, S. (2019): Topographic and morphometric study of the mental foramina of Abaza goats with its clinical implication for regional anesthesia. *Folia Morphologica*, DOI: 10.5603/FM.a2019.0122.
- Ebling, FJ. (1957): The effects of testosterone and oestradiol on the sebaceous glands and epidermis of therat. *J. Embryol. Exp. Morphol.*, 5: 74-82.
- Erençin Z. (1958): Genel Histoloji, Ankara Üniversitesi Veteriner Fakültesi Yayınları:98.
- French, MH. (1970): Observations on the goat. FAO, Rome, p. 2.
- Jenkinson, G. Blackburn, PS. Proudfoot, R. (1967): Seasonal changes in the skin glands of the goat. *Br. Vet. J*, 123 (12): 541-549,1967, DOI: 10.1016/s0007-1935(17)39654-9.
- Kuru, M., Kuru, B., Kulaksız, R., Arı, UÇ., Oral, H. (2017): Abaza Keçilerinde Progesteron Destekli Östrus Senkronizasyonunun Bazı Reprodüktif Parametrelere Etkileri *Kocatepe Vet J 10 ( 3 )*: 164 - 171 DOI: 10.5578/kvj.57526.
- S. Van Lancker., W. Van den broeck., P. Simoens, (2005): Morphology of caprine skin glands involved in buckodour production, *The Veterinary Journal 170*, 351-358.
- Sar, M. and Calhoun, ML. (1966): Microscopic anatomy of the integument of the common American goat. *Am. J. Vet. Res.*, 27: 444-456.
- Sezgin, E., Kopuzlu, S., Yüksel, S. (2010): Abaza keçisi. Ulusal Keçicilik Kongresi, Çanakkale, pp. 241-244.
- Strauss, JS. Kligman, AM. and Pochi, PE. (1962): The effect of androgen and estrogen on human sebaceous glands. *J. Invest. Dermatol.*, 39: 139-155, 1962. DOI: 10.1038/jid.1962.94.
- Yalçın BC, (1990): Türkiye’de yetiştirilen keçi ırkları. “Koyun-Keçi Hastalıkları ve Yetiştiriciliği”, Ed; Aytuğ CN, Alaçam E, Özkoç Ü, Yalçın BC, Gökçen H, Türker H, Tüm Vet. Hayvancılık Hizmetleri Yayını, Teknografik Matbaası, İstanbul, Türkiye.

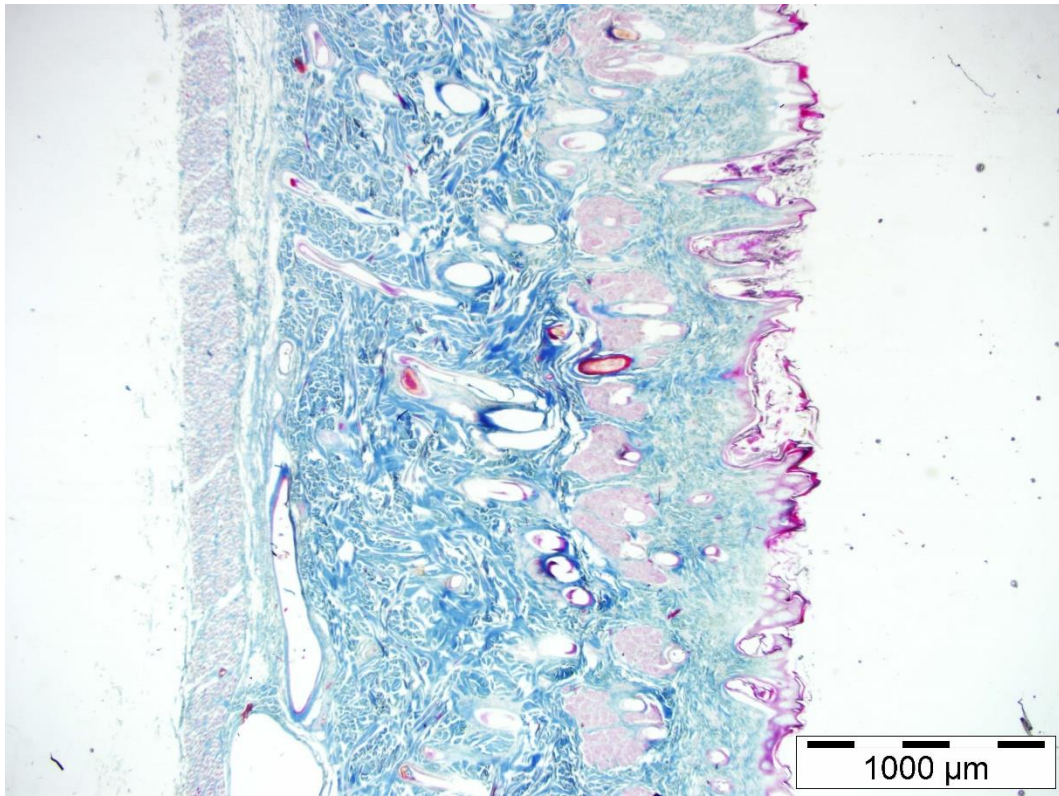




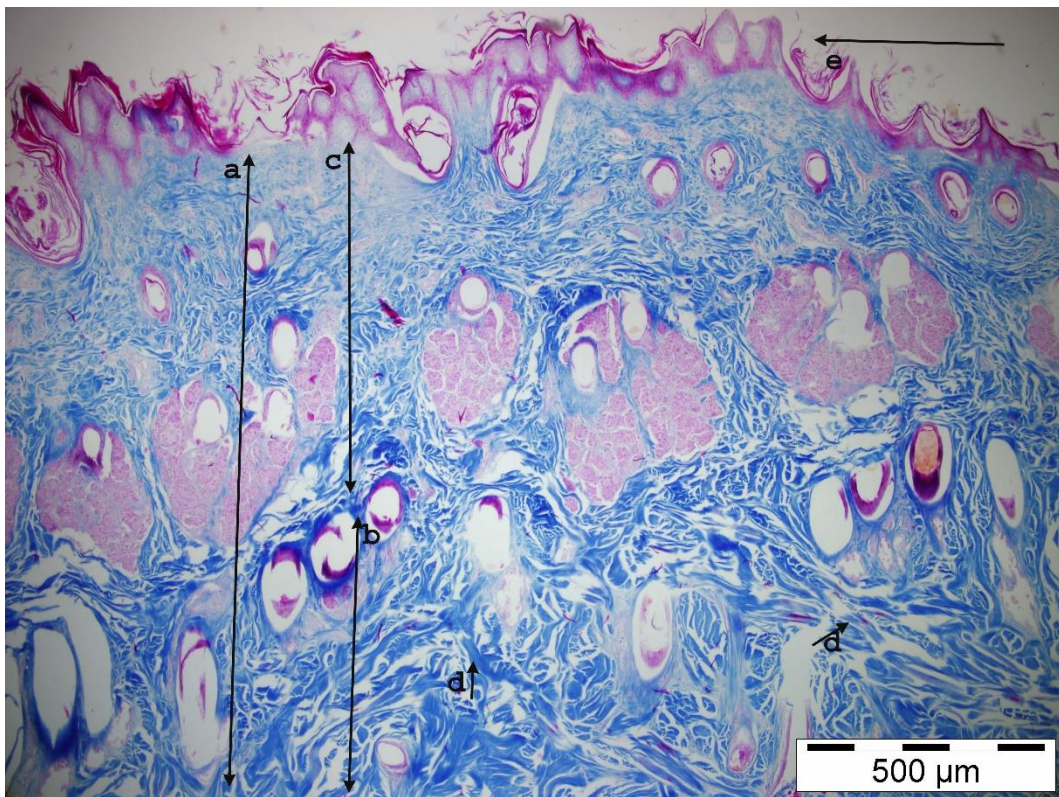
**Figure 1.**The horns of an Abaza goat



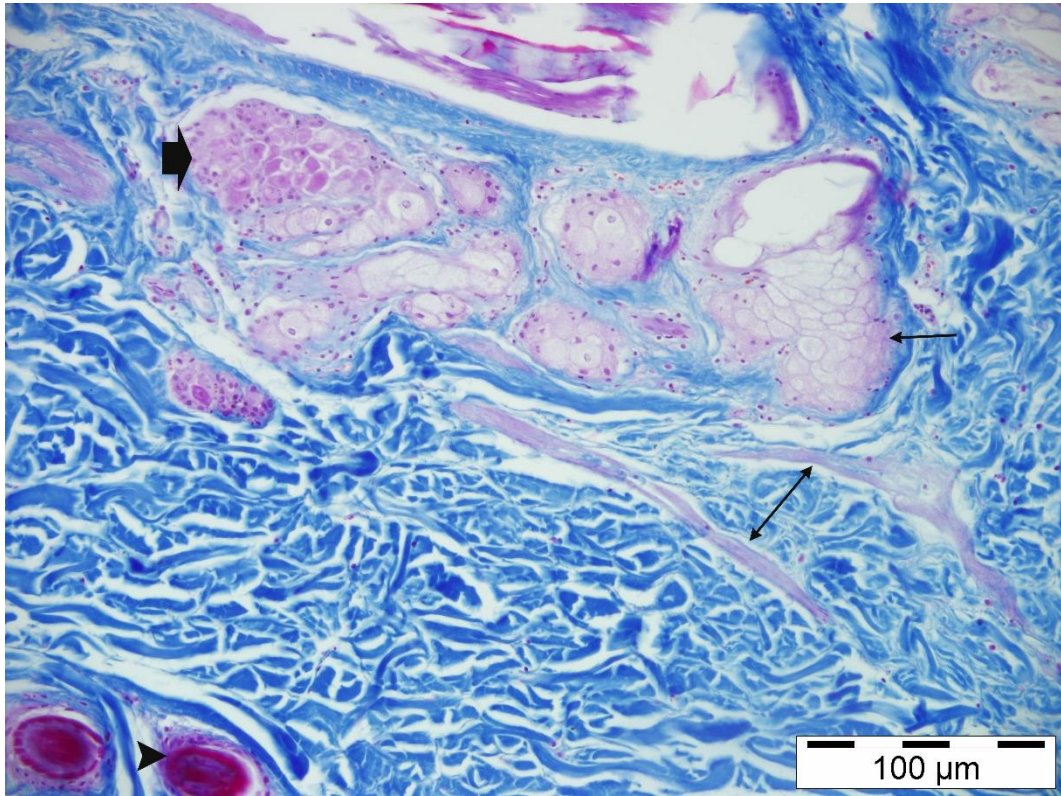
**Figure 2.** The horns of a Georgian goat



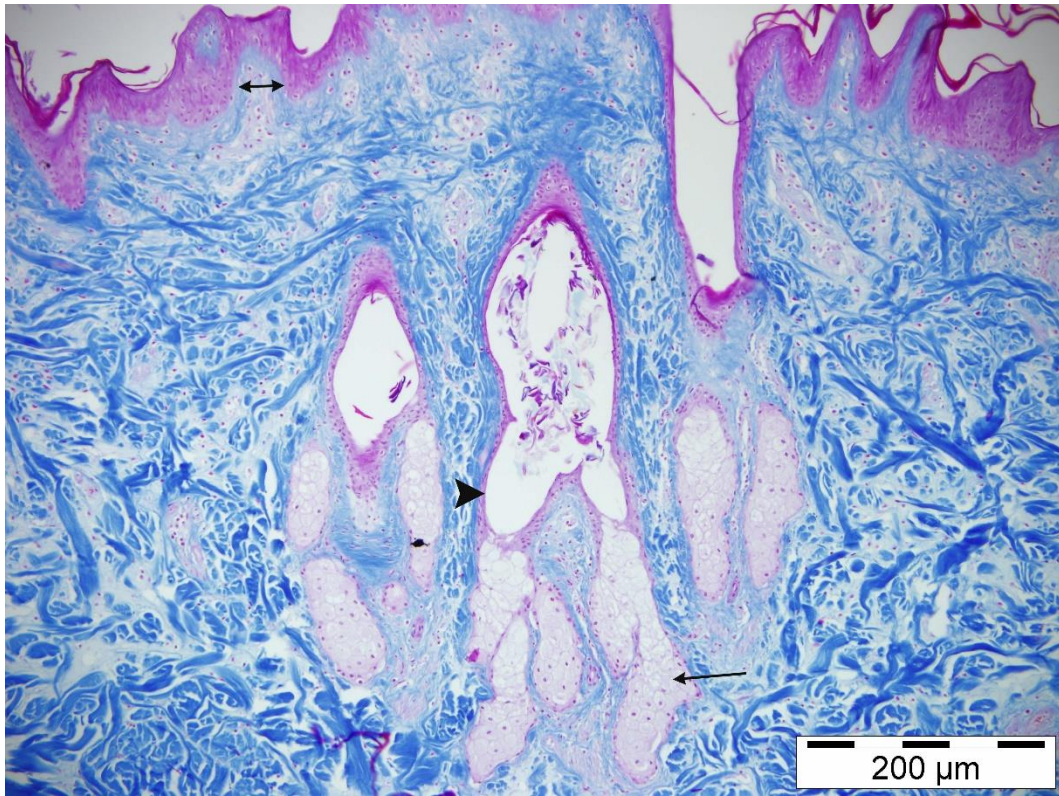
**Figure 3.** Microscopic view of the skin of goats. Tripple X 2



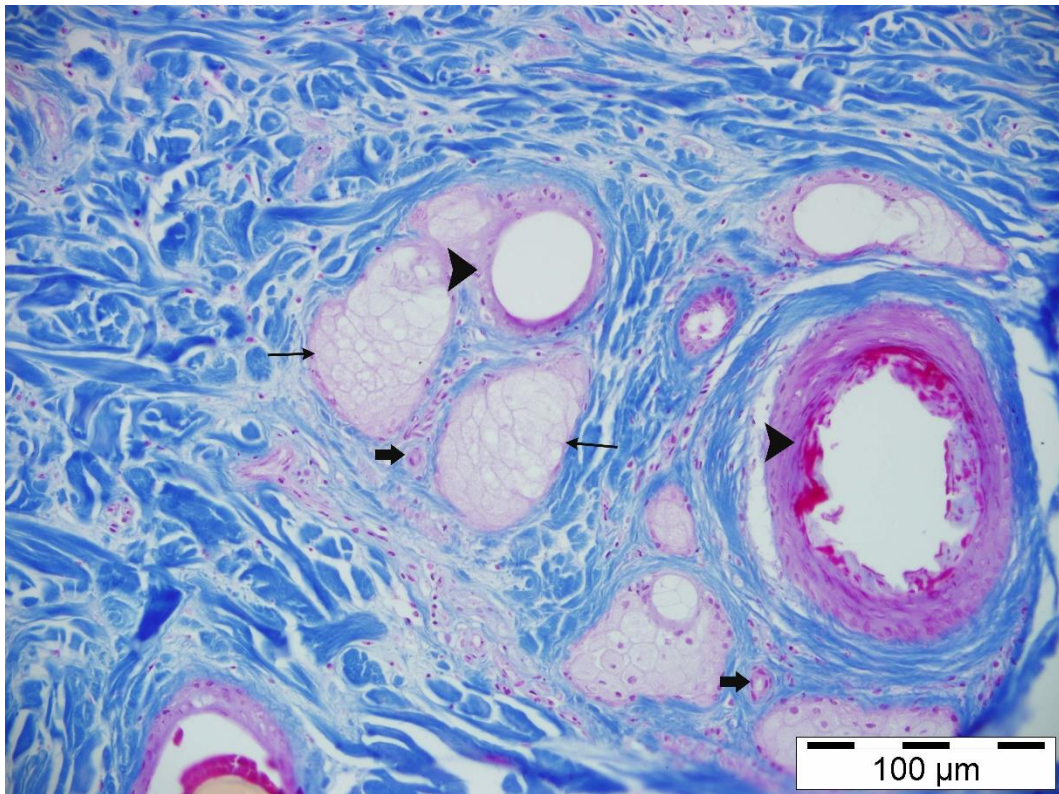
**Figure 4.** Dermis layers of in the goats. a) dermis b) stratum polymorphic c) stratum superficial d) collagen yarns e) epidermis



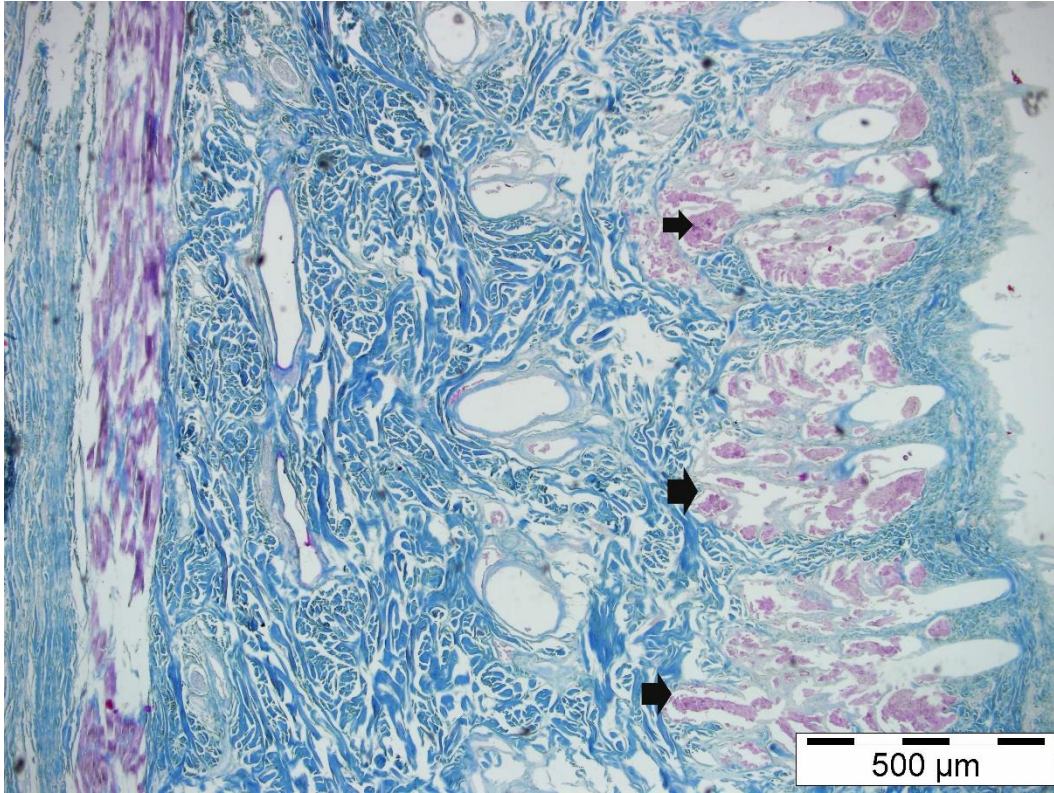
**Figure 5.** Dermis structures of the goats. Arrowhead: hair root thin arrow: sebaceous glands  
thick arrow: sebaceous gland-like structures double headed arrow: muscle erraktor battery  
Tripple x 20



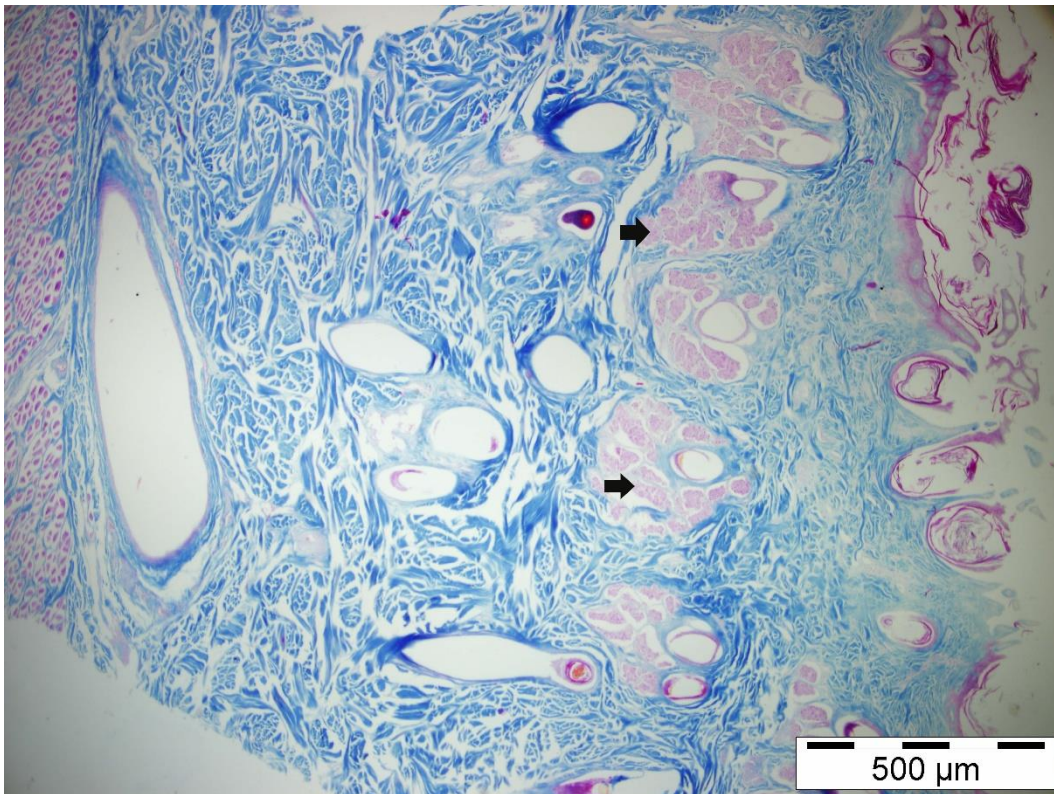
**Figure 6.** The opening of the sebaceous glands to the hair root in the dermis. Thin arrow: sebaceous glands, arrowhead: hair root double-headed arrow: multi-layer epithelial structure



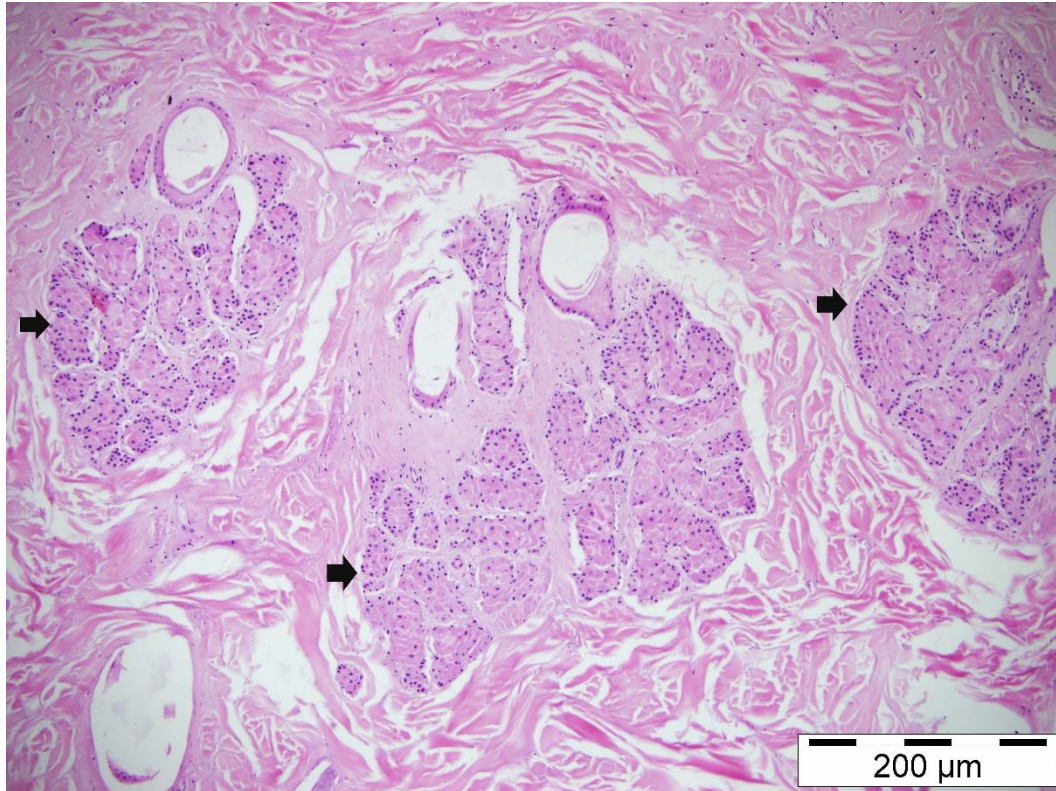
**Figure 7.** Microscopic view of a hair follicle, sebaceous gland and sweat gland drainage duct. Arrowhead: hair root thin arrow: oil glands thick arrow: sweat gland duct



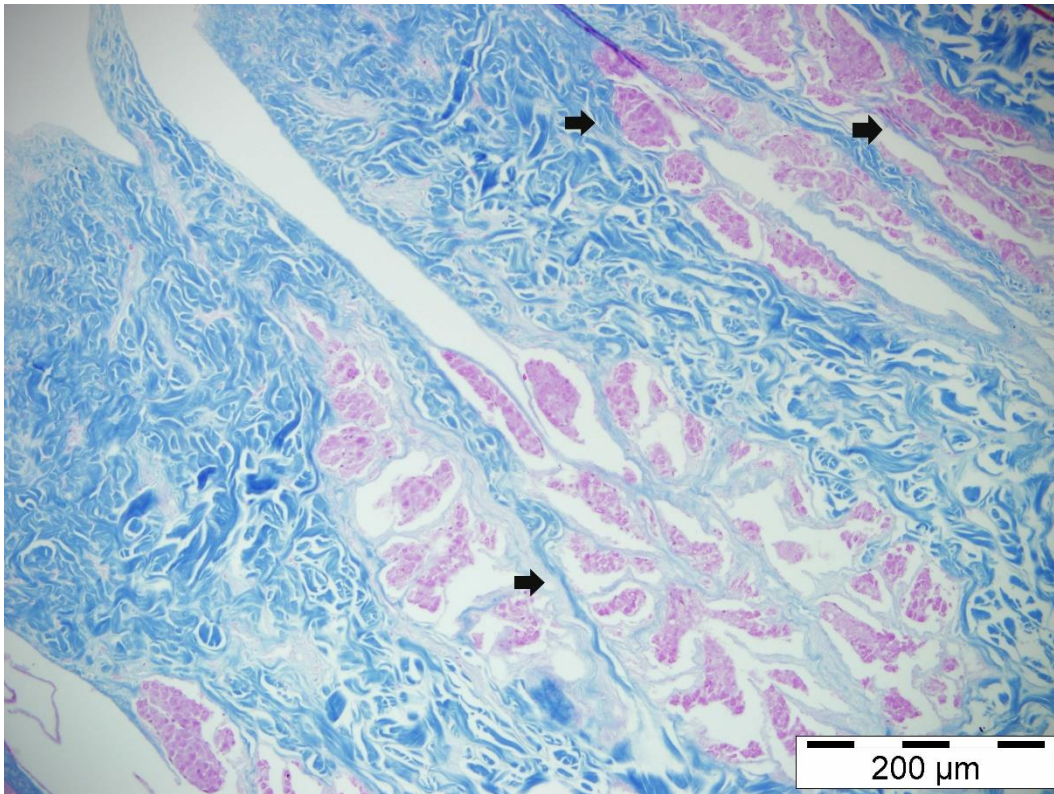
**Figure 8.** Localization of the glands in stratum superfiale of the Georgian goats. Thick arrow: Tripple, x 4, similar to the sebaceous gland structures



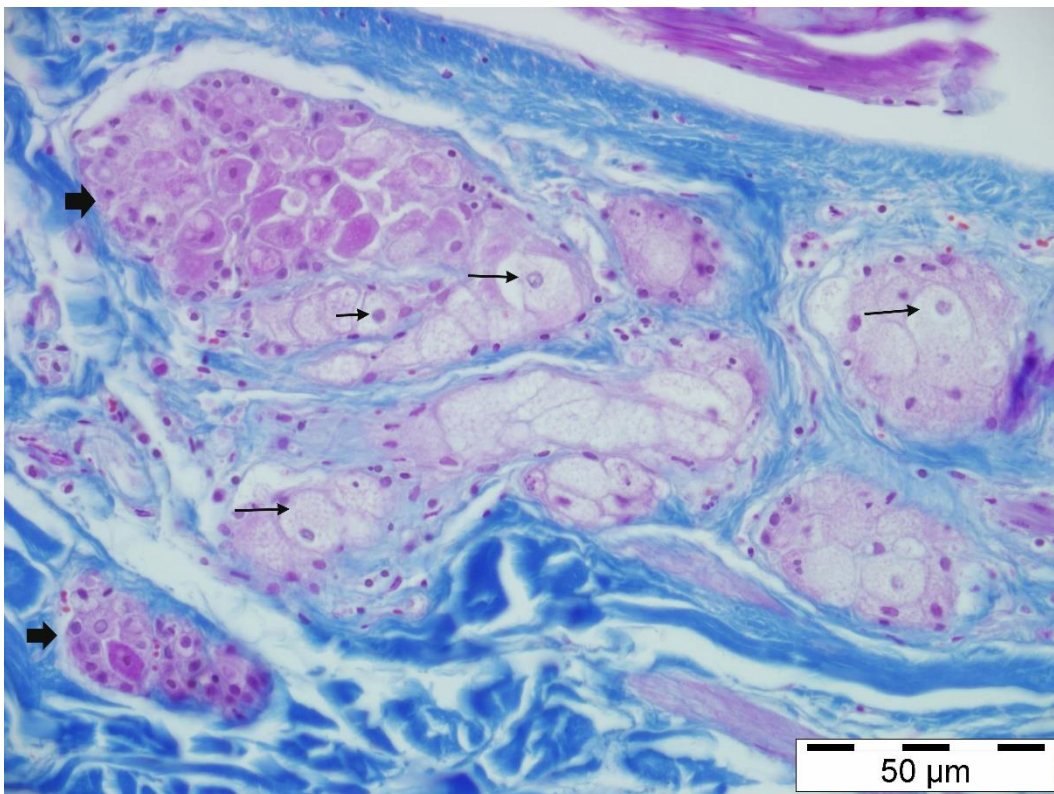
**Figure 9.** Localization of the glands in the stratum superficiale of the Abaza goats. Thick arrow: Tripple, x 4, similar to the sebaceous gland structures



**Figure 10.** Lobe (alveolar) structure of the glands of the Abaza goats. Thick arrow: oil cloth-like structures H & E



**Figure 11.** Multi-lobed structure of the glands of the Georgian goats. Thick arrow: Tripple, similar to the sebaceous gland structures, x 10



**Figure 12.** Different cell groups located between the fat cells in the dermis. Thick arrow: oil gland-like structures Tripple, x 40