

Dilated cardiomyopathy with severe arrhythmias in Emery-Dreifuss muscular dystrophy

Andrzej Kułach¹, Michał Majewski¹, Zbigniew Gąsior¹, Rafał Gardas²,
Kinga Gościńska-Bis², Krzysztof S. Gołba²

¹Department of Cardiology, School of Health Sciences, Medical University of Silesia, Katowice, Poland

²Department of Electrocardiology and Heart Failure, School of Health Sciences,
Medical University of Silesia, Katowice, Poland

Herein presented is the case of a 51-year-old male with Emery-Dreifuss muscular dystrophy (EDMD) with a history of rapid progression heart failure (HF) and heart rhythm disturbances over an 8 year period. EDMD is a rare genetic condition that primarily affects skeletal muscles. The patient presented with muscle weakness since childhood. Family history was negative. At the age of 43 atrial fibrillation was diagnosed and 2 years later a single chamber pacemaker was implanted due to third atrioventricular block. After another 2 years, the patient was admitted due to ventricular tachycardia. Transthoracic echocardiography (TTE) revealed moderately reduced left ventricular function (ejection fraction [EF] 48%). A single-chamber cardioverter-defibrillator (ICD-VR) was implanted. After 2 years of well-being, he was admitted to the hospital due to an electrical storm. TTE revealed dilated cardiomyopathy with severe left ventricular dysfunction (EF 15%). Due to clinical presentation,

a high percentage of right ventricular pacing, and wide QRS complex (paced QRS 200 ms) the patient qualified for cardiac resynchronization therapy with defibrillator (CRT-D). The left ventricular electrode was implanted and ICD was upgraded to CRT-D resulting in a correct VVI-BiV stimulation with narrowing of QRS complexes to 140 ms. TTE performed after another few months showed significantly improved EF (30%). After another year a right ventricular lead malfunction occurred — myopotential oversensing and inappropriate detection of ventricular tachycardia. Connection of the right ventricular pace/sense lead to the pace-sense header resulted in proper sensing. Since then the patient has remained stable. EDMD leads to HF, arrhythmias and conduction disturbances in about 30% of cases. It is thus believed that implantation of CRT-D in an early stage of cardiac involvement may both treat arrhythmias and slow HF progression (Fig. 1).

Conflict of interest: None declared

Address for correspondence: Andrzej Kułach, MD, PhD, Department of Cardiology, School of Health Sciences, Medical University of Silesia, ul. Ziołowa 47, 40–636 Katowice, Poland, tel: 505 863 793, e-mail: andrzejkulach@gmail.com

Received: 13.09.2019

Accepted: 25.12.2017

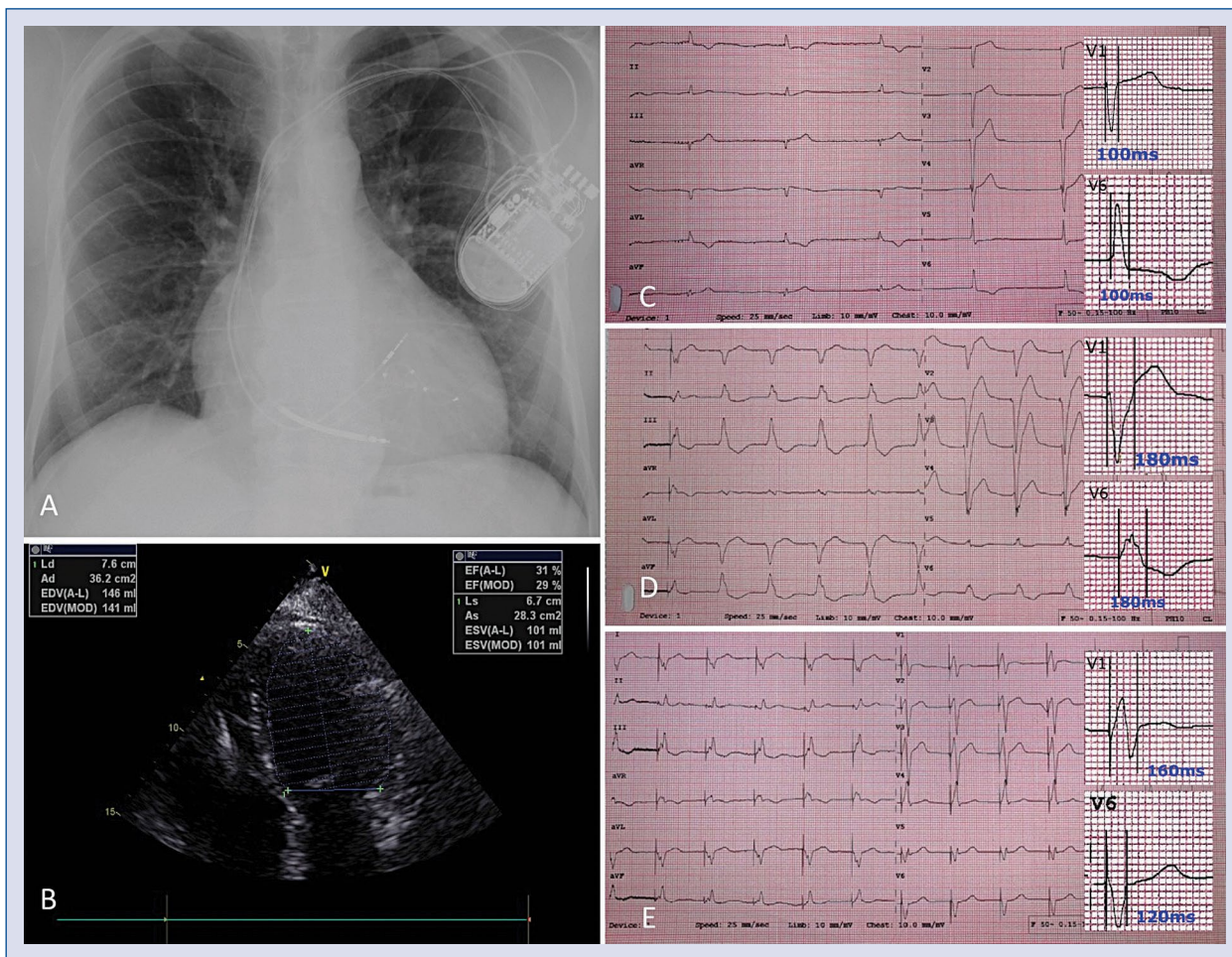


Figure 1. A. Chest X-ray after cardiac resynchronization therapy (CRT) implantation; B. Dilated cardiomyopathy in transthoracic echocardiography; C. Native rhythm electrocardiogram with atrial fibrillation and complete atrioventricular block; D. Electrocardiogram after single-chamber implantable cardioverter-defibrillator implantation; E. Electrocardiogram after up-grade to CRT-D with VVI-BiV mode stimulation.