



# Puncture site bleeding complications in patients with Clopidogrel hyper-response. Three case reports

Nedeljković Žarko<sup>1</sup>, Vukasinović Ivan<sup>2</sup>, Majstorović Branislava<sup>3</sup>, Milosević Medenica Svetlana<sup>2</sup>, Milićević Mihailo<sup>1</sup>, Ilić Rosanda<sup>1</sup>, Aleksić Vuk<sup>1</sup>, Paunović Aleksandra<sup>1</sup>, Stanimirović Aleksandar<sup>1</sup>, Scepanović Vuk<sup>1</sup>, Milić Marina<sup>1</sup>, Todorović Marko<sup>1</sup>, Milisavljević Filip<sup>1</sup>, Grujičić Danica<sup>1</sup>

<sup>1</sup> Clinic for Neurosurgery, Clinical Center of SERBIA

<sup>2</sup> Center for Radiology and Magnetic Resonance, Clinical Center of SERBIA

<sup>3</sup> Center for Anesthesiology, Clinical Center of SERBIA

## ABSTRACT

Dual antiplatelet therapy (clopidogrel and acetylsalicylic acid) is a standard for the embolization of planned intracranial aneurysms with CNS stent due to the possibility of stent thrombus formation. All anti-aggregation drugs, including those listed, have bleeding as a side effect. Three patients with aneurysm had an elevated response to antiplatelet therapy with clopidogrel, which was confirmed by a multiplate test on the "VerifyNow" system. After reducing the dose of clopidogrel or after interrupting it, with the introduction of low molecular weight heparin for the duration of five days, aneurysms were successfully resolved by intracranial implantation of the stent. Perioperative angiograms and postoperative CT angiograms have verified hematomas at the place of puncture of the femoral artery. Bleeding was resolved by the femoral artery suture by a vascular surgeon. All patients were discharged home without further complications and with dual antiplatelet therapy. By measuring the platelet function in vitro, the degree of inhibition of platelet activity achieved by the action of the drug can be assessed. A specific test can identify those patients who are highly responsive to the drug with increased platelet reactivity and the possibility of increased risk of bleeding. Our suggestion is to reduce the dosage of clopidogrel or to leave it out for 24 hours with preventive doses of low molecular weight heparin or to change the strategy of treatment of intracranial aneurysm, i.e. avoiding implantation of CNS stent.

## INTRODUCTION

According to statistics, about 5% of the population has intracranial aneurysm, out of which 1 to 2% suffer from aneurysm rupture with a dramatic clinical manifestations and consequences [1,2,3]. Today, it is

## Keywords

intracranial aneurysms,  
dual antiplatelet therapy,  
Clopidogrel hyper-response



Corresponding author:  
**Vuk Aleksić**

Clinic for Neurosurgery, Clinical  
Center of Serbia

[aleksicvuk@hotmail.com](mailto:aleksicvuk@hotmail.com)

**Copyright and usage.** This is an Open Access article, distributed under the terms of the Creative Commons Attribution Non-Commercial No Derivatives License (<https://creativecommons.org/licenses/by-nc-nd/4.0/>) which permits non-commercial re-use, distribution, and reproduction in any medium, provided the original work is unaltered and is properly cited.

The written permission of the Romanian Society of Neurosurgery must be obtained for commercial re-use or in order to create a derivative work.

ISSN online 2344-4959  
© Romanian Society of  
Neurosurgery



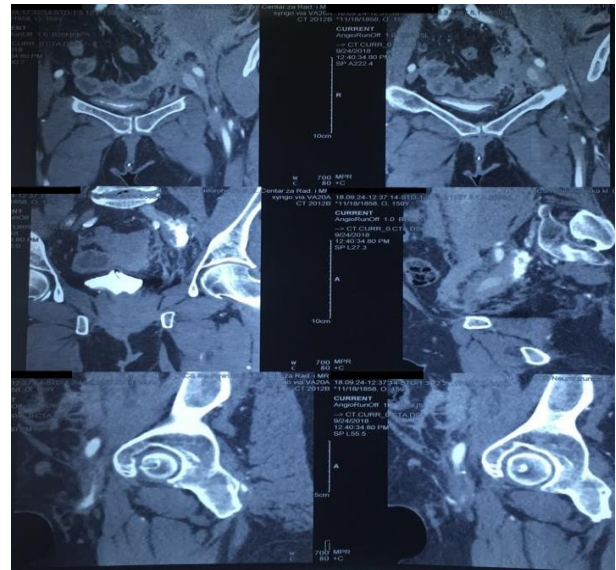
First published  
March 2020 by  
London Academic Publishing  
[www.lapub.co.uk](http://www.lapub.co.uk)

believed that endovascular treatment is a better, more modern and less aggressive treatment associated with less complications and lower mortality, shorter length of hospital stay and lower costs of treatment compared to conventional neurosurgical treatment, i.e. microsurgical clipping of aneurysms [4,5,6,7,8]. The current standard of preoperative preparation for stent placement in aneurysms involves dual antiplatelet therapy with acetylsalicylic acid and clopidogrel. Antiplatelet drugs inhibit platelet aggregation and thus stop the formation of thrombus. Thrombus formation is a complex mechanism of responses to vascular changes, injuries, atherosclerosis and other diseases. The data indicate that in addition to the effect of these drugs, other local and systemic factors (diabetes mellitus, left ventricular hypertrophy, atrial fibrillation) may be the cause of unwanted ischemic events [9,10]. Other antiplatelet drugs: prasugrel, dipyridamole, cilostazol, cangrelor and ticagrelor have not been analyzed so far, and therefore are the subject of recent researches that are yet to define the benefits of their application in therapy.

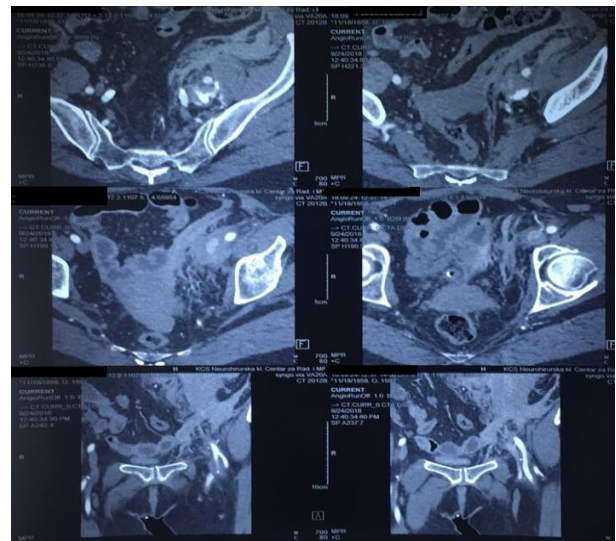
### CASE 1

Pre-procedural angiograms showed the condition of 59-year-old patient, after the coiling of ACI aneurysms on both sides. From the medical documentation, it is learned that the patient's embolization of aneurysms was done on both internal carotid arteries in 2016. Hematological parameters on admission: RBC  $4,75 \times 10^{12}/L$ , Hgb 138 g/L, Hct 0,45 L/L. Due to the impaction of the coiling to the right internal carotid artery, placement of the stent was planned, therefore, three days before the intervention, the patient was administered clopidogrel 75 mg twice daily and acetylsalicylic acid 100 mg once a day. Drug-resistance testing on the „VerifyNow“ device showed an increased sensitivity of platelet activity to the action of clopidogrel. Clopidogrel was discontinued for five days and acetylsalicylic acid was continued. During this period, a low molecular weight heparin is administered at a dose of 0,3 ml twice a day, and then it was proceeded to the procedure. By accessing the left femoral artery, the Flow diverting Silc 3x20mm stent is placed over the aneurysm's neck on the right internal carotid artery, which causes the pathway obstruction of the contrast agent in aneurysm. During puncture there was perforation of the left femoral artery and

extravasation of the contrast medium with the expansion pathway caudally. The intervention was interrupted, the puncture site was pressed with long-term compression in groin. The patient complained of pain in the left side of abdomen. Physical examination found palpatory pain sensation of the abdomen and drop in blood pressure. CT angiography of the leg and abdomen showed the extravasation of the contrast agent at the level of the left femoral artery with expansion towards the retroperitoneum. [Figure 1, Figure 2].



**Figure 1.** Angiographic presentation of aneurysms and CT angiographic exploration of bleeding at the puncture site.




**Figure 2.** Angiographic presentation of aneurysms and CT angiographic exploration of bleeding at the puncture site.

The vascular surgeon was called for consultation. The patient was transferred and operated in the Clinic for vascular and endovascular surgery of Clinical center of Serbia where hematoma was evacuated and suture of left femoral artery was performed. Hematological parameters two days after femoral artery puncture: RBC  $2,56 \times 10^{12}/L$ , Hgb 80 g/L, Hct 0,25 L/L. In the postoperative course, the patient received fraxiparine at a dose of 0,3 ml twice daily for the next eight days. After leaving the hospital, dual antiplatelet therapy (clopidogrel and acetylsalicylic acid) was continued for the next three months once a day, followed by acetylsalicylic acid onwards.

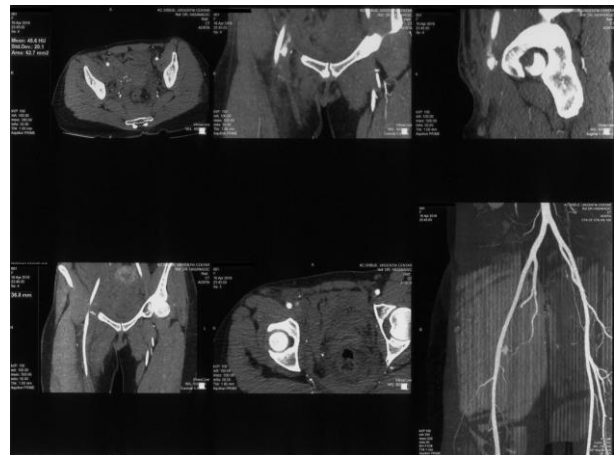
## CASE 2

A 45-year-old female patient was previously planned for the placement of an intracranial stent due to an aneurysm on anterior communicating artery. She was taking clopidogrel 75 mg twice a day and acetylsalicylic acid 100 mg once a day for three days. Hematological parameters on admission: RBC  $4,13 \times 10^{12}/L$ , Hgb 128 g/L, Hct 0,409 L/L. Drug-resistance testing on the „VerifyNow“ device showed an increased sensitivity of platelets to the action of clopidogrel. Administration of clopidogrel was stopped for the next five days, it was continued with the administration of acetylsalicylic acid 100 mg once a day. Also, 0,3 ml of fraxiparin was administered twice a day, and then it was proceeded with procedure. Through the right femoral artery, the guiding catheter was placed in the left internal carotid artery, the microcatheter was positioned in the aneurysm which was excluded from the circulation by placing the coil. As aneurysm was resolved by a coil, the dual antiaggregation therapy was interrupted in the postoperative course. In the early postprocedural period, hematoma formation in the groin region occurred, and therefore changes in the complete blood count: RBC  $2,87 \times 10^{12}/L$ , Hgb 91 g/L, Hct 0,264 L/L. The patient complained of pain in the lower right quadrant of the abdomen in the area above the right inguinal ligament. A vascular surgeon was consulted, after which a patient was admitted to the Clinic for vascular and endovascular surgery of Clinical center of Serbia. CT angiography of the leg and abdomen was performed, which showed the presence of a lesion in the area of the transition of the external iliac to the right common femoral artery with extravasation of contrast. [Figure 3, Figure 4,

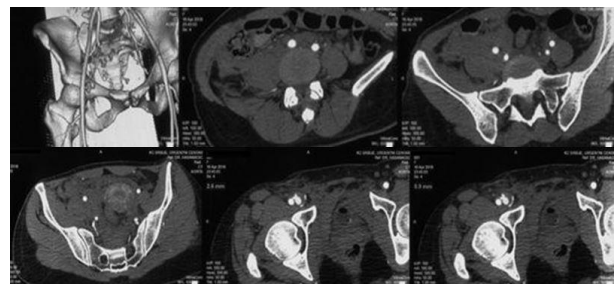
Figure 5] Due to active retroperitoneal bleeding, conciliar decision was to undergo emergency surgical treatment. The patient was postoperative hemodynamically stable with palpable pedal pulses.



**Figure 3.** CT angiography of the leg and abdomen showing the presence of a lesion in the area of the transition of the external iliac to the right common femoral artery with extravasation of contrast.



**Figure 4.** CT angiography of the leg and abdomen showing the presence of a lesion in the area of the transition of the external iliac to the right common femoral artery with extravasation of contrast.



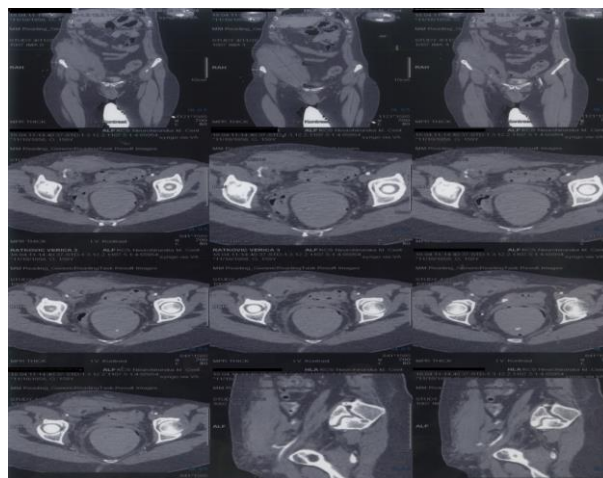
**Figure 5.** CT angiography of the leg and abdomen showing the presence of a lesion in the area of the transition of the external

iliac to the right common femoral artery with extravasation of contrast.

### CASE 3

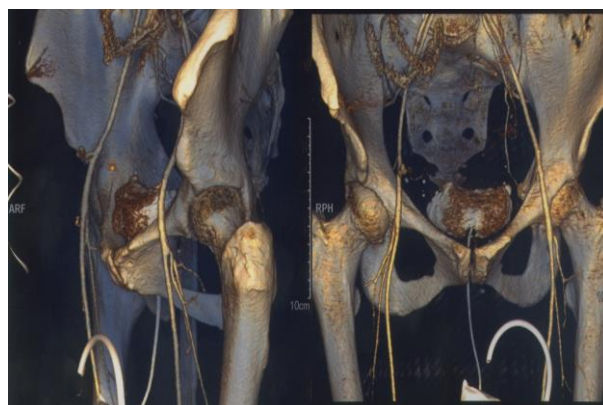
A 47-year-old female patient was admitted to perform an endovascular treatment due to the presence of aneurysm on the supraclinoid segment of the left internal carotid artery, which was randomly detected as part of the examination of pituitary microadenoma. The width of aneurysm neck was 6,5 mm. The patient was planned for placing of the flow diverting stent over the aneurysm neck. In the preprocedural period, the patient received dual antiplatelet therapy (clopidogrel 75 mg twice a day and acetylsalicylic acid 100 mg once a day) for three days. Drug-resistance testing on the „VerifyNow“ device showed an increased platelet sensitivity to clopidogrel. An aneurysm embolization was attempted on two occasions. During the second intervention, placement of microcatheter was attempted distal from the aneurysm neck in order to place a "flow-diverting" stent, which failed even after several attempts, and as a result, the procedure was interrupted. In the early postprocedural course, the condition of the patient worsened in terms of confusion, paleness, hypotension, and the presence of a larger subcutaneous hematoma in the right groin. CT angiography of the leg and abdomen was performed, which showed extravasation of contrast at the puncture site [Figure 6, Figure 7, Figure 8, Figure 9, Figure 10]. The patient was transferred to the Clinic for vascular and endovascular surgery of Clinical center of Serbia where the suture of right external iliac artery and evacuation of hematoma were performed. During the third hospitalization, the patient was again prepared for stent placement with dual antiplatelet therapy, and the response to clopidogrel was again too strong. This time, it was also attempted to place the stent through the aneurysm neck, but while the microwire was passing, further distal from the branch of the left middle cerebral artery, extravasation of contrast occurred. Protamine sulfate was administered by venous route, which is an antidote for intravenous administration of heparin and the contrast extravasation was no longer shown. It was attempted again to go through with a microcatheter distally from the neck of aneurysm, but even after additional attempts, it failed due to extremely unfavorable angioarchitecture. Subsequently, the microcatheter was used to access the fundus of

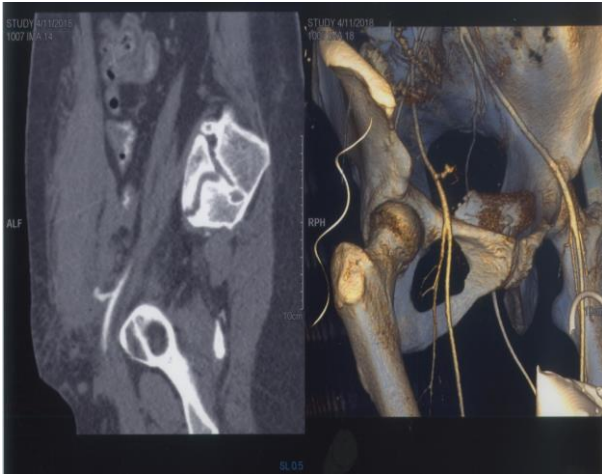
aneurysm and to place the "pCONUS" stent, and then, after placement of several coils, aneurysm was excluded from the circulation with less residual filling and preserved passage of all blood vessels. Postprocedurally, the patient was somnolent, slowed down, intubated and with progressive deterioration of consciousness. There was an acute hydrocephalus occurrence that was taken care by the external drainage of the cerebrospinal fluid [Figure 10]. On this occasion, a subdural hematoma was formed, which gradually spontaneously absorbed. Ten days after embolization, a permanent drainage system, ventriculoperitoneal shunt, was placed. It was continued with the administration of clopidogrel 75mg and acetylsalicylic acid 100mg once a day for three months, and then only acetylsalicylic acid 100mg going forward. There has been a recovery in the general and neurological condition of the patient with a residual right-sided weakness [Figure 11].



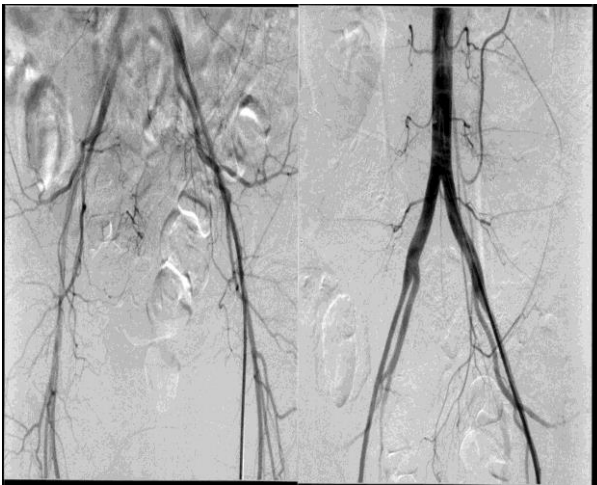
**Figure 6.** CT angiography of lower extremities et pelvis showing extravasation of contrast at the puncture site.

**Figure 7.** CT angiography of lower extremities et pelvis showing extravasation of contrast at the puncture site.

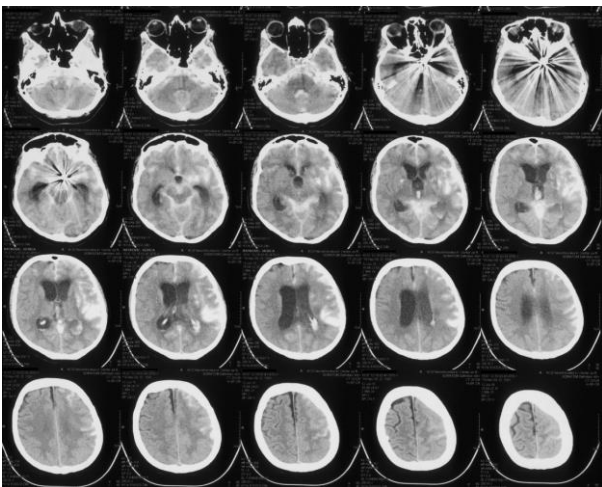




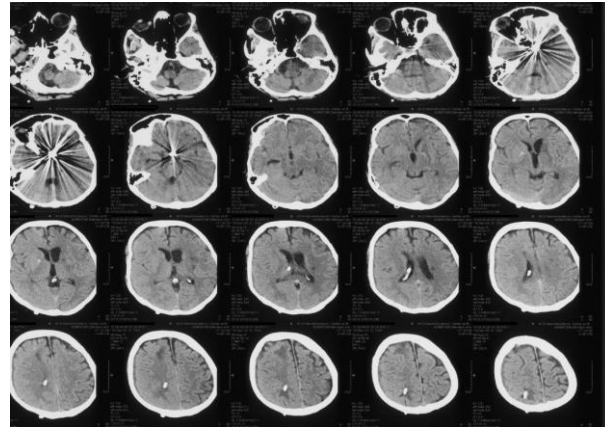
**Figure 8.** CT angiography of lower extremities et pelvis showing extravasation of contrast at the puncture site.



**Figure 9.** CT angiography of lower extremities et pelvis showing extravasation of contrast at the puncture site.



**Figure 10.** Head CT scan showing the occurrence of acute hydrocephalus.



**Figure 11.** Control head CT scan 1 month after the embolisation of aneurysm and VP shunt placement.

**DISCUSSION**

Neuroradiological procedures, such as embolization of intracranial aneurysms, have been routinely applied since their implementation in 1990 to the present day. They are performed in general anesthesia for better control of pain and immobility of patients, control of local blood flow at the site of vascular changes via mean arterial pressure, with the use of a continuous or bolus dose of heparin by the venous line. Dual antiplatelet therapy is used pre- and post-procedurally in cases of stent implantation. In principle, anticoagulant or antiplatelet therapy is widely used in various areas of medicine to prevent the development of occlusive thrombosis. When it comes to drugs, the prevention is achieved by changing the coagulation of the blood. Coagulation of the blood, composed of a series of proteolytic reactions, is a complex cascade process of which the ultimate result is the creation of insoluble fibrin.

The platelet function is regulated by three types of compounds. The first group consists of compounds that are formed outside of the platelet and act on receptors located on the platelet membrane: catecholamines, collagen, thrombin, prostacyclin. The second group of compounds consists of compounds that form in the platelet itself but act on membrane receptors: ADP, prostaglandins D2 and E2, and serotonin. The third group of compounds are produced by platelet, but they act in the platelet itself: thromboxane A2, cyclic AMP and GMP.

In clinical practice, acetylsalicylic acid and clopidogrel are generally available. Because of the high resistance to clopidogrel antiplatelet activity

(16%) measured by the same in vitro platelet function tests, a full range of drugs is available. Current studies evaluate the efficacy of P2Y12 receptor inhibitors: prasugrel, ticagrelor, cangrelor, elinogrel; then prothrombin antagonists, glycoprotein inhibitors, phosphodiesterases, and others.

A response to antiplatelet therapy with clopidogrel confirmed by drug-resistance testing on the „VerifyNow“ device. Verifynow System (Accumetrics Inc., San Diego, California, USA) monitors the platelet aggregation by agglutination of human-fibrinogen-coated granules, which is triggered by activated platelets stimulated by agonists in citrate full blood. This system measures induced platelet aggregation by ADP and prostaglandin E1, following an increase in light transmission (P2Y12) test. It uses an iso-thrombin receptor activating peptide (iso-TRAP) that activates platelets regardless of the action of clopidogrel. The results are expressed in the PRU (platelet reactivity unit) units showing the degree of aggregation mediated by P2Y12 receptors. [11,12,13]

Acetylsalicylic acid irreversibly inhibits the COX-1 enzyme, then the synthesis of cyclic endoperoxides and all prostaglandins that result therefrom. The COX-1 inhibition inhibits the synthesis of thromboxane, and then prostacyclin and prostaglandin E2. Due to irreversible enzyme inhibition, once daily dosing of the drug is sufficient. There are data indicating that at low doses of 100 mg per day, the biosynthesis of thromboxane can be selectively inhibited without any influence on prostacyclin synthesis. As a result, small doses of acetylsalicylic acid restrict the therapeutic effect of prostaglandins that have a significant role in a large number of physiological and pathophysiological processes in the body (regulation of arterial blood pressure, renal function or interaction with antihypertensive effect of diuretic, and angiotensin-converting enzyme, etc.) [14,15,16]

Simultaneous administration of analgesic drugs from a group of non-selective COX1 inhibitors, such as ibuprofen and naproxen, can lead to a reduction in acetylsalicylic acid by competing for the same receptor [17,18] in the preoperative and postoperative period.

Clopidogrel is a drug whose metabolite is a platelet aggregation inhibitor. To switch to an active metabolite that inhibits platelet aggregation,

clopidogrel is metabolized by the CYP450 enzyme. The active metabolite of clopidogrel selectively inhibits adenosine-diphosphate adhesion (ADP) for its P2Y12 receptors on platelets and in this way, via ADP-mediated activation of the IIb/IIIa glycoprotein complex, inhibits platelet aggregation. ADP binds to delta granules in platelets. ADP achieves its effect by binding to its platelet receptors and leads to: inhibition of adenylate cyclase by stimulating Gi protein and decreasing the concentration of intracellular cAMP, the formation of inositol triphosphate (IP3) leading to the mobilization of calcium from cell depots, the release of arachidonic acid leading to the creation of TXA2 and activation phospholipase A2. It is believed that ADP exhibits its effect by binding to three purinergic receptors: P2Y1, P2Y12, and P2X1. It is believed that P2Y12 plays a key role in the pathogenesis of arterial thrombus, mediating in ADP-induced platelet aggregation, potentiating the secretion of granules under the action of agonists and potentiating the inhibition of the antithrombotic effect of natural regulators of the platelet function, prostacyclin. P2Y12 is associated with Gi2 protein whose stimulation leads to the inhibition of adenylate cyclase and the activation of phosphatidylinositol 3 kinase (PI3K). Since this receptor is considered to have a central role in the formation of a coagulum, it is a target molecule for antithrombotic therapy. Due to irreversible binding, the effect of inhibition on the affected platelets lasts for the entire duration of their plasma life (about 7-10 days), and re-establishment of platelet function occurs after plasma exchange time [19]. This drug was approved in 1997 and after showing similar antithrombotic efficacy, but also as a significantly safer medication for patients, it completely replaced ticlopidine. For those patients with a history of stroke, it is known that antithrombotic therapy reduces incidence of re-ischemic events up to 22%. Clopidogrel proved superior to aspirin in reducing risk and was recommended for secondary prevention of stroke.

Due to irreversible inhibition of P2Y12 receptor, the effect of clopidogrel is present during the life of platelets (7-10 days). Cell recovery is expected in the period of 3 to 5 days, that is, the platelets are fully functional on average for 7 days after taking the last dose of the drug. The maximum inhibition of the P2Y12 receptor was achieved after 4-5 days of daily administration of 75 mg of clopidogrel. This interval

can be reduced to 3-5 hours by taking a loading dose of 300-600mg. Thus, in addition to the proven antithrombotic effect, clopidogrel has its disadvantages: its antithrombotic effect is delayed due to the necessary metabolism and activation of the prodrug, as well as interindividual variability in the therapeutic response to the drug.

The CYP enzyme system is responsible for 40-80% metabolism of almost all drugs in the active metabolite. Since clopidogrel and lipophilic statins are metabolised via the CYP3A4/3A5 enzyme system, the inhibition of the formation of the active metabolite of clopidogrel and unwanted thrombosis can occur [14,15]. Observations and randomized clinical studies have shown that the concomitant use of clopidogrel and proton pump inhibitors for pre-operative purposes, and due to gastric irritation, can lead to a reduction in the anti-aggregation effect and an increase in the number of repeated thromboses or ischemic events [20]. Dual anti-aggregation therapy is used to prevent the formation of thrombus or stent thrombosis. However, antiaggregation drugs can cause bleeding as an adverse drug reaction [21,22]. In the literature there are few studies that investigate increased sensitivity of platelets to the action of clopidogrel as opposed to postprocedural bleeding aneurysms [23]. For this reason, we listed 3 clinical cases with various causes of bleeding at the puncture site.

We believe that preprocedural management procedures should be acceptable in order to solve the resulting complication and complete the procedure. We summarized the mechanism of action, the current clinical assessment, and the standards for the use of antiaggregating drugs in the pre-procedural, procedural and postprocedural period for the treatment of unruptured aneurysms.

N	SEX	AGE	ANEURYSM
N <sup>1</sup>	F	59	ACI BILL.
N <sup>2</sup>	F	45	ACoA
N <sup>3</sup>	F	47	ACI L.SIN.

**Table 1.** Anthropological characteristics of the patients.

N	Clopidogrel bleeding<95-208<thrombosis	Acetylsalicylic acidbleeding<350-549<thrombosis
N <sup>1</sup>	3	359
N <sup>2</sup>	39	525

N <sup>3</sup>	14	370
----------------	----	-----

**Table 2.** Results of the resistance test for clopidogrel and acetylsalicylic acid.

#### REFERENCES

- Samardžić M, Grujičić D, Prstojević B. Spontanaintrakranijalnakrvarenja, U: Samardžić M, Ur. Hitnastanja u neurohirurgiji. Beograd, I.P. Obeležja;2010.
- Maud A, Lakshminarayan K, Suri MF, Vazquez G, Lanzino G, Qureshi A. Cost-effectiveness analysis of endovascular versus neurosurgical treatment for ruptured intracranial aneurysms in the United States. *J Neurosurg* 2009;110(5):880 – 6.
- Greving JP, Rinkel GJ, Buskens E, Algra A. Cost-effectiveness of preventive treatment of intracranial aneurysms: new data and uncertainties. *Neurology* 2009;73(4):258 – 65.
- Wolstenholme J, Rivero-Arias O, Gray A. Treatment Pathways, Resource Use, and Cost of Endovascular Coiling Versus Surgical Clipping After SAH. *Stroke* 2008;39:111 – 9.
- Higashida RT, Lahue BJ, Torbey MT, Hopkings LN, Leip E, Hanley DF. Treatment of unruptured intracranial aneurysms: a nationwide assessment of effectiveness. *AJNR Am J Neuroradiol* 2007;28(1):146 – 51.
- Varma MK, Price K, Jayakrishnan V, Manickam B, Kessell G. Anaesthetic considerations for interventional neuroradiology. *BJA* 2007;99(1):75 – 85.
- Labalette C, Houdart E, David S. Embolization of intracranial aneurysms: reimbursement and perspectives. *J Radiol* 2010;91:895 – 900.
- Majstorović BM, Milošević-Medenica SB, MilakovićBD, Naumović TS. New Interventional Neuroradiological Procedures in Serbia – The Direct Costs of Classical Neurosurgical Intervention in Relation to the Endovascular Treatment of Intracranial Aneurysms. *Hospital Pharmacology*. 2015;2(2):272-278.
- JenningsLK. Role of platelets in atherothrombosis. *Am J Cardiol* 2009;103:4A–10A.
- Bhatt DL. Role of antiplatelet therapy across the spectrum of patients with coronary artery disease. *Am J Cardiol* 2009;103:11A–9A.
- Prinz V, Finger T, Bayerl S, Rosenthal C, Wolf S, Liman T, VajkoczyP. High prevalence of pharmacologically induced platelet dysfunction in the acute setting of brain injury. *Acta Neurochir (Wien)* 2016;158(1):117-23.
- Flechtenmacher N, Kämmerer F, Dittmer R, Budde U, Michels P, Röther J, Eckert B. Clopidogrel Resistance in Neurovascular Stenting: Correlations between Light Transmission Aggregometry, VerifyNow, and the Multiplate. *AJNR Am J Neuroradiol*. 2015;36(10):1953-8.
- Jastrzębska M, Chelstowski K, Wódecka A, Siennicka A, Clark J, NowackiP. Factors influencing multiplate whole blood impedance platelet aggregometry measurements, during aspirin treatment in acute ischemic stroke: a pilot

- study. *BloodCoagul Fibrinolysis* 2013;24(8):830-8
14. Hall R, Mazer CD. Antiplatelet drugs: a review of their pharmacology and management in the perioperative period. *AnesthAnalg* 2011;112(2):292-318.
  15. Benedek IH, Joshi AS, Pieniaszek HJ, King SY, Kornhauser DM. Variability in the pharmacokinetics and pharmacodynamics of low dose aspirin in healthy male volunteers. *J ClinPharmacol* 1995;35:1181-6.
  16. Teo KK, Yusuf S, Pfeffer M, Torp-Pedersen C, Kober L, Hall A, Pogue J, Latini R, Collins R; ACE Inhibitors Collaborative Group. Effects of long-term treatment with angiotensin-converting-enzyme inhibitors in the presence or absence of aspirin: a systematic review. *Lancet*. 2002;360(9339):1037-43.
  17. Václavík J, Táborský M. Antiplatelet therapy in the perioperative period. *Eur J Intern Med*. 2011 Feb;22(1):26-31.
  18. Catella-Lawson F, Reilly MP, Kapoor SC, Cucchiara AJ, DeMarco S, Tournier B et al. Cyclooxygenase inhibitors and the antiplatelet effects of aspirin. *N Engl J Med* 2001;345:1809-15.
  19. Matula JM, Lesiak M, Michalak M, Kowal J, Mączyński M, Siniawski A, Mularek-Kubzdela T, Wiśniewski S, Grajek S. Association between high on-treatment platelet reactivity and occurrence of cerebral ischemic events in patients undergoing percutaneous coronary intervention. *Thromb Res*. 2016;138:49-54.
  20. Saw J, Brennan DM, Steinhubl SR, Bhatt DL, Mak KH, Fox K. Lack of evidence of a clopidogrel-statin interaction in the CHARISMA trial. *J Am Coll Cardiol* 2007;50:291-5.
  21. Trenk D, Hochholzer W, Frundi D, Stratz C, Valina CM et al. Impact of cytochrome P450 3A4-metabolized statins on the antiplatelet effect of a 600-mg loading dose clopidogrel and on clinical outcome in patients undergoing elective coronary stent placement. *Thromb Haemost* 2008;99:174-81.
  22. Ho PM, Maddox TM, Wang L, Fihn SD, Jesse RL, Peterson ED et al. Risk of adverse outcomes associated with concomitant use of clopidogrel and proton pump inhibitors following acute coronary syndrome. *JAMA* 2009;301:937-44.
  23. Kim MS, Park ES, Park JB, Lyo IU, Sim HB, Kwon SC. Clopidogrel Response Variability in Unruptured Intracranial Aneurysm Patients Treated with Stent-Assisted Endovascular Coil Embolization : Is Follow-Up Clopidogrel Response Test Necessary? *J Korean Neurosurg Soc*. 2018 Mar;61(2):201-211.