



Ophthalmol Ther
<https://doi.org/10.1007/s40123-020-00233-1>

COMMENTARY

Adult Presentation of X-Linked Retinoschisis: Patient and Physician Perspectives

Yu Jeat Chong · Grahame Price-Hunt · Alastair Denniston

Received: January 7, 2020
© The Author(s) 2020

ABSTRACT

This commentary article is co-authored by an adult patient with X-linked retinoschisis and two ophthalmologists affiliated with the University Hospitals Birmingham NHS Foundation Trust. It describes the patient's experiences of sight loss and the diagnosis and management of X-linked retinoschisis. The treating ophthalmologists then draw upon these experiences and discuss the disease and associated sight loss in a wider context.

Keywords: Adult onset; Patient perspective; X-linked retinoschisis

Key Summary Points

This commentary provides patients and physicians with unique perspectives on X-linked retinoschisis.

The patient's perspective on the process of diagnosing and managing X-linked retinoschisis and on living with this condition from day to day is described.

The physicians' response to the patient's perspective is also provided.

Enhanced Digital Features To view enhanced digital features for this article go to <https://doi.org/10.6084/m9.figshare.11708934>.

Y. J. Chong (✉) · A. Denniston
University Hospitals Birmingham NHS Foundation
Trust, Birmingham, UK
e-mail: yu.chong.2@city.ac.uk

G. Price-Hunt
Birmingham, UK

PATIENT'S EXPERIENCE

Like many people, I knew nothing about blindness; to me, you could either see or you could not. I was reasonably fit and active, and was rarely ill—up until the one morning when everything changed. I got out of bed and just could not focus. At first, I just thought I was still sleepy, but the blurring just did not go. I also had severe headaches and nausea. I went to my local optician who spotted something unusual at the back of my eyes, and referred me to my local specialist ophthalmology unit the same day at a hospital. Although surprised, I was not overly concerned at that time.

I attended the clinic and had several eye scans over the course of 8 h, each time seeming to see someone more senior. I knew something was amiss. I was then told that holes had appeared at the back of my eyes and further investigations were required.

From this point, things moved quickly: I was sent to another eye specialist for more tests and eventually ended up under the care of specialists at a tertiary eye specialist unit. I was worried that my symptoms could be indicative of a brain tumour, especially given the sudden onset of symptoms.

Over the next few months, I underwent a vast number of tests. I had brain scans, full body scans, lumbar punctures. Many thoughts went through my mind, including 'Am I going to die?' and 'What about my wife and children?'. My personality began to change; I started feeling anxious, panicking, and having constant headaches.

Thankfully, when the results came back they confirmed that I did not have a tumour. It was a huge weight lifted from my shoulders. Yes, I was losing my sight, but at least there was no imminent threat to my life. My illness was still unknown, and I underwent a period in hospital for plasma exchange treatment—not a pleasant experience, and not without dangers, but well worth trying. Sadly, my sight continued to deteriorate, although at a much slower rate than the first onset. This has left me severely sight impaired.

The unusual thing about sight loss is that it is an invisible condition. The only time people realize is when you use a white cane. Every aspect of my life has changed.

Two distinct incidents will always stay with me. The first at an occupational health interview with my 'disability' officer. I worked at a university and expected to be treated with considerable understanding, but was met with what I could only describe as hostility. No one made their way to escort me to the third floor of a building, showed me to a seat, shook my hand, or asked if I was okay. The disability officer began to talk to me, and after a short time asked 'How bad are your eyes, as you are looking at me when I talk to you?'. I felt so uncomfortable, and had to explain that I could

follow her voice even though I could not see her. My job at that time relied heavily on eyesight—handling chemicals, bacteria and lab equipment in a congested space. She told me that there were no other jobs available on campus at the time, and I should be a dispatcher at a taxi company as I did not need eyesight to handle the phone. I felt betrayed: she knew nothing of me, my capabilities, my education. Because I was blind, I was stupid and incapable of nothing more than answering a phone. Another incident was when a close relative sarcastically said 'not bad for a blind man to be cleaning windows' when they came around to my house.

You would be amazed by how many people assume that if you are blind, you must be deaf. They shout at you or speak very slowly, and it can be amusing to play along. It is a myth that your hearing improves because of sight loss; it is just that you rely on it more.

I think very often that it is the psychological effect of sight loss that causes more problems. With the physical side you learn to adapt. You do things from memory; it's surprising how you subliminally count the number of steps on a staircase. I also rely on touch hugely—it's amazing how your fingertips transmit so much information. You learn to tell minute differences in thickness, feel the head of a screw, find the buttons on a keypad, etc. Mentally though, I do not think I will ever come completely to terms with sight loss. It took me a long time to feel even remotely comfortable asking for help from anybody; I even hated people offering to help. I find not being able to recognise faces upsetting. I have to rely on voices to be able to work out who they are. It's amazing how much you miss not being able to see the microexpressions on people's face. Now I realise those expressions often tell you more than what someone is saying.

I have some peripheral vision left, though I have total night blindness—I cannot see a thing in low light, or bright light either come to think of it. It's so difficult trying to explain to other people what you can or cannot see, what you can and cannot do. No two people with sight loss that I have met have been affected in the same way. I know that depression affects many

though; I have heard many people say that they wanted to end it all! Thankfully, this is not a sentiment that has ever crossed my mind.

People say that it must be terrible to lose your sight at my age, but with everything there are always two ways of looking at things. I am so thankful that this did not happen to me at an earlier age. I have done so many things and seen so much—I have travelled the world, met the love of my life, witnessed the birth of my two gorgeous children. Those memories will always be there.

PHYSICIANS' RESPONSE

We are grateful to Mr Price-Hunt for sharing his patient journey.

X-linked retinoschisis (XLRS) is one of the most common paediatric retinal dystrophies, with a prevalence ranging from 1 in 5000 to 1 in 20,000 [1]. Due to the genetics of X-linked conditions, this condition predominantly affects male patients; female carriers typically do not present with clinical features [2, 3]. XLRS leads to schisis (splitting) of the neural retina and thus to reduced visual acuity in affected patients. The gene that is affected in this condition is known as RS-1, which encodes for proteins that are responsible for cell-to-cell adhesion and are only found in the retina [4].

Mr Price-Hunt's presentation of XLRS was unusual and diagnostically challenging. He presented to us middle-aged (in his late 40s). This condition can present at different ages, but primarily affects school-age children [5]. The delay between the time a patient is referred to an ophthalmologist and the diagnosis of this condition can be up to 8.3 years [5]. The degree of visual impairment is variable and can range from 20/20 to 20/600 [6].

The clinical features of XLRS are classically described as small cysts around the fovea with a spoke-wheel appearance [7]. Other clinical features include peripheral retinoschisis in the inferotemporal region. Additional peripheral changes include pigmentations that can resemble retinitis pigmentosa, vitreous veils, perivascular sheathing, subretinal fibrosis, and

an inner retinal reflex which shows as a tapetal-like reflex [5].

When Mr Price-Hunt was first referred to us, he had reductions in vision in both eyes, a best corrected visual acuity of 6/36 in the right eye and 6/18 in the left eye, persistent macular oedema, epiretinal membrane, and a loss of outer retinal photoreceptors (Fig. 1). There was no evidence of anterior segment inflammation or changes.

Cystic changes and macula oedema can be caused by various conditions, including vein occlusions, diabetic maculopathy, uveitis, inherited cystoid macular oedema and retinal dystrophies such as retinitis pigmentosa. Foveal schisis in X-linked retinoschisis can lead to macular oedema and can sometimes be difficult to distinguish from other clinical causes. Mr Price-Hunt was also checked extensively for autoimmune retinopathy (AIR), which can sometimes present with diffuse retinal atrophy, macular oedema, and minimal findings on ophthalmic examination [8]. AIR is a type of immune-mediated disease caused by circulating autoantibodies against the retina, which can on occasion be due to the presence of neoplastic disease [9]. This was why he had investigations to rule out neoplastic disease, including full-body computed tomography (CT) scans, positron emission tomography (PET) scans, a magnetic resonance imaging (MRI) brain scan with contrast and a cerebrospinal fluid examination to rule out infection and autoimmune and demyelinating diseases. He was also treated empirically with plasmapheresis, which sometimes improves the symptoms of AIR. In diagnostically uncertain cases, we sometimes perform electrodiagnostic testing. This can lead to nonspecific results, with electroretinogram (ERG) findings sometimes showing electronegative b-waves in X-linked retinoschisis, conditions such as AIR, and a variety of other hereditary and acquired retinal disorders [9, 10]. While we might not be able to alter the course of the disease, sometimes one of the roles we have as clinicians is to reassure the patient that there is no other systemic or life-threatening condition that is causing the visual loss.

In our experience, we find that it is often helpful to offer patients genetic testing to

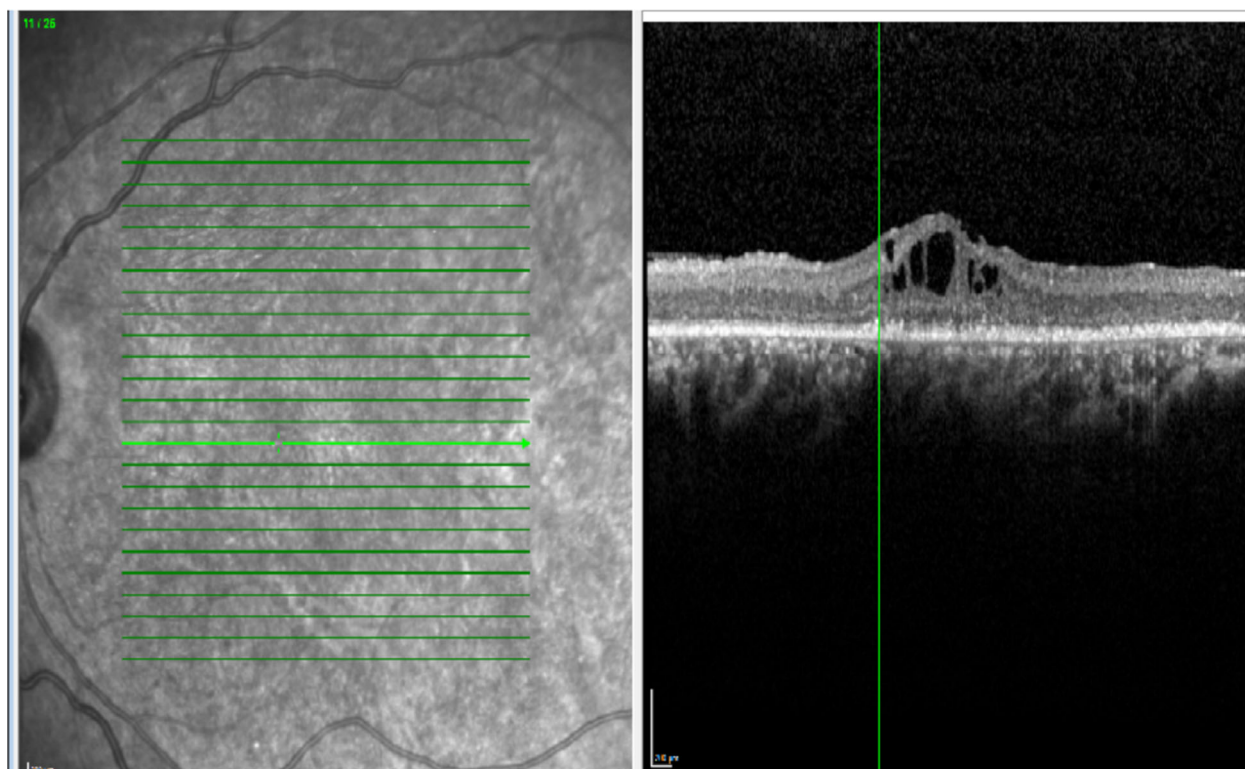


Fig. 1 Optical coherence tomography showing epiretinal membrane, macular oedema, and a loss of outer retinal photoreceptors

determine the underlying genetic cause of the eye disease. While the results of genetic testing at this point would be unlikely to offer any new treatment, it can provide patients with a greater understanding of the underlying disease. From a practical point of view, the results of the test could also lead to the testing of other family members who might want to know if they have a particular inherited condition. We have an excellent genetics department at the West Midlands Regional Clinical Genetics Service in Birmingham, which processes over 170 genes associated with the retina. This led to the diagnosis of X-linked retinoschisis in the present case, as the patient was positive for the corresponding RS-1 gene mutation.

We follow up patients every 6–12 months with an examination and OCT scans to check for signs of vitreous haemorrhage, retinal detachment and cystic changes in the retina. Schisis cavities or cystic changes can sometimes be successfully treated with topical dorzolamide

[11]. However, it is the patient who has to live with the realities of sight impairment, including its associated psychological and physical challenges. In the UK, we are fortunate to have a number of great charities to support patients with sight impairment, such as the Royal National Institute of Blind People (RNIB) and the Macular Society [12, 13]. These charities offer low-vision aids such as equipment to help patients to continue to read and write and to perform everyday tasks such as navigating around the home and kitchen.

Eye care liaison officers (ECLO) function as a unique bridge for patients to access health and social services in the UK. ECLOs usually work in a hospital setting and can help support the patient's emotional and mental well-being after a clinic appointment with an ophthalmologist. They provide advice on welfare benefits, remaining in employment, and access to various organisations and local support groups.

They are also able to guide the patients through the process of being registered as sight impaired.

As Mr Price-Hunt rightly pointed out, no two patients with sight loss are affected in the same way. In X-linked retinoschisis for example, there are extreme differences in severity within families, even amongst affected brothers [14].

This article is based on previously conducted studies and does not contain any studies with human participants or animals performed by any of the authors.

ACKNOWLEDGEMENTS

Funding. No funding or sponsorship was received for this study or the publication of this article.

Authorship. All named authors meet the International Committee of Medical Journal Editors (ICMJE) criteria for authorship for this article, take responsibility for the integrity of the work as a whole, and have given their approval for this version to be published.

Disclosures. Yu Jeat Chong, Grahame Price-Hunt and Alastair Denniston have no interests to disclose.

Compliance with Ethics Guidelines. This article is based on previously conducted studies and does not contain any studies with human participants or animals performed by any of the authors.

Open Access. This article is distributed under the terms of the Creative Commons Attribution-NonCommercial 4.0 International License (<http://creativecommons.org/licenses/by-nc/4.0/>), which permits any noncommercial use, distribution, and reproduction in any medium, provided you give appropriate credit to the original author(s) and the source, provide a link to the Creative Commons license, and indicate if changes were made.

REFERENCES

- George ND, Yates JR, Bradshaw K, Moore AT. Infantile presentation of X linked retinoschisis. *Br J Ophthalmol.* 1995;79(7):653–7.
- Sieving PA, Bingham EL, Roth MS, Young MR, Boehnke M, Kuo CY, Ginsburg D. Linkage relationship of X-linked juvenile retinoschisis with Xp22.1-p22.3 probes. *Am J Hum Genet.* 1990;47(4):616.
- Wu G, Cotlier E, Brodie S. A carrier state of X-linked juvenile retinoschisis. *Ophthalmic Paediatr Genet.* 1985;5(1–2):13–7.
- Sauer CG, Gehrig A, Warneke-Wittstock R, Marquardt A, Ewing CC, Gibson A, Lorenz B, Jurklics B, Weber BH. Positional cloning of the gene associated with X-linked juvenile retinoschisis. *Nat Genet.* 1997;17(2):164.
- George ND, Yates JR, Moore AT. Clinical features in affected males with X-linked retinoschisis. *Arch Ophthalmol.* 1996;114(3):274–80.
- Forsius H. Visual acuity in 183 cases of X-chromosomal retinoschisis. *Can J Ophthalmol.* 1973;8:385–93.
- Rao P, Dedania VS, Drenser KA. Congenital X-linked retinoschisis: an updated clinical review. *Asia Pac J Ophthalmol.* 2018;7(3):169–75.
- Grange L, Dalal M, Nussenblatt RB, Sen HN. Autoimmune retinopathy. *Am J Ophthalmol.* 2014;157(2):266–72.
- Canamary AM, Takahashi WY, Sallum JM. Autoimmune retinopathy: a review. *Int J Retina Vitreous.* 2018;4(1):1.
- Sikkink SK, Biswas S, Parry NR, Stanga PE, Trump D. X-linked retinoschisis: an update. *J Med Genet.* 2007;44(4):225–32.
- Apushkin MA, Fishman GA. Use of dorzolamide for patients with X-linked retinoschisis. *Retina.* 2006;26(7):741–5.
- Royal National Institute of Blind People. Homepage [Internet]. London: RNIB; 2020. www.rnib.org.uk. Accessed 8 Feb 2020.
- Macular Society. Homepage [Internet]. Andover: Macular Society; 2020. www.macularsociety.org. Accessed 8 Feb 2020.
- Pimenides D, George ND, Yates JR, Bradshaw K, Roberts SA, Moore AT, Trump D. X-linked retinoschisis: clinical phenotype and RS1 genotype in 86 UK patients. *J Med Genet.* 2005;42(6):e35.