

Malignant Mixed Mullerian Tumor of the Uterus Associated with Tamoxifen Therapy in a Patient with a History of Breast Cancer

ZAHRA EFTEKHAR, FARIBA YARANDI, NARGES IZADI-MOOD, PARVANEH RAHIMI-MOGHADDAM

For author affiliations, see end of text.

Received June 16, 2005; Revised May 29, 2006; Accepted June 3, 2006

This paper is available online at <http://ijpt.iums.ac.ir>

ABSTRACT

Tamoxifen is the drug of choice in the treatment of breast cancer. Recent reports show an increased incidence of endometrial carcinoma in patients taking tamoxifen. In this article, we report a case of malignant mixed mullerian tumor after tamoxifen use.

Keywords: *Tamoxifen, Breast cancer, Endometrial cancer, Case report*

Tamoxifen therapy is known to increase the risk of endometrial carcinoma. Most of these malignancies are endometrial adenocarcinoma, but occurrence of endometrial sarcoma has been reported as well [1-6]. Here, we report a woman who developed a malignant mixed mullerian tumor after use of tamoxifen for 5 years.

CASE REPORT

A 72-year-old woman, gravida 6, para 6, live child 4, was admitted to our gynecologic clinic because of post-menopausal vaginal bleeding for two months. Her medical history showed a standard radical left mastectomy after the diagnosis of left breast cancer at age 60. She received an oral dose of 200mg tamoxifen daily for 5 years. In physical exam, she had a big uterus approximately in size of uterus of a 16-weeks pregnant woman. Abdominal ultrasound image showed a big uterine mass (3 × 2.9 × 1.8 cm) in endometrial area in association with liquid accumulation in adnexae. CT scan showed no bone involvement. An endometrial biopsy was obtained which showed a mixture of carcinomatous and sarcomatous elements. In sarcomatous component, pleomorphic cells with atypical mitoses and bizarre tumoral giant cells were observed (Fig 1). In the carcinomatous part, malignant epithelial cells were arranged in tubular structures or cords (Fig 2). The preliminary pathological diagnosis was malignant mixed mullerian tumor. We performed laparotomy with a pre-operative diagnosis of malignant uterine mass. A total abdominal hysterectomy and bilateral salpingo-ophorectomy and pelvic lymph node sampling were performed. In gross

examination, there was a polypoid tumoral mass measuring 5 x 4 cm in diameter which occupied endometrial cavity. The tumor invaded full thickness of the myometrium. In microscopic examination, tumor consisted of tumoral epithelial cells with foci of pleomorphic atypical spindle cells. Omentum and liver were involved as well. The diagnosis of malignant mixed mullerian tumor was made.

DISCUSSION

Tamoxifen, a partial agonist of estrogen, has been widely used in the treatment of breast cancer. In the recent years, the occurrence of uterine malignancy in patients receiving tamoxifen has been identified. These malignancies have been reported as adenocarcinoma as well as uterine sarcoma. In women not taking tamoxifen, fewer cases of uterine malignancies have been observed when compared with those taking the drug.

Tamoxifen is a complex drug with both agonist and antagonist effects on estrogen receptors. This mixture of agonist and antagonist properties may explain both efficacy and toxicity of tamoxifen. Toxic effects of tamoxifen are observable throughout the entire urogenital tract including vaginal epithelium, cervix, uterine corpus, endometrium and ovaries. Tamoxifen has a proliferative effect on endometrial stromal cells and this effect is intensified by higher doses of drug as well as a longer time of its use [7-8].

Overall, benefits of tamoxifen in the treatment and prevention of breast cancer is much higher than its risk for uterine malignancies. It should be kept in mind that

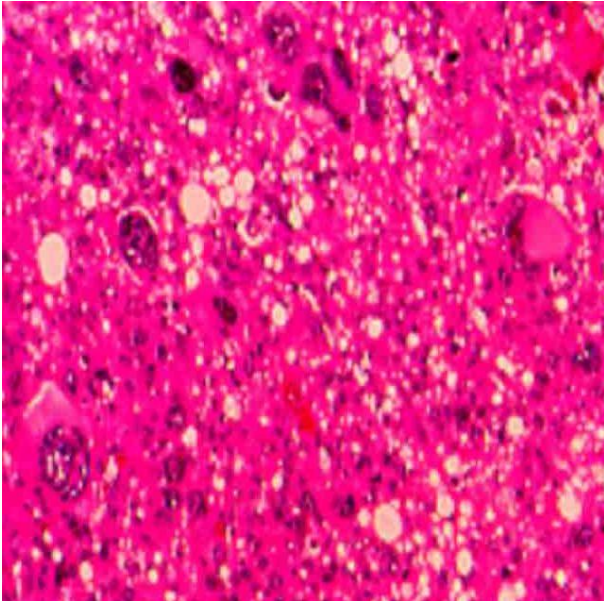


Fig 1. Sarcomatous component of malignant mixed müllerian tumor.

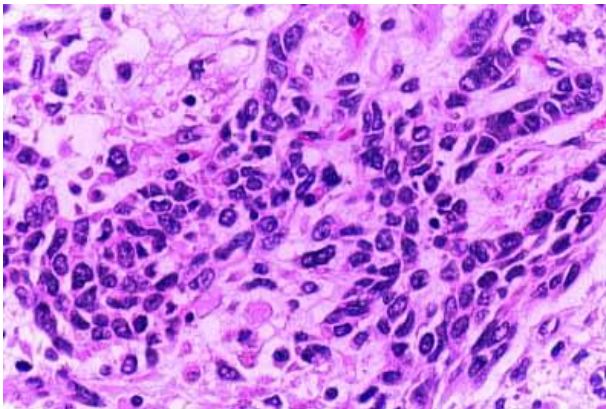


Fig 2. Carcinomatous element of malignant mixed müllerian tumor.

high-risk patient for endometrial cancer should be identified before tamoxifen therapy. Also, in patients receiving tamoxifen, regular uterine sonography in conjunction with endometrial biopsies would be appropriate for early diagnosis of endometrial malignancies.

REFERENCES

1. Bocklage T, Lee KR, Belinson JL. Uterine müllerian adenosarcoma following adenomyoma in a woman on tamoxifen therapy. *Gynecol Oncol.* 1992;44:104-9.
2. Clarke MR. Uterine malignant mixed müllerian tumor in a patient on long-term tamoxifen therapy for breast cancer. *Gynecol Oncol.* 1993;51:411-5.
3. Carvalho FM, Carvalho JP, Motta EV, Souen J. Müllerian adenosarcoma of the uterus with sarcomatous overgrowth following tamoxifen treatment for breast cancer. *Rev Hosp Clin Fac Med Sao Paulo.* 2000;55:17-20.
4. Arici DS, Aker H, Yildiz E, Tasyurt A. Müllerian adenosarcoma of the uterus associated with tamoxifen therapy. *Arch Gynecol Obstet.* 2000;264:105-7.
5. Maluf FC, Sabbatini P, Schwartz L, Xia J, Aghajanian C. Endometrial stromal sarcoma: objective response to letrozole. *Gynecol Oncol.* 2001;82:384-8.
6. Saga Y, Ohwada M, Kohno T, Takayashiki N, Suzuki M. High-grade endometrial stromal sarcoma after treatment with tamoxifen in a patient treated for breast cancer. *Int J Gynecol Cancer.* 2003;13:690-2.
7. Dallenbach-Hellweg G, Schmidt D, Hellberg P, Bourne T, Kreuzwieser E, Doren M, Rydh W, Rudenstam G, Granberg S. The endometrium in breast cancer patients on tamoxifen. *Arch Gynecol Obstet.* 2000;263:170-7.
8. Deligdisch L, Kalir T, Cohen CJ, de Latour M, Le Bouedec G, Penault-Llorca F. Endometrial histopathology in 700 patients treated with tamoxifen for breast cancer. *Gynecol Oncol.* 2000;78:181-6.

CURRENT AUTHOR ADDRESSES

Zahra Eftekhar, Department of Gynecologic Oncology, Mirza-Koochak-Khan Hospital, Tehran University of Medical Sciences, Nejatollahi St. Karim Khan Zand Ave. Tehran, Iran. Phone: +98 (21) 6693 9320, Fax: +98 (21) 6693 7321 E-mail: par127@mail.usask.ca (Corresponding Author).

Fariba Yarandi, Department of Gynecologic Oncology, Iran University of Medical Sciences, Mirza-Koochak-Khan Hospital, Tehran University of Medical Sciences.

Narges Izadi-Mood, Department of Pathology, Mirza-Koochak-Khan Hospital, Tehran University of Medical Sciences.

Parvaneh Rahimi-Moghaddam, Razi Institute for Drug Research, Iran University of Medical Sciences, Tehran, Iran.