

## RESEARCH ARTICLE

## Zinc Supplementation Effect on the Bronchial Cilia Length, the Number of Cilia, and the Number of Intact Bronchial Cell in Zinc Deficiency Rats

Andy Darma, Alpha Fardah Athiyyah\*, Reza Gunadi Ranuh, Wiweka Merbawani, Retno Asih Setyoningrum, Boerhan Hidajat, Siti Nurul Hidayati, Anang Endaryanto, Subijanto Marto Sudarmo

Department of Child Health, Dr. Soetomo Hospital, Faculty of Medicine, Universitas Airlangga, Jl. Prof Dr. Moestopo No 6-8, Surabaya, Indonesia

\*Corresponding author. E-mail: alpha-f-a@fk.unair.ac.id

Received date: Oct 10, 2019; Revised date: Jan 21, 2020; Accepted date: Jan 23, 2020

### Abstract

**BACKGROUND:** Airway epithelium is the first line of defense against a variety of exposures. Inflammatory processes, hyperresponsiveness and zinc deficiency cause epithelial damage. Zinc is involved in apoptosis and microtubule formation. However, its role in the integrity of bronchial mucosa and cilia is unclear.

**METHODS:** To assess the effect of zinc on the integrity of the bronchial epithelium, 24 male *Rattus norvegicus* strain Wistar rats were randomized into four experimental groups: normal zinc diet group without zinc supplementation, normal zinc diet group with 60 ppm zinc supplementation, zinc deficient diet group without zinc supplementation, and zinc deficient diet group with 120 ppm zinc supplementation. Bronchial mucosal integrity was measured with the number of epithelial cells, and the number and length of cilia.

**RESULTS:** Number of cell in normal zinc diet group was  $8.8 \pm 1.82$ , while it was only  $8.1 \pm 1.08$  in zinc deficient diet group ( $p < 0.001$ ). Number of cilia per cell was  $4.6 \pm 1.08$  in normal zinc diet group, compared to  $4.0 \pm 0.79$  in zinc deficient diet group ( $p < 0.001$ ). Ciliary length also differ by  $7.68 \pm 0.66 \mu\text{m}$  in normal zinc diet group and only  $5.16 \pm 0.91 \mu\text{m}$  in zinc deficient diet group ( $p < 0.001$ ).

**CONCLUSION:** Zinc supplementation of the normal zinc diet group affected the length of bronchial cilia. Zinc supplementation of the zinc deficient diet group affected the integrity of the bronchial epithelium, which was shown by the number and length of cilia, and the number of epithelial cells.

**KEYWORDS:** zinc, bronchial epithelial integrity, cilia length, number of cilia, epithelial cell

*Indones Biomed J. 2020; 12(1): 78-84*

### Introduction

Integrity of airway mucosal epithelium is the first line of a complex defense that is always exposed to endogenous and exogenous material.(1) Inflammatory processes, hyperresponsiveness, antioxidants and zinc deficiency may affect the disruption of bronchial epithelium.(2) Zinc is a vital factor in the lung epithelium, protecting against barrier dysfunction. Zinc deprivation would induce caspase-3, enhancing apoptosis, leading to the degradation of junction proteins, loss of cell-to-cell contact, and increased

permeability of the epithelium.(3) Numerous studies suggest that zinc as a micronutrient decreases morbidity and mortality from respiratory infection.(4,5)

Respiratory tract infections are the most common diseases in primary health care and hospitals. In 2019, the United Nations Children's Fund (UNICEF) reported that 36% of deaths in children under five years old were caused by respiratory tract infections.(6) The use of the preventive nebulized product containing echinacea, vitamins A and C, iron and folic acid, is still controversial.(5,7,8) Zinc deficiency in children represents a risk factor for acute respiratory tract infections.(9)

Airway mucosal permeability and mucociliary clearance are the primary defense mechanisms of the respiratory tract. Zinc is thought to play a role in the formation of microtubule constituents of cells and cilia, calcium flux related to the performance of cilia, and inhibition of caspase 3 activation and oxidation, which also involved in apoptosis and the regeneration of cells and cilia.(10) Based on an unclear mechanism of zinc action in the prevention of epithelial damage and airway cilia, particularly in bronchi, as well as the impracticality of direct examination of these areas in human subjects, this study examined rats under normal conditions and with zinc deficiency.

## Methods

### Ethical Issues

Experimental units were ethically approved (No. 055-KE/date 20th March 2009) by the Animal Care and Use Committee, Faculty of Veterinary Medicine, Universitas Airlangga Surabaya, East Java, Indonesia.

### Preliminary Study

We conducted a preliminary study to determine zinc deficiency in rats. A total of 11 white male *Rattus norvegicus* strain Wistar rats, aged 5 weeks, of body weight 60–100 grams were adapted for 1 week. Two rats were sacrificed without treatment in order to measure pre-treatment zinc level. The other 10 rats were classified into 3 treatment groups: 2 rats under controlled group received diet without any zinc content; 4 rats under zinc deficient diet group received diet with 0.5 ppm/day zinc content based on previous study with modified half dose and shorter duration (11), and 4 rats under normal zinc diet group received diet with 30 ppm/day zinc content based on prior study (12). After 2 weeks, 2 rats in controlled group, 1 rat in zinc deficient diet group, and 1 rat in normal zinc diet group were sacrificed. Serum and tibia zinc level were measured.

Other 5 rats (3 rats in zinc deficient diet group and 2 rats in normal zinc diet group) further grouped to measure effect of zinc supplementation. Three rats from zinc deficient diet group was given: 60, 90, and 120 ppm/day zinc supplementation, while 2 rats from normal zinc diet group was given: 45 and 60 ppm/day zinc supplementation.

### Animals and Zinc Administration

Based on our preliminary study, 24 white male *Rattus norvegicus* strain Wistar rats, aged 5 weeks, of body weight 60–100 grams were divided into 4 groups: normal zinc diet

group without zinc supplementation, normal zinc diet group with 60 ppm zinc supplementation, zinc deficient diet group without zinc supplementation, and zinc deficient diet group with 120 ppm zinc supplementation.

### Bronchial Tissue Collection

On day 42, necropsy was performed. The bronchial tissue was cleaned and fixed in 10% buffered formalin solution, followed by dehydration, clearing, impregnation and embedding.(13) Fixation took place at the Pathology Anatomy Laboratory, using the paraffin method, while sections were stained with haematoxylin and eosin at the Biomedical Laboratory, Faculty of Medicine, Universitas Brawijaya, Malang. Sections were viewed and counted by a pathologist using a Nikon E100 microscope (Nikon Instruments Inc., Tokyo, Japan) at a magnification of 1000x.

### Statistical Analysis

Descriptive analysis was performed for each group based on observations of ciliary length, the number of cilia per epithelial cell and the number of intact epithelial cells. Data was compiled and analyzed using IBM SPSS Version 22 (IBM Corporation, New York, USA). Multivariate analysis of variance (MANOVA) was used to analyze the effect of zinc administration on cilia length, number of cilia per epithelial cell and number of intact epithelial cells per group. Student's t-test was used to analyze the differences between each variable for the normal group and zinc deficiency. Data were analyzed with a 95% confidence level ( $\alpha = 0.05$ ).

## Results

### Preliminary Study Results

Results of the preliminary study were shown in Table 1. The result showed that giving zinc supplementation for 2 weeks was enough to increase serum zinc level to normal. Therefore, considering this, we conducted an experiment with 3 weeks to yield more favorable results.

### Study Results

During the study, 3 rats died due to aspiration. Multivariate analysis (Table 2) using Hotelling's T-square indicated a difference ( $p < 0.001$ ) between normal zinc diet group and zinc deficient diet group.

There were significant differences between the structure of the bronchial mucosal epithelium of the normal zinc diet group and zinc deficient diet group (Figure 1A). In normal zinc diet group, typical bronchial mucosal epithelial

**Table 1. Preliminary study results.**

Groups	Zinc Levels (ppm)	
	Serum Zinc Level	Tibia Zinc Level
<b>Pre-treatment group</b>		
Rats 1	0.097	1.307
Rats 2	0.088	1.224
<b>Controlled group</b>		
Rats 3	0.049	0.522
Rats 4	0.042	0.502
<b>Zinc deficient diet group without zinc supplementation</b>		
Rats 5	0.031	0.474
<b>Normal zinc diet group without zinc supplementation</b>		
Rats 6	0.022	0.449
<b>Zinc deficient diet group with zinc supplementation</b>		
Rats 7 – 60 ppm/day zinc supplementation	0.088	0.943
Rats 8 – 90 ppm/day zinc supplementation	0.104	1.024
Rats 9 – 120 ppm/day zinc supplementation	0.117	1.138
<b>Normal zinc diet group with zinc supplementation</b>		
Rats 10 – 45 ppm/day zinc supplementation	0.102	1.229
Rats 11 – 60 ppm/day zinc supplementation	0.184	1.147

cells were observed, with associated erect and neatly organized cilia. In contrast, the zinc deficient diet group had many damaged epithelial cells, which exhibited ballooning. This could be caused by damaged to the tight junctions and matrix constituent cells. Only a few intact cilia were observed, with many shortened cilia.

The effect of zinc supplementation in normal zinc diet group, as assessed by multivariate analysis using Hotelling's T-square, showed that the number of cells and length of cilia were significantly different ( $p < 0.001$ ). The mean number of cells increased in the normal zinc diet group with zinc supplementation, as well as the average number and length of cilia.

Statistical analysis by t-test showed no significant difference in the number of epithelial cells ( $p = 0.344$ ) and

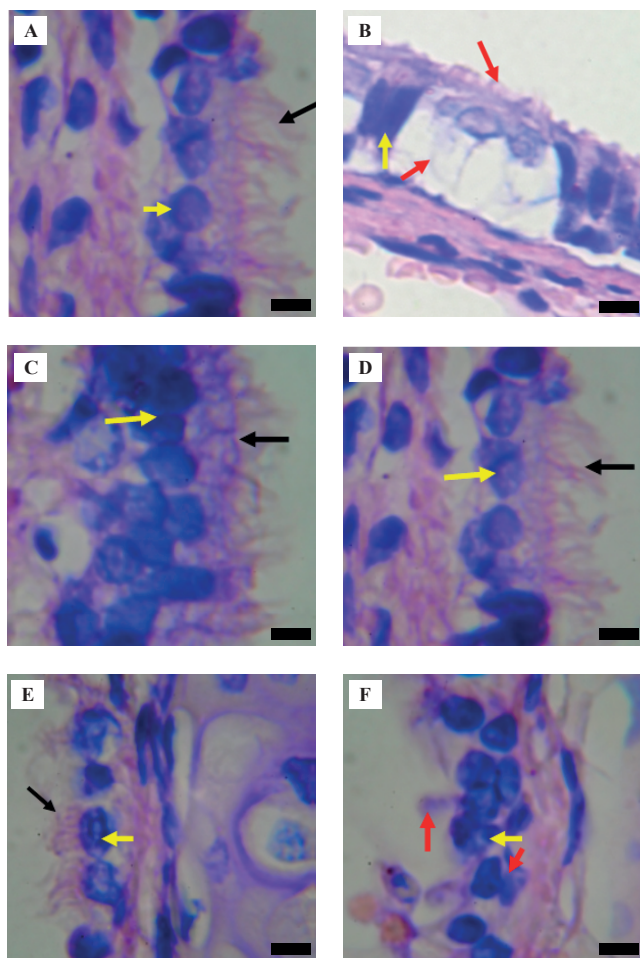
the number of cilia ( $p = 0.518$ ) between the normal zinc diet group and those on normal zinc diet group with zinc supplementation (Table 3). Length of cilia increased from  $5.76 \pm 1.00 \mu\text{m}$  to  $7.68 \pm 0.66 \mu\text{m}$  in normal zinc diet group ( $p = 0.007$ ). The mean number of intact epithelial cells was increased in the normal zinc diet group with zinc supplementation, compared to the normal zinc diet group without supplementation. However, the difference was not statistically significant. Cilia were neatly arranged in both groups on the epithelial cells (Figure 1B).

The effect of zinc supplementation in zinc deficient diet group on epithelial cell number, and number and length of cilia, showed significant differences ( $p < 0.001$ ) when assessed by multivariate analysis using Hotelling's T-square. Student's t-test was also used to assess the effect of zinc

**Table 2. Analysis of intact epithelial cells and cilia before zinc supplementation.**

Variable	Zinc Diet Group		<i>p</i> -value*	<i>p</i> -value**
	Normal Zinc Diet (Mean±SD)	Zinc Deficient Diet (Mean±SD)		
Cell number	7.90±0.82	3.08±0.66	0.000	
Cilia per cell	4.20±0.76	2.08±0.86	0.002	0.000
Length of cilia (μm)	5.76±1.00	2.40±0.76	0.000	

\*Significant difference,  $p < 0.05$ , tested with independent sample t-test. \*\*Significant difference,  $p < 0.05$ , tested with Hotelling's T-square.



**Figure 1. Structure of the bronchial mucosal epithelium and cilia.** A: normal zinc diet group; B: zinc deficient diet group; C: normal zinc diet group with zinc supplementation; D: normal zinc diet group without zinc supplementation; E: zinc deficient diet group with supplementation; F: zinc deficient diet group without zinc supplementation. Black arrows indicate intact cilia, yellow arrows indicate intact epithelial cells, and red arrows indicate damaged epithelial cells and shortening of cilia. Black bar: 10  $\mu$ m.

on epithelial cell number, and number and length of cilia in the zinc deficient diet group (Table 4). On zinc treatment, there were significant differences in the number of cells ( $p < 0.001$ ), number of cilia per epithelium cell ( $p = 0.004$ ), and the length of cilia ( $p < 0.001$ ).

Bronchial mucosal epithelium of experimental animals in zinc deficient diet group (Figure 1C) showed irregular cell stacks with or without cilia, and cilia bulging. Groups of experimental animals under zinc deficient diet group with supplementation showed irregular arrangements of cells. However, cilia were upright on these irregular cells. MANOVA analysis was conducted to determine the main effects and interaction between the independent variables with regard to bronchial mucosal epithelial integrity in test

animal. The main effect in this current study was the effect of zinc status regardless of zinc supplementation, and zinc supplementation regardless of zinc status for experimental animals, with regard to the integrity of the mucosal epithelium of bronchi.

Individual zinc status significantly affected the number of cells, number of cilia per cell and the length of cilia (Table 5). Individual zinc supplementation also significantly affected the number of cells, number of cilia per cell and the length of cilia. In addition, individual zinc status interacted with zinc supplementation, but only significantly affecting the number of epithelial cells. Zinc supplementation was useful in conditions of zinc deficiency, though the only significant benefit was increasing the number of epithelial cells. Zinc deficiency increased the influence of zinc supplementation in terms of repairs amount epithelial cells.

## Discussion

Zinc is necessary for the defense functions of airway mucosal epithelium, and lack of zinc can cause damage to the epithelium.(14) Zinc has antioxidant effects that prevent the oxidation of sulfhydryl and hydroxyl groups, reducing the formation of  $H_2O_2$  and  $O_2$  radicals. Conditions of zinc deficiency would destabilize the cell skeleton, including the cilia, and cause changes in cell shape or organelles.(15) In the current study, subjects in normal zinc diet group showed ordered cell arrangements and cell shapes compared to the zinc deficient diet group. Such presentations formed cilia more regularly and did not have bulging or damaged cilia. However, the number of cells and cilia showed no increase.

Zinc is needed with actin and intra-flagellar transport (IFT) to determine the length of cilia. LIM zinc fingers, composed of double-cysteine-rich domains, bind to actin and also determine the length of the cilia.(16) Zinc treatment under normal conditions, with doses twice daily, does not significantly increase the number of cells. It is conceivable that zinc protects epithelial cell turnover by maintaining a reserve without inducing excessive growth and zinc did not cause apoptosis at these doses. These results indicate that administration of zinc at twice the recommended dose per day is safe under normal conditions. Acute ingestion of 1-2 grams zinc may cause nausea, abdominal pain, vomiting, diarrhea, lethargy, and dizziness due to irritation and corrosion of gastrointestinal tract.(17,18) When high dose of zinc is taken for a long time, zinc may induce copper deficiency and inhibit T-cell function.(18) Zinc excess can

**Table 3. Epithelial cell number, and number and length of cilia in rats on a normal zinc diet group.**

Variable	Normal Zinc Diet Group		<i>p</i> -value*	<i>p</i> -value**
	Zinc (+) (Mean±SD)	Zinc (-) (Mean±SD)		
Cell number	8.80±1.82	7.90±0.82	0.344	
Cilia per cell	4.60±1.08	4.20±0.76	0.518	0.000
Length of cilia (µm)	7.68±0.66	5.76±1.00	0.007	

Zinc (+) group received zinc supplementation, while zinc (-) group did not. \*Significant difference,  $p < 0.05$ , tested with independent sample t-test. \*\*Significant difference,  $p < 0.05$ , tested with Hotelling's T-square.

lead to cell apoptosis, though this effect is different from cell to cell.(19-21)

The images of damaged cells and cilia in nearly all epithelia showed the importance of zinc in maintaining the integrity of cells and bronchial cilia. Zinc deficiency can cause apoptosis directly, with the zinc bond with sulfhydryl easily oxidized, or indirectly. The second mechanism begins with the release of reactive oxygen species (ROS) from mitochondria, triggering caspase 3 activation and causing apoptosis.(22) Apoptosis is a mechanism of cell death, which is also part of the natural process of epithelial cell turnover, including airway epithelium. Epithelial cells that undergo apoptosis, experience phagocytosis, fragmentation and passage into the bronchial lumen, aided by mucociliary clearance (MC), where they are then swallowed or expectorated.(23)

Bronchi and alveoli cells given zinc chelators show decreased zinc levels, followed by increased levels of caspase 3, DNA fragmentation, and changes in cell shape. Increase in caspase 3 occurred 1–2 hours after the addition of the zinc binding agent. Increase in caspase 6 also triggers caspase 3, though more slowly.(24) These findings were supported by examining the expression of p53 and caspase activity in normal human bronchial epithelial (NHBE) cells

under zinc deficiency. Results of this study suggested a three-fold increase in p53 mRNA abundance in zinc deficient cells compared to normal cells, with the main function of p53 being the induction of apoptosis.(25)

Tracheal epithelium of mice exposed to filtered air and ozone for three days showed bulk damage and loss of cilia. However, by forty-two- and sixty-days cilia recovered, except for uniform shortening.(25) Although ciliary epithelial cell growth is thought to occur in less than 35 days, the above research found cilia growth takes a long time to return to normal. Our results showed that the growth of cilia was longer, and the number of cells and cilia increased significantly in the normal zinc diet group, compared to the zinc deficient diet group. This indicated that the administration of zinc could speed the improvement of bronchial mucosal epithelium.

Other studies also support that the administration of zinc could speed up the improvement of bronchial mucosal epithelium which observations on conditioned zinc deficiency in human lung fibroblasts. Zinc deficient lung cells showed more than twice the increase in gene expression with DNA damage to cells, compared to the normal zinc group. Human lung alveolar epithelial cells (HLUAec) given a zinc chelator TPEN showed that cell shape with

**Table 4. Epithelial cell number, and number and length of cilia in rats on a zinc deficient diet group.**

Variable	Zinc Deficient Diet Group		<i>p</i> -value*	<i>p</i> -value**
	Zinc (+) (Mean±SD)	Zinc (-) (Mean±SD)		
Cell number	8.10±1.08	3.08±0.66	0.000	
Cilia per cell	4.00±0.79	2.08±0.86	0.004	0.000
Length of cilia (µm)	5.16±0.91	2.40±0.76	0.000	

Zinc (+) group received zinc supplementation, while zinc (-) group did not. \*Significant difference,  $p < 0.05$ , tested with independent sample t-test. \*\*Significant difference,  $p < 0.05$ , tested with Hotelling's T-square.

**Table 5. Interaction of zinc status and zinc supplementation for cells numbers, and number and length of cilia in the normal zinc diet group and the deficient zinc diet group.**

Main Effect and Interaction Effect	Integrity of Epithelial Mucosal Bronchus	Mean Square	p-value *	p-value **
Effects of zinc diet (normal/deficiency) for epithelial integrity	Cell number	29.458		
	Cilia per cell	12.390	0.003	
	Length of cilia	64.144	0.000	
Effects of zinc supplementation (normal/deficiency) for epithelial integrity	Cell number	33.885	0.000	0.000
	Cilia per cell	9.010	0.008	
	Length of cilia	40.634	0.000	
Interaction effects of zinc diet (normal/deficiency) with zinc supplementation (yes/no) for epithelial integrity (Status_Zn * Supp_Zn)	Cell number	16.404	0.001	0.011
	Cilia per cell	3.862	0.066	
	Length of cilia	1.309	0.268	

\*Significant difference,  $p < 0.05$ , tested by univariate analysis. \*\*Significant difference,  $p < 0.05$ , with Wilk's lambda.

zinc deficiency induces caspase 3, leading to apoptosis and degradation of junction proteins. Zinc treatment inhibits caspase 3, preventing apoptosis and providing protection against disruption of epithelial defenses.(3) Zinc treatment is important in the regeneration of cells and bronchial cilia after apoptosis.(23) This study was conducted by providing  $ZnSO_4$  to bronchi and alveoli cells undergoing apoptosis. Caspase inactivation in zinc-deficient cells occurred at any time, and was prevented by  $ZnSO_4$ .(23) Caspase 3 activity and apoptosis in the NHBE group, which received zinc supplementation (8-fold of normal zinc doses) was significantly different from the normal zinc group, or those that were zinc deficient.(24)

Zinc supplementation affected bronchial mucosal epithelial integrity, both under normal and zinc deficient conditions. There was an interaction between the individual zinc status and zinc supplementation in terms of the number of bronchial mucosal epithelial cells. Zinc treatment over three weeks showed faster cilia growth than other studies that reported complete cell regeneration after damage, within 35 days post-exposure. Two aspects of the addition of long cilia need to be further investigated, whether they end with enhanced functionality, durability and MC, or result in proliferation and cancer.

## Conclusion

Zinc supplementation affected bronchial cilia length in rats under conditions of zinc deficiency. It affected the integrity of the bronchial epithelium, as reflected by the length of cilia, the number of cilia per epithelial cell, and the number of intact bronchial epithelial cells in experimental animals with zinc deficiency.

## References

- Papadaki HA, Velegraki M. The immunology of the respiratory system. *Pneumon.* 2007; 20: 384-94.
- Finamore A, Massimi M, Conti Devirgiliis L, Mengheri E. Zinc deficiency induces membrane barrier damage and increases neutrophil transmigration in Caco-2 cells. *J Nutr.* 2008; 138: 1664-70.
- Bao S, Knoell DL. Zinc modulates cytokine-induced lung epithelial cell barrier permeability. *Am J Physiol Lung Cell Mol Physiol.* 2006; 291: L1132-41.
- Aggarwal R, Sentz J, Miller MA. Role of zinc administration in prevention of childhood diarrhea and respiratory illnesses: a meta-analysis. *Pediatrics.* 2007; 119: 1120-30.
- Roth DE, Caulfield LE, Ezzati M, Black RE. Acute lower respiratory infections in childhood: opportunities for reducing the global burden through nutritional interventions. *Bull World Health Organ.* 2008; 86: 356-64.
- United Nations Children's Fund (UNICEF) [Internet]. Jakarta: UNICEF Indonesia. Kesehatan [updated 2019 May 7; cited 2019 Dec 2]. Available from: <https://www.unicef.org/indonesia/id/kesehatan>
- Cohen HA, Varsano I, Kahan E, Sarrell EM, Uziel Y. Effectiveness of an herbal preparation containing echinacea, propolis, and vitamin C in preventing respiratory tract infections in children: a randomized, double-blind, placebo-controlled, multicenter study. *Arch Pediatr Adolesc Med.* 2004; 158: 217-21.
- Stanton N, Francis NA, Butler CC. Reducing uncertainty in managing respiratory tract infections in primary care. *Br J Gen Pract.* 2010; 60: e466-75.
- Bhutta ZA, Black RE, Brown KH, Gardner JM, Gore S, Hidayat A, *et al.* Prevention of diarrhea and pneumonia by zinc supplementation in children in developing countries: pooled analysis of randomized controlled trials. Zinc Investigators' Collaborative Group. *J Pediatr.* 1999; 135: 689-97.
- Carter JE, Truong-Tran AQ, Grosser D, Ho L, Ruffin RE, Zalewski PD. Involvement of redox events in caspase activation in zinc-depleted airway epithelial cells. *Biochem Biophys Res Commun.* 2002; 297: 1062-70.
- Williams RB, Mills CF. The experimental production of zinc deficiency in the rat. *Br J Nutr.* 1970; 24: 989-1003.

12. Yu Q, Sun X, Zhao J, Zhao L, Chen Y, Fan L, *et al.* The effects of zinc deficiency on homeostasis of twelve minerals and trace elements in the serum, feces, urine and liver of rats. *Nutr Metab.* 2019; 16: 73. doi: 10.1186/s12986-019-0395-y.
13. Canene-Adams K. Chapter fifteen: Preparation of formalin-fixed paraffin-embedded tissue for immunohistochemistry. In: Lorsch J, editor. *Methods in Enzymology*, Vol.533. 1st ed. Amsterdam: Elsevier; 2013. p. 225-33.
14. Roof DJ, Hayes A, Adamian M, Chishti AH, Li T. Molecular characterization of abLIM, a novel actin-binding and double zinc finger protein. *J Cell Biol.* 1997; 138: 575-88.
15. Murgia C, Grosser D, Truong-Tran AQ, Roscioli E, Michalczyk A, Ackland ML, *et al.* Apical localization of zinc transporter ZnT4 in human airway epithelial cells and its loss in a murine model of allergic airway inflammation. *Nutrients.* 2011; 3: 910-28.
16. Chai F, Truong-Tran AQ, Evdokiou A, Young GP, Zalewski PD. Intracellular zinc depletion induces caspase activation and p21 Waf1/Cip1 cleavage in human epithelial cell lines. *J Infect Dis.* 2000; 182 (Suppl): S85-92.
17. Barceloux DG, Barceloux D. Zinc. *J Toxicol Clin Toxicol.* 1999; 37: 279-92.
18. Plum LM, Rink L, Haase H. The essential toxin: impact of zinc on human health. *Int J Environ Res Public Health.* 2010; 7: 1342-65.
19. Franklin RB, Costello LC. The important role of the apoptotic effects of zinc in the development of cancers. *J Cell Biochem.* 2009; 106: 750-7.
20. Kocdor H, Ates H, Aydin S, Cehreli R, Soyarat F, Kemanli P, *et al.* Zinc supplementation induces apoptosis and enhances antitumor efficacy of docetaxel in non-small-cell lung cancer. *Drug Des Devel Ther.* 2015; 9: 3899-909.
21. Gomez NN, Biaggio VS, Ciminari ME, Chaca MVP, Álvarez SM. Zinc: what is its role in lung cancer? In: Erkekoglu P, editor. *Nutritional Deficiency*. London: InTech; 2016. doi: 10.5772/63209.
22. Fanzo JC, Reaves SK, Cui L, Zhu L, Wu JY, Wang YR, *et al.* Zinc status affects p53, gadd45, and c-fos expression and caspase-3 activity in human bronchial epithelial cells. *Am J Physiol Cell Physiol.* 2001; 281: C751-7.
23. Nikula KJ, Wilson DW, Giri SN, Plopper CG, Dungworth DL. The response of the rat tracheal epithelium to ozone exposure. Injury, adaptation, and repair. *Am J Pathol.* 1988; 131: 373-84.
24. Ho E, Courtemanche C, Ames BN. Zinc deficiency induces oxidative DNA damage and increases p53 expression in human lung fibroblasts. *J Nutr.* 2003; 133: 2543-8.
25. Puchelle E, Zahm JM, Tournier JM, Coraux C. Airway epithelial repair, regeneration, and remodeling after injury in chronic obstructive pulmonary disease. *Proc Am Thorac Soc.* 2006; 3: 726-33.