

CASE REPORT

Laparoscopic Approach for Huge Benign Ovarian Cyst in Woman with History of Previous 5 Laparotomies (including 4 cesarean section)

Aisha Taraby^{1*}, Dalal Boogis¹, Ayman Zamreek¹, Nahla Alyawer¹, Saad Alsudairy¹

¹King Abdulaziz Hospital, Saudi Arabia

*Corresponding author: Aisha Taraby: aishataraby@yahoo.com



Citation: Taraby A., Boogis D., Zamreek A., Alyawer N., Alsudairy S. (2020) Laparoscopic Approach for Huge Benign Ovarian Cyst in Woman with History of Previous 5 Laparotomies (including 4 cesarean section). Open Science Journal 5(1)

Received: 30th October 2019

Accepted: 6th December 2019

Published: 09th March 2020

Copyright: © 2020 This is an open access article under the terms of the [Creative Commons Attribution License](#), which permits unrestricted use, distribution, and reproduction in any medium, provided the original author and source are credited.

Funding: The author(s) received no specific funding for this work

Competing Interests: The author have declared that no competing interests exist.

Abstract:

An adnexal mass (mass of the ovary, fallopian tube, or surrounding connective tissues) is a common gynecologic problem. In the United States, it is estimated that there is a 5 to 10% lifetime risk for women undergoing surgery for a suspected ovarian neoplasm. Adnexal masses may be found in females of all ages, from fetuses to older adults, and there are a wide variety of types of masses. Today, the surgical treatment has become more conservative and less invasive; hence, a laparoscopic approach in the presence of benign cysts has become a golden standard. In the past, patients with previous abdominal surgery were discouraged from undergoing laparoscopic surgery because of its increased risk of bowel injury caused by needle and trocar insertion. Complications occur two times more frequently in patients with previous laparotomy in a study of long series. The potential risk for injury of organs adherent to the abdominal wall during veress needle or trocar insertion as well as the necessity for adhesiolysis and its attendant complications are the two major specific problems constraining surgeons from performing laparoscopic cystectomy/oophorectomy for patients with previous abdominal surgery. Herein, we report a case of a 32-year-old woman P4 + 2 with history of previous four cesarean section and a following laparotomy for interval sterilization presented to our clinic with abdominal mass, discovered by ultrasound scan, managed by a laparoscopic approach.

Keywords: Benign ovarian cyst, laparoscopy, ovary, previous cesarean section, previous laparotomy

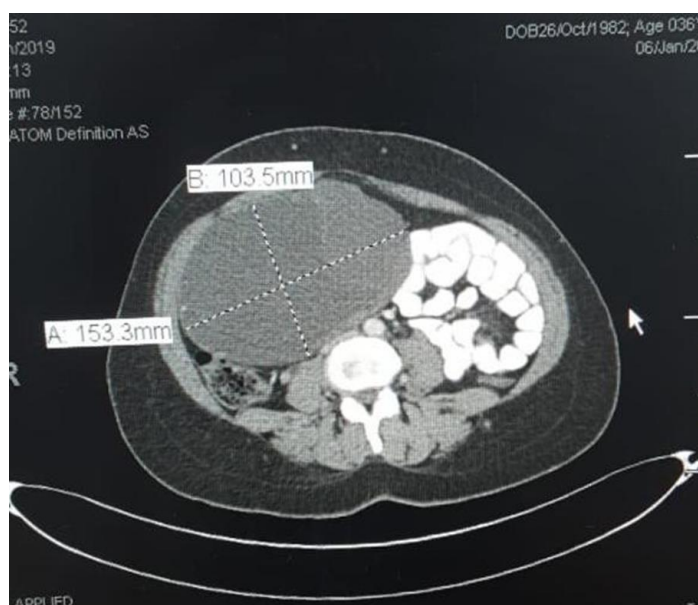
Introduction

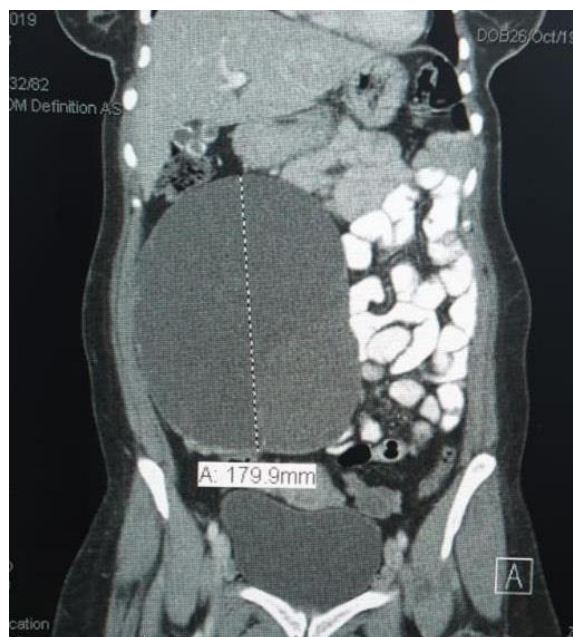Ovarian cysts are the most common cause of pelvic masses in women, and in the majority of the cases are women in fertile age. Today the surgical treatment has become more conservative and less invasive, hence laparoscopic approach in presence of benign cysts has become a golden standard.

Case report

A 32-year-old para 4 +2, with history of previous 4 cesarean section (in which the last two of them were midline followed by a midline laparotomy 6 month after the last cesarean section for interval sterilization), presented to our clinic with a history of abdominal distention, no other symptoms, she reported no bowel or urinary disturbance and her a regular menstrual cycles were regular. In addition, sShe did not have a family history for cancer.

On examination, the patient was average body beltbuild; the abdomen was distended by a large abdominal mass that reached up to the level of the xiphisternum. The abdominal CT scan showed a huge pelviabdominal multilocular cystic lesion measuring 10 x 15 x 18, arising mostly from the right ovary. [Fig1, Fig2]

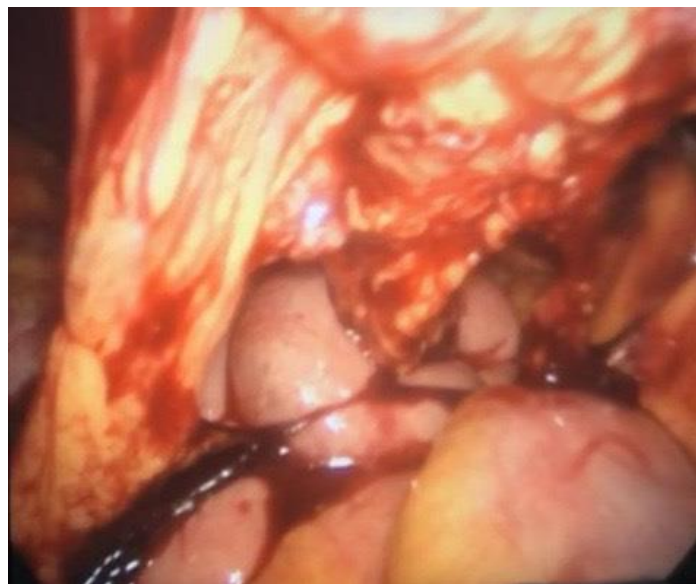
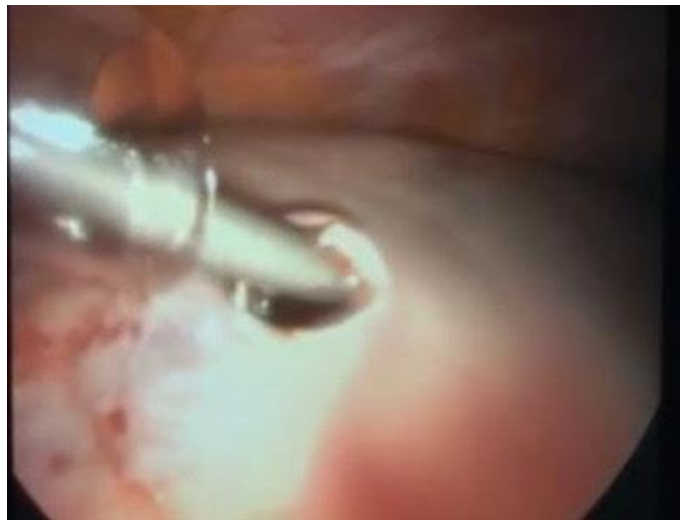


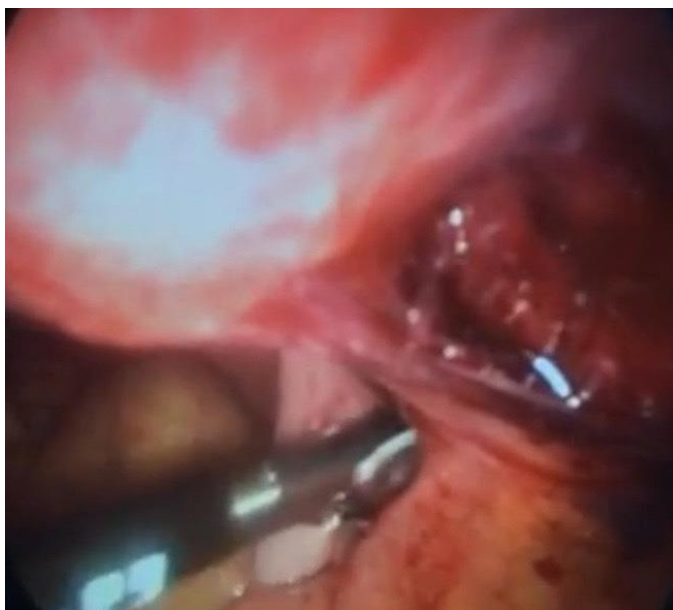The Patient was consented for a laparoscopy and possible conversion to laparotomy if any complication encountered.

Her serum tumor markers were all within the normal range. The pre-operative evaluation revealed features of a benign cyst, and her general health conditions were good, so thus we decided to use the laparoscopic approach.

During the operation, we prefer an open laparoscopic technique near the umbilicus to avoid the adhesions. Intraoperative finding shows: 1-Moderate adhesion between omentum and anterior abdominal wall in multiple areas. 2-The uterus was fixed and adherent to the anterior pelvic wall. 3- Normal looking left ovary and tube. 4-Huge ovarian cyst around 15 x 18 cm found arising from the right ovary with part of the small bowel adherent to the cyst and the other part is adherent to the pelvic sidewall. Three more ancillary trocar was were inserted, omental adhenolysis is made, cyst aspiration done before excision around 2 L of clear fluid was aspirated. Right adectomy was done after releasing the adhesions. [Fig3, Fig4, Fig5].





The pathological examination revealed a benign mucinous cystadenoma. The patient has been discharged the next day in good health.

Discussion

Previous abdominal surgery has been recognized as one of the most important risk factors for laparoscopic surgery. But the question is how the morbidity can be kept at the minimum while maintaining its superior benefit over open surgery [1].

Laparoscopic access is the most crucial most part of the surgery where veress needle was are blindly inserted to create pneumoperitoneum followed by primary trocar. Obtaining access to the peritoneal cavity in laparoscopic surgery is more difficult in patients with previous abdominopelvic surgery, as it can be difficult, time-consuming, and occasionally hazardous procedure. The majority of complications (30–50%), occur during surgical access [2,3], with vascular and bowel injuries the most serious sequela [4].

Formation and extent of adhesions are unpredictable. The incidence of abdominal wall adhesions was significantly more frequent after prior laparotomy. Midline laparotomy above the level of the umbilicus was found to be associated with the highest rate of adhesion (67%)[5]. The risk of adhesion for suprapubic transverse incision was (28%)[6]. Adhesions, when present involved mainly omentum (96%) and bowel (29%).

Surgical exploration for an adnexal mass may be performed laparoscopically (conventional or robotic) or via a laparotomy. The employment of laparoscopy for the surgical management of benign ovarian cysts has become popular. Although it is a challenging task when the cysts are large with the presence of adhesions. The choice of surgical approach depends upon the degree of suspicion of malignancy and surgeon and patient preference. If there is a low or moderate suspicion of malignancy, a laparoscopic approach is typically used.

Most ovarian surgeries are for benign disease and can be performed via a minimally invasive surgical (MIS) approach. The major advantages to MIS over laparotomy are reductions in recovery time, hospital stay, cost, and adhesion

formation, which is particularly important for women in whom fertility is an issue.

A randomized prospective study comparing laparoscopy and laparotomy in the management of patients with benign ovarian masses less than 10 cm in diameter reported a significant reduction in operative morbidity, postoperative pain and analgesic requirement, hospital stay and recovery period. However, the same results can be obtained with large cysts also. [7]

A disadvantage of an MIS oophorectomy/cystectomy is the potential for spill of cancer cells if the mass is malignant

There is an increasing sentiment to evaluate some complex cysts with MIS because most of them are benign. There are no dogmatic recommendations for this group of patients, and clinicians must individualize treatment according to their index of suspicion. The concern associated with the use of MIS in this setting is that the prognosis may be worsened by cyst rupture if malignancy is encountered, although however this is unproven. Therefore, one must take into account the patient's age, medical condition, clinical examination (e.g. fixed mass or mobile), sonographic appearance of the mass, and tumor markers (e.g. cancer antigen 125 [CA 125]) to gauge the likelihood of malignancy when deciding upon the proper operative approach. MIS should be reserved for those cases in which the risk of malignancy is very low, or if a malignancy is encountered, the patient should have immediate access to appropriate surgical staging and definitive treatment, preferably with the assistance of a gynecologic oncologist

In the surgical treatment of benign ovarian cysts in young women, independently of its size, one of the main goals that all surgeons need to keep in mind is to preserve the reproductive and hormonal functions of the ovaries and prevent recurrence. However, relatively frequent, this cannot be achieved because the cysts have strong adhesions with the ovary as reported in this paper.

The laparoscopic approach for the removal of cysts with a diameter greater than 10 cm presents different difficulties; the most important are as follows: First, the rupture of the cysts with spillage of its contents during the introduction of a trocar or veress needle. We prefer an open technique near the umbilicus. we did not aspirate the cyst prior to the operation. A recent literature revealed that some authors prefer cyst size reduction prior to laparoscopy and it may be obtained using different techniques such as ultrasound-guided aspiration [8] or with the use of the Bonanno catheter [9]. Second, there is a limited visualization and work space that causes difficulties in identifying important structures such as the ureters.

We believe that managing patient laproscopically for huge ovarian cystectomy/adexectomy with history of previous multiple laparotomies is feasible with proper patient selection and availability of experts in gynecological endoscopy.

References:

1. Hazim W, Roszaman R. Impact of Previous Abdominal Surgery on Laparoscopic Cystectomy/Oophorectomy Results: A Comparative Clinical Study. *IMJM* 2012; 11:29-2.
2. Tarik A, Fehmi C. Complications of gynaecological laparoscopy—a retrospective analysis of 3572 cases from a single institute. *J Obstet Gynaecol* 2004; 24:813-6.
3. Mac Cordick C, Lecuru F, Rizk E, et al. Morbidity of laparoscopy for gynecological surgery. Results of a prospective monocentre study. *Surg Endosc* 1999; 13:57-61.
4. Chapron C, Pierre F, Lacroix S, Querleu D, Lansac J, Dubuisson JB. Major vascular injuries during gynaecologic laparoscopy.

- J Am Coll Surg 1997; 185:461-5.
5. Brill AI, Nezhat F, Nezhat CH, Nezhat C. The incidence of adhesions after prior laparotomy: a laparoscopic appraisal. *Obstet Gynecol* 1995; 85:269-72.
 6. Bieber EJ, Barnes RB. Anterior abdominal wall adhesions after laparotomy or laparoscopy. *J Am Assoc Gynecol Laparosc* 1997; 4:353-6.
 7. Yeun PM, Yu KM, Yip SK, Lau WC, Rogers MS, Chang A. A randomized prospective study of laparoscopy and laparotomy in the management of benign ovarian masses. *Am J Obstet Gynecol*. 1997; 177:109-14. [PubMed]
 8. Nagele F, Magos AL. Combined ultrasonographically guided drainage and laparoscopic excision of a large ovarian cyst. *Am J Obstet Gynecol*. 1996;175:1377-8. [PubMed]
 9. Eltabbakh GH, Chaboneau AM, Eltabbakh NG. Laparoscopic surgery for large benign ovarian cysts. *Gynecol Oncology*. 2008; 108:72-6. [PubMed]