

## CASE REPORT

## “Fleshy” Skin Cellulitis: A Triggering Factor for ANCA Associated Vasculitis

*Sim Chun Yang<sup>1</sup>, Ruslinda Mustafar<sup>2</sup>, Lydia Kamaruzaman<sup>2</sup>, Kong Wei Yen<sup>2</sup>, Rozita Mohd<sup>2</sup>, Rizna Cader<sup>2</sup>*

<sup>1</sup> Department of Medicine, Universiti Kebangsaan Malaysia Medical Centre (UKMMC), Malaysia.

<sup>2</sup> Nephrology Unit, Department of Medicine, Universiti Kebangsaan Malaysia Medical Centre (UKMMC), Malaysia.

### **Corresponding Author:**

*Ruslinda Mustafar. Consultant Nephrologist and Physician. Nephrology Unit, Department of Medicine, Universiti Kebangsaan Malaysia Medical Centre (UKMMC). Jalan Yaacob Latiff, 56000 Cheras, Kuala Lumpur, Malaysia. email: ruslinda.m@gmail.com.*

### **ABSTRAK**

*Seorang wanita usia 59 tahun dengan hipotiroidisme dermatitis kontak akut berkembang menjadi selulitis dengan infeksi bakteri superimposed dan cedera ginjal akut. Dia merespons penatalaksanaan awal dengan antibiotik, namun seminggu kemudian mengalami vaskulitis kulit dan sistemik. Biopsi kulit konsisten dengan vaskulitis leuko-sitoklastik yang dimediasi imun dan hasil tes darah positif antibodi sitoplasma-anti-neutrofil sitoplasma (c-ANCA). Diagnosis vaskulitis terkait ANCA ditegakkan. Wanita tersebut dirawat dengan immunosupresan plasmaferesis dan dukungan hemodialisis untuk gagal ginjalnya. Laporan kasus ini menunjukkan bahwa infeksi jaringan lunak dapat memicu perkembangan vaskulitis terkait ANCA, latar belakang hipotiroidisme berfungsi sebagai faktor predisposisi karena kedua kondisi tersebut dilaporkan secara terpisah dalam beberapa studi kasus sebelumnya.*

**Kata kunci:** selulitis, anti-neutrophil cytoplasmic antibody, vaskulitis.

### **ABSTRACT**

*A 59-year-old lady with underlying hypothyroidism presented with acute contact dermatitis progressed to cellulitis with superimposed bacterial infection and acute kidney injury. She responded to initial management with antibiotics, but a week later, she had cutaneous and systemic vasculitis. Her skin biopsy consistent with immune-mediated leuko-cytoplastic vasculitis and her blood test was positive for cytoplasmic-anti-neutrophil cytoplasmic antibody (c-ANCA). A diagnosis of ANCA-associated vasculitis was made and she was treated with immunosuppressant with plasmapheresis and hemodialysis support for her kidney failure. Despite aggressive measures, the patient succumbed to her illness. This case report demonstrates that soft tissue infection could trigger the development of ANCA-associated vasculitis whilst a background of hypothyroidism serves as a predisposing factor as both condition were reported separately in a couple of case studies before.*

**Keywords:** cellulitis, anti-neutrophil cytoplasmic antibody, vasculitis.

## INTRODUCTION

ANCA associated vasculitis (AAV) is a small vessel vasculitis (SVV) which is necrotizing in nature with few or no immune deposits. It is associated with myeloperoxidase (MPO)-ANCA or proteinase 3 (PR3)-ANCA antibody. In literature, AAV is divided into 3 main categories namely microscopic polyangiitis (MPA), granulomatosis with polyangiitis (GPA), and eosinophilic granulomatosis with polyangiitis (EGPA).<sup>1</sup> Despite a better understanding of the disease, the classification of AAV remains tricky because of the unknown etiology and considerable overlap in the clinical expression of these vasculitis syndromes.

It is well known that all the three types of AAV have common clinical presentations, including some of the non-specific inflammatory symptoms and signs such as malaise, fever, anemia, weight loss, rashes and synovitis. Therefore the exact diagnosis is often elusive and complex.<sup>2</sup> As for now, to establish the definitive diagnosis of AAV warrant a collective assessment of clinical manifestations, a biopsy of the involved organ and the positivity of ANCA in the plasma. In view of malignant nature of untreated AAV, high clinical suspicion, early recognition and management are vital to retard the progression and to prevent life-threatening complications of the disease.

Here, we describe a case of multi-systemic AAV precipitated by soft tissue infection in a patient with underlying thyroid disease that potentially increases the likelihood of such association.

## CASE ILLUSTRATION

A 59-year-old lady with underlying hypothyroidism on thyroxine replacement for 2 years, presented with bilateral feet pain for one month duration. She consulted primary healthcare and was treated with oral analgesic (Meloxicam - Mobic®) and vitamin supplements. A week later, as her feet got worse and became erythematous, she soaked her feet in cleansing solution (Dettol®) for disinfection purposes. Unfortunately, her feet started to develop multiple blisters which caused her to come to our hospital. She denied any history of

fever and did not receive any antibiotic prior to her admission.

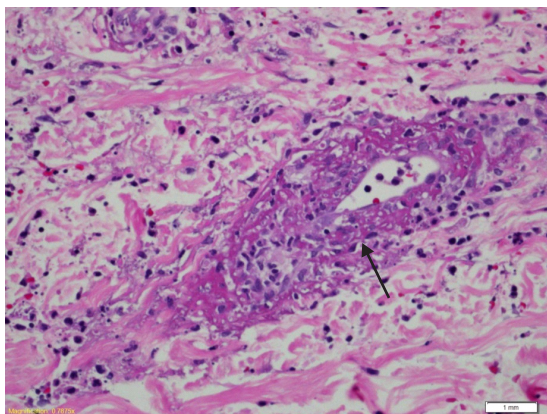
Physical examination revealed few oral ulcers as well as blisters and erythema of both feet. She was afebrile and her vital signs were normal with blood pressure (BP) of 129/69 mmHg and pulse rate (PR) of 117 beats per minute (bpm). Investigations showed a total white count of  $19.9 \times 10^9/L$  and raised C-reactive protein (CRP) of 21.89 mg/dL. She had normochromic normocytic anemia with hemoglobin (Hb) of 8.7 g/dL whilst her renal profile was deranged with urea of 13.0 mmol/L and creatinine of 222  $\mu\text{mol/L}$ . Her baseline creatinine 6 months earlier was normal at 63.5  $\mu\text{mol/L}$ . Other systemic examination and investigations were unremarkable. Her lungs were clear with normal chest X-ray.

She was diagnosed to have acute contact dermatitis of both feet and cellulitis with superimposed bacterial infection with non-steroidal anti-inflammatory drugs (NSAIDs) (cyclo-oxygenase-2 inhibitor) induced acute kidney injury (AKI). She was started on intravenous (IV) ampicillin-sulbactam, potassium permanganate soak of her feet twice a day and oral Prednisolone of 20 mg daily with tapering every 3 days. Her serum creatinine peaked at 242.9  $\mu\text{mol/L}$ . She completed a week of antibiotic, her feet and kidney function improved whilst her serum creatinine upon discharge was 198  $\mu\text{mol/L}$ . She was planned for clinic review and given Betamethasone cream with her usual thyroxine replacement of 75  $\mu\text{g}$  daily.

Unfortunately, a week later, she was readmitted with fever and pus discharge from the wounds of her feet. Physical examination showed swollen macerated feet with cracked skin and pus discharge. There were purpuric rashes found bilaterally up till her thighs. She was febrile with BP of 120/75 mmHg and PR of 110 bpm. Blood investigations revealed worsening anemia with Hb of 6.6 g/dL, white cell count (WCC) of  $11 \times 10^9/L$ , CRP of 25 mg/dL, severe hyponatraemia with serum sodium of 118 mmol/L, worsening AKI with urea of 25.7 mmol/L and creatinine of 959  $\mu\text{mol/L}$ . She has no evidence of gastro-intestinal bleed and did not take any NSAIDs since discharge.

She was treated for infected bullous ulcer with sepsis causing worsening AKI and cutaneous vasculitis. She was started on IV Piperacillin-tazobactam, intravenous saline hydration, packed cell transfusions and oral Prednisolone of 40 mg daily. Ultrasound scan of the kidneys revealed normal kidneys size with no obstruction, urinalysis showed blood 3+ and protein 2+ with urine protein creatinine index (UPCI) of 0.28 g/mmol creatinine. Urine phase contrast showed isomorphic red blood cells. She had a negative antinuclear antibody (ANA), normal C3 level of 71.5 mg/dL and normal C4 level of 12.9 mg/dL. Panel immunoglobulin level was not raised with immunoglobulin (Ig) M of 20.3 mg/dL, IgG 767 mg/dL, and IgA 209 mg/dL while cryoglobulins were also negative. Her infective screening for hepatitis B and C, human immunodeficiency virus (HIV), anti-streptolysin O titre (ASOT), venereal disease research laboratory (VDRL) test were all negative with negative blood and urine culture and sensitivity (C+S). Meanwhile, a swab C+S of her wounds showed a mixed growth – a combination of gram-positive and gram-negative organisms.

A biopsy of the vasculitis lesions from her left shin (**Figure 1**) revealed moderate perivascular neutrophilic inflammatory infiltrates with nuclear debris over the superficial dermis, these were stained positive for C3, IgG and IgM on immunofluorescence study. The findings were consistent with leuko-cytoplastic vasculitis and suggestive of immune-mediated lesion. Her kidney function rapidly deteriorated and she required hemodialysis (HD). A renal biopsy was



**Figure 1.** Skin biopsy (40 x magnifications) showing perivascular neutrophilic infiltration (arrow).

planned however it was postponed due to ongoing sepsis and thrombocytopenia with platelets of  $65 \times 10^9/L$ . Her immunosuppressive medication was changed to IV Methylprednisolone 50 mg daily.

She progressed rapidly with multi-organ involvement; acute coronary syndrome due to carditis and hepatitis. She was dialysis dependent and still suffering from on-going sepsis. Due to severe organ involvement due to systemic vasculitis, she was given pulsed corticosteroid with IV Methylprednisolone 150 mg daily for 3 days followed by 50 mg daily and was also given first dose of IV Cyclophosphamide to treat her active disease. Meanwhile, her antibiotic was escalated to IV Meropenem. She received only one session of plasmapheresis as she developed severe pancytopenia post procedure with Hb of 7.3 g/dL, WCC of  $1.0 \times 10^9/L$  and platelets of  $36 \times 10^9/L$ .

A computed tomography (CT) scan of thorax, abdomen and pelvis was performed to look for internal malignancy which was reported as negative. A qualitative test for cytoplasmic ANCA (c-ANCA) from a private laboratory was positive whilst perinuclear ANCA (p-ANCA) was negative. From the extensive investigations, she was treated aggressively for systemic vasculitis and multi-organ failure with superimposed sepsis due to cutaneous skin infections and the final diagnosis was attributed due to AAV.

Her clinical condition gradually improved with our aggressive measures and was given a 2nd dose of IV Cyclophosphamide. Unfortunately, she also suffered from severe depression from her illness needing selective serotonin re-uptake inhibitor (SSRI). She and her family were given extensive counselling on the disease and eventually they opted for conservative/palliative management. She finally succumbed to her illness.

## DISCUSSION

Primary systemic vasculitis associated with anti-neutrophil cytoplasmic antibodies (ANCA) is one of the common causes of rapidly progressive glomerulonephritis. ANCAs are directed against several myeloid enzymes

namely c-ANCA and p-ANCA.<sup>3</sup> Testing for ANCA is by enzyme-linked immunosorbent assay (ELISA) where c-ANCA reacts with proteinase 3 (ANCA-PR3) whilst p-ANCA reacts with myeloperoxidase (ANCA-MPO). ANCA-PR3-positivity is predominantly found in patients with granulomatous polyangiitis (GPA) and microscopic polyangiitis (MPA) meanwhile ANCA-MPO-positivity is found in patients with MPA and eosinophilic granulomatous polyangiitis (EGPA) as well as in patients with other vasculitides and auto-immune conditions.<sup>4</sup>

Our patient had biopsy-proven cutaneous vasculitis lesions with rapidly declining renal function that is attributed to rapidly progressive glomerulonephritis (RPGN) as well as sepsis which required hemodialysis support. Her skin biopsy was suggestive of immune-mediated vasculitis however, we were unable to proceed with a kidney biopsy as her platelets were low and her condition was unstable. Her plasma c-ANCA was positive and when we tied up together with her clinical conditions, these have led to the diagnosis of multi-systemic AAV. Despite the small percentage possibility co-existent of ANCA and anti-GBM positivity, we did not proceed with further test even testing the ANCA with ELISA for MPO or PR3 specificity as it was very costly and would not change much of our current management.

ANCA-associated glomerulonephritis is classically pauci-immune in nature from the renal histopathology immunofluorescence (IF) study and unfortunately, in this case, we were unable to perform the renal biopsy due to her ill condition. However, from the skin biopsy, it was stained positive for C3, IgG and IgM on IF. In literature, there were reported cases whereby immune complex deposits were found on skin and renal biopsies in AAV.<sup>5</sup> A study by Haas and Eustace on 126 renal biopsies with ANCA-associated or arteritis-associated necrotizing crescentic GN found that 15% had positive immunofluorescence microscopy findings for IgG, 49% for IgM, 57% for C3 and 8% for C1q.<sup>6</sup> As mentioned earlier, the exact pathogenesis and the significance of immune deposits in the affecting organs remain unclear. This case perhaps also illustrates the small percentage of

cases that has positive ANCA in the plasma and her skin biopsy showed positivity for immune complexes.

This case was initially treated for acute contact dermatitis with superimposed bacterial infection causing cellulitis. Although she had mixed growth in swab culture, *Staphylococcus aureus* remains the most common organism leading to soft tissue infections in the community.<sup>7,8</sup> The hypothesis of an infectious agent such as *Staphylococcus aureus* triggering the immune system has been suggested before. This theory emerged based on the observation that up to 70% of patients with chronic nasal GPA are carriers of this microorganism.<sup>9,10</sup> William et al.<sup>11</sup> suggested role of infections as triggers for AAV and he also described anti-complement antibodies in patients with PR3-ANCA vasculitis. These antibodies were found to react to the peptide sequences from the complementary PR3-sequence, which has similarity with a number of infectious pathogens such as *Staphylococcus aureus*. Hence, infections as triggering factors for AAV is a valid argument and in our case, we hypothesis that her initial infected dermatitis as the inciting event to a full-blown multi-systemic AAV.

Previous studies and case reports have shown the association between two autoimmune diseases occurring together either simultaneously or sequentially.<sup>12</sup> Small vessels vasculitis has been reported to be associated with other autoimmune diseases.<sup>13,14</sup> A population-based study reported that thyroid disease was prevalent at the time of diagnosis of AAV in as many as 40% of cases.<sup>14</sup> Tanaka et al.<sup>15</sup> found 4 cases out of 10 with MPO-ANCA positive nephropathy had hypothyroidism and two of them were subclinical. Concur to the report; Lai et al.<sup>16</sup> also reported a case of AAV with Hashimoto's thyroiditis in Malaysia. Similarly as we illustrated in this case, our patient was diagnosed to have hypothyroidism for 2 years and was put on thyroxine replacement. Even though there were no investigations to determine the etiology of her hypothyroidism, it was possible the cause of her hypothyroidism is due to Hashimoto's thyroiditis or due to iodine deficiency.<sup>17</sup> We believe this case report supports the association between AAV and autoimmune thyroid diseases as suggested by previous studies.

AAV is an immune-mediated disease; therefore its treatment involves immunosuppression to induce remission followed by maintenance therapy to prevent relapses. A multitude of treatment options can be incorporated with agents such as corticosteroid, azathioprine, methotrexate, mycophenolate mofetil, cyclophosphamide and anti CD-20 monoclonal antibody such as Rituximab.<sup>18,19</sup> Therapies such as plasma exchange (PE) also can be used in combination or sequential with the immunosuppressive medications especially in cases of severe, refractory or relapsing AAV.<sup>20</sup> However, despite significant evidence-based advances in our treatment strategies, AAV remains a disease with substantial mortality and morbidity with worse prognosis in the elderly and for those with severe renal involvement.<sup>21,22</sup>

## CONCLUSION

This case report suggests that cellulitis could be the trigger for the development of multi-systemic AAV. Her background history of hypothyroidism, potentially become a risk for such development and concur with very limited case reports before. Under these circumstances we need to have a high index of suspicion to detect AAV earlier and administer definitive treatment as soon as possible for a better prognosis to this devastating condition.

## ACKNOWLEDGMENTS

No author of this paper has conflict of interest. We receive no financial support for this case report.

## REFERENCES

- Jennette JC. Overview of the 2012 revised International Chapel Hill Consensus Conference nomenclature of vasculitides. *Clin Exp Nephrol*. 2013;17(5):603-6.
- McKinney EF, Willcocks LC, Broecker V, Smith KG. The immunopathology of ANCA-associated vasculitis. *Seminars Immunopathol*. 2014;36(4):461-78.
- Savige J, Gillis D, Benson E, et al. International Consensus Statement on Testing and Reporting of Antineutrophil Cytoplasmic Antibodies (ANCA). *American J Clin Pathol*. 1999;111(4):507-13.
- Schonermark U, Lamprecht P, Csernok E, Gross WL. Prevalence and spectrum of rheumatic diseases associated with proteinase 3-antineutrophil cytoplasmic antibodies (ANCA) and myeloperoxidase-ANCA. *Rheumatol*. 2001;40(2):178-84.
- El-Ters M, Muthyala U, Philipneri MD, Hussein FA, Lentine KL. Immune-complex deposits in "pauci-immune" glomerulonephritis: a case report and brief review of recent literature. *Arch Med Sci*. 2010;6(4):633-7.
- Haas M, Eustace JA. Immune complex deposits in ANCA-associated crescentic glomerulonephritis: a study of 126 cases. *Kidney Int*. 2004;65(6):2145-52.
- Ray GT, Suaya JA, Baxter R. Incidence, microbiology, and patient characteristics of skin and soft-tissue infections in a U.S. population: a retrospective population-based study. *BMC Infect Dis*. 2013;13:252.
- Ray GT, Suaya JA, Baxter R. Microbiology of skin and soft tissue infections in the age of community-acquired methicillin-resistant *Staphylococcus aureus*. *Diagn Microbiol Infect Dis*. 2013;76(1):24-30.
- Munoz-Grajales C, Pineda JC. Pathophysiological relationship between infections and systemic vasculitis. *Autoimmune Dis*. 2015;2015:286783.
- Stegeman CA, Tervaert JW, Sluiter WJ, Manson WL, de Jong PE, Kallenberg CG. Association of chronic nasal carriage of *Staphylococcus aureus* and higher relapse rates in Wegener granulomatosis. *Annals of Intern Med*. 1994;120(1):12-7.
- Pendergraft WF, Preston GA, Shah RR, et al. Autoimmunity is triggered by cPR-3(105-201), a protein complementary to human autoantigen proteinase-3. *Nature Med*. 2004;10(1):72-9.
- Shoenfeld Y. The kaleidoscope of autoimmunity. *Autoimmunity*. 1993;15(3):245-52.
- Szyper-Kravitz M, Marai I, Shoenfeld Y. Coexistence of thyroid autoimmunity with other autoimmune diseases: friend or foe? Additional aspects on the mosaic of autoimmunity. *Autoimmunity*. 2005;38(3):247-55.
- Lionaki S, Hogan SL, Falk RJ, et al. Association between thyroid disease and its treatment with ANCA small-vessel vasculitis: a case-control study. *Nephrol Dial Transplant*. 2007;22(12):3508-15.
- Tanaka A, Maeda K, Sawai K, Okuda J, Sugawara A, Kuwahara T. Concealed hypothyroidism in patients with myeloperoxidase antineutrophil cytoplasmic autoantibodies- (MPO-ANCA) positive renal disease. *Clin Nephrol*. 1999;52(2):91-5.
- Lai Y, Nik Yahya NH, Ong SG. ANCA-associated vasculitis - revisited, and its association with autoimmune thyroid disease. *Med J Malaysia*. 2014;69(2):98-100.
- Vanderpump MP. The epidemiology of thyroid disease. *British Med Bulletin*. 2011;99:39-51.
- Belaconi IN, Toma CL, Bogdan MA. [Update in the management and treatment of ANCA-associated vasculitis]. *Pneumologia*. 2014;63(2):78-80, 3-6.
- Hamour S, Salama AD, Pusey CD. Management of ANCA-associated vasculitis: Current trends and future prospects. *Ther Clin Risk Manag*. 2010;6:253-64.

20. Walters G. Role of therapeutic plasmapheresis in ANCA-associated vasculitis. *Pediatric Nephrol.* 2016;31(2):217-25.
21. Tan JA, Dehghan N, Chen W, Xie H, Esdaile JM, Avina-Zubieta JA. Mortality in ANCA-associated vasculitis: a meta-analysis of observational studies. *Annals Rheumatic Dis.* 2017;76(9):1566-74.
22. Weiner M, Goh SM, Mohammad AJ, et al. Outcome and treatment of elderly patients with ANCA-associated vasculitis. *Clin J Am Soc Nephrol: CJASN.* 2015;10(7):1128-35.