

**Case Report****Chronic Graft-Versus-Host-Disease-Related Polymyositis: a 17-Months-Old Child with a Rare and Late Complication of Haematopoietic Stem Cell Transplantation**

Matteo Chinello<sup>1</sup>, Rita Balter<sup>1</sup>, Massimiliano De Bortoli<sup>1</sup>, Virginia Vitale<sup>1</sup>, Ada Zaccaron<sup>1</sup>, Elisa Bonetti<sup>1</sup>, Paola Tonin<sup>2</sup>, Gaetano Vattemi<sup>2</sup>, Valeria Guglielmi<sup>2</sup> and Simone Cesaro<sup>1</sup>.

<sup>1</sup> Pediatric Hematology Oncology, Azienda Ospedaliera Universitaria Integrata, Verona, Italy.

<sup>2</sup> Department of Neurosciences, Biomedicine and Movement Sciences, Section of Clinical Neurology, University of Verona, Italy.

**Competing interests:** The authors declare no conflict of Interest.

**Abstract. Background:** Chronic graft versus host disease (cGVHD) occurs in 20-30% of paediatric patients receiving haematopoietic stem cell transplantation (HSCT). Neuromuscular disorders such as polymyositis are considered a rare and distinctive but non-diagnostic manifestation of cGVHD and, in the absence of other characteristic signs and symptoms, biopsy is highly recommended to exclude other causes.

**Case report:** We report a case of a 17-months-old child affected by hemophagocytic lymphohistiocytosis who underwent a matched unrelated donor haematopoietic stem cell transplantation (HSCT). She developed severe cGVHD-related polymyositis that was successfully treated with high-dose steroid therapy, rituximab and sirolimus.

**Conclusions:** This is the first case of cGVHD-related-polymyositis described in a pediatric patient which was successfully treated with rituximab.

**Keywords:** Hemophagocytic Lymphohistiocytosis; Emapalumab; Chronic graft-versus-host-disease; Polymyositis; Methylprednisolone; Rituximab; Sirolimus.

**Citation:** Chinello M., Balter R., De Bortoli M., Vitale V., Zaccaron A., Bonetti E., Tonin P., Vattemi G., Guglielmi V., Cesaro S. Chronic graft-versus-host-disease-related polymyositis: a 17-months-old child with a rare and late complication of haematopoietic stem cell transplantation. *Mediterr J Hematol Infect Dis* 2020, 12(1): e2020002, DOI: <http://dx.doi.org/10.4084/MJHID.2020.002>

**Published:** January 1, 2020

**Received:** July 24, 2019

**Accepted:** November 14, 2019

This is an Open Access article distributed under the terms of the Creative Commons Attribution License (<https://creativecommons.org/licenses/by-nc/4.0>), which permits unrestricted use, distribution, and reproduction in any medium, provided the original work is properly cited.

Correspondence to: Matteo Chinello, M.D. Pediatric Hematology Oncology, Azienda Ospedaliera Universitaria Integrata, Piazzale A. Stefani 1, 37126, Verona, Italy. Fax: +390458127887, Tel: +390458127816. E-mail: [matteo.chinello@aovr.veneto.it](mailto:matteo.chinello@aovr.veneto.it)

**Introduction.** Chronic graft-versus-host-disease (cGVHD) is a late complication of allogeneic haematopoietic stem cell transplantation (HSCT), occurring more than 100 days after transplantation.<sup>1</sup> It occurs in 20-30% of patients receiving HSCT with higher frequency in patients with acute graft-versus-host-disease (aGVHD).<sup>2-4</sup> Early or delayed neurological GVHD-related manifestations occur in 30-60% of allogeneic HSCT recipients.<sup>5,6</sup> These include immune-mediated polyneuropathies and less frequently, polymyositis, myasthenia gravis, myositis, demyelination, cerebrovascular complications and immune-mediated encephalitis.<sup>5,6</sup> We report the case of

a 17-month-old child with an immune-mediated myopathy as a consequence of cGVHD-related polymyositis.

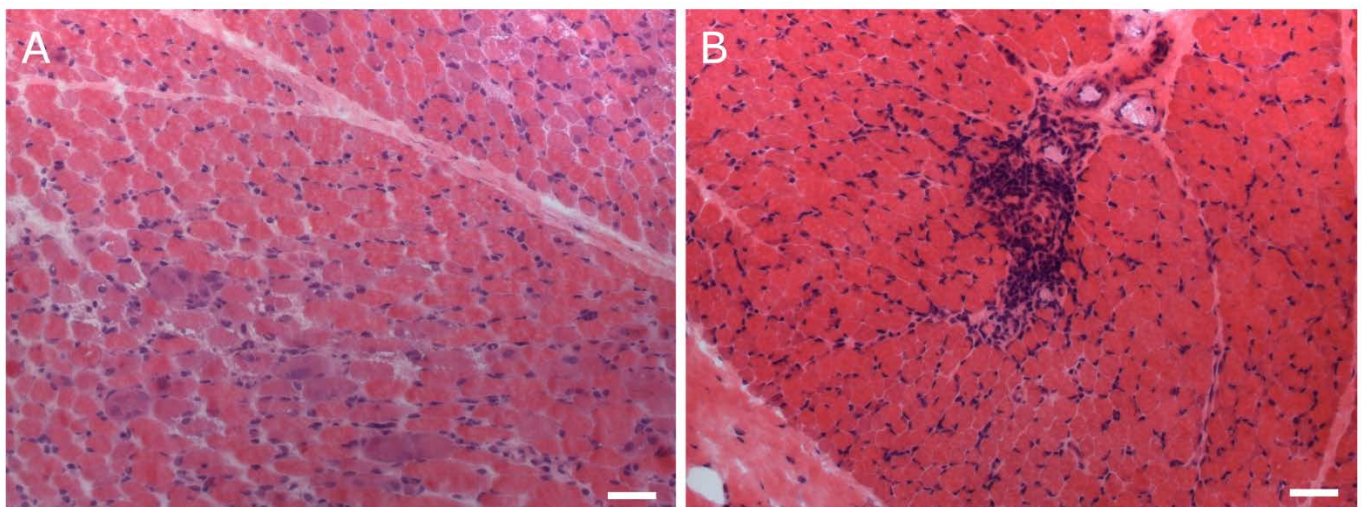
**Case Report.** A one-month-old girl of African origin was admitted to the local emergency pediatric unit for high fever, trilineage blood cytopenia and hepatosplenomegaly. Natural killer cells analysis showed a lack of perforin expression. The diagnosis of hemophagocytic lymphohistiocytosis (HLH) was confirmed by Next Generation Sequencing (NGS) analysis on peripheral blood DNA, showing the presence of genomic variants c.50delT and c.1130G>A

in PRF1 gene, both heterozygous. NM\_005041 (PRF1): c.[50delT(;):1130G>A], p.[Leu17ArgfsTer34(;):Cys377Tyr]. These variants, both homozygous and compound heterozygous, are described as related to HLH.<sup>7,8</sup> The patient started treatment with dexamethasone and cyclosporine, followed by emapalumab, a monoclonal antibody anti-interferon gamma.<sup>9</sup> She underwent HLA-matched unrelated donor HSCT at the age of 6 months (HLA-A, DRB1, permissive DPB1 allele mismatches). Conditioning regimen: busulfan (3x3,2 mg/kg/day), fludarabine (3x50 mg/m<sup>2</sup>/day), thiotepa (2x5 mg/kg/day) and rabbit antithymocyte globulin (ATG Genzyme<sup>TM</sup>) (3x4,5 mg/kg/day). The patient received 4.14x10<sup>8</sup>/kg bone marrow total nucleated cells and 7.37x10<sup>6</sup>/kg of CD34+ cells. GVHD prophylaxis was based on cyclophosphamide (2x50 mg/kg) and cyclosporine and low dose of prednisone (0,4 mg/kg/die). The pre-engraftment period was complicated by *Pseudomonas aeruginosa* sepsis (day + 10) and right lobar pneumonia (day +13). The engraftment occurred at day +16 with no sign of aGVHD. Therapy with ciclosporin was interrupted three months after HSCT, and she started therapy with tacrolimus. The prednisone given as GVHD prophylaxis was interrupted at month +7 post-HSCT. Full donor chimerism was found at day +50 and confirmed at month +8 post-HSCT. At 17 months the child was admitted to the hospital for lack of appetite, elevated liver enzymes with alanine aminotransferase (ALT) 850 U/L and aspartate aminotransferase (AST) 499 U/L (normal value 5-45), and polypnea. Presuming GVHD-related symptoms, she was treated with methylprednisolone at the dose of 2 mg/kg/die with no clinical improvement. The child rapidly developed respiratory failure that required mechanical ventilation. An extensive diagnostic work-up was performed: blood analysis revealed an increased value of creatine kinase

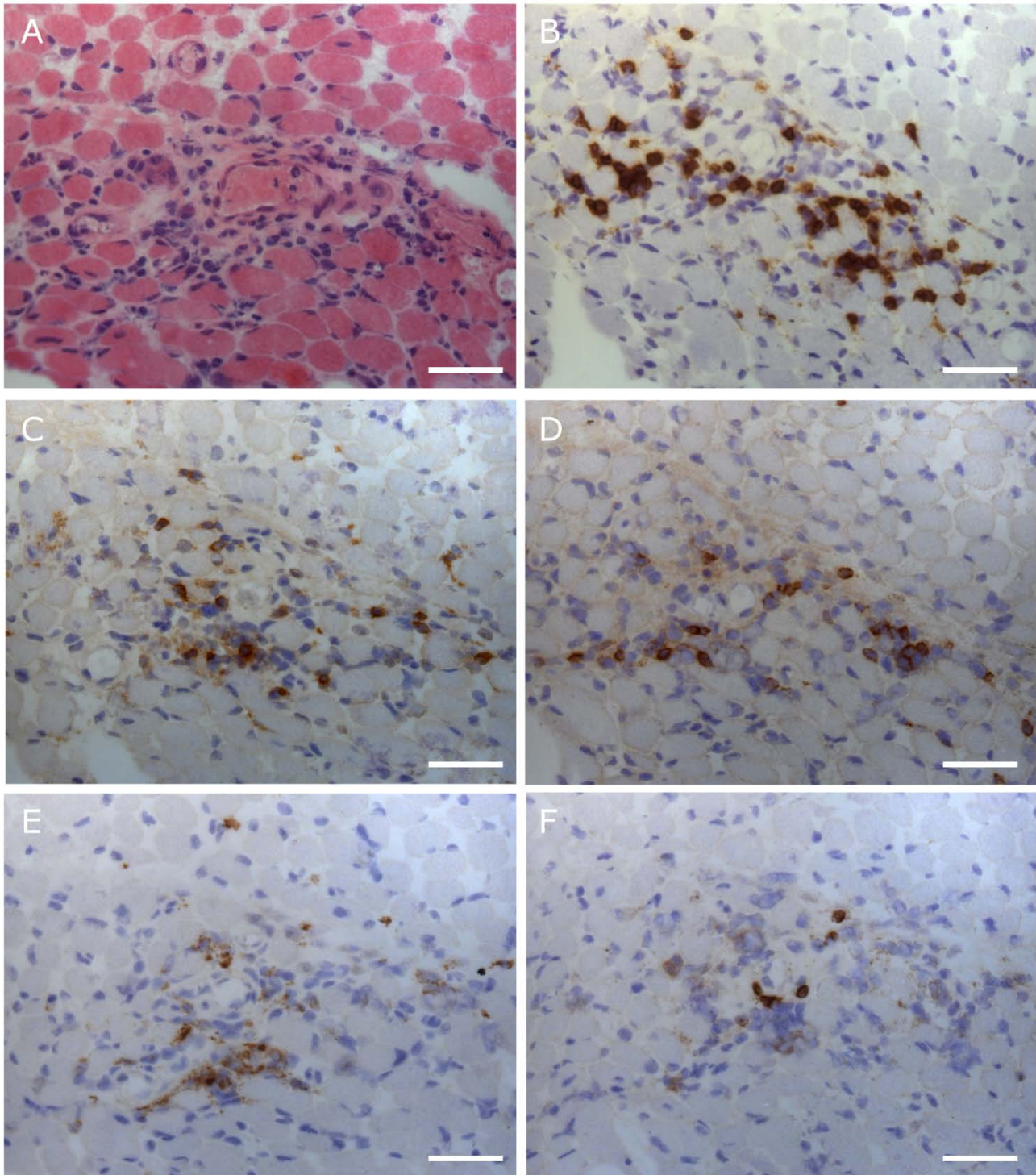
(CK) of 13830 U/L (normal value 25-190), creatine kinase (CK)-MB 555 ng/L (normal value < 6) and troponin of 2601 ng/L (normal value < 45); tacrolimus through blood level was in range; immunoglobulin levels were normal whilst the peripheral blood lymphocyte subpopulations showed an increase in the content of B-lymphocytes (2544,34 cells/ul, normal value 123-349); echocardiography showed a normal biventricular function; electroencephalography (EEG) revealed no abnormality; serological test and polymerase chain reaction (PCR) assay revealed no evidence of recent parvovirus B19, Adenovirus, Enterovirus, Cytomegalovirus, Human herpesvirus 6, Human immunodeficiency virus, hepatitis B virus, hepatitis C virus or Epstein-Barr virus infection; cerebrospinal fluid (CSF) findings resulted negative for bacterial and viral infections; electromyography (EMG) showed a normal pattern of the motor unit action potential (MUAP) waveform with normal values of F wave and only sporadic myopathic MUAPs were found; an extensive screen for autoantibodies related to autoimmune and neuromuscular disease was negative. In suspicion of a GVHD-related myositis, a biopsy from vastus lateralis muscle was performed showing necrotic and degenerating muscle fibres, basophilic regenerating fibres and inflammatory infiltrates predominantly around vessels (**Figure 1**).

Inflammatory cells were predominantly composed of CD3+ CD8+ T cells; some CD4+ T cells and a few CD68+ macrophages, CD20+ B cells and CD57+ natural killer cells were observed; only rare CD 138+ cells were present (**Figure 2**).

These findings indicated immune-mediated polymyositis; therefore the immunosuppression treatment was potentiated with methylprednisolone 30 mg/kg for three days, rituximab (105 mg/m<sup>2</sup> once weekly for four doses); tacrolimus was replaced with sirolimus because of its potential neurotoxicity. In the



**Figure 1. Light microscopy of muscle biopsy.** Hematoxylin and eosin stain shows necrotic, degenerating and regenerating muscle fibers (A) and a large inflammatory infiltrate around vessels (B). ATPase reactions showed normal differentiation and distribution of muscle fibers and no increase of perimysial or endomysial connective tissue was observed. All other histochemical stains were normal.



**Figure 2. Immunohistochemistry of muscle biopsy.** Serial muscle fiber sections (hematoxylin and eosin) showing mononuclear inflammatory cells (A) which are predominantly composed of CD8+ T cells (B); a few CD4+ T cells (C) and CD57+ NK cells (D), and rare CD68+ macrophages (E) and CD20+ B cells (F). Major histocompatibility complex (MHC) class I antigen was upregulated on the sarcolemma of many muscle fibers and membrane attack complex (MAC) deposits were detected on the wall of few capillaries.

following days the clinical conditions of the child improved, with a decrease in CK, CK-MB, AST, ALT and troponin values; she was weaned from mechanical ventilation after 25 days. In the following weeks the girl presented a progressive clinical improvement with complete normalisation of the neuromuscular disease in about two months. The girl was treated with sirolimus (ongoing), and low dose of prednisone (0,2 mg/kg/die) gradually tapered off over nine months.

Currently, after 15 months, the girl is asymptomatic in very good general conditions without any neuromuscular alteration. The values of CK-MB, AST, ALT and troponin are average while CK persists slightly abnormal (1.5 times above the normal upper range).

**Discussion.** Polymyositis is a sign of cGVHD<sup>1,10,12-15</sup> although not a frequent manifestation, the incidence

being approximately 3.4-7.7%.<sup>1,5</sup> Host-reactive donor lymphocytes are the cells responsible for muscle damage involving preferentially and symmetrically the proximal muscle groups. Most of the cases reported in the literature concern adults<sup>1,17</sup> and only a few cases are described in children.<sup>10-13</sup> This case is the earliest age of onset reported, and from a literature review it is the only one diagnosed among paediatric allogeneic HSCT performed from 2012 to 2018. It is interesting to point out that this case occurred in a patient with HLA allele mismatch on loci A, DRB1, DPB1 that induced to potentiate the regimen of GVHD prophylaxis with the use of post-transplant cyclophosphamide. Clinical features are similar to those of idiopathic polymyositis, involving bilateral muscular weakness of proximal muscles while lower extremities are less frequently involved.<sup>6</sup> Muscular pain is not always present whilst heart involvement has been reported.<sup>1,5</sup> In our patient, as reported in literature<sup>6,14</sup> the symptoms appeared after the tapering or withdrawal of immunosuppression therapy. Laboratory tests show elevated CK (5-50 times above normal) in most patients, as in our case, however CK may be normal or slightly increased in clinically stable patients.<sup>5,6</sup> Unlike idiopathic polymyositis the presence of myositis-specific antibodies is rarely positive.<sup>6</sup> EMG shows the typical myopathic pattern<sup>5</sup> although in some cases it may be normal,<sup>14</sup> as described in our patient. GVHD-related polymyositis has been reported to respond to corticosteroids alone or in combination with cyclosporine, mycophenolate mofetil, methotrexate or cyclophosphamide.<sup>14</sup> Due to the rarity of this manifestation and the complexity of differential diagnosis, biopsy has a key role in confirming the

diagnosis. The typical histopathology examination showed segmental muscle fibre necrosis, muscle fibre regeneration and mononuclear cell inflammation. Generally, immunohistochemistry shows cytotoxic CD8+ T donor cell infiltration of endomysium and CD4+ and CD8+ T cell infiltration of the perimysium.<sup>5</sup> We found B-lymphocytes (CD20+ cells) infiltration in the muscle that correlated with the abnormally high number of CD20+ cells on peripheral blood. This finding suggested a treatment based on the combination of high-dosed methylprednisolone together with rituximab, whereas tacrolimus was replaced by sirolimus because of some anecdotal cases of tacrolimus-related myositis.<sup>16</sup> A biopsy with B-cell infiltration has already been described in literature, and the therapy with rituximab has been shown to be effective in adult patients.<sup>17-19</sup> This case of cGVHD-related-polymyositis is the first described in a pediatric patient who was successfully treated with rituximab. A lower dose was used, if compared to other cases (105 mg/m<sup>2</sup> versus 375 mg/m<sup>2</sup>),<sup>20</sup> thus reducing the possible risks due to immunosuppression.

**Conclusions.** In conclusion, in a patient undergoing HSCT with myalgia and muscle weakness even without other signs of cGVHD, it is crucial to exclude a myopathy secondary to steroid treatment, a myasthenia gravis or a viral myopathy.<sup>20</sup> The cGVHD-related polymyositis is a rare condition, but it has to be suspected and confirmed with EMG and muscle biopsy.<sup>20</sup> This condition can be treated, in addition to steroid therapy, with rituximab, in particular if the muscle biopsy demonstrates B-cell infiltration.

## References:

- Ahn JS, Cho SH, Kim YK, Yang DH, Bae WK, Shim HJ et al. Polymyositis and myocarditis after donor lymphocyte infusion. *Int J Hematol.* 2009 Jul;90(1):113-116. Epub 2009 May 27. *Blood.* 2002 Aug 15;100(4):1192-200. <https://doi.org/10.1007/s12185-009-0332-3> PMID:19472035
- Zecca M, Prete A, Rondelli R, Lanino E, Balduzzi A, Messina C, Fagioli F et al. Po.AIEOP-BMT Group. Italian Association for Pediatric Hematology and Oncology-Bone Marrow Transplant. Chronic graft-versus-host disease in children: incidence, risk factors, and impact on outcome. *Blood.* 2002 Aug 15;100(4):1192-200. <https://doi.org/10.1182/blood-2001-11-0059> PMID:12149197
- Bertaina A, Zecca M, Buldini B, Sacchi N, Algeri M, Saglio F et al. Unrelated donor vs HLA-haploidentical  $\alpha\beta$  T-cell- and B-cell-depleted HSCT in children with acute leukemia. *Blood.* 2018 Dec 13;132(24):2594-2607. Epub 2018 Oct 22. <https://doi.org/10.1182/blood-2018-07-861575> PMID:30348653
- Sharaf N, Prayson RA. Relapsing polymyositis in chronic graft versus host disease. *J Clin Neurosci.* 2014 Nov;21(11):1964-5. <https://doi.org/10.1016/j.jocn.2014.03.025> PMID:24980629
- Grauer O, Wolff D, Bertz H, Greinix H, Kühl JS, Lawitschka A et al. Neurological manifestations of chronic graft-versus-host disease after allogeneic haematopoietic stem cell transplantation: report from the Consensus Conference on Clinical Practice in chronic graft-versus-host disease. *Brain.* 2010 Oct;133(10):2852-65. <https://doi.org/10.1093/brain/awq245> PMID:20846944
- Koepfen S1, Thirugnanasambanthan A, Koldehoff M. Neuromuscular complications after hematopoietic stem cell transplantation. *Support Care Cancer.* 2014 Sep;22(9):2337-41 <https://doi.org/10.1007/s00520-014-2225-0> PMID:24682581
- Lee SM1, Sumegi J, Villanueva J, Tabata Y, Zhang K, Chakraborty R, Sheng X, Clementi R, de Saint Basile G, Filipovich AH. Patients of African ancestry with hemophagocytic lymphohistiocytosis share a common haplotype of PRF1 with a 50delT mutation. *J Pediatr.* 2006 Jul;149(1):134-7. <https://doi.org/10.1016/j.jpeds.2006.03.003> PMID:16860143
- Benezech S, Walzer T, Charrier E, Heidelberg D, De Saint-Basile G, Bertrand Y, Belot A. Late-onset hemophagocytic lymphohistiocytosis with neurological presentation. *Clin Case Rep.* 2017 Sep 12;5(11):1743-1749. doi: 10.1002/ccr3.1135. eCollection 2017 Nov. <https://doi.org/10.1002/ccr3.1135> PMID:29152263 PMCID:PMC5676276
- Locatelli F, Jordan MB, Allen CE, Cesaro S, Rizzari C, Rao A et al. Safety and Efficacy of Emapalumab in Pediatric Patients with Primary Hemophagocytic Lymphohistiocytosis. *Blood* 2018 132:LBA-6). <https://doi.org/10.1182/blood-2018-120810>
- Pier N, Dubowitz V. Chronic graft versus host disease presenting with polymyositis. *Br Med J (Clin Res Ed).* 1983 Jun 25;286(6383):2024.

- <https://doi.org/10.1136/bmj.286.6383.2024>  
PMid:6409214 PMCID:PMC1548493
11. Anderson BA, Young PV, Kean WF, Ludwin SK, Galbraith PR, Anastassiades TP. Polymyositis in chronic graft vs host disease. A case report. *Arch Neurol*. 1982 Mar;39(3):188-90.  
<https://doi.org/10.1001/archneur.1982.00510150058015>  
PMid:7039565
  12. Tse S, Saunders EF, Silverman E, Vajsar J, Becker L, Meaney B. Myasthenia gravis and polymyositis as manifestations of chronic graft-versus-host-disease. *Bone Marrow Transplant*. 1999 Feb;23(4):397-9.  
<https://doi.org/10.1038/sj.bmt.1701575>  
PMid:10100585
  13. Klein R1, Franck P, Ehl S, Schmitt-Graeff A, Duffner U, Niemeyer CM. Polymyositis-an unusual presentation of cGvHD in children. *Pediatr Transplant*. 2007 Mar;11(2):225-7.  
<https://doi.org/10.1111/j.1399-3046.2006.00615.x>  
PMid:17300507
  14. Maillard-Lefebvre H, Morell-Dubois S, Lambert M, Charlanne H, Launay D, Hachulla E et al. Graft-versus-host disease-related polymyositis. *Clin Rheumatol*. 2010 Apr;29(4):431-33.  
<https://doi.org/10.1007/s10067-009-1350-5>  
PMid:20069327
  15. Michelis FV, Bril V, Lipton JH. A case report and literature review of chronic graft-versus-host disease manifesting as polymyositis. *Int J Hematol*. 2015 Jul;102(1):144-6. Epub 2015 Mar 3. Review.  
<https://doi.org/10.1007/s12185-015-1768-2>  
PMid:25732066
  16. Orlandi V, Campieri C, Mosconi G, D'Arcangelo GL, Feliciangeli G, Scolari MP et al. Tacrolimus-associated myositis: a case report in a renal transplant patient. *Transplant Proc*. 2004 Apr;36(3):708-10.  
<https://doi.org/10.1016/j.transproceed.2004.03.018>  
PMid:15110639
  17. Williams KM, Ostrow LW, Loeb DM, Chung T, Cohn RD, Corse AM et al. Immunohistochemistry of affected tissue may guide cGVHD treatment decisions. *Bone Marrow Transplant*. 2012 May;47(5):731-3.  
<https://doi.org/10.1038/bmt.2011.164>  
PMid:21927032 PMCID:PMC4251459
  18. Teshima T, Nagafuji K, Henzan H, Miyamura K, Takase K, Hidaka M et al. Rituximab for the treatment of corticosteroid-refractory chronic graft-versus-host disease. *Int J Hematol*. 2009 Sep;90(2):253-260.  
<https://doi.org/10.1007/s12185-009-0370-x>  
PMid:19543951
  19. Von Bonin M, Oelschlägel U, Radke J, Stewart M, Ehninger G, Bornhauser M et al. Treatment of chronic steroid-refractory graft-versus-host disease with low-dose rituximab. *Transplantation*. 2008 Sep 27;86(6):875-9.  
<https://doi.org/10.1097/TP.0b013e318183f662>  
PMid:18813113
  20. Jagasia MH, Greinix HT, Arora M, Williams KM, Wolff D, Cowen EW et al. National Institutes of Health Consensus Development Project on Criteria for Clinical Trials in Chronic Graft-versus-Host Disease: I. The 2014 Diagnosis and Staging Working Group report. *Biol Blood Marrow Transplant*. 2015 Mar;21(3):389-401.e1.  
<https://doi.org/10.1016/j.bbmt.2014.12.001>  
PMid:25529383 PMCID:PMC4329079