



Review

The Amyloid-Tau-Neuroinflammation Axis in the Context of Cerebral Amyloid Angiopathy

Pablo Cisternas ^{1,2}, Xavier Taylor ^{1,2}  and Cristian A. Lasagna-Reeves ^{1,2,*}

¹ Stark Neurosciences Research Institute, Indiana University School of Medicine, Indianapolis, IN 46202, USA; pcistern@iu.edu (P.C.); xtaylor@iu.edu (X.T.)

² Department of Anatomy, Cell Biology & Physiology, Indiana University School of Medicine, Indianapolis, IN 46202, USA

* Correspondence: clasagna@iu.edu; Tel.: +1-(317)-274-7830

Received: 30 November 2019; Accepted: 12 December 2019; Published: 14 December 2019



Abstract: Cerebral amyloid angiopathy (CAA) is typified by the cerebrovascular deposition of amyloid. Currently, there is no clear understanding of the mechanisms underlying the contribution of CAA to neurodegeneration. Despite the fact that CAA is highly associated with the accumulation of A β , other types of amyloids have been shown to associate with the vasculature. Interestingly, in many cases, vascular amyloidosis has been associated with an active immune response and perivascular deposition of hyperphosphorylated tau. Despite the fact that in Alzheimer's disease (AD) a major focus of research has been the understanding of the connection between parenchymal amyloid plaques, tau aggregates in the form of neurofibrillary tangles (NFTs), and immune activation, the contribution of tau and neuroinflammation to neurodegeneration associated with CAA remains understudied. In this review, we discussed the existing evidence regarding the amyloid diversity in CAA and its relation to tau pathology and immune response, as well as the possible contribution of molecular and cellular mechanisms, previously associated with parenchymal amyloid in AD and AD-related dementias, to the pathogenesis of CAA. The detailed understanding of the "amyloid-tau-neuroinflammation" axis in the context of CAA could open the opportunity to develop therapeutic interventions for dementias associated with CAA that are currently being proposed for AD and AD-related dementias.

Keywords: cerebral amyloid angiopathy; tau; neuroinflammation; amyloid

1. Introduction

Alzheimer's disease (AD), the most common form of dementia, is characterized by the extracellular deposition of parenchymal β -amyloid (A β), intracellular accumulation of tau as neurofibrillary tangles (NFTs), synaptic loss, and significant inflammation [1,2]. Cerebral amyloid angiopathy (CAA) is typified by the cerebrovascular deposition of amyloid and has a close molecular relationship with AD, but remains clinically distinct. Vascular amyloid accumulation is identified in an estimated 85%–95% of individuals with AD [3,4], positioning CAA as one of the strongest vascular contributors to age-related cognitive decline [5,6]. Despite this high prevalence, the severity of CAA is highly variable in AD and therefore does not seem to strongly depend on the severity of AD pathology (e.g., CERAD and Braak stages) [7–9]. The mechanisms responsible for CAA pathogenesis and its downstream effects on the brain are complex and not completely understood. As for the origin of amyloid in CAA, the smooth muscle cells were originally proposed as the source of cerebral amyloid. Nevertheless, the sole contribution of smooth muscle cells to CAA is made less likely by the existence of amyloid deposits in capillaries in CAA patients. Based on this, it has been proposed that the amyloid is indeed derived from neurons and is drained along the perivascular interstitial fluid pathway of the brain parenchyma and leptomeninges, depositing along the vessels [10,11]. This perivascular drainage impairment sets

in motion a self-reinforcing pathway by which worsening vascular amyloid accumulation leads to the activation of vascular injury pathways. This results in the impairment of vascular physiology, leading to a further increase in amyloid accumulation [12,13]. The damaged endothelium can produce proinflammatory cytokines that magnify neuroinflammation, glial activation, and secondary injury, leading to blood–brain barrier (BBB) breakdown [14]. Despite the fact that CAA is highly associated with the accumulation of A β [4], other types of amyloids have been shown to associate with the vasculature, suggesting that CAA should be considered as a group of biochemically and genetically diverse disorders unified by the accumulation of amyloid deposits in the walls of arterial blood vessels, and, in some cases, also in capillaries of the CNS parenchyma and leptomeninges [15–17]. Interestingly, in many cases, vascular amyloidosis is associated with severe neurofibrillary tau pathology, which is more pronounced around amyloid-laden blood vessels [18–20].

Over the past decades, a major focus of research has been on understanding the molecular and cellular connections between parenchymal amyloid, tau aggregation, and neuroinflammation, while the correlation between vascular amyloid pathology with tau aggregation and neuroinflammation has mainly been reported based on neuropathological observations.

In this review, we will summarize the existing evidence regarding the amyloid diversity in CAA and its relation to tau pathology and neuroinflammation, as well as discuss the possible contribution of molecular and cellular mechanisms, previously associated with parenchymal amyloid, to the pathogenesis of CAA.

2. The Diversity of Amyloid in CAA

Though CAA is defined by the accumulation of amyloid in the vasculature, distinct types of amyloids have been reported to deposit in blood vessels, as seen in Table 1. Broadly, there are A β -related CAAs and other amyloid-related CAAs [4,21–23]. In A β -CAA, the amyloidogenic forms of A β (A β ₄₀ and A β ₄₂) are produced from the processing of the 695 aa amyloid precursor protein (APP) by the sequential proteolytic cleavage of a β -secretase (BACE) and a γ -secretase-presenilin complex in what is called the amyloidogenic pathway, since it produces peptides that are prone to aggregate. This differs from the more physiological non-amyloidogenic pathway, where the sequential cleavage is produced by an α -secretase first and later by the γ -secretase-presenilin complex [24–26]. The transition from soluble to amyloidogenic nature of these A β peptides is explained by the conformational change given by the increase in the content of β -sheets in their structure, favoring their deposition as oligomers to finally form aggregated fibrils. The main type of A β accumulated in the vasculature is A β ₄₀ and to a lesser extent A β ₄₂ [3]. The vascular accumulation of amyloid species promotes the weakening of the blood vessel wall, challenging its integrity and leading to infarcts and hemorrhages [4,27]. This also causes smooth muscle degeneration and neurotoxicity [28].

Table 1. Sporadic and hereditary cerebral amyloid angiopathy (CAA) forms.

Amyloid	Gene	Precursor Protein	Mutation	Disease
A β	<i>APP</i>	Amyloid precursor protein	none	Sporadic CAA [21,22]
A β	<i>APP</i>	Amyloid precursor protein	E693Q	Hereditary Cerebral Hemorrhage with Amyloidosis Dutch type [29–32]
A β	<i>APP</i>	Amyloid precursor protein	E693K	Hereditary Cerebral Hemorrhage with Amyloidosis Italian type [33]
A β	<i>APP</i>	Amyloid precursor protein	E693G	Hereditary Cerebral Hemorrhage with Amyloidosis Arctic type [34]
A β	<i>APP</i>	Amyloid precursor protein	E693 Δ	Hereditary Cerebral Hemorrhage with Amyloidosis Osaka type [35,36]
A β	<i>APP</i>	Amyloid precursor protein	A692G	Hereditary Cerebral Hemorrhage with Amyloidosis Flemish type [37]
A β	<i>APP</i>	Amyloid precursor protein	D694N	Hereditary Cerebral Hemorrhage with Amyloidosis Iowa type [38]
A β	<i>APP</i>	Amyloid precursor protein	L705V	Hereditary Cerebral Hemorrhage with Amyloidosis Piedmont type [39]
A β	<i>APP</i>	Amyloid precursor protein	A713T	Hereditary Cerebral Hemorrhage with Amyloidosis Italian type [40,41]
A β	<i>APP</i>	Amyloid precursor protein	T714I	Hereditary Cerebral Hemorrhage with Amyloidosis Austrian type [42]
A β	<i>APP</i>	Amyloid precursor protein	T714A	Hereditary Cerebral Hemorrhage with Amyloidosis Iranian type [43]
ABri	<i>BRI2</i>	British Amyloid protein	799A>T	Familial British Dementia [18,44–47]
ADan	<i>BRI2</i>	Danish Amyloid protein	787_796dupTTTAATTGT	Familial Danish Dementia [18,45,46,48–50]
ACys	<i>CST3</i>	Cystatin C	L68Q	Hereditary Cerebral Hemorrhage with Amyloidosis Islandic type [51–53]
ATTR	<i>TTR</i>	Transthyretin	D18G	Meningovascular amyloidosis Hungarian variant [54–57]
ATTR	<i>TTR</i>	Transthyretin	V30G	Meningovascular amyloidosis Ohio variant [58–60]
ATTR	<i>TTR</i>	Transthyretin	Y69H	Meningovascular amyloidosis rare variant [61–64]
ATTR	<i>TTR</i>	Transthyretin	A25T	Meningovascular amyloidosis rare variant [65,66]
ATTR	<i>TTR</i>	Transthyretin	V30M	Meningovascular amyloidosis rare variant [67,68]
ATTR	<i>TTR</i>	Transthyretin	T49P	Meningovascular amyloidosis rare variant [69]
ATTR	<i>TTR</i>	Transthyretin	L58R	Meningovascular amyloidosis rare variant [70]
ATTR	<i>TTR</i>	Transthyretin	F64S	Meningovascular amyloidosis rare variant [71]
ATTR	<i>TTR</i>	Transthyretin	Y114C	Meningovascular amyloidosis rare variant [72]
ATTR	<i>TTR</i>	Transthyretin	L12P	Meningovascular amyloidosis rare variant [73]
ATTR	<i>TTR</i>	Transthyretin	G53R	Meningovascular amyloidosis rare variant [74]
AGel	<i>GSN</i>	Gelsolin	D187N or D187Y	Hereditary gelsolin amyloidosis or familial amyloidosis Finnish type [75–77]
PrPSc	<i>PRNP</i>	Prion protein	Y145stop	Gerstmann–Sträussler–Scheinker syndrome variant [20]
PrPSc	<i>PRNP</i>	Prion protein	Y163stop	Gerstmann–Sträussler–Scheinker syndrome variant [78]

2.1. A β Amyloid in CAA

A β -CAA can be divided into two main groups: a sporadic type (SCAA) and a hereditary type. SCAA constitutes the most common and the majority of the cases of A β -CAAs. In these, an

age-related failure of elimination of amyloidogenic A β peptides is the most important risk factor for their accumulation in the vasculature [79]. On the contrary, in hereditary A β -CAAs, specific mutations are directly related with the vascular accumulation of A β . These are the cases of several rare familial genetic conditions termed hereditary hemorrhages with amyloidosis, caused by a mutation on the *APP* gene located on chromosome 21 [21,22,80,81]. The most studied of these is the Dutch type, where the substitution of glutamic acid for glutamine at codon 693 leads to the production of an aberrant A β_{40} that aggregates and accumulates rapidly in arterioles of meninges and brain cortex [29–32]. Three other less studied mutations of this same codon are the Italian, the Arctic, and the Osaka types. The first one presents a substitution of glutamic acid for lysine and the second for glycine, both upregulating an aberrant form of A β_{40} [33,34]. In the third one, the lack of a glutamate as a result of a whole deletion of codon 693 leads to the production of highly oligomeric A β_{40} and A β_{42} [35,36]. Mutations on other codons are reported to cause synthesis of abnormal forms of A β as well. An alanine replacement by glycine at codon 692 is present in the Flemish type. In this case, the change affects the cleavage site of the α -secretase on APP, shifting it towards β -secretase processing, upregulating both A β_{40} and A β_{42} [37]. On the other hand, in the Iowa type, a substitution of asparagine for aspartic acid at codon 694 causes an increase only of A β_{40} [38]. A substitution of leucine for valine at codon 705 is identified as the Piedmont variant, showing severe A β_{40} and A β_{42} vascular deposits [39]. Another Italian type was reported affecting codon 713, where the replacement of alanine for threonine causes extensive A β_{40} aggregation [40,41]. Additionally, codon 714 can be differently mutated giving rise to the Austrian and a rare Iranian type. In the first case, the mutation presents a change in a threonine for an isoleucine, directly affecting the γ -secretase cleavage site, increasing the A β_{42} /A β_{40} ratio [42]. In the second case, the substitution is for alanine, and is likely to alter APP processing such that more A β_{42} is produced [43].

2.2. Non-A β Amyloid in CAA

Although the A β peptide is by far the most common amyloid accountable for the vascular accumulation and damage, other types of amyloid have been shown to cause the same effects in hereditary types of CAA [21,22]. This is the case of Familial British Dementia (FBD) and Familial Danish Dementia (FDD) [18,44,48]. Both conditions show progressive loss of cognitive functions, dementia and ataxia. Neuropathologically, FDD closely resembles FBD regarding its vascular amyloidosis; however, parenchymal deposits found in the hippocampus of patients with FDD were Congo red and Thioflavine-S (ThioS)-negative [19]. Interestingly, brains from affected individuals present tau aggregation [45]. Common to both FBD and FDD is the involvement of mutations on the *BRI2* gene on chromosome 13 that encodes the membrane-bound 266 aa BRI₂ protein. Its physiological cleavage by protein convertases generates the soluble 23 aa BRI₂-23 peptide [18,44,46]. However, two different mutations on the *BRI2* gene will lead to the production of a mutated form of BRI₂. In individuals affected by FBD, a point mutation eliminates the normal stop codon on the gene. In FDD, individuals show a 10-nucleotide duplication causing a frameshift. In both cases, there is a read extension and a subsequent addition of 11 aa. The processing of these abnormal 277 aa mutated Bri₂ proteins produce the 34 aa ABri and ADan amyloids in FBD and FDD respectively, both of which are highly amyloidogenic and neurotoxic [22,46,47,49,82]. In addition, it has been reported that ADan can be deposited in combination with A β in blood vessels of the brain parenchyma [44]. In the case of cerebral hemorrhage with amyloidosis of the Islandic type (HCHWA-I), the nature of extensive deposits of amyloid fibrils is the accumulation of the mutated form of the cystatin C transmembrane protein [51,52]. The mutation corresponds to a single nucleotide substitution at codon 68 of the *CST3* gene on chromosome 20 [51,83]. Remarkably, immunohistochemical analysis of brains of patients with AD revealed that this mutated peptide colocalizes with A β in parenchymal and vascular amyloid deposits [53]. Other mutated proteins that can accumulate in an amyloidogenic fashion are transthyretins (TTRs), gelsolin, and the prion protein (PrP) [21,22]. Several different mutations, see Table 1, on the *TTR* gene on chromosome 18 produce an amyloidogenic form of the TTR protein that aggregates extensively in leptomeninges [58].

This condition is termed meningo-vascular amyloidosis [22,80]. Interestingly, one of the cases analyzed showed distinctive aggregates of phospho-tau subjacent to TTR amyloid deposits in all regions of the neocortex and primary motor and striate cortices, indicating a potential link between TTR amyloid and cortical tauopathy [61]. In hereditary gelsolin amyloidosis, also called familial amyloidosis Finnish type (FAF), a mutation in the *GSN* gene on chromosome 9 causes gelsolin to be abnormally cleaved, generating several small fragments with amyloidogenic properties [75–77]. Finally, the amyloidogenic variant of the PrP (PrP^{Sc}) is caused by a single point mutation at codon 145 in the *PRNP* gene on chromosome 20, resulting in a premature stop codon that alters its glycosylation and signal sequence sites [20], leading to an increase of β -sheet structures in the protein [84]. These characteristics allow PrP^{Sc} to increase its propensity to aggregate in the vasculature [85]. A mutation at codon 163 has also been reported to produce a PrP^{Sc} [22,78]. Overall, these observations suggest that CAA is a heterogeneous group of CNS disorders, characterized by the dynamic accumulation of different amyloid species in the vasculature.

3. Perivascular Tau Aggregation and Its Interplay with Cerebrovascular Damage and CAA

Pathological aggregation of the microtubule-associated protein tau and the preponderance of NFTs or other inclusions containing tau are defining histopathological features of AD and many neurodegenerative diseases collectively known as tauopathies [86]. Interestingly, accumulation of tau has been detected in cerebrovascular pathologies associated with endothelial dysfunction and cognitive impairment [87,88]. Noteworthy, several studies have suggested that pathological changes of tau in neurons can impact brain endothelial cell biology, altering the integrity of the brain's microvasculature [89,90]. For instance, it has been shown that vessel wall remodeling of leptomeningeal arteries is an early-onset, tau pathology-dependent process, which may potentially contribute to downstream CAA-dependent microvascular pathology in AD patients [90]. Even more, other studies have demonstrated an increase of BBB permeability and the accumulation of tau oligomers in the cerebral microvasculature of human patients with progressive supranuclear palsy (PSP) [91,92], emphasizing the role of tau aggregates in the functional and structural integrity of the cerebral vasculature. In a similar fashion, tau-overexpressing mice develop changes to blood vessels including abnormal, spiraling morphologies, reduced blood vessel diameter, and increased overall blood vessel density in the cortex [89]. In a different mouse model for tauopathies, BBB dysfunction emerges at the same time that perivascular tau emerges around major hippocampal blood vessels. However, when tau expression is suppressed, BBB integrity is preserved, suggesting that the BBB can be stabilized in a tauopathic brain by reducing tau levels [93]. Overall, these studies suggest a strong relation between tau pathology and vascular damage, and how tau aggregation is not a unidirectional event where vascular damage initiates a series of events that triggers tau aggregation, but is rather a vicious cycle where tau pathology enhances vascular damage.

In many cases, vascular amyloidosis is accompanied by significant perivascular tau pathology [19,20,94], supporting a unifying pathological mechanism in which vascular accumulation of amyloidogenic peptides triggers a complex pathological cascade leading to tau accumulation and neurodegeneration. However, it remains to be determined whether abnormal tau phosphorylation is the consequence of CAA or an independent disease characteristic. Recently, we biochemically demonstrated an increase of hyperphosphorylated forms of tau in the Tg-FDD mouse model characterized by vascular deposition of ADan amyloid [95]. This increase was only observed in certain phospho-tau epitopes, but not others that have been associated with tau NFTs in AD, suggesting that the process of tau hyperphosphorylation associated with CAA deposits could be different from the hyperphosphorylation of tau associated with parenchymal deposition of amyloid [96]. In the same study, we observed how these perivascular tau aggregates in the vicinity of vascular amyloid were associated with activated astrocytes [95]. Interestingly, astrocytes play a key role in maintaining the BBB via astrocytic endfeet directly opposed to vascular endothelial cells [96], and tau has been shown to accumulate in these endfeet in tauopathies [97,98], including perivascular astrocytic tau deposits in CAA patients [19].

Even more, the presence of perivascular tau aggregates has been reported in patients with chronic trauma encephalopathy (CTE) [99,100]. These tau deposits in CTE were also associated with activated astrocytes [99]. These results suggest that vascular damage, independent of its cause (amyloid accumulation or CTE), could induce an astrocytic response that triggers tau aggregation.

Previous studies have shown how endogenous WT tau appears to be required for parenchymal A β -amyloid accumulation and ApoE4 to cause synaptic, network, and cognitive deficits in mouse models of AD [101–103]. Significantly, the removal of endogenous tau expression in a mouse model for Parkinson's disease, characterized by the aggregation of mutant alpha-synuclein, completely ameliorates cognitive dysfunction and concurrent synaptic deficits without affecting alpha-synuclein expression or accumulation of selected toxic alpha-synuclein oligomers [104]. Tau ablation has also been shown to attenuate motor abnormalities in a Huntington's disease (HD) mouse model [105] and prevent deficits in spatial learning and memory after repeated mild frontal impact in WT mice [106]. Furthermore, tau reduction has the ability to block epileptogenesis of diverse causes, including epileptic activity triggered by pharmacological blockade of GABAA channels [104,107], genetic ablation of the voltage-gated potassium channel subunit Kv1.1 [108], depletion of ethanolamine kinase or of the K⁺-Cl⁻ cotransporter [108], or depletion of the voltage-gated sodium channel subunit Nav1.1 [109]. The mechanisms underlying these beneficial effects of tau reduction remain to be determined [86]. New evidence suggests that tau could be involved in a common pathway for neurodegeneration triggered by cerebrovascular abnormalities and parenchymal amyloid pathologies [88]. Recently, a novel study showed how exposing mice to a salt-rich diet not only leads to cognitive dysfunction associated with a nitric oxide deficit in cerebral endothelial cells and cerebral hypoperfusion, but also induces hyperphosphorylation of tau [110]. Remarkably, the authors did not observe salt-induced cognitive impairment in tau-null mice or in mice treated with anti-tau antibodies, despite the persistent cerebral hypoperfusion and neurovascular dysfunction [110].

Thus, considering the dependency of parenchymal amyloid for tau to exert neurotoxicity and the relevance of tau in several pathogenesis associated with neurovascular dysfunction, it is feasible to suggest that vascular amyloid would also depend on tau to trigger neurodegeneration and that partial tau reduction could be considered a feasible approach for the treatment of dementias associated with CAA.

4. The Implication of AD Immune-Risk Factors and Glial Response in CAA

The aggregation and accumulation of vascular amyloid has long been recognized as a major contributor to neuroinflammation, playing a fundamental role in the pathogenesis of AD. However, the majority of studies addressing this issue have focused on parenchymal amyloid deposition with little attention given to CAA [111–114]. Data from human patients and in vivo models for CAA suggest that damage to vessel walls activates the endothelium, facilitates the infiltration of monocytes/macrophages and incites glial reactivity, increasing the production of pro-inflammatory cytokines [115–119]. Novel genetic studies suggest that glial reactivity and innate immune cell activation may drive AD pathogenesis through a vascular-related mechanism [120]. Given the relationship between neuroinflammation and vascular damage, it is imperative to understand in detail the role of neuroinflammatory pathways associated with CAA pathogenesis.

The neurovascular unit (NVU) is a complex structure organized by endothelial cells, intimately associated with pericytes and astrocytic endfeet to form the BBB. Parenchymal cells including excitatory neurons, regulatory interneurons and microglia actively interact with the NVU [121]. As central components of the NVU, pericytes represent the first line of immunological defense as antigen-presenting cells, playing a pivotal role in the maintenance of the BBB and microvascular stability. They also participate in capillary constriction and dilation, regulating cerebral blood flow, immune cell entry, and clearance of macromolecules from the brain's interstitial fluid [122,123]. When CAA occurs, pericytes display degenerative features influencing BBB breakdown, microaneurysms, neuroinflammation, and neurodegeneration [124–127]. When exposed to A β ₄₀, pericytes exhibit an

increase in the activity of caspases-3 and -7, reducing their viability and promoting tau pathology that develops into early neuronal loss and cognitive changes [124]. Alongside pericytes, perivascular macrophages (PVM) are important immunoregulatory cells performing phagocytosis and responding to transient CNS inflammation [128]. PVM are distinguished from microglia by their expression of CD36, CD206, and acid phosphatase. They have a high rate of turnover and are involved in the movement of solutes, infectious agents and immune cells from the blood to the brain [129–131]. The depletion of PVM by directly injecting clodronate, a compound used to study innate responses to CNS injuries, into the left lateral ventricle of four-month-old TgCRND8 mice results in a significant increase in CAA in cortical and leptomeningeal blood vessels [132]. On the other hand, the sustained stimulation of PVM by injecting chitin, a long-chain polymer of N-Acetylglucosamine, caused a significant reduction of ThioS-labeled cortical blood vessels and CAA load [133,134]. It has been suggested that PVM requires the C-C chemokine receptor type 2 (CCR2), a receptor involved in the regulation of macrophage migration and infiltration, to remove amyloid from the brain, since APP^{swE} CCR2^{-/-} mice showed a drastic impairment in A β clearance and amplified CAA [135].

4.1. Microgliosis in CAA

Besides PVM, microglia are also important regulators of neuroinflammation, releasing a variety of proinflammatory and cytotoxic products in response to cerebral insult or injury. In AD patients and AD mouse models, microglia clusters around plaques and vascular amyloid, moving toward newly formed plaques within 24 h of their formation as well as toward existing plaques [136,137], displaying an activated phenotype capable of producing cytokines and chemokines such as IL-1, IL-6, TNF- α , TGF- β 1, TGF- β 2, MIP-1 α , and MCP-1, enriching the brain's neuroinflammatory profile [138]. Several studies have investigated the targeted elimination of microglial in 5xFAD mice through inhibition of colony stimulating factor 1 receptor (CSF1R), a microglial chemokine receptor, and showed that chronic microglial elimination at advanced stages of pathology does not alter amyloid- β levels or plaque load; however, it does rescue dendritic spine loss and prevent neuronal loss, as well as decrease overall neuroinflammation [139]. Surprisingly, elimination of microglia in the initial stages of the disease, during the plaque-forming period, appears to play a role in the pathogenesis of CAA as the sustained elimination of microglia parallels the loss of parenchymal plaque deposition and results in an immense shift in CAA pathology suggesting one function of microglia in the normal brain is to protect from CAA [140]. Numerous studies have focused on targeting plaque elimination through passive immunization and opsonization by microglia/macrophages through the peripheral administration of anti-A β antibodies. These studies have shown potential beneficial effects on plaque clearance and cognitive improvement; however, there are also toxic effects such as CAA-associated hemorrhage [141–149]. Additionally, the targeting of certain scavenger receptors expressed in innate immune cells and cerebral blood vessels has shown to have therapeutic effects for CAA. This is the case of CD36, a critical innate immune receptor present in endothelial cells and microglia/macrophages, involved in a key signaling pathway through which A β exerts its deleterious vascular effects through the production of reactive oxygen species. APP^{swE} mice with a genetic deletion of CD36 showed reduced CAA burden, improved neurovascular function, reduced smooth muscle cell fragmentation, a selective reduction in A β ₄₀ plaque load leaving A β ₄₂ amyloid levels unchanged, and improved cognitive performance, suggesting improved cerebrovascular health is able to preserve cognitive function irrespective of parenchymal amyloid burden [150].

4.2. Astrogliosis in CAA

At the same time, astrocytes also have the ability to respond to and influence immune and inflammatory responses following insults such as excitotoxicity, ischemia, apoptosis, necrosis, and inflammatory cues. This is achieved by undergoing a pronounced transformative state called 'reactive astrogliosis', regulating inflammatory responses that can be either neuroprotective or neurotoxic and participating in migratory, phagocytic, and proteolytic activity [151–156]. The interplay between

apolipoprotein E (ApoE), A β , and astrocytes has gained important attention as ApoE, the most abundant apolipoprotein in the brain, is produced by astrocytes and has been widely confirmed to influence lipid metabolism and the processing, accumulation, and clearance of A β . Additionally, the ApoE4 allele mutation is the strongest genetic risk factor for both AD and CAA [157–159]. ApoE-deficient astrocytes lose their ability to internalize and degrade deposited A β peptides [160], with evidence suggesting that A β ₄₀ is internalized in vivo preferentially by astrocytes, not microglia [161,162]. The role of ApoE in CAA pathogenesis has gained important attention as it was observed that APP^{swE} mice expressing human ApoE4 show substantial CAA pathology, with very little parenchymal plaque deposition, as well as an early increase in the A β ₄₀/42 ratio, demonstrating that once A β fibrillogenesis occurs, ApoE4 expression results in a shift in the amyloid deposition from parenchyma to the vasculature [163]. In addition to ApoE, immunohistochemistry from human AD cases has also revealed a relationship of amyloid with apolipoprotein J or clusterin (ApoJ or CLU) and apolipoprotein A-I (ApoA-I), both with implications in CAA pathology [164]. CLU is the second major apolipoprotein produced by astrocytes, having roles in the aggregation, toxicity and BBB transport of A β , suggesting a strong role in CAA regulating the balance between A β deposition and clearance [165,166]. Additionally, loss of CLU in APP/PS1 mice results in a marked decrease in plaque deposition in the brain parenchyma and a striking increase in CAA, suggesting that the absence of CLU shifts A β to perivascular drainage pathways, resulting in fewer parenchymal plaques. To this extent, it was observed that adding CLU exogenously reduces A β ₄₀ and A β ₄₂ interactions with cerebral vessels [166]. ApoA-I has also been linked to AD pathology, binding to circulating A β peptides and occasionally associating with senile plaques [164,167]. Complete loss of ApoA-I increases cortical and hippocampal CAA pathology and astrogliosis in APP/PS1 mice, boosting both neuro and vascular inflammatory markers, specifically IL-1 β , PDGFR β , GFAP, and ICAM-1. These mice also showed an increase in GFAP-positive astrocytes associated with the cerebrovasculature [168]. ApoA-I could be an interesting target for a CAA-directed therapy as it was observed that APP/PS1 mice overexpressing ApoA-I or injection of ApoA-I reduced both astrogliosis and cerebral amyloid burden. Some groups have already begun to evaluate the potential benefits of ApoA-I mimetics in AD, observing benefits with respect to astrogliosis, amyloid pathology, CAA, and whole brain neuroinflammation [169–171]. Additionally to the aforementioned proteins, several AD genetic risk factors are immune-related genes [172–174]. Again, the presiding focus pertains to the relationship of these genes to parenchymal amyloid, with little consideration to vascular amyloid deposition. For instance, TREM2, one of the most studied AD-immune risk factors, has always been analyzed in the context of parenchymal amyloid [175–179]. This is also the case for genes such as *CR1*, *ABCA7*, *CD33*, *MEF2C*, *HLA-DRB1/DRB5*, *TRIP4*, *MS4A*, *EPHA1*, and *SPI1* [180,181]. Interestingly, recent genetic association studies of AD and other dementias have established correlations between specific risk factors such as *ABCA7*, *CR1*, *FERMT2*, *NME8*, *SLC24A4*, *SORL1*, *ZCWPW1*, and *GALNT7* to CAA, with *ABCA7* and *CR1* having the strongest association [182], enhancing the necessity of further cellular and molecular studies to dissect this relationship in detail.

5. Conclusions

Tau pathology and neuroinflammation have been identified as major contributors of neurodegeneration associated with amyloid deposits in AD and AD-related dementias. This contribution to amyloid pathology has been extensively studied in vivo utilizing animal models characterized by the accumulation of extra- or intracellular accumulation of parenchymal amyloid [103,104,179,183–186]. However, not many cellular and molecular studies have been performed to determine the role of tau and neuroinflammation in dementias associated with vascular amyloid accumulation, despite the fact that numerous pathological studies have suggested a preponderant neuroinflammatory response and perivascular tau aggregation in patients and in vivo models for CAA [19,50,95,118,187,188]. In this review, we discussed novel studies that link tau aggregation and neuroinflammation to neurovascular pathologies such as CAA and suggest how the “amyloid–tau–neuroinflammation” axis that has been studied in extensive detail in the context of

parenchymal amyloid needs to be dissected in the context of vascular amyloid deposition, as seen in Figure 1. Further studies on the involvement of tau and neuroinflammation on dementias associated with CAA could open the opportunity to develop therapeutic interventions for CAA that are currently being proposed for AD and AD-related dementias [183–185], as seen in Figure 1.

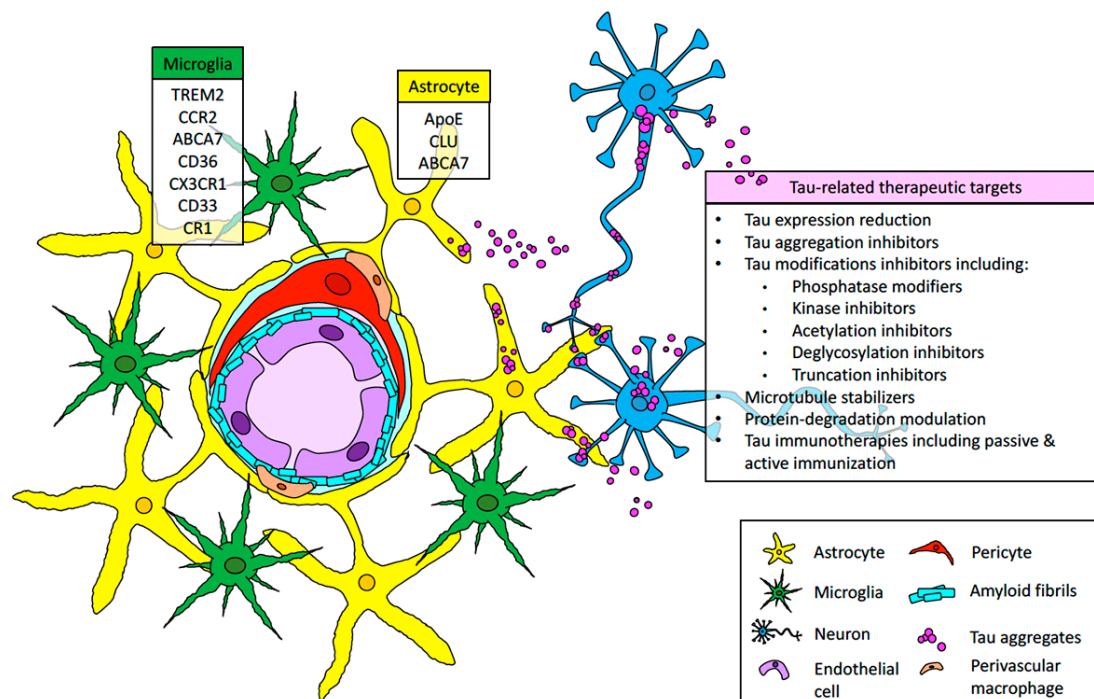


Figure 1. The amyloid-tau-neuroinflammation axis in the context of cerebral amyloid angiopathy (CAA). Amyloid accumulates in the vasculature, causing a destabilization of the neurovascular unit, translated in endothelial damage, pericyte decay, and perivascular macrophage, astrocyte, and microglial reaction. These series of events leads to neuroinflammation. Additionally, tau aggregates in astrocytes and neurons could contribute to neuroinflammation and neurodegeneration observed in CAA. A number of immune-related genes previously associated with AD and the inclusion of tau-related events could be signaled as possible therapeutic targets and a useful tool to contain the detrimental consequences of CAA.

Author Contributions: Conceptualization: C.A.L.-R., P.C. and X.T.; Funding Acquisition: C.A.L.-R.; Writing—Original Draft: C.A.L.-R., P.C. and X.T.; Writing—Review and editing: C.A.L.-R., P.C. and X.T. All authors read and approved the final manuscript.

Funding: This research was funded by the NIH/NINDS (grant number K22NS092688), the NIH/NIA (grant number R01AG059639) and the Alzheimer’s association (grant number AARGD-591887).

Acknowledgments: We thank Abigail Perkins for her suggestions and critical reading of the manuscript.

Conflicts of Interest: The authors declare no conflict of interest.

References

1. Karch, C.M.; Cruchaga, C.; Goate, A.M. Alzheimer’s disease genetics: From the bench to the clinic. *Neuron* **2014**, *83*, 11–26. [[CrossRef](#)] [[PubMed](#)]
2. Citron, M. Alzheimer’s disease: Strategies for disease modification. *Nat. Rev. Drug Discov.* **2010**, *9*, 387–398. [[CrossRef](#)] [[PubMed](#)]
3. Attems, J. Sporadic cerebral amyloid angiopathy: Pathology, clinical implications, and possible pathomechanisms. *Acta Neuropathol.* **2005**, *110*, 345–359. [[CrossRef](#)] [[PubMed](#)]
4. Biffi, A.; Greenberg, S.M. Cerebral amyloid angiopathy: A systematic review. *J. Clin. Neurol.* **2011**, *7*, 1–9. [[CrossRef](#)]

5. Viswanathan, A.; Greenberg, S.M. Cerebral amyloid angiopathy in the elderly. *Ann. Neurol.* **2011**, *70*, 871–880. [[CrossRef](#)]
6. Boulouis, G.; Charidimou, A.; Greenberg, S.M. Sporadic Cerebral Amyloid Angiopathy: Pathophysiology, Neuroimaging Features, and Clinical Implications. *Semin. Neurol.* **2016**, *36*, 233–243. [[CrossRef](#)]
7. Attems, J.; Jellinger, K.A. Only cerebral capillary amyloid angiopathy correlates with Alzheimer pathology—A pilot study. *Acta Neuropathol.* **2004**, *107*, 83–90. [[CrossRef](#)]
8. Tian, J.; Shi, J.; Bailey, K.; Mann, D.M.A. Negative association between amyloid plaques and cerebral amyloid angiopathy in Alzheimer's disease. *Neurosci. Lett.* **2003**, *352*, 137–140. [[CrossRef](#)]
9. Xu, D.; Yang, C.; Wang, L. Cerebral amyloid angiopathy in aged Chinese: A clinico-neuropathological study. *Acta Neuropathol.* **2003**, *106*, 89–91. [[CrossRef](#)]
10. Weller, R.O.; Massey, A.; Newman, T.A.; Hutchings, M.; Kuo, Y.M.; Roher, A.E. Cerebral amyloid angiopathy: Amyloid beta accumulates in putative interstitial fluid drainage pathways in Alzheimer's disease. *Am. J. Pathol.* **1998**, *153*, 725–733. [[CrossRef](#)]
11. Weller, R.O.; Subash, M.; Preston, S.; Mazanti, I.; Carare, R. Perivascular drainage of amyloid-beta peptides from the brain and its failure in cerebral amyloid angiopathy and Alzheimer's disease. *Brain Pathol.* **2008**, *18*, 253–266. [[CrossRef](#)] [[PubMed](#)]
12. Hawkes, C.A.; Härtig, W.; Kacza, J.; Schliebs, R.; Weller, R.O.; Nicoll, J.A.; Carare, R.O. Perivascular drainage of solutes is impaired in the ageing mouse brain and in the presence of cerebral amyloid angiopathy. *Acta Neuropathol.* **2011**, *121*, 431–443. [[CrossRef](#)] [[PubMed](#)]
13. Arbel-Ornath, M.; Hudry, E.; Eikermann-Haerter, K.; Hou, S.; Gregory, J.L.; Zhao, L.; Betensky, R.A.; Frosch, M.P.; Greenberg, S.M.; Bacsikai, B.J. Interstitial fluid drainage is impaired in ischemic stroke and Alzheimer's disease mouse models. *Acta Neuropathol.* **2013**, *126*, 353–364. [[CrossRef](#)] [[PubMed](#)]
14. Chodobski, A.; Zink, B.J.; Szmydynger-Chodobska, J. Blood-brain barrier pathophysiology in traumatic brain injury. *Transl. Stroke Res.* **2011**, *2*, 492–516. [[CrossRef](#)]
15. Cadavid, D.; Mena, H.; Koeller, K.; Frommelt, R.A. Cerebral beta amyloid angiopathy is a risk factor for cerebral ischemic infarction. A case control study in human brain biopsies. *J. Neuropathol. Exp. Neurol.* **2000**, *59*, 768–773. [[CrossRef](#)]
16. Greenberg, S.M. Cerebral amyloid angiopathy and dementia: Two amyloids are worse than one. *Neurology* **2002**, *58*, 1587–1588. [[CrossRef](#)]
17. Natte, R.; Maat-Schieman, M.L.; Haan, J.; Bornebroek, M.; Roos, R.A.; Van Duinen, S.G. Dementia in hereditary cerebral hemorrhage with amyloidosis-Dutch type is associated with cerebral amyloid angiopathy but is independent of plaques and neurofibrillary tangles. *Ann. Neurol.* **2001**, *50*, 765–772. [[CrossRef](#)]
18. Garringer, H.J.; Murrell, J.; D'Adamio, L.; Ghetti, B.; Vidal, R. Modeling familial British and Danish dementia. *Brain Struct. Funct.* **2010**, *214*, 235–244. [[CrossRef](#)]
19. Vidal, R.; Calero, M.; Piccardo, P.; Farlow, M.R.; Unverzagt, F.W.; Méndez, E.; Jiménez-Huete, A.; Beavis, R.; Gallo, G.; Gomez-Tortosa, E.; et al. Senile dementia associated with amyloid beta protein angiopathy and tau perivascular pathology but not neuritic plaques in patients homozygous for the APOE-epsilon4 allele. *Acta Neuropathol.* **2000**, *100*, 1–12. [[CrossRef](#)]
20. Ghetti, B.; Piccardo, P.; Spillantini, M.G.; Ichimiya, Y.; Porro, M.; Perini, F.; Kitamoto, T.; Tateishi, J.; Seiler, C.; Frangione, B.; et al. Vascular variant of prion protein cerebral amyloidosis with tau-positive neurofibrillary tangles: The phenotype of the stop codon 145 mutation in PRNP. *Proc. Natl. Acad. Sci. USA* **1996**, *93*, 744–748. [[CrossRef](#)]
21. Revesz, T.; Holton, J.L.; Lashley, T.; Plant, G.; Rostagno, A.; Ghiso, J.; Frangione, B. Sporadic and familial cerebral amyloid angiopathies. *Brain Pathol.* **2002**, *12*, 343–357. [[CrossRef](#)] [[PubMed](#)]
22. Revesz, T.; Holton, J.L.; Lashley, T.; Plant, G.; Frangione, B.; Rostagno, A.; Ghiso, J. Genetics and molecular pathogenesis of sporadic and hereditary cerebral amyloid angiopathies. *Acta Neuropathol.* **2009**, *118*, 115–130. [[CrossRef](#)] [[PubMed](#)]
23. Kumar-Singh, S. Hereditary and sporadic forms of abeta-cerebrovascular amyloidosis and relevant transgenic mouse models. *Int. J. Mol. Sci.* **2009**, *10*, 1872–1895. [[CrossRef](#)] [[PubMed](#)]
24. Chen, G.F.; Xu, T.H.; Yan, Y.; Zhou, Y.R.; Jiang, Y.; Melcher, K.; Xu, H.E. Amyloid beta: Structure, biology and structure-based therapeutic development. *Acta Pharm. Sin.* **2017**, *38*, 1205–1235. [[CrossRef](#)] [[PubMed](#)]

25. Kirkwood, C.M.; Ciuchta, J.; Ikonovic, M.D.; Fish, K.N.; Abrahamson, E.E.; Murray, P.S.; Klunk, W.E.; Sweet, R.A. Dendritic spine density, morphology, and fibrillar actin content surrounding amyloid-beta plaques in a mouse model of amyloid-beta deposition. *J. Neuropathol. Exp. Neurol.* **2013**, *72*, 791–800. [[CrossRef](#)] [[PubMed](#)]
26. Kang, J.; Lemaire, H.G.; Unterbeck, A.; Salbaum, J.M.; Masters, C.L.; Grzeschik, K.H.; Multhaup, G.; Beyreuther, K.; Muller-Hill, B. The precursor of Alzheimer's disease amyloid A4 protein resembles a cell-surface receptor. *Nature* **1987**, *325*, 733–736. [[CrossRef](#)] [[PubMed](#)]
27. Wisniewski, T.; Ghiso, J.; Frangione, B. Peptides homologous to the amyloid protein of Alzheimer's disease containing a glutamine for glutamic acid substitution have accelerated amyloid fibril formation. *Biochem. Biophys. Res. Commun.* **1991**, *180*, 1528. [[CrossRef](#)]
28. Kumar-Singh, S. Cerebral amyloid angiopathy: Pathogenetic mechanisms and link to dense amyloid plaques. *Genes Brain Behav.* **2008**, *7* (Suppl. 1), 67–82. [[CrossRef](#)]
29. Maat-Schieman, M.L.; van Duinen, S.G.; Bornebroek, M.; Haan, J.; Roos, R.A. Hereditary cerebral hemorrhage with amyloidosis-Dutch type (HCHWA-D): II—A review of histopathological aspects. *Brain Pathol.* **1996**, *6*, 115–120. [[CrossRef](#)]
30. Bornebroek, M.; Haan, J.; Maat-Schieman, M.L.; Van Duinen, S.G.; Roos, R.A. Hereditary cerebral hemorrhage with amyloidosis-Dutch type (HCHWA-D): I—A review of clinical, radiologic and genetic aspects. *Brain Pathol.* **1996**, *6*, 111–114. [[CrossRef](#)]
31. Levy, E.; Carman, M.D.; Fernandez-Madrid, I.J.; Power, M.D.; Lieberburg, I.; van Duinen, S.G.; Bots, G.T.; Luyendijk, W.; Frangione, B. Mutation of the Alzheimer's disease amyloid gene in hereditary cerebral hemorrhage, Dutch type. *Science* **1990**, *248*, 1124–1126. [[CrossRef](#)] [[PubMed](#)]
32. Miravalle, L.; Tokuda, T.; Chiarle, R.; Giaccone, G.; Bugiani, O.; Tagliavini, F.; Frangione, B.; Ghiso, J. Substitutions at codon 22 of Alzheimer's abeta peptide induce diverse conformational changes and apoptotic effects in human cerebral endothelial cells. *J. Biol. Chem.* **2000**, *275*, 27110–27116. [[PubMed](#)]
33. Bugiani, O.; Giaccone, G.; Rossi, G.; Mangieri, M.; Capobianco, R.; Morbin, M.; Mazzoleni, G.; Cupidi, C.; Marcon, G.; Giovagnoli, A.; et al. Hereditary cerebral hemorrhage with amyloidosis associated with the E693K mutation of APP. *Arch. Neurol.* **2010**, *67*, 987–995. [[CrossRef](#)] [[PubMed](#)]
34. Nilsberth, C.; Westlind-Danielsson, A.; Eckman, C.B.; Condron, M.M.; Axelman, K.; Forsell, C.; Stenh, C.; Luthman, J.; Teplow, D.B.; Younkin, S.G.; et al. The 'Arctic' APP mutation (E693G) causes Alzheimer's disease by enhanced Abeta protofibril formation. *Nat. Neurosci.* **2001**, *4*, 887–893. [[CrossRef](#)] [[PubMed](#)]
35. Tomiyama, T.; Nagata, T.; Shimada, H.; Teraoka, R.; Fukushima, A.; Kanemitsu, H.; Takuma, H.; Kuwano, R.; Imagawa, M.; Ataka, S.; et al. A new amyloid beta variant favoring oligomerization in Alzheimer's-type dementia. *Ann. Neurol.* **2008**, *63*, 377–387. [[CrossRef](#)] [[PubMed](#)]
36. Inayathullah, M.; Teplow, D.B. Teplow, Structural dynamics of the DeltaE22 (Osaka) familial Alzheimer's disease-linked amyloid beta-protein. *Amyloid* **2011**, *18*, 98–107. [[CrossRef](#)]
37. De Jonghe, C.; Zehr, C.; Yager, D.; Prada, C.M.; Younkin, S.; Hendriks, L.; Van Broeckhoven, C.; Eckman, C.B. Flemish and Dutch mutations in amyloid beta precursor protein have different effects on amyloid beta secretion. *Neurobiol. Dis.* **1998**, *5*, 281–286. [[CrossRef](#)]
38. Grabowski, T.J.; Cho, H.S.; Vonsattel, J.P.; Rebeck, G.W.; Greenberg, S.M. Novel amyloid precursor protein mutation in an Iowa family with dementia and severe cerebral amyloid angiopathy. *Ann. Neurol.* **2001**, *49*, 697–705. [[CrossRef](#)]
39. Obici, L.; Demarchi, A.; de Rosa, G.; Bellotti, V.; Marciano, S.; Donadei, S.; Arbustini, E.; Palladini, G.; Diegoli, M.; Genovese, E.; et al. A novel AbetaPP mutation exclusively associated with cerebral amyloid angiopathy. *Ann. Neurol.* **2005**, *58*, 639–644. [[CrossRef](#)]
40. Rossi, G.; Giaccone, G.; Maletta, R.; Morbin, M.; Capobianco, R.; Mangieri, M.; Giovagnoli, A.R.; Bizzi, A.; Tomaino, C.; Perri, M.; et al. A family with Alzheimer disease and strokes associated with A713T mutation of the APP gene. *Neurology* **2004**, *63*, 910–912. [[CrossRef](#)]
41. Conidi, M.E.; Bernardi, L.; Puccio, G.; Smirne, N.; Muraca, M.G.; Curcio, S.A.; Colao, R.; Piscopo, P.; Gallo, M.; Anfossi, M.; et al. Homozygous carriers of APP A713T mutation in an autosomal dominant Alzheimer disease family. *Neurology* **2015**, *84*, 2266–2273. [[CrossRef](#)] [[PubMed](#)]

42. Kumar-Singh, S.; De Jonghe, C.; Cruets, M.; Kleinert, R.; Wang, R.; Mercken, M.; De Strooper, B.; Vanderstichele, H.; Lofgren, A.; Vanderhoeven, I.; et al. Nonfibrillar diffuse amyloid deposition due to a gamma(42)-secretase site mutation points to an essential role for N-truncated A beta(42) in Alzheimer's disease. *Hum. Mol. Genet.* **2000**, *9*, 2589–2598. [[CrossRef](#)] [[PubMed](#)]
43. Pasalar, P.; Najmabadi, H.; Noorian, A.R.; Moghimi, B.; Jannati, A.; Soltanzadeh, A.; Krefft, T.; Crook, R.; Hardy, J. Iranian family with Alzheimer's disease caused by a novel APP mutation (Thr714Ala). *Neurology* **2002**, *58*, 1574–1575. [[CrossRef](#)] [[PubMed](#)]
44. Vidal, R.; Frangione, B.; Rostagno, A.; Mead, S.; Révész, T.; Plant, G.; Ghiso, J. A stop-codon mutation in the BRI gene associated with familial British dementia. *Nature* **1999**, *399*, 776–781. [[CrossRef](#)] [[PubMed](#)]
45. Garringer, H.J.; Sammeta, N.; Oblak, A.; Ghetti, B.; Vidal, R. Amyloid and intracellular accumulation of BRI2. *Neurobiol. Aging* **2017**, *52*, 90–97. [[CrossRef](#)] [[PubMed](#)]
46. Marcora, M.S. Amyloid peptides ABri and ADan show differential neurotoxicity in transgenic Drosophila models of familial British and Danish dementia. *Mol. Neurodegener.* **2014**, *9*, 5. [[CrossRef](#)]
47. Holton, J.L. Regional distribution of amyloid-Bri deposition and its association with neurofibrillary degeneration in familial British dementia. *Am. J. Pathol.* **2001**, *158*, 515–526. [[CrossRef](#)]
48. Vidal, R.; Revesz, T.; Rostagno, A.; Kim, E.; Holton, J.L.; Bek, T.; Bojsen-Moller, M.; Braendgaard, H.; Plant, G.; Ghiso, J.; et al. A decamer duplication in the 3' region of the BRI gene originates an amyloid peptide that is associated with dementia in a Danish kindred. *Proc. Natl. Acad. Sci. USA* **2000**, *97*, 4920–4925. [[CrossRef](#)]
49. Holton, J.L.; Lashley, T.; Ghiso, J.; Braendgaard, H.; Vidal, R.; Guerin, C.J.; Gibb, G.; Hanger, D.P.; Rostagno, A.; Anderton, B.H.; et al. Familial Danish dementia: A novel form of cerebral amyloidosis associated with deposition of both amyloid-Dan and amyloid-beta. *J. Neuropathol. Exp. Neurol.* **2002**, *61*, 254–267. [[CrossRef](#)]
50. Vidal, R.; Barbeito, A.G.; Miravalle, L.; Ghetti, B. Cerebral amyloid angiopathy and parenchymal amyloid deposition in transgenic mice expressing the Danish mutant form of human BRI2. *Brain Pathol.* **2009**, *19*, 58–68. [[CrossRef](#)]
51. Jurczak, P.; Groves, P.; Szymanska, A.; Rodziewicz-Motowidlo, S. Human cystatin C monomer, dimer, oligomer, and amyloid structures are related to health and disease. *FEBS Lett.* **2016**, *590*, 4192–4201. [[CrossRef](#)] [[PubMed](#)]
52. Wang, Z.Z.; Jansson, O.; Thorsteinnsson, L.; Vinters, H.V. Microvascular degeneration in hereditary cystatin C amyloid angiopathy of the brain. *APMIS* **1997**, *105*, 41–47. [[CrossRef](#)] [[PubMed](#)]
53. Levy, E.; Sastre, M.; Kumar, A.; Gallo, G.; Piccardo, P.; Ghetti, B.; Tagliavini, F. Codeposition of cystatin C with amyloid-beta protein in the brain of Alzheimer disease patients. *J. Neuropathol. Exp. Neurol.* **2001**, *60*, 94–104. [[CrossRef](#)] [[PubMed](#)]
54. Jin, K.; Sato, S.; Takahashi, T.; Nakazaki, H.; Date, Y.; Nakazato, M.; Tominaga, T.; Itoyama, Y.; Ikeda, S. Familial leptomeningeal amyloidosis with a transthyretin variant Asp18Gly representing repeated subarachnoid haemorrhages with superficial siderosis. *J. Neurol. Neurosurg. Psychiatry* **2004**, *75*, 1463–1466. [[CrossRef](#)] [[PubMed](#)]
55. Garzuly, F.; Vidal, R.; Wisniewski, T.; Brittig, F.; Budka, H. Familial meningocerebrovascular amyloidosis, Hungarian type, with mutant transthyretin (TTR Asp18Gly). *Neurology* **1996**, *47*, 1562–1567. [[CrossRef](#)] [[PubMed](#)]
56. Garzuly, F. Clinical characteristics of Hungarian-type familial meningo-cerebrovascular amyloidosis. *Orv. Hetil.* **1996**, *137*, 2393–2399. [[PubMed](#)]
57. Vidal, R.; Garzuly, F.; Budka, H.; Lalowski, M.; Linke, R.P.; Brittig, F.; Frangione, B.; Wisniewski, T. Meningocerebrovascular amyloidosis associated with a novel transthyretin mis-sense mutation at codon 18 (TTRD 18G). *Am. J. Pathol.* **1996**, *148*, 361–366.
58. Petersen, R.B.; Goren, H.; Cohen, M.; Richardson, S.L.; Tresser, N.; Lynn, A.; Gali, M.; Estes, M.; Gambetti, P. Transthyretin amyloidosis: A new mutation associated with dementia. *Ann. Neurol.* **1997**, *41*, 307–313. [[CrossRef](#)]
59. Martin, S.E.; Benson, M.D.; Hattab, E.M. The pathologic spectrum of oculoleptomeningeal amyloidosis with Val30Gly transthyretin gene mutation in a postmortem case. *Hum. Pathol.* **2014**, *45*, 1105–1108. [[CrossRef](#)]
60. Roe, R.H.; Fisher, Y.; Eagle, R.C., Jr.; Fine, H.F.; Cunningham, E.T., Jr. Oculoleptomeningeal amyloidosis in a patient with a TTR Val30Gly mutation in the transthyretin gene. *Ophthalmology* **2007**, *114*, e33–e37. [[CrossRef](#)]

61. Ziskin, J.L.; Greicius, M.D.; Zhu, W.; Okumu, A.N.; Adams, C.M.; Plowey, E.D. Neuropathologic analysis of Tyr69His TTR variant meningovascular amyloidosis with dementia. *Acta Neuropathol. Commun.* **2015**, *3*, 43. [[CrossRef](#)] [[PubMed](#)]
62. Blevins, G.; Macaulay, R.; Harder, S.; Fladeland, D.; Yamashita, T.; Yazaki, M.; Hamidi Asl, K.; Benson, M.D.; Donat, J.R. Oculoleptomeningeal amyloidosis in a large kindred with a new transthyretin variant Tyr69His. *Neurology* **2003**, *60*, 1625–1630. [[CrossRef](#)] [[PubMed](#)]
63. Schweitzer, K.; Ehmann, D.; Garcia, R.; Alport, E. Oculoleptomeningeal amyloidosis in 3 individuals with the transthyretin variant Tyr69His. *Can. J. Ophthalmol.* **2009**, *44*, 317–319. [[CrossRef](#)] [[PubMed](#)]
64. Suhr, O.B.; Andersen, O.; Aronsson, T.; Jonasson, J.; Kalimo, H.; Lundahl, C.; Lundgren, H.E.; Melberg, A.; Nyberg, J.; Olsson, M.; et al. Report of five rare or previously unknown amyloidogenic transthyretin mutations disclosed in Sweden. *Amyloid* **2009**, *16*, 208–214. [[CrossRef](#)]
65. Hagiwara, K.; Ochi, H.; Suzuki, S.; Shimizu, Y.; Tokuda, T.; Murai, H.; Shigeto, H.; Ohyagi, Y.; Iwata, M.; Iwaki, T.; et al. Highly selective leptomeningeal amyloidosis with transthyretin variant Ala25Thr. *Neurology* **2009**, *72*, 1358–1360. [[CrossRef](#)]
66. Shimizu, Y.; Takeuchi, M.; Matsumura, M.; Tokuda, T.; Iwata, M. A case of biopsy-proven leptomeningeal amyloidosis and intravenous Ig-responsive polyneuropathy associated with the Ala25Thr transthyretin gene mutation. *Amyloid* **2006**, *13*, 37–41. [[CrossRef](#)]
67. Herrick, M.K.; DeBruyne, K.; Horoupian, D.S.; Skare, J.; Vanefsky, M.A.; Ong, T. Massive leptomeningeal amyloidosis associated with a Val30Met transthyretin gene. *Neurology* **1996**, *47*, 988–992. [[CrossRef](#)]
68. Maia, L.F.; Magalhaes, R.; Freitas, J.; Taipa, R.; Pires, M.M.; Osorio, H.; Dias, D.; Pessegueiro, H.; Correia, M.; Coelho, T. CNS involvement in V30M transthyretin amyloidosis: Clinical, neuropathological and biochemical findings. *J. Neurol. Neurosurg. Psychiatry* **2015**, *86*, 159–167. [[CrossRef](#)]
69. Nakagawa, K.; Sheikh, S.I.; Snuderl, M.; Frosch, M.P.; Greenberg, S.M. A new Thr49Pro transthyretin gene mutation associated with leptomeningeal amyloidosis. *J. Neurol. Sci.* **2008**, *272*, 186–190. [[CrossRef](#)]
70. Motozaki, Y.; Sugiyama, Y.; Ishida, C.; Komai, K.; Matsubara, S.; Yamada, M. Phenotypic heterogeneity in a family with FAP due to a TTR Leu58Arg mutation: A clinicopathologic study. *J. Neurol. Sci.* **2007**, *260*, 236–239. [[CrossRef](#)]
71. Uemichi, T.; Uitti, R.J.; Koeppen, A.H.; Donat, J.R.; Benson, M.D. Oculoleptomeningeal amyloidosis associated with a new transthyretin variant Ser64. *Arch. Neurol.* **1999**, *56*, 1152–1155. [[CrossRef](#)] [[PubMed](#)]
72. Nakamura, M.; Yamashita, T.; Ueda, M.; Obayashi, K.; Sato, T.; Ikeda, T.; Washimi, Y.; Hirai, T.; Kuwahara, Y.; Yamamoto, M.T.; et al. Neuroradiologic and clinicopathologic features of oculoleptomeningeal type amyloidosis. *Neurology* **2005**, *65*, 1051–1056. [[CrossRef](#)] [[PubMed](#)]
73. Brett, M.; Persey, M.R.; Reilly, M.M.; Revesz, T.; Booth, D.R.; Booth, S.E.; Hawkins, P.N.; Pepys, M.B.; Morgan-Hughes, J.A. Transthyretin Leu12Pro is associated with systemic, neuropathic and leptomeningeal amyloidosis. *Brain* **1999**, *122 Pt 2*, 183–190. [[CrossRef](#)]
74. Liepnieks, J.J.; Dickson, D.W.; Benson, M.D. A new transthyretin mutation associated with leptomeningeal amyloidosis. *Amyloid* **2011**, *18* (Suppl. 1), 160–162. [[CrossRef](#)] [[PubMed](#)]
75. Solomon, J.P.; Page, L.J.; Balch, W.E.; Kelly, J.W. Gelsolin amyloidosis: Genetics, biochemistry, pathology and possible strategies for therapeutic intervention. *Crit. Rev. Biochem. Mol. Biol.* **2012**, *47*, 282–296. [[CrossRef](#)] [[PubMed](#)]
76. Kiuru, S. Gelsolin-related familial amyloidosis, Finnish type (FAF), and its variants found worldwide. *Amyloid* **1998**, *5*, 55–66. [[CrossRef](#)]
77. Ghiso, J.; Haltia, M.; Prelli, F.; Novello, J.; Frangione, B. Gelsolin variant (Asn-187) in familial amyloidosis, Finnish type. *Biochem. J.* **1990**, *272*, 827–830. [[CrossRef](#)]
78. Mead, S.; Gandhi, S.; Beck, J.; Caine, D.; Gallujipali, D.; Carswell, C.; Hyare, H.; Joiner, S.; Ayling, H.; Lashley, T.; et al. A novel prion disease associated with diarrhea and autonomic neuropathy. *N. Engl. J. Med.* **2013**, *369*, 1904–1914. [[CrossRef](#)]
79. Weller, R.O.; Preston, S.D.; Subash, M.; Carare, R.O. Cerebral amyloid angiopathy in the aetiology and immunotherapy of Alzheimer disease. *Alzheimers Res. Ther.* **2009**, *1*, 6. [[CrossRef](#)]
80. Revesz, T.; Ghiso, J.; Lashley, T.; Plant, G.; Rostagno, A.; Frangione, B.; Holton, J.L. Cerebral amyloid angiopathies: A pathologic, biochemical, and genetic view. *J. Neuropathol. Exp. Neurol.* **2003**, *62*, 885–898. [[CrossRef](#)]

81. Frangione, B.; Revesz, T.; Vidal, R.; Holton, J.; Lashley, T.; Houlden, H.; Wood, N.; Rostagno, A.; Plant, G.; Ghiso, J. Familial cerebral amyloid angiopathy related to stroke and dementia. *Amyloid* **2001**, *8* (Suppl. 1), 36–42. [[PubMed](#)]
82. Garringer, H.J.; Murrell, J.; Sammeta, N.; Gnezda, A.; Ghetti, B.; Vidal, R. Increased tau phosphorylation and tau truncation, and decreased synaptophysin levels in mutant BRI2/tau transgenic mice. *PLoS ONE* **2013**, *8*, e56426. [[CrossRef](#)] [[PubMed](#)]
83. Kolodziejczyk, R.; Michalska, K.; Hernandez-Santoyo, A.; Wahlbom, M.; Grubb, A.; Jaskolski, M. Crystal structure of human cystatin C stabilized against amyloid formation. *FEBS J.* **2010**, *277*, 1726–1737. [[CrossRef](#)] [[PubMed](#)]
84. Yamaguchi, K.I.; Kuwata, K. Formation and properties of amyloid fibrils of prion protein. *Biophys. Rev.* **2018**, *10*, 517–525. [[CrossRef](#)]
85. Ghetti, B.; Piccardo, P.; Frangione, B.; Bugiani, O.; Giaccone, G.; Young, K.; Prelli, F.; Farlow, M.R.; Dlouhy, S.R.; Tagliavini, F. Prion protein amyloidosis. *Brain Pathol.* **1996**, *6*, 127–145. [[CrossRef](#)] [[PubMed](#)]
86. Morris, M.; Maeda, S.; Vossel, K.; Mucke, L. The many faces of tau. *Neuron* **2011**, *70*, 410–426. [[CrossRef](#)] [[PubMed](#)]
87. Nation, D.A.; Edmonds, E.C.; Bangen, K.J.; Delano-Wood, L.; Scanlon, B.K.; Han, S.D.; Edland, S.D.; Salmon, D.P.; Galasko, D.R.; Bondi, M.W.; et al. Pulse pressure in relation to tau-mediated neurodegeneration, cerebral amyloidosis, and progression to dementia in very old adults. *JAMA Neurol.* **2015**, *72*, 546–553. [[CrossRef](#)]
88. Kim, H.J.; Park, S.; Cho, H.; Jang, Y.K.; San Lee, J.; Jang, H.; Kim, Y.; Kim, K.W.; Ryu, Y.H.; Choi, J.Y.; et al. Assessment of Extent and Role of Tau in Subcortical Vascular Cognitive Impairment Using 18F-AV1451 Positron Emission Tomography Imaging. *JAMA Neurol.* **2018**. [[CrossRef](#)]
89. Bennett, R.E.; Robbins, A.B.; Hu, M.; Cao, X.; Betensky, R.A.; Clark, T.; Das, S.; Hyman, B.T. Tau induces blood vessel abnormalities and angiogenesis-related gene expression in P301L transgenic mice and human Alzheimer's disease. *Proc. Natl. Acad. Sci. USA* **2018**, *115*, E1289–E1298. [[CrossRef](#)]
90. Merlini, M.; Wanner, D.; Nitsch, R.M. Tau pathology-dependent remodelling of cerebral arteries precedes Alzheimer's disease-related microvascular cerebral amyloid angiopathy. *Acta Neuropathol.* **2016**, *131*, 737–752. [[CrossRef](#)]
91. Bartels, A.L.; Willemsen, A.T.; Kortekaas, R.; de Jong, B.M.; de Vries, R.; de Klerk, O.; van Oostrom, J.C.; Portman, A.; Leenders, K.L. Decreased blood-brain barrier P-glycoprotein function in the progression of Parkinson's disease, PSP and MSA. *J. Neural Transm.* **2008**, *115*, 1001–1009. [[CrossRef](#)] [[PubMed](#)]
92. Castillo-Carranza, D.L.; Nilson, A.N.; Van Skike, C.E.; Jahrling, J.B.; Patel, K.; Garach, P.; Gerson, J.E.; Sengupta, U.; Abisambra, J.; Nelson, P.; et al. Cerebral Microvascular Accumulation of Tau Oligomers in Alzheimer's Disease and Related Tauopathies. *Aging Dis.* **2017**, *8*, 257–266. [[CrossRef](#)] [[PubMed](#)]
93. Blair, L.J.; Frauen, H.D.; Zhang, B.; Nordhues, B.A.; Bijan, S.; Lin, Y.C.; Zamudio, F.; Hernandez, L.D.; Sabbagh, J.J.; Selenica, M.L.; et al. Tau depletion prevents progressive blood-brain barrier damage in a mouse model of tauopathy. *Acta Neuropathol. Commun.* **2015**, *3*, 8. [[CrossRef](#)] [[PubMed](#)]
94. Oshima, K.; Uchikado, H.; Dickson, D.W. Perivascular neuritic dystrophy associated with cerebral amyloid angiopathy in Alzheimer's disease. *Int. J. Clin. Exp. Pathol.* **2008**, *1*, 403–408.
95. You, Y.; Perkins, A.; Cisternas, P.; Munoz, B.; Taylor, X.; You, Y.; Garringer, H.J.; Oblak, A.L.; Atwood, B.K.; Vidal, R.; et al. Tau as a mediator of neurotoxicity associated to cerebral amyloid angiopathy. *Acta Neuropathol. Commun.* **2019**, *7*, 26. [[CrossRef](#)]
96. Ransom, B.; Behar, T.; Nedergaard, M. New roles for astrocytes (stars at last). *Trends Neurosci.* **2003**, *26*, 520–522. [[CrossRef](#)]
97. Komori, T. Tau-positive glial inclusions in progressive supranuclear palsy, corticobasal degeneration and Pick's disease. *Brain Pathol.* **1999**, *9*, 663–679. [[CrossRef](#)]
98. Ikeda, K.; Akiyama, H.; Kondo, H.; Haga, C.; Tanno, E.; Tokuda, T.; Ikeda, S. Thorn-shaped astrocytes: Possibly secondarily induced tau-positive glial fibrillary tangles. *Acta Neuropathol.* **1995**, *90*, 620–625. [[CrossRef](#)]
99. Kanaan, N.M.; Cox, K.; Alvarez, V.E.; Stein, T.D.; Poncil, S.; McKee, A.C. Characterization of Early Pathological Tau Conformations and Phosphorylation in Chronic Traumatic Encephalopathy. *J. Neuropathol. Exp. Neurol.* **2016**, *75*, 19–34. [[CrossRef](#)]

100. Mez, J.; Daneshvar, D.H.; Kiernan, P.T.; Abdolmohammadi, B.; Alvarez, V.E.; Huber, B.R.; Alosco, M.L.; Solomon, T.M.; Nowinski, C.J.; McHale, L.; et al. Clinicopathological Evaluation of Chronic Traumatic Encephalopathy in Players of American Football. *JAMA* **2017**, *318*, 360–370. [[CrossRef](#)]
101. Andrews-Zwilling, Y.; Bien-Ly, N.; Xu, Q.; Li, G.; Bernardo, A.; Yoon, S.Y.; Zwilling, D.; Yan, T.X.; Chen, L.; Huang, Y. Apolipoprotein E4 causes age- and Tau-dependent impairment of GABAergic interneurons, leading to learning and memory deficits in mice. *J. Neurosci. Off. J. Soc. Neurosci.* **2010**, *30*, 13707–13717. [[CrossRef](#)]
102. Roberson, E.D.; Halabisky, B.; Yoo, J.W.; Yao, J.; Chin, J.; Yan, F.; Wu, T.; Hamto, P.; Devidze, N.; Yu, G.Q.; et al. Amyloid-beta/Fyn-induced synaptic, network, and cognitive impairments depend on tau levels in multiple mouse models of Alzheimer's disease. *J. Neurosci.* **2011**, *31*, 700–711. [[CrossRef](#)]
103. Roberson, E.D.; Scarce-Levie, K.; Palop, J.J.; Yan, F.; Cheng, I.H.; Wu, T.; Gerstein, H.; Yu, G.Q.; Mucke, L. Reducing endogenous tau ameliorates amyloid beta-induced deficits in an Alzheimer's disease mouse model. *Science* **2007**, *316*, 750–754. [[CrossRef](#)]
104. Singh, B.; Covelo, A.; Martell-Martinez, H.; Nanclares, C.; Sherman, M.A.; Okematti, E.; Meints, J.; Teravskis, P.J.; Gallardo, C.; Savonenko, A.V.; et al. Tau is required for progressive synaptic and memory deficits in a transgenic mouse model of alpha-synucleinopathy. *Acta Neuropathol.* **2019**, *138*, 551–574. [[CrossRef](#)]
105. Fernandez-Nogales, M.; Cabrera, J.R.; Santos-Galindo, M.; Hoozemans, J.J.; Ferrer, I.; Rozemuller, A.J.; Hernandez, F.; Avila, J.; Lucas, J.J. Huntington's disease is a four-repeat tauopathy with tau nuclear rods. *Nat. Med.* **2014**, *20*, 881–885. [[CrossRef](#)]
106. Cheng, J.S.; Craft, R.; Yu, G.Q.; Ho, K.; Wang, X.; Mohan, G.; Mangnitsky, S.; Ponnusamy, R.; Mucke, L. Tau reduction diminishes spatial learning and memory deficits after mild repetitive traumatic brain injury in mice. *PLoS ONE* **2014**, *9*, e115765. [[CrossRef](#)]
107. DeVos, S.L.; Goncharoff, D.K.; Chen, G.; Kebodeaux, C.S.; Yamada, K.; Stewart, F.R.; Schuler, D.R.; Maloney, S.E.; Wozniak, D.F.; Rigo, F.; et al. Antisense reduction of tau in adult mice protects against seizures. *J. Neurosci. Off. J. Soc. Neurosci.* **2013**, *33*, 12887–12897. [[CrossRef](#)]
108. Holth, J.K.; Bomben, V.C.; Reed, J.G.; Inoue, T.; Younkin, L.; Younkin, S.G.; Pautler, R.G.; Botas, J.; Noebels, J.L. Tau loss attenuates neuronal network hyperexcitability in mouse and Drosophila genetic models of epilepsy. *J. Neurosci.* **2013**, *33*, 1651–1659. [[CrossRef](#)]
109. Gheyara, A.L.; Ponnusamy, R.; Djukic, B.; Craft, R.J.; Ho, K.; Guo, W.; Finucane, M.M.; Sanchez, P.E.; Mucke, L. Tau reduction prevents disease in a mouse model of Dravet syndrome. *Ann. Neurol.* **2014**, *76*, 443–456. [[CrossRef](#)]
110. Faraco, G.; Hochrainer, K.; Segarra, S.G.; Schaeffer, S.; Santisteban, M.M.; Menon, A.; Jiang, H.; Holtzman, D.M.; Anrather, J.; Iadecola, C. Dietary salt promotes cognitive impairment through tau phosphorylation. *Nature* **2019**, *574*, 686–690. [[CrossRef](#)]
111. Naj, A.C.; Jun, G.; Beecham, G.W.; Wang, L.S.; Vardarajan, B.N.; Buross, J.; Gallins, P.J.; Buxbaum, J.D.; Jarvik, G.P.; Crane, P.K.; et al. Common variants at MS4A4/MS4A6E, CD2AP, CD33 and EPHA1 are associated with late-onset Alzheimer's disease. *Nat. Genet.* **2011**, *43*, 436–441. [[CrossRef](#)]
112. Harold, D.; Abraham, R.; Hollingworth, P.; Sims, R.; Gerrish, A.; Hamshere, M.L.; Pahwa, J.S.; Moskva, V.; Dowzell, K.; Williams, A.; et al. Genome-wide association study identifies variants at CLU and PICALM associated with Alzheimer's disease. *Nat. Genet.* **2009**, *41*, 1088–1093. [[CrossRef](#)]
113. Bertram, L.; Lange, C.; Mullin, K.; Parkinson, M.; Hsiao, M.; Hogan, M.F.; Schjeide, B.M.; Hooli, B.; Divito, J.; Ionita, I.; et al. Genome-wide association analysis reveals putative Alzheimer's disease susceptibility loci in addition to APOE. *Am. J. Hum. Genet.* **2008**, *83*, 623–632. [[CrossRef](#)]
114. Ramirez, L.M.; Goukasian, N.; Porat, S.; Hwang, K.S.; Eastman, J.A.; Hurtz, S.; Wang, B.; Vang, N.; Sears, R.; Klein, E.; et al. Common variants in ABCA7 and MS4A6A are associated with cortical and hippocampal atrophy. *Neurobiol. Aging* **2016**, *39*, 82–89. [[CrossRef](#)]
115. Kimbrough, I.F.; Robel, S.; Roberson, E.D.; Sontheimer, H. Vascular amyloidosis impairs the gliovascular unit in a mouse model of Alzheimer's disease. *Brain* **2015**, *138*, 3716–3733. [[CrossRef](#)]
116. Thomsen, M.S.; Routhe, L.J.; Moos, T. The vascular basement membrane in the healthy and pathological brain. *J. Cereb. Blood Flow Metab.* **2017**, *37*, 3300–3317. [[CrossRef](#)]

117. Magaki, S.; Tang, Z.; Tung, S.; Williams, C.K.; Lo, D.; Yong, W.H.; Khanlou, N.; Vinters, H.V. The effects of cerebral amyloid angiopathy on integrity of the blood-brain barrier. *Neurobiol. Aging* **2018**, *70*, 70–77. [[CrossRef](#)]
118. Yamada, M.; Itoh, Y.; Shintaku, M.; Kawamura, J.; Jensson, O.; Thorsteinnsson, L.; Suematsu, N.; Matsushita, M.; Otomo, E. Immune reactions associated with cerebral amyloid angiopathy. *Stroke* **1996**, *27*, 1155–1162. [[CrossRef](#)]
119. Pober, J.S.; Sessa, W.C. Evolving functions of endothelial cells in inflammation. *Nat. Rev. Immunol.* **2007**, *7*, 803–815. [[CrossRef](#)]
120. Misra, A.; Chakrabarti, S.S.; Gambhir, I.S. New genetic players in late-onset Alzheimer's disease: Findings of genome-wide association studies. *Indian J. Med. Res.* **2018**, *148*, 135–144. [[CrossRef](#)]
121. Brown, L.S.; Foster, C.G.; Courtney, J.M.; King, N.E.; Howells, D.W.; Sutherland, B.A. Pericytes and Neurovascular Function in the Healthy and Diseased Brain. *Front. Cell. Neurosci.* **2019**, *13*, 282. [[CrossRef](#)]
122. Winkler, E.A.; Sagare, A.P.; Zlokovic, B.V. The pericyte: A forgotten cell type with important implications for Alzheimer's disease? *Brain Pathol.* **2014**, *24*, 371–386. [[CrossRef](#)]
123. Cheng, J.; Korte, N.; Nortley, R.; Sethi, H.; Tang, Y.; Attwell, D. Targeting pericytes for therapeutic approaches to neurological disorders. *Acta Neuropathol.* **2018**, *136*, 507–523. [[CrossRef](#)]
124. Sagare, A.P.; Bell, R.D.; Zhao, Z.; Ma, Q.; Winkler, E.A.; Ramanathan, A.; Zlokovic, B.V. Pericyte loss influences Alzheimer-like neurodegeneration in mice. *Nat. Commun.* **2013**, *4*, 2932. [[CrossRef](#)]
125. Zehendner, C.M.; Sebastiani, A.; Hugonnet, A.; Bischoff, F.; Luhmann, H.J.; Thal, S.C. Traumatic brain injury results in rapid pericyte loss followed by reactive pericytosis in the cerebral cortex. *Sci. Rep.* **2015**, *5*, 13497. [[CrossRef](#)]
126. Lindahl, P.; Johansson, B.R.; Leveen, P.; Betsholtz, C. Pericyte loss and microaneurysm formation in PDGF-B-deficient mice. *Science* **1997**, *277*, 242–245. [[CrossRef](#)]
127. Schultz, N.; Brännström, K.; Byman, E.; Moussaud, S.; Nielsen, H.M.; Olofsson, A.; Wennström, M. Amyloid-beta 1-40 is associated with alterations in NG2+ pericyte population ex vivo and in vitro. *Aging Cell* **2018**, *17*, e12728. [[CrossRef](#)]
128. Thomas, W.E. Brain macrophages: On the role of pericytes and perivascular cells. *Brain Res. Brain Res. Rev.* **1999**, *31*, 42–57. [[CrossRef](#)]
129. Faraco, G.; Park, L.; Anrather, J.; Iadecola, C. Brain perivascular macrophages: Characterization and functional roles in health and disease. *J. Mol. Med.* **2017**, *95*, 1143–1152. [[CrossRef](#)]
130. Williams, K.; Alvarez, X.; Lackner, A.A. Central nervous system perivascular cells are immunoregulatory cells that connect the CNS with the peripheral immune system. *Glia* **2001**, *36*, 156–164. [[CrossRef](#)]
131. Bechmann, I.; Priller, J.; Kovac, A.; Bontert, M.; Wehner, T.; Klett, F.F.; Bohsung, J.; Stuschke, M.; Dirnagl, U.; Nitsch, R. Immune surveillance of mouse brain perivascular spaces by blood-borne macrophages. *Eur. J. Neurosci.* **2001**, *14*, 1651–1658. [[CrossRef](#)] [[PubMed](#)]
132. Polfliet, M.M.; Goede, P.H.; van Kesteren-Hendriks, E.M.; van Rooijen, N.; Dijkstra, C.D.; van den Berg, T.K. A method for the selective depletion of perivascular and meningeal macrophages in the central nervous system. *J. Neuroimmunol.* **2001**, *116*, 188–195. [[CrossRef](#)]
133. Hawkes, C.A.; McLaurin, J. Selective targeting of perivascular macrophages for clearance of beta-amyloid in cerebral amyloid angiopathy. *Proc. Natl. Acad. Sci. USA* **2009**, *106*, 1261–1266. [[CrossRef](#)]
134. Hawkes, C.; Brown, M.; Williams, K.; McLaurin, J. Perivascular macrophages and cerebral amyloid angiopathy in CRND8 mice. *J. Neurol. Sci.* **2009**, *283*, 289–290. [[CrossRef](#)]
135. Mildner, A.; Schlevogt, B.; Kierdorf, K.; Bottcher, C.; Erny, D.; Kummer, M.P.; Quinn, M.; Bruck, W.; Bechmann, I.; Heneka, M.T.; et al. Distinct and non-redundant roles of microglia and myeloid subsets in mouse models of Alzheimer's disease. *J. Neurosci. Off. J. Soc. Neurosci.* **2011**, *31*, 11159–11171. [[CrossRef](#)]
136. Meyer-Luehmann, M.; Spires-Jones, T.L.; Prada, C.; Garcia-Alloza, M.; de Calignon, A.; Rozkalne, A.; Koenigsnecht-Talboo, J.; Holtzman, D.M.; Bacskai, B.J.; Hyman, B.T. Rapid appearance and local toxicity of amyloid-beta plaques in a mouse model of Alzheimer's disease. *Nature* **2008**, *451*, 720–724. [[CrossRef](#)]
137. Bolmont, T.; Haiss, F.; Eicke, D.; Radde, R.; Mathis, C.A.; Klunk, W.E.; Kohsaka, S.; Jucker, M.; Calhoun, M.E. Dynamics of the microglial/amyloid interaction indicate a role in plaque maintenance. *J. Neurosci. Off. J. Soc. Neurosci.* **2008**, *28*, 4283–4292. [[CrossRef](#)]

138. Akiyama, H.; Barger, S.; Barnum, S.; Bradt, B.; Bauer, J.; Cole, G.M.; Cooper, N.R.; Eikelenboom, P.; Emmerling, M.; Fiebich, B.L.; et al. Inflammation and Alzheimer's disease. *Neurobiol. Aging* **2000**, *21*, 383–421. [[CrossRef](#)]
139. Spangenberg, E.E.; Lee, R.J.; Najafi, A.R.; Rice, R.A.; Elmore, M.R.; Blurton-Jones, M.; West, B.L.; Green, K.N. Eliminating microglia in Alzheimer's mice prevents neuronal loss without modulating amyloid- β pathology. *Brain* **2016**, *139*, 1265–1281. [[CrossRef](#)]
140. Spangenberg, E.; Severson, P.L.; Hohsfield, L.A.; Crapser, J.; Zhang, J.; Burton, E.A.; Zhang, Y.; Spevak, W.; Lin, J.; Phan, N.Y.; et al. Sustained microglial depletion with CSF1R inhibitor impairs parenchymal plaque development in an Alzheimer's disease model. *Nat. Commun.* **2019**, *10*, 3758. [[CrossRef](#)]
141. Koenigsnecht-Talboo, J.; Meyer-Luehmann, M.; Parsadanian, M.; Garcia-Alloza, M.; Finn, M.B.; Hyman, B.T.; Bacskai, B.J.; Holtzman, D.M. Rapid microglial response around amyloid pathology after systemic anti-A β antibody administration in PDAPP mice. *J. Neurosci. Off. J. Soc. Neurosci.* **2008**, *28*, 14156–14164. [[CrossRef](#)] [[PubMed](#)]
142. Bard, F.; Cannon, C.; Barbour, R.; Burke, R.L.; Games, D.; Grajeda, H.; Guido, T.; Hu, K.; Huang, J.; Johnson-Wood, K.; et al. Peripherally administered antibodies against amyloid beta-peptide enter the central nervous system and reduce pathology in a mouse model of Alzheimer disease. *Nat. Med.* **2000**, *6*, 916–919. [[CrossRef](#)] [[PubMed](#)]
143. Wilcock, D.M.; Rojiani, A.; Rosenthal, A.; Levkowitz, G.; Subbarao, S.; Alamed, J.; Wilson, D.; Wilson, N.; Freeman, M.J.; Gordon, M.N.; et al. Passive amyloid immunotherapy clears amyloid and transiently activates microglia in a transgenic mouse model of amyloid deposition. *J. Neurosci. Off. J. Soc. Neurosci.* **2004**, *24*, 6144–6151. [[CrossRef](#)] [[PubMed](#)]
144. Wilcock, D.M.; Alamed, J.; Gottschall, P.E.; Grimm, J.; Rosenthal, A.; Pons, J.; Ronan, V.; Symmonds, K.; Gordon, M.N.; Morgan, D. Deglycosylated anti-amyloid-beta antibodies eliminate cognitive deficits and reduce parenchymal amyloid with minimal vascular consequences in aged amyloid precursor protein transgenic mice. *J. Neurosci. Off. J. Soc. Neurosci.* **2006**, *26*, 5340–5346. [[CrossRef](#)]
145. Vasilevko, V.; Xu, F.; Previti, M.L.; Van Nostrand, W.E.; Cribbs, D.H. Experimental investigation of antibody-mediated clearance mechanisms of amyloid-beta in CNS of Tg-SwDI transgenic mice. *J. Neurosci. Off. J. Soc. Neurosci.* **2007**, *27*, 13376–13383. [[CrossRef](#)]
146. Boche, D.; Zotova, E.; Weller, R.O.; Love, S.; Neal, J.W.; Pickering, R.M.; Wilkinson, D.; Holmes, C.; Nicoll, J.A. Consequence of A β immunization on the vasculature of human Alzheimer's disease brain. *Brain* **2008**, *131*, 3299–3310. [[CrossRef](#)]
147. Wilcock, D.M.; Rojiani, A.; Rosenthal, A.; Subbarao, S.; Freeman, M.J.; Gordon, M.N.; Morgan, D. Passive immunotherapy against A β in aged APP-transgenic mice reverses cognitive deficits and depletes parenchymal amyloid deposits in spite of increased vascular amyloid and microhemorrhage. *J. Neuroinflamm.* **2004**, *1*, 24. [[CrossRef](#)]
148. Patton, R.L.; Kalback, W.M.; Esh, C.L.; Kokjohn, T.A.; Van Vickle, G.D.; Luehrs, D.C.; Kuo, Y.M.; Lopez, J.; Brune, D.; Ferrer, I.; et al. Amyloid-beta peptide remnants in AN-1792-immunized Alzheimer's disease patients: A biochemical analysis. *Am. J. Pathol.* **2006**, *169*, 1048–1063. [[CrossRef](#)]
149. Nicoll, J.A.; Barton, E.; Boche, D.; Neal, J.W.; Ferrer, I.; Thompson, P.; Vlachouli, C.; Wilkinson, D.; Bayer, A.; Games, D.; et al. A β species removal after A β 42 immunization. *J. Neuropathol. Exp. Neurol.* **2006**, *65*, 1040–1048. [[CrossRef](#)]
150. Park, L.; Zhou, J.; Zhou, P.; Pistick, R.; El Jamal, S.; Younkin, L.; Pierce, J.; Arreguin, A.; Anrather, J.; Younkin, S.G.; et al. Innate immunity receptor CD36 promotes cerebral amyloid angiopathy. *Proc. Natl. Acad. Sci. USA* **2013**, *110*, 3089–3094. [[CrossRef](#)]
151. Chun, H.; Lee, C.J. Reactive astrocytes in Alzheimer's disease: A double-edged sword. *Neurosci. Res.* **2018**, *126*, 44–52. [[CrossRef](#)] [[PubMed](#)]
152. Liddelow, S.A.; Gattenplan, K.A.; Clarke, L.E.; Bennett, F.C.; Bohlen, C.J.; Schirmer, L.; Bennett, M.L.; Münch, A.E.; Chung, W.-S.; Peterson, T.C.; et al. Neurotoxic reactive astrocytes are induced by activated microglia. *Nature* **2017**, *541*, 481–487. [[CrossRef](#)] [[PubMed](#)]
153. Sofroniew, M.V.; Vinters, H.V. Astrocytes: Biology and pathology. *Acta Neuropathol.* **2010**, *119*, 7–35. [[CrossRef](#)] [[PubMed](#)]
154. Colombo, E.; Farina, C. Astrocytes: Key Regulators of Neuroinflammation. *Trends Immunol.* **2016**, *37*, 608–620. [[CrossRef](#)] [[PubMed](#)]

155. al-Ali, S.Y.; al-Hussain, S.M. An ultrastructural study of the phagocytic activity of astrocytes in adult rat brain. *J. Anat.* **1996**, *188 Pt 2*, 257–262.
156. Montgomery, D.L. Astrocytes: Form, functions, and roles in disease. *Vet. Pathol.* **1994**, *31*, 145–167. [[CrossRef](#)] [[PubMed](#)]
157. Greenberg, S.M.; Rebeck, G.W.; Vonsattel, J.P.; Gomez-Isla, T.; Hyman, B.T. Apolipoprotein E epsilon 4 and cerebral hemorrhage associated with amyloid angiopathy. *Ann. Neurol.* **1995**, *38*, 254–259. [[CrossRef](#)]
158. Mahley, R.W. Central Nervous System Lipoproteins: ApoE and Regulation of Cholesterol Metabolism. *Arterioscler. Thromb. Vasc. Biol.* **2016**, *36*, 1305–1315. [[CrossRef](#)]
159. Rannikmae, K.; Kalaria, R.N.; Greenberg, S.M.; Chui, H.C.; Schmitt, F.A.; Samarasekera, N.; Al-Shahi Salman, R.; Sudlow, C.L. APOE associations with severe CAA-associated vasculopathic changes: Collaborative meta-analysis. *J. Neurol. Neurosurg. Psychiatry* **2014**, *85*, 300–305. [[CrossRef](#)]
160. Koistinaho, M.; Lin, S.; Wu, X.; Esterman, M.; Koger, D.; Hanson, J.; Higgs, R.; Liu, F.; Malkani, S.; Bales, K.R.; et al. Apolipoprotein E promotes astrocyte colocalization and degradation of deposited amyloid-beta peptides. *Nat. Med.* **2004**, *10*, 719–726. [[CrossRef](#)]
161. Matsunaga, W.; Shirokawa, T.; Isobe, K. Specific uptake of Abeta1-40 in rat brain occurs in astrocyte, but not in microglia. *Neurosci. Lett.* **2003**, *342*, 129–131. [[CrossRef](#)]
162. Funato, H.; Yoshimura, M.; Yamazaki, T.; Saido, T.C.; Ito, Y.; Yokofujita, J.; Okeda, R.; Ihara, Y. Astrocytes containing amyloid beta-protein (Abeta)-positive granules are associated with Abeta40-positive diffuse plaques in the aged human brain. *Am. J. Pathol.* **1998**, *152*, 983–992. [[PubMed](#)]
163. Fryer, J.D.; Simmons, K.; Parsadanian, M.; Bales, K.R.; Paul, S.M.; Sullivan, P.M.; Holtzman, D.M. Human apolipoprotein E4 alters the amyloid-beta 40:42 ratio and promotes the formation of cerebral amyloid angiopathy in an amyloid precursor protein transgenic model. *J. Neurosci. Off. J. Soc. Neurosci.* **2005**, *25*, 2803–2810. [[CrossRef](#)] [[PubMed](#)]
164. Harr, S.D.; Uint, L.; Hollister, R.; Hyman, B.T.; Mendez, A.J. Brain expression of apolipoproteins E, J, and A-I in Alzheimer's disease. *J. Neurochem.* **1996**, *66*, 2429–2435. [[CrossRef](#)]
165. Nelson, A.R.; Sagare, A.P.; Zlokovic, B.V. Role of clusterin in the brain vascular clearance of amyloid-beta. *Proc. Natl. Acad. Sci. USA* **2017**, *114*, 8681–8682. [[CrossRef](#)]
166. Wojtas, A.M.; Kang, S.S.; Olley, B.M.; Gatherer, M.; Shinohara, M.; Lozano, P.A.; Liu, C.C.; Kurti, A.; Baker, K.E.; Dickson, D.W.; et al. Loss of clusterin shifts amyloid deposition to the cerebrovasculature via disruption of perivascular drainage pathways. *Proc. Natl. Acad. Sci. USA* **2017**, *114*, e6962–e6971. [[CrossRef](#)]
167. Koudinov, A.R.; Berezov, T.T.; Kumar, A.; Koudinova, N.V. Alzheimer's amyloid beta interaction with normal human plasma high density lipoprotein: Association with apolipoprotein and lipids. *Clin. Chim. Acta Int. J. Clin. Chem.* **1998**, *270*, 75–84. [[CrossRef](#)]
168. Button, E.B.; Boyce, G.K.; Wilkinson, A.; Stukas, S.; Hayat, A.; Fan, J.; Wadsworth, B.J.; Robert, J.; Martens, K.M.; Wellington, C.L. ApoA-I deficiency increases cortical amyloid deposition, cerebral amyloid angiopathy, cortical and hippocampal astrogliosis, and amyloid-associated astrocyte reactivity in APP/PS1 mice. *Alzheimers Res.* **2019**, *11*, 44. [[CrossRef](#)]
169. Handattu, S.P.; Garber, D.W.; Monroe, C.E.; van Groen, T.; Kadish, I.; Nayyar, G.; Cao, D.; Palgunachari, M.N.; Li, L.; Anantharamaiah, G.M. Oral apolipoprotein A-I mimetic peptide improves cognitive function and reduces amyloid burden in a mouse model of Alzheimer's disease. *Neurobiol. Dis.* **2009**, *34*, 525–534. [[CrossRef](#)]
170. Fernandez-de Retana, S.; Montanola, A.; Marazuela, P.; De La Cuesta, M.; Batlle, A.; Fatar, M.; Grudzenski, S.; Montaner, J.; Hernandez-Guillamon, M. Intravenous treatment with human recombinant ApoA-I Milano reduces beta amyloid cerebral deposition in the APP23-transgenic mouse model of Alzheimer's disease. *Neurobiol. Aging* **2017**, *60*, 116–128. [[CrossRef](#)]
171. Robert, J.; Stukas, S.; Button, E.; Cheng, W.H.; Lee, M.; Fan, J.; Wilkinson, A.; Kulic, I.; Wright, S.D.; Wellington, C.L. Reconstituted high-density lipoproteins acutely reduce soluble brain Abeta levels in symptomatic APP/PS1 mice. *Biochim. Biophys. Acta* **2016**, *1862*, 1027–1036. [[CrossRef](#)] [[PubMed](#)]
172. Karch, C.M.; Goate, A.M. Alzheimer's disease risk genes and mechanisms of disease pathogenesis. *Biol. Psychiatry* **2015**, *77*, 43–51. [[CrossRef](#)] [[PubMed](#)]
173. Giri, M.; Zhang, M.; Lu, Y. Genes associated with Alzheimer's disease: An overview and current status. *Clin. Interv. Aging* **2016**, *11*, 665–681. [[CrossRef](#)] [[PubMed](#)]

174. Beecham, G.W.; Hamilton, K.; Naj, A.C.; Martin, E.R.; Huentelman, M.; Myers, A.J.; Corneveaux, J.J.; Hardy, J.; Vonsattel, J.P.; Younkin, S.G.; et al. Genome-wide association meta-analysis of neuropathologic features of Alzheimer's disease and related dementias. *PLoS Genet.* **2014**, *10*, e1004606. [[CrossRef](#)]
175. Wang, Y.; Cella, M.; Mallinson, K.; Ulrich, J.D.; Young, K.L.; Robinette, M.L.; Gilfillan, S.; Krishnan, G.M.; Sudhakar, S.; Zinselmeyer, B.H.; et al. TREM2 lipid sensing sustains the microglial response in an Alzheimer's disease model. *Cell* **2015**, *160*, 1061–1071. [[CrossRef](#)]
176. Wang, Y.; Ulland, T.K.; Ulrich, J.D.; Song, W.; Tzaferis, J.A.; Hole, J.T.; Yuan, P.; Mahan, T.E.; Shi, Y.; Gilfillan, S.; et al. TREM2-mediated early microglial response limits diffusion and toxicity of amyloid plaques. *J. Exp. Med.* **2016**, *213*, 667–675. [[CrossRef](#)]
177. Yuan, P.; Condello, C.; Keene, C.D.; Wang, Y.; Bird, T.D.; Paul, S.M.; Luo, W.; Colonna, M.; Baddeley, D.; Grutzendler, J. TREM2 Haplodeficiency in Mice and Humans Impairs the Microglia Barrier Function Leading to Decreased Amyloid Compaction and Severe Axonal Dystrophy. *Neuron* **2016**, *90*, 724–739. [[CrossRef](#)]
178. Ulland, T.K.; Song, W.M.; Huang, S.C.; Ulrich, J.D.; Sergushichev, A.; Beatty, W.L.; Loboda, A.A.; Zhou, Y.; Cairns, N.J.; Kambal, A.; et al. TREM2 Maintains Microglial Metabolic Fitness in Alzheimer's Disease. *Cell* **2017**, *170*, 649–663.e613. [[CrossRef](#)]
179. Jay, T.R.; Miller, C.M.; Cheng, P.J.; Graham, L.C.; Bemiller, S.; Broihier, M.L.; Xu, G.; Margevicius, D.; Karlo, J.C.; Sousa, G.L.; et al. TREM2 deficiency eliminates TREM2+ inflammatory macrophages and ameliorates pathology in Alzheimer's disease mouse models. *J. Exp. Med.* **2015**, *212*, 287–295. [[CrossRef](#)]
180. Efthymiou, A.G.; Goate, A.M. Late onset Alzheimer's disease genetics implicates microglial pathways in disease risk. *Mol. Neurodegener.* **2017**, *12*, 43. [[CrossRef](#)]
181. Lambert, J.C.; Heath, S.; Even, G.; Campion, D.; Sleegers, K.; Hiltunen, M.; Combarros, O.; Zelenika, D.; Bullido, M.J.; Tavernier, B.; et al. Genome-wide association study identifies variants at CLU and CR1 associated with Alzheimer's disease. *Nat. Genet.* **2009**, *41*, 1094–1099. [[CrossRef](#)] [[PubMed](#)]
182. Mäkelä, M.; Kaivola, K.; Valori, M.; Paetau, A.; Polvikoski, T.; Singleton, A.B.; Traynor, B.J.; Stone, D.J.; Peuralinna, T.; Tienari, P.J.; et al. Alzheimer risk loci and associated neuropathology in a population-based study (Vantaa 85+). *Neurol. Genet.* **2018**, *4*, e211. [[CrossRef](#)] [[PubMed](#)]
183. Wes, P.D.; Sayed, F.A.; Bard, F.; Gan, L. Targeting microglia for the treatment of Alzheimer's Disease. *Glia* **2016**, *64*, 1710–1732. [[CrossRef](#)] [[PubMed](#)]
184. Congdon, E.E.; Sigurdsson, E.M. Tau-targeting therapies for Alzheimer disease. *Nat. Rev. Neurol.* **2018**, *14*, 399–415. [[CrossRef](#)]
185. Heneka, M.T.; Kummer, M.P.; Latz, E. Innate immune activation in neurodegenerative disease. *Nat. Rev. Immunol.* **2014**, *14*, 463–477. [[CrossRef](#)]
186. Castillo-Carranza, D.L.; Guerrero-Munoz, M.J.; Sengupta, U.; Hernandez, C.; Barrett, A.D.; Dineley, K.; Kaye, R. Tau immunotherapy modulates both pathological tau and upstream amyloid pathology in an Alzheimer's disease mouse model. *J. Neurosci.* **2015**, *35*, 4857–4868. [[CrossRef](#)]
187. Vidal, R.; Ghetti, B. Hereditary Cerebral Amyloid Angiopathies. In *Neuropathology of Neurodegenerative Diseases: A Practical Guide*; Kovacs, G., Ed.; Cambridge University Press: Cambridge, UK, 2015; Volume 13, pp. 249–258.
188. Herzig, M.C.; Winkler, D.T.; Burgermeister, P.; Pfeifer, M.; Kohler, E.; Schmidt, S.D.; Danner, S.; Abramowski, D.; Sturchler-Pierrat, C.; Burki, K.; et al. Aβ is targeted to the vasculature in a mouse model of hereditary cerebral hemorrhage with amyloidosis. *Nat. Neurosci.* **2004**, *7*, 954–960. [[CrossRef](#)]

