

# Diagnostic role of ultrasound elastography for nail bed involvement in psoriasis

Kiyasettin Asil, MD<sup>a,\*</sup>, Mahizer Yaldiz, MD<sup>b</sup>

## Abstract

**Objective:** Psoriasis is a chronic inflammatory disease that affects the skin, joints, and nails. To investigate the efficacy of sonoelastographic evaluation for assessing nail involvement and severity in psoriasis.

**Materials and methods:** Thirty-one psoriasis patients and 31 healthy control subjects were included in the study. The nail thickness and nail bed thickness of the thumbs of all cases were measured by gray scale ultrasonography. In addition, the values of strain elastography were measured by sonoelastography.

**Results:** Of the participants, 38 were male and 24 were female; the ratio of males and females was equal in both groups. There was no significant difference between the patient and control group in terms of gender and age. In the patient group, the mean duration of illness was  $13.87 \pm 9.8$  years, mean PASI score was  $5.53 \pm 2.38$ , and mean NAPSI score was  $33.97 \pm 37.99$ . The nail plate thickness and elastography strain ratios were found to be statistically higher in the psoriasis group compared to the control group. There was also significant correlation between elastography strain ratios and nail thickness ( $P = .014$ ), nail bed thickness ( $P < .001$ ) and NAPSI scores ( $P = .01$ ).

**Conclusion:** Due to the superiority of ultrasound in real-time imaging of the nail structure and the compatibility of sonographic elastography with clinical scores in the assessment of the nail bed, we believe that it can be used as a complementary method.

**Abbreviations:** HFUS = high frequency ultrasonography, PASI = psoriasis area severity index, pNAPSI = nail psoriasis severity index of thumb scores of psoriasis, tNAPSI = total nail psoriasis severity index.

**Keywords:** elastography, nail bed, psoriasis

## 1. Introduction

Psoriasis is a chronic and systemic inflammatory disease that affects the skin, joints, and nails with prevalence of 1% to 3%.<sup>[1,2]</sup> Up to 90% of patients with psoriasis develop nail involvement over their lifetimes. Nail involvement has been shown as a clinical determinant of psoriatic arthritis.<sup>[3]</sup> Nail psoriasis is evaluated traditionally and diagnosed clinically. Disease severity and response to treatment are usually measured

using the clinical scoring system. Clinical scoring is often used for research purposes, but due to its time-consuming nature, it is not widespread in daily clinical practice, and moreover, clinical scoring systems subjectively assess the variables and cannot evaluate subclinical nail involvement.<sup>[4-6]</sup> An ideal method for diagnosis should be easy to perform without causing subjective differences and shouldn't take too much time in clinical practice.

In this context, high frequency ultrasonography (HFUS) has emerged as an alternative approach for evaluating disease severity and morphological examination in psoriasis over the last few decades.<sup>[7-11]</sup> The advantages of HFUS are that it is widely accessible, low cost, noninvasive and practical, and allows quantitative evaluation.<sup>[12,13]</sup>

Most of the general-purpose ultrasound systems also provide the option of tissue-elasticity imaging. Sonoelastography evaluating tissue stiffness has been used in the last 20 years and applied to many diseases.<sup>[7-9]</sup> Sonoelastography is a relatively new technique with reported applications in skin pathologies, but its dermatological potential has not been adequately researched.<sup>[14-17]</sup>

The present study aimed to evaluate the use of sonoelastography in assessing nail involvement and severity in patients with psoriasis.

## 2. Materials-method

Thirty-one patients with psoriasis, and 31 healthy controls having no chronic inflammatory disease, recruited from dermatology outpatient clinic, were included in the study. The inclusion criteria were absence of psoriatic arthritis or other chronic inflammatory disease, and age between 18 to 70 years. Patients who had lichen planus, nail dystrophy, traumatic nail,

Editor: Raouf Hajji.

All procedures performed in studies involving human participants were in accordance with the ethical standards of the institutional and/or national research committee (name of institute/committee) and with the 1964 Helsinki declaration and its later amendments or comparable ethical standards.

The authors have no funding and conflicts of interest to disclose.

<sup>a</sup> Department of Radiology, <sup>b</sup> Department of Dermatology, Sakarya University Training and Research Hospital, Sakarya, Turkey.

\* Correspondence: Kiyasettin Asil, Sakarya University Training and Research Hospital, Department of Radiology, Sakarya, Turkey (e-mail: drkiyasettin@gmail.com).

Copyright © 2019 the Author(s). Published by Wolters Kluwer Health, Inc. This is an open access article distributed under the terms of the Creative Commons Attribution-Non Commercial License 4.0 (CCBY-NC), where it is permissible to download, share, remix, transform, and build up the work provided it is properly cited. The work cannot be used commercially without permission from the journal.

How to cite this article: Asil K, Yaldiz M. Diagnostic role of ultrasound elastography for nail bed involvement in psoriasis. *Medicine* 2019;98:50(e17917).

Received: 4 May 2019 / Received in final form: 4 October 2019 / Accepted: 14 October 2019

<http://dx.doi.org/10.1097/MD.00000000000017917>

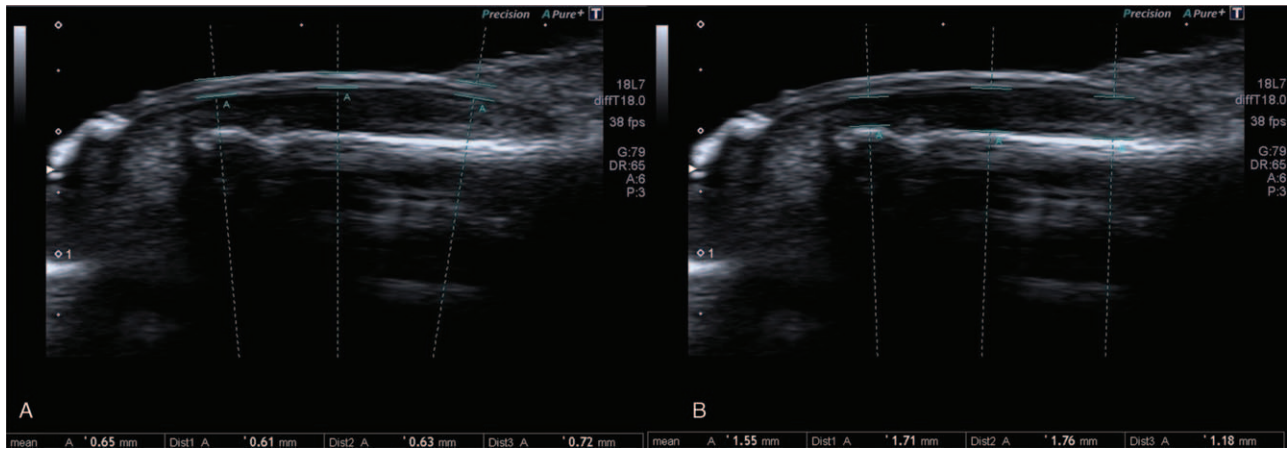


Figure 1. Show of nail thickness (A) and nail bed (B) measurements.

chronic paronychia, onychomycosis, etc. and who were diagnosed with any nail disease were excluded from the study. Prior to the study, local ethics committee approval (SUEK: 1614662/050.01.04/79) and a written informed consent was obtained from all participants.

After detailed anamnesis and physical examination, the study follow-up form was completed. The duration of disease, type of psoriasis, psoriasis area severity index (PASI), and total nail psoriasis severity index (tNAPSI) and nail psoriasis severity index of thumb (pNAPSI) scores of psoriasis patients with nail involvement were recorded.

Nail thickness and nail bed thickness of the subjects were measured in both thumb nails by the same physician using intima media preset of the gray scale ultrasonography (Toshiba Aplio

400 US, Otowara-shi, Japan, 4–18 MHz linear probe) while patients were sitting, and their hands were on the table in the neutral position. Measurements were taken from both thumb fingernails only and other fingers were not included in the examination. Three measurements were taken from each nail, (proximal, middle and distal) and the mean was calculated (Fig. 1). The freehand quasi-static method was used in the elastography. The strain ratio was calculated as the kPa value / normal tissue kPa value obtained from the root of the nail (Fig. 2). Nail thickness, nail bed thickness and strain ratios were compared between psoriasis patients with and without nail involvement clinically and with the control group. The patients with psoriasis were divided into two subgroups, with and without nail involvement. While 21 patients had psoriasis nail involvement, 10 patients with psoriasis had no

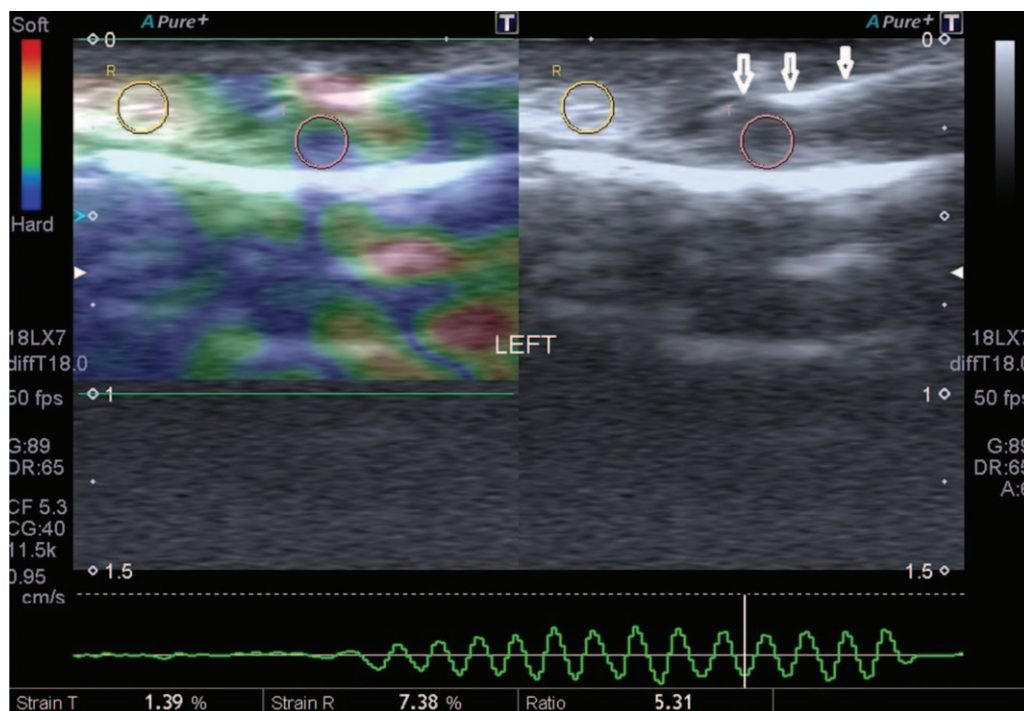


Figure 2. Demonstration of ultrasonographic elastogram measurement (arrows: nail).

**Table 1**  
Comparisons between patient group and control group (student *t* test).

	Mean ± Standart deviation		<i>P</i>
	Control	Patient	
Nail thickness	0.714 ± 0,196	0,812 ± 0,242	,022
Nail bed thickness	1,853 ± 0,369	1,828 ± 0,379	,004
Elastogram value	1,422 ± 0,623	8,342 ± 8,372	,008

*P* < .05 have been accepted as meaningful.

symptomatic nail involvement. In addition, the correlation between these data and the disease duration, PASI, total NAPSI, and pNAPSI values of the measured nail, was investigated.

SPPSS v.17 software program was used for statistical analysis. Chi-square was used for the comparison of categorical data and Student’s *t* test was used for the comparison of numerical values in both groups. Pearson correlation test and linear regression test were used to evaluate the correlation between variables. A measurement of 0.05 and 0.01 were accepted as statistically significant and highly significant, respectively.

### 3. Results

The 31 patients and 31 control subjects participated in the study. Of the participants, 38 were male and 24 were female; the ratio of males to females was equal in both groups. The mean age was 42.06 years in the patient group and 41.87 years in the control group. There was no significant difference between the patient and control group in terms of gender and age. In the patient group, the mean duration of illness was 13.87 years (standard deviation (SD) 9.8), mean PASI score was 5.53 (SD=2.38), and mean NAPSI score was 33.97 (SD=37.99).

The nail plate thickness was higher in the patient group than the control group whereas that of the nail bed was seen to be lower, indicating that the patient’s nail bed was thinner. Mean elastography strain ratios were higher in the patient compared to control group (Table 1). The mean elasto-graph value was 11,131 kPa in symptomatic patients and 4,686 kPa in psoriasis patients who were clinically asymptomatic (Table 2). In addition, there was a statistically significant difference between psoriasis patients without nail involvement and the control group in terms of elastography strain ratios (n=12; *P* =.000). A correlation was detected between elastography strain ratios and age (*P* =.002, Table 3). There was also significant correlation between elastography strain ratios and nail bed thickness (*P* =.014) and NAPSI scores (*P* =.01) and a correlation with nail thickness. However, elastography did not correlate with disease duration

**Table 2**  
Comparisons between asymptomatic patient group (plaque psoriasis without nail involvement) and symptomatic patient group (plaque psoriasis with nail psoriasis) (student *t* test).

	Mean ± Standart deviation		<i>P</i>
	Asymptomatic n:10	Symptomatic n:21	
Nail thickness	0.710 ± 0.171	0.861 ± 0.256	.009
Nail bed thickness	1.664 ± 0.339	1.906 ± 0.375	.002
Elastogram value	4.686 ± 6.265	11.131 ± 8.726	.000

*P* < .05 have been accepted as meaningful.

**Table 3**  
Ultrasonographic elastogram correlation table in patients (Pearson correlation test).

	<i>r</i>	<i>P</i>
Age	0.378	.002*
Nail thickness (mean)	0.310	.014**
Nail bed thickness (mean)	0.501	.000***
PASI	0.038	.770
NAPSI	0.426	.01***
Duration of illness (month)	−0.027	.838

*P* < .05 have been accepted as meaningful.

**Table 4**  
Correlation of thumb NAPSI values of ultrasonographic elastogram values (Pearson correlation test).

	<i>r</i>	<i>P</i>
rpNAPSI	0.586	.001***
lpNAPSI	0.416	.02*

lpNAPSI=left thumb NAPSI, rpNAPSI=right thumb NAPSI. *P* < .05 have been accepted as meaningful.

and PASI values (Table 3). A correlation was also found between elastography strain ratios and NAPSI scores of both right and left thumbs (Table 4). Excluding the age variable, there was a correlation between elastography strain rates and the thickness of both thumb nail beds. (Table 5 and Figs. 1 and 2).

### 4. Discussion

According to our results, there was a statistically significant difference between nail plate and nail bed thickness and elastography strain ratios in patients with psoriasis when compared to the control group. Besides, there was a statistically significant difference between the control group and psoriasis patients without nail involvement in terms of elastography strain ratios. We also found a correlation between elastography strain ratios and tNAPSI, pNAPSI, nail plate, and nail bed thickness in psoriasis patients.

The diagnosis of nail psoriasis is usually only done by clinical examination, and sometimes, it is required to scrape the nail surface to search for fungal infection and exclude onychomycosis. Nail biopsy is not a routine procedure, as it is a painful procedure and can cause permanent damage to the nail. Therefore, noninvasive methods that complement the clinical examination of the nails have been searched for. Magnetic

**Table 5**  
Correlation of ultrasonographic elastogram evaluation with nail and nail bed thicknesses in all patient cases when age limit was excluded (linear regression analysis).

	<i>r</i>	<i>P</i>
Right nail thickness	1.090	.285
Right nail bed thickness	2.308	.029
Left nail thickness	1.903	.067
Left nail bed thickness	2.052	.048

*P* < .05 have been accepted as meaningful.

resonance imaging and optical coherence tomography are recommended, but they have no widespread accessibility and are expensive.<sup>[18,19]</sup> The advantage of ultrasound is easy access, low cost, it is noninvasive, there is no need to use drugs, and it allows detailed visualization of real time and high-resolution nail anatomy.<sup>[8–10]</sup> In their publication, Moreno Mireia et al stated that the measurements of nail thickness and bed have good consistency between the observer and the observer. A healthy nail consists of dorsal and ventral plates consisting of 2 hyperechoic layers with hypoechoic space between them which can be seen on the ultrasound image.<sup>[11]</sup> In a study comparing psoriasis and control groups in terms of nail plate and nail bed thickness with the ultrasound, nail plate and nail bed thickness were found to be statistically higher in the psoriasis group.<sup>[20]</sup> Gutierrez et al<sup>[11]</sup> found that nail bed thickness of the right hand second finger was 3 mm in the psoriasis group and it was 1.5 mm in the control group. Ally Essayed et al<sup>[21]</sup> assessed clinical studies of nails with ultrasound in 2015 and reported that ultrasound increased diagnostic accuracy with clinical examination and was useful in avoiding invasive procedures, such as nail biopsy, cosmetic abnormalities, and long diagnostic periods. Krajewska-Wlodarczyk<sup>[22]</sup> and Moreno et al<sup>[23]</sup> reported that the nail thickened in accordance with our study. In addition, in the Moreno et al<sup>[23]</sup> study, nail bed thickness decreased as in our study in psoriatic patients. Therefore, our findings regarding the ultrasonographic evaluation of the nail supported the results in the literature. Unlike other studies, we evaluated nail involvement and nail elasticity using elastography and found that nail bed thickness and NAPS scores were correlated with the elastography findings. We think that elastography is a supportive imaging method for the diagnosis and follow-up of nail psoriasis.

Elasticity is the ability of a tissue to be deformed by an applied external force and to be able to return to its original shape and size when the external force is removed. Tissue deformation is inversely proportional to the tissue stiffness. Ultrasound elastography is the most commonly used technique for tissue elasticity mapping.

Skin diseases, such as psoriasis and scleroderma, skin burns, skin aging, and changes in epidermal hydration may cause changes in skin elasticity.<sup>[17,24]</sup> Nail psoriasis may cause thickening of the nail bed and nail plate and might alter in elasticity of the nail. In our study, nail bed kPa values were statistically significantly higher in patients with psoriasis compared to the control group. In addition, kPa values were correlated with NAPS score and nail bed thickness, which are involved in the clinical evaluation of nail involvement. These results suggest that ultrasound elastography is a noninvasive imaging modality that can support the clinic and assess nail involvement.

In previous studies, the thumb nail on the dominant hand is typically affected by nail involvement in psoriasis.<sup>[25]</sup> In our study, there was a correlation between NAPS scores of both thumbs according to the elastography imaging appearance, as well as a correlation between the right-hand thumbs which was more noticeable. This finding was associated with dominant use of right hand in our society.

Ultrasound elastography examination of the nail bed is technically patient and user-dependent even if it is easily accessible with newly developed ultrasonography devices and probe technology, non-radiative, non-invasive and cost-effective. Tremors on the patient's finger, excessive pressure on the base of the patient's fingers, deformities on the patient's fingers,

inaccurate preset settings of the user and probe selection, and lack of experience and capability during maneuvering of the probe adversely affects measurement. The limiting and challenging factors for this examination can be minimized by ultrasonic devices involving elastography with the share-wave method.

Psoriasis, a common dermatosis, is usually accompanied by nail involvement. The treatment of nail involvement is quite difficult. The use of different scoring systems in clinical trials to evaluate the disease severity for psoriatic nail treatment makes the comparison of results difficult. The diversity of nail symptoms also complicates the objective assessment of the severity of nail involvement. In our study, values in patients with plaque psoriasis but without psoriatic nail involvement may be significant in determining the severity of psoriasis. Thus, the incidence of psoriatic arthritis can be reduced with early treatment. In conclusion, we believe that elastography can be used as a complementary method to clinical evaluation for diagnosis of nail psoriasis, and determining the severity of nail involvement as well as evaluation of response to therapy since it is a relatively objective method that allows real-time nail imaging and correlates with clinical findings. In addition, if the share-wave method is used in conjunction with the elastographic method, we think that the measurements taken will be more standardized because it will be independent from user bias.

## Author contributions

**Conceptualization:** Kiyasettin Asil.

**Data curation:** Kiyasettin Asil, Mahizer Yaldiz.

**Formal analysis:** Kiyasettin Asil, Mahizer Yaldiz.

**Methodology:** Kiyasettin Asil, Mahizer Yaldiz.

**Software:** Kiyasettin Asil, Mahizer Yaldiz.

**Supervision:** Kiyasettin Asil, Mahizer Yaldiz.

**Visualization:** Kiyasettin Asil, Mahizer Yaldiz.

**Writing – original draft:** Kiyasettin Asil, Mahizer Yaldiz.

## References

- [1] Menter A, Gottlieb A, Feldman SR, et al. Guidelines of care for the management of psoriasis and psoriatic arthritis: Section Overview of psoriasis and guidelines of care for the treatment of psoriasis with biologics. *J Am Acad Dermatol* 2008;58:826–50.
- [2] Cohen SN, Baron SE, Archer CB. British Association of Dermatologists and Royal College of General Practitioners. Guidance on the diagnosis and clinical management of psoriasis. *Clin Exp Dermatol* 2012;37:13–8.
- [3] Wilson FC, Icen M, Crowson CS, et al. Incidence and clinical predictors of psoriatic arthritis in patients with psoriasis: a population-based study. *Arthritis Rheum* 2009;61:233–9.
- [4] Kaçar N, Ergin Ş, Erdoğan BŞ. Psoriatic tırnak şiddetinin ölçümünde iki skorlama sisteminin karşılaştırılması. *Türkiye Klinikleri J Dermatol* 2006;16:160–2.
- [5] Rich P, Scher RK. Nail Psoriasis severity Index: a useful tool for evaluation of nail psoriasis. *J Am Acad Dermatol* 2003;49:206–12.
- [6] Baran RL. A nail psoriasis severity index. *Br J Dermatol* 2004;150:568–9.
- [7] Di Nardo A, Seidenari S, Giannetti A. B-scanning evaluation with image analysis of psoriatic skin. *Exp Dermatol* 1992;1:121–5.
- [8] Vaillant L, Berson M, Macher L, et al. Ultrasound imaging of psoriatic skin: a noninvasive technique to evaluate treatment of psoriasis. *Int J Dermatol* 1994;33:786–90.
- [9] Hoffmann K, Dirschka T, Schwarze H, et al. 20 MHz sonography, colorimetry and image analysis in the evaluation of psoriasis vulgaris. *J Dermatol Sci* 1995;9:103–10.
- [10] Gupta AK, Turnbull DH, Harasiewicz KA, et al. The use of high-frequency ultrasound as a method of assessing the severity of a plaque of psoriasis. *Arch Dermatol* 1996;132:658–62.

- [11] Gutierrez M, Wortsman X, Filippucci E, et al. High-frequency sonography in the evaluation of psoriasis: nail and skin involvement. *J Ultrasound Med* 2009;28:1569–74.
- [12] Schmid-Wendtner MH, Burgdorf W. Ultrasound scanning in dermatology. *Arch Dermatol* 2005;141:217–24.
- [13] Jemec GB, Gniadecka M, Ulrich J. Ultrasound in dermatology. Part I. High frequency ultrasound. *Eur J Dermatol* 2000;10:492–7.
- [14] Gaspari R, Blehar D, Mendoza M, et al. Use of ultrasound elastography for skin and subcutaneous abscesses. *J Ultrasound Med* 2009;28:855–60.
- [15] Iagnocco A, Kaloudi O, Perella C, et al. Ultrasound elastography assessment of skin involvement in systemic sclerosis: lights and shadows. *J Rheumatol* 2010;37:1688–91.
- [16] Deprez JF, Brusseau E, Fromageau J, et al. On the potential of ultrasound elastography for pressure ulcer early detection. *Med Phys* 2011;38:1943–50.
- [17] Cucoş M, Crişan M, Lenghel M, et al. Conventional ultrasonography and sonoelastography in the assessment of plaque psoriasis under topical corticosteroid treatment-work in progress. *Med Ultrason* 2014;16:107–13.
- [18] Dalbeth N1, Pui K, Lobo M, et al. Nail disease in psoriatic arthritis: distal phalangeal bone edema detected by magnetic resonance imaging predicts development of onycholysis and hyperkeratosis. *J Rheumatol* 2012;39:841–3.
- [19] Sattler E, Kaestle R, Rothmund G, et al. Confocal laser scanning microscopy, optical coherence tomography and trans onychial waterloss for in vivo investigation of nails. *Br J Dermatol* 2012;166:740–6.
- [20] Gisondi P, Idolazzi L, Girolomani G. Ultrasonography reveals nail thickening in patients with chronic plaque psoriasis. *Arch Dermatol res* 2012;304:727–32.
- [21] Alley Essayed SM, Al-Shatouri MA, Allah YSN, et al. Ultrasonographic characterization of the nails in patients with psoriasis and onychomycosis. *Egypt J Radiol Nucl Med* 2015;46:733–9.
- [22] Krajewska-Włodarczyk M, Owczarczyk-Saczonek A, Placek W, et al. Ultrasound assessment of changes in nails in psoriasis and psoriatic arthritis. *Biomed Res Int* 2018;9:8251097.
- [23] Moreno M, Lisbona MP, Gallardo F, et al. Ultrasound assessment of psoriatic onychopathy: a cross-sectional study comparing psoriatic onychopathy with onychomycosis. *Acta Derm Venereol* 2019;99:164–9.
- [24] Vogt M, Ermert H. Development and evaluation of a highfrequency ultrasound-based system for in vivo strain imaging of the skin. *IEEE Trans Ultrason Ferroelectr Freq Control* 2005;52:375–85.
- [25] Ash ZR1, Tinazzi I, Gallego CC, et al. Psoriasis patients with nail disease have a greater magnitude of underlying systemic subclinical anthesopathy than those with normal nails. *Ann Rheum Dis* 2012;71:553–6.