

Washington University School of Medicine

Digital Commons@Becker

Open Access Publications

2019

Small bowel obstruction secondary to wild banana seed ingestion

Divya K Natarajan

Phonexay Homthavong

Indi Trehan

Follow this and additional works at: https://digitalcommons.wustl.edu/open_access_pubs

Images in Clinical Tropical Medicine

Small Bowel Obstruction Secondary to Wild Banana Seed Ingestion

Divya K. Natarajan,¹ Phonexay Homthavong,^{2,3} and Indi Trehan^{1,2*}

¹Department of Pediatrics, Washington University in St. Louis, St. Louis, Missouri; ²Lao Friends Hospital for Children, Luang Prabang, Lao PDR; ³Luang Prabang Provincial Hospital, Luang Prabang, Lao PDR

A previously healthy 13-year-old boy from a rural village in northern Laos presented with progressive abdominal pain, constipation, emesis, and marked abdominal distention. Radiographs showed a small bowel obstruction which did not resolve with conservative management (Figure 1). At laparotomy, a bezoar was identified as the cause of his bowel obstruction (Figure 2). Resection of the mass identified a phytobezoar of banana seeds (Figure 3). The patient tolerated surgery well and had an unremarkable postoperative course.

Further history obtained postoperatively revealed that before presentation, the patient was hungry and foraging for food for several days as his family was without means and reliable access to food. He chanced on a wild banana tree and indulged in its fruits.

The offending fruit, *Musa balbisiana*, is a wild banana species native to Southeast Asia, spanning from India to Papua New Guinea (Figure 4). Ingestion of the fruit seeds is known to cause intestinal complications, including constipation, appendicitis, and small bowel obstruction, most commonly in rural, impoverished populations because of limited access to safe nutrition.^{1–4} Despite local wisdom to avoid these dangerous fruits and multiple reports of wild

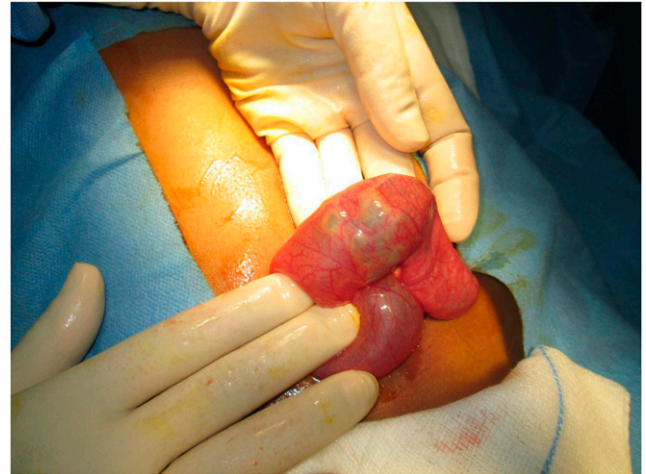

FIGURE 2. Intraoperative finding of bezoar causing bowel obstruction. Individual banana seeds are visible through the intestinal lumen. This figure appears in color at www.ajtmh.org.

banana ingestion–related bowel obstruction, cases like this demonstrate the impact that food insecurity and starvation can have on impoverished populations.

Received August 8, 2019. Accepted for publication August 16, 2019.

Authors' addresses: Divya K. Natarajan, Department of Pediatrics, Washington University in St. Louis, St. Louis, MO, E-mail: dknatar@wustl.edu. Phonexay Homthavong, Luang Prabang Provincial Hospital,

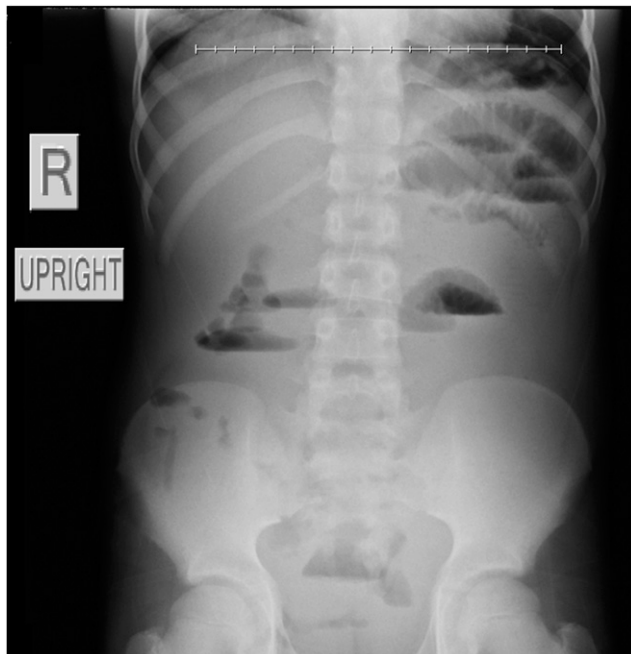


FIGURE 1. Abdominal X-ray demonstrating small bowel obstruction.



FIGURE 3. Phytobezoar specimens extracted from the bowel. This figure appears in color at www.ajtmh.org.

* Address correspondence to Indi Trehan, Indi Trehan, One Children's Place, Campus Box 8116, St. Louis, MO 63110. E-mail: indi@alum.berkeley.edu



FIGURE 4. Wild banana plant *Musa balbisiana* native to Southeast Asia depicting large seeds capable of causing intestinal obstruction through formation of phytobezoar. (Image courtesy of Scott Zona.) This figure appears in color at www.ajtmh.org.

Luang Prabang, Lao PDR, E-mail: phonexay23866868@gmail.com. Indi Trehan, Department of Pediatrics, Washington University in St. Louis, St. Louis, MO and Lao Friends Hospital for Children, Luang Prabang, Lao PDR, E-mail: indi@alum.berkeley.edu.

This is an open-access article distributed under the terms of the Creative Commons Attribution License, which permits unrestricted use, distribution, and reproduction in any medium, provided the original author and source are credited.

REFERENCES

1. Chai FY, Heng SS, Asilah SM, Adila IN, Tan YE, Chong HC, 2016. Wild banana seed phytobezoar rectal impaction causing intestinal obstruction. *Indian J Surg* 78: 326–328.
2. Schoeffl V, Varatorn R, Blinnikov O, Vidamaly V, 2004. Intestinal obstruction due to phytobezoars of banana seeds: a case report. *Asian J Surg* 27: 348–351.
3. Slesak G, Mounlaphome K, Inthalad S, Phoutsavath O, Mayxay M, Newton PN, 2011. Bowel obstruction from wild bananas: a neglected health problem in Laos. *Trop Doct* 41: 85–90.
4. Manatakis DK, Acheimastos V, Antonopoulou MI, Balalis D, Korkolis DP, 2019. Gastrointestinal seed bezoars: a systematic review of case reports and case series. *Cureus* 11: e4686.