



## Pakistan Journal of Neurological Sciences (PJNS)

Volume 14 | Issue 4

Article 4

12-2019

### Cerebral venous sinus thrombosis with positive Dengue serology

Sajid Hameed

*Aga Khan University, Karachi*

Owais Hashmat

*Aga Khan University, Karachi*

Mubashar Memon

*Aga Khan University, Karachi*

Muhammad Wasay

*Aga Khan University Karachi*

Follow this and additional works at: <https://ecommons.aku.edu/pjns>

 Part of the [Neurology Commons](#)

#### Recommended Citation

Hameed, Sajid; Hashmat, Owais; Memon, Mubashar; and Wasay, Muhammad (2019) "Cerebral venous sinus thrombosis with positive Dengue serology," *Pakistan Journal of Neurological Sciences (PJNS)*: Vol. 14 : Iss. 4 , Article 4.

Available at: <https://ecommons.aku.edu/pjns/vol14/iss4/4>

# CEREBRAL VENOUS SINUS THROMBOSIS WITH POSITIVE DENGUE SEROLOGY

Sajid Hameed<sup>1</sup>, Owais Hashmat<sup>2</sup>, Mubashar Memon<sup>3</sup>, Muhammad Wasay<sup>4</sup>

<sup>1,2,3,4</sup>Neurology, Aga Khan University, Karachi, Pakistan

Correspondence to: Sajid Hameed, Email: sajid.hameed@aku.edu

Date of submission: July 28, 2019 Date of revision: September 12, 2019 Date of acceptance: September 25, 2019

## ABSTRACT:

Dengue fever is a viral febrile illness caused by dengue virus and spread by Aedes mosquito worldwide. It usually manifests as an acute fever associated with body ache, skin rash, and thrombocytopenia. Neurological manifestations are relatively uncommon but well-known. We report a case of a 25-year-old male patient who presented to our hospital with acute febrile illness, headache, and vomiting. Extensive laboratory investigations were done and he was diagnosed with cerebral venous sinus thrombosis. Dengue serology was positive. He was treated with anticoagulation and hydration with complete recovery. The treatment with anticoagulation is challenging due to accompanying thrombocytopenia. Only two previous case reports of cerebral venous sinus thrombosis with positive dengue serology have been reported in the literature.

**KEY WORDS:** cerebral venous sinus thrombosis, dengue fever, CVST, anticoagulation, thrombocytopenia

A 25-year-old man presented to our hospital with an eight-day history of high-grade fever, associated with generalized body ache and vomiting. For the past two days, he also complained of blurry vision and headache. Past medical history was unremarkable. Physical examination revealed a blood pressure of 104/66 mmHg, a pulse of 104 per minute and a temperature of 102oF. He was awake with intact higher mental functions. Cranial nerves were intact. He had a painless maculopapular rash over his left arm. The neck was supple. His fundus showed bilateral papilledema. Motor examination revealed a mild right upper limb weakness with the Medical Research Council (MRC) grading of 4/5. Motor strength was normal in remaining limbs. Deep tendon reflexes were normal. Sensory and cerebellar examination was unremarkable.

Laboratory investigations revealed thrombocytopenia with a platelet count of 77,000/cmm, a white cell count of 13,000/cmm with 88.9% neutrophils, and a hemoglobin of 12 g/dL. Liver enzymes were elevated with aspartate aminotransferase (AST) of 59 IU/L (Normal <35 IU/L) and alanine aminotransferase (ALT) of 222 IU/L (Normal <45 IU/L). Further testing revealed positive IgM antibodies against the dengue virus. Malarial parasite was not detected. We did not test for

chikungunya virus or other arboviruses. Cranial magnetic resonance imaging (MRI) with venogram was performed (Figure 1), which revealed filling defects in the right transverse sinus, right sigmoid sinus, straight sinus and superior sagittal sinus representing cerebral venous sinus thrombosis. Electroencephalography (EEG) showed diffuse slowing suggestive of encephalopathy. No epileptiform discharges were seen. An extensive laboratory evaluation for hypercoagulable states was negative.

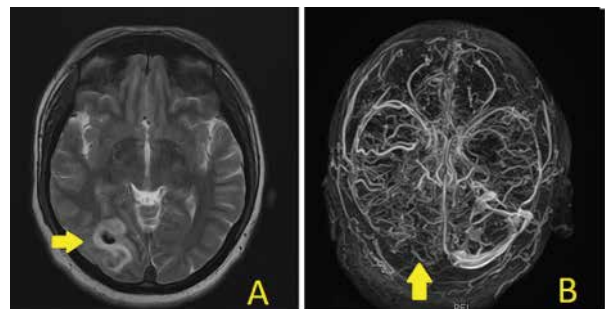


Figure 1: Magnetic Resonance Imaging (MRI) of brain showing hemorrhagic infarct in the right parietal lobe (yellow arrow in panel A). Magnetic resonance venogram showing non-visualization of right transverse sinus (yellow arrow in panel B).

He was diagnosed with cerebral venous sinus thrombosis (CVST) secondary to dengue infection. He was managed with intravenous hydration, acetaminophen, and anticoagulation with subcutaneous enoxaparin 1 mg per kg every 12-hourly, which was later switched to rivaroxaban 20 mg once daily. Platelet counts were monitored twice a day. On the 2nd day of admission, he had one episode of generalized-onset tonic-clonic seizure. There was no past history or family history of seizures. He was started on levetiracetam 500 mg twice daily. On the 4th day of hospital admission, his blurring vision and headache improved. His right arm weakness recovered completely at the time of discharge.

### DISCUSSION:

Dengue viral fever is an acute febrile illness presenting with fever, headache, joint and muscle pain, and decreased platelets (thrombocytopenia). It is caused by a dengue virus (DENV), which is an arbovirus belonging to the Flaviviridae family. DENV is transmitted by the bites of female *Aedes* mosquitoes, *Aedes aegypti* and *Aedes albopictus*. DENV has four serotypes (DENV-1 through DENV-4) [1]. Dengue fever is currently a pandemic condition. According to the statistics by the World Health Organization (WHO), approximately 400 million dengue viral infections occur annually. This number is still under-reported as a large number of cases are asymptomatic, mildly symptomatic and self-managed, or misdiagnosed as other febrile illnesses [2]. The WHO reported more than 47,000 cases of dengue fever in Pakistan in four months from July to November 2019, with 75 confirmed deaths [3]. Neurological manifestations associated with dengue viral fever are uncommon but well-known and occur in about 1% of total cases [4]. The neurological manifestations include meningoencephalitis, Guillain-Barre syndrome (GBS), acute disseminated encephalomyelitis (ADEM), transverse myelitis, stroke, and cranial nerve pathologies, with meningoencephalitis being the most common neurological manifestation [5,6]. Although thrombocytopenia is one of the cardinal features of dengue fever and increases the risk of bleeding, the cases of large vessel thrombosis have been reported [7]. A number of factors have been suggested with dengue fever that increase the risk of thrombosis. Dengue virus enhances thrombomodulin expression by activating endothelial cells. Activated protein C is downregulated due to thrombomodulin-thrombin-protein C complex formation. Low antithrombin III and protein C and S levels were previously found in severe dengue but in our case, no similar risk factors were seen [8]. Cerebral venous sinus thrombosis (CVST) is one of the rare

thrombotic complications associated with dengue fever and previously only two case reports have been reported in the literature [9,10]. This is the first case from Pakistan.

Anticoagulation is the main treatment strategy for CVST, even in hemorrhagic CVST [11]. The decision to anticoagulate in patients with CVST and positive dengue serology is challenging due to accompanying thrombocytopenia. Vasanthi et al. [9] managed their patient with parenteral fluids replacement only and did not institute anticoagulation therapy. However, Tilara et al. [10] administered anticoagulation with subcutaneous low molecular weight heparin in their case. We initially managed our patient with therapeutic subcutaneous enoxaparin followed by oral rivaroxaban, along with parenteral hydration. We monitored platelet counts twice daily. Our plan was to continue anticoagulation for at least three months and transfuse platelets if the platelet count decreased below 50,000/cmm or the patient had symptomatic bleeding but none of these complications occurred. In all the cases of dengue virus-associated CVST, including our case, the patients achieved complete neurological recovery.

### CONCLUSION:

Cerebral venous sinus thrombosis is rarely associated with dengue fever. Anticoagulation and parenteral fluid replacement are the main treatment regimens for patients with CVST. The serial platelet counts and the risk of bleeding should be assessed when treating with anticoagulation in these patients. The prognosis is excellent with complete recovery in all three cases reported to date.

## REFERENCES:

1. Hesse RR. Dengue virus evolution and virulence models. *Clinical Infectious Diseases*. 2007 Jun 1;44(11):1462-6.
2. Cogan JE. Dengue and severe dengue [Internet]. World Health Organization. 2019 [cited 12 December 2019]. Available from: <https://www.who.int/news-room/fact-sheets/detail/dengue-and-severe-dengue>
3. World Health Organization. Dengue fever – Pakistan [Internet]. 2019. [cited 12 December 2019]. Available from: <https://www.who.int/csr/don/19-november-2019-dengue-pakistan/en/>
4. Carod-Artal FJ, Wichmann O, Farrar J, Gascón J. Neurological complications of dengue virus infection. *The Lancet Neurology*. 2013 Sep 1;12(9):906-19.
5. Misra UK, Kalita J, Syam UK, Dhole TN. Neurological manifestations of dengue virus infection. *Journal of the neurological sciences*. 2006 May 15;244(1-2):117-22.
6. Solomon T, Dung NM, Vaughn DW, et al. Neurological manifestations of dengue infection. *The Lancet*. 2000 Mar 25;355(9209):1053-9.
7. da Costa PS, Ribeiro GM, Junior CS, da Costa Campos L. Severe thrombotic events associated with dengue fever, Brazil. *The American journal of tropical medicine and hygiene*. 2012 Oct 3;87(4):741-2.
8. Roy A, Chaudhuri JA, Chakraborty S. Deep vein thrombosis associated with dengue fever. *Indian Pediatr*. 2013 Nov 1;50(11):1053.
9. Vasanthi N, Vairamon PM, Gowtham T, Das AK. Unusual presentation of dengue fever-cerebral venous thrombosis. *Journal of clinical and diagnostic research: JCDR*. 2015 Jun;9(6):OD09.
10. Tilara M, Shah AN, Negi S, Dadhania J. A Case of Cerebral Venous Thrombosis in the Patient with Dengue. *International Journal of Scientific and Research Publications*. 2014 Aug;4(8):1-1.
11. Khan M, Kamal AK, Wasay M. Controversies of treatment modalities for cerebral venous thrombosis. *Stroke research and treatment*. 2010;2010.

Conflict of interest: Author declares no conflict of interest.

Funding disclosure: Nil

Author's contribution:

**Sajid Hameed**; concept, data collection, data analysis, manuscript writing, manuscript review

**Owais Hashmat**; concept, data analysis, manuscript writing, manuscript review

**Mubashar Memon**; data analysis, manuscript writing, manuscript review

**Muhammad Wasay**; data analysis, manuscript writing, manuscript review