


Photochemical & Photobiological Sciences

Accepted Manuscript



This article can be cited before page numbers have been issued, to do this please use: M. D. Marquioni-Ramella and A. Suburo, *Photochem. Photobiol. Sci.*, 2015, DOI: 10.1039/C5PP00188A.



This is an *Accepted Manuscript*, which has been through the Royal Society of Chemistry peer review process and has been accepted for publication.

Accepted Manuscripts are published online shortly after acceptance, before technical editing, formatting and proof reading. Using this free service, authors can make their results available to the community, in citable form, before we publish the edited article. We will replace this *Accepted Manuscript* with the edited and formatted *Advance Article* as soon as it is available.

You can find more information about *Accepted Manuscripts* in the [Information for Authors](#).

Please note that technical editing may introduce minor changes to the text and/or graphics, which may alter content. The journal's standard [Terms & Conditions](#) and the [Ethical guidelines](#) still apply. In no event shall the Royal Society of Chemistry be held responsible for any errors or omissions in this *Accepted Manuscript* or any consequences arising from the use of any information it contains.

Photo-damage, Photo-protection and Age-related Macular Degeneration

Melisa Marquioni Ramella and Angela M. Suburo

Medicina Celular y Molecular, Facultad de Ciencias Biomédicas,

Universidad Austral, Pilar B1629AHJ, Buenos Aires, Argentina.

Acknowledgements. MMR is a Research Fellow funded by Universidad Austral and Consejo Nacional de Investigaciones Científicas y Técnicas (CONICET). AMS is Principal Researcher at CONICET. Our work was supported by grants from the ANPCyT (Argentina), PICT 2010-2632 and PICT 2013-3200. We are very grateful to Dr. Mariela Marazita for the careful reading of this manuscript.

Abstract

Age-related macular degeneration (AMD) is a degenerative retinal disease that causes blindness in people 60-65 years and older, with the highest prevalence appearing in people 90 years-old or more. Epidemiological estimates indicate that the number of cases is increasing, and will almost double in the next 20 years. Preventive measures require precise etiological knowledge. This is quite difficult, since AMD is a multifactorial condition with intricate relationships between causes and risk factors. In this review, we describe the impact of light on the structure and physiology of the retina and the pigment epithelium, taking into account the continuous exposure to natural and artificial light sources along the life of an individual. A large body of experimental evidence demonstrates the toxic effects of some lighting conditions on the retina and the pigment epithelium, and consensus exists about the importance of photo-oxidation phenomena in the causality chain between light and retinal damage. Here, we analyzed the transmission of light to the retina, and compared the aging human macula in healthy and diseased retinas, as shown by histology and non-invasive imaging systems. Finally, we have compared the putative retinal photo-sensitive molecular structures that might be involved in the genesis of AMD. The relationship between these compounds and retinal damage supports the hypothesis of light as an important initiating cause of AMD.

1. Introduction

The clinical and social importance of Age-related Macular Degeneration (AMD)

The retina is a photo-sensitive tissue that captures light and transforms it into electrical signals. The specialized cells that capture light include rods, specialized for nightlight vision, and cones, which are in charge of daylight and color vision. Rods contain the visual pigment rhodopsin that is sensitive to blue-green light (500 nm). Cones, instead, respond to short wavelengths (S-cones, 420 nm), medium wavelengths (M-cones, 530nm) and long wavelengths (L-cones, 560 nm).

Near the center of the retina, the macula lutea appears as a yellowish spot, including four anatomical regions: the perifovea, the parafovea, the fovea and the foveola. The perifovea shows a high density of retinal vessels and a high rod:cone ratio, although the density of cones and ganglion cells is higher than in the periphery. Almost 50% of the total ganglion cell population resides in the macula¹. Thus, the ganglion cell layer (GCL) shows more than one row, up to six cells deep, except at the foveola^{2,3}. The parafovea has a low density of retinal vessels and a rod:cone ratio close to 4:1. Cones become dominant in the slopes of the foveal pit, where vessels are restricted to a perifoveal capillary plexus. Narrowing and elongation of cones at the fovea are essential for visual acuity. Inner retinal layers are absent in the foveola, where photoreceptor cell bodies lie close to the vitreal surface².

AMD is a degenerative retinal disease that causes blindness in people 60-65 years and older, with the highest prevalence appearing in people 80 years-old or more⁴. Vision loss is preceded by early asymptomatic stages characterized by the presence of medium-sized

drusen (63-125 μm). The disease progresses to intermediate AMD with larger drusen and/or retinal pigment epithelium (RPE) alterations near the macula. The latter include hypo- or hyperpigmentation and accumulation of autofluorescent material (lipofuscin). In addition, multifocal electroretinography, optical coherence tomography (OCT), and spectral domain OCT (SD-OCT) have shown the presence of various photoreceptor changes^{5,6}.

Early AMD lesions further develop into one of the two forms of late disease: geographic atrophy (GA) or dry AMD, characterized by loss of RPE cells and photoreceptors; and neovascular (or wet) AMD⁷, where abnormally growing choroidal vessels invade the subretinal space between the RPE and the neural retina⁸.

With a global prevalence been estimated in 8.69 %⁹, AMD has replaced cataracts and refractive errors as the leading cause of blindness and severe vision impairment in higher-income regions such as Western Europe, Australia, USA, Japan¹⁰ and Southern Latin America¹¹. Current estimates suggest that the 2.07 million cases recorded in 2010 will become more than 5.00 million in 2050¹².

Etiopathogenesis of AMD

Chronic oxidant RPE injury, together with a low-level inflammatory response are important factors for development of early RPE lesions^{8, 13-15}. Thus, a high risk for AMD is associated to cigarette smoking¹⁶, which is a well-known oxidant^{17, 18}. Age is the main risk factor for developing AMD, but in most cases, genetic factors explain the overall severity of the disease¹⁹. That the most frequent factors associated to AMD are genetic variants facilitating inflammation²⁰, points at the existence of sustained stress in the retina and the

RPE. Two would be the most likely causes: exposure to environmental light and the visual transduction processes. Since both circumstances are unavoidable in ordinary life, the epidemiology of AMD arguments in favor of robust endogenous mechanisms quenching photo-oxidative stress. Light radiation reaching the retina and the RPE provoke oxidative stress, which is normally restrained by endogenous antioxidant systems and by mechanisms extinguishing the associated inflammation stress¹⁵. The main risk factors for AMD probably reflect the failure of these systems and mechanisms but still, photo-oxidation would be the initial pathogenic factor. As previously expressed by others, “prevention or attenuation of the initial oxidative injury will reduce the risk of developing AMD, regardless of genetic background”²¹.

The association between this disease and environmental light is mainly based on epidemiological grounds, and on the physical evidence explaining the interaction of light with ocular tissues. Therefore, we will first analyze transmission of light to the retina, and then we will describe the diseased macula, as shown by modern imaging procedures. Finally, we will evaluate the putative retinal photo-sensitive molecular structures that might be involved in the genesis of AMD, which have been mainly identified by experimental studies in animal species or *in vitro*.

2. Environmental light and AMD

Effects of environmental light on the course of AMD must depend on the light wavelengths and intensities reaching the retina. Ocular structures can interact with a broad portion of the spectrum, ranging between 100 and 10,000 nm and including visible

(750-400 nm), ultraviolet (UV-A, 400-320 nm; UV-B, 320-280 nm; UV-C, <280 nm) and infrared wavelengths^{22, 23}. However, almost no UV-C reaches earth's surface²⁴, and various natural ocular filters restrict radiation transmission to photoreceptors.

Sunlight

Retinal irradiance in daylight is in the 0.01 mW/cm² to 0.1 mW/cm² range, depending on time of day, season, presence of snow or water surfaces, wearing a hat, etc. Additionally, squinting, which prevents the formation of a sun image on the inferior retina, and photophobia, serve as biological protections against sun exposure^{25, 26}.

The average human retina absorbs each day approximately 10¹² to 10¹⁵ photons²⁷, which can be increased by workplace exposure or activities in high light environments. The association between sun exposure and AMD is controversial, since it has been found in some studies²⁸⁻³¹ but not in others³²⁻³⁴. However, a meta-analysis based on 14 epidemiological studies strongly supports the notion that more sunlight exposure increases risk for AMD³⁵. Research has also emphasized the protective role of hats and eyeglasses and has suggested the possible relevance of individual differences in the reaction to sunlight exposure^{36, 37}. Thus, the Age-related Maculopathy and Macular Degeneration in the elderly European populations (EUREYE) study only reported significant associations between blue-light exposure and neovascular AMD for individuals in the quartile of lowest dietary antioxidant level—vitamin C, zeaxanthin, vitamin E, and zinc³⁸.

Other light sources

Welding arcs emit a wide spectrum, ranging from infrared (IR) to ultraviolet (UV). The cornea and the lens absorb UV radiation, whereas water absorbs far-IR. Visible light and near-IR may reach the retina in the unprotected eye, producing an acute macular lesion that often results in a bilateral central scotoma accompanied by pigmentation alterations^{39, 40}. With only partial protection, UV light may generate corneal epithelial injury, whereas blue light destroys the center of the macula⁴⁰. In a more recent study, macular lesions were demonstrated using OCT in 38% of welders (n = 80, age mean = 36.9 years) that did not refer visual symptoms and showed no visual acuity problems⁴¹. Thus, it would be of great interest to study the evolution of these lesions with age.

Concern has been raised about domestic and vehicular lighting, increasingly dependent on light-emitting diodes (LEDs). Dissemination of these devices poses a potential problem for the retina since billboards, and emergency lights extensively use blue LEDs. As it will be explained in the last part of this review, the retina is particularly vulnerable to blue-light. Current regulations establishes that for an exposure greater than 10,000 s, the exposure limit value (ELV) for blue-light radiance is about 100 W/m²/sr (or 1.0 x10⁶ J m⁻² sr⁻¹)⁴².

Published spectral power distributions show that LEDs emit an intense blue-light component which is absent in the daylight spectra⁴³. Cold-white LEDs are particularly questionable, since they emit about 3-4 times as much energy in the blue-light risk portion of the spectrum as warm-white LEDs⁴³. Most important, due to their small size, it is relatively easy to produce LED sources of very high luminance that may generate visual discomfort⁴⁴. A publication from the Department of Energy, U.S. reported that “the

proportion of blue-light in the spectrum is not significantly higher for LEDs than it is for any other light source at the same correlated color temperature (CCT)⁴⁵. However, this report emphasized that safety could not be guaranteed for blue LEDs, nor for infants in close proximity to bright light sources.

Even though data from other species or *in vitro* cultures cannot be directly extrapolated to humans, we cannot disregard the experimental studies suggesting that LED blue irradiation might produce greater damage than other wavelengths. After exposure to 750 lux, retinal damage in rats occurred earlier in those exposed to blue and white (CCT 6,500 K) LEDs than in those exposed to white (CCT 6,500 K) or yellow compact fluorescent lamps (CFLs)⁴⁶. After 9 days under blue or white LEDs, the outer nuclear layer (ONL), containing photoreceptor nuclei, was reduced to about 1/3, whereas no significant changes appeared in rats exposed to CFLs⁴⁶. With a 3-day exposure, levels of superoxide anion in the retina were higher in those exposed to blue LEDs than in those exposed to white LEDs and CFLs. Using different commercially available blue LEDs, severe retinal damage was produced by radiances below the currently accepted ELV for blue-light⁴⁴. Experiments *in vitro* also support the damaging potential of blue and white LED. Under the same illuminance (2,500 lux) blue LED light damaged 661W cells (a line derived from mouse cones) more severely than white and green LED lights⁴⁷. Only blue and white LED light significantly reduced cell viability when 661W cultures were exposed under the same energy conditions (0.38 mW/cm²)⁴⁷. The question of artificial light sources in AMD etiopathogeny still requires more evidence; however, we cannot presently exclude their potential role as a significant hazard. Regulations are required to control glaring from billboards and emergency lights

because, in addition to their potential role in retinal photo-toxicity, they might also conspire against security⁴⁸.

The normal eye filters UV and blue light

Cornea and lens

The cornea and lens absorb all UV-C light and most UV-B²⁴. However, some UV-A radiation is transmitted, since it is about 10 times more abundant than UV-B in the solar spectrum^{24, 49}. Filtering in the human lens reflects the presence of tryptophan derivatives, the kynurenes, which block most of the incident light between 295 and 400 nm⁵⁰⁻⁵². Although kynurenes decrease with age, UV filtering properties of the human lens increase because these compounds form covalent bonds with crystallins⁵³. Advanced glycation end products (AGE) also contribute to lens UV-filters⁵¹. UV and blue-light transmission decrease linearly as a function of age⁵². In contrast, a higher fraction of this region of the spectrum reaches the young retina (< 8-10 years)⁴³, determining the rapid formation of lipofuscin in children⁵⁴.

A review, including a large number of studies (2003-2014), has shown clear-cut associations between cataract surgery and AMD. However, both increased transmission of short-wavelength light to the retina^{50, 55}, and/or an inflammatory response^{56, 57} could explain the greater risk for AMD. Since the aphakic eye loses most UV- and blue-light filtering properties^{50, 55}, it seems reasonable to replace cataractous lenses with intraocular lenses (IOLs) with those filtering properties. UV-filtering IOLs can be untinted or yellow-tinted. Compared with aphakic eyes, untinted IOLs allow a 60% reduction in

blue-light irradiance, whereas yellow-tinted IOLs confer an additional reduction (17 to 56%)⁵⁸.

The directly photo-sensitive retinal ganglion cells involved in the circadian rhythm are maximally sensitive to light at ~480 nm⁵⁹; therefore, concerns about tBoth the sleep-wake cycle following implantation of filtering IOLs have been raised⁶⁰. Decrease in the transmission of 480 nm light may occur, but it is very small compared to that of the aged lens. By the age of 80 years, transmission of 480 nm light is only 28% of the transmission in 10 year-old children⁶¹. A prospective study, including 961 participants has shown that sleep quality improves after removal of cataract, notwithstanding the type of IOL used⁶². Most important, the beneficial effect of blue-light filtering IOLs is strongly supported by a very recent study measuring the enlargement of the atrophic area in patients with dry AMD. After implantation of a non-blue filter IOL, this enlargement was almost twice as after implantation of a blue-blocking IOL⁶³.

Macular Pigment

Macular pigment (MP) is composed of the xanthophyll carotenoids: lutein, zeaxanthin, and meso-zeaxanthin⁶⁴. Xanthophylls gradually increase towards the center of the macula, and in the human fovea, they reach concentrations greater than 1 mM⁶⁵. The cause of this elevated concentration might be explained by the low activity of β,β -carotene-9',10'-dioxygenase, the only known mammalian enzyme that cleaves xanthophylls, which is much weaker in humans and primates than in other mammals⁶⁶. Xanthophylls accumulate preferentially in the outer and inner plexiform layers (ONL and INL) where they may be inserted in the plasma membrane, or associated with specific binding proteins⁶⁵. The

lutein : zeaxanthin : meso-zeaxanthin ratio changes progressively from 1 : 1 : 1 at the fovea to a ratio approaching 3 : 1 : 0 in the periphery. Since their peak absorbance is at 460 nm, and because they are located in the anterior (vitreal) portion of individual photoreceptors, macular pigments attenuate the amount of blue-light incident on the photoreceptors in the most sensitive region of the retina⁶⁷.

Macular pigment optical density (MPOD), which may be measured *in vitro* or *in vivo*^{68, 69}, is positively related to visual performance^{65, 70}. Blue-light filtering improves the visibility of distant objects, most likely because scattered light from haze aerosols suspended on the horizon is predominantly blue⁷¹. The implantation of blue-light filtering IOLs after cataract surgery is associated with augmentation of MPOD in the absence of raised serum concentrations of lutein and zeaxanthin⁵⁷, highlighting the efficacy of these molecules as blue filters. By contrast, in a sample of healthy volunteers (n = 828), MPOD levels were significantly and independently reduced by age, current and past smoking and AMD family history⁷².

After the Age-related Eye Disease Study (AREDS) provided level 1 evidence that supplementation with vitamins C and E, β -carotene and zinc resulted in a 25% risk reduction of progression from intermediate to advanced AMD⁷³, numerous clinical and epidemiological studies have tried to ascertain the putative protecting role of macular xanthophylls. Addition of lutein + zeaxanthin to the AREDS formulation did not further reduce the risk of progression to advanced AMD⁷⁴, and only a mild beneficial effect on visual acuity has been observed after a one-year lutein supplementation⁷⁵. However, functional abnormalities of the central retina in early AMD can be ameliorated by lutein

and zeaxanthin supplementation, an effect attributed to elevations in MPOD⁷⁶. A recent review concluded that supplementation with macular carotenoids is probably the best available measure to strengthen the antioxidant defenses of the macula, thus reducing the risk of AMD and/or its progression⁶⁷. Xanthophyll carotenoid supplementation in AMD would not only be significantly associated with improvements in visual acuity and contrast sensitivity, but also with a concomitant increase of MPOD⁷⁷. Results of carotenoid supplementation may depend on previous nutritional conditions and genetic risk status. Thus, in the Blue Mountains Eye and the Rotterdam studies, an interaction between lutein/zeaxanthin intake and early AMD incidence was only found in participants with high genetic risk (carriers of ≥ 2 risk alleles of CFH or ARMS2)⁷⁸. The impact of supplements containing different combinations of lutein, zeaxanthin and meso-zeaxanthin on visual function in normal subjects and subjects with early AMD is under investigation⁷⁹. Independently of their filtering function in the macula, carotenoids could serve as antioxidants in the macula and in the RPE. They protect against singlet oxygen mediated photo-oxidation reactions and can also react with free radicals⁸⁰. Thus, they would also reduce photo-oxidation of retinyl derivatives (such as A2-phosphatidylethanolamine and A2E, see below)^{81, 82}. Cultured RPE cells actively uptake lutein and zeaxanthin and these xanthophylls prevent photo-oxidative inactivation of the proteasome, and photo-oxidation induced changes in the expression of MCP-11, IL-8, and CFH⁸³. Zeaxanthin has direct anti-oxidant actions on RPE cells, including the induction of Nrf2-mediated phase II enzymes such as heme-oxygenase-1, NAD(P)H:quinone oxidoreductase and γ -glutamyl-cysteine ligase⁸⁴.

Melanin

Melanins, the heterogeneous polymers formed by tyrosinase (TYR) oxidation products of tyrosine, and L-DOPA (L-3,4-dihydroxyphenylalanine), are essential instruments for defense against UV exposure⁸⁵. Uveal melanocytes and RPE cells contain eumelanin and trace amounts of pheomelanin⁸⁶. Eumelanin, which has a broadband absorption spectrum smoothly decaying to the lower-energy end, can rapidly dissipate UV and blue-light energy as heat⁸⁷. Thus, eumelanin light absorption followed by rapid thermal relaxation could quench potentially harmful photo-chemical reactions. Melanin can also scavenge free radicals and reduce the oxidative stress resulting from lipid peroxidation and reactive oxygen species (ROS) production⁸⁸.

The function of melanin in sun photo-protection seems to be undeniable⁸⁶. Therefore, if sunlight is a stressing factor involved in the etiopathogenesis of AMD, melanin might be one of the anti-AMD defense mechanisms. In line with this hypothesis, AMD is more frequent in white persons than in persons of black African inheritance⁸⁹. Most studies also agree that white subjects with light blue-colored irises have a higher AMD prevalence than those with dark-colored irises⁸⁹. In the Beaver Dam Eye Study, increased risk of early AMD was found for persons with high sunlight exposure and light colored eyes (gray/blue), or light colored hair (blond/red)⁹⁰. Remarkably, initial recovery of patients with neovascular AMD after anti-VEGF treatment shows a seasonal oscillation that is inversely correlated with global radiation intensity⁹¹, and functional improvement is significantly higher in patients with dark-colored eyes than in those with light-colored eyes⁹¹. In addition, a

recent report suggests a possible relationship between early AMD and TYR single nucleotide polymorphisms (SNPs) previously associated with skin and eye pigmentation⁹². Quantitative observations in eyes from human cadaveric donors indicate a decrease in RPE melanin with age, most likely related to photo-oxidation^{93, 94}. Aging also affects melanosomes, and by age 90, most RPE melanin appears as melanolipofuscin⁹⁵. The latter can generate ROS upon excitation with blue light⁹⁶. Studies *in vitro* have shown that melanin may reduce the accumulation of lipofuscin in RPE cells⁹⁷, and the photo-oxidation of its components⁹⁸.

Pupillary diameter

The pupil modulates retinal illumination; consequently, it would also regulate retinal susceptibility to photo-toxicity. In eyes with little pigmentation, light might reach the retina by transmission through the iris and the sclera, possibly increasing the risk of light-induced damage⁹⁹.

Light sensitivity of the pupil constriction reflex seems to be unaffected by age¹⁰⁰; however, AMD patients confronted by a navigation task display larger pupillary diameters than controls of the same age and sex¹⁰¹. A larger pupillary diameter under the same luminance conditions might increase retinal light exposure and contribute to progression of the disease.

Light-induced damage

Electromagnetic radiation in the 100 nm⁻¹ mm range is widely known as “optical radiation”⁴². Light absorption by biological material implies energy transfer, which may be

damaging for absorbing tissues. Light-inflicted damage will depend on the specific combination of radiation wavelength, exposure time, tissue properties and volume²². Photo-chemical damage arises when a chromophore, or photo-sensitive molecule, undergoes physico-chemical changes after the absorption of a photon. In the eye, chromophores include visual pigments in the photoreceptors, the macular pigments, absorbing in the 400-530 nm range, and the broadband absorbers melanin and lipofuscin in the RPE and choroid²³. Effects of chromophore excitation may be transmitted to neighboring molecules, dissipating extra energy in various ways, including chemical bond splitting, hydrogen exchange and ROS production, such as singlet oxygen, superoxide, hydrogen peroxide and hydroxyl radicals. In turn, these radicals react with nearby molecules, inducing diverse photo-oxidative changes. Thus, photo-chemical damage is almost synonymous with photo-oxidative damage^{22, 102}. Cells may or may not repair these lesions depending on the irradiation intensity and the exposure time^{22, 23, 27, 103}. Spreading of photo-oxidative effects is particularly damaging in tissues with high concentration of cell membranes, such as photoreceptor outer segments¹⁰⁴. Oxidative stress contributes to photoreceptor cell death in animal models of retinal degeneration, including light-induced retinopathy^{105, 106}.

3. Macular damage in aging and AMD

Photoreceptors

Eyes from 40-year or older persons without significant ocular disease show loss of photoreceptor nuclei in the macular ONL, together with disappearance of outer segments,

but without defects in the RPE or the choriocapillaris¹⁰⁷. Quantitative microscopy studies in donor eyes demonstrated a steady decline in central rod number with age, without concomitant changes in cone numbers¹⁰⁸. Cones, however, displayed some morphological abnormalities, including lipofuscin deposition^{109, 110}. More recent studies have detected a significant thinning of the RPE and the choroid, together with an increase in the thickness of the OPL³, which in the macular region is known as the fiber layer of Henle. Greater OPL thickness most likely reflects activation and hypertrophy of Müller cells following photoreceptor loss¹¹¹. Aging eyes also exhibited a reduced thickness of the retinal nerve fiber layer (RFNL), GCL, inner plexiform layer (IPL), INL and photoreceptor inner segments, except at the fovea^{3, 112}. By contrast, width of the photoreceptor outer segment layer correlated positively with age, presumably reflecting the age-related decrease in RPE phagocytosis¹¹². The amount of parafoveal rods significantly decreased in aging retinas¹⁰⁸. Although changes in foveal cone numbers were not detected histologically¹⁰⁸, adaptive optics have shown that, in old age, cone packing density decreases up to 25% within 0.45 mm of the foveal center, but not in peripheral regions¹¹³⁻¹¹⁵.

Histological evaluation of dry AMD showed RPE irregularities and atrophy, whereas wet AMD samples displayed both RPE defects and fibrovascular scars¹⁰⁸. Foveal cone numbers showed few changes, but rods were almost completely lost in the parafovea. In the wet AMD samples, photoreceptors surviving in the neighborhood of disciform scars were largely cones¹⁰⁸. Since external light is focused on the cone-rich fovea, sparing of foveal cones suggests that they may be more resistant than rods to light-induced damage. Nevertheless, since they depend on the rod-derived cone viability factor (RdCVF)¹¹⁶, they

would disappear after demise of parafoveal rods. It has been demonstrated that RdCVF protects 661W cells from photooxidative damage¹¹⁷ and, most important, that RdCVF-deficient mice are extraordinarily sensitive to light-induced damage¹¹⁸.

Histological findings are supported by analysis of rod function¹¹⁹, and adaptive optics scanning laser ophthalmoscopy¹²⁰. Besides, AMD retinas also displayed reduced cone reflectivity, suggesting mild structural abnormalities¹²⁰. Additionally, scanning laser polarimetry studies indicated that the number of central cone photoreceptors may be lower, and/or structural alterations of their axons significantly higher, than in non-AMD eyes of the same age¹²¹. Reduction of the RPE/photoreceptor and ONL layers overlying drusen has been consistently found^{6, 122, 123}, but reports about their thinning in drusen-free areas¹²² need confirmation.

Loss of rod photoreceptors, with cone sparing, resembles the consequences of white light-induced damage in rodents, where cones remained after complete disappearance of rods¹²⁴. Remarkably, in rats maintained under cyclic lighting, the retinas of older animals suffered more damage from exposure to intense light than those of younger animals¹²⁵.

Retinal Pigment Epithelium and Lipofuscin

The outer segments of rods and cones are under constant renewal, with old discs being shed from the apical tip and phagocytosed by RPE cells^{126, 127}. A current development is the *in vivo* study of disc renewal in human cones through changes in their reflectance¹²⁸. Daily shed outer segments are phagocytosed by the RPE and processed using a combination of phagocytic and autophagic mechanisms where lysosomes are fused with autophagosomes. Since some autophagy characteristic proteins (LC3 and Atg5) appear in

the membrane of phagosomes, the process is known as non-canonical autophagy or LC3-associated phagocytosis^{129, 130}. Most of the material is recycled to the photoreceptors; however, the RPE accumulates lipofuscin, a non-digested heterogeneous substance, within the residual bodies of the lysosomal compartment¹³¹.

Lipofuscin distribution in the RPE shows a defined pattern, increasing from the equator to the posterior pole with a consistent dip at the macula. Curiously, melanin follows a contrasting distribution, decreasing from the equator to the posterior pole, but with a regular peak at the macula. This polarization fades by the age of 50, presumably because most melanin becomes incorporated into melanolipofuscin granules¹³².

Lipofuscin has a broad excitation range (300-600 nm) and a broad emission spectrum (480-800 nm), allowing histological and non-invasive studies of fundus autofluorescence¹³³. Wholemount studies of human donor retinas have shown that the topography of RPE autofluorescence follows the distribution of rod photoreceptors, being highest in the vicinity of the rod-rich perifoveal annulus¹³⁴. The highest autofluorescence levels were found in 80 years or more retinas¹³⁴. Older retinas displayed an increase of non-hexagonal shapes, without changes in RPE cell density¹³⁴. Degranulation of RPE cells appeared in healthy and AMD aged eyes, whereas granule aggregation was only observed in AMD eyes. In the latter, some RPE cells were greatly enlarged and displayed cytoskeletal alterations¹³⁵. In GA patients, the atrophic patches were usually surrounded by a junctional region of abnormal autofluorescence. Distinct patterns have been described and some of them may have a genetic basis^{136, 137}.

4. Main targets of photo-toxicity

Understanding the role of light exposure in the course of AMD requires identification of the molecular targets that initiate photo-oxidation reactions, which we may call primary targets. Some other molecules, the secondary targets, would not be directly affected by light, but they would become the immediate targets of ensuing photo-oxidation. Some compounds could be both primary and secondary targets, for example all-*trans*-retinal or lipofuscin. Available information about light molecular targets results from a large amount of experimental work that has been mainly done in animals or *in vitro*^{23, 27, 96, 138-140}.

Early work in albino rats showed photoreceptor damage after light exposure through blue (360-530 nm) and green (490-580 nm) filters. Electroretinogram (ERG) alterations, however, were most efficiently induced by exposure to 500 nm¹⁴¹. The RPE was sometimes involved, depending on age of the animal, temperature, previous illumination conditions and the intensity and duration of the damaging light¹⁴². Results suggested that these lesions depended, directly or indirectly, on rhodopsin excitation. Indirect damage would require the activation of other photo-sensitive molecules appearing under light adaptation conditions, perhaps including products of the rhodopsin bleaching process, such as vitamin A derivatives^{27, 139, 142}. By contrast, experiments using blue light (441 nm), done in monkeys, showed an initial damage of the RPE, followed by alteration of the photoreceptor outer segments and remarkable recovery 10-11 days after exposure¹⁴³. Available data for monochromatic-induced retinal damage support the existence of at least two damage action spectra. Irradiation in the 320-440 nm range predominantly affected photoreceptors¹⁴⁴, whereas in the 440-550 nm range injured the RPE and/or the

photoreceptors^{103, 141, 142}. Rhodopsin, and also other chromophores such as lipofuscin, intermediate products of the visual cycle, and even melanin, could be the photo-sensitive targets converting light into retinal damage²⁷. Rhodopsin, however, is not only affected by 500 nm light, but can also be a target for blue light-induced photoreversal of bleaching. This phenomenon increases the photon-catch capacity of the retina and its susceptibility to light damage, thus explaining why blue light has a greater damage potential than green light¹⁴⁵.

Of note, most spectral data for retinal damage has been obtained in anesthetized animals, often using funduscopy visible changes as threshold damage¹⁰³. Therefore, lesions described in these experiments do not resemble aging or AMD changes, but those found in welders^{40, 41} and laser or sun-gazing accidents^{146, 147}. Their relationship with AMD is conceivable, but is far from proven, particularly since these experiments provide little information about the damage spectra of very long exposures in freely moving subjects. Curiously, exposure of albino mice or rats to diffuse white light induces photoreceptor death, without overt RPE damage^{124, 148}.

Rhodopsin

White light did not cause photoreceptor degeneration in mice lacking functional rhodopsin, thus, rhodopsin must play an essential role in the retinal response to excessive lighting¹³⁸. This role is further supported by the correlation between rates of visual pigments regeneration and light-induced damage thresholds^{138, 149}. Moreover, white light did not induce retinal damage in mice and rats under halothane anesthesia, which blocks

rhodopsin metabolic regeneration. In these animals, however, exposure to blue light (403 nm) induced photoreceptor apoptosis and RPE swelling¹⁴⁸.

The absence of functional transducin, which blocks signaling from light-activated rhodopsin, did not protect from bright light-induced degeneration. However, mutant mice with persistent rhodopsin activation, which are extremely sensitive to low-intensity cyclic light, were protected¹³⁸.

Photo-transduction and oxidative stress in the outer segments

Oxidative metabolism, which is required to support the light pathway, could also induce or aggravate photoreceptor damage¹⁵⁰. Since a significant fraction of the O₂ used by cells is converted to ROS, excessive activation of photo-transduction might determine a higher activity of the respiratory complexes, and a higher oxidative stress. These phenomena might occur within the outer segments, which contain their own machinery for ATP synthesis, including mitochondrial-like electron transport chains, F1-ATP synthase and the TCA cycle enzymes, as has been demonstrated in bovine retinas using proteomic procedures and immunogold transmission electron microscopy¹⁵¹⁻¹⁵³. Remarkably, bovine and mouse outer segments are selectively stained with mitochondrial dyes^{151, 154}.

The nicotinamide adenine dinucleotide phosphate (NADPH) oxidases (NOX) are also involved in light-induced oxidative stress. The primary function of NOX enzymes is the reduction of oxygen into superoxide anion using NADPH as an electron donor and oxygen as an electron acceptor¹⁵⁵. Increase of these species is observed in mouse outer segments when whole eyeball cultures are irradiated with blue light (405 nm), and can be prevented by the NOX inhibitor apocynin¹⁵⁴.

The visual cycle and the retinoids

Photo-excitation of rhodopsin and other visual pigments leads to isomerization of their chromophore 11-*cis*-retinal to all-*trans*-retinal, which dissociates from the opsin protein. Regeneration of the visual pigments requires the restoration of 11-*cis*-retinal. Visual pigments in rods and cones recover at very different rates, about 40 min in rods but only 2-3 min in cones¹⁵⁶. These are the times required by their specific regeneration processes: the rod and the cone visual cycles^{156, 157}.

The rod visual cycle

Both 11-*cis*- and all-*trans*-retinal form Schiff base adducts with phosphatidylethanolamine (PE). The ATP-binding cassette subfamily member 4 (ABCA4) flips this N-retinylidene-PE to the disk cytoplasmic leaflet¹⁵⁸, and cytoplasmic dehydrogenases (RDHs) reduce it to all-*trans*-retinol¹⁵⁶. This retinoid is released and bound by the interphotoreceptor retinoid-binding protein (IRBP). It is then captured by RPE cells, becoming bound to a retinaldehyde-binding protein (CRALBP). All-*trans*-retinol is esterified by lecithin-retinol acyltransferase (LRAT) and turned into 11-*cis*-retinol by the isomerase (RPE-specific 65 kDa protein; Rpe65). Further oxidation produces 11-*cis*-retinal, which abandons the RPE and is taken up by photoreceptors, regenerating a functional visual pigment¹⁵⁶.

The cone visual cycle

The cone visual cycle is intraretinal. Instead of trafficking to the RPE, all-*trans*-retinol diffuses from cones to the Müller cells, where it is isomerized to 11-*cis*-retinol, probably by dihydroceramide desaturase-1 (DES1)¹⁵⁹. This is a type 2 isomerase that, at difference with Rpe65, acts directly on all-*trans*-retinol¹⁵⁹. 11-*cis*-retinol is rapidly esterified by

multifunctional O-acyltransferase (MFAT)¹⁶⁰. CRALBP plays an important role in the cone visual cycle, since its absence desensitizes cone-driven vision in humans and mice¹⁶¹. Both cone and rod dark adaptation depend on the presence of CRALBP¹⁶¹.

Phototoxicity of all-trans-retinal

The possible role of all-*trans*-retinal as the agent of light-induced damage, initially discussed by Noell (1966)¹⁴¹, has been extensively described^{132, 149}. Remarkably, the instantaneous concentration of this retinoid in the light-exposed outer segment could be as high as 5 mM^{162, 163}. Bleaching less than 0.5% of all rhodopsin would still generate toxic levels of all-*trans*-retinal¹⁶⁴. Thus, this molecule could either be an indirect damage target of rhodopsin activation and/or the direct target of short-wavelength light. Peak absorption of all-*trans*-retinal is at 380 nm, which is almost completely filtered by the human lens. However, this retinoid still shows substantial absorption at > 410 nm wavelengths¹⁶⁵. UV-A (355 nm) and blue (422 nm) light excitation of all-*trans*-retinal in the presence of oxygen generates singlet oxygen, which can in turn oxidize all-*trans*-retinal¹⁶⁶. The degradation products, including several endoperoxides, shorter-chain aldehydes and epoxides, significantly increase all-*trans*-retinal cytotoxic effects on RPE cells *in vitro*¹⁶⁶.

Rod photoreceptors would be the primary site of all-*trans*-retinal attack¹⁶⁷. Damage is induced through different mechanisms, including photo-damage of its own transporter ABCA4¹⁶⁵, impairment of mitochondrial function, increase in the production of superoxide through the activation of NOX enzymes¹⁶⁸, and/or the activation of Toll-like-receptor 3 (TLR-3)¹⁶⁹, followed by microglial activation¹⁷⁰. In addition, *in vitro* irradiation (400-700

nm) of rod outer segments in the presence of all-*trans*-retinal impairs the ability of rhodopsin to regenerate¹⁷¹, indicating another probable cause of photoreceptor degeneration.

All-*trans*-retinal arrives to the RPE together with phagocytosed outer segment discs, but can also be synthesized in the RPE from β,β carotene or all-*trans*-retinol¹⁷². All-*trans*-retinal is highly cytotoxic to human RPE cells in primary cultures, and potentiates the effect of light irradiation¹⁷².

The pharmacological control of visual chromophore biosynthesis has been proposed as a preventive method for retinal diseases depending on light-induced damage, increase of retinoid byproducts and hyperoxia¹⁷³. Emixustat hydrochloride, presently in clinical trial for dry AMD is an RPE65 inhibitor and retinal scavenger. This drug has significant adverse effects; however, it has shown that all-*trans*-retinal sequestration is a crucial function for photo-toxicity protection¹⁷⁴.

Lipofuscin and A2E

Although lipofuscin has been extensively described, its composition is still poorly understood and might differ between the diverse regions of the retina. Lipofuscin, which contains little protein, would mainly derive from all-*trans*-retinal, docosahexaenoic acid (DHA), and other components from outer segments¹⁷⁵⁻¹⁷⁷. Its best known constituents are the bisretinoids, a complex mixture of autofluorescent compounds^{132, 176}. Retinal isomers, including all-*trans* and 11-*cis*, covalently react with the amine group of PE forming N-retinylidene-PE. The addition of a second retinal molecule produces N-retinylidene-N-retinylphosphatidylethanolamine (A2PE). A2E forms after removal of the A2PE

phospholipid moiety¹⁷⁶. Lipofuscin also contains all-*trans*-retinal dimers, which are more abundant than A2E in the retina of *Abca4*^{-/-} mice²⁷. RPE bisretinoids exhibit diverse excitation maxima, but they all emit fluorescence centered around 600 nm, which is similar to the maximum emission of the fundus autofluorescence¹⁷⁶.

Numerous experiments, *in vivo* and *in vitro*, support the role of lipofuscin, all-*trans*-retinal and A2E as targets for blue light. In primate eyes, visible light (488 and 568 nm) may photo-bleach RPE cells autofluorescence at levels previously considered safe. Experiments *in vitro* suggested that A2E might be involved in this response²⁷. At higher intensity irradiation levels, but still not higher than the maximum permissible exposure, the RPE developed long-term structural disruption. At present, it is unclear whether these lesions represent a lipofuscin- or photopigment-dependent damage mechanism²⁷. However, damage induced in RPE cell cultures fed isolated lipofuscin granules, and exposed to short-wavelength visible light (390–550 nm)⁹⁷, but in the absence of photoreceptors, cannot be attributed to a rhodopsin effect.

A2E may be less damaging than retinaldehydes¹⁷², and it has been postulated that the formation of A2E and its precursor A2PE would reduce the photo-reactivity of all-*trans*-retinal¹⁷². In contrast with this hypothesis, a damage spectrum has been described for A2E-loaded porcine RPE cells, with lesions occurring between 390 and 552 nm (maximal at 420–450 nm)¹⁷⁸. This apparent contradiction can be explained by the increased photo-toxicity of A2E oxidation products¹⁷⁹, which would contribute to RPE photo-damage in rat retinas exposed to blue light¹⁸⁰. Photo-oxidation and photo-degradation of bisretinoids release small carbonyls involved in the formation of Advanced Glycation End-products,

which may accumulate in drusen and laminar deposits¹⁸¹. It has also been suggested that photo-activation and cleavage of bisretinoids promote complement attack on RPE cells^{182, 183}. These similarities in the cytotoxicity of lipofuscin and A2E, plus the fact that both molecules show the same distribution in mice RPE¹⁸⁴, were taken as an indication that A2E might be the target triggering and maintaining the course of AMD¹⁸⁵.

A2E and its oxides have been studied *in situ* using high-resolution matrix-assisted laser desorption/ionization imaging mass spectrometry (MALDI-IMS). Whereas the RPE central area displayed the highest lipofuscin fluorescence intensities, the highest A2E densities were found in the far periphery^{186, 187}. Comparison of A2E distribution in human and mouse retinas suggests that this bisretinoid is characteristic of rod-rich areas. Low levels in the cone-rich area macular area suggest that the cone visual cycle does not favor the transformation of all-*trans*-retinal into A2E. Thus, light-induced damage in the central retina would not depend on A2E. Nevertheless, the distribution of lipofuscin in a perifoveal ring corresponds to the localization of perifoveal rods¹³⁴, which are the first photoreceptors to perish in aging and AMD^{108, 119, 120}.

On the other hand, photo-oxidative damage (448 nm) of lipofuscin-loaded primary human RPE cells and ARPE-19 cells activated the inflammasome, suggesting a link between photo-oxidative damage and innate immune activation¹⁸⁸.

The ABCA4 gene and clearance of all-trans-retinal

Clearance of all-*trans*-retinal is delayed when certain variants of the ABCA4 gene are present, as in recessive Stargardt's disease (STGD1), a juvenile form of macular

degeneration¹⁸⁹. Two variants of the human gene have been associated with increased risk for AMD¹⁹⁰.

STGD1 patients show a distinctive fundus autofluorescence pattern, the granular pattern with peripheral punctate spots (GPS+), that also appears in 2-3 % of GA AMD patients¹³⁷.

About half of the GPS+ patients carried a monoallelic ABCA4 variant, whereas only 10% of the GPS- patients carried these variant alleles¹³⁷. Of note, light deprivation might contribute to reduced progression of decreased autofluorescence in STGD1 patients¹⁹¹.

Although the vast majority of AMD cases are not related to ABCA4 gene variants, the aforementioned associations support a role of all-*trans*-retinal in AMD development.

Data obtained in mice carrying *Abca4* mutations suggest a complex and still controversial scenario. *Abca4*^{-/-} mice, which are more vulnerable to light-induced retinal degeneration, accumulate RPE lipofuscin and A2E¹⁹². *Rdh8*^{-/-}*Abca4*^{-/-} mice, with a delayed all-*trans*-retinal clearance, develop retinal lesions resembling human AMD (RPE/photoreceptor dystrophy, lipofuscin, drusen-like deposits under the RPE and choroidal neovascularization), and show an acute retinopathy under irradiation levels harmless for *Rdh8*^{+/+}*Abca4*^{+/+} mice¹⁴⁹.

Abca4^{-/-} mice increased the expression of proteins activating the complement system, and downregulated the complement regulatory proteins. Besides, they showed basal laminar deposits along the Bruch's membrane¹⁹³. Moreover, all-*trans*-retinal sensitized human RPE cells *in vitro* to alternative complement pathway attack¹⁹⁴, suggesting another likely link between light exposure, the visual cycle and AMD.

Retinal lipids

DHA is the most abundant fatty acid in whole retinas (22-24%)¹⁹⁵. Prolonged light exposure and high-light rearing environments reduce DHA levels in rod outer segments¹⁹⁶. Interestingly, acute exposure to bright light did not damage photoreceptor outer segments in rats with dietary DHA or linolenic acid deprivation^{196, 197}.

Involvement of N-retinylidene-PE in the clearance of all-*trans*-retinal probably explains the extraordinarily high content of PE and its long-chain DHA in photoreceptor membranes. In the disc membranes, PE would act as a sink preventing diffusion of 11-*cis*-retinal¹⁹⁸.

As a precursor of neuroprotectin D1, DHA may also shield retinal cells from oxidative stress¹⁹⁹. Importantly, photo-activation of rhodopsin may be regulated by the relative proportion of polyunsaturated lipids, such as DHA, and cholesterol, in the disc membranes. Thus, quantum yield of all-*trans*-retinal depends on the availability of DHA in the retina⁹⁶.

Lipid peroxidation significantly increases in the retina of rats exposed to light²⁰⁰.

Moreover, it has been shown that the oxidative potential of the posterior region of the human eye, including the macula, increases with age²⁰¹. Exposure to light induces phospholipid oxidation and immunoreactivity for oxidized phosphatidylcholine appears in photoreceptors and RPE cells at the healthy human macular area. Its levels increase with age and eyes with AMD show stronger immunoreactivity than age-matched normal eyes²⁰². Increase of oxidized phospholipids multiplies the expression of monocyte chemoattractant protein-1 (MCP-1), followed by macrophage accumulation, and these

effects are prevented by antioxidants. Moreover, subretinal application of oxidized phospholipids induces choroidal neovascularization, typical of the wet-type AMD²⁰³.

Carboxyethylpyrrole adducts

Carboxyethylpyrrole protein (CEP)-adducts are oxidative products derived from fragmentation of DHA-containing lipids. They are elevated in ocular tissues and plasma in AMD patients, where they can be detected in drusen²⁰⁴. Purified lipofuscin granules also contain CEP-adducts^{175, 205}. Likewise, CEP adducts are found in the retina of rodents exposed to intense light²⁰⁶. The photo-oxidative processes that generate CEP-adducts could occur in photoreceptor cells, but may also take place after disc shedding in the RPE autophagosomes and lysosomal bodies¹⁷⁶. CEP-adducts may well be another pathway to macular degeneration, since autoantibodies are present in the blood of AMD patients. Moreover, mice immunization with CEP-seroalbumin induced, after 12-14 months, numerous sub-RPE deposits and accumulation of complement proteins in the Bruch's membrane²⁰⁷.

Isolevuglandins

Levuglandins (LGs) and isolevuglandins are γ -keto-aldehydes derived from the oxidation of arachydonyl phospholipids^{208, 209}. These molecules are highly reactive toward free primary amines such as the ϵ -amine of lysine residues in proteins and the primary amino groups of phosphatidylethanolamines²¹⁰. They also react with mitochondrial cytochrome P450 27A1 (CYP27A1), impairing its function in sterol elimination²¹¹. Isolevuglandins are highly abundant in the human retina, where immunoreactivity is mainly localized in photoreceptor inner segments. They are not detected in retinas of mice reared under dim

light, but can be found in inner segments and RPE cells after exposure to a bright light source (10,000 lux 2 h)²¹². Iso[4]levuglandin E₂ adducts have been found in purified lipofuscin granules¹⁷⁵.

5. Concluding Remarks

Evidence presented here supports the concept that light reaching the retina and the RPE provokes oxidative stress, leading to a buildup of toxic compounds that induce inflammation and cell death. Experimental and clinical findings indicate that light can affect oxidative homeostasis in the outer retina, either by excessive activation of photo-transduction processes or by the impairment of waste disposal mechanisms. All-*trans*-retinal and its subproducts appear as the major offenders in the retinal degeneration circuit.

In experimental models, accumulations of all-*trans*-retinal in photoreceptors, and bisretinoids and lipofuscin in the RPE, are light-dependent processes. In addition, these compounds are both photo-reactive, and photo-toxicity inducers as well. Experimental evidence indicates that all-*trans*-retinal accumulation in photoreceptors suffices for the initiation of their degeneration. Therefore, early AMD might represent the direct effect of all-*trans*-retinal on photoreceptors, perhaps reinforced by lipofuscin accumulation in cones. In a second stage, lipofuscin, A2E, and related compounds, would increasingly accrue in the RPE, giving rise to a new target site for photo-toxicity. The course of the disease would then accelerate, since the light attack becomes possible at two different fronts. Differences between early and late AMD could perhaps be explained by this

temporal pattern. In addition, all-*trans*-retinal photo-toxicity includes disruption of ABCA4, the N-retinylidene-PE transporter. Since photoreceptor PE molecules are highly enriched in DHA, all-*trans*-retinal photo-toxicity might be involved in the formation of CEP-adducts that appear in drusen and lipofuscin granules.

The availability of precise and fast analytic tools has also brought to light that rods and cones follow different death pathways. Most important, both histological and modern imaging procedures have shown that perifoveal rods die before foveal cones. This sequence could be associated to differences in the management of visual pigment regeneration, which requires an RPE step for rods, but is mainly intraretinal for cones. Moreover, cones seem to be more resistant to light-damage than rods. Since their light-resistance and survival depends on RdCVF availability, loss of perifoveal rods predicts the future demise of foveal cones. Of note, experiments suggest that a replacement therapy might extend cone survival.

Ample evidence shows that light-induced photoreceptor and/or RPE injury would trigger the inflammatory component, amplifying the initial damage. These processes explain the importance of certain gene variants for complement regulatory proteins as risk factors for AMD development.

As shown by data presented in this review, the hypothesis of light as an initiation cause of AMD is mainly supported by the existence of molecular targets in the retina and the pigment epithelium which light can transform into photoreceptor toxics.

REFERENCES

1. C. Zhang, A. J. Tatham, R. N. Weinreb, L. M. Zangwill, Z. Yang, J. Z. Zhang and F. A. Medeiros, Relationship between ganglion cell layer thickness and estimated retinal ganglion cell counts in the glaucomatous macula, *Ophthalmology*, 2014, **121**, 2371-2379.
2. J. M. Provis, P. L. Penfold, E. E. Cornish, T. M. Sandercoe and M. C. Madigan, Anatomy and development of the macula: specialisation and the vulnerability to macular degeneration, *Clinical & experimental optometry : journal of the Australian Optometrical Association*, 2005, **88**, 269-281.
3. C. A. Curcio, J. D. Messinger, K. R. Sloan, A. Mitra, G. McGwin and R. F. Spaide, Human chorioretinal layer thicknesses measured in macula-wide, high-resolution histologic sections, *Invest Ophthalmol Vis Sci*, 2011, **52**, 3943-3954.
4. C. G. Owen, Z. Jarrar, R. Wormald, D. G. Cook, A. E. Fletcher and A. R. Rudnicka, The estimated prevalence and incidence of late stage age related macular degeneration in the UK, *Br J Ophthalmol*, 2012, **96**, 752-756.
5. B. Feigl, B. Brown, J. Lovie-Kitchin and P. Swann, Cone- and rod-mediated multifocal electroretinogram in early age-related maculopathy, *Eye (Lond)*, 2005, **19**, 431-441.
6. S. Sadigh, A. V. Cideciyan, A. Sumaroka, W. C. Huang, X. Luo, M. Swider, J. D. Steinberg, D. Stambolian and S. G. Jacobson, Abnormal thickening as well as thinning of the photoreceptor layer in intermediate age-related macular degeneration, *Invest Ophthalmol Vis Sci*, 2013, **54**, 1603-1612.

7. F. L. Ferris, 3rd, C. P. Wilkinson, A. Bird, U. Chakravarthy, E. Chew, K. Csaky, S. R. Sadda and C. Beckman Initiative for Macular Research Classification, Clinical classification of age-related macular degeneration, *Ophthalmology*, 2013, **120**, 844-851.
8. J. Ambati, J. P. Atkinson and B. D. Gelfand, Immunology of age-related macular degeneration, *Nat Rev Immunol*, 2013, **13**, 438-451.
9. W. L. Wong, X. Su, X. Li, C. M. Cheung, R. Klein, C. Y. Cheng and T. Y. Wong, Global prevalence of age-related macular degeneration and disease burden projection for 2020 and 2040: a systematic review and meta-analysis, *The Lancet. Global health*, 2014, **2**, e106-116.
10. R. R. Bourne, J. B. Jonas, S. R. Flaxman, J. Keeffe, J. Leasher, K. Naidoo, M. B. Parodi, K. Pesudovs, H. Price, R. A. White, T. Y. Wong, S. Resnikoff, H. R. Taylor and S. Vision Loss Expert Group of the Global Burden of Disease, Prevalence and causes of vision loss in high-income countries and in Eastern and Central Europe: 1990-2010, *Br J Ophthalmol*, 2014, **98**, 629-638.
11. J. L. Leasher, V. Lansingh, S. R. Flaxman, J. B. Jonas, J. Keeffe, K. Naidoo, K. Pesudovs, H. Price, J. C. Silva, R. A. White, T. Y. Wong, S. Resnikoff, H. R. Taylor, R. R. Bourne and S. Vision Loss Expert Group of the Global Burden of Disease, Prevalence and causes of vision loss in Latin America and the Caribbean: 1990-2010, *Br J Ophthalmol*, 2014, **98**, 619-628.
12. NEI, Age-related macular degeneration (AMD), <https://www.nei.nih.gov/eyedata/amd#6>, (accessed 04/20/2015, 2015).

13. S. Beatty, H. Koh, M. Phil, D. Henson and M. Boulton, The role of oxidative stress in the pathogenesis of age-related macular degeneration, *Surv Ophthalmol*, 2000, **45**, 115-134.
14. B. S. Winkler, M. E. Boulton, J. D. Gottsch and P. Sternberg, Oxidative damage and age-related macular degeneration, *Mol Vis*, 1999, **5**, 32.
15. S. G. Jarrett and M. E. Boulton, Consequences of oxidative stress in age-related macular degeneration, *Mol Aspects Med*, 2012, **33**, 399-417.
16. J. C. Khan, D. A. Thurlby, H. Shahid, D. G. Clayton, J. R. Yates, M. Bradley, A. T. Moore and A. C. Bird, Smoking and age related macular degeneration: the number of pack years of cigarette smoking is a major determinant of risk for both geographic atrophy and choroidal neovascularisation, *Br J Ophthalmol*, 2006, **90**, 75-80.
17. M. Cano, R. Thimmalappula, M. Fujihara, N. Nagai, M. Sporn, A. L. Wang, A. H. Neufeld, S. Biswal and J. T. Handa, Cigarette smoking, oxidative stress, the anti-oxidant response through Nrf2 signaling, and Age-related Macular Degeneration, *Vision Res*, 2010, **50**, 652-664.
18. A. Woodell and B. Rohrer, A mechanistic review of cigarette smoke and age-related macular degeneration, *Adv Exp Med Biol*, 2014, **801**, 301-307.
19. J. M. Seddon, J. Cote, W. F. Page, S. H. Aggen and M. C. Neale, The US twin study of age-related macular degeneration: relative roles of genetic and environmental influences, *Arch Ophthalmol*, 2005, **123**, 321-327.
20. J. N. Cooke Bailey, M. A. Pericak-Vance and J. L. Haines, Genome-Wide Association Studies: Getting to Pathogenesis, the Role of Inflammation/Complement in Age-Related

Macular Degeneration, *Cold Spring Harbor perspectives in medicine*, 2014, **4**, a017186-a017186.

21. J. G. Hollyfield, V. L. Bonilha, M. E. Rayborn, X. Yang, K. G. Shadrach, L. Lu, R. L. Ufret, R. G. Salomon and V. L. Perez, Oxidative damage-induced inflammation initiates age-related macular degeneration, *Nat Med*, 2008, **14**, 194-198.
22. R. D. Glickman, Phototoxicity to the retina: mechanisms of damage, *International journal of toxicology*, 2002, **21**, 473-490.
23. M. Boulton, M. Rozanowska and B. Rozanowski, Retinal photodamage, *J Photochem Photobiol B*, 2001, **64**, 144-161.
24. D. Balasubramanian, Ultraviolet radiation and cataract, *J Ocul Pharmacol Ther*, 2000, **16**, 285-297.
25. D. H. Sliney, Eye protective techniques for bright light, *Ophthalmology*, 1983, **90**, 937-944.
26. J. M. Stringham, K. Fuld and A. J. Wenzel, Action spectrum for photophobia, *Journal of the Optical Society of America. A, Optics, image science, and vision*, 2003, **20**, 1852-1858.
27. J. J. Hunter, J. I. Morgan, W. H. Merigan, D. H. Sliney, J. R. Sparrow and D. R. Williams, The susceptibility of the retina to photochemical damage from visible light, *Prog Retin Eye Res*, 2012, **31**, 28-42.
28. H. R. Taylor, B. Munoz, S. West, N. M. Bressler, S. B. Bressler and F. S. Rosenthal, Visible light and risk of age-related macular degeneration, *Transactions of the American Ophthalmological Society*, 1990, **88**, 163-173; discussion 173-168.

29. H. R. Taylor, S. West, B. Munoz, F. S. Rosenthal, S. B. Bressler and N. M. Bressler, The long-term effects of visible light on the eye, *Arch Ophthalmol*, 1992, **110**, 99-104.
30. S. C. Tomany, K. J. Cruickshanks, R. Klein, B. E. Klein and M. D. Knudtson, Sunlight and the 10-year incidence of age-related maculopathy: the Beaver Dam Eye Study, *Arch Ophthalmol*, 2004, **122**, 750-757.
31. B. Vojnikovic, S. Njiric, M. Coklo and J. Spanjol, Ultraviolet sun radiation and incidence of age-related macular degeneration on Croatian Island Rab, *Collegium antropologicum*, 2007, **31 Suppl 1**, 43-44.
32. S. K. West, F. S. Rosenthal, N. M. Bressler, S. B. Bressler, B. Munoz, S. L. Fine and H. R. Taylor, Exposure to sunlight and other risk factors for age-related macular degeneration, *Arch Ophthalmol*, 1989, **107**, 875-879.
33. J. C. Khan, H. Shahid, D. A. Thurlby, M. Bradley, D. G. Clayton, A. T. Moore, A. C. Bird, J. R. Yates and A. M. D. S. Genetic Factors in, Age related macular degeneration and sun exposure, iris colour, and skin sensitivity to sunlight, *Br J Ophthalmol*, 2006, **90**, 29-32.
34. P. Darzins, P. Mitchell and R. F. Heller, Sun exposure and age-related macular degeneration. An Australian case-control study, *Ophthalmology*, 1997, **104**, 770-776.
35. G. Y. Sui, G. C. Liu, G. Y. Liu, Y. Y. Gao, Y. Deng, W. Y. Wang, S. H. Tong and L. Wang, Is sunlight exposure a risk factor for age-related macular degeneration? A systematic review and meta-analysis, *Br J Ophthalmol*, 2013, **97**, 389-394.
36. M. Hirakawa, M. Tanaka, Y. Tanaka, A. Okubo, C. Koriyama, M. Tsuji, S. Akiba, K. Miyamoto, G. Hillebrand, T. Yamashita and T. Sakamoto, Age-related maculopathy and

sunlight exposure evaluated by objective measurement, *Br J Ophthalmol*, 2008, **92**, 630-634.

37. K. J. Cruickshanks, R. Klein and B. E. Klein, Sunlight and age-related macular degeneration. The Beaver Dam Eye Study, *Arch Ophthalmol*, 1993, **111**, 514-518.

38. A. E. Fletcher, G. C. Bentham, M. Agnew, I. S. Young, C. Augood, U. Chakravarthy, P. T. de Jong, M. Rahu, J. Seland, G. Soubrane, L. Tomazzoli, F. Topouzis, J. R. Vingerling and J. Vioque, Sunlight exposure, antioxidants, and age-related macular degeneration, *Arch Ophthalmol*, 2008, **126**, 1396-1403.

39. M. Cellini, V. Profazio, P. Fantaguzzi, E. Barbaresi, L. Longanesi and R. Caramazza, Phototoxic maculopathy by arc welding. A case report, *International ophthalmology*, 1987, **10**, 157-159.

40. M. Vukicevic and W. Heriot, Phototoxic maculopathy associated with arc welding: clinical findings and associated functional vision impairment, *Clinical & experimental ophthalmology*, 2008, **36**, 695-697.

41. X. Yang, D. Shao, X. Ding, X. Liang, J. Yang and J. Li, Chronic phototoxic maculopathy caused by welding arc in occupational welders, *Canadian journal of ophthalmology. Journal canadien d'ophtalmologie*, 2012, **47**, 45-50.

42. ICNIRP, Guidelines on limits of exposure to broad-band incoherent optical radiation (0.38 to 3 μm). International Commission on Non-Ionizing Radiation Protection, *Health Phys.*, 1997, **73**, 539-554.

43. F. Behar-Cohen, C. Martinsons, F. Vienot, G. Zisis, A. Barlier-Salsi, J. P. Cesarini, O. Enouf, M. Garcia, S. Picaud and D. Attia, Light-emitting diodes (LED) for domestic lighting: any risks for the eye?, *Prog Retin Eye Res*, 2011, **30**, 239-257.
44. I. Jaadane, P. Boulenguez, S. Chahory, S. Carre, M. Savoldelli, L. Jonet, F. Behar-Cohen, C. Martinsons and A. Torriglia, Retinal damage induced by commercial light emitting Diodes (LED), *Free Radic Biol Med*, 2015, **84**, 373-384.
45. Building Technologies Office, Solid-state lighting technology fact sheet, U.S. Department of Energy, PNNL-SA-96340, June 2013,
http://apps1.eere.energy.gov/buildings/publications/pdfs/ssl/opticalsafety_fact-sheet.pdf.
46. Y. M. Shang, G. S. Wang, D. Sliney, C. H. Yang and L. L. Lee, White light-emitting diodes (LEDs) at domestic lighting levels and retinal injury in a rat model, *Environmental health perspectives*, 2014, **122**, 269-276.
47. Y. Kuse, K. Ogawa, K. Tsuruma, M. Shimazawa and H. Hara, Damage of photoreceptor-derived cells in culture induced by light emitting diode-derived blue light, *Scientific reports*, 2014, **4**, 5223.
48. M. Smith Bright, Emergency vehicle LED lighting: friend or foe?, School of Public Service and Health Public Administration, American Public University System, Master's Capstone Theses, 76 pp, 2014.
<http://digitalcommons.apus.edu/cgi/viewcontent.cgi?article=1018&context=theses>
49. R. D. Glickman, Ultraviolet phototoxicity to the retina, *Eye Contact Lens*, 2011, **37**, 196-205.

50. E. R. Gaillard, L. Zheng, J. C. Merriam and J. Dillon, Age-related changes in the absorption characteristics of the primate lens, *Invest Ophthalmol Vis Sci*, 2000, **41**, 1454-1459.
51. F. Avila, B. Friguet and E. Silva, Photosensitizing Activity of Endogenous Eye Lens Chromophores: An Attempt to Unravel Their Contributions to Photo-Aging and Cataract Disease, *Photochem Photobiol*, 2015, DOI: 10.1111/php.12443.
52. J. Dillon, L. Zheng, J. C. Merriam and E. R. Gaillard, Transmission of light to the aging human retina: possible implications for age related macular degeneration, *Exp Eye Res*, 2004, **79**, 753-759.
53. S. Vazquez, N. R. Parker, M. Sheil and R. J. Truscott, Protein-bound kynurenine decreases with the progression of age-related nuclear cataract, *Invest Ophthalmol Vis Sci*, 2004, **45**, 879-883.
54. E. R. Gaillard, J. Merriam, L. Zheng and J. Dillon, Transmission of light to the young primate retina: possible implications for the formation of lipofuscin, *Photochem Photobiol*, 2011, **87**, 18-21.
55. C. Brockmann, M. Schulz and T. Laube, Transmittance characteristics of ultraviolet and blue-light-filtering intraocular lenses, *Journal of cataract and refractive surgery*, 2008, **34**, 1161-1166.
56. S. Cugati, P. Mitchell, E. Rochtchina, A. G. Tan, W. Smith and J. J. Wang, Cataract surgery and the 10-year incidence of age-related maculopathy: the Blue Mountains Eye Study, *Ophthalmology*, 2006, **113**, 2020-2025.

57. J. M. Nolan, P. O'Reilly, J. Loughman, J. Stack, E. Loane, E. Connolly and S. Beatty, Augmentation of macular pigment following implantation of blue light-filtering intraocular lenses at the time of cataract surgery, *Invest Ophthalmol Vis Sci*, 2009, **50**, 4777-4785.
58. M. Tanito, T. Okuno, Y. Ishiba and A. Ohira, Transmission spectrums and retinal blue-light irradiance values of untinted and yellow-tinted intraocular lenses, *Journal of cataract and refractive surgery*, 2010, **36**, 299-307.
59. R. J. Lucas, S. N. Peirson, D. M. Berson, T. M. Brown, H. M. Cooper, C. A. Czeisler, M. G. Figueiro, P. D. Gamlin, S. W. Lockley, J. B. O'Hagan, L. L. Price, I. Provencio, D. J. Skene and G. C. Brainard, Measuring and using light in the melanopsin age, *Trends in neurosciences*, 2014, **37**, 1-9.
60. M. A. Mainster and P. L. Turner, Blue-blocking IOLs vs. short-wavelength visible light: hypothesis-based vs. evidence-based medical practice, *Ophthalmology*, 2011, **118**, 1-2.
61. A. E. Brondsted, J. H. Lundeman and L. Kessel, Short wavelength light filtering by the natural human lens and IOLs -- implications for entrainment of circadian rhythm, *Acta Ophthalmol*, 2013, **91**, 52-57.
62. I. Alexander, F. M. Cuthbertson, G. Ratnarajan, R. Safa, F. E. Mellington, R. G. Foster, S. M. Downes and K. Wulff, Impact of cataract surgery on sleep in patients receiving either ultraviolet-blocking or blue-filtering intraocular lens implants, *Invest Ophthalmol Vis Sci*, 2014, **55**, 4999-5004.

63. A. Pipis, E. Touliou, L. E. Pillunat and A. J. Augustin, Effect of the blue filter intraocular lens on the progression of geographic atrophy, *European Journal of Ophthalmology*, 2015, **25**, 128-133.
64. F. Khachik, P. S. Bernstein and D. L. Garland, Identification of lutein and zeaxanthin oxidation products in human and monkey retinas, *Invest Ophthalmol Vis Sci*, 1997, **38**, 1802-1811.
65. B. Li, P. Vachali and P. S. Bernstein, Human ocular carotenoid-binding proteins, *Photochemical & photobiological sciences : Official journal of the European Photochemistry Association and the European Society for Photobiology*, 2010, **9**, 1418-1425.
66. B. Li, P. P. Vachali, A. Gorusupudi, Z. Shen, H. Sharifzadeh, B. M. Besch, K. Nelson, M. M. Horvath, J. M. Frederick, W. Baehr and P. S. Bernstein, Inactivity of human beta,beta-carotene-9',10'-dioxygenase (BCO2) underlies retinal accumulation of the human macular carotenoid pigment, *Proc Natl Acad Sci U S A*, 2014, **111**, 10173-10178.
67. S. Sabour-Pickett, J. M. Nolan, J. Loughman and S. Beatty, A review of the evidence germane to the putative protective role of the macular carotenoids for age-related macular degeneration, *Molecular nutrition & food research*, 2012, **56**, 270-286.
68. J. L. Dennison, J. Stack, S. Beatty and J. M. Nolan, Concordance of macular pigment measurements obtained using customized heterochromatic flicker photometry, dual-wavelength autofluorescence, and single-wavelength reflectance, *Exp Eye Res*, 2013, **116**, 190-198.

69. P. Smolarek-Kasprzak, J. M. Nolan, S. Beatty, J. Dennison, K. O. Akuffo, R. Kuchling, J. Stack and G. O'Regan, Measuring Visual Function Using the MultiQuity System: Comparison with an Established Device, *Journal of ophthalmology*, 2014, **2014**, 180317.
70. J. M. Nolan, K. Meagher, S. Kashani and S. Beatty, What is meso-zeaxanthin, and where does it come from?, *Eye (Lond)*, 2013, **27**, 899-905.
71. L. M. Fletcher, M. Engles and B. R. Hammond, Jr., Visibility through atmospheric haze and its relation to macular pigment, *Optom Vis Sci*, 2014, **91**, 1089-1096.
72. J. M. Nolan, J. Stack, O. D. O, E. Loane and S. Beatty, Risk factors for age-related maculopathy are associated with a relative lack of macular pigment, *Exp Eye Res*, 2007, **84**, 61-74.
73. Age-related Eye Disease Study (AREDS) Research Group,, A randomized, placebo-controlled, clinical trial of high-dose supplementation with vitamins C and E, beta carotene and zinc for age-related macular degeneration and vision loss: AREDS report no. 8., *Arch Ophthalmol*, 2001, **119**.
74. Age-related Eye Disease Study (AREDS) Research Group,, Lutein + zeaxanthin and omega-3 fatty acids for age-related macular degeneration: the Age-Related Eye Disease Study 2 (AREDS2) randomized clinical trial, *JAMA*, 2013, **309**, 2005-2015.
75. I. J. Murray, M. Makridaki, R. L. van der Veen, D. Carden, N. R. Parry and T. T. Berendschot, Lutein supplementation over a one-year period in early AMD might have a mild beneficial effect on visual acuity: the CLEAR study, *Invest Ophthalmol Vis Sci*, 2013, **54**, 1781-1788.

76. L. Ma, H. L. Dou, Y. M. Huang, X. R. Lu, X. R. Xu, F. Qian, Z. Y. Zou, H. L. Pang, P. C. Dong, X. Xiao, X. Wang, T. T. Sun and X. M. Lin, Improvement of retinal function in early age-related macular degeneration after lutein and zeaxanthin supplementation: a randomized, double-masked, placebo-controlled trial, *Am J Ophthalmol*, 2012, **154**, 625-634 e621.
77. R. Liu, T. Wang, B. Zhang, L. Qin, C. Wu, Q. Li and L. Ma, Lutein and zeaxanthin supplementation and association with visual function in age-related macular degeneration, *Invest Ophthalmol Vis Sci*, 2015, **56**, 252-258.
78. J. J. Wang, G. H. Buitendijk, E. Rohtchina, K. E. Lee, B. E. Klein, C. M. van Duijn, V. M. Flood, S. M. Meuer, J. Attia, C. Myers, E. G. Holliday, A. G. Tan, W. T. Smith, S. K. Iyengar, P. T. de Jong, A. Hofman, J. R. Vingerling, P. Mitchell, R. Klein and C. C. Klaver, Genetic susceptibility, dietary antioxidants, and long-term incidence of age-related macular degeneration in two populations, *Ophthalmology*, 2014, **121**, 667-675.
79. K. O. Akuffo, S. Beatty, J. Stack, J. Dennison, S. O'Regan, K. A. Meagher, T. Peto and J. Nolan, Central Retinal Enrichment Supplementation Trials (CREST): design and methodology of the CREST randomized controlled trials, *Ophthalmic epidemiology*, 2014, **21**, 111-123.
80. R. Edge, D. J. McGarvey and T. G. Truscott, The carotenoids as anti-oxidants--a review, *J Photochem Photobiol B*, 1997, **41**, 189-200.
81. S. R. Kim, K. Nakanishi, Y. Itagaki and J. R. Sparrow, Photooxidation of A2-PE, a photoreceptor outer segment fluorophore, and protection by lutein and zeaxanthin, *Exp Eye Res*, 2006, **82**, 828-839.

82. H. L. Ramkumar, J. Tuo, F. Shen de, J. Zhang, X. Cao, E. Y. Chew and C. C. Chan, Nutrient supplementation with n3 polyunsaturated fatty acids, lutein, and zeaxanthin decrease A2E accumulation and VEGF expression in the retinas of Ccl2/Cx3cr1-deficient mice on Crb1rd8 background, *The Journal of nutrition*, 2013, **143**, 1129-1135.
83. Q. Bian, S. Gao, J. Zhou, J. Qin, A. Taylor, E. J. Johnson, G. Tang, J. R. Sparrow, D. Gierhart and F. Shang, Lutein and zeaxanthin supplementation reduces photooxidative damage and modulates the expression of inflammation-related genes in retinal pigment epithelial cells, *Free Radical Biology and Medicine*, 2012, **53**, 1298-1307.
84. X. Zou, J. Gao, Y. Zheng, X. Wang, C. Chen, K. Cao, J. Xu, Y. Li, W. Lu, J. Liu and Z. Feng, Zeaxanthin induces Nrf2-mediated phase II enzymes in protection of cell death, *Cell death & disease*, 2014, **5**, e1218.
85. P. Meredith and T. Sarna, The physical and chemical properties of eumelanin, *Pigment Cell Res*, 2006, **19**, 572-594.
86. D. N. Hu, J. D. Simon and T. Sarna, Role of ocular melanin in ophthalmic physiology and pathology, *Photochem Photobiol*, 2008, **84**, 639-644.
87. C. T. Chen, C. Chuang, J. Cao, V. Ball, D. Ruch and M. J. Buehler, Excitonic effects from geometric order and disorder explain broadband optical absorption in eumelanin, *Nat Commun*, 2014, **5**, 3859.
88. M. Rozanowska, T. Sarna, E. J. Land and T. G. Truscott, Free radical scavenging properties of melanin interaction of eu- and pheo-melanin models with reducing and oxidising radicals, *Free Radic Biol Med*, 1999, **26**, 518-525.

89. R. N. Frank, J. E. Puklin, C. Stock and L. A. Canter, Race, iris color, and age-related macular degeneration, *Transactions of the American Ophthalmological Society*, 2000, **98**, 109-115; discussion 115-107.
90. B. E. Klein, K. P. Howard, S. K. Iyengar, T. A. Sivakumaran, K. J. Meyers, K. J. Cruickshanks and R. Klein, Sunlight exposure, pigmentation, and incident age-related macular degeneration, *Invest Ophthalmol Vis Sci*, 2014, **55**, 5855-5861.
91. C. Brockmann, T. Brockmann and J. Dawczynski, Influence of seasonal sunlight intensity and iris color on the anti-VEGF therapy for neovascular age-related macular degeneration, *Eye (Lond)*, 2013, **27**, 1169-1173.
92. E. G. Holliday, A. V. Smith, B. K. Cornes, G. H. Buitendijk, R. A. Jensen, X. Sim, T. Aspelund, T. Aung, P. N. Baird, E. Boerwinkle, C. Y. Cheng, C. M. van Duijn, G. Eiriksdottir, V. Gudnason, T. Harris, A. W. Hewitt, M. Inouye, F. Jonasson, B. E. Klein, L. Launer, X. Li, G. Liew, T. Lumley, P. McElduff, B. McKnight, P. Mitchell, B. M. Psaty, E. Roachchina, J. I. Rotter, R. J. Scott, W. Tay, K. Taylor, Y. Y. Teo, A. G. Uitterlinden, A. Viswanathan, S. Xie, C. Wellcome Trust Case Control, J. R. Vingerling, C. C. Klaver, E. S. Tai, D. Siscovick, R. Klein, M. F. Cotch, T. Y. Wong, J. Attia and J. J. Wang, Insights into the genetic architecture of early stage age-related macular degeneration: a genome-wide association study meta-analysis, *PLoS One*, 2013, **8**, e53830.
93. T. Sarna, J. M. Burke, W. Korytowski, M. Rozanowska, C. M. Skumatz, A. Zareba and M. Zareba, Loss of melanin from human RPE with aging: possible role of melanin photooxidation, *Exp Eye Res*, 2003, **76**, 89-98.

94. S. Ito, A. Pilat, W. Gerwat, C. M. Skumatz, M. Ito, A. Kiyono, A. Zadlo, Y. Nakanishi, L. Kolbe, J. M. Burke, T. Sarna and K. Wakamatsu, Photoaging of human retinal pigment epithelium is accompanied by oxidative modifications of its eumelanin, *Pigment Cell Melanoma Res*, 2013, **26**, 357-366.
95. L. Feeney-Burns, R. P. Burns and C. L. Gao, Age-related macular changes in humans over 90 years old, *Am J Ophthalmol*, 1990, **109**, 265-278.
96. M. Rozanowska and T. Sarna, Light-induced damage to the retina: role of rhodopsin chromophore revisited, *Photochem Photobiol*, 2005, **81**, 1305-1330.
97. S. P. Sundelin, S. E. Nilsson and U. T. Brunk, Lipofuscin-formation in cultured retinal pigment epithelial cells is related to their melanin content, *Free Radic Biol Med*, 2001, **30**, 74-81.
98. Z. Wang, J. Dillon and E. R. Gaillard, Antioxidant properties of melanin in retinal pigment epithelial cells, *Photochem Photobiol*, 2006, **82**, 474-479.
99. R. H. Kardon, S. Hong and A. Kawasaki, Entrance pupil size predicts retinal illumination in darkly pigmented eyes, but not lightly pigmented eyes, *Invest Ophthalmol Vis Sci*, 2013, **54**, 5559-5567.
100. V. Daneault, G. Vandewalle, M. Hebert, P. Teikari, L. S. Mure, J. Doyon, C. Gronfier, H. M. Cooper, M. Dumont and J. Carrier, Does pupil constriction under blue and green monochromatic light exposure change with age?, *Journal of biological rhythms*, 2012, **27**, 257-264.

101. P. A. Aspinall, S. Borooah, C. Al Alouch, J. Roe, A. Laude, R. Gupta, M. Gupta, A. Montarzino and B. Dhillon, Gaze and pupil changes during navigation in age-related macular degeneration, *Br J Ophthalmol*, 2014, **98**, 1393-1397.
102. B. R. Hammond, B. A. Johnson and E. R. George, Oxidative photodegradation of ocular tissues: beneficial effects of filtering and exogenous antioxidants, *Exp Eye Res*, 2014, **129**, 135-150.
103. D. van Norren and T. G. Gorgels, The action spectrum of photochemical damage to the retina: a review of monochromatic threshold data, *Photochem Photobiol*, 2011, **87**, 747-753.
104. J. Wu, S. Seregard and P. V. Algvere, Photochemical damage of the retina, *Surv Ophthalmol*, 2006, **51**, 461-481.
105. M. Donovan, R. J. Carmody and T. G. Cotter, Light-induced photoreceptor apoptosis in vivo requires neuronal nitric-oxide synthase and guanylate cyclase activity and is caspase-3-independent, *J Biol Chem*, 2001, **276**, 23000-23008.
106. D. T. Organisciak, R. M. Darrow, Y. I. Jiang, G. E. Marak and J. C. Blanks, Protection by dimethylthiourea against retinal light damage in rats, *Invest Ophthalmol Vis Sci*, 1992, **33**, 1599-1609.
107. S. Gartner and P. Henkind, Aging and degeneration of the human macula. 1. Outer nuclear layer and photoreceptors, *British Journal of Ophthalmology*, 1981, **65**, 23-28.
108. C. A. Curcio, Photoreceptor topography in ageing and age-related maculopathy, *Eye (Lond)*, 2001, **15**, 376-383.

109. G. S. Tucker, Refractile bodies in the inner segments of cones in the aging human retina, *Invest Ophthalmol Vis Sci*, 1986, **27**, 708-715.
110. M. Iwasaki and H. Inomata, Lipofuscin granules in human photoreceptor cells, *Invest Ophthalmol Vis Sci*, 1988, **29**, 671-679.
111. D. A. DiLoreto, Jr., M. R. Martzen, C. del Cerro, P. D. Coleman and M. del Cerro, Muller cell changes precede photoreceptor cell degeneration in the age-related retinal degeneration of the Fischer 344 rat, *Brain Res*, 1995, **698**, 1-14.
112. S. Ooto, M. Hangai, A. Tomidokoro, H. Saito, M. Araie, T. Otani, S. Kishi, K. Matsushita, N. Maeda, M. Shirakashi, H. Abe, S. Ohkubo, K. Sugiyama, A. Iwase and N. Yoshimura, Effects of age, sex, and axial length on the three-dimensional profile of normal macular layer structures, *Invest Ophthalmol Vis Sci*, 2011, **52**, 8769-8779.
113. H. Song, T. Y. P. Chui, Z. Zhong, A. E. Elsner and S. A. Burns, Variation of Cone Photoreceptor Packing Density with Retinal Eccentricity and Age, *Investigative Ophthalmology & Visual Science*, 2011, **52**, 7376-7384.
114. T. Y. P. Chui, H. Song, C. A. Clark, J. A. Papay, S. A. Burns and A. E. Elsner, Cone Photoreceptor Packing Density and the Outer Nuclear Layer Thickness in Healthy Subjects, *Investigative Ophthalmology & Visual Science*, 2012, **53**, 3545-3553.
115. S. P. Park, J. K. Chung, V. Greenstein, S. H. Tsang and S. Chang, A study of factors affecting the human cone photoreceptor density measured by adaptive optics scanning laser ophthalmoscope, *Exp Eye Res*, 2013, **108**, 1-9.
116. N. Ait-Ali, R. Fridlich, G. Millet-Puel, E. Clerin, F. Delalande, C. Jaillard, F. Blond, L. Perrocheau, S. Reichman, L. C. Byrne, A. Olivier-Bandini, J. Bellalou, E. Moyse, F. Bouillaud,

- X. Nicol, D. Dalkara, A. van Dorsselaer, J. A. Sahel and T. Leveillard, Rod-derived cone viability factor promotes cone survival by stimulating aerobic glycolysis, *Cell*, 2015, **161**, 817-832.
117. X. W. Wang, B. Z. Tan, M. Sun, B. Ho and J. L. Ding, Thioredoxin-like 6 protects retinal cell line from photooxidative damage by upregulating NF-kappaB activity, *Free Radic Biol Med*, 2008, **45**, 336-344.
118. G. Elachouri, I. Lee-Rivera, E. Clerin, M. Argentini, R. Fridlich, F. Blond, V. Ferracane, Y. Yang, W. Raffelsberger, J. Wan, J. Bennett, J. A. Sahel, D. J. Zack and T. Leveillard, Thioredoxin rod-derived cone viability factor protects against photooxidative retinal damage, *Free Radic Biol Med*, 2015, **81**, 22-29.
119. G. R. Jackson, C. Owsley and C. A. Curcio, Photoreceptor degeneration and dysfunction in aging and age-related maculopathy, *Ageing Res Rev*, 2002, **1**, 381-396.
120. S. Zayit-Soudry, J. L. Duncan, R. Syed, M. Menghini and A. J. Roorda, Cone structure imaged with adaptive optics scanning laser ophthalmoscopy in eyes with nonneovascular age-related macular degeneration, *Invest Ophthalmol Vis Sci*, 2013, **54**, 7498-7509.
121. D. A. VanNasdale, A. E. Elsner, T. D. Peabody, K. D. Kohne, V. E. Malinovsky, B. P. Haggerty, A. Weber, C. A. Clark and S. A. Burns, Henle fiber layer phase retardation changes associated with age-related macular degeneration, *Invest Ophthalmol Vis Sci*, 2015, **56**, 284-290.
122. J. Rogala, B. Zangerl, N. Assaad, E. L. Fletcher, M. Kalloniatis and L. Nivison-Smith, In vivo quantification of retinal changes associated with drusen in age-related macular degeneration, *Invest Ophthalmol Vis Sci*, 2015, **56**, 1689-1700.

123. R. Obata and Y. Yanagi, Quantitative analysis of cone photoreceptor distribution and its relationship with axial length, age, and early age-related macular degeneration, *PLoS One*, 2014, **9**, e91873.
124. V. Torbidoni, M. Iribarne, L. Ogawa, G. Prasanna and A. M. Suburo, Endothelin-1 and endothelin receptors in light-induced retinal degeneration, *Exp Eye Res*, 2005, **81**, 265-275.
125. D. T. Organisciak, R. M. Darrow, L. Barsalou, R. A. Darrow, R. K. Kutty, G. Kutty and B. Wiggert, Light history and age-related changes in retinal light damage, *Invest Ophthalmol Vis Sci*, 1998, **39**, 1107-1116.
126. R. W. Young, The renewal of rod and cone outer segments in the rhesus monkey, *J Cell Biol*, 1971, **49**, 303-318.
127. D. H. Anderson, S. K. Fisher and R. H. Steinberg, Mammalian cones: disc shedding, phagocytosis, and renewal, *Invest Ophthalmol Vis Sci*, 1978, **17**, 117-133.
128. R. S. Jonnal, J. R. Besecker, J. C. Derby, O. P. Kocaoglu, B. Cense, W. Gao, Q. Wang and D. T. Miller, Imaging outer segment renewal in living human cone photoreceptors, *Opt Express*, 2010, **18**, 5257-5270.
129. J. Y. Kim, H. Zhao, J. Martinez, T. A. Doggett, A. V. Kolesnikov, P. H. Tang, Z. Ablonczy, C. C. Chan, Z. Zhou, D. R. Green and T. A. Ferguson, Noncanonical autophagy promotes the visual cycle, *Cell*, 2013, **154**, 365-376.
130. T. A. Ferguson and D. R. Green, Autophagy and phagocytosis converge for better vision, *Autophagy*, 2014, **10**, 165-167.

131. V. L. Bonilha, Age and disease-related structural changes in the retinal pigment epithelium, *Clin Ophthalmol*, 2008, **2**, 413-424.
132. A. R. Wielgus and J. E. Roberts, Retinal photodamage by endogenous and xenobiotic agents, *Photochem Photobiol*, 2012, **88**, 1320-1345.
133. S. Schmitz-Valckenberg, F. G. Holz, A. C. Bird and R. F. Spaide, Fundus autofluorescence imaging: review and perspectives, *Retina*, 2008, **28**, 385-409.
134. T. Ach, C. Huisingh, G. McGwin, Jr., J. D. Messinger, T. Zhang, M. J. Bentley, D. B. Gutierrez, Z. Ablonczy, R. T. Smith, K. R. Sloan and C. A. Curcio, Quantitative autofluorescence and cell density maps of the human retinal pigment epithelium, *Invest Ophthalmol Vis Sci*, 2014, **55**, 4832-4841.
135. T. Ach, E. Tolstik, J. D. Messinger, A. V. Zarubina, R. Heintzmann and C. A. Curcio, Lipofuscin redistribution and loss accompanied by cytoskeletal stress in retinal pigment epithelium of eyes with age-related macular degeneration, *Invest Ophthalmol Vis Sci*, 2015, **56**, 3242-3252.
136. S. Schmitz-Valckenberg, M. Fleckenstein, H. P. Scholl and F. G. Holz, Fundus autofluorescence and progression of age-related macular degeneration, *Surv Ophthalmol*, 2009, **54**, 96-117.
137. L. G. Fritsche, M. Fleckenstein, B. S. Fiebig, S. Schmitz-Valckenberg, A. Bindewald-Wittich, C. N. Keilhauer, A. B. Renner, F. Mackensen, A. Mossner, D. Pauleikhoff, C. Adrion, U. Mansmann, H. P. Scholl, F. G. Holz and B. H. Weber, A subgroup of age-related macular degeneration is associated with mono-allelic sequence variants in the ABCA4 gene, *Invest Ophthalmol Vis Sci*, 2012, **53**, 2112-2118.

138. A. Wenzel, C. Grimm, M. Samardzija and C. E. Reme, Molecular mechanisms of light-induced photoreceptor apoptosis and neuroprotection for retinal degeneration, *Prog Retin Eye Res*, 2005, **24**, 275-306.
139. D. T. Organisciak and D. K. Vaughan, Retinal light damage: mechanisms and protection, *Prog Retin Eye Res*, 2010, **29**, 113-134.
140. M. B. Rozanowska, Light-induced damage to the retina: current understanding of the mechanisms and unresolved questions: a symposium-in-print, *Photochem Photobiol*, 2012, **88**, 1303-1308.
141. W. K. Noell, V. S. Walker, B. S. Kang and S. Berman, Retinal damage by light in rats, *Invest Ophthalmol*, 1966, **5**, 450-473.
142. W. K. Noell, Possible mechanisms of photoreceptor damage by light in mammalian eyes, *Vision Res*, 1980, **20**, 1163-1171.
143. W. T. Ham, Jr., J. J. Ruffolo, Jr., H. A. Mueller, A. M. Clarke and M. E. Moon, Histologic analysis of photochemical lesions produced in rhesus retina by short-wave-length light, *Invest Ophthalmol Vis Sci*, 1978, **17**, 1029-1035.
144. T. G. Gorgels and D. van Norren, Ultraviolet and green light cause different types of damage in rat retina, *Invest Ophthalmol Vis Sci*, 1995, **36**, 851-863.
145. C. Grimm, A. Wenzel, T. Williams, P. Rol, F. Hafezi and C. Reme, Rhodopsin-mediated blue-light damage to the rat retina: effect of photoreversal of bleaching, *Invest Ophthalmol Vis Sci*, 2001, **42**, 497-505.
146. Y. Barkana and M. Belkin, Laser eye injuries, *Surv Ophthalmol*, 2000, **44**, 459-478.

147. N. Khatib, B. Knyazer, T. Lifshitz and J. Levy, Acute eclipse retinopathy: a small case series, *Journal of optometry*, 2014, **7**, 225-228.
148. C. Keller, C. Grimm, A. Wenzel, F. Hafezi and C. Reme, Protective effect of halothane anesthesia on retinal light damage: inhibition of metabolic rhodopsin regeneration, *Invest Ophthalmol Vis Sci*, 2001, **42**, 476-480.
149. T. Maeda, M. Golczak and A. Maeda, Retinal photodamage mediated by all-trans-retinal, *Photochem Photobiol*, 2012, **88**, 1309-1319.
150. A. Ames, 3rd, Y. Y. Li, E. C. Heher and C. R. Kimble, Energy metabolism of rabbit retina as related to function: high cost of Na⁺ transport, *J Neurosci*, 1992, **12**, 840-853.
151. P. Bianchini, D. Calzia, S. Ravera, G. Candiano, A. Bachi, A. Morelli, M. Bruschi, I. M. Pepe, A. Diaspro and I. Panfoli, Live imaging of mammalian retina: rod outer segments are stained by conventional mitochondrial dyes, *J Biomed Opt*, 2008, **13**, 054017.
152. I. Panfoli, D. Calzia, M. Bruschi, M. Oneto, P. Bianchini, S. Ravera, A. Petretto, A. Diaspro and G. Candiano, Functional expression of oxidative phosphorylation proteins in the rod outer segment disc, *Cell biochemistry and function*, 2013, **31**, 532-538.
153. D. Calzia, G. Garbarino, F. Caicci, L. Manni, S. Candiani, S. Ravera, A. Morelli, C. E. Traverso and I. Panfoli, Functional expression of electron transport chain complexes in mouse rod outer segments, *Biochimie*, 2014, **102**, 78-82.
154. C. Roehlecke, U. Schumann, M. Ader, C. Brunssen, S. Bramke, H. Morawietz and R. H. Funk, Stress reaction in outer segments of photoreceptors after blue light irradiation, *PLoS One*, 2013, **8**, e71570.

155. Z. Nayernia, V. Jaquet and K. H. Krause, New insights on NOX enzymes in the central nervous system, *Antioxid Redox Signal*, 2014, **20**, 2815-2837.
156. J. C. Saari, Vitamin A metabolism in rod and cone visual cycles, *Annual review of nutrition*, 2012, **32**, 125-145.
157. J. S. Wang and V. J. Kefalov, The cone-specific visual cycle, *Prog Retin Eye Res*, 2011, **30**, 115-128.
158. F. Quazi, S. Lenevich and R. S. Molday, ABCA4 is an N-retinylidene-phosphatidylethanolamine and phosphatidylethanolamine importer, *Nat Commun*, 2012, **3**, 925.
159. J. J. Kaylor, Q. Yuan, J. Cook, S. Sarfare, J. Makshanoff, A. Miu, A. Kim, P. Kim, S. Habib, C. N. Roybal, T. Xu, S. Nusinowitz and G. H. Travis, Identification of DES1 as a vitamin A isomerase in Muller glial cells of the retina, *Nature chemical biology*, 2013, **9**, 30-36.
160. J. J. Kaylor, J. D. Cook, J. Makshanoff, N. Bischoff, J. Yong and G. H. Travis, Identification of the 11-cis-specific retinyl-ester synthase in retinal Muller cells as multifunctional O-acyltransferase (MFAT), *Proc Natl Acad Sci U S A*, 2014, **111**, 7302-7307.
161. Y. Xue, S. Q. Shen, J. Jui, A. C. Rupp, L. C. Byrne, S. Hattar, J. G. Flannery, J. C. Corbo and V. J. Kefalov, CRALBP supports the mammalian retinal visual cycle and cone vision, *J Clin Invest*, 2015, **125**, 727-738.
162. K. Palczewski, G protein-coupled receptor rhodopsin, *Annu Rev Biochem*, 2006, **75**, 743-767.

163. S. Nickell, P. S. Park, W. Baumeister and K. Palczewski, Three-dimensional architecture of murine rod outer segments determined by cryoelectron tomography, *J Cell Biol*, 2007, **177**, 917-925.
164. A. Maeda, M. Golczak, Y. Chen, K. Okano, H. Kohno, S. Shiose, K. Ishikawa, W. Harte, G. Palczewska, T. Maeda and K. Palczewski, Primary amines protect against retinal degeneration in mouse models of retinopathies, *Nature chemical biology*, 2012, **8**, 170-178.
165. H. Sun and J. Nathans, ABCR, the ATP-binding cassette transporter responsible for Stargardt macular dystrophy, is an efficient target of all-trans-retinal-mediated photooxidative damage in vitro. Implications for retinal disease, *J Biol Chem*, 2001, **276**, 11766-11774.
166. M. Rozanowska, K. Handzel, M. E. Boulton and B. Rozanowski, Cytotoxicity of all-trans-retinal increases upon photodegradation, *Photochem Photobiol*, 2012, **88**, 1362-1372.
167. A. Maeda, G. Palczewska, M. Golczak, H. Kohno, Z. Dong, T. Maeda and K. Palczewski, Two-photon microscopy reveals early rod photoreceptor cell damage in light-exposed mutant mice, *Proc Natl Acad Sci U S A*, 2014, **111**, E1428-1437.
168. Y. Chen, K. Okano, T. Maeda, V. Chauhan, M. Golczak, A. Maeda and K. Palczewski, Mechanism of all-trans-retinal toxicity with implications for stargardt disease and age-related macular degeneration, *J Biol Chem*, 2012, **287**, 5059-5069.
169. S. Shiose, Y. Chen, K. Okano, S. Roy, H. Kohno, J. Tang, E. Pearlman, T. Maeda, K. Palczewski and A. Maeda, Toll-like receptor 3 is required for development of retinopathy

- caused by impaired all-trans-retinal clearance in mice, *J Biol Chem*, 2011, **286**, 15543-15555.
170. H. Kohno, Y. Chen, B. M. Kevany, E. Pearlman, M. Miyagi, T. Maeda, K. Palczewski and A. Maeda, Photoreceptor Proteins Initiate Microglial Activation via Toll-like Receptor 4 in Retinal Degeneration Mediated by All-trans-retinal, *J Biol Chem*, 2013, **288**, 15326-15341.
171. M. Y. Loginova, Y. V. Rostovtseva, T. B. Feldman and M. A. Ostrovsky, Light Damaging Action of all-trans-Retinal and Its Derivatives on Rhodopsin Molecules in the Photoreceptor Membrane, *Biochemistry (Mosc)*, 2007, **73**, 130-138.
172. A. R. Wielgus, C. F. Chignell, P. Ceger and J. E. Roberts, Comparison of A2E cytotoxicity and phototoxicity with all-trans-retinal in human retinal pigment epithelial cells, *Photochem Photobiol*, 2010, **86**, 781-791.
173. C. Bavik, S. H. Henry, Y. Zhang, K. Mitts, T. McGinn, E. Budzynski, A. Pashko, K. L. Lieu, S. Zhong, B. Blumberg, V. Kuksa, M. Orme, I. Scott, A. Fawzi and R. Kubota, Visual Cycle Modulation as an Approach toward Preservation of Retinal Integrity, *PLoS One*, 2015, **10**, e0124940.
174. J. Zhang, P. D. Kiser, M. Badiie, G. Palczewska, Z. Dong, M. Golczak, G. P. Tochtrop and K. Palczewski, Molecular pharmacodynamics of emixustat in protection against retinal degeneration, *J Clin Invest*, 2015, DOI: 10.1172/JCI80950.
175. K. P. Ng, B. Gugiu, K. Renganathan, M. W. Davies, X. Gu, J. S. Crabb, S. R. Kim, M. B. Rozanowska, V. L. Bonilha, M. E. Rayborn, R. G. Salomon, J. R. Sparrow, M. E. Boulton, J. G.

- Hollyfield and J. W. Crabb, Retinal pigment epithelium lipofuscin proteomics, *Mol Cell Proteomics*, 2008, **7**, 1397-1405.
176. J. R. Sparrow, E. Gregory-Roberts, K. Yamamoto, A. Blonska, S. K. Ghosh, K. Ueda and J. Zhou, The bisretinoids of retinal pigment epithelium, *Prog Retin Eye Res*, 2012, **31**, 121-135.
177. M. E. Boulton, Studying melanin and lipofuscin in RPE cell culture models, *Exp Eye Res*, 2014, **126**, 61-67.
178. E. Arnault, C. Barrau, C. Nanteau, P. Gondouin, K. Bigot, F. Vienot, E. Gutman, V. Fontaine, T. Villette, D. Cohen-Tannoudji, J. A. Sahel and S. Picaud, Phototoxic action spectrum on a retinal pigment epithelium model of age-related macular degeneration exposed to sunlight normalized conditions, *PLoS One*, 2013, **8**, e71398.
179. Y. Wu, E. Yanase, X. Feng, M. M. Siegel and J. R. Sparrow, Structural characterization of bisretinoid A2E photocleavage products and implications for age-related macular degeneration, *Proc Natl Acad Sci U S A*, 2010, **107**, 7275-7280.
180. A. R. Wielgus, R. J. Collier, E. Martin, F. B. Lih, K. B. Tomer, C. F. Chignell and J. E. Roberts, Blue light induced A2E oxidation in rat eyes--experimental animal model of dry AMD, *Photochemical & photobiological sciences : Official journal of the European Photochemistry Association and the European Society for Photobiology*, 2010, **9**, 1505-1512.
181. K. D. Yoon, K. Yamamoto, K. Ueda, J. Zhou and J. R. Sparrow, A novel source of methylglyoxal and glyoxal in retina: implications for age-related macular degeneration, *PLoS One*, 2012, **7**, e41309.

182. J. Zhou, S. R. Kim, B. S. Westlund and J. R. Sparrow, Complement activation by bisretinoid constituents of RPE lipofuscin, *Invest Ophthalmol Vis Sci*, 2009, **50**, 1392-1399.
183. R. A. Radu, J. Hu, Z. Jiang and D. Bok, Bisretinoid-mediated complement activation on retinal pigment epithelial cells is dependent on complement factor H haplotype, *J Biol Chem*, 2014, **289**, 9113-9120.
184. A. C. Grey, R. K. Crouch, Y. Koutalos, K. L. Schey and Z. Ablonczy, Spatial localization of A2E in the retinal pigment epithelium, *Invest Ophthalmol Vis Sci*, 2011, **52**, 3926-3933.
185. R. T. Smith, P. S. Bernstein and C. A. Curcio, Rethinking A2E, *Invest Ophthalmol Vis Sci*, 2013, **54**, 5543.
186. Z. Ablonczy, D. Higbee, D. M. Anderson, M. Dahrouj, A. C. Grey, D. Gutierrez, Y. Koutalos, K. L. Schey, A. Hanneken and R. K. Crouch, Lack of correlation between the spatial distribution of A2E and lipofuscin fluorescence in the human retinal pigment epithelium, *Invest Ophthalmol Vis Sci*, 2013, **54**, 5535-5542.
187. Z. Ablonczy, D. Higbee, A. C. Grey, Y. Koutalos, K. L. Schey and R. K. Crouch, Similar molecules spatially correlate with lipofuscin and N-retinylidene-N-retinylethanolamine in the mouse but not in the human retinal pigment epithelium, *Archives of biochemistry and biophysics*, 2013, **539**, 196-202.
188. C. Brandstetter, L. K. Mohr, E. Latz, F. G. Holz and T. U. Krohne, Light induces NLRP3 inflammasome activation in retinal pigment epithelial cells via lipofuscin-mediated photooxidative damage, *J Mol Med (Berl)*, 2015, DOI: 10.1007/s00109-015-1275-1.
189. R. Allikmets, N. F. Shroyer, N. Singh, J. M. Seddon, R. A. Lewis, P. S. Bernstein, A. Peiffer, N. A. Zabriskie, Y. Li, A. Hutchinson, M. Dean, J. R. Lupski and M. Leppert, Mutation

of the Stargardt disease gene (ABCR) in age-related macular degeneration, *Science*, 1997, **277**, 1805-1807.

190. R. Allikmets, Further evidence for an association of ABCR alleles with age-related macular degeneration. The International ABCR Screening Consortium, *Am J Hum Genet*, 2000, **67**, 487-491.

191. M. M. Teussink, M. D. Lee, R. T. Smith, R. A. van Huet, C. C. Klaver, B. J. Klevering, T. Theelen and C. B. Hoyng, The effect of light deprivation in patients with Stargardt disease, *Am J Ophthalmol*, 2015, **159**, 964-972 e962.

192. L. Wu, K. Ueda, T. Nagasaki and J. R. Sparrow, Light damage in Abca4 and Rpe65rd12 mice, *Invest Ophthalmol Vis Sci*, 2014, **55**, 1910-1918.

193. R. A. Radu, J. Hu, Q. Yuan, D. L. Welch, J. Makshanoff, M. Lloyd, S. McMullen, G. H. Travis and D. Bok, Complement system dysregulation and inflammation in the retinal pigment epithelium of a mouse model for Stargardt macular degeneration, *J Biol Chem*, 2011, **286**, 18593-18601.

194. J. E. Berchuck, P. Yang, B. A. Toimil, Z. Ma, P. Baciuc and G. J. Jaffe, All-trans-retinal sensitizes human RPE cells to alternative complement pathway-induced cell death, *Invest Ophthalmol Vis Sci*, 2013, **54**, 2669-2677.

195. A. Liu, J. Chang, Y. Lin, Z. Shen and P. S. Bernstein, Long-chain and very long-chain polyunsaturated fatty acids in ocular aging and age-related macular degeneration, *J Lipid Res*, 2010, **51**, 3217-3229.

196. D. T. Organisciak, R. M. Darrow, Y. L. Jiang and J. C. Blanks, Retinal light damage in rats with altered levels of rod outer segment docosahexaenoate, *Invest Ophthalmol Vis Sci*, 1996, **37**, 2243-2257.
197. R. A. Bush, C. E. Reme and A. Malnoe, Light damage in the rat retina: the effect of dietary deprivation of N-3 fatty acids on acute structural alterations, *Exp Eye Res*, 1991, **53**, 741-752.
198. F. Quazi and R. S. Molday, ATP-binding cassette transporter ABCA4 and chemical isomerization protect photoreceptor cells from the toxic accumulation of excess 11-cis-retinal, *Proc Natl Acad Sci U S A*, 2014, **111**, 5024-5029.
199. P. K. Mukherjee, V. L. Marcheselli, J. C. de Rivero Vaccari, W. C. Gordon, F. E. Jackson and N. G. Bazan, Photoreceptor outer segment phagocytosis attenuates oxidative stress-induced apoptosis with concomitant neuroprotectin D1 synthesis, *Proc Natl Acad Sci U S A*, 2007, **104**, 13158-13163.
200. D. L. Birkle and N. G. Bazan, Light exposure stimulates arachidonic acid metabolism in intact rat retina and isolated rod outer segments, *Neurochem Res*, 1989, **14**, 185-190.
201. M. De La Paz and R. E. Anderson, Region and age-dependent variation in susceptibility of the human retina to lipid peroxidation, *Invest Ophthalmol Vis Sci*, 1992, **33**, 3497-3499.
202. M. Suzuki, M. Kamei, H. Itabe, K. Yoneda, H. Bando, N. Kume and Y. Tano, Oxidized phospholipids in the macula increase with age and in eyes with age-related macular degeneration, *Mol Vis*, 2007, **13**, 772-778.

203. M. Suzuki, M. Tsujikawa, H. Itabe, Z. J. Du, P. Xie, N. Matsumura, X. Fu, R. Zhang, K. H. Sonoda, K. Egashira, S. L. Hazen and M. Kamei, Chronic photo-oxidative stress and subsequent MCP-1 activation as causative factors for age-related macular degeneration, *J Cell Sci*, 2012, **125**, 2407-2415.
204. J. W. Crabb, M. Miyagi, X. Gu, K. Shadrach, K. A. West, H. Sakaguchi, M. Kamei, A. Hasan, L. Yan, M. E. Rayborn, R. G. Salomon and J. G. Hollyfield, Drusen proteome analysis: an approach to the etiology of age-related macular degeneration, *Proc Natl Acad Sci U S A*, 2002, **99**, 14682-14687.
205. F. Schutt, M. Bergmann, F. G. Holz and J. Kopitz, Proteins modified by malondialdehyde, 4-hydroxynonenal, or advanced glycation end products in lipofuscin of human retinal pigment epithelium, *Invest Ophthalmol Vis Sci*, 2003, **44**, 3663-3668.
206. D. T. Organisciak, R. M. Darrow, C. M. Rapp, J. P. Smuts, D. W. Armstrong and J. C. Lang, Prevention of retinal light damage by zinc oxide combined with rosemary extract, *Mol Vis*, 2013, **19**, 1433-1445.
207. J. G. Hollyfield, V. L. Perez and R. G. Salomon, A Hapten Generated from an Oxidation Fragment of Docosahexaenoic Acid Is Sufficient to Initiate Age-Related Macular Degeneration, *Mol Neurobiol*, 2010, **41**, 290-298.
208. R. G. Salomon, Distinguishing levuglandins produced through the cyclooxygenase and isoprostane pathways, *Chemistry and physics of lipids*, 2005, **134**, 1-20.
209. E. Poliakov, M. L. Brennan, J. Macpherson, R. Zhang, W. Sha, L. Narine, R. G. Salomon and S. L. Hazen, Isolevuglandins, a novel class of isoprostenoid derivatives,

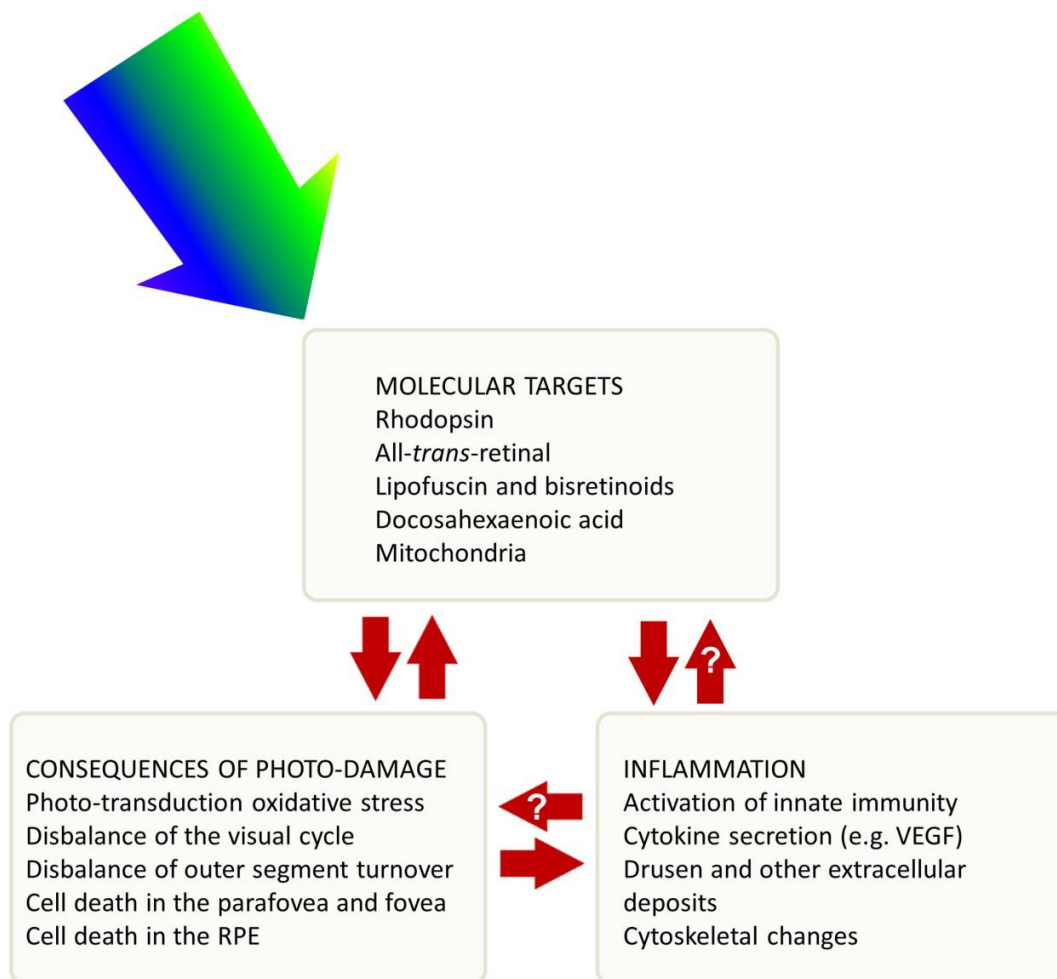
function as integrated sensors of oxidant stress and are generated by myeloperoxidase in vivo, *FASEB J*, 2003, **17**, 2209-2220.

210. W. Li, J. M. Laird, L. Lu, S. Roychowdhury, L. E. Nagy, R. Zhou, J. W. Crabb and R. G. Salomon, Isolevuglandins covalently modify phosphatidylethanolamines in vivo: detection and quantitative analysis of hydroxylactam adducts, *Free Radic Biol Med*, 2009, **47**, 1539-1552.

211. C. Charvet, W. L. Liao, G. Y. Heo, J. Laird, R. G. Salomon, I. V. Turko and I. A. Pikuleva, Isolevuglandins and mitochondrial enzymes in the retina: mass spectrometry detection of post-translational modification of sterol-metabolizing CYP27A1, *J Biol Chem*, 2011, **286**, 20413-20422.

212. C. D. Charvet, A. Saadane, M. Wang, R. G. Salomon, H. Brunengraber, I. V. Turko and I. A. Pikuleva, Pretreatment with pyridoxamine mitigates isolevuglandin-associated retinal effects in mice exposed to bright light, *J Biol Chem*, 2013, **288**, 29267-29280.

Graphical abstract



Legend for Graphical Abstract

The course of Age-related Macular Degeneration (AMD) is described as the effect of light (400-580 nm) on several molecular targets in photoreceptors and the retinal pigment epithelium (RPE). Photo-oxidative changes determine damage of cellular structures, and may determine the appearance of secondary molecular targets, such as bisretinoids and lipofuscin. Photo-damage results in severe disturbances followed by death of macular

photoreceptors and RPE cells. Photo-oxidation and photo-damage elicit several inflammatory processes that support development of characteristic drusen and VEGF-induced angiogenesis, typical of AMD. Question marks indicate that photo-damage- and inflammatory-derived products could perhaps contribute other photo-sensitive molecules, thus increasing the initial damage.

Short statement of Novelty

The course of Age-related Macular Degeneration (AMD) is described as the effect of light (400-580 nm) on various molecular targets in photoreceptors and the retinal pigment epithelium (RPE).