

ID Design Press, Skopje, Republic of Macedonia
 Open Access Macedonian Journal of Medical Sciences. 2019 Dec 30; 7(24):4368-4371.
<https://doi.org/10.3889/oamjms.2019.837>
 eISSN: 1857-9655
Basic and Clinical Medical Researches in Vietnam



A Rare Colonic Metastasis Case from Hepatocellular Carcinoma

Binh Van Pham¹, Huynh Huu Phan¹, Lam Le Ngo¹, Hang Thi Thuy Nguyen¹, Ky Van Le¹, Thien Chu Dinh², Nguyen Duy Bac^{3*}

¹Vietnam National Cancer Hospital, Hanoi, Vietnam; ²Institute for Research and Development, Duy Tan University, 03 Quang Trung, Danang, Vietnam; ³Vietnam Military Medical University (VMMU), Hanoi, Vietnam

Abstract

Citation: Van Pham B, Huu Phan H, Le Ngo L, Nguyen HTT, Le KV, Chu Dinh Y, Bac ND. A Rare Colonic Metastasis Case from Hepatocellular Carcinoma. Open Access Maced J Med Sci. 2019 Dec 30; 7(24):4368-4371. <https://doi.org/10.3889/oamjms.2019.837>

Keywords: Hepatocellular carcinoma; GI metastasis; Sigmoid metastasis

***Correspondence:** Nguyen Duy Bac. Vietnam Military Medical University (VMMU), Hanoi, Vietnam. E-mail: nguyenduybac@vmmu.edu.vn

Received: 11-Sep-2019; **Revised:** 20-Nov-2019; **Accepted:** 21-Nov-2019; **Online first:** 20-Dec-2019

Copyright: © 2019 Binh Van Pham, Huynh Huu Phan, Lam Le Ngo, Hang Thi Thuy Nguyen, Ky Van Le, Thien Chu Dinh, Nguyen Duy Bac. This is an open-access article distributed under the terms of the Creative Commons Attribution-NonCommercial 4.0 International License (CC BY-NC 4.0)

Funding: This research did not receive any financial support

Competing Interests: The authors have declared that no competing interests exist

BACKGROUND: Hepatocellular carcinoma (HCC) metastasis include intrahepatic and extrahepatic metastasis. Similar to intrahepatic metastasis, extrahepatic metastases are not unusual in cases with HCC. However, colonic metastasis is infrequent.

CASE REPORT: We describe a clinical case, he was diagnosed with HCC a year ago, treated with TACE (transarterial chemoembolisation), re-examined with abdominal pain and defecation disorder. The tests such as CT scan, colorectal endoscopy, fine needle aspiration (FNA) revealed secondary metastatic lesion of HCC in sigmoid colon. This is the first gastrointestinal (GI) tract metastatic we have encountered.

CONCLUSION: HCC metastases of the colon are rare, especially cases of hematogenous spread. The prognosis of these patients is often very critical. Indications for surgical removal of the lesion may be used if the general situation of patient is acceptable.

Introduction

In the top ten frequent cancers worldwide, the cancers of lung, breast, prostate, colon, non-melanoma of skin, and stomach are followed by primary liver cancer. On the other hand, primary liver cancer is one of most common causes of death which relative to cancer diseases globally due to its extremely poor prognosis [1]. It is not denying that many patients could not be diagnosed at early stage. Even though surveillance programs for early liver cancer and hepatocellular carcinoma (HCC) have been implemented. Consequently, only 30% of them take advantage of radical treatment such as hepatectomy, liver transplant surgery [2]. Extrahepatic metastasis of HCC is not rare, lung and adrenal are two of typical side. Gastrointestinal (GI) tract metastasis from HCC is not common. Distal colon metastasis is extremely uncommon situation of extrahepatic metastasis. This article aims to present a case of HCC patient with a

single colonic metastatic lesion which derive from HCC treated with TACE.

Case Report

The patient was 60 years old; he had been infected hepatitis B virus for 15 years was determined to have HCC in 2018. He received TACE. This man has been reexamined every three months. The result of CT scans and AFP test were normal. He visited our center because tenesmus and left lower quadrant abdominal pain lasting for several days.

Nothing abnormal was found during physical examination. The result of AFP was 9.48 ng/ml. Other laboratory tests were within normal limits. A colonoscopy revealed a mass located in sigmoid colon with intact overlying mucosa so the biopsy

procedure was not performed. CT scan revealed a 50 x 60 mm sized, bulging contoured mass located in sigmoid colon (Figure 1E and 1F). A natural hypodense mass with 39 x 41 mm located in segment IV – VIII of liver (Figure 1A), no enhancement at arterial phase. Several hypervascular lesions located in both lobes (Figure 1B and 1C). An ultra sound – guided FNA biopsy was performed. Result of pathology demonstrated metastasis of carcinoma.

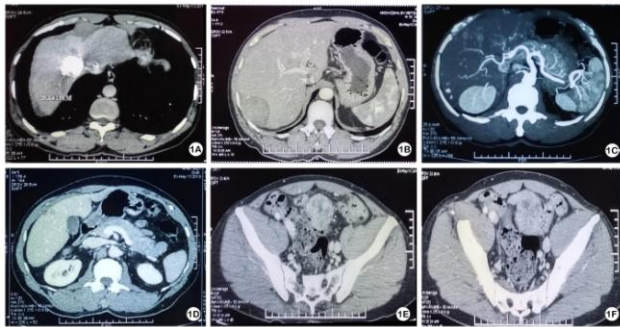


Figure 1: CT scan result: A natural hypodense mass with 39 x 41 mm located in segment IV – VIII

At the multidisciplinary team meeting, we decided that he would undergo surgical treatment first. The patient underwent anterior resection. He tolerated that surgical procedure without any complication.

Gross examination, the 15 cm rectosigmoid segment with smooth surface mucosa had two well-circumscribed masses measuring 50 x 40 x 35 mm and 15 x 10 x 10 mm and pushing the serosa. The cut surface was tan-yellow. Nine masses ranging from 15 x 10 x 10 mm to 30 x 30 x 20 mm attaching to adipose tissue were removed from the mesentery. They shared similar features with intestinal masses. Histopathological examination showed the tumor found under the mucosa was composed of atypical polygonal cells with irregular hyperchromatic nuclei, prominent nucleoli and clear or eosinophilic cytoplasm (Figure 2A). They were arranged in large sheets or trabeculae. Vascular invasion was seen (Figure 2B).

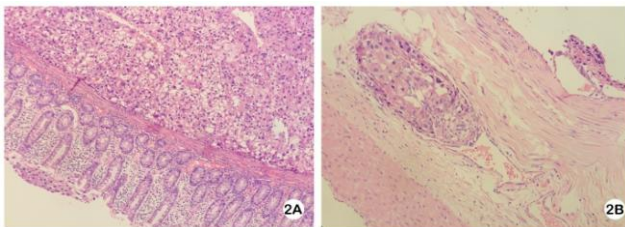


Figure 2: The tumor is in submucosa, was composed of a typical polygonal cells that resemble HCC 2A) and vascular invasion 2B)

Immunohistochemistry staining were utilized. They show the reacting positively for Hepar-1 and Arginase-1 (Figure 3A and B).

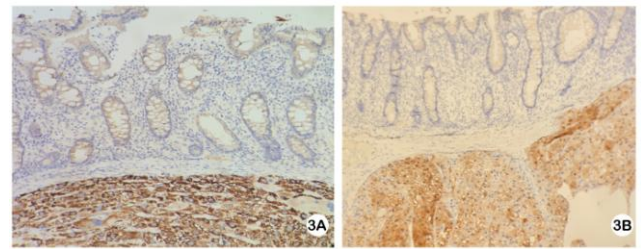


Figure 3: Immunohistochemical staining, the tumor cells were positive for Hepar-1 3A) and Arginase-1 3B)

After completing recovery, he started received HAIC (hepatic arterial infusion chemotherapy). We concluded that the metastasis lesion in sigmoid colon appeared due to the seeding which occurs after some interventional techniques such as TACE. The lesion had been removed completely. On the other hand, there was no evidence of other extrahepatic metastasis. Moreover, the patient did not accept the expense of target therapy. As result, we decided HAIC is convenience therapy for him. The patient had been treated with HAIC-mFP, 3 cycles. The response was quite good. AFP and PIVKA-II were decrease.

Discussion

Currently, liver cancer is classified as the third cause of death due to malignant diseases over the world, approximately 800 000 per year. Liver cancer has particular age, sex and geographic distributions, likely influenced by certain etiologic variables. Histologically, the majority of liver cancer falls into one of two categories: HCC and ICC (intrahepatic cholangiocarcinoma), and cholangiocarcinoma is less common. Even though malignant hepatic tumor is more common in developing countries, it is still significantly prevalent in other developed regions such as North America and central Europe [3]. While other cancers, like breast, lung, and colorectal cancer are on the decline, the mortality rate for primary liver cancer has increased in both sexes in recent decades [4]. While hepatitis B is a paving hepatic cancer risk factor in Asia, hepatitis C infection is reason why the incidence of liver cancer is increasing in the US. Furthermore, other significant risk factors include aflatoxin B1 poisoning, diabetes, alcoholic abuse, non-alcoholic fatty liver disease [5].

Among malignant diseases of the liver, the most frequent is HCC, the direct cause of the disease is unclear, the mechanism of the disease is thought to be a disorder of the DNA structure of the cell nucleus [6]. According the Globocan 2018 data base, the number new HCC cases in Vietnam (both sexes, all ages) is highest (25 335 – 15.4%). As reported by a recently published study on HCC in southern and central Vietnam, statistics show that there were 24

091 patients between 2010 and 2016, with a significant increase over the years (from 2793 cases in 2010 to 4069 in 2016), men were the majority compared to women, most patients were positive for viral hepatitis (88.3% positive for hepatitis B or hepatitis C and 2.7% simultaneously positive for both of them) [7].

HCC is considered to be a cancer with a very high degree of malignancy, it has the tend to invade the portal vein as well as the liver vein. Therefore, lymph node metastases and distant metastases are also common, about 50% [8], especially for tumors larger than 5 cm in diameter [9]. Most extrahepatic HCC has been observed in cases with advanced stage of disease (stage VIa), as expected [10]. The longer a patient survives, the more risk of extrahepatic metastases increases and metastases to the lungs, bones, lymph nodes are most common [8].

Signs and symptoms of patients suffering from HCC primarily focused on the manifestation of the primary tumor and the metastatic features later. Recently, the metastatic characteristics of HCC has displayed two alluring new behaviors: the unexpected spread site, and the discovery of the metastatic lesion before the primary tumor is recognized. Metastases to the gastrointestinal tract are rare and mainly reported by clinical case reports. Direct invasion through the adjoining serous tumor due to the excessive growth of a primary tumor is a common mechanism and the invasive organ is often the duodenum, the stomach, jejunum, and colon (anatomical location close to the liver) [11], [12]. Metastases to other parts of the gastrointestinal tract are rarer and have not been adequately explained. Hematogenous dissemination is a hypothesis of distant GI tract metastasis. The explanation of haematogenous spread has been supposed to be the blockage of portal vein come after the vascular was infiltrated. The existence of tumour thrombosis in the portal vein may lead to a reversal of flow, which likely acts as the medium of haematogenous metastasis of HCC to the GI tract [13]. Transarterial embolization (TAE) and TACE can also cause increased portal vein pressure to cause blood clots and reverse flow [12], enabling HCC to invade nearby organs such as the colon or other parts of the digestive tract.

Main local symptoms of colon metastasis from HCC patient are blood in stool, changed defecation pattern, abdominal pain, very similar with primary colorectal cancer. Unfortunately, gastrointestinal endoscopy is easy to confuse metastatic damage of HCC with polyps, mucosal tumors or colorectal ulcers. Sometimes, it is really difficult to identify them through endoscopic examination and performed biopsy, especially the lesions which have intact overlying mucosal. Therefore, immunohistochemistry is considered an effective tool for the differential diagnosis between liver cancer and adenocarcinoma of the colorectal. Hepar-1, Arg-1, GPC-3, p-CEA, BSEP are some popular immunohistochemical

markers which are available for establishing the diagnosis. As previously study, Hepar-1 and p-CEA are the two most widely used markers for high sensitivity and specificity [14], [15].

Some reports indicate GI metastasis usually could be detected between 3 months to 8 years from the initial confirmation of HCC [11], [16], [17]. Nasuizaka et al., reported an average survival time of HCC patients with metastatic gastrointestinal tract was 7 months (1-59 months) and only 24.9% lived more than 1 year or more [10]. Another aspect for these patients is whether the treatment to eliminate extrahepatic metastatic lesions is effective, especially in the early cases with good liver function and no portal vein invasion [18]. Although there is too little evidence and insufficient data to prove the effectiveness of surgical treatment, especially for colon metastases in HCC patients, we believe that surgery removes this type of metastatic injury is especially necessary for patients with only a single metastatic lesion and good physical condition.

In conclusion, this article aims to report a patient with HCC who has metastases of sigmoid colon. This is a very rare clinical morphology and is the first case in our clinic. Medical history has noted that HCC's extrahepatic metastases are quite common but colon metastases are very rare. Like other metastatic cases, colon metastasis patients have not delight outcome. Surgery to remove metastatic lesions is thought to be a treatment option especially for patients who had good liver function and acceptable condition.

Ethical approval

This study is approved by the ethics committee of Vietnam National Cancer Hospital

Informed consent

The consent and commitment were signed by the patients in the study

References

1. Bray F, et al. Global cancer statistics 2018: GLOBOCAN estimates of incidence and mortality worldwide for 36 cancers in 185 countries. *CA Cancer J Clin.* 2018; 68(6):394-424. <https://doi.org/10.3322/caac.21492> PMID:30207593

2. Llovet JM, Burroughs A, Bruix J. Hepatocellular carcinoma. *Lancet*. 2003; 362:1907-1917. [https://doi.org/10.1016/S0140-6736\(03\)14964-1](https://doi.org/10.1016/S0140-6736(03)14964-1)
3. Hashim D, Boffetta PP, La Vecchia C, et al. The global decrease in cancer mortality: trends and disparities. *Ann Oncol*. 2016; 27:926-33. <https://doi.org/10.1093/annonc/mdw027> PMID:26802157
4. Siegel RL, Miller KD, Jemal A. Cancer statistics. *CA Cancer J Clin*. 2016; 66:7-30. <https://doi.org/10.3322/caac.21332> PMID:26742998
5. Makariva-Rusher OV, Altekruse SF, McNeel TS. Population - attributable fractions of risk factors for hepatocellular carcinoma in the United States. *Cancer*. 2016; 122:1757-65. <https://doi.org/10.1002/cncr.29971> PMID:26998818 PMCID:PMC5548177
6. Alison MR. Liver stem cells: implications for hepatocarcinogenesis. *Stem Cell Rev*. 2005; 1(3):253-60. <https://doi.org/10.1385/SCR.1.3:253>
7. Nguyen Dinh SH, Do A, Pham TND, et al. High burden of hepatocellular carcinoma and viral hepatitis in Southern and Central Vietnam: Experience of a large tertiary referral center, 2010 to 2016. *World J Hepatol*. 2018; 10(1):116-123. <https://doi.org/10.4254/wjh.v10.i1.116> PMID:29399285 PMCID:PMC5787675
8. Si Ms, Amersi F, Golish SR, Ortiz JA, et al. Prevalence of metastases in hepatocellular carcinoma: risk factors and impact on survival. *Am Surg*. 2003; 69:879-885.
9. Yuki K, Hirohashi S, Sakamoto M. Growth and spread of hepatocellular carcinoma. *Cancer*. 1990; 66:2174-2179. [https://doi.org/10.1002/1097-0142\(19901115\)66:10<2174::AID-CNCR2820661022>3.0.CO;2-A](https://doi.org/10.1002/1097-0142(19901115)66:10<2174::AID-CNCR2820661022>3.0.CO;2-A)
10. Natsuzaka M, Omura T, Akaike T, et al. Clinical features of hepatocellular carcinoma with extra hepatic metastases. *J Gastroenterol Hepatol*. 2005; 20:1781-1787. <https://doi.org/10.1111/j.1440-1746.2005.03919.x> PMID:16246200
11. Chen LT, Chen CY, Jan CM, et al. Gastrointestinal tract involvement in hepatocellular carcinoma: clinical, radiological and endoscopic studies. *Endoscopy*. 1990; 118-123. <https://doi.org/10.1055/s-2007-1012815> PMID:2162757
12. Hu ML, Tai WC, Chuah SK. Gastric metastasis of hepatocellular carcinoma via a possible existing retrograde hematogenous pathway. *J Gastroenterol Hepatol*. 2010; 25(2):408-412. <https://doi.org/10.1111/j.1440-1746.2009.06022.x> PMID:19929932
13. Tapuria N, Sinha CK, Michael NG, Fisher PW. Haematogenous metastasis to ascending colon in a patient with hepatocellular carcinoma and autoimmune hepatitis. *Eur J Gastroenterol Hepatol*. 2007; 19:607-609. <https://doi.org/10.1097/MEG.0b013e3281c55f3e> PMID:17556911
14. Chu PG, Ishizawa S, Wu E, Weiss LM. Hepatocyte antigen as a marker of hepatocellular carcinoma: an immunohistochemical comparison to carcinoembryonic antigen, CD10, and alpha-fetoprotein. *Am J Surg Pathol*. 2002; 26(8):978-988. <https://doi.org/10.1097/0000478-200208000-00002> PMID:12170084
15. Fan Z, van de Rijin M, Montgomery K, Rouse RV. Hep Par 1 antibody stain for the differential diagnosis of hepatocellular carcinoma: 676 tumors tested using tissue microarrays and conventional tissue sections. *Mod Pathol*. 2003; 16(2):137-144. <https://doi.org/10.1097/01.MP.0000052103.13730.20> PMID:12591966
16. Lin CP, Cheng JS, Lai KH, et al. Gastrointestinal metastasis in hepatocellular carcinoma: radiological and endoscopic studies of 11 cases. *J Gastroenterol Hepatol*. 2000; 15:536-541. <https://doi.org/10.1046/j.1440-1746.2000.02152.x> PMID:10847441
17. Park MS, Kim KW, Yu JS, et al. Radiologic findings of gastrointestinal tract involvement in hepatocellular carcinoma. *J Comput Assist Tomogr*. 2002; 26:95-101. <https://doi.org/10.1097/00004728-200201000-00014> PMID:11801910
18. Uka K, Aikata H, Takaki S. Clinical features and prognosis of patients with extrahepatic metastases from hepatocellular carcinoma. *World J Gastroenterol*. 2007; 13:414-420. <https://doi.org/10.3748/wjg.v13.i3.414> PMID:17230611 PMCID:PMC4065897