

ID Design Press, Skopje, Republic of Macedonia
Open Access Macedonian Journal of Medical Sciences. 2019 Dec 30; 7(24):4244-4249.
<https://doi.org/10.3889/oamjms.2019.368>
eISSN: 1857-9655

Basic and Clinical Medical Researches in Vietnam



Efficacy and Toxicity of Folfoxiri for Patients with Metastatic Colorectal Cancer

Trinh Le Huy¹, My Hanh Bui^{2,3*}, Toi Chu Dinh⁴, Hoang Thi Hong Xuyen⁵

¹Department of Oncology, Hanoi Medical University Hospital, Hanoi, Vietnam; ²Tuberculosis and Lung Disease Department, Hanoi Medical University, Hanoi, Vietnam; ³Scientific Research & International Cooperation Department, Hanoi Medical University Hospital, Hanoi, Vietnam; ⁴Department of Human and Animal Physiology, Faculty of Biology, Hanoi National University of Education, Hanoi, Vietnam; ⁵Center for Development of Curriculum and Human Resource in Health, Hanoi Medical University, Hanoi, Vietnam

Abstract

Citation: Huy TL, Bui MH, Chu Dinh T, Xuyen HTH. Efficacy and Toxicity of Folfoxiri for Patients with Metastatic Colorectal Cancer. *Open Access Maced J Med Sci*. 2019 Dec 30; 7(24):4244-4249. <https://doi.org/10.3889/oamjms.2019.368>

Keywords: Efficacy; Toxicity; Folfoxiri; Metastatic colorectal cancer

***Correspondence:** My Hanh Bui, Tuberculosis and Lung Disease Department, Hanoi Medical University, Hanoi, Vietnam; Scientific Research & International Cooperation Department, Hanoi Medical University Hospital, Hanoi, Vietnam. E-mail: buimyh@hmu.edu.vn

Received: 26-Jun-2019; **Revised:** 20-Nov-2019; **Accepted:** 21-Nov-2019; **Online first:** 10-Dec-2019

Copyright: © 2019 Trinh Le Huy, My Hanh Bui, Toi Chu Dinh, Hoang Thi Hong Xuyen. This is an open-access article distributed under the terms of the Creative Commons Attribution-NonCommercial 4.0 International License (CC BY-NC 4.0)

Funding: This research did not receive any financial support

Competing Interests: The authors have declared that no competing interests exist

BACKGROUND: In recent times, scientists have found new treatments for colorectal cancer patients.

AIM: The study is to evaluate the efficacy and toxicity of triplet combination chemotherapy of 5-fluorouracil/leucovorin, oxaliplatin, and irinotecan (FOLFOXIRI) for patients with metastatic colorectal cancer in stage IV.

METHODS: Uncontrolled clinical trial carried on 39 stage IV colorectal cancer patients.

RESULTS: The overall response rate of the treatment was 79.4%. The average progression-free survival was 13.4 ± 9 months. The overall survival rate at 12th month and 24th month were 90% and 76%, respectively. The proportion of granulocytopenia was 48.9%, no grade 3 or 4. Side effect beyond hematology was most seen in hepatic toxicity with 52.5%, mainly at grade 1. Vomiting was 18.3%, all at grade 1. Other adverse event was very low at percentage.

CONCLUSIONS: The triplet combination FOLFOXIRI chemotherapy improves the outcome of patients with metastatic colorectal cancer regarding rate of response, overall survival rate and progression-free survival, and the level of toxicity was acceptable.

Introduction

Colorectal cancer is a common type of gastrointestinal cancer. The disease tends to increase in recent times. Treatment of metastatic colorectal cancer is still difficult, with overall survival (OS) and 5-year survival rate reported of 16-25 months and 11%, respectively [1], [2]. At present, 5-fluorouracil, oxaliplatin and irinotecan are still three "backbone" drugs to the treatment for metastatic colorectal cancer.

A meta-analysis presented that the increase of overall survival rate significantly associate with the use of all 5-fluorouracil, oxaliplatin and irinotecan over the total duration of treatment [3]. Currently, in accordance with recommendation by many cancer

organizations around the world, these three drugs are used step by step through two-drug regimen (FOLFOX/XELOX, FOLFIRI/XELIRI). However, not all 100% of patients are treated with all 3 these drugs because some patients abandon the following treatment lines, or their condition does not allow second-line treatment.

Thus, the idea of using all three drugs from the first-line treatment was sprouted more than 10 years ago. In 2002, the first two Phase II studies reported the efficacy and safety of the combination of Oxaliplatin/Irinotecan/5-FULV (FOLFOXIRI) at the first stage [4]. Subsequently, many phase III studies were performed with satisfactory results of this regimen. Since 2010, FOLFOXIRI were recommended in NCCN (National Comprehensive Cancer Network) Clinical Practice Guidelines in Oncology [5].

In Vietnam, the rate of colorectal cancer ranks 4th in men and 6th in women [6]. FOLFOXIRI regimen is gradually being introduced at some oncology facilities due to its efficacy and feasibility. However, since then there was no clinical trial established to evaluate the effectiveness as well as toxicity of FOLFOXIRI in Vietnamese patients with metastatic colorectal cancer.

Therefore, we carried out this work with the aim of performing an initial review in relation to the efficacy and toxicity of FOLFOXIRI in treatment for patients with metastatic colorectal cancer in stage IV.

Materials and Methods

Study design

This study was a single-arm, uncontrolled prospective clinical trial. All eligible patients were selected from October 2013 to September 2014 in the Oncology and Palliative Care Department, Hanoi Medical University Hospital.

Patient selection and study process

Main eligibility criteria were as followed: patients were diagnosed with metastatic unresectable colorectal adenocarcinoma; age from 20 to 75 years; Eastern Cooperative Oncology Group (ECOG) performance status (PS) score of 0 or 1; the patients were treated by at least 3 cycles of FOLFOXIRI in the first-line treatment (Table 1); liver, kidney and hematological functions before treatment were in normal limits; did not suffer from diseases with near-death risk and other chronic diseases. General information was collected by questioning patients and their family member to record age, gender, medical history, reasons of hospitalization, signs and symptoms of disease. Pre-treatment assessment included physical examination, performance status evaluation, complete blood profile, CEA level measurement, colonoscopy, X-ray imaging or CT (computed tomography) scan, abdominal CT scan and/or ultrasound, electrocardiogram and any other applicable method to examine metastatic sites. In the period of treatment, a physical examination was conducted once in two weeks. Metastatic sites were re-examined once within 8 weeks. Abdominal CT scan or MRI was demanded in order to evaluate liver and abdominal metastases.

Table 1: Treatment of FOLFOXIRI chemotherapy at first-line with specific dosage

Dosage	Day of receiving
Irinotecan: 165 mg/m ² , intravenous infusion for 1 hour.	Day 1, 15
Oxaliplatin: 85 mg/m ² , intravenous infusion for 2 hours	Day 1, 15
Calcium folinat 200 mg/m ² , intravenous infusion for 2 hours	Day 1, 15
5FU 3200 mg/m ² , continuous intravenous infusion during 48 hours	Day 1, 2, 3, 15, 16, 17

Note: The regimen was repeated once per 2 weeks.

Evaluation of treatment response was made in accordance with RECIST (Response Evaluation Criteria in Solid Tumors) criteria version 1.1 [7]. Overall response = Complete response + partly response [7]. The adverse event of FOLFOXIRI chemotherapy were observed weekly and categorized in accordance with standard National Cancer Institute Common Terminology Criteria for Adverse Events version 4.0. Patients with disease stability or continuous response after 6 cycles were shifted to maintenance phase with oral Capecitabine (Xeloda). During maintenance treatment, patients were re-examined before Capecitabine administration. Progression Free Survival is estimated in the period of time between the time the study starts and the time of disease progression. Overall survival was calculated at 12-month and 24-month.

Statistics

All collected data were analyzed and measured by SPSS 22.0 software. Progression-free survival (PFS) and overall survival (OS) were estimated by the Kaplan-Meier method from the day of treatment started. Dichotomous variables were analyzed by using Chi-square test and median values compa. The p values < 0.05 were recognized statistically significant.

Ethical

This study is completely voluntary and is aimed at improving the quality of treatment, not for any other purpose. Patients who have met the selection criteria will be explained in detail about the study, patients who agree to participate in the study will be signed on a volunteer to participate in the study. All details about the patient's condition are encrypted and confidential. The patient has the right to withdraw from the study.

Results

A total of 39 unresectable metastatic colorectal cancer patients were recruited to the study. There were 26 males and 13 females, with a median age of 52.9 years (range 25-70). Half of the participants had taken chemotherapy for their disease previously. The most common reason for hospitalization was abdominal pain with 74.4%. Majority of patients were with PS-1 (82.1%), while performance status (PS) score of 0 accounted for percentage of 17.9%. Bowel obstruction was the most common symptom (43.6%), followed by palpable abdominal mass of 20.5% at the time of diagnosis (Table 2).

Moderately differentiated adenocarcinoma was responsible for two third of the study population, followed by participants having type of histopathology as mucinous adenocarcinoma. The peritoneum was more commonly found in patients with mucinous colorectal cancer (20.5%, compared with 5.1% of patients with moderately differentiated adenocarcinoma) (Table 2).

Regarding primary tumor distribution, left-sided colorectal cancer had the highest percentage of 61.5%. Of which, primary tumors were more frequently distributed at sigmoid colon (41%) and liver (17.9%), other locations accounted for proportion of 41.1%. Liver was the most prevalent distant metastatic site (64.1%), whereas patients with peritoneal metastasis and pulmonary metastasis were 25.6% and 17.9%, respectively. Retroperitoneal lymph node occurred in 30.8% of metastatic colorectal patients. 26 patients (66.7%) had CEA levels of 20ng/ml or below before treatment (Table 2).

Table 2: Clinic-pathology features of metastatic colorectal cancer patients whose disease was not radically resectable

Characteristics	Percentage
Gender	Male 26 (66.7%) Female 13 (33.3%)
Age	Under 40 8 (20.5%) 45-60 26 (66.7%) Over 65 5 (13.8%)
Signs	Abdominal pain 29 (74.4%) Hematochezia 10 (25.6%) Diarrhea 9 (23.1%)
Performance status	PS1 32 (82.1%) PS0 7 (17.9%)
Symptoms	Bowel obstruction 17 (43.6%) Fluid in the abdomen 1 (2.6%) Palpable abdominal mass 8 (20.5%) No symptom 13 (33.3%)
Tumor location	Sigmoid colon 16 (41%) Hepatic flexure 7 (18%) Other location 16 (41%)
Distant metastatic site	Liver metastasis 25 (64.1%) Pulmonary metastasis 7 (17.9%) Peritoneal metastasis 10 (25.6%) Retroperitoneal lymph node 12 (30.8%)
No. of involved organs	> 1 32 (82.1%) = 1 7 (17.9%)
CEA concentration	CEA > 20 ng/ml 13 (33.3%) CEA ≤ 20 ng/ml 26 (66.7%)
Histopathology	Moderately differentiated adenocarcinoma 26 (66.7%) Mucinous adenocarcinoma 13 (33.3%)

Efficacy

All participating patients had measurable disease and were evaluated for response (Table 3).

Table 3: Response rate of the treatment

Response	Percentage (%)
Completely	2 (5.9%)
Partially	25 (73.5%)
Disease stability	4 (11.8%)
Disease progression	3 (8.8%)

After 3 cycles, we recorded 5.1% of patients who responded fully after 3 cycles and the majority of patients had partial response (76.9%); 5.1% of patients with progressed disease. After 6 cycles, five patients discontinued the chemotherapy prematurely because of disease progression after 3 cycles and geographical distance. According to Table 3, 25

patients (73.5%) achieved partial remission and 2 cases (5.9%) obtained a complete response, therefore, the rate of overall response and disease control were 79.4% and 91.2%, respectively. The median dosage intensity of irinotecan, oxaliplatin and 5-FU used in the treatment for 39 colorectal cancer patients were 83.7%, 83.08% and 84.33%, respectively.

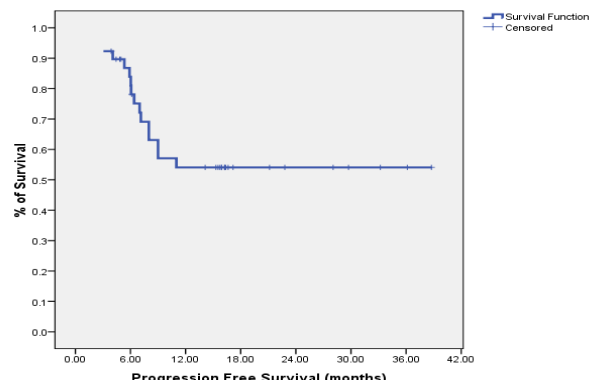


Figure 1: Progression-free survival

After 36 months of follow-up, the progression-free survival in our study was calculated as 13.4 ± 9 months (Figure 1). The overall survival rate at 12th month was 90% and 24th month was 76% (Figure 2).

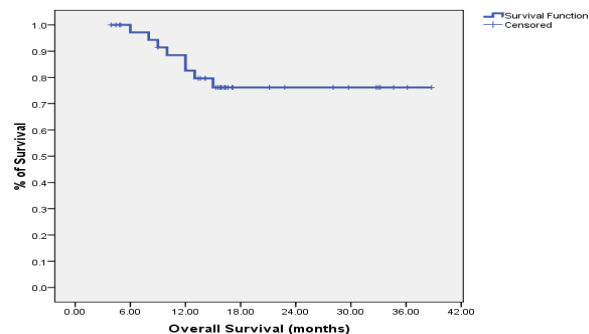


Figure 2: Overall survival rate

All patients in the study were assessable for the safety of treatment. The most prevalent adverse events included neutropenia, thrombocytopenia, anemia, vomiting, diarrhea, stomatitis, hepatic toxicity, peripheral neurotoxicity. Nevertheless, most toxicity complications were at grade 1 or 2, and grade 3 or 4 was commonly seen in neutropenia. Of which, granulocytopenia of grade 1/2 occurred in 25.5% of patients, while grade 3 and 4 occupied a lower rate of 14.1% and 9.3%, respectively. Thrombocytopenia and anemia accounted for very low percentage of 3.2% and 8.3%, mainly at grade 1. Liver toxicity was the most prevalent non-hematological adverse event and accounted for the highest proportion of 52.5%, followed by vomiting and diarrhea with the figure of 18.3% and 6.9%, respectively. All of them were scored at grade 1/2 (Table 4).

Table 4: Adverse Event of FOLFOXIRI regimen

Adverse Event	Grade 0 (%)	Grade 1-2 (%)	Grade 3-4 (%)
Granulopenia	51.1	25.5	23.4
Thrombocytopenia	96.8	3.2	0
Anemia	91.7	8.3	0
Vomiting	74.23	23	2.67
Diarrhea	93.1	6.9	0
Oral toxicity	96.57	3.63	0
Liver toxicity	47.5	52.5	0

Discussion

In recent times, the development of chemotherapy in treatment for patients with colorectal cancer has led to considerable benefit regarding antitumor activity and efficacy [5]. Documents showed that the best outcomes are obtained from patients who received all three main active substances (5-FU, irinotecan and oxaliplatin), but that in a sequential strategy only 60% to 80% of patients are able to continue the second-line treatments and thus, to be able to expose to all these three agents. These considerations assist the procedure to improve potentially more active first-line regimens which put 5-FU with both irinotecan and oxaliplatin. Thus, we conducted the study to evaluate effectiveness combo of irinotecan, oxaliplatin and 5-FU/LV (FOLFOXIRI), orderly.

In our research, the overall response rate was 79.4%. Of which, there were 5.1% of patients with full response, 73.5% with partial response, 11.8% with stable disease and 5.9% with progressive disease. Consequently, the rate of disease control was calculated as 91.2%. The overall response rate is among the highest findings which were presented in previous study on any chemotherapy regimens for treatment of metastatic colorectal cancer [4], [8], [9], [10]. The median dose intensities were 83.7% with Irinotecan, 83.08% with Oxaliplatin and 84.33% with 5-FU. This is the lowest dose intensity of chemotherapy compared with those four reference studies, except for Souglakos et al.'s study [8]. Regarding to patients' characteristics, based on three main factors: median age, prevalence of patients treated with chemotherapy before, severity of disease, our patients group presented a younger median age (54 years), the second lowest number of patients with metastases > 1 (16.7%, just behind the figure of Azmy et al.'s study with 9%), and approximately 50% of patients had been taken with chemotherapy previously (middle-ranking among 4 cited studies). Thus, the characteristics of our studied population were relatively more favorable than those of other groups in mentioned studies.

During a follow-up period of 36 months, our study showed that the median progression-free survival was recorded as 13.37 ± 9 months. This result was comparable to foreign studies using the

same regimen. Particularly, Falcone et al.'s study, (2002) revealed a median progression-free survival of 10.4 months while Souglakos et al.'s study reported the progression-free survival of 13 months on average [4], [8]. Furthermore, in comparison with other regimens, FOLFOXIRI increased PFS by about 3 months, and decreased the risk of early disease progression by half. The 12th month and 24th month overall survival rate was 90% and 76%, respectively.

A notable disadvantage of FOLFOXIRI is to have many side-effects, but in an acceptable level. Neutropenia was the most common hematological toxic effect with proportion of 48.9%. In particular, the incidence of grade 1/2 granulocytopenia was 25.5% while grade 3/4 was found in 23.4% of patients. There was no case of fever caused by neutropenia. Interestingly, neutropenia was one of the adverse event with the highest rate in studies conducted by Falcone et al., (2002)'s which suggested that 14% of patients had at least one episode of neutropenia fever [4], and Souglakos et al., (2002) which found that grade 3 and grade 4 neutropenia happened in 14 patients (45%), two patients had neutropenia fever (6%) [8]. Compared with mentioned authors, our result of neutropenia was somewhat lower. In our study, patients were screened for blood count routinely on day 8 after chemotherapy. Cases with grade 2 or above were injected with leukocyte stimulants and closely observed, daily white blood cell counts were measured to administer leukocyte-stimulating drugs if necessary, until blood count reached over 2000 white blood cells/ml. In addition, dosage adjustment for each patient was based on level of granulocytopenia in the period of treatment. Cases with grade 3 granulocytopenia were isolated in sterile rooms and broad-spectrum antibiotic prophylaxis was used until white blood cells increased to above 2000/ml.

Regarding anemia, the rates of anemia and thrombocytopenia in our study were 8.3% and 3.2%, respectively. Most of side effects of anemia (6.5%) and thrombocytopenia were at grade 1. The rate of grade 2 anemia was very low with 2.3% and these side effects at grade 3 and 4 did not appear in the study. Also, the percentages of anemia and thrombocytopenia of foreign studies were very low (< 10%) [11], [12]. The three drugs Oxaliplatin, 5-FU and Irinotecan have unclear effect on thrombocytopenia occurrence. Regarding anemia, only oxaliplatin can cause a small erythropoietic anemia because a small fraction (~ 7%) of oxaliplatin penetrate into red blood cells and break down the red blood cells after 48 days. Nevertheless, because only a small proportion of oxaliplatin can get into red blood cells, the levels of anemia of regimens containing oxaliplatin in general and of FOLFOXIRI in particular are not high.

Vomiting during chemotherapy occurred in 42 cases. However, no incidence of vomiting at grade 4, grade 3 occurred in 2.67% of the patients. The remaining was mainly infusions causing vomiting at grade 1 (74.23%) and grade 2 (23%). The toxicity rate

was lower than Falcone et al.'s study, in which the incidence of vomiting was 60% for grade 1, 53% for grade 2 and 13% for grade 3 [4]. The causes of this type of vomiting are usually related to psychological factors which stimulate pneumogastric nerve to cause vomiting. To solve this problem, we usually use supplements of pills (Diazepam) for patients with a history of severe vomiting in the previous infusion. In addition to using the 5-HT₃ class of anti-vomiting medication, we also combined two other classes in a routine way: Corticosteroids (dexamethasone) have anti-vomiting mechanism on the central nervous system; Primperan has anti-vomiting mechanism by D₄ receptor blockade. Several severe vomiting cases (grade 3) were also given Haloperidol, a chemotherapy-induced P-receptor blocker in the CTZ (chemo-trigger zone).

The incidence of diarrhea in our study group was 6.9%. Most patients developed diarrhea at later time (after 24 hours of chemical infusion). There was no case of diarrhea in grade 3 or 4. By contrast, Souglakos et al., treated on 31 stage IV colorectal cancer patients with the similar regimen and found that grade 3 and 4 diarrhea was presented in 10 cases (32%) [8]. Besides, the rate of grade 3, 4 diarrhea in Falcone et al.'s research (2007) was 20%, with no significant difference from FOLFIRI group [10]. Irinotecan, in addition to be Topoisomerase II enzyme inhibitor, inhibit Acetylcholinesterase, an enzyme that decomposes neurotransmitter of Acetylcholin receptor. Therefore, using Irinotecan will stimulate parasympathetic nervous system which intensifies bowel movement and results in diarrhea. All of our patients are taking Atropin to prevent this side effect. Depending on the severity of patient's diarrhea, Atropin is added during infusion.

Three-point six three percent of patients with oral toxicity had been detected in this study and all were at grade 1. FOLFOXIRI regimen not using bolus 5-FU as a feature causes low rate of stomatitis. Studies of Peeters M et al., (2010) [13] and Douillard JY et al., (2000) [14] also had a low incidence of this toxicity (below 5%) [13], [14]. Cases with oral toxicity was detected and treated early, which limited significantly the severity of this unwanted effects.

The most prevail non-hematological adverse event was liver toxicity, accounting for 52.5% of patients treated by FOLFOXIRI, by most of them were at grade 1 (50%), followed by grade 2 with only 2.5%. Similarly, liver toxicity in majority of foreign studies amounted to the highest percentage at grade 1 while the figure of grade 2 toxicity was very small [15], [16]. Of three drugs used in this study, Oxaliplatin is metabolized and excreted mainly in kidney so there is no effect on the liver. 5-FU and irinotecan are metabolised and excreted primarily in the liver, which can cause hepatitis due to the drug. However, the severity of hepatitis is usually mild and self-healing after chemotherapy discontinuation. In the period of treatment, we focussed on the use of infusion after

chemotherapy to improve liver function, which helps reduce liver enzymes.

In conclusion, the FOLFOXIRI chemotherapy is a highly effective regimen demonstrated by an increase in response rate, progression-free survival and has side-effects at manageable and well tolerated levels during first-line treatment of metastatic colorectal cancer. The regimen needs to be conducted more in study with a larger sample size and a broader scope to prove its effectiveness and safety before being widely applied in hospitals across the country.

Ethical Approval

Ethical approval to report this case series was obtained from Hanoi Medical University Review Board (Approval Number: IRB00003117).

Informed Consent

Written or verbal informed consent was achieved from the patient(s) for their anonymized information to be published in this article.

Acknowledgment

We would like to thank Ms. Bui Nhat Le (Faculty of Clinical Pharmacy, University of Pharmacy, Hanoi, Vietnam) for checking and improving the English in the manuscript.

References

1. Ferlay J, Soerjomataram I, Dikshit R, et al. Cancer incidence and mortality worldwide: sources, methods and major patterns in GLOBOCAN 2012. *Int J Cancer*. 2015; 136(5):E359-86. <https://doi.org/10.1002/ijc.29210> PMID:25220842
2. Jemal A, Bray F, Center MM, et al. Global cancer statistics. *CA Cancer J Clin*. 2011; 61(2):69-90. <https://doi.org/10.3322/caac.20107> PMID:21296855
3. Grothey A, Sargent D, Goldberg RM, et al. Survival of patients with advanced colorectal cancer improves with the availability of fluorouracil-leucovorin, irinotecan, and oxaliplatin in the course of treatment. *J Clin Oncol*. 2004; 22(7):1209-14. <https://doi.org/10.1200/JCO.2004.11.037> PMID:15051767
4. Falcone A, Masi G, Allegrini G, et al. Biweekly chemotherapy

- with oxaliplatin, irinotecan, infusional Fluorouracil, and leucovorin: a pilot study in patients with metastatic colorectal cancer. *J Clin Oncol.* 2002; 20(19):4006-14. <https://doi.org/10.1200/JCO.2002.12.075> PMID:12351598
5. Edwards MS, Chadda SD, Zhao Z, et al. 2012; A systematic review of treatment guidelines for metastatic colorectal cancer. *Colorectal Dis.* 2002; 14(2):e31-e47. <https://doi.org/10.1111/j.1463-1318.2011.02765.x> PMID:21848897 PMCID:PMC3562494
6. Duc NB, Dieu B. The situation of cancer in Vietnam in 2010 through data of 6 regions recorded in the period 2004-2008. *Vietnam Journal of Oncology.* 2010; 1:73-80.
7. Schwartz LH, Litière S, de Vries E, Ford R, Gwyther S, Mandrekar S, Shankar L, Bogaerts J, Chen A, Dancey J, Hayes W. RECIST 1.1-Update and clarification: From the RECIST committee. *Eur J Cancer.* 2016; 62:132-7. <https://doi.org/10.1016/j.ejca.2016.03.081> PMID:27189322 PMCID:PMC5737828
8. Souglakos J, Mavroudis D, Kakolyris S, et al. Triplet combination with irinotecan plus oxaliplatin plus continuous-infusion fluorouracil and leucovorin as first-line treatment in metastatic colorectal cancer: a multicenter phase II trial. *J Clin Oncol.* 2002; 20(11):2651-7. <https://doi.org/10.1200/JCO.2002.08.015> PMID:12039926
9. Azmy AM, Nasr KE, Gobran NS, et al. Infusional Fluorouracil, Leucovorin, Oxaliplatin, and Irinotecan (FOLFOXIRI) Compared with Infusional Fluorouracil, Levcovorin, and Irinotecan (FOLFIRI) as First-Line Treatment for Metastatic Colorectal Cancer. *Journal of Cell Science & Therapy.* 2012; 3:125. <https://doi.org/10.4172/2157-7013.1000125>
10. Falcone A, Ricci S, Brunetti I, et al. FOLFOXIRI plus bevacizumab versus FOLFIRI plus bevacizumab as first-line treatment of patients with metastatic colorectal cancer: updated overall survival and molecular subgroup analyses of the open-label, phase 3 TRIBE study. *J Clin Oncol.* 2007; 25(13):1670-6. <https://doi.org/10.1200/JCO.2006.09.0928> PMID:17470860
11. Cremolini C, Loupakis F, Masi G, et al. FOLFOXIRI or FOLFOXIRI plus bevacizumab as first-line treatment of metastatic colorectal cancer: a propensity score-adjusted analysis from two randomized clinical trials. *Ann Oncol.* 2016; 27(5):843-9. <https://doi.org/10.1093/annonc/mdw052> PMID:26861604
12. Loupakis F, Cremolini C, Salvatore L, et al. FOLFOXIRI plus bevacizumab as first-line treatment in BRAF mutant metastatic colorectal cancer. *Eur J Cancer.* 2014; 50(1):57-63. <https://doi.org/10.1016/j.ejca.2013.08.024> PMID:24138831
13. Peeters M, Price TJ, Cervantes A, et al. Randomized phase III study of panitumumab with fluorouracil, leucovorin, and irinotecan (FOLFIRI) compared with FOLFIRI alone as second-line treatment in patients with metastatic colorectal cancer. *J Clin Oncol.* 2010; 28:4706-4713. <https://doi.org/10.1200/JCO.2009.27.6055> PMID:20921462
14. Douillard JY, Cunningham D, Roth AD, et al. Irinotecan combined with fluorouracil compared with fluorouracil alone as first-line treatment for metastatic colorectal cancer: a multicentre randomised trial. *Lancet.* 2000; 355:1041-1047. [https://doi.org/10.1016/S0140-6736\(00\)02034-1](https://doi.org/10.1016/S0140-6736(00)02034-1)
15. Cremolini C, Loupakis F, Antoniotti C, et al. FOLFOXIRI plus bevacizumab versus FOLFIRI plus bevacizumab as first-line treatment of patients with metastatic colorectal cancer: updated overall survival and molecular subgroup analyses of the open-label, phase 3 TRIBE study. *Lancet Oncol.* 2015; 16(13):1306-15. [https://doi.org/10.1016/S1470-2045\(15\)00122-9](https://doi.org/10.1016/S1470-2045(15)00122-9)
16. Hurwitz H, Fehrenbacher L, Novotny W, et al. Bevacizumab plus irinotecan, fluorouracil, and leucovorin for metastatic colorectal cancer. *N Engl J Med.* 2004; 350(23):2335-42. <https://doi.org/10.1056/NEJMoa032691> PMID:15175435