



ID Design Press, Skopje, Republic of Macedonia  
 Open Access Macedonian Journal of Medical Sciences. 2019 Dec 30; 7(24):4239-4243.  
<https://doi.org/10.3889/oamjms.2019.367>  
 eISSN: 1857-9655  
*Basic and Clinical Medical Researches in Vietnam*

# Quality of Life and Suitability with Vietnamese Harmonious Face Index in Class III Malocclusion Patients

Nguyen Hoang Minh<sup>1</sup>, Truong Manh Dung<sup>1</sup>, Vo Truong Nhu Ngoc<sup>1</sup>, Pham Hoang Tuan<sup>2</sup>, Nguyen Hong Ha<sup>3</sup>, Le Van Son<sup>1</sup>, Nguyen Thi Thu Phuong<sup>1</sup>, Hoang Thi Doi<sup>4</sup>, Vo Van Thanh<sup>5</sup>, Thien Chu Dinh<sup>6</sup>, Nguyen Thi Phuong<sup>7</sup>, Toi Chu Dinh<sup>1,8\*</sup>

<sup>1</sup>School of Odonto Stomatology, Hanoi Medical University, Hanoi, Vietnam; <sup>2</sup>Hanoi National Hospital of Odontostomatology, Hanoi, Vietnam; <sup>3</sup>Viet Duc Hospital, Hanoi, Vietnam; <sup>4</sup>Hanoi Medical College, Hanoi, Vietnam; <sup>5</sup>Hanoi Medical University, Hanoi, Vietnam; <sup>6</sup>Institute for Research and Development, Duy Tan University, Danang, Vietnam; <sup>7</sup>NTT Hi-tech Institute, Nguyen Tat Thanh University, Ho Chi Minh City, Vietnam; <sup>8</sup>Department of Human and Animal Physiology, Faculty of Biology, Hanoi National University of Education, Hanoi, Vietnam

## Abstract

**Citation:** Minh NH, Dung TM, Ngoc VTN, Tuan PH, Ha NH, Son LV, Phuong NTT, Doi HT, Thanh VV, Dinh TC, Phuong NT, Chu Dinh T. Quality of Life and Suitability with Vietnamese Harmonious Face Index in Class III Malocclusion Patients. Open Access Maced J Med Sci. 2019 Dec 30; 7(24):4239-4243. <https://doi.org/10.3889/oamjms.2019.367>

**Keywords:** Oral health care; Class III malocclusion; Orthognathic surgery; Harmonious faces

**\*Correspondence:** Toi Chu Dinh, School of Odonto Stomatology, Hanoi Medical University, Hanoi, Vietnam; Department of Human and Animal Physiology, Faculty of Biology, Hanoi National University of Education, Hanoi, Vietnam. E-mail: [chudinhtoi@hnue.edu.vn](mailto:chudinhtoi@hnue.edu.vn)

**Received:** 19-Jun-2019; **Revised:** 20-Sep-2019; **Accepted:** 21-Sep-2019; **Online first:** 15-Oct-2019

**Copyright:** © 2019 Nguyen Hoang Minh, Truong Manh Dung, Vo Truong Nhu Ngoc, Pham Hoang Tuan, Nguyen Hong Ha, Le Van Son, Nguyen Thi Thu Phuong, Hoang Thi Doi, Vo Van Thanh, Thien Chu Dinh, Nguyen Thi Phuong, Toi Chu Dinh. This is an open-access article distributed under the terms of the Creative Commons Attribution-NonCommercial 4.0 International License (CC BY-NC 4.0)

**Funding:** This research did not receive any financial support

**Competing Interests:** The authors have declared that no competing interests exist

**BACKGROUND:** Maxillary Lefort I osteotomy, mandibular bilateral sagittal split ramus was frequently used in correcting skeletal class III malocclusion. There was a lack of research on class III malocclusion patients' quality of life (QoL) after bimaxillary osteotomy.

**AIM:** Class I Intermaxillary relationship was achieved, aesthetic was significantly improved. Significant improvement in Class III skeletal patients' quality of life was acquired. The achievement of harmonious face would be beneficial to the facial aesthetics of patients, thus improving the quality of life.

**METHODS:** Harmonious face index is an effective criterion in assessing the surgery's outcome. In this study was conducted on 30 patients at Hanoi National Hospital of Odontostomatology, Viet Duc Hospital, and Hong Ngoc Hospital from April 2017 to April 2018, and it was a quasi-experimental study with self-comparison, 12 months follow up.

**RESULTS:** Orthognathic surgery effectively corrected malocclusion crossbite, dental compensation, and helped to improve facial aesthetics. 100% of patients had the quality of life improved, good quality of life consisted of 86.7%. In comparison with a harmonious facial index of Kinh ethnic in Vietnam, 70% of patients achieved skeletal harmony, 63.3% of patients achieved dental harmony, 80% achieved soft tissue harmony.

**CONCLUSIONS:** Vietnamese harmonious facial index should be used in planning and pre-surgical simulation.

## Introduction

Malocclusion is the incorrect dental phenomena between the teeth of two arches. In America and Asian countries, this incidence of malocclusion can reach 70% of the population [1]. Class III malocclusion comprises high percentages in the population, up to 35% [2]. Class III malocclusion is the aetiology of occlusal trauma, functional decrease, and an increased risk of dental diseases, facial aesthetic and psychological problems [3]. Treatment for skeletal class III malocclusion is quite necessary to improve quality of life [4]. Most adult patients with skeletal class III

malocclusion, need a combination of orthodontic and surgical treatment to achieve good outcomes in function and aesthetic. Maxillary Lefort I osteotomy and bilateral sagittal split osteotomy ramus (BSSO) are commonly applied worldwide, providing good outcome in aesthetic and function in three dimensions, as well as post-operative stability[5],[6]. Therefore, patients' physical, psychological aspects, as well as the quality of life, can make significant progress. In recent years, patients' quality of life (QoL) has been a matter of concern which has been considered to be a criterion in assessing the patients' recovery after surgery. Orthognathic Quality of Life Questionnaire (OQLQ) was created to measure patients' quality of life. OQLQ was

considered to be an effective instrument for the assessment of patients' quality of life after orthognathic surgery [7], [8]. The Vietnamese harmonious facial index is an aesthetic criterion of surgery. Thus, we conducted this study to evaluate the quality of life and the suitability with the harmonious Vietnamese facial in skeletal class III malocclusion patients after orthognathic surgery.

## Subjects and Methods

Subjects: 30 skeletal class III malocclusion patients were treated with preoperative orthodontic and had orthognathic surgery in Hanoi (Hanoi National Hospital of Odontostomatology, Viet Duc University Hospital and Hong Ngoc Hospital) from April 2017 to April 2018. Patients with severe congenital facial defects were excluded.

Study method: Quasi-experimental study with self-comparison before operation (T0) and after operation 12 months (T12). All patients were operated with maxillary Lefort I osteotomy and bilateral sagittal split ramus osteotomy. The cephalometric X-ray was used to assess the patients' skeletal, dental, soft tissue before the operation and after operation 12 months. Orthognathic Quality of Life Questionnaire (OQLQ) was used to evaluate patients' quality of life before the operation and after operation 12 months (appendix A). The questionnaire contains 22 questions which were divided into four parts, including facial aesthetics, oral function, awareness of dentofacial aesthetics and social aspects of dentofacial deformity. Each question is scored on a 4-point scale, which 1 refers to "bothers you a little", 4 = "bothers you a lot", 2 and 3 = "between these statements", 0 score refers to "does not apply or does not bother". The high score presents a negative influence on the patient's QoL. The low score indicates a positive influence on the QoL. Average score: ≤ 2: good quality of life; 2-3: moderate quality of life; ≥ 3: poor quality of life.

Evaluating the effectiveness of surgery is evaluation the changes in the facial index before and after surgery by comparing skeletal, dental and soft tissue index in pre-operation (T0) and 12 months post-operation (T12).

Assess the suitability with Vietnamese harmonious facial index is assess the suitability between the post-operation facial index and Vietnamese harmonious facial index by comparing patients' cephalometric indexes after 12 months post-operation with Vietnamese Kinh Ethnic, harmonious facial index in National Research in School of Odonto& Stomatology – Hanoi Medical University.

### Statistics

Data analysis: Continuous variables were skeletal, dental and soft tissue index (SNA, SNB, ANB angle, A-V, B-V, Pg-V, Wits, overjet, overbite, U1-SN, Is-V, L1-MP, li-V, Li-E, Ls-E, Cm-Sn – Ls angle, Li-B'-Pg' angle, Ns - Sn-Pg'

angle) measured in Cephalometric X – rays and OQLQ score were analysed with SPSS 16.0 software. Pair T-tests was used to compare the normal distribution variables before and after the operation. Wilcoxon signed-rank test was used to compare OQLQ score and the non-normal distribution variables.

## Results

### Patch test results

There were 30 patients including 14 male patients (46.7%); 16 female patients (53.3%) in the study. All the patients were Kinh ethnic. The subjects' age was in a range of 18 to 25 years old.

**Table 1: Skeletal, dental and soft tissue index in 12month postoperation (T12) in comparison with preoperation (T0)**

Index	T0 (N = 30)		T12 (N = 30)		P (T0vs T12)
	$\bar{x}$	SD	$\bar{x}$	SD	
SNA (degree)	80.87	3.81	82.72	3.34	< 0.001*
A-V (mm)	60.37	5.44	63.67	4.85	< 0.001*
SNB (degree)	84.98	4.22	81.67	3.78	< 0.001*
B-V (mm)	65.66	7.73	63.45	6.51	< 0.001*
Pg-V (mm)	66.59	9.36	63.89	8.62	< 0.001*
ANB (degree)	-4.11	2.65	1.05	1.01	< 0.001**
Overjet (mm)	-4.08	2.15	2.10	0.31	< 0.001**
Overbite (mm)	1.47	0.67	1.61	0.51	> 0.05**
U1-SN (degree)	110.53	9.15	107.34	8.61	< 0.001*
Is-V (mm)	67.17	7.24	69.90	6.67	< 0.001*
L1-MP (degree)	86.87	8.71	94.78	3.70	< 0.001*
li-V (mm)	71.44	8.01	67.24	6.14	< 0.001*
Li-E (mm)	3.68	1.12	1.45	2.20	< 0.001**
Ls-E (mm)	-3.04	1.65	-0.17	1.75	< 0.001**
Cm-Sn-Ls (degree)	81.92	4.49	94.26	4.04	< 0.001*
Li-B'-Pg' (degree)	146.29	8.94	133.75	7.81	< 0.001*
Ns-Sn-Pg' (degree)	185.54	3.41	167.41	3.56	< 0.001*

Note: \*P values were determined by Pair T-test; \*\*P values were determined by Wilcoxon signed-rank test.

According to Table 1, there was a forward movement of the maxilla (SNA, A-V increased), the backward movement of the mandible, prognathic chin reduced (SNB, B-V, Pg-V reduced). Class I intermaxillary relationship was achieved, crossbite was corrected. Upper incisors (Is-V increased) moved forward, lower incisors (li-V decreased) moved backwards. The angle between the lower incisors and mandibular plane (L1-MP) increased, the angle between the upper incisors and cranial plane (U1-SN) decreased. Forward movement of the upper lip (Ls-E increased), the backward movement of the lower lip (Li-E decreased) were seen, facial angle decreased (Ns-Sn-Pg'). Nasolabial angle was larger (Cm-Sn-Ls increased), and the labiomental angle was smaller (Li – B' – Pg' decreased) in comparison with the pre-surgery index. Above changings were statistically significant (p < 0.05). Overbite changing is not statistically significant (p > 0.05).

**Table 2: The improvement of quality of life**

OQLQ	Facial Aesthetics		Oral Function		Awareness of Dentofacial Aesthetics		Social Aspects of Dentofacial Deformities		SUM	
	Pre-op	Post-op	Pre-op	Post-op	Pre-op	Post-op	Pre-op	Post-op	Pre-op	Post-op
N	30	30	30	30	30	30	30	30	30	30
MEDIAN	16.5	5	17	6	14	5	26	8	72	23
MIN	12	0	12	0	10	0	17	0	52	0
MAX	20	14	20	14	16	11	31	23	87	61
P	< 0,001		< 0,001		< 0,001		< 0,001		< 0,001	

Note: P values were determined by Wilcoxon signed-rank test.

As can be seen from Table 2, before surgery, the minimum score for OQLQ in sum was 52, and the maximum score was 87, the median score was 23. One year after surgery, all the minimum, maximum and median score decreased significantly to 0, 61 and 23, respectively ( $p < 0.001$ , Wilcoxon Signed Rank Test). The same trends were seen in the score for OQLQ in Facial Aesthetics, Oral Function, Awareness of Dentofacial Aesthetics, Social Aspects of Dentofacial Deformities.

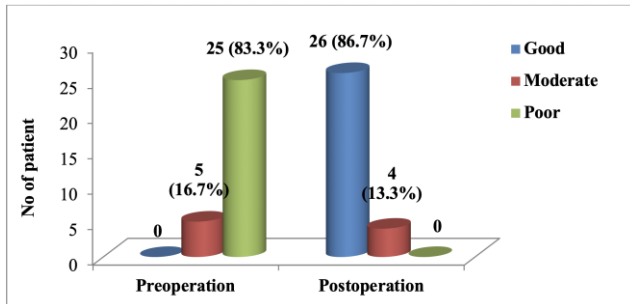


Figure 1: Quality of life-changing after surgery

From the above chart, before surgery, there was no good quality of life case, the poor quality of life consisted of 83.3%. In contrast, after surgery, 26 cases were having a good quality of life (86.7%), 4 cases having the moderate quality of life (13.3%) and there was no case having poor quality of life (Fig. 1).

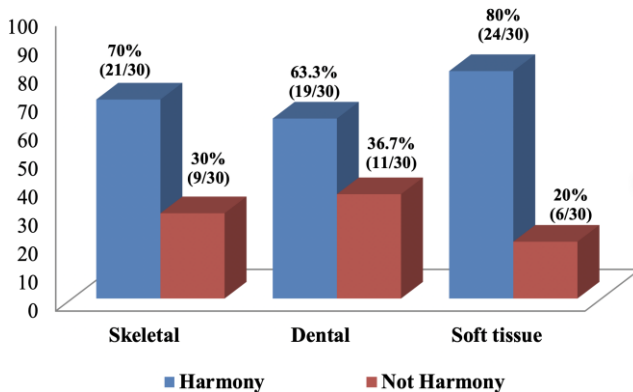


Figure 2: Suitable rate with Vietnamese harmonious facial index

Among 30 patients got 12 months postoperative following up, 21 cases were having harmonious skeletal index (70%), 19 cases having harmonious dental index (63.3%) and 24 cases having harmonious soft tissue index (80%) (Figure 2).

## Discussion

Twelve months postoperative, our study observed forward movement of the maxilla, the backward movement of the mandible and the intermaxillary relationship was changed from class III (pre-operation) to class I. Overjet

was increased to the positive average value, crossbite was corrected. The angle between lower incisors and the mandibular plane was increased, the angle between maxillary incisors and the basal plane was decreased, dental decompensation was achieved (palatal inclination of upper incisors and labial inclination of lower incisors), dental esthetic was improved. Soft tissue was also changed: forward movement of the upper lip, the backward movement of the lower lip, decreasing facial angle, increasing nasolabial angle as well as decreasing labiomental angle in comparison with pre-operation. These changes significantly improved facial aesthetics, the relationship between upper lip and nose, lower lip and chin. Our result was appropriate with studies conducted by Ghassemi [6], Aydemir [9].

There were a variety of articles that have mentioned the merits of orthognathic surgery in skeletal class III malocclusion patients. In recent year, other studies have directly cared about the patients' quality of life which is a wide concept related to physical health, aesthetic aspect, psychological state, social relationships.

In our study, OQLQ was chosen because OQLQ is a questionnaire designed for orthognathic. We evaluate patients' quality of life at the one-year postoperative period because we tended to asses the long-term complications, including skeletal relapse and neurosensory disturbances. Thus, it was possible to evaluate the influence of long-term complications on QoL.

In our study, the results described a highly significant degree of overall improvement in patients' quality of life after orthognathic surgery. The subjects' quality of life achieved a statistically significant improvement in all four OQLQ domains. In agreement with our outcome, other authors, including Wee, 2014 [10], Abdullad, 2015 [11], also found the improvement of patients' quality of life after orthognathic. Applying OQLQ for 41 patients, Wee found that patients' quality of life was significantly improved after two years bimaxillary osteotomies [10]. Similarly, Abdullad also used OQLQ to assess the quality of life for 17 patients, and the outcomes showed that the highly significant improvement in patients' quality of life was evident [11].

All subjects in our study underwent the combination of Lefort I maxillary advancement and BSSO mandibular setback operation with rigid fixation. The complications and surgical outcomes remarkably affected the quality of life. Long-term complications were the main factor that contributed to the changes in patients' quality of life. In BSSO, the inferior alveolar nerve was damaged, thus causing numbness of the lower lip and chin. In the study of Alolayan, in 238 patients, the percentage of nerve injury was 36.6% after mandibular procedures [12]. In our study, we found that the neurosensory disturbances reduced after one-year follow, that refer to the recovery of the nerve. After a one-year post-operation, only 5 patients were complaining about a little numbness of chin. The other long-term common complication is skeletal and dental relapse.

In our study, the percentage of patients who achieved the harmonious Vietnamese face after 12 months post-operation was high. Dental decompensation, less acute

nasolabial angle, less obtuse labiomental angle, decreasing facial angle helps improving facial esthetic significantly. Patients' facial aesthetic made remarkable progress, thus improving the patients' confidence as well as the quality of life. Therefore, Vietnamese harmonious facial index should be applied in planning and preoperative simulation to increase the surgery's outcome and the patient's quality of life.

In conclusion, maxillary Lefort I osteotomy and mandibular bilateral sagittal split ramus osteotomy were effective in correcting skeletal class III malocclusion. After surgery, class I intermaxillary relationship was acquired, esthetic was significantly improved. The study showed a highly significant improvement in Class III skeletal patients' quality of life after 12 months bimaxillary osteotomies. All four OQLQ domains improved remarkably after 12 months of surgery. The achievement of harmonious face would be beneficial to the facial aesthetics of patients, thus improving the quality of life. Vietnamese harmonious facial index should be used in planning and preoperative simulation to increase the surgery's outcome and the patient's quality of life.

## Acknowledgement

We would like to express our sincere gratitude to volunteers for their participation in our study, as well as Hanoi National Hospital of Odontostomatology, Viet Duc Hospital, Hong Ngoc Hospital, School of Odonto & Stomatology – Hanoi Medical University

## Ethical Approval

All procedures performed in studies involving human participants were in accordance with the ethical standards of the institutional and/or national research committee and with the 1964 Helsinki declaration and its later amendments or comparable ethical standards. This study belongs to National research of School of Odonto & Stomatology – Hanoi Medical University, which had been approved this study according to Decision No. 202/HĐĐĐHYN, signed on October 20<sup>th</sup> 2016.

## Acknowledgements

We want to thank Ms Nguyen Thi Yen Vy (Faculty of Biology, University of Hanoi National University of Education, Hanoi, Vietnam) checking and improving the English in the manuscript.

## Informed Consent

Informed consent was obtained from the patients included in the study.

## References

1. Carvalho F.S.d., et al., Epidemiology of malocclusion in children and adolescents: a critic review. *RGO - Revista Gaúcha de Odontologia*. 2014; 62:253-260. <https://doi.org/10.1590/1981-8637201400030000041190>
2. Hardy DK, Cubas YP, Orellana MF. Prevalence of angle class III malocclusion: A systematic review and meta-analysis. *Open Journal of Epidemiology*. 2012; 2(04):75. <https://doi.org/10.4236/ojepi.2012.24012>
3. Nicodemo D, Pereira MD, Ferreira LM. Self-esteem and depression in patients presenting angle class III malocclusion submitted for orthognathic surgery. *Med Oral Patol Oral Cir Bucal*. 2008; 13(1):48-51.
4. Huang S, et al. The changes of oral health-related quality of life and satisfaction after surgery-first orthognathic approach: a longitudinal prospective study. *Head & Face Medicine*. 2016; 12:2. <https://doi.org/10.1186/s13005-015-0098-1> PMID:26729274 PMCID:PMC4700618
5. Aydemir H, Toygar-Memikoglu U. Facial Soft Tissue Changes in Class III Patients Treated With Bimaxillary, Maxillary Advancement or Mandibular Set Back Orthognathic Surgery. *OHDH*. 2015; 14:75-80.
6. Ghassemi M, et al. Evaluation of soft and hard tissue changes after bimaxillary surgery in class III orthognathic surgery and aesthetic consideration. *National Journal of Maxillofacial Surgery*. 2014; 5(2):157-160. <https://doi.org/10.4103/0975-5950.154819> PMID:25937726 PMCID:PMC4405957
7. Momeni Danaei S, et al. Assessment of the Reliability and Validity of the Farsi Translation of the "Orthognathic Quality of Life Questionnaire" in 10-14 Year-Olds in Shiraz. *The Journal of Islamic Dental Association of IRAN (JIDA)*. 2013; 25(4):322-328.
8. Bortoluzzi MC, Manfro R, Soares IC, Presta AA. Cross-cultural adaptation of the orthognathic quality of life questionnaire (OQLQ) in a Brazilian sample of patients with dentofacial deformities. *Med Oral Patol Oral Cir Bucal*. 2011; 16(5):e694-9. <https://doi.org/10.4317/medoral.16938> PMID:20711138
9. Aydemir H, et al. Evaluation of long-term soft tissue changes after bimaxillary orthognathic surgery in Class III patients. *The Angle Orthodontist*. 2015; 85(4):631-637. <https://doi.org/10.2319/062214-449.1> PMID:25271955
10. Haur Wee T, Yoke Poon C. Quality of Life Treatment Outcomes of Class III Skeletal Patients after Bimaxillary Osteotomies. *Proceedings of Singapore Healthcare*. 2014; 23(3):183-190. <https://doi.org/10.1177/201010581402300302>
11. Abdullah WA. Changes in quality of life after orthognathic surgery in Saudi patients. *The Saudi Dental Journal*. 2015; 27(3):161-164. <https://doi.org/10.1016/j.sdentj.2014.12.001> PMID:26236131 PMCID:PMC4501467
12. Alolayan AB, Leung YY. Risk Factors of Neurosensory Disturbance following Orthognathic Surgery. *PLoS ONE*. 2014; 9(3):e91055. <https://doi.org/10.1371/journal.pone.0091055> PMID:24599321 PMCID:PMC3945003

## Appendix A

### OQLQ

Please read the following statements carefully. In order to find out how important each of the statements is to you, please circle 1, 2, 3, 4 or N/A where:

1 means it *bothers you a little*

4 means it *bothers you a lot*

2+3 lie *between these statements*

N/A means the statement does not apply to you or does not bother you at all

1	2	3	4
Bothers you a little			Bothers you a lot
1. I am self-conscious about the appearance of my teeth	1	2	3 4 N/A
2. I have problems biting	1	2	3 4 N/A
3. I have problems chewing	1	2	3 4 N/A
4. There are some foods I avoid eating because the way my teeth meet makes it difficult	1	2	3 4 N/A
5. I don't like eating in public places	1	2	3 4 N/A
6. I get pains in my face or jaw	1	2	3 4 N/A
7. I don't like seeing a side view of my face (profile)	1	2	3 4 N/A
8. I spend a lot of time studying my face in the mirror	1	2	3 4 N/A
9. I spend a lot of time studying my teeth in the mirror	1	2	3 4 N/A
10. I dislike having my photograph taken	1	2	3 4 N/A
11. I dislike being seen on video	1	2	3 4 N/A
12. I often stare at other people's teeth	1	2	3 4 N/A
13. I often stare at other people's faces	1	2	3 4 N/A
14. I am self-conscious about my facial appearance	1	2	3 4 N/A
15. I try to cover my mouth when I meet people for the first time	1	2	3 4 N/A
16. I worry about meeting people for the first time	1	2	3 4 N/A
17. I worry that people will make hurtful comments about my appearance	1	2	3 4 N/A
18. I lack confidence when I am out socially	1	2	3 4 N/A
19. I do not like smiling when I meet people	1	2	3 4 N/A
20. I sometimes get depressed about my appearance	1	2	3 4 N/A
21. I sometimes think that people are staring at me	1	2	3 4 N/A
22. Comments about my appearance really upset me, even when I know people are only joking	1	2	3 4 N/A