

DR LIISI RIPATTI (Orcid ID : 0000-0003-1858-8618)

Article type : Original Research Article

## **Surgically treated ovarian lesions in preadolescent girls**

Liisi Ripatti<sup>1,2</sup>, Mervi Taskinen<sup>3</sup>, Antti Koivusalo<sup>2</sup>, and Seppo Taskinen<sup>2</sup>

<sup>1</sup>Department of Pediatric Surgery, Turku University Hospital, Turku, Finland

<sup>2</sup>Department of Pediatric Surgery, New Children's Hospital, Helsinki University Hospital, Helsinki, Finland

<sup>3</sup> Division of Pediatric Hematology, Oncology and Stem Cell Transplantation, New Children's Hospital, Helsinki University Hospital, Helsinki, Finland

### **Corresponding author:**

Liisi Ripatti

Department of Pediatric Surgery, Turku University Hospital, Kiinamyllynkatu 4-8, PL 52, 20521 Turku, Finland.

E-mail: [liisi.ripatti@tyks.fi](mailto:liisi.ripatti@tyks.fi)

### **Conflicts of interest:**

None

This article has been accepted for publication and undergone full peer review but has not been through the copyediting, typesetting, pagination and proofreading process, which may lead to differences between this version and the [Version of Record](#). Please cite this article as [doi: 10.1111/aogs.13717](https://doi.org/10.1111/aogs.13717)

This article is protected by copyright. All rights reserved

## **Funding:**

This research did not receive any funding from public, commercial, or not-for-profit sectors.

## **ABSTRACT**

**Introduction:** The purpose of this study was to investigate the epidemiology and characteristics of surgically treated ovarian lesions in preadolescent girls. **Material and Methods:** This was a retrospective cohort study including all 0-11-year-old girls operated at a single center from 1999 to 2016 for ovarian cysts, neoplasms, or torsions. Patient charts were reviewed for symptoms, preoperative radiological imaging, operative details, and histopathology. **Results:** We identified 78 girls resulting in a population-based incidence of 4.2/100 000. Infants (n= 44) presented with benign cysts (42/44, 95%, one bilateral), a benign neoplasm (1/44, 2%), and a torsion without other pathology (1/44, 2%). Torsion was found in 25/29 (86%) ovaries with complex and in 3/15 (21%) ovaries with simple cysts in preoperative imaging ( $p<0.001$ ). Most infants were asymptomatic. Lesions in 1-11-year-old girls (n=34) included benign neoplasms (n=21/34, 62%), malignant neoplasms (n=5/34, 15%), a cyst with torsion (n=1/34, 3%), and torsions without other pathology (n=7/34, 21%). Torsion was more common in benign (17/21, 81%) than in malignant neoplasms (1/5, 20%) ( $p<0.020$ ). Ovarian diameter did not differ between ovaries with or without torsion ( $p=0.238$ ), or between benign and malignant neoplasms ( $p=0.293$ ). The duration of symptoms in lesions with or without torsion was similar. **Conclusions:** The majority of surgically treated ovarian lesions in preadolescent are benign lesions with torsion. Surgery should be ovary preserving and performed without delay.

## **Key words**

Ovary, pediatric, neoplasm, torsion, cyst, symptom

## Abbreviations

interquartile range=IQR

## Key message

Most surgically treated ovarian lesions in preadolescent girls are benign lesions with torsion. Ovary sparing is often possible even with radiological sign of torsion. Thus, surgery should be performed without delay in all children with suspicion of ovarian torsion.

## INTRODUCTION

Ovarian cystic lesions are common in neonates due to maternal, placental, and fetal hormonal activity<sup>1</sup> and in adolescent patients<sup>2</sup> with increasing hormonal activity at puberty. In preadolescent patients with low hormonal activity large cystic ovarian lesions are rare.<sup>3</sup> The incidence of ovarian cysts in girls <1 years of age has been estimated to be 5.70/100 000.<sup>4</sup> The total incidence of ovarian cysts in this age-group is probably higher because small clinically insignificant cysts are likely to remain undiagnosed.<sup>5</sup>

Benign and malignant ovarian neoplasms are extremely rare in neonates but their incidence increases with age. However, there are little data on the population-based incidence of ovarian neoplasms in children.<sup>4,6</sup> Previous studies have suggested that about half of the ovarian masses in children are neoplastic.<sup>7,8</sup> In a previous study we found that overall incidence of ovarian neoplasms in 0-15-year-old girls was 2.2/100 000 and the median age at presentation was 13 years.<sup>6</sup> A Dutch national study has reported an incidence of benign ovarian neoplasms from 0.34 at age of 2 years to 4.38 at age of 12 years per 100 000 girls.<sup>4</sup> The incidence of malignant ovarian neoplasms has been reported to vary with age from 0.04 to 0.85/100 000 girls.<sup>4,6</sup>

Differential diagnostics between uncomplicated ovarian cysts, cysts with torsion, or benign or malignant neoplasms is often challenging. Symptoms such as abdominal pain, nausea, vomiting, and fever may occur in lesions with or without torsion.<sup>9,10</sup>

There is no clear consensus on the indications and the timing of surgery of different pediatric ovarian lesions. To facilitate correctly timed and fertility sparing surgery, more data on both clinical characteristics and radiological findings of different ovarian lesions are needed.

We aimed to investigate the epidemiology, the findings in the preoperative imaging, and the symptoms of ovarian lesions in prepubertal girls operated at the catchment area of Children's Hospital, University of Helsinki. In addition, we aimed to report the histopathology and the operative technique of ovarian benign and malignant neoplasms, and cysts, and specifically to analyze which symptoms and radiological findings are associated with ovarian torsion.

## **MATERIAL AND METHODS**

### **Patients and methods**

We included all girls aged 0 to 11 years who underwent surgery for ovarian cysts, neoplasms, or torsion at Helsinki University Hospital for Children and Adolescents from 1999 to 2016. Patients were identified from the operative database. Data collected from hospital records included symptoms, radiological findings, operative technique, intraoperative findings, and histopathology. Cysts were classified according to the preoperative radiologic imaging into complex and simple cysts. Complex cysts had sedimentation, septae, or solid components in the imaging, whereas simple cysts contained clear fluid. Ovary with 'torsion without other pathology', was defined as ovarian torsion without perioperative or histopathologic diagnosis of cyst (more than 8 mm) or neoplasms. Necrosis was verified at histopathologic examination. We focused on prepubertal girls because all surgically treated ovarian lesions in this age group are treated in one university hospital with pediatric surgical service. This enabled the identification of all successive patients and

the calculation of accurate incidence figures. In addition, ovarian lesions in prepubertal girls differ from older girls mainly because of the lack of sex hormonal effect. Para-ovarian cystic lesions were excluded from this study.

The assessment of the population-based incidence of ovarian lesions was based on the institutional referral area that includes 1.5 million inhabitants. Because all cysts in the study patients were of neonatal origin and all preoperatively detectable neoplastic tumors were detected after infancy we have evaluated these two patient groups separately. Incidence was separately analyzed for two groups of patients; Group 1 included infants operated at less than one year of age with either prenatal or postnatal diagnosis of ovarian lesion and Group 2 consisted of girls operated between the ages of 1 and 11 years. The incidence of ovarian pathology in Group 1 was calculated in relation of annual birth rate and in Group 2 to the relation of the number of 1 to 11-year-old girls at the institutional referral area. Data of birth rate and annual number of 1 to 11-year-old girls were provided by Statistics Finland.

### **Statistical analyses**

Continuous variables were expressed as medians and interquartile ranges (IQR) or ranges. The Mann-Whitney U test was used to compare continuous variables and Fisher's Exact test to compare categorical variables. The StatView® 5.0.1 software program (SAS Institute Inc., Cary, NC, USA) was used for statistical analyses. P-value of less than 0.05 was considered statistically significant.

### **Ethical approval**

The study was approved by the Ethics committee of Helsinki University Hospital (approval date 25th September 2014, No: 285/13/03/03/2014).

## RESULTS

### **Incidence and histopathology of ovarian lesions requiring surgery**

A total of 78 girls (n=44 in Group 1 and n=34 in Group 2) were operated for ovarian neoplasms, torsions, or cysts during the study period. The total birth rate at the referral area was 155 839 and the mean annual birth rate of female neonates was 8 658. The mean number of 0 to 11-year-old girls living annually in the referral area during 1999 to 2016 was 103076 (range 99 658-108 335, altogether 1 855 369 girls). Accordingly, the corresponding population-based incidence of ovarian lesions for girls aged 0 to 11 years was 4.2/100 000. The most common finding at surgery (n=55/78 [71%]) was ovarian torsion (Table 1). Age at the time of ovarian surgery according to histopathology is shown in Table 2.

#### **Group 1**

The mean age of the patients in Group 1 at surgery was 0.15 years (SD  $\pm$ 0.07, range 0-0.98). Out of the 44 infants, 42 (95%) had ovarian cysts (one bilaterally). In 29/44 (66%) infants, the ovary was in torsion. Only one infant was diagnosed with ovarian benign neoplasm. This was a gonadoblastoma found in prophylactic oophorectomy performed due to the risk of neoplasm in an asymptomatic girl with mosaic Turner syndrome. This patient was excluded from the further analysis. Another infant undergoing surgery for small bowel obstruction had preoperative ultrasound finding of an enlarged ovary (37mm) and was eventually diagnosed at surgery with ovarian torsion without a cyst or other pathology. Out of the 43 infants without a neoplasm, 36 were diagnosed antenatally, four were symptomatic (pain in three and lack of appetite in one). Three had an incidental postnatal diagnosis; one was noticed at 2 days of age at palpation of the abdomen, second at 127 days when imaged for suspicion of inguinal hernia, and the third at 193 days when imaged due to vaginal bleeding. Symptoms were reported in 1/14 (7%) patients without torsion and 3/28 (11%) with torsion ( $p>0.999$ ).

#### *Ultrasound findings in Group 1*

Preoperative ultrasound indicated a complex cyst in 28/43 (65%) and a simple cyst in 15/43 (35%) of the cystic cases (Figure 1). Out of the 28 complex cysts, sedimentation was seen in 17 (61%), solid components in 8 (29%) (one also with sedimentation), and three had miscellaneous findings. Eventually, torsion was detected at surgery in

25/28 (89%) of the complex cysts, in all with solid components, and in 3/15 (20%) of the simple cysts ( $p<0.001$ ). All nine ovaries with solid components in complex cyst in ultrasound were removed because of complete necrosis. The median size of the ovary with torsion was 51 (range 24-90) mm. Examples of preoperative ultrasound images of two ovaries in torsion are shown in Figure 2A and B.

### *Surgery in Group 1*

Out of the 44 infants (42 with cysts), 15 (34%) underwent laparoscopy, nine (20%) underwent para-umbilical laparotomy, and 20 (45%) Pfannenstiel or other laparotomy. Ovary-sparing procedure was possible in 22/43 (51%) infants with ovarian cysts; ovary was spared in 8/28 (29%) with cysts and torsion, and in 14/15 (93%) with cysts without torsion ( $p<0.001$ ) (Figure 1).

### **Group 2**

The mean age of the patients in Group 2 at surgery was 7.6 years (SD  $\pm 3.1$ , range 1.5-11.9). Of the total of 34 patients, 21 (62%) had a benign neoplasm, five (15%) a malignant neoplasm (Table 3), seven (21%) a simple ovarian torsion without specific ovarian pathology, and one (3%) a simple cyst. Thirty-three (97%) patients were symptomatic (pain  $n=30$ , fever  $n=5$ , vomiting  $n=5$ , abdominal swelling  $n=3$ ). The median duration of symptoms before surgery was 2 days (IQR 1-6). The duration of symptoms before surgery did not significantly differ in patients with or without ovarian torsion (median 3, [IQR 2-76], vs. 2 [IQR 1 -5] days, respectively) ( $p=0.429$ ). The only asymptomatic patient was diagnosed with an autoamputated ovary at the age of 2.3 years as an incidental finding in pelvic x-ray and possibly of neonatal origin.

### *Factors associated with ovarian torsion in Group 2*

Torsion was detected in 81% (17/21) of benign neoplasms whereas only one of five (20%) malignant neoplasms presented with torsion ( $p<0.020$ , see Figure 3). The ovarian diameter did not differ between benign (median 77mm [IQR 57-91]) and malignant neoplasms (90mm [68-113]) ( $p=0.293$ ) or in ovaries with (66mm [IQR49-

83]) and without (77mm [IQR 65-110]) torsion ( $p=0.238$ ). In addition, the ovaries with benign and malignant neoplasms did not differ in size with those in torsion without identifiable other pathology, 79mm (IQR 60-95) and 60mm (IQR 46-66), respectively ( $p=0.296$ ). Cysts were observed in 19/21 benign neoplasms, 4/5 malignant neoplasms, and small cysts ( $\leq 8$ mm) also in 5/7 ovaries with torsion without other pathology ( $p=0.208$ ).

### *Surgery in Group 2*

In Group 2, 6/34 (18%) of the patients underwent laparoscopic surgery (simple torsions  $n=4$ , benign neoplasms  $n=1$ , simple cyst  $n=1$ ). Ovary-sparing surgery was performed in 7/34 (21%) including five with torsion without other pathology and two with mature teratoma with torsion.

## **DISCUSSION**

Our main results were: 1) The incidence of ovarian lesions that required surgery in 0-11-year-old girls was 4.2 / 100000. Incidence was further divided into an incidence of 28.2 /100000 in infants from 0 to 1 years of age and 2.0 /100000 in girls aged from 1 to 11 years. Incidence of malignant lesions was 0.3 / 100000 in 1-11-year-old girls. 2) Study infants were mostly asymptomatic. In infants, the most common surgical pathology was large ovarian cysts with torsion and with a complex cyst in preoperative ultrasound. Sedimentation was often associated with torsion but not necessarily with necrosis. Ovaries could be spared in 29% of the infants despite of torsion. 3) In girls from 1 to 11 years of age, the most common surgical pathology was a symptomatic benign neoplasms. The duration of symptoms in lesions with or without torsion was similar. 4) Ovarian diameter measured in the ultrasound did not predict either torsion or a malignant ovarian lesion. 5) Malignancy was very rare in an ovary with torsion.

Since we had access to comprehensive data of pediatric patients operated in the catchment area of our hospital with a population of approximately 1.5 million inhabitants, we were able to calculate incidences of different ovarian lesions operated



in girls at different age groups. In line with previous studies<sup>4</sup>, most study infants had benign cysts with or without ovarian torsion while the incidence of ovarian neoplasms was very low in infants. The incidence rate of malignant neoplasms in our study population (0.3 per 100 000 girls) was low and comparable to previous Dutch reports with an incidence ranging from 0.04 to 0.85 per 100 000 girls below 13 years of age per year.<sup>4</sup>

In infants, the appearance of a simple cyst (without sedimentation or different components) in preoperative imaging was quite well predictive of the operative finding of an uncomplicated ovarian cyst (73%). This is in line with previous studies and with the recommendations of non-operative follow-up of small simple cysts when the diagnosis is clear and the patient is asymptomatic.<sup>3,11</sup> In our cohort, sedimentation was often an indicator of torsion, but not necessarily of necrosis. This suggests that infants with sedimentation of the cyst may benefit from an operation on a more urgent basis in order to avoid ovarian necrosis and oophorectomy. However, solid components in a cyst in an infant were likely to indicate necrosis, suggesting that the operation does not need to be performed urgently.

The risk of ovarian torsion and the risk of having surgery is considered increased if size of an ovarian cyst in radiological imaging exceeds 40-50 mm.<sup>12,13</sup> However, there is controversy on whether a large cyst size alone should be an indication for surgical treatment or not.<sup>3,9</sup> Interestingly, in our material the cyst size was less than 50mm in 11 out of 28 ovaries with torsion. The smallest ovarian cyst with torsion was 24mm. While small cyst size was associated with torsion in our study, we cannot draw a conclusion on this. For comparison, it would have been of interest to have follow-up data on infants with small cyst that were conservatively treated. Unfortunately these data were not available.

Ovarian torsions were most commonly found in girls with cysts or benign neoplasms. Only one patient had ovarian torsion in relation to a malignant ovarian neoplasm. This supports the previous theory of malignant neoplasms being less likely to rotate around themselves due to adhesions.<sup>9</sup> Also, since most 1-11-year-old girls had either benign

or malignant ovarian neoplasms, or torsions, our results support the previous recommendation of operating on prepubertal girls with persisting or complex ovarian cysts.<sup>3</sup>

According to our results, pain is a relatively poor indicator of ovarian torsion.

Particularly the infants remain asymptomatic despite of torsion. In 1-11-year-old girls, pain was the most common symptom in ovarian torsion. However, as observed in previous studies,<sup>10</sup> most patients with an ovarian lesion without torsion presented with abdominal pain as well. Also, the duration of symptoms before operation was similar in patients with ovarian torsion and in patients without torsion. The long duration of symptoms before surgery in our series is partly explained by our earlier policy to wait for the tumor markers before proceeding to surgery. However, since it is very rare for an ovary with malignant neoplasm to be in torsion<sup>9</sup>, we have recently changed our policy on this.

Conservative surgical treatment of ovarian torsion by detorsion and of benign neoplasms by ovary-sparing techniques has been advocated instead of oophorectomy<sup>14-16</sup> to save viable ovarian tissue to preserve fertility and to avoid early menopause.<sup>17,18</sup> Purely cystic lesions with negative tumor markers or of small size have been suggested as indications for gonad sparing procedure.<sup>19</sup> In our data, ovary-sparing procedures were rarely performed (21%) in 1-11-year old girls. This is in contrast to previous reports with ovary-sparing procedures performed in 40 to even 95% of the cases with benign conditions.<sup>10,20-21</sup> The high rate of oophorectomies in this patient group is partly explained by our earlier policy to prefer oophorectomy to avoid tumor rupture also in benign neoplasms. We have started to be more active in performing ovary-sparing procedures nowadays since good long term results have been observed with ovary-sparing surgery in pediatric patients despite black-bluish color in twisted ovary.<sup>15,22</sup> On the other hand, our results showed a greater rate of ovary-sparing procedures in infants compared to a previous study reporting only 14% of ovary-sparing surgeries in infants with operatively treated ovarian cysts.<sup>23</sup> This is may be explained by the shorter delay in surgery. Unfortunately, we did not have data on function of the ovaries that had been preserved. Ovary-sparing treatment to preserve future fertility is further encouraged by our previous study showing that 23%

of girls operated for benign ovarian lesion were later diagnosed with contralateral ovarian neoplasm.<sup>24</sup>

The limitation of our study is the lack of information on conservatively treated cysts. It would have been of interest to have data of the small infant ovarian cysts without operation to be able to estimate further the association of cyst size and torsion.

Because some rather small ovaries were twisted in our material, it seem that this aspect needs further investigation. Although increasing towards the end of the study period, ovary-sparing surgery was infrequent in our material. However, our results support the concept of ovary-sparing surgery in infants and also in older patients in whom torsion was mostly associated with a benign condition. The strength of our study is the population based material from the hospital catchment area to give reliable incidence figures.

## **CONCLUSION**

In infants, the prevailing pathology was a cyst with torsion whereas neoplasms were more common in 1-11-year-old girls. Irrespectively of etiology, most operated patients had ovarian torsion, and torsion was almost always associated with a benign condition. Despite of torsion, many ovaries could be spared even in infants. Thus, to preserve viable ovarian tissue, unnecessary delay of surgery and oophorectomies in benign conditions should be avoided.

## **REFERENCES**

1. Dolgin SE. Ovarian Masses in the Newborn. *Semin Pediatr Surg* 2000; 9, 3:121-127.
2. Schallert E, Abbas P, Mehollin-Ray A et al. Physiologic Ovarian Cysts versus Other Ovarian and Adnexal Pathologic Changes in the Preadolescent and Adolescent Population: US and Surgical Follow-up. *Radiology*. 2019;292:172–178

3. Brandt ML, Helmrath MA. Ovarian cysts in infants and children. *Semin Pediatr Surg.* 2005;14:78-85.
4. Hermans AJ, Kluivers KB, Janssen LM, et al. Adnexal masses in children, adolescents and women of reproductive age in the Netherlands: A nationwide population-based cohort study. *Gynecol Oncol.* 2016;143:93-7.
5. Vogtlander MF, Rijntjes-Jacobs EG, van den Hoonaard TL, et al. Neonatal ovarian cysts. *Acta Paediatr* 2003;92:498-501.
6. Taskinen S, Fagerholm R, Lohi J, et al. Pediatric ovarian neoplastic tumors: incidence, age at presentation, tumor markers and outcome. *Acta Obstet Gynecol Scand* 2015;94:425-9.
7. von Allmen D. Malignant lesions of the ovary in childhood. *Semin Pediatr Surg.* 2005;14:100-5.
8. Cass DL, Hawkins E, Brandt ML, et al. Surgery for ovarian masses in infants, children, and adolescents: 102 consecutive patients treated in a 15-year period. *J Pediatr Surg.* 2001;36:693-9.
9. Sasaki KJ, Miller CE. Adnexal torsion: review of the literature. *J Minim Invasive Gynecol.* 2014;21:196-202.
10. Spinelli C, Pucci V, Strambi S, et al. Treatment of ovarian lesions in children and adolescents: a retrospective study of 130 cases. *Pediatr Hematol Oncol.* 2015;32:199-206.
11. Akin MA, Akin L, Ozbek S, et al. Fetal-neonatal ovarian cysts--their monitoring and management: retrospective evaluation of 20 cases and review of the literature. *J Clin Res Pediatr Endocrinol.* 2010;2:28-33.
12. Bascietto F, Liberati M, Marrone L, et al. Outcome of fetal ovarian cysts diagnosed on prenatal ultrasound: a systematic review and meta-analysis. *Ultrasound Obstet Gynecol.* 2017;50:20-31.
13. Naffaa L, Deshmukh T, Tumu S, et al. Imaging of Acute Pelvic Pain in Girls: Ovarian Torsion and Beyond. *Curr Probl Diagn Radiol* 2017;46:317-329.

14. Spinelli C, Piscioneri J, Strambi S. Adnexal torsion in adolescents: update and review of the literature. *Curr Opin Obstet Gynecol* 2015;27:320-5.
15. Geimanaite L, Trainavicius K. Ovarian torsion in children: management and outcomes. *J Pediatr Surg* 2013;48:1946-53.
16. Galinier P, Carfagna L, Delsol M, et al. Ovarian torsion. Management and ovarian prognosis: a report of 45 cases. *J Pediatr Surg* 2009;44:1759-65.
17. Bjelland EK, Wilkosz P, Tanbo TG, et al. Is unilateral oophorectomy associated with age at menopause? A population study (the HUNT2 Survey). *Hum Reprod* 2014;29:835-41.
18. Oskayli MC, Gulcin N, Ozatman E, et al. Assessment of ovarian reserve using serum anti-Mullerian hormone after ovarian torsion surgery. *Pediatr Int* 2019;61:504-7.
19. Luczak J, Baglaj M. Selecting treatment method for ovarian masses in children - 24 years of experience. *J Ovarian Res.* 2017;10:59.
20. Hernon M, McKenna J, Busby G, et al. The histology and management of ovarian cysts found in children and adolescents presenting to a children's hospital from 1991 to 2007: a call for more paediatric gynaecologists. *BJOG* 2010;117:181-4.
21. Adeyemi-Fowode O, Lin EG, Syed F, et al. Adnexal Torsion in Children and Adolescents: A Retrospective Review of 245 Cases at a Single Institution. *J Pediatr Adolesc Gynecol.* 2019;32:64-9.
22. Geimanaite L, Trainavicius K. Pediatric ovarian torsion: Follow- up after preservation of ovarian tissue. *J Pediatr Surg* 2019;54:1453-6.
23. Rialon KL, Akinkuotu A, Fahy AS, et al. Management of ovarian lesions diagnosed during infancy. *J Pediatr Surg* 2019;54:955-8.
24. Taskinen S, Urtane A, Fagerholm R, et al. Metachronous benign ovarian tumors are not uncommon in children. *J Pediatr Surg* 2014;49:543-5.

### **Legends of the figures**

Figure 1. The findings in preoperative ultrasound and at operation of the cystic ovaries in Group 1 (<1 years of age).

Figure 2. Neonatal ovarian cysts with torsion. A. Cyst with sedimentation and a viable ovary. B. Cyst with solid components and a necrotic ovary.

Figure 3. Findings at histology and operation of ovarian tumors in Group 2 (1-11-year-old girls).

Table 1. Findings at ovarian surgery in the study groups. Incidence for Group 1 is calculated per 100 000 newborn females and for Group 2 as a population-based incidence of girls from 1 to 11 years of age living at the catchment area from 1999 to 2016. Cases with torsion are given in parenthesis.

<b>Ovarian pathology</b>	<b>Group 1 (&lt;1 years of age) n</b>	<b>Group 1 incidence/ 100 000 newborn females</b>	<b>Group 2 (age 1-11 years) n</b>	<b>Group2 incidence/ 100 000 1-11 year-old girls</b>	<b>All study patients (0-11 years) n</b>	<b>All study patients, incidence/ 100 000 0-11 year-old girls</b>
<b>Neoplasms</b>	1 (0)	0.6	26 (18)	1.5	27 (18)	1.5
- benign	1*	0.6	21 (17)	1.2	22 (17)	1.2
- malignant	0	0	5 (1)	0.3	5 (1)	0.3
<b>Cyst</b>	42** (28)	27.0	1 (1)***	0.05	43** (29)	0.24
<b>Torsion without other pathology</b>	1 (1)	0.6	7 (7)	0.4	8 (8)	0.4
<b>Total</b>	<b>44 (29)</b>	<b>28.2</b>	<b>34 (26)</b>	<b>2.0</b>	<b>78 (55)</b>	<b>4.2 (3.0)</b>

\*A prophylactic gonadectomy was performed due to mosaic Turner syndrome and an incidental finding of gonadoblastoma was found at histology examination.

\*\*One patient had bilateral cysts.

\*\*\*Autoamputated ovary

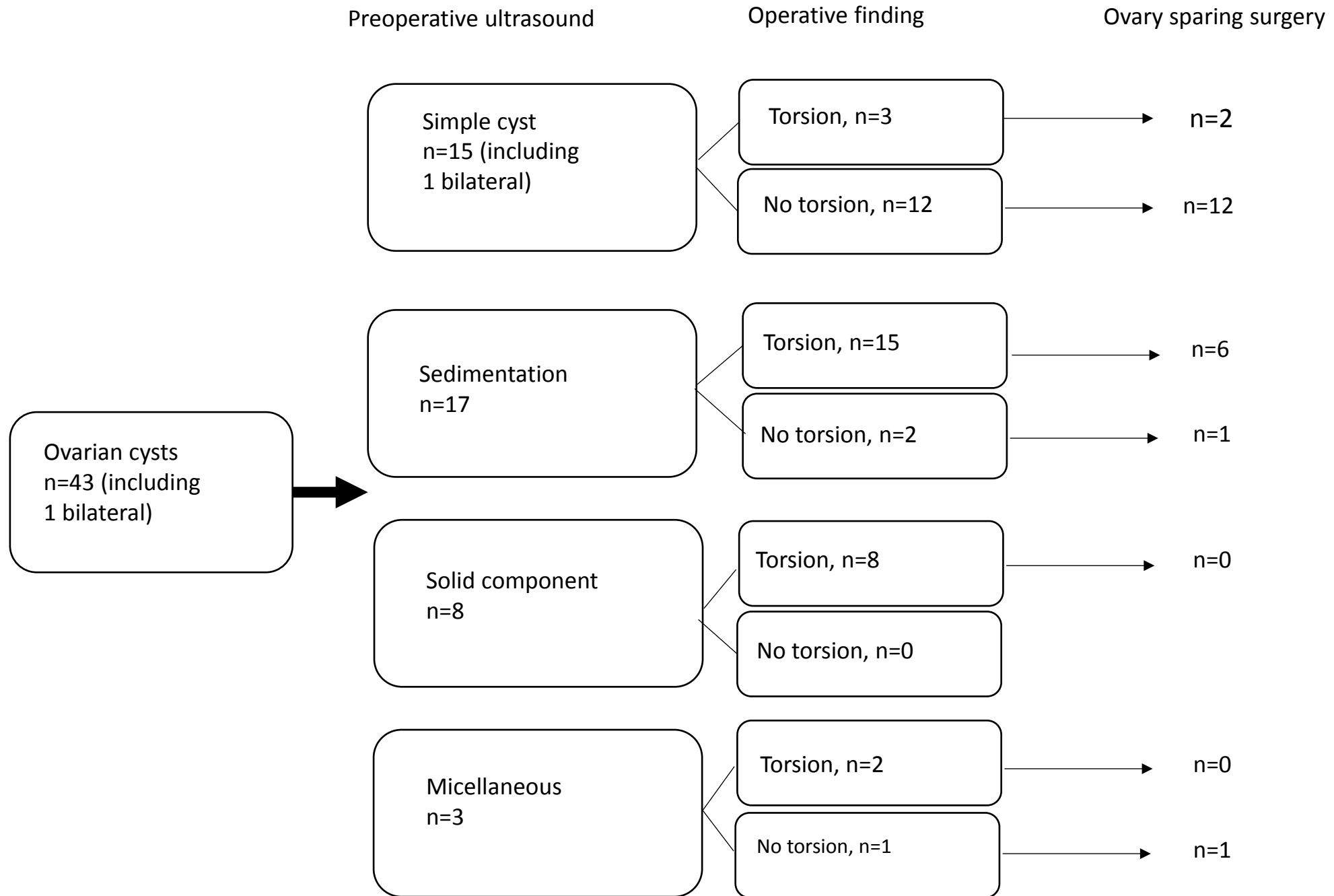
Table 2. Age at ovarian surgery according to the diagnosis at histology.

IQR=interquartile range.

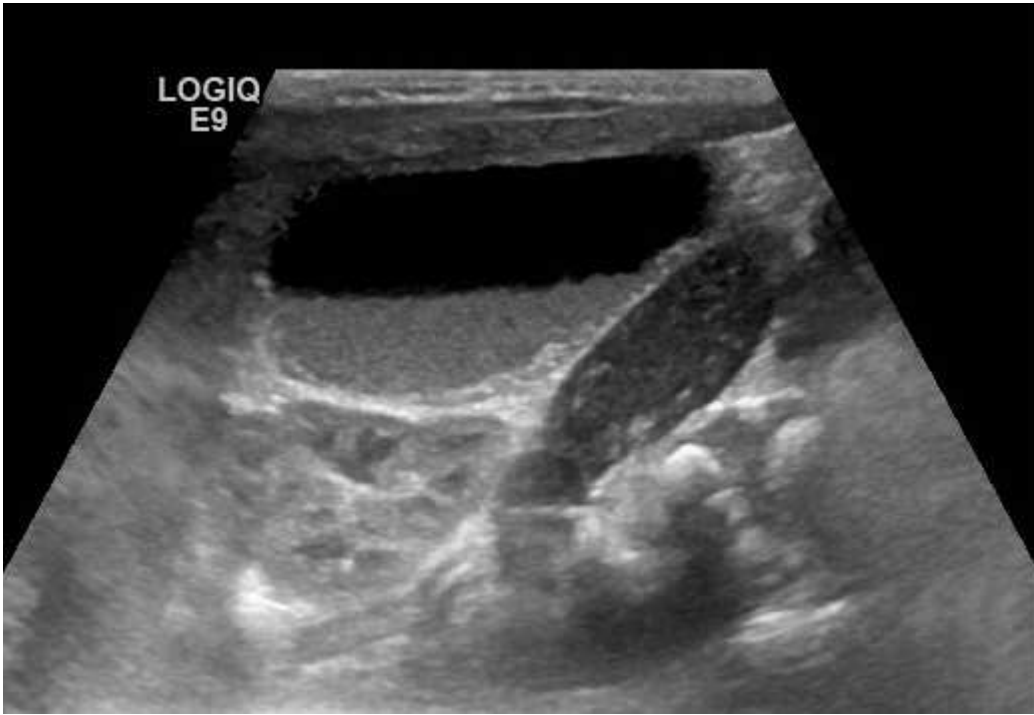
<b>Diagnosis</b>	<b>Median age (years)</b>
Cyst	0.1 (IQR 0.0-0.2, range 0-2.4)
Torsion without other pathology	7.7 (IQR 4.0-10.5, range 0.1-11.3)
Benign neoplasm	8.2 (IQR 4.9-10.1, range 1.5-11.9)
Malignant neoplasm	8.3 (IQR 7.1-9.8, range 3.9-11.9)

Table 3. Histological diagnoses of the ovarian neoplasms in 0-11 –year-old girls.

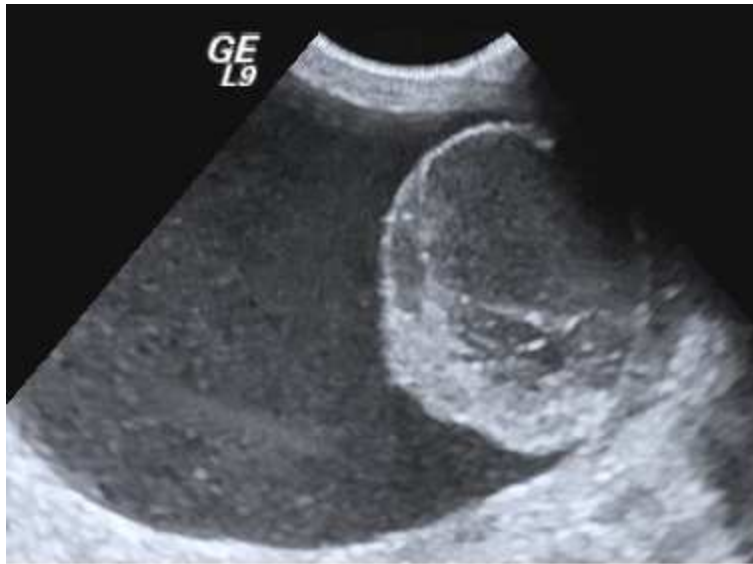<b>Benign neoplasms</b>	<b>22</b>
Mature teratoma	21
Gonadoblastoma	1
<b>Malign neoplasms</b>	<b>5</b>
Immature teratoma	3
Yolk sac tumor	1
Stromal sex cord tumor	1







aogs\_13717\_f2a.tif



aogs\_13717\_f2b.tif

