

Human Monkeypox

Epidemiologic and Clinical Characteristics, Diagnosis, and Prevention

Eskild Petersen, MD, DMSc, DTMH^{a,b,c,*}, Anu Kantele, MD, PhD^d,
Marion Koopmans, DVM, PhD^e, Danny Asogun, MBBS, FWACP^{f,g},
Adesola Yinka-Ogunleye, BDS, MPH^h,
Chikwe Ihekweazu, MBBS, MPH, FFPH^h,
Alimuddin Zumla, FRCP, PhD, FRCPathⁱ

KEYWORDS

• Monkeypox • Smallpox • West Africa • Epidemic

KEY POINTS

- Human monkeypox is a zoonosis caused by the monkeypox virus (MPXV), a double-stranded DNA virus of the family Poxviridae.
- The frequency and geographic distribution of human monkeypox cases across West and Central Africa have increased in recent years.

Continued

All authors contributed equally.

A. Zumla, D. Asogun, and C. Ihekweazu are members of the PANDORA-ID-NET Consortium. PANDORA-ID-NET (EDCTP Reg/Grant RIA2016E-1609) is funded by the European and Developing Countries Clinical Trials Partnership (EDCTP2) programme, which is supported under Horizon 2020, the European Union's Framework Programme for Research and Innovation. A. Zumla is in receipt of a National Institutes of Health Research senior investigator award.

Conflicts of Interest: All authors have an interest in global public health and emerging and re-emerging infections. All authors have no other conflict of interest to declare.

^a Institute of Clinical Medicine, University of Aarhus, Palle Juul-Jensens Boulevard 82, Aarhus N DK-8200, Denmark; ^b The Royal Hospital, Muscat, Oman; ^c European Society for Clinical Microbiology and Infectious Diseases, Task Force for Emerging Infections, Basel, Switzerland; ^d Inflammation Center, Helsinki University Hospital and Helsinki University, Stenbäckinkatu 9, PO BOX 100, Helsinki FI-00029 HUS, Finland; ^e Viroscience Department, Erasmus Medical Centre, Postbus 2040, Rotterdam 3000 CA, the Netherlands; ^f Department of Public Health, College of Medicine, Ambrose Alli University, Ekpoma, Nigeria; ^g Department of Public Health, and Institute of Lassa Fever Research and Control, Irrua Specialist Teaching Hospital, Irrua, Nigeria; ^h Nigeria Centre for Disease Control, Plot 801, Ebitu Ukiwe Street, Jabi, Abuja, Nigeria; ⁱ Division of Infection and Immunity, Center for Clinical Microbiology, University College London, The National Institute of Health Research Biomedical Research Centre at UCL Hospitals, Gower Street, London WC1E 6BT, UK

* Corresponding author. Directorate General for Communicable Disease Surveillance and Control, Ministry of Health, 18th November Street, 101 Muscat, Sultanate of Oman.

E-mail address: eskild.petersen@gmail.com

Infect Dis Clin N Am ■ (2019) ■–■

<https://doi.org/10.1016/j.idc.2019.03.001>

0891-5520/19/© 2019 Elsevier Inc. All rights reserved.

id.theclinics.com

Continued

- The clinical presentation of monkeypox is similar to that of smallpox, in terms of symptom onset, timing of rash occurrence, and rash distribution, but generally less severe than smallpox with lower fatality rate and scarification.
- Most confirmed Monkeypox cases are younger than 40 years with a median age of 31 years, a population born only after discontinuation of the smallpox vaccination campaign, and thus may reflect a lack of cross-protective immunity.

INTRODUCTION

Human monkeypox virus (MPXV) is a double-stranded DNA virus of the Orthopoxvirus genus of the family Poxviridae.^{1–4} Two genetic clades of the monkeypox virus have been characterized: West African and Central African. MPXV is one of the 4 orthopoxvirus species pathogenic for humans, the other 3 being (1) variola major virus (VARV), the causative agent of smallpox, now eradicated, (2) variola minor virus, and (3) cowpox virus (CPXV). There is a range of animal poxviruses, several of which have zoonotic potential. Infections in humans have been described for vaccinia virus, cowpox virus, buffalopox virus, and sporadic cases of camelpox.^{5,6} Monkeypox infects a wide range of mammalian species, but its natural host reservoir remains unknown.

PUBLIC HEALTH IMPORTANCE

Thought to be a rare and self-limiting disease,⁷ monkeypox has not attracted much attention since its discovery 70 years ago. The frequency and geographic distribution of human monkeypox cases have increased in recent years in a specific region of Africa (**Fig. 1**),⁸ and monkeypox has been recognized as an increasing public health threat, particularly in regions in West Africa where there is close interaction between humans and wild animal reservoirs and in particular where there is evidence that the infection attack rate is increasing. The clinical presentation of monkeypox is similar to that of smallpox² in terms of symptom onset, timing of rash occurrence, and rash distribution,⁷ but generally less severe than smallpox in terms of complication rate, case fatality rate, and levels of scarification.

Recently, concern has been raised about the emergence of MPXV as well as the resemblance of its clinical presentation to that of smallpox, a deadly disease globally eradicated by vaccination 40 years ago.⁹ During outbreaks, it has been challenging to clinically distinguish monkeypox from chickenpox, an unrelated herpesvirus infection. However, sporadic zoonotic infections with other orthopoxviruses also call for vigilance. Outbreaks of buffalopox have occurred with multiple human cases in India.¹⁰ Similarly, during outbreaks of vaccinia virus infection in cattle in Brazil, there is documented evidence of human infections.¹¹

Cross-Immunity and Protection

Various orthopoxvirus species share genetic and antigenic features,^{12–14} and an infection by any of these species may confer substantial protection against infection by the others.¹⁵ Vaccination with vaccinia virus protects against disease caused by VARV, MPXV, or CPXV.¹⁶ The immunologic mechanisms underlying cross-protection by immunization with vaccinia virus seem to be diverse, with neutralizing antibodies among the principal components.¹⁷ Consistent with the ability of smallpox vaccine to provide

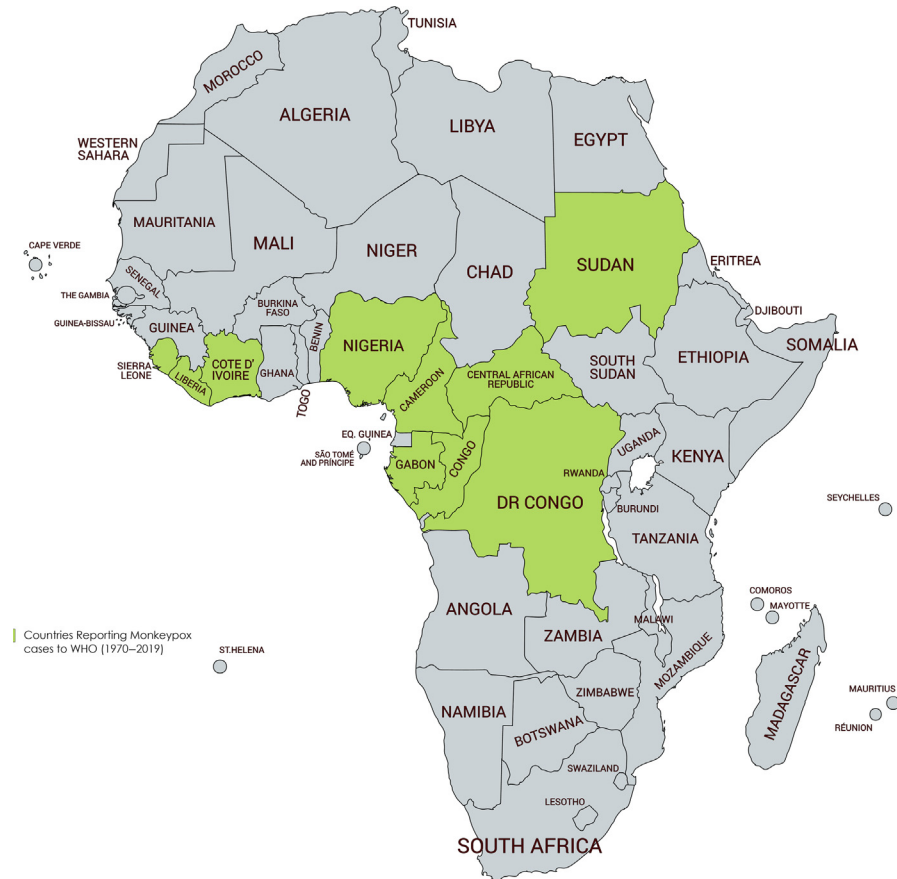

Fig. 1. Map of Africa showing countries reporting human Monkeypox cases (1971–2019).

cross-protection for humans against monkeypox, monkeys can be protected against monkeypox by immunization with the human smallpox vaccine.^{18,19}

Ever since smallpox vaccinations were discontinued in 1978, cross-protective immunity to various orthopoxviruses has waned, particularly in younger individuals lacking vaccinia-induced immunity, and the number of unvaccinated, susceptible individuals has grown worldwide. Indeed, these changes have been accompanied by an increased frequency and geographic distribution of human monkeypox cases in recent years.

EPIDEMIOLOGY

Discovery and Animal Reservoirs

MPXV was first detected in 1958 in an outbreak of a vesicular disease among captive monkeys transported to Copenhagen, Denmark from Africa for research purposes. Hence the name “monkeypox.”²⁰ The term is inappropriate because the largest animal reservoirs of the virus have been found in rodents, including squirrels and giant pouched rats, both of which are hunted for food.²¹ Rodents are the largest group of mammals with more than 1500 species. The extent of the wild animal reservoir, the natural history, and pathogenesis of monkeypox in

both animals and humans remains unknown, requiring characterization through ecologic and epidemiologic studies. Thus far, MPXV has been detected in diverse animal species: squirrels (rope and tree), rats, striped mice, dormice, and monkeys. In 1985, the virus was isolated from a rope squirrel in the Democratic Republic of Congo (DRC) and a dead infant mangabey monkey in Tai National Park, Cote d'Ivoire.²² During a large monkeypox outbreak following introduction of the virus through animals imported into an animal trading company, at least 14 species of rodents were found to be infected.²³

Like humans, monkeys are considered disease hosts. Further studies are needed to understand how the virus persists in nature, and to explore pathogen-host associations and the effect of climatic and ecologic factors influencing the shifts between geographic areas and the virus as a cause of disease in humans.²⁴

Transmission of Monkeypox Virus to Humans

Not only the specific animal host reservoir of monkeypox but also the mode of transmission of MPXV from animals to humans remain unknown. Aerosol transmission has been demonstrated in animals,^{25,26} and may explain a nosocomial outbreak in the Central African Republic.²⁷ However, indirect or direct contact with live or dead animals is assumed to be the driver of human monkeypox infections in humans.^{28,29} Poverty and continued civil unrest force people to hunt small mammals (bushmeat) to obtain protein-rich food, thus increasing exposure to wild rodents, which may carry monkeypox.³⁰

In August 1970 the first human case of monkeypox was identified in a 9-year-old child with smallpox-like vesicular skin lesions in the village of Bukenda in the Equatorial region of Zaire (now DRC).³¹ This patient was found during a period of intensified smallpox surveillance conducted 9 months after the World Health Organization (WHO) the eradication of smallpox in the DRC had certified the eradication of smallpox in the DRC.

Geographic Endemicity and Increase in Number of Cases

Ever since its discovery, the disease has been endemic to Central and West Africa with intermittent, sporadic cases of monkeypox transmitted from local wildlife reported among humans. Retrospective studies indicated that similar cases had occurred in 1970 to 1971 in the Ivory Coast, Liberia, Nigeria, and Sierra Leone.^{32–35} Subsequent enhanced surveillance observed a steady increase in the rate of human monkeypox cases. The number of cases of human monkeypox has increased exponentially over the past 20 years, and has already exceeded that accumulated during the first 45 years since its first discovery.^{28,29,36–45}

A comprehensive enhanced surveillance study in the DRC in 2004 to 2005 showed a steep increase in incidence compared with data from a WHO enhanced surveillance program carried out from 1970 to 1986 reporting 404 cases.⁴⁶ The incidence was highest in forested regions, and in lower age groups not vaccinated as part of the smallpox eradication program.⁴² To date, human monkeypox cases have been reported from 10 African countries: DRC, Republic of the Congo, Cameroon, Central African Republic, Nigeria, Ivory Coast, Liberia, Sierra Leone, Gabon, and South Sudan.^{1,36,47} The growing incidence of human monkeypox cases in Central and West Africa is considered a consequence of waning cross-protective immunity among the population after smallpox vaccination was discontinued in the early 1980s, following the eradication of smallpox.^{28,42} The deteriorating immunologic status is not only related to waning vaccine-induced protection among those initially vaccinated, but probably—and even more—to

the increasing proportion of those never given the vaccine, that is, nonvaccinated younger age groups. Both mechanisms lead to a growing percentage of susceptible individuals in the endemic areas in Central and West Africa. Another central factor considered to contribute to the incidence of monkeypox is related to increasing contact between humans and small mammals potentially carrying MPXV. Humans invade jungles and forests, the natural environment of the reservoir species. Civil wars, refugee displacement, farming, deforestation, climate change, demographic changes, and population movement may have led to a spread of monkeypox-infected animals and increased their interaction with humans across West and Central Africa.

Monkeypox Cases in the United States

Monkeypox remained an ignored global public health threat and was only given international attention when the first cases outside Africa were detected in the United States in 2003.⁴⁸ After several Midwesterners developed fever, rash, respiratory symptoms, and lymphadenopathy, outbreak investigation linked the symptoms to exposure to pet prairie dogs (*Cynomys* species), and monkeypox virus was identified as a causative agent.⁴⁸ It spread rapidly. Monkeypox cases were reported from 6 states—Illinois, Indiana, Kansas, Missouri, Ohio, and Wisconsin—during the outbreak.⁴⁹ Molecular investigations identified a monkeypox virus of the West African genetic group (clade). Epidemiologic studies concluded that the virus had been imported into the United States, more specifically to Texas, from Ghana on April 9, 2003, with a shipment of small mammals of 9 different species, including 6 genera of African rodents.⁵⁰ These comprised rope squirrels (*Funisciurus* sp.), tree squirrels (*Heliosciurus* sp.), African giant pouched rats (*Cricetomys* sp.), brush-tailed porcupines (*Atherurus* sp.), dormice (*Graphiurus* sp.), and striped mice (*Lemniscomys* sp.). Some of the infected animals were housed in close proximity to prairie dogs later sold as pets.

Monkeypox Cases in the United Kingdom and Israel

In September 2018, monkeypox again drew the attention of global media, politicians, and scientists when 3 individual patients in the United Kingdom were diagnosed with monkeypox.⁵¹ The first 2 had recently traveled in Nigeria, a country with an ongoing outbreak of the disease,⁵² and both were symptomatic during their flight home. The third case of monkeypox in the United Kingdom was diagnosed in a health care worker caring for 1 of these first 2 patients. As the clinical picture of the 3 patients' disease raised a concern over an exotic disease, special infection control measures were taken well before monkeypox was suspected. One of the primary cases reported contact with a person with suspected rash at a family gathering, and the consumption of bushmeat.⁵² Secondary and tertiary human-to-human transmission of monkeypox does occur in endemic areas.^{53,54} Of note, definitive confirmation of human-to-human transmission in endemic areas is somewhat problematic, because even the secondary and tertiary cases may have been exposed to infected animals. The disease contracted by the British health care worker provides indisputable evidence of human-to-human transmission from an infected patient.

In October 2018, Israel reported a monkeypox case imported from Nigeria.⁵⁵ It is well known that travelers can act as sentinels of infectious disease epidemics in the region visited. Not consistent with the reports of low levels of transmission in Nigeria, 3 cases imported to other countries from there within a couple of months should raise the concern of health authorities.⁵⁶

Ongoing Monkeypox Outbreak in West Africa

On September 22, 2017, the Nigeria Center for Disease Control (NCDC) commenced an outbreak investigation following the identification of a suspected case of monkeypox in an 11-year-old child.⁵⁷ The data available indicate that the current outbreak is either a multisource outbreak or one stemming from previously undetected endemic transmission, because the cases were not epidemiologically linked.^{28,58–60} The exact zoonotic origin and role of environmental and ecologic factors in the Nigerian outbreak are not yet known. New cases of monkeypox continue to be detected in the country. Since the beginning of the outbreak on September 22, 2018, as of January 1, 2019 there have been 311 suspected cases reported from 26 states (132 confirmed cases affecting children and adults of all ages) and 7 deaths reported.⁶⁰ Most of the confirmed monkeypox patients are aged between 21 and 40 years, with a median age of 31 years, similar to the observed age range in DRC.⁴² It is noteworthy that all were born after 1978, when the global vaccination programs for smallpox were discontinued.

MODES OF TRANSMISSION OF MONKEYPOX VIRUS TO HUMANS

The exact mode of MPXV transmission to humans remains unknown. Primary animal-to-human infection is assumed to occur when handling monkeypox-infected animals, through direct (touch, bite, or scratch) or indirect contact, although the exact mechanism(s) remains to be defined. The virus is assumed to enter the body through broken skin, respiratory tract, or the mucous membranes (eyes, nose, or mouth). Secondary human-to-human transmission is considered common,^{37,53,61} presumably through large respiratory droplets or direct or indirect contact with body fluids, lesion material, and contaminated surfaces or other material, such as clothing or linens. Prolonged contact with patients renders hospital staff and family members at greater risk of infection. Nosocomial transmission has been described.³⁸ There is no evidence to date that human-to-human transmission alone can sustain monkeypox infections in the human population.

There have only been a few genomic studies of the origins of monkeypox outbreaks. Human-to-human transmission has been described from primary human cases and secondary cases,^{53,62,63} and serial transmission across 4 cases has been observed.⁶⁴ In the current monkeypox outbreak in Nigeria, genomic studies of monkeypox virus isolates from humans⁶⁰ indicate that the index case was not imported into Nigeria. Thus, the outbreak is considered to be a spillover from multiple sources of introduction into the human population. The zoonotic source(s) of the outbreak are being investigated at present, and it is unclear what, if any, environmental or ecologic changes might have facilitated the sudden re-emergence of monkeypox in Nigeria. Case clustering has been identified within the various states, but no epidemiologic linkages between them have been detected thus far. Three family clusters have been identified, suggesting human-to-human transmission.^{58–60} In one family the secondary attack rate was 71%. However, most patients had no obvious epidemiologic linkage or person-to-person contact, indicating a probable multiple-source outbreak or, possibly, an endemic disease previously unrecognized.

CLINICAL FEATURES

The incubation period has been estimated at 5 to 21 days, and duration of symptoms and signs at 2 to 5 weeks. The illness begins with nonspecific symptoms and signs that include fever, chills, headaches, lethargy, asthenia, lymph node swellings, back

pain, and myalgia (muscle ache) and begins with a fever before rashes appear. Within 1 to 5 days after the onset of fever, rashes of varying sizes appear, first on the face (Fig. 2), then across the body (Fig. 3), hands (Fig. 4A), and legs and feet (Fig. 4B). The rash undergoes several stages of evolution from macules, papules, vesicles (fluid-filled blisters) (see Fig. 2), and pustules (see Fig. 3B, D), followed by resolution over time with crusts and scabs (Fig. 5), which drop off on recovery. Various stages of the rash may show at the same time (see Figs. 3B and 5). Areas of erythema (see Fig. 2A) and/or skin hyperpigmentation (see Fig. 5) are often seen around discrete lesions. Detached scabs may be considerably smaller than the original lesion. Inflammation of the pharyngeal, conjunctival, and genital mucosae may also be seen.

The clinical presentation of monkeypox includes symptoms and lesions that are difficult to distinguish from smallpox.^{37,60,65,66} Although the clinical manifestations of monkeypox are milder than smallpox, the disease can prove fatal, death rates ranging from 1% to 10%. Mortality is higher among children and young adults and the course is more severe in immunocompromised individuals.⁶⁷ A range of complications has been reported, such as secondary bacterial infections, respiratory distress, bronchopneumonia, encephalitis, corneal infection with ensuing loss of vision, gastrointestinal

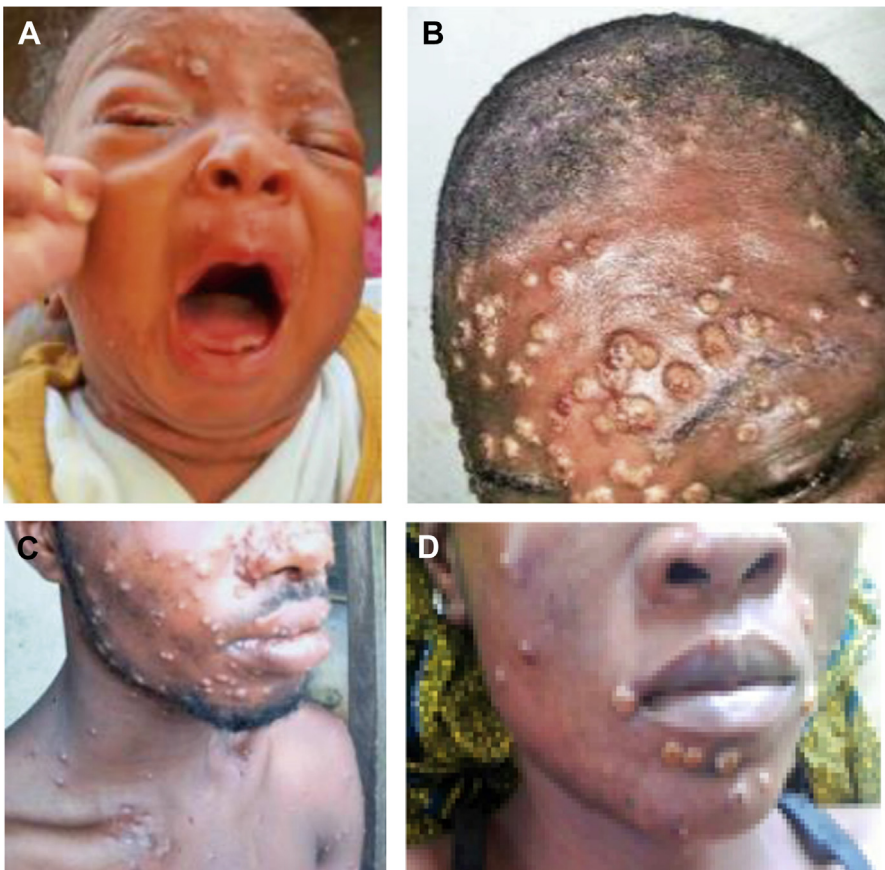

Fig. 2. (A–D) Maculo-papular-vesicular-pustular monkeypox skin lesions of varying sizes on the face. (Courtesy of Nigeria Centre for Disease Control, Abuja, Nigeria.)

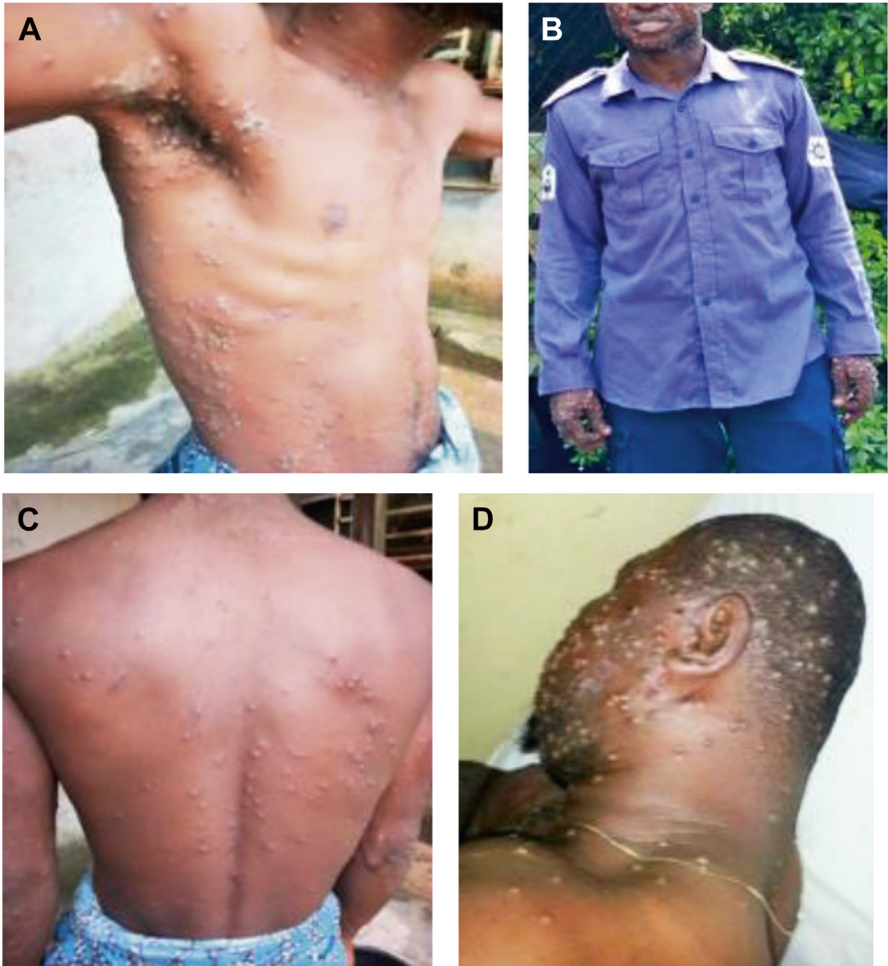

Fig. 3. (A–D) Papular-vesicular-pustular monkeypox skin lesions of varying sizes across the body. (Courtesy of Nigeria Centre for Disease Control, Abuja, Nigeria.)

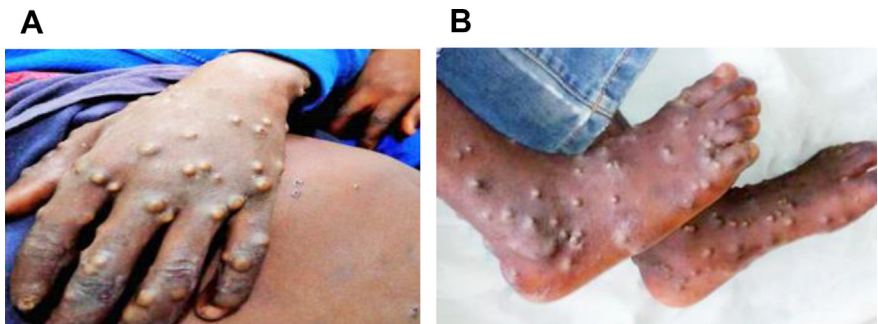


Fig. 4. (A, B) Papular-pustular monkeypox skin lesions on the hands, legs, and feet. (Courtesy of Nigeria Centre for Disease Control, Abuja, Nigeria.)

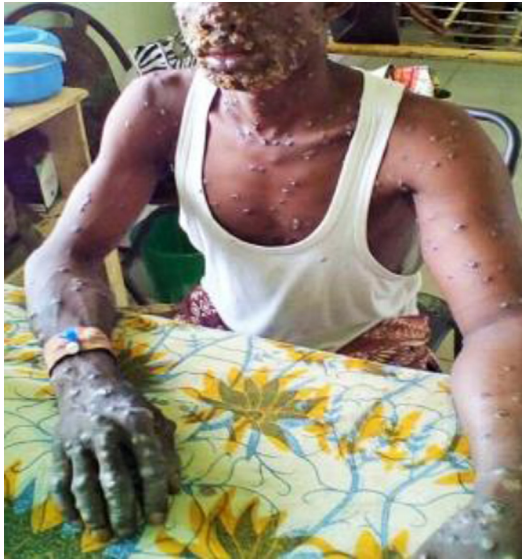

Fig. 5. Extensive papulo-pustular monkeypox rashes with crust and scar formation. (Courtesy of Nigeria Centre for Disease Control, Abuja, Nigeria.)

involvement, vomiting, and diarrhea with dehydration. Case fatality rates have varied between 1% and 10% in outbreaks, deaths occurring mostly among young adults and children. Particularly those with immunosuppression are at risk of severe disease. Lymphadenopathy is seen in up to 90% of patients and appears to be a clinical feature distinguishing human monkeypox from smallpox.

Previous smallpox vaccination confers some cross-protection against monkeypox and modifies the clinical picture toward a milder disease. Between 1980 and 1990, the clinical presentation of human monkeypox seems to have changed: primary human cases have increasingly been seen among those never vaccinated against smallpox. Compared with those vaccinated, the clinical picture described for the unvaccinated was more severe, with more vigorous and pleomorphic rashes and higher mortality.^{62,66,68–70}

The primary differential diagnosis is severe chickenpox with lesions in palms and soles.^{7,65} The lesions in chickenpox are more superficial and occur in clusters of the same stage, with denser manifestations on the trunk than on the face and extremities. Because of the nonspecific nature of the symptoms and signs of monkeypox, a wide variety of differential diagnoses should be considered, ranging from chickenpox, molluscum contagiosum, measles, rickettsial infections, bacterial skin infections (such as those caused by *Staphylococcus aureus*), anthrax, scabies, syphilis, and drug reactions to other noninfectious causes of rash. A clinical sign differentiating monkeypox from smallpox and chickenpox is the presence of enlarged lymph nodes, particularly submental, submandibular, cervical, and inguinal nodes.⁷¹

SMALLPOX VACCINATION, MONKEYPOX PREVALENCE, AND CHANGING CLINICAL PRESENTATIONS

In 1980, the Global Commission for the Certification of Smallpox Eradication (GCCSE) continued to designate monkeypox as a public health threat, recommending that the epidemiologic, ecologic, and surveillance program on monkeypox be continued.^{35,72}

In response, the WHO supported an active surveillance program for human monkeypox from 1970 to 1986.⁴⁶ It was assumed to be endemic to DRC, but other Central and West African countries also reported cases of monkeypox in humans or circulation in wildlife. At the end of the smallpox eradication campaign, the GCCSE stated that smallpox vaccination to prevent monkeypox was no longer justified, even if cross-protective immunity could not be relied on for long because of the vaccinations being discontinued. In retrospect, this resolution may have been an error.

Experimental studies of monkeys have shown immunization with smallpox vaccine to give cross-protection against monkeypox.¹⁹

Several reviews have summarized human monkeypox outbreaks over the past 38 years.^{28,29,42} Between November 2005 and November 2007, population-based surveillance studies conducted in 9 health zones in central DRC identified 760 laboratory-confirmed human monkeypox cases. The average annual cumulative incidence across the zones was 5.53 per 10,000 (2.18–14.42). Factors associated with increased risk of infection included living in forested areas, male sex, age less than 15 years, and absence of smallpox vaccination scar. Among those vaccinated, the risk of monkeypox was found to be 5.2-fold lower than among those unvaccinated (0.78 versus 4.05 per 10,000). Compared with surveillance data from the same region recorded in the 1980s, a 20-fold increase in human monkeypox incidence was observed. Between January 2001 and December 2004, the DRC Ministry of Health surveillance program reported 2734 cases of suspected human monkeypox in 11 provinces, showing an annual upward trend: 380 cases in 2001, 545 in 2002, 783 in 2003, and 1026 in 2004. Most cases (94%) were observed in children and adults younger than 25 years.⁴¹ These patients had not been vaccinated against smallpox. Surveillance activities have been halted since 2005 because of the civil war.

DIAGNOSIS: LABORATORY, VIROLOGIC, AND HISTOLOGIC FEATURES

Optimal clinical specimens for laboratory analyses include specimens from skin lesions such as swabs of vesicular lesions, exudate, or crusts stored in a dry, sterile tube (no viral transport media) and kept cold. A viral culture should be obtained by an oropharyngeal or nasopharyngeal swab. Skin biopsies of vesiculopustular rash or a sample of the roof of an intact skin vesicular lesion are valuable for analyses. Reference laboratories with high containment facilities are required to make a definitive diagnosis using electron microscopy, culture and molecular analysis identification by polymerase chain reaction, and sequencing. Serologic testing requires paired acute and convalescent sera for MPXV-specific immunoglobulin M detection within 5 days of presentation, or immunoglobulin G detection after 8 days.

Histology and immunohistochemistry of papular lesions may show acanthosis, individual keratinocyte necrosis, and basal vacuolization, along with a superficial and deep perivascular lymphohistiocytic infiltrate in the dermis. Vesicular lesions show spongiosis with reticular and ballooning degeneration, multinucleated epithelial giant cells with epidermal necrosis with numerous eosinophils and neutrophils, and features of vasculitis and viral inclusions in keratinocytes. Intracytoplasmic, round-to-oval inclusions with sausage-shaped structures centrally, measuring 200 to 300 μm , may be seen on electron microscopic observation.

TREATMENT

There is no specific treatment for monkeypox. Supportive care, symptomatic management, and treatment of secondary bacterial infections remain the main recommendations.

PREVENTION

Prevention of MPXV spread in endemic areas is highly challenging, and consists of avoiding any contact with rodents and primates as well as limiting direct exposure to blood and inadequately cooked meat. Efforts to halt bushmeat trade and consumption of wild animals are extremely difficult both culturally and economically because this meat may be the only protein source available for the poorest people. Massive health education campaigns are needed to increase general awareness and to advise on proper handling of potential animal reservoir species (gloves, protective clothing, surgical mask) as well as avoiding close contact with anyone infected.

Infection control measures are vital to prevention of human-to-human transmission in health care. Improved nursing (gloves, protective clothing, surgical masks) and isolation practices require education as well as adequate facilities and staffing.

National health authorities should consider arranging immunization against smallpox for health care workers and those treating or exposed to patients with monkeypox or their samples. Smallpox vaccination has been estimated to provide 85% cross-protection against monkeypox infection.³² The Centers for Disease Control and Prevention (CDC) recommended smallpox vaccination within 2 weeks, ideally before 4 days, after significant, unprotected exposure to a diseased animal or a confirmed human case.

During an outbreak, the spread of monkeypox virus may be controlled by quarantining (at least for 6 weeks from the date of last exposure) the infected animals and tracing their contacts. Adherence to specific instructions from the local and global public health authorities is mandatory. Increasing awareness and action (adequate decisions, medical staff, sampling, surveillance, education) both by local and international authorities are of central importance.

At hospitals in developed countries, when suspecting a case of monkeypox (eg, a patient with fever, skin lesions, and history of visiting endemic area or contact with patients), the patient should immediately be placed in a negative air pressure isolation room, or a private room if such facilities are unavailable. Standard, contact, and droplet precautions should all be taken. Infection control personnel should be contacted without delay. In developed countries, likewise, increasing awareness among health care personnel about the disease and its endemic areas is an important precaution.

VACCINES AGAINST MONKEYPOX

Although new vaccines are being developed for monkeypox, there is a need for conducting controlled clinical trials to evaluate the impact of the use of smallpox vaccines for prevention of monkeypox or modifying disease severity. Studies should focus on the cost/benefit of population-level vaccination and investigation of alternative vaccination strategies such as targeting vaccination to affected areas, contacts, and health care workers, and wider geographic areas. Currently the CDC recommends pre-exposure smallpox vaccination for field investigators, veterinarians, animal control personnel, contacts of monkeypox patients, researchers, and health care workers caring for such patients and their contacts.³

Can the Smallpox Vaccine Available Be Used to Protect Against Monkeypox?

Percutaneous inoculation with vaccinia virus elicits a broad and heterogeneous serum antibody response targeting a large number of antigenic determinants of vaccinia virus.^{73,74} The viral inhibitory activity of serum from immune subjects with cross-

neutralizing activity to vaccinia virus, MPXV, and VARV is presumably composed of antibodies with diverse specificities.^{75–77}

Production of first-generation live attenuated vaccine has been reviewed by the WHO in 1988.⁹ A considerable proportion of the population may have contraindications for the vaccine candidates: 15.2% to 15.8% of the United States population has been estimated to have potential contraindications for taking the live attenuated smallpox vaccine.⁷⁸

The rates of side effects associated with the live attenuated vaccinia virus in the United States in 1968 were 74 complications and 1 death per 1 million primary vaccinations. Morbidity and mortality rates were highest for infants, with 112 complications and 5 deaths per million primary vaccinations.⁷⁹ In 2002, the US Department of Defense resumed a program for widespread smallpox vaccinations because of a perceived threat of biological warfare. A total of 540,824 military personnel were vaccinated with a New York City Board of Health (NYCBH) strain of vaccinia, “DryVax,” from December 2002 through December 2003. Dryvax was produced by infecting the skin of calves using the NYCBH strain as seed virus. Of these, 67 (1 in 8000) developed myopericarditis.^{80,81}

The highest rate of postvaccine encephalitis (pVE) was found with the Bern strain (44.9 expected cases per million vaccines), followed by the Copenhagen strain (33.3 per million vaccines), the Lister strain (26.2 per million vaccines), and the NYCBH strain with the lowest rate (2.9 per million vaccinations).⁸²

ADDRESSING GAPS IN KNOWLEDGE AND STRENGTHENING PUBLIC HEALTH PREPAREDNESS

Most data available on monkeypox are obtained from individual case or outbreak reports, and from passive intermittent surveillance, none of which convey an accurate overall picture. The current major gaps in monkeypox knowledge, the changing epidemiologic and clinical presentations, and the multifarious factors involved in monkeypox transmission argue the need to strengthen outbreak preparedness efforts. There remains an urgent need for developing public health and surveillance capacities in Central and West Africa to guide appropriate surveillance, data collection, prevention, preparedness, and response activities to monkeypox and other emerging and re-emerging infections with epidemic potential. Advancing public health preparedness and aligning proactive surveillance activities to priority research will require coordinated, locally led, multidisciplinary efforts adjusted closely to capacity development and training.

SUMMARY

The spread of monkeypox across West Africa over the past decade and the ongoing outbreak in Nigeria indicates that it is no longer “a rare viral zoonotic disease that occurs primarily in remote parts of Central and West Africa, near tropical rainforests.” Its potential for further spread both regionally and internationally remains a major concern.^{28,29} The ecologic, zoonotic, epidemiologic, clinical, and public health aspects of monkeypox remain inadequately characterized.^{33,36,44,45} The first-generation live attenuated vaccinia virus vaccines stored for emergency purposes in many countries cannot be used because of severe adverse reactions. Discontinuing the smallpox vaccination program has created an ecologic gap whereby an increasing proportion of the population has either waning or nonexistent immunity to MPXV. This development will further increase the risk of both the animal-to-human and human-to-human spread of the virus. Therefore, priority research and surveillance should

urgently be conducted through a joint “One-Human-Animal-Environmental Health” effort across Central and West Africa.^{83–85}

ACKNOWLEDGMENTS

The authors thank the NCDC staff for providing the clinical photographs from the ongoing 2019 monkeypox outbreak in Nigeria, and the patients who gave permission to have the photos taken.

REFERENCES

1. WHO. Human monkeypox 2019. Available at: <https://www.who.int/emergencies/diseases/monkeypox/en/>. Accessed February 22, 2019.
2. WHO. Smallpox 2019. Available at: <https://www.who.int/biologicals/vaccines/smallpox/en/>. Accessed February 20, 2019.
3. CDC. Monkeypox. *MMWR Morb Mortal Wkly Rep* 2018;67:306–10.
4. Shchelkunov SN, Totmenin AV, Babkin IV, et al. Human monkeypox and smallpox viruses: genomic comparison. *FEBS Lett* 2001;509:66–70.
5. Pauli G, Blümel J, Burger R, et al. Orthopox viruses: infections in humans. *Transfus Med Hemother* 2010;37:351–64.
6. Bera BC, Shanmugasundaram K, Barua S, et al. Zoonotic cases of camelpox infection in India. *Vet Microbiol* 2011;152:29–38.
7. Cook GC, Zumla A. Chapter 47. Cutaneous viral diseases. Monkeypox. In: Cook GC, Zumla A, editors. *Manson's tropical diseases*. 22nd edition. London: Harcourt Brace Saunders, Publishing Group; 2009. p. 839–40.
8. Petersen E, Abubakar I, Ihekweazu C, et al. Monkeypox—Enhancing public health preparedness for an emerging lethal human zoonotic epidemic threat in the wake of the smallpox post-eradication era. *Int J Infect Dis* 2019;78:78–84.
9. Fenner F, Henderson DA, Arita I, et al. *Smallpox and its eradication*. Geneva (Switzerland): World Health Organisation; 1988.
10. Singh RK, Hosamani M, Balamurugan V, et al. Buffalopox: an emerging and re-emerging zoonosis. *Anim Health Res Rev* 2007;8:105–14.
11. Oliveira JS, Figueiredo PO, Costa GB, et al. Vaccinia virus natural infections in Brazil: the good, the bad, and the ugly. *Viruses* 2017;9(11) [pii:E340].
12. Hughes AL, Irausquin S, Friedman R. The evolutionary biology of poxviruses. *Infect Genet Evol* 2010;10:50–9.
13. Ichihashi Y, Oie M. Epitope mosaic on the surface proteins of orthopoxviruses. *Virology* 1988;163:133–44.
14. Stanford MM, McFadden G, Karupiah G, et al. Immunopathogenesis of poxvirus infections: forecasting the impending storm. *Immunol Cell Biol* 2007;85:93–102.
15. McConnell S, Herman YF, Mattson DE, et al. Protection of rhesus monkeys against monkeypox by vaccinia virus immunization. *Am J Vet Res* 1964;25:192–5.
16. Hammarlund E, Lewis MW, Carter SV, et al. Multiple diagnostic techniques identify previously vaccinated individuals with protective immunity against monkeypox. *Nat Med* 2005;11:1005–11.
17. Moss B. Smallpox vaccines: targets of protective immunity. *Immunol Rev* 2011; 239:8–26.
18. Gispén R, Verlinde JD, Zwart P. Histopathological and virological studies on monkeypox. *Arch Gesamte Virusforsch* 1967;21:205–16.
19. McConnell S, Hickman RL, Wooding WL Jr, et al. Monkeypox: experimental infection in chimpanzee (*Pan satyrus*) and immunization with vaccinia virus. *Am J Vet Res* 1968;29:1675–80.

20. von Magnus P, Anderson EK, Petersen KB, et al. A pox-like disease in cynomolgus monkeys. *Acta Pathol Microbiol Scand* 1959;46:156–76.
21. Doty JB, Malekani JM, Kalemba LN, et al. Assessing monkeypox virus prevalence in small mammals at the human-animal interface in the democratic Republic of the Congo. *Viruses* 2017;9(10) [pii:E283].
22. Radonić A, Metzger S, Dabrowski PW, et al. Fatal monkeypox in wild-living sooty mangabey, Côte d'Ivoire, 2012. *Emerg Infect Dis* 2014;20:1009–11.
23. Hutson CL, Lee KN, Abel J, et al. Monkeypox zoonotic associations: insights from laboratory evaluation of animals associated with the multi-state US outbreak. *Am J Trop Med Hyg* 2007;76:757–68.
24. Thomassen HA, Fuller T, Asefi-Najafabady S, et al. Pathogen-host associations and predicted range shifts of human monkeypox in response to climate change in central Africa. *PLoS One* 2013;8:e66071.
25. Prier JE, Sauer RM. A pox disease of monkeys. *Ann N Y Acad Sci* 1960;85:951–9.
26. Wenner HA, Macasaet D, Kamitsuka PS, et al. Monkeypox I. Clinical, virologic and immunologic studies. *Am J Epidemiol* 1968;87:551–66.
27. Nakoune E, Lampaert E, Ndjapou SG, et al. A nosocomial outbreak of human monkeypox in the Central African Republic. *Open Forum Infect Dis* 2017;4: ofx168.
28. Durski KN, McCollum AM, Nakazawa Y, et al. Emergence of monkeypox—West and Central Africa, 1970-2017. *MMWR Morb Mortal Wkly Rep* 2018;67:306–10.
29. Sklenovská N, Van Ranst M. Emergence of monkeypox as the most important orthopoxvirus infection in humans. *Front Public Health* 2018;6:241.
30. Quiner CA, Moses C, Monroe BP, et al. Presumptive risk factors for monkeypox in rural communities in the Democratic Republic of the Congo. *PLoS One* 2017;12: e0168664.
31. Marennikova SS, Seluhina EM, Malceva NN, et al. Isolation and properties of the causal agent of a new variola-like disease (monkeypox) in man. *Bull World Health Organ* 1972;46:599–611.
32. Fine PE, Jezek Z, Grab B, et al. The transmission potential of monkeypox virus in human populations. *Int J Epidemiol* 1988;17:643–50.
33. Heymann DL, Szczeniowski M, Esteves K. Reemergence of monkeypox in Africa: a review of the past six years. *Br Med Bull* 1998;54:693–702.
34. Breman JG, Kalisa R, Steniowski MV, et al. Human monkeypox, 1970-79. *Bull World Health Organ* 1980;58:165–82.
35. WHO. 1980 the global eradication of smallpox: final report of the Global Commission for the Certification of Smallpox Eradication. Geneva (Switzerland): World Health Organization; 1980.
36. WHO. Human monkeypox (MPX) 2018. Available at: <http://www.who.int/emergencies/diseases/monkeypox/en/>. Accessed February 22, 2019.
37. Hutin YJ, Williams RJ, Malfait P, et al. Outbreak of human monkeypox, Democratic Republic of Congo, 1996 to 1997. *Emerg Infect Dis* 2001;7:434.
38. Learned LA, Reynolds MG, Wassa DW, et al. Extended interhuman transmission of monkeypox in a hospital community in the Republic of the Congo, 2003. *Am J Trop Med Hyg* 2005;73:428–34.
39. Reynolds MG, Emerson GL, Pukuta E, et al. Detection of human monkeypox in the Republic of the Congo following intensive community education. *Am J Trop Med Hyg* 2013;88:982–5.
40. Khodakevich L, Widy-Wirski R, Arita I, et al. Monkey pox virus infection in humans in the Central African Republic. *Bull Soc Pathol Exot Filiales* 1985;78: 311–20.

41. Rimoin AW, Kitalu N, Kebela-Ilunga B, et al. Endemic human monkeypox, Democratic Republic of Congo, 2001-2004. *Emerg Infect Dis* 2007;13:934-7.
42. Rimoin AW, Mulembakani PM, Johnston SC, et al. Major increase in human monkeypox incidence 30 years after smallpox vaccination campaigns cease in the Democratic Republic of Congo. *Proc Natl Acad Sci U S A* 2010;107:16262-7.
43. Kantele A, Chickering K, Vapalahti O, et al. Emerging diseases—the monkeypox epidemic in the Democratic Republic of the Congo. *Clin Microbiol Infect* 2016;22:658-9.
44. Hoff NA, Doshi RH, Colwell B, et al. Evolution of a disease surveillance system: an increase in reporting of human monkeypox disease in the Democratic Republic of the Congo, 2001-2013. *Int J Trop Dis Health* 2017;25 [pii:IJTDH.35885].
45. Yinka-Ogunleye A, Aruna O, Ogoina D, et al. Reemergence of human Monkeypox in Nigeria, 2017. *Emerg Infect Dis* 2018;24:1149-51.
46. Jezek Z, Fenner F. Human monkeypox. Monographs in virology, vol. 17. Basel (Switzerland): Karger; 1988. p. 49. Tabel 7.
47. Formenty P, Muntasir MO, Damon I, et al. Human monkeypox outbreak cause by novel virus belonging to Congo Basin clade, Sudan, 2005. *Emerg Infect Dis* 2010;16:1539-45.
48. Centers for Disease Control and Prevention (CDC). Update: multistate outbreak of monkeypox—Illinois, Indiana, Kansas, Missouri, Ohio, and Wisconsin, 2003. *MMWR Morb Mortal Wkly Rep* 2003;52(27):642-6.
49. Centers for Disease Control and Prevention (CDC). Update: multistate outbreak of monkeypox—Illinois, Indiana, Kansas, Missouri, Ohio, and Wisconsin, 2003. *MMWR Morb Mortal Wkly Rep* 2003;52(25):589-90.
50. CDC, Centers for Disease Control and Prevention. Monkeypox in the United States. 2003 Outbreak. Available at: <https://www.cdc.gov/poxvirus/monkeypox/outbreak.html>. Accessed February 22, 2019.
51. Public Health England. Cases of monkeypox confirmed in England. Available at: <https://www.gov.uk/government/news/monkeypox-case-in-england>. Accessed March 28, 2019.
52. Vaughan A, Aarons E, Astbury J, et al. Two cases of monkeypox imported to the United Kingdom, September 2018. *Euro Surveill* 2018;23(38). <https://doi.org/10.2807/1560-7917>.
53. Jezek Z, Arita I, Mutombo M, et al. Four generations of probable person-to-person transmission of human monkeypox. *Am J Epidemiol* 1986;123:1004-12.
54. Kalthan E, Tenguere J, Ndjapou SG, et al. Investigation of an outbreak of monkeypox in an area occupied by armed groups, Central African Republic. *Med Mal Infect* 2018;48:263-8.
55. Ministry of Health, State of Israel. Monkeypox patient diagnosed. Available at: https://www.health.gov.il/English/News_and_Events/Spokespersons_Messages/Pages/12102018_1.aspx. Accessed February 19, 2019.
56. WHO. Human monkeypox in Nigeria 2018. Available at: <https://www.who.int/csr/don/05-october-2018-monkeypox-nigeria/en/>. Accessed February 22, 2019.
57. Eteng WE, Mandra A, Doty J, et al. Notes from the field: responding to an outbreak of monkeypox using the one health approach—Nigeria, 2017-2018. *MMWR Morb Mortal Wkly Rep* 2018;67:1040-1.
58. Nigeria CDC. An update of monkeypox outbreak in Nigeria 2018. Available at: <https://ncdc.gov.ng/diseases/sitreps/?cat=8&name=An%20Update%20of%20Monkeypox%20Outbreak%20in%20Nigeria>. Accessed February 22, 2019.

59. Nigeria CDC. Monkeypox 2019. Available at: <https://ncdc.gov.ng/diseases/sitreps/?cat=8&name=An%20Update%20of%20Monkeypox%20Outbreak%20in%20Nigeria>. Accessed February 22, 2019.
60. Faye O, Pratt CB, Faye M, et al. Genomic characterisation of human monkeypox virus in Nigeria. *Lancet Infect Dis* 2018;18:246.
61. Jezek Z, Grab B, Szczeniowski MV, et al. Human monkeypox: secondary attack rates. *Bull World Health Organ* 1988;66:465–70.
62. Jezek Z, Grab B, Dixon H. Stochastic model for interhuman spread of monkeypox. *Am J Epidemiol* 1987;126:1082–92.
63. Jezek Z, Szczeniowski M, Paluku KM, et al. Human monkeypox: clinical features of 282 patients. *J Infect Dis* 1987;156:293–8.
64. Nolen LD, Osadebe L, Katomba J, et al. Extended human-to-human transmission during a monkeypox outbreak in the Democratic Republic of the Congo. *Emerg Infect Dis* 2016;22:1014–21.
65. Jezek Z, Szczeniowski M, Paluku KM, et al. Human monkeypox: confusion with chickenpox. *Acta Trop* 1988;45:297–307.
66. Di Giulio DB, Eckburg PB. Human monkeypox: an emerging zoonosis. *Lancet* 2004;4:15–25.
67. Gordon SN, Cecchinato V, Andresen V, et al. Smallpox vaccine safety is dependent on T cells and not B cells. *J Infect Dis* 2011;203:1043–53.
68. Huhn GD, Bauer AM, Yorita K, et al. Clinical characteristics of human monkeypox, and risk factors for severe disease. *Clin Infect Dis* 2005;41:1742–51.
69. Damon IK. Status of human monkeypox: clinical disease, epidemiology and research. *Vaccine* 2011;29(Suppl 4):D54–9.
70. McCollum AM, Damon IK. Human monkeypox. *Clin Infect Dis* 2014;58:260–7.
71. Osadebe L, Hughes CM, Shongo Lushima R, et al. Enhancing case definitions for surveillance of human monkeypox in the Democratic Republic of Congo. *PLoS Negl Trop Dis* 2017;11:e0005857.
72. WHO. The current status of human monkeypox: memorandum from a WHO Meeting. *Bull World Health Organ* 1984;62:703–13.
73. Davies DH, Liang X, Hernandez JE al. Profiling the humoral immune response to infection by using proteome microarrays: high-throughput vaccine and diagnostic antigen discovery. *Proc Natl Acad Sci U S A* 2005;102:547–52.
74. Davies DH, Molina DM, Wrammert, et al. Proteome-wide analysis of the serological response to vaccinia and smallpox. *Proteomics* 2007;7:1678–86.
75. Hughes CM, Newman FK, Davidson WB, et al. Analysis of variola and vaccinia virus neutralization assays for smallpox vaccines. *Clin Vaccine Immunol* 2012;19:1116–8.
76. Kennedy JS, Gurwith M, Dekker CL, et al. Safety and immunogenicity of LC16m8, an attenuated smallpox vaccine in vaccinia-naïve adults. *J Infect Dis* 2011;204:1395–402.
77. Gilchuk I, Gilchuk P, Sapparapu G, et al. Cross-neutralizing and protective human antibody specificities to poxvirus infections. *Cell* 2016;167:684–94.
78. Carlin EP, Giller N, Katz R. Estimating the size of the U.S. population at risk of severe adverse events from replicating smallpox vaccine. *Public Health Nurs* 2017;34:200–9.
79. Lane JM, Ruben FL, Neff JM, et al. Complications of smallpox vaccination, 1968. *N Engl J Med* 1969;281:1201–8.
80. Eckart RE, Love SS, Atwood JE, et al, Department of Defense Smallpox Vaccination Clinical Evaluation Team. Incidence and follow-up of inflammatory

- cardiac complications after smallpox vaccination. *J Am Coll Cardiol* 2004;44:201–5.
81. Neff J, Modlin J, Birkhead GS, et al, and the Advisory Committee on Immunization. Practices; Armed Forces Epidemiological Board. Monitoring the safety of a smallpox vaccination program in the United States: report of the joint Smallpox Vaccine Safety Working Group of the advisory committee on immunization practices and the Armed Forces Epidemiological Board. *Clin Infect Dis* 2008;46(Suppl 3):258–70.
 82. Kretzschmar M, Walinga J, Teunis P, et al. Frequency of adverse events after vaccination with different vaccinia strains. *PLoS Med* 2006;3(8):e272.
 83. Bass J, Tack DM, McCollum AM, et al. Enhancing health care worker ability to detect and care for patients with monkeypox in the Democratic Republic of the Congo. *Int Health* 2013;5:237–43.
 84. Zumla A, Dar O, Kock R, et al. Taking forward a 'One Health' approach for turning the tide against the Middle East respiratory syndrome coronavirus and other zoonotic pathogens with epidemic potential. *Int J Infect Dis* 2016;47:5–9.
 85. Doshi RH, Guagliardo SAJ, Dzabatou-Babeaux A, et al. Strengthening of surveillance during monkeypox outbreak, Republic of the Congo, 2017. *Emerg Infect Dis* 2018;24:1158–60.