


## The expression and prognostic value of stem cell markers Bmi-1, HESC5:3, and HES77 in human papillomavirus–positive and –negative oropharyngeal squamous cell carcinoma

Hesham Mohamed<sup>1,2</sup>, Jaana Hagström<sup>1,3\*</sup>, Lauri Jouhi<sup>4\*</sup>, Timo Atula<sup>4</sup>, Alhadi Almangush<sup>1</sup>, Antti Mäkitie<sup>4,5,6#</sup> and Caj Haglund<sup>3,7#</sup>

### Abstract

Human papillomavirus is detected in over 50% of oropharyngeal squamous cell carcinomas. Human papillomavirus–positive oropharyngeal squamous cell carcinomas differ from human papillomavirus–negative tumors, and both expression patterns are classified as distinct entities. The Bmi-1 oncogene is a well-known member of the mammalian polycomb-group family. HESC5:3 and HES77 are newly developed monoclonal antibodies produced against undifferentiated embryonic stem cells. Our aim was to explore their roles in both human papillomavirus–positive and –negative oropharyngeal squamous cell carcinomas. Our cohort comprised 202 consecutive oropharyngeal squamous cell carcinoma patients diagnosed and treated with curative intent. We used tissue microarray tumor blocks to study the immunohistochemical expression of Bmi-1, HESC5:3, and HES77. We compared the expressions of these stem cell markers with p16 immunorexpression and human papillomavirus status, as well as with other characteristics of the tumor, and with patients' clinical data and follow-up data. Human papillomavirus– and p16–positive tumors expressed less Bmi-1 and more HESC5:3 than the negative tumors. HES77 expression was high in human papillomavirus–positive oropharyngeal squamous cell carcinoma, but it did not correlate with p16 positivity. In our multivariable model, Bmi-1 and HESC5:3 were still associated with human papillomavirus, but the association between human papillomavirus and HES77 remained absent. In conclusion, Bmi-1, HESC5:3, and HES77 may have a different role in human papillomavirus–positive and human papillomavirus–negative tumors. There was no correlation between Bmi-1, HESC5:3, and HES77 expression and survival.

### Keywords

Cancer, oropharynx, human papillomavirus, immunohistochemistry, p16

Date received: 5 September 2018; accepted: 5 March 2019

<sup>1</sup>Department of Pathology, Helsinki University Hospital, University of Helsinki, Helsinki, Finland

<sup>2</sup>Department of Histology, Omar Al-Mukhtar University, El-Beida, Libya

<sup>3</sup>Translational Cancer Medicine Research Program, Faculty of Medicine, University of Helsinki, Helsinki, Finland

<sup>4</sup>Department of Otorhinolaryngology—Head and Neck Surgery, Helsinki University Hospital and University of Helsinki, Helsinki, Finland

<sup>5</sup>Division of Ear, Nose and Throat Diseases, Department of Clinical Sciences, Intervention and Technology and Karolinska University Hospital, Karolinska Institutet, Stockholm, Sweden

<sup>6</sup>Research Programme in Systems Oncology, Faculty of Medicine, University of Helsinki, Helsinki, Finland

<sup>7</sup>Department of Surgery, Helsinki University Hospital and University of Helsinki, Helsinki, Finland

\*Shared second authorship.

#Equal contribution.

### Corresponding author:

Hesham Mohamed, Department of Pathology, Helsinki University Hospital, University of Helsinki, Haartmaninkatu 3, P.O. Box 21, FI-00014 Helsinki, Finland.

Email: hesham.mohamed@helsinki.fi



## Introduction

Oropharyngeal squamous cell carcinoma (OPSCC) is the 12th most common cancer worldwide.<sup>1</sup> Tobacco and alcohol consumption is a traditional risk factor for OPSCC.<sup>2</sup> Lately, the infection with high-risk types of human papillomavirus (HPV), particularly HPV-16, has been identified as an important cause of OPSCC.<sup>3</sup> HPV positivity is detected in 52% of tonsillar carcinomas in the UK,<sup>4</sup> in more than 60% of OPSCCs cases in the USA,<sup>5</sup> and in more than 50% in some European countries.<sup>6,7</sup> According to the latest World Health Organization (WHO) classification of head and neck tumors, HPV-positive and HPV-negative head and neck tumors represent different entities.<sup>8</sup> They behave differently, as HPV-positive head and neck squamous cell carcinomas (HNSCC) associate less with smoking and alcohol use, have a higher radiosensitivity, and have a better prognosis than HPV-negative tumors.<sup>9,10</sup> The main treatment approaches for OPSCC are surgery and radiotherapy, either separately or in combination. Definitive chemoradiotherapy is used for advanced stage disease.<sup>11</sup> Still, OPSCC mortality remains quite high, and the 5-year overall survival (OS) does not exceed 60%.<sup>12,13</sup>

The p16 gene is a well-known tumor suppressor, identified in 1993 as cyclin-dependent kinase inhibitor (CDKI),<sup>14</sup> which is encoded by a gene localized on chromosome 9p21.<sup>15</sup> Subsequently, in 1994, its tumorigenic role was confirmed for many types of cancers.<sup>15,16</sup> p16 expression associates positively with the presence of HPV16 in OPSCC cancers.<sup>17,18</sup> In addition, it has a positive prognostic value in OPSCC.<sup>18,19</sup>

Epithelial–mesenchymal transition (EMT) appears to play an important role in tumor metastasis. In EMT, epithelial cells lose their cell polarity and cell-to-cell adhesion and gain migratory and invasive properties as they become more like mesenchymal-type cancer stem cells (CSCs). These cells are thought to express specific proteins named CSC markers.<sup>20</sup> The properties and behavior of CSCs may explain the tumor recurrence following curative treatment. Moreover, a recent study has found that HPV promotes keratinocyte stem cells to become CSCs, which may be the cause of increased metastasis rate of HPV-related tumors.<sup>21</sup>

The B cell-specific Murine leukemia virus Integration site 1 (Bmi-1) oncogene is a well-known member of the mammalian polycomb-group family. It plays a significant role in self-renewal and repair in normal adult stem cells,<sup>22</sup> and it also participates in preventing cellular senescence and immortalization through activation of telomerase.<sup>22</sup> Bmi-1 is considered to act as an oncogene.<sup>23</sup> Jacobs et al.<sup>23</sup> showed that in Bmi-1-negative cells, p16ink expression appears to be upregulated, and the *in vivo* and *in vitro* results showed that Bmi-1 upregulation downregulates p16ink. Furthermore, in

leukemia, the overexpression of the Bmi-1 oncogene was found to play a role in leukemic stem cell proliferation and maintenance.<sup>24</sup> Moreover, in breast cancer, Bmi-1 appears to play a role in tumor progression and lymph node metastasis.<sup>25</sup> A recent study by our group reported a significant prognostic value of Bmi-1 expression in tongue squamous cell carcinoma.<sup>26</sup>

HESC5:3 is a novel monoclonal antibody raised against undifferentiated embryonic stem cells, although its antigen epitope has not yet been determined.<sup>27</sup> HESC5:3 was previously found to distinguish between neoplastic and non-neoplastic follicular thyroid nodules.<sup>27</sup> HES77 is another newly developed monoclonal antibody with an undetermined antigen epitope. Its target antigen is located on the cell membrane.<sup>28</sup> It is highly specific to undifferentiated human embryonic stem cells, but it loses its expression once the cells begin to differentiate.<sup>28</sup> In rectal neuroendocrine tumors, HES77 overexpression associates with a poor prognosis.<sup>28</sup>

Finding novel molecular markers could improve our understanding of the behavior of OPSCC and help to predict its response to different treatment modalities. In this study, we evaluated the expression and prognostic value of stem cell-associated markers Bmi-1, HESC5:3, and HES77, and their association with HPV and p16 status, in a cohort of 202 consecutive OPSCC patients treated with curative intent at the Helsinki University Hospital.

## Materials and methods

### Patient selection

We identified a total of 331 patients diagnosed with oropharyngeal cancer at the Department of Otorhinolaryngology—Head and Neck Surgery, Helsinki University Hospital (Helsinki, Finland) between 1 January 2000 and 31 December 2009. We excluded patients receiving palliative treatment ( $n = 44$ ), those with concurrent ( $n = 5$ ) or previously treated HNSCC ( $n = 11$ ), those with histology other than SCC or a subtype of SCC ( $n = 18$ ), and patients for whom no tumor tissue was available ( $n = 51$ ). Our final study cohort consisted of 202 patients treated with a curative intent; 130 patients underwent primary surgery, 116 of whom received post-operative oncological treatment. Definitive oncological treatment was administered to 72 patients, 11 of whom required salvage surgeries for residual disease.

### Data source from hospital records

Clinical data were collected from patient records. The median follow-up time for patients was 5 years, and all patients had a minimum follow-up of 3 years or until death. The dates and causes of death were obtained

from Statistics Finland. The patient data are described in detail in our previous publication.<sup>29</sup> Formalin-fixed and paraffin-embedded surgical tissue samples were collected from the archives of the Department of Pathology. All slides were re-evaluated by an experienced pathologist, and the cancer areas were marked on these slides.

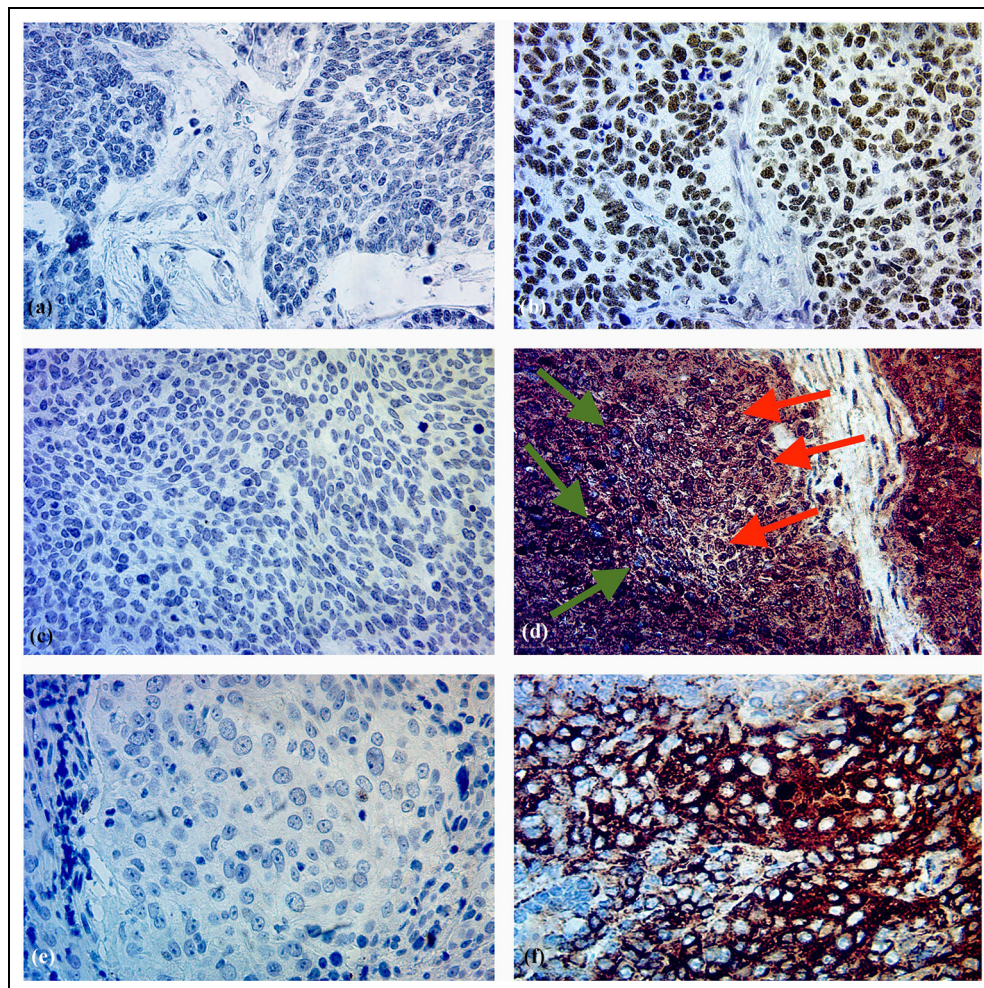
### Tissue microarray blocks

Tissue microarray (TMA) blocks were prepared from the donor paraffin blocks. From the selected cancer areas, four tumors spots were detached for each case by a 1-mm needle and placed onto a recipient paraffin block with a semi-automatic tissue microarrayer (Beecher Instruments, Silver Spring, MD, USA).<sup>30</sup>

### Immunohistochemistry

From the TMA blocks, 4- $\mu$ m thick sections were cut, deparaffinized in xylene and rehydrated through a graded alcohol series. Antigen retrieval was achieved by heating the samples in 98°C Tris-HCl buffer (pH 8.5) for 20 min in a pretreatment PT module (Lab Vision Corp., Fremont, CA, USA). The samples were then cooled to room temperature. Endogenous peroxidase was inactivated by incubating the specimens in methanol containing 1.6% hydrogen peroxidase for 30 min. The samples were treated with horse serum to block non-specific binding sites. The staining was performed with Dako Real Detection System, peroxidase DAB+, in an Autostainer 480 (Lab Vision Corp).

We used a specific primary antibody for each marker: monoclonal Bmi-1 diluted 1:400 (ab 14389;



**Figure 1.** Immunohistochemical staining pattern of Bmi-1, HES5:3, and HES77 in oropharyngeal carcinoma (OPSCC): (a) OPSCC with negative Bmi-1 expression (magnification  $\times 40$ ), (b) OPSCC with positive nuclear Bmi-1 expression (magnification  $\times 40$ ), (c) OPSCC with negative HES5:3 expression (magnification  $\times 40$ ), (d) OPSCC with positive cytoplasmic HES5:3 expression “green arrows” and nuclear HES5:3 expression “red arrows” (magnification  $\times 40$ ), (e) OPSCC with negative HES77 expression (magnification  $\times 40$ ), and (f) OPSCC with positive cytoplasmic HES77 expression (magnification  $\times 40$ ).

**Table 1.** Expression of Bmi-1, HESC5:3, and HES77 in oropharyngeal squamous cell carcinoma (n = 202).

Marker	Positive	Negative	Total	% positivity
Bmi-1	123	79	202	61
Cytoplasmic HESC5:3	136	66	202	67
Nuclear HESC5:3	6	196	202	3
HES77	88	114	202	44

Abcam, Cambridge, UK) incubated for 1 h,<sup>26</sup> HESC5:3 mAb diluted 1:300 incubated for 1 h,<sup>27</sup> and HES77 mAb diluted 1:300 incubated for 1 h.<sup>28</sup>

For Bmi-1, we used breast cancer and colon cancer tissue samples as positive controls. For HESC5:3 and HES77, we used colon cancer tissue as positive control. For each staining, the negative control was a slide without a primary antibody.

### HPV in situ hybridization and p16 immunostaining

HPV in situ hybridization and p16 immunohistochemical staining are described in detail in our previous

study by Jouhi et al. Briefly, 52% (105/202) of the tumors were HPV-positive and 48% (97/202) were HPV-negative, whereas 58% (117/202) of the tumors were p16-positive and 42% (85/202) were p16-negative.<sup>29</sup>

### Scoring

Two independent investigators (H.M. and A.A.) scored the immunopositivity of the tumor cells, and their scorings were re-evaluated by a head and neck pathologist (J.H.). In the case of a discrepancy, a consensus score was used for further analysis.

For Bmi-1, the scoring was performed as described by Häyry et al.<sup>26</sup> The staining was nuclear, and the percentage of positive tumor cells was evaluated. No positivity was graded as 0; up to 30% positive cells was scored as 1 (very low); 30–50% as 2 (low); 50–80% as 3 (moderate); and over 80% as 4 (high).

For HESC5:3, immunopositivity was scored according to Heikkilä et al.<sup>27</sup> as follows: cytoplasmic staining as 0 (negative), 1 (mild), 2 (moderate), and 3 (strong) according to the intensity. The nuclear scoring was

**Table 2.** Expression of Bmi-1, HESC5:3, and HES77 and their association with HPV and p16 in oropharyngeal squamous cell carcinoma (n = 202).

Variable	HPV positivity				P16 positivity			
	HPV+	HPV–	All	P	P16+	P16–	All	P
Bmi-1								
0	52	27	79		54	25	79	
1	22	29	51		27	24	51	
2	15	16	31		17	14	31	
3	10	13	23		13	10	23	
4	6	12	18		6	12	18	
Total	105	97	202	0.006 <sup>a</sup>	117	85	202	0.013 <sup>a</sup>
Cytoplasmic HESC5:3								
0	30	36	66		32	34	66	
1	26	32	58		31	27	58	
2	33	23	56		37	19	56	
3	16	6	22		17	5	22	
Total	105	97	202	0.016 <sup>a</sup>	117	85	202	0.006 <sup>a</sup>
Nuclear HESC5:3								
0	101	95	196		112	84	196	
1	1	2	3		2	1	3	
2	1	0	1		1	0	1	
3	2	0	2		2	0	2	
Total	105	97	202	0.247 <sup>b</sup>	117	85	202	0.183 <sup>b</sup>
HES77								
0	52	62	114		61	53	114	
1	28	25	53		31	22	53	
2	12	3	15		11	4	15	
3	11	4	15		11	4	15	
4	2	3	5		3	2	5	
Total	105	97	202	0.030 <sup>a</sup>	117	85	202	0.094 <sup>a</sup>

HPV: human papillomavirus.

<sup>a</sup>Chi-squared test with asymptotic P-value.

<sup>b</sup>Chi-squared test with exact P-value.

based on the percentage of positive tumor cells as follows: 0 = negative, 1 = low (1–35%), 2 = medium (36–75%), and 3 = high (>75%).

For HES77, the scoring was performed according Jernman et al.<sup>28</sup> based on the intensity of the cytoplasmic staining. Scores ranged from 0 to 4: 0 = negative expression, 1 = weak expression, 2 = moderate expression, 3 = strong expression, 4 = very strong expression. No nuclear HES77 positivity was detected in this study.

For all markers, the highest score of the four spots from each sample was used for further analysis.

### Statistical analysis

We used SPSS version 20.0 (SPSS Inc., Chicago, IL, USA) to analyze all data. The scoring results for the different markers were compared with clinical and pathological data. We used the chi-squared test to analyze the categorical variables with asymptotic and exact P-values when most suitable. We examined the relationship between the markers and patients' age using the Kruskal–Wallis test. Logistic regression was used to explore which variables were independently associated with HPV. The Kaplan–Meier estimate with long-rank test was used to calculate the 5-year disease-specific survival (DSS) rate and the recurrence-free survival (RFS) rate. The follow-up time refers to the period between the last treatment day and the end of follow-up period or death from disease in DSS, or the detection of OPSCC recurrence at the primary site, regional lymph nodes, or at distant sites in RFS. In the RFS analysis, we censored all events aside from recurrences. We considered a P-value of less than 0.05 as statistically significant.

## Results

### Expressions of the markers

Bmi-1 expression was nuclear and present in 61% (123/202) of the tumors. The cytoplasmic expression of HESC5:3 was seen in 67% (136/202) of the tumors, while the nuclear expression of HESC5:3 was only seen in 3% (6/202) of the tumors. HES77 expression was cytoplasmic and detected in 44% (88/202) of the tumors (Figure 1 and Table 1).

### Relationship between the markers and HPV status and p16 immunexpression

Bmi-1 was expressed in 50% (53/105) of HPV-positive and in 54% (63/117) of p16-positive tumors; and it was expressed in 72% (70/97) of HPV-negative and in 71% (60/85) of p16-negative tumors. The expression of Bmi-1 was lower in HPV- and p16-positive tumors than in HPV- and p16-negative tumors (Table 2). Low Bmi-1

**Table 3.** Multivariable logistic regression analysis for variables predicting HPV positivity in oropharyngeal squamous cell carcinoma (n = 202).

Variables	P	OR	95% CI for OR	
			Lower	Upper
Smoking				
Never	REF			
Earlier	0.052	0.172	0.029	1.018
Currently	<0.001	0.017	0.003	0.100
Bmi-1				
0	REF			
1–2	0.005	0.251	0.097	0.652
3–4	0.006	0.181	0.054	0.606
HESC5:3				
0	REF			
1–2	0.011	3.532	1.334	9.354
3	0.010	6.650	1.559	28.360
HES77				
0	REF			
1–2	0.151	1.922	0.787	4.692
3–4	0.183	2.582	0.639	10.445
cT				
T1–2	REF			
T3–4	0.543	0.773	0.337	1.773
cN				
N0	REF			
N+	0.009	5.282	1.529	18.247
Age	0.093	0.962	0.920	1.006

HPV: human papillomavirus; OR: odds ratio (for HPV positivity); CI: confidence interval; REF: reference category.

OR > 1 = a positive relation between the variable and HPV positivity; OR < 1 = a negative relation between the variable and HPV positivity; age was analyzed as a continuous variable.

expression was associated with HPV positivity also in our multivariable analysis, when the analysis was controlled for other studied markers, smoking, T class, N class, and age (Table 3).

Cytoplasmic HESC5:3 expression was found in 71% (75/105) of HPV-positive and in 73% (85/117) of p16-positive tumors and in 63% (61/97) of HPV-negative and 60% (51/85) of p16-negative tumors.

Nuclear HESC5:3 expression was seen in 4% (4/105) of HPV-positive tumors and 4% (5/117) of p16-positive tumors and in 2% (2/97) of HPV-negative and 1% (1/85) of p16-negative tumors.

The cytoplasmic expression of HESC5:3 was observed more in HPV- and p16-positive than in HPV- and p16-negative tumors, while there was no correlation between the nuclear HESC5:3 expression and HPV or p16 status (Table 2). In addition, multivariable analysis revealed that high cytoplasmic HESC5:3 expression was associated with HPV positivity (Table 3).

HES77 was expressed in 50% (53/105) of HPV-positive and 48% (56/117) of p16-positive tumors and in 36% (35/97) of HPV-negative and 38% (32/85) of p16-

**Table 4.** Expression of Bmi-1, HESC5:3, and HES77 and their association with smoking and alcohol abuse in oropharyngeal squamous cell carcinoma (n = 202).

Variable	Smoking					Alcohol use				
	Never	Ex-smoker	Regularly	All	P	No	Previously	Yes	All	P
<b>Bmi-1</b>										
0	12	17	30	59		19	10	11	40	
1	6	14	27	47		18	5	10	33	
2	4	7	19	30		10	2	10	22	
3	4	6	9	19		7	5	2	14	
4	0	5	11	16		7	2	5	14	
Total	26	49	96	171	0.192 <sup>b</sup>	61	24	38	123	0.909 <sup>b</sup>
<b>Cytoplasmic HESC5:3</b>										
0	11	14	30	55		14	5	16	35	
1	4	15	28	47		21	7	9	37	
2	6	15	29	50		18	9	10	37	
3	5	5	9	19		8	3	3	14	
Total	26	49	96	171	0.878 <sup>a</sup>	61	24	38	123	0.137 <sup>a</sup>
<b>Nuclear HESC5:3</b>										
0	25	48	93	166		57	24	38	119	
1	0	0	2	2		2	0	0	2	
2	0	1	0	1		1	0	0	1	
3	1	0	1	2		1	0	0	1	
Total	26	49	96	171	0.601 <sup>b</sup>	61	24	38	123	0.114 <sup>b</sup>
<b>HES77</b>										
0	10	27	60	97		31	16	23	70	
1	9	13	23	45		17	3	10	30	
2	0	5	6	11		6	1	1	8	
3	7	3	3	13		5	3	2	10	
4	0	1	4	5		2	1	2	5	
Total	26	49	96	171	0.036 <sup>b</sup>	61	24	38	123	0.472 <sup>b</sup>

<sup>a</sup>Chi-squared test with asymptotic P-value.

<sup>b</sup>Chi-squared test with exact P-value.

negative tumors. The expression of HES77 was observed more in HPV-positive than in HPV-negative tumors, whereas no correlation was detected between HES77 expression and p16 (Table 2). According to our multivariable model, HES77 was, however, not independently associated with HPV positivity (Table 3).

#### Correlations between markers and other clinicopathological parameters and survival

HES77 expression was significantly associated with smoking status. Among patients with HES77-negative tumors, the relative proportion of smokers and ex-smokers was higher than among those with HES77-positive tumors (Table 4).

We found no significant relation between Bmi-1, HESC5:3, and HES77 expressions and the patient's age (Bmi-1:  $p = 0.165$ ; HESC5:3-cytoplasm:  $p = 0.060$ ; HESC5:3-nuclear:  $p = 0.960$ ; HES7:  $p = 0.720$ ). We found no correlation between Bmi-1, HESC5:3, or HES77 expression and tumor extension (T class), presence of neck metastasis (N class), stage (Table 5), or survival (Figure 2).

Multivariable analysis revealed a negative relationship between smoking and HPV positivity and a positive relationship between N class and HPV positivity (Table 3).

#### Discussion

In this study, we examined the expressions of Bmi-1, a well-known stem cell marker, and two recently discovered stem cell markers HESC5:3 and HES77 in a series of 202 oropharyngeal carcinomas. To our knowledge, this is the first study to show a relationship of HESC5:3 and HES77 to HPV and p16ink expression in OPSCC. In addition, we found that HPV-positive and p16-positive tumors expressed less Bmi-1.

HPV-positive HNSCC tumors have better prognosis<sup>5,10</sup> and better response to radiotherapy than negative tumors. HPV positivity promotes cells to become CSCs and increases the formation of metastasis.<sup>21</sup> The detection of primary OPSCC, especially in the case of HPV-positive tumors, is often preceded by the detection of neck metastasis.<sup>31</sup> This agrees with our results, showing higher expression of HESC5:3 and HES77 in HPV-positive OPSCCs that tend to metastasize at an

**Table 5.** Expression of Bmi-1, HESC5:3, and HES77 and their association with clinicopathological factors in oropharyngeal squamous cell carcinoma (n = 202).

Variable	Tumor staging											
	Primary tumor (T)				Regional lymph nodes (N)				Stage			
	T1-2	T3-4	All	P	N0	N+	All	P	I-II	III-IV	All	P
<b>Bmi-1</b>												
0	39	40	79		15	64	79		9	70	79	
1	32	19	51		9	42	51		9	42	51	
2	18	13	31		4	27	31		3	28	31	
3	16	7	23		7	16	23		5	18	23	
4	9	9	18		4	14	18		4	14	18	
Total	114	88	202	0.353 <sup>a</sup>	39	163	202	0.503 <sup>a</sup>	30	172	202	0.231 <sup>b</sup>
<b>Cytoplasmic HESC5:3</b>												
0	37	29	66		9	57	66		5	61	66	
1	34	24	58		13	45	58		11	47	58	
2	31	25	56		13	43	56		11	45	56	
3	12	10	22		4	18	22		3	19	22	
Total	114	88	202	0.867 <sup>a</sup>	39	163	202	0.336 <sup>a</sup>	30	172	202	0.173 <sup>a</sup>
<b>Nuclear HESC5:3</b>												
0	110	86	196		39	157	196		30	166	196	
1	2	1	3		0	3	3		0	3	3	
2	0	1	1		0	1	1		0	1	1	
3	2	0	2		0	2	2		0	2	2	
Total	114	88	202	0.565 <sup>b</sup>	39	163	202	0.392 <sup>b</sup>	30	172	202	0.523 <sup>b</sup>
<b>HES77</b>												
0	64	50	114		18	96	114		15	99	114	
1	31	22	53		14	39	53		10	43	53	
2	9	6	15		3	12	15		3	12	15	
3	8	7	15		4	11	15		2	13	15	
4	2	3	5		0	5	5		0	5	5	
Total	114	88	202	0.732 <sup>a</sup>	39	163	202	0.611 <sup>b</sup>	30	172	202	1.000 <sup>b</sup>

<sup>a</sup>Chi-squared test with asymptotic P-value.

<sup>b</sup>Chi-squared test with exact P-value.

early stage. In addition, in our cohort, we found a positive correlation between HPV positivity and regional lymph node metastasis. We speculate that HESC5:3 and HES77 in CSCs, which are actively dividing, might involve in the positive radiosensitive response of HPV-positive OPSCCs.

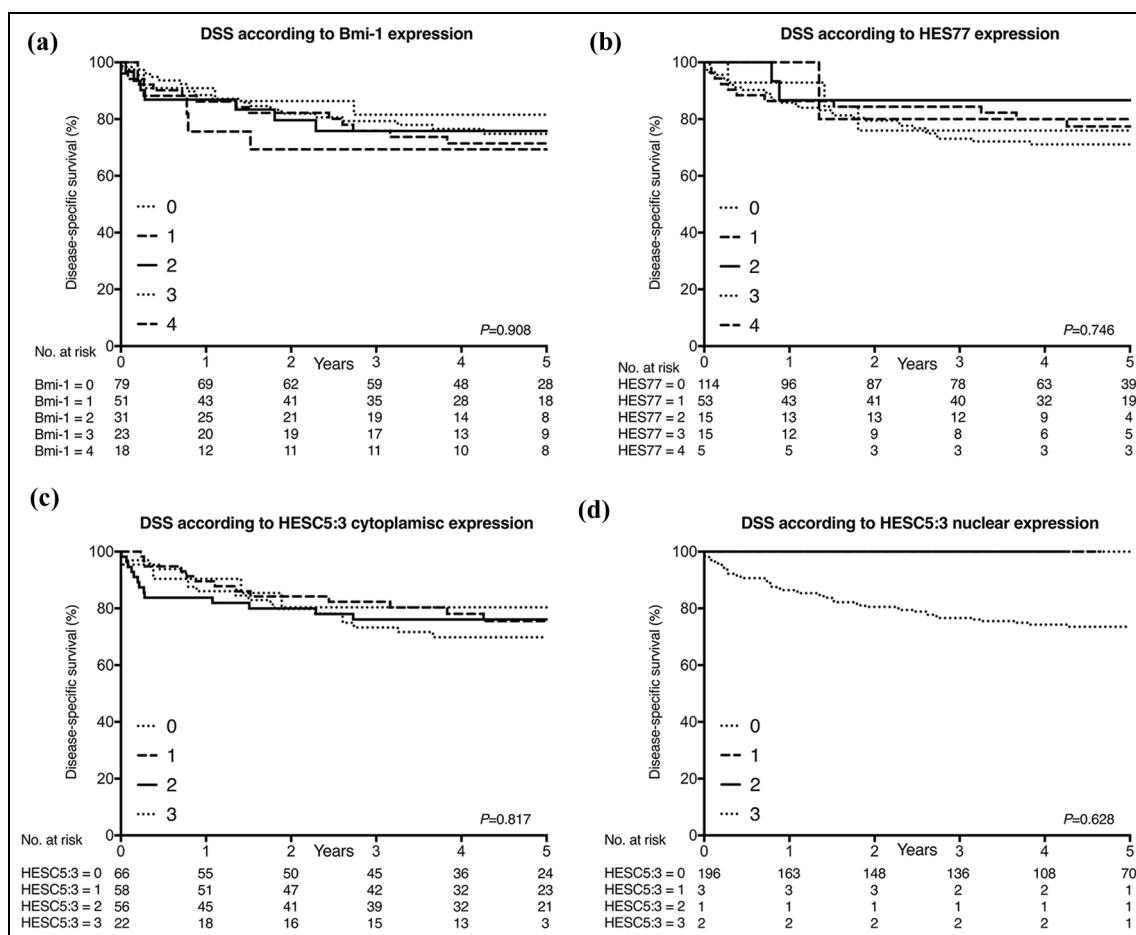
In cervical carcinoma, no correlation between Bmi-1 and HPV infection has been detected.<sup>32</sup> In contrast, in penile carcinoma, the highest Bmi-1 expression was found in HPV-negative tumors.<sup>33</sup> These results mimic our results showing that the expression of Bmi-1 was lower in HPV-positive and p16-positive OPSCC. Moreover, Bmi-1 is known to suppress p16ink expression. According to our results, HPV and p16-positivity suppressed Bmi-1 expression, suggesting a bidirectional pathway.

Tumors in older people are more often caused by tobacco smoking and alcohol use than by HPV<sup>8</sup> and are more often both p16 and HPV negative.<sup>8,34</sup> Similarly, in our cohort, most of HPV-negative tumors were diagnosed among currently smoking patients.

However, we found no association between age and HPV infection or p16 status.

In previous studies, a high Bmi-1 expression has strongly associated with a poor prognosis in oropharyngeal carcinoma<sup>19</sup> and in tongue,<sup>35</sup> cervical,<sup>32,36</sup> and urinary bladder cancer,<sup>37</sup> but contradictory results have also been reported.<sup>26</sup> HPV-positive tumors are known to have a better prognosis, and indeed, in our study, a higher Bmi-1 expression was more commonly observed in HPV-negative tumors, which are known to be more aggressive. It may be that a high Bmi-1 expression reflects the aggressiveness of the tumor. However, no correlation between its expression and patient survival was found.

HESC5:3 did not associate with prognosis in follicular thyroid cancer,<sup>27</sup> while HES77 expression has been linked to a poorer prognosis in rectal neuroendocrine tumors.<sup>28</sup> In our study, although HESC5:3 and HES77 are expressed more in HPV-positive tumors (which have better prognosis) than HPV-negative tumors, we found no correlation between the expression of HES77 or HESC5:3 and the prognosis in OPSCC.



**Figure 2.** Disease-specific survival (DSS) curve of 202 patients in relation to the expression of: (a) Bmi-1, (b) HES77, (c) cytoplasmic HESC5:3, and (d) nuclear HESC5:3.

## Conclusion

Our results show a lower Bmi-1 expression and a higher HESC5:3 expression in HPV-positive tumors than in HPV-negative tumors, while the relationship between HES77 expression and HPV status was not, statistically, confirmed. Thus, HESC5:3, HES77, and Bmi-1, may play a different role in HPV-positive and HPV-negative tumors. Further studies are needed to verify the roles of HESC5:3 and HES77 in stem cells.

## Acknowledgements

The authors wish to thank Päivi Peltokangas and Olli Sirviö for their laboratory assistance. They also extend their thanks and appreciation to Olle Nilsson and Christian Fermer (Fujirebio, Gothenburg, Sweden) for donating antibodies and for participating in this work.

## Declaration of conflicting interests

The author(s) declared no potential conflicts of interest with respect to the research, authorship, and/or publication of this article.

## Ethical approval


This study is a part of a larger research project regarding oropharyngeal cancer carried out by the Department of Otorhinolaryngology Head and Neck Surgery (HUS). Institutional review board approval was obtained from the Research Ethics Committee of Helsinki University Hospital (HUS). In addition, a hospital study permission was granted (Dnro179/13/03/02/2013). All procedures performed in the studies involving human participants were carried out in accordance with the ethical standards of the institutional and/or national research committees and adhered to the 1964 Helsinki Declaration and its later amendments or comparable ethical standards.

## Funding

The author(s) disclosed receipt of the following financial support for the research, authorship, and/or publication of this article: The study was funded by Helsinki University Hospital Research Fund study grants, the Sigrid Jusélius Foundation, Medicinska understödsföreningen Liv och Hälsa, the Finnish Dental Association, Apollonia, and the Libyan Ministry of Higher Education and Scientific Research.



**ORCID iD**

Hesham Mohamed  <https://orcid.org/0000-0002-9044-366X>

**References**

- Parkin DM, Pisani P and Ferlay J. Estimates of the worldwide incidence of 25 major cancers in 1990. *Int J Cancer* 1999; 80(6): 827–841.
- Blot WJ, McLaughlin JK, Winn DM, et al. Smoking and drinking in relation to oral and pharyngeal cancer. *Cancer Res* 1988; 48(11): 3282–3287.
- D'Souza G, Kreimer AR, Viscidi R, et al. Case-control study of human papillomavirus and oropharyngeal cancer. *N Engl J Med* 2007; 356: 1944–1956.
- Schache AG, Powell NG, Cuschieri KS, et al. HPV-related oropharynx cancer in the United Kingdom: an evolution in the understanding of disease etiology. *Cancer Res* 2016; 76: 6598–6606.
- Amini A, Jasem J, Jones BL, et al. Predictors of overall survival in human papillomavirus-associated oropharyngeal cancer using the National Cancer Data Base. *Oral Oncol* 2016; 56: 1–7.
- Laco J, Vosmikova H, Novakova V, et al. The role of high-risk human papillomavirus infection in oral and oropharyngeal squamous cell carcinoma in non-smoking and non-drinking patients: a clinicopathological and molecular study of 46 cases. *Virchows Arch* 2011; 458(2): 179–187.
- Nasman A, Attner P, Hammarstedt L, et al. Incidence of human papillomavirus (HPV) positive tonsillar carcinoma in Stockholm, Sweden: an epidemic of viral-induced carcinoma? *Int J Cancer* 2009; 125(2): 362–366.
- El-Naggar AK, Chan JKC, Grandis JR, et al. *WHO classification of head and neck tumours*. 4th ed. Lyon: IARC, 2017, pp. 134–138.
- Mellin H, Friesland S, Lewensohn R, et al. Human papillomavirus (HPV) DNA in tonsillar cancer: clinical correlates, risk of relapse, and survival. *Int J Cancer* 2000; 89(3): 300–304.
- Gillison ML, Koch WM, Capone RB, et al. Evidence for a causal association between human papillomavirus and a subset of head and neck cancers. *J Natl Cancer Inst* 2000; 92(9): 709–720.
- Mehanna H, Evans M, Beasley M, et al. Oropharyngeal cancer: United Kingdom National Multidisciplinary Guidelines. *J Laryngol Otol* 2016; 130(Suppl. 2): S90–S96.
- Wang H-M, Hsu C-L, Hsieh C-H, et al. Concurrent chemoradiotherapy using cisplatin, tegafur, and leucovorin for advanced squamous cell carcinoma of the hypopharynx and oropharynx. *Biomed J* 2014; 37(3): 133.
- Jouhi L, Halme E, Irjala H, et al. Epidemiological and treatment-related factors contribute to improved outcome of oropharyngeal squamous cell carcinoma in Finland. *Acta Oncol* 2018; 57: 541–551.
- Xiong Y, Zhang H and Beach D. Subunit rearrangement of the cyclin-dependent kinases is associated with cellular transformation. *Genes Dev* 1993; 7(8): 1572–1583.
- Kamb A, Gruis NA, Weaver-Feldhaus J, et al. A cell cycle regulator potentially involved in genesis of many tumor types. *Science* 1994; 264(5157): 436–440.
- Nobori T, Miura K, Wu DJ, et al. Deletions of the cyclin-dependent kinase-4 inhibitor gene in multiple human cancers. *Nature* 1994; 368(6473): 753–756.
- Begum S, Cao D, Gillison M, et al. Tissue distribution of human papillomavirus 16 DNA integration in patients with tonsillar carcinoma. *Clin Cancer Res* 2005; 11(16): 5694–5699.
- Saito Y, Yoshida M, Omura G, et al. Prognostic value of p16 expression irrespective of human papillomavirus status in patients with oropharyngeal carcinoma. *Jpn J Clin Oncol* 2015; 45(9): 828–836.
- Huber GF, Albinger-Hegy A, Soltermann A, et al. Expression patterns of Bmi-1 and p16 significantly correlate with overall, disease-specific, and recurrence-free survival in oropharyngeal squamous cell carcinoma. *Cancer* 2011; 117(20): 4659–4670.
- Thiery JP and Sleeman JP. Complex networks orchestrate epithelial-mesenchymal transitions. *Nat Rev Mol Cell Biol* 2006; 7(2): 131–142.
- Swanson MS, Kokot N and Sinha UK. The role of HPV in head and neck cancer stem cell formation and tumorigenesis. *Cancers* 2016; 8(2): 24.
- Siddique HR and Saleem M. Role of Bmi-1, a stem cell factor, in cancer recurrence and chemoresistance: preclinical and clinical evidences. *Stem Cells* 2012; 30(3): 372–378.
- Jacobs JJ, Kieboom K, Marino S, et al. The oncogene and polycomb-group gene Bmi-1 regulates cell proliferation and senescence through the INK4A locus. *Nature* 1999; 397(6715): 164–168.
- Lessard J and Sauvageau G. Bmi-1 determines the proliferative capacity of normal and leukaemic stem cells. *Nature* 2003; 423(6937): 255–260.
- Kim JH, Yoon SY, Jeong S-H, et al. Overexpression of Bmi-1 oncoprotein correlates with axillary lymph node metastases in invasive ductal breast cancer. *Breast* 2004; 13(5): 383–388.
- Häyry V, Mäkinen LK, Atula T, et al. Bmi-1 expression predicts prognosis in squamous cell carcinoma of the tongue. *Br J Cancer* 2010; 102(5): 892–897.
- Heikkilä A, Fermér C, Hagström J, et al. A novel stem cell associated marker identified by monoclonal antibody HESC5: 3 differentiates between neoplastic lesions in follicular thyroid neoplasms. *APMIS* 2015; 123(7): 604–612.
- Jernman J, Hagström J, Mäenpää H, et al. Expression of stem cell-associated marker HES77 in rectal neuroendocrine tumors. *Anticancer Res* 2015; 35(7): 3767–3772.
- Jouhi L, Mohamed H, Makitie A, et al. Toll-like receptor 5 and 7 expression may impact prognosis of HPV-positive oropharyngeal squamous cell carcinoma patients. *Cancer Immunol Immunother* 2017; 66: 1619–1629.
- Mäkinen LK, Häyry V, Atula T, et al. Prognostic significance of matrix metalloproteinase-2, -8, -9, and -13 in oral tongue cancer. *J Oral Pathol Med* 2012; 41(5): 394–399.
- Goldenberg D, Begum S, Westra WH, et al. Cystic lymph node metastasis in patients with head and neck cancer: an HPV-associated phenomenon. *Head Neck* 2008; 30(7): 898–903.
- Min L, Dong-Xiang S, Xiao-Tong G, et al. Clinicopathological and prognostic significance of Bmi-1 expression in

- human cervical cancer. *Acta Obstet Gynecol Scand* 2011; 90(7): 737–745.
33. Ferreux E, Lont AP, Horenblas S, et al. Evidence for at least three alternative mechanisms targeting the p16INK4A/cyclin D/Rb pathway in penile carcinoma, one of which is mediated by high-risk human papillomavirus. *J Pathol* 2003; 201(1): 109–118.
  34. Kwon H, Brasch H, Benison S, et al. Changing prevalence and treatment outcomes of patients with p16 human papillomavirus related oropharyngeal squamous cell carcinoma in New Zealand. *Br J Oral Maxillofac Surg* 2016; 54: 898–903.
  35. Li Z, Wang Y, Yuan C, et al. Oncogenic roles of Bmi-1 and its therapeutic inhibition by histone deacetylase inhibitor in tongue cancer. *Lab Invest* 2014; 94(12): 1431–1445.
  36. Tong YQ, Liu B, Zheng HY, et al. Overexpression of Bmi-1 is associated with poor prognosis in cervical cancer. *Asia Pac J Clin Oncol* 2012; 8(4): e55–e62.
  37. Qin Z-K, Yang J-A, Ye YL, et al. Expression of Bmi-1 is a prognostic marker in bladder cancer. *BMC Cancer* 2009; 9: 61.