

Intracranial hypertension and cortical thickness in syndromic craniosynostosis

ALEXANDER T WILSON^{1,2}  | BIANCA K DEN OTTELANDER¹ | ROBBIN DE GOEDEREN¹ | MARIE-LISE C VAN VEELLEN³ | MARJOLEIN H G DREMMEN⁴ | JOHN A PERSING² | HENRI A VROOMAN^{4,5} | IRENE M J MATHIJSSSEN¹

1 Department of Plastic and Reconstructive Surgery, Erasmus Medical Center, Rotterdam, the Netherlands. **2** Department of Surgery, Section of Plastic Surgery, Yale School of Medicine, New Haven, CT, USA. **3** Department of Neurological Surgery, Erasmus Medical Center, Rotterdam; **4** Department of Radiology, Erasmus Medical Center, Rotterdam; **5** Department of Medical Informatics, Erasmus Medical Center, Rotterdam, the Netherlands.

Correspondence to Alexander T Wilson, Department of Plastic and Reconstructive Surgery, Erasmus Medical Center, Wytemaweg 80, 3015 CN, Rotterdam, the Netherlands.
E-mail: a.wilson@erasmusmc.nl

PUBLICATION DATA

Accepted for publication 7th January 2020.
Published online

ABBREVIATIONS

ICH	Intracranial hypertension
OFC	Occipitofrontal circumference
OSA	Obstructive sleep apnea

AIM To evaluate the impact of risk factors for intracranial hypertension (ICH) on cerebral cortex thickness in syndromic craniosynostosis.

METHOD ICH risk factors including papilloedema, hydrocephalus, obstructive sleep apnea (OSA), cerebellar tonsillar position, occipitofrontal circumference (OFC) curve deflection, age, and sex were collected from the records of patients with syndromic craniosynostosis (Apert, Crouzon, Pfeiffer, Muenke, Saethre-Chotzen syndromes) and imaging. Magnetic resonance images were analysed and exported for statistical analysis. A linear mixed model was developed to determine correlations with cerebral cortex thickness changes.

RESULTS In total, 171 scans from 107 patients (83 males, 88 females, mean age 8y 10mo, range 1y 1mo–34y, SD 5y 9mo) were evaluated. Mean cortical thickness in this cohort was 2.78mm (SD 0.17). Previous findings of papilloedema ($p=0.036$) and of hydrocephalus ($p=0.007$) were independently associated with cortical thinning. Cortical thickness did not vary significantly by sex ($p=0.534$), syndrome ($p=0.896$), OSA ($p=0.464$), OFC ($p=0.375$), or tonsillar position ($p=0.682$).

INTERPRETATION Detection of papilloedema or hydrocephalus in syndromic craniosynostosis is associated with significant changes in cortical thickness, supporting the need for preventative rather than reactive treatment strategies.

Craniosynostosis is a congenital disease of premature fusion of calvarial sutures, which occurs in 1 to 2000 or 2500 births.¹ This results in craniocerebral disproportion and skull deformity, based on the location and number of sutures involved. Syndromic variants of the disease (most commonly Apert, Crouzon, Pfeiffer, Muenke, and Saethre-Chotzen syndromes), which are attributable to single gene mutations or chromosomal abnormalities, comprise 20% of these cases and are characterized by additional defects such as limb, ear, or midface deformities.^{1,2} Of particular concern in patients with the syndrome is the increased incidence of intracranial hypertension (ICH), which may lead to cognitive or visual impairment.^{3,4} Previous studies have demonstrated ICH prevalence in 61% to 83% of patients with the syndrome before surgery, with 35% to 47% developing recurrent ICH after a vault expansion procedure.^{4–8}

The detection of ICH is a frequent indication for surgical intervention in patients with craniosynostosis. The criterion standard method of measurement is

intraparenchymal pressure monitoring, which is too invasive for use as a screening tool. Therefore, less invasive methods are frequently utilized along with the clinical examination and history. In our centre, these include funduscopy, optical coherence tomography, and magnetic resonance imaging (MRI). Because of the complexity of the pathogenesis of ICH in these patients, further evaluation of contributing factors is often necessary and may include polysomnography to assess obstructive sleep apnea (OSA), occipitofrontal circumference (OFC) measurement to determine the risk of craniocerebral disproportion, and radiographic assessment for hydrocephalus or Chiari type I malformation.^{9,10}

It remains unclear what effects ICH may have on structural neurological development in syndromic craniosynostosis. Cortical thickness is an important in vivo biomarker for cognitive ability and may provide valuable insight regarding potential changes due to ICH.^{11–15} As a subcomponent of cortical volume, cortical thickness reflects

neuronal density per column, dendritic arborization, and glial support.¹⁶ Development of the cortex occurs rapidly during childhood and adolescence, and cortical thinning has been correlated with reductions in IQ, making it an appropriate biomarker for evaluation in patients with syndromic craniosynostosis.^{14,15,17} Understanding structural sequelae from positive clinical and imaging evaluation for ICH will better inform clinical decision making and timing of surgical intervention. The aim of this study was to evaluate the effect of ICH risk factors and markers on cortical thickness in patients with syndromic craniosynostosis.

METHOD

Participants

Medical and imaging records of all patients with syndromic craniosynostosis (Apert, Crouzon, Pfeiffer, Muenke, Saethre-Chotzen syndromes) at the Dutch Craniofacial Center (Erasmus University Medical Center) were reviewed from 2008 to 2018. All MRI studies, including a 3D T1-weighted fast spoiled gradient-echo sequence from these patients were included in the study, often resulting in multiple scans per patient; however, some of these scans were eventually excluded because of image processing failure. Children with isolated single suture synostosis were excluded. Additional clinical and demographic data were collected for further analysis. Clinical management of patients with the syndrome included scheduled vault expansion in the first year of life. Subsequent development of ICH was treated according to suspected cause (e.g. secondary vault expansion for growth restriction, continuous positive airway pressure/midface advancement for OSA). This study was approved by the institutional review board of Erasmus Medical Centre (MEC-2014-461).

Papilloedema

Patients with craniosynostosis were evaluated by fundoscopy at follow-up for evidence of papilloedema, indicating ICH.¹⁸ All patients underwent fundoscopy one day before initial vault expansion, 3 months postoperatively, biannually until the age of 4 years, and then annually until the age of 6 years. After age 6 years, fundoscopy was only performed on clinical indication. When papilloedema was detected it was followed up with confirmatory fundoscopy and imaging 4 to 6 weeks later. Patients were considered to have a finding of papilloedema as noted in the medical chart from the fundoscopic examination by an experienced paediatric ophthalmologist after clinical exclusion of pseudopapilloedema due to hypermetropia.

OSA

A diagnosis of OSA was made by clinical and ambulatory sleep studies. Polysomnography data were analysed and scored by a trained physician according to the American Academy of Sleep Medicine guideline for scoring paediatric respiratory events¹⁹ and subsequently the obstructive apnea-hypopnea index was calculated. The obstructive apnea-hypopnea index is the number of obstructive and mixed apneas and obstructive hypopneas with desaturation/

What this paper adds

- Papilloedema is associated with thinning of the cerebral cortex in syndromic craniosynostosis, independently of hydrocephalus.

arousal, divided by the total sleep time.¹⁰ Patients with an obstructive apnea-hypopnea index of 5 or more were considered to have moderate to severe sleep apnea, which may cause ICH.²⁰ Dates of the sleep studies were recorded and any history of moderate to severe OSA before the date of MRI acquisition was considered positive in our analysis.

OFC

The OFC reliably predicts intracranial volume in syndromic craniosynostosis. Therefore, OFC curve deflection is seen as a risk factor for ICH.^{9,20} OFC was manually measured preoperatively every 3 months until the age of 2 years, every 6 months until the age of 4 years, and from then annually until age 18 years. Growth curve deflection was defined as a standard deviation fall of 0.5 or more from baseline over 2 years.

Hydrocephalus

Ventricular size was manually assessed on MRI. All scans were reviewed on a 3D reformatting platform (AquariusNET; TeraRecon, Inc., Melbourne, Australia) to align scans in all planes. The size of the lateral ventricles was evaluated on axial planes using the frontal occipital horn ratio, ventricles were considered enlarged when the frontal occipital horn ratio was greater than 0.34.²¹ Hydrocephalus was considered present when ventricles were progressively enlarged on two or more consecutive MRI studies. Progressive hydrocephalus after vault expansion was treated with third ventriculostomy or ventriculoperitoneal shunting.

Cerebellum tonsillar position

The cerebellum tonsillar position was manually measured in the mid-sagittal and adjacent magnetic resonance slices at the level of the lowest observable point, as previously described.²² The level of the foramen magnum was set as 0 and measurements above this level were considered negative and those below as positive. All measurements were performed on 3D reformatting software (AquariusNET) to align scans in all planes.

MRI acquisition

All MRI was performed on a 1.5 T scanner (GE Healthcare, MR Signa Excite HD, Little Chalfont, UK) and the imaging protocol included a 3D T1-weighted fast spoiled gradient-echo magnetic resonance sequence. Imaging parameters for craniosynostosis patients were as follows: 2mm slice thickness, no slice gap; field of view 22.4cm; matrix size 224×224; in plane resolution of 1mm; echo time 3.1ms; and repetition time 9.9ms.²²

Cortical thickness

MRI dicom files were exported and converted to NIfTI-1 file format on a computer cluster with Scientific Linux

(Fermilab, Batavia, IL, USA) as the operating system and containing preloaded FreeSurfer software modules, version 6.0 (<https://surfer.nmr.mgh.harvard.edu>). FreeSurfer is a brain imaging software package, developed by the Athinoula A Martinos Center for Biomedical Imaging at Massachusetts General Hospital, for analysing MRI data. It is an important tool in functional brain mapping and facilitates the visualization of the functional regions of the highly folded cerebral cortex. FreeSurfer is a fully-automated image processing software package, which allows for surface-based registration analysis and has demonstrated some advantages over more traditional voxel-based morphometric techniques, which are prone to partial voluming effects.²³ The processing methodologies used by FreeSurfer have previously been validated and described in detail.^{24–27}

All T1-weighted scans from our cohort were processed by the FreeSurfer ‘auto-recon-all’ pipeline. The quality of the scans and surfaces generated by FreeSurfer were then inspected after pipeline for accuracy and error logs were reviewed for scans which failed to complete the pipeline. Visual inspection is common practice in studies using automated tools such as FreeSurfer, to ensure that surfaces are not including the dura or excluding entire segments of cortex due to incorrect thresholding.¹⁷ Error logs revealed uncorrectable topology errors due to excessive motion artifact or poor grey-white differentiation in younger patients. Scans which failed to complete the auto-recon-all pipeline because of excessive motion artifacts and/or poor quality, or scans which demonstrated white matter or pial surface errors, were excluded from further analysis. Vertex-wise cortical thickness estimates were then generated by the FreeSurfer package for successful scans and exported for statistical analysis.

Statistical analysis

All acquired biomarker data were imported into R statistical software, version 3.6.1, 2019 (R Core Team, Vienna, Austria) and a multivariate linear mixed model was used to account for multiple measurements, age, and sex (non-linear mixed effects package). Patient identity was the only random effect term included. Syndrome, papilloedema, OFC deflection, and hydrocephalus were all evaluated as potential interaction terms, but were not found to improve the model fit by Akaike information criterion, therefore no interaction terms were used. Necessary assumptions for linear mixed models were also evaluated. Linearity was assessed graphically, using the lattice package). Homogeneity of variance was evaluated with Levene’s test ($p=0.90$) and normal distribution of residuals was evaluated via $Q-Q$ plot, using car and stats packages. No transformation was necessary. Global cortical thickness was calculated as the average measurement between left and right hemisphere outputs from FreeSurfer and was treated as the primary outcome. All variables except for age, tonsillar position, and cortical thickness were evaluated as categorical. p -values and 95% confidence intervals were calculated for each model variable; a significance level of 0.05 was considered

in all tests. Graphs were created using the ggplot2 package with a loess smoother.

RESULTS

In total, 171 MRI scans of 107 patients with syndromic craniosynostosis were successfully processed and included for analysis (Fig. S1, online supporting information). Of those excluded, 83% were considered too young (<2y) to expect consistent grey-white matter differentiation at a level suitable for FreeSurfer analysis. The final number of scans per syndrome were as follows: Apert, 38; Crouzon, 68; Muenke, 25; Pfeiffer, 18; and Saethre-Chotzen, 22 (Table 1).

Mean global cortical thickness for the entire study population was 2.78mm (SD 0.17, range 2.34–3.25mm). Cortical thickness estimates generated by FreeSurfer were overlaid onto the pial surface of a patient with Crouzon syndrome (Fig. 1). The average age of the patients at the time of MRI was 8 years 10 months (range 1y 1mo–34y). Our model demonstrated a significant association between a historical finding of papilloedema and cortical thickness ($p=0.036$) (Fig. 2). Patients with a finding of hydrocephalus were also shown to have significantly thinner cortices ($p=0.007$). A history of OFC curve deflection ($p=0.375$), moderate to severe OSA ($p=0.464$), or tonsillar position ($p=0.682$) did not have a significant impact. Last, syndrome diagnosis and sex were both found to have non-significant influences on cortical thickness in our cohort.

DISCUSSION

In this study we evaluated the effect of various ICH risk factors on cortical thickness in syndromic craniosynostosis. Historical findings of papilloedema as well as hydrocephalus were found to result in a thinner cortex. Other factors associated with development of ICH were not correlated with

Table 1: Linear mixed model of the average global cortical thickness of 107 patients with syndromic craniosynostosis with 171 magnetic resonance imaging (MRI) scans, including repeated scans

Grouping	MRIs, <i>n</i> (%)	Mean thickness (range)	<i>p</i>
(+) Hydrocephalus	25 (14.6)	2.71 (2.34–3.22)	0.007
(+) Papilloedema	83 (48.5)	2.73 (2.34–3.22)	0.036
(+) OSA	30 (17.5)	2.79 (2.51–3.01)	0.464
(+) OFC	66 (38.6)	2.83 (2.49–3.25)	0.375
Tonsillar position	–	–	0.682
Sex	–	–	0.534
Male	83 (48.5)	2.80 (2.34–3.25)	–
Female	88 (51.5)	2.78 (2.41–3.14)	–
Syndrome	–	–	0.832
Apert	38 (22.2)	2.81 (2.52–3.13)	–
Crouzon	68 (39.8)	2.77 (2.52–3.06)	–
Muenke	25 (14.6)	2.84 (2.49–3.09)	–
Pfeiffer	18 (10.5)	2.76 (2.51–3.03)	–
Saethre-Chotzen	22 (12.9)	2.74 (2.37–3.09)	–
Age	–	–	<0.001
Total MRIs	171	2.78 (2.34–3.25)	–

Thickness values are reported in millimetres. OSA, obstructive sleep apnea; OFC, occipitofrontal circumference.

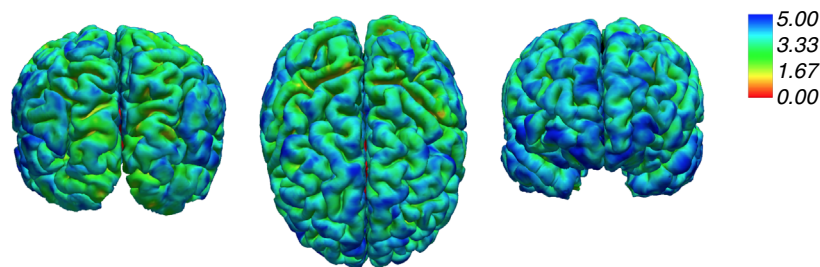


Figure 1: Cortical thickness color map overlaid on the pial surface of a 4-year-old patient with Crozon syndrome. Occipital, axial, and frontal views are shown respectively from left to right with a 0–5mm color-coded scale.

cortical thickness changes. Syndrome diagnosis, independent of other detected indicators (e.g. hydrocephalus, papilloedema), did not affect cortical thickness.

In typically developing children, natural development of the cerebral cortex results in a non-linear thinning pattern over time, with a significant increase in rate occurring during adolescence.²⁸ This process can be understood as a natural decline in thickness driven by synaptic pruning and guided by the stimulation level in critical periods of development.^{29–32} Our study demonstrates a similar cortical maturation pattern in patients with syndromic craniosynostosis, with age correlating to a thinner cortex.

In the current study, we found the presence of papilloedema to be significantly correlated with global cortical thinning in patients with syndromic craniosynostosis. Previous work by Tuite et al. demonstrated papilloedema to be a reliable tool for the diagnosis of ICH in patients with craniosynostosis, with an overall specificity of 98% but with an age-dependent sensitivity of 100% only for patients over the age of 8 years.¹⁸ Furthermore, it has been shown that papilloedema does not occur as a result of transient elevations in intracranial pressure but rather arises from prolonged exposure, leading to axoplasmic flow stasis, neuronal swelling, and extracellular fluid accumulation.³³ The necessity of prolonged ICH exposure for papilloedema detection could explain why it occurs in the context of accelerated cortical thinning and other metrics have not. By the time ICH is detectable as papilloedema, cortical neurons may have already sustained sufficient stress to result in aberrant remodeling, thereby limiting neuronal density and dendritic arborization. This process is critical to establishing normative cytoarchitecture of the cortex and disruption would explain the thinning pattern observed in this study. Furthermore, this pattern seems to mirror that of hydrocephalus, for which a causal relationship is generally accepted. It is possible that a causal relationship does exist between papilloedema and cortical thinning; however, to prove this would require successful processing of the preoperative scans in neonates, which are unavailable at present.

Our data suggest that once papilloedema is clinically observable, its association with cortical thinning will continue throughout future radiographic evaluation of these

patients, as evidenced by sustained reductions as patients age (Fig. 2). Given that structural neurological change has already occurred at the time of papilloedema detection, this calls into question whether waiting for evidence of sustained ICH exposure is the best course of action in treating these patients. Although preventative surgery does not guarantee patients will not develop ICH during the years of childhood, we feel it offers a distinct advantage by alleviating skull growth restriction during a critical period of brain development within the first year of life. An aim of this study was to demonstrate that this is an important intervention given that at the time of detection of papilloedema, cortical thinning has already occurred. Indeed, further investigation into alternative tests allowing for earlier detection and better risk stratification is warranted.

A finding of hydrocephalus was also shown to result in thinner cortices. This finding confirms previous studies demonstrating varying levels of cortical thinning and grey matter reduction according to the severity of hydrocephalus, in both children and animal models.^{34–36} The pathogenesis of hydrocephalus in craniosynostosis is thought to be multifactorial. Primary causes are often considered to be impaired cerebrospinal fluid (CSF) reabsorption, overproduction of CSF at the choroid plexus, Chiari type I malformation, and/or increased venous outflow resistance from progressive crowding of the posterior fossa, or at the level of third ventricle.³⁷ Microstructurally, this results in widespread neuronal swelling, increased extracellular space, and myelination delay.³⁸ It is not surprising, then, that the shared cellular pathology of hydrocephalus and papilloedema is reflected in similar changes to the cerebral cortex. Although patients with papilloedema may also present with hydrocephalus, we report only 18 out of 83 cases of this in our cohort. Furthermore, it is important to emphasize that hydrocephalus and papilloedema were independently associated with cortical thinning in our model after accounting for such nested effects.

Although moderate to severe OSA has been shown to confer increased risk of ICH development in craniosynostosis,^{10,39} it has not resulted in cortical thickness changes in this study. The mechanism by which OSA is thought to contribute to ICH is through hypercapnia leading to altered

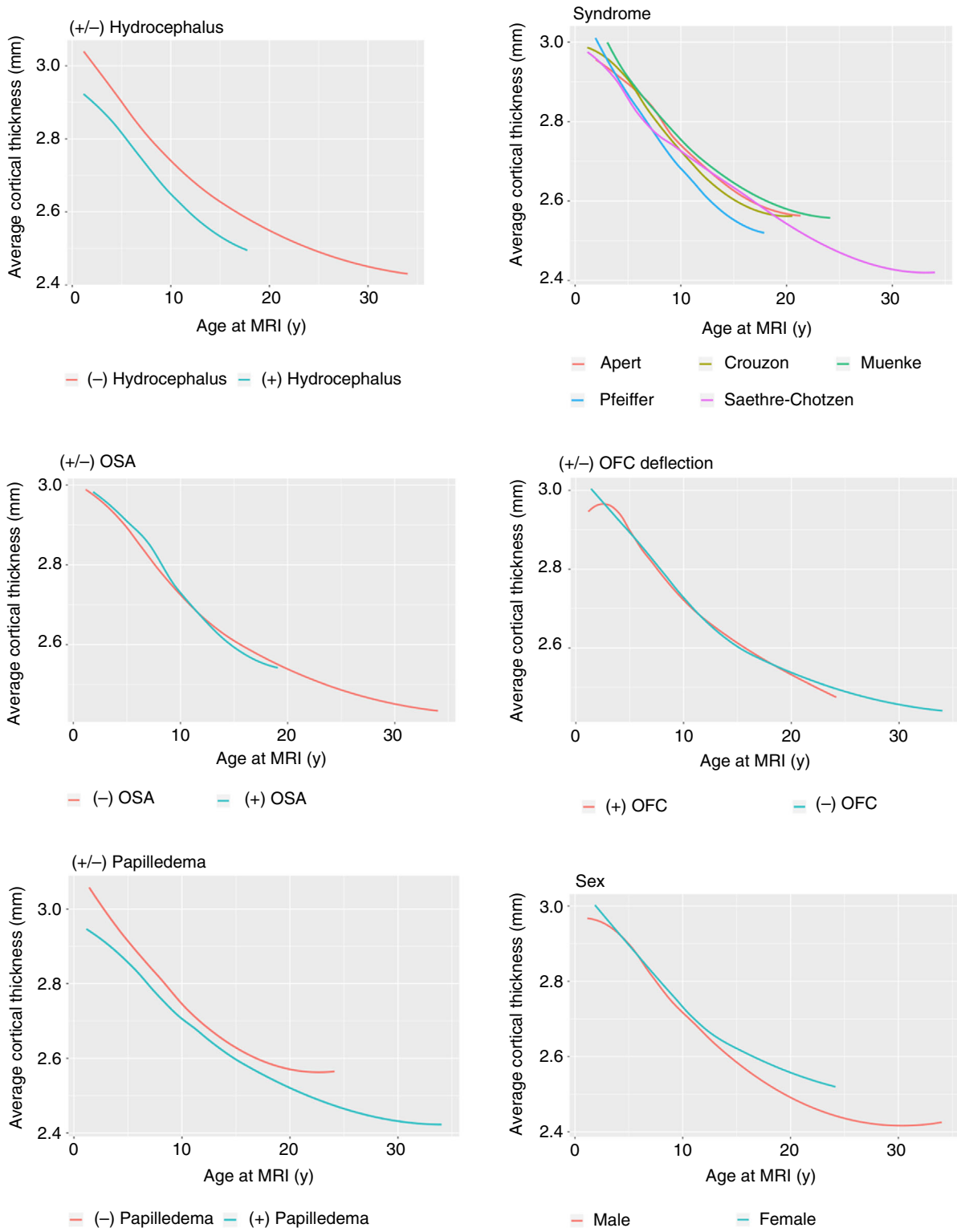


Figure 2: Effects of categorical variables on cortical thickness progression. MRI, magnetic resonance imaging; OSA, obstructive sleep apnea; OFC, occipitofrontal circumference.

cerebral hemodynamics.⁴⁰ OSA diagnosis may not be reflected in cortical changes because unlike papilloedema and hydrocephalus, it does not appear to be a sequela of longstanding ICH but rather an aetiology. Furthermore, the

duration of OSA is often limited as parents are regularly coached regarding detection of symptoms and treatment begins shortly after diagnosis. It seems prolonged exposure to ICH is necessary to induce changes in cortical thickness

and transient OSA may be insufficient to produce such an effect.

Occipitofrontal circumference measurement is a reliable proxy for intracranial volume in syndromic craniosynostosis and significant deflections in its progression have been linked to ICH development, especially in the postoperative period.^{9,41} However, we did not observe any changes in cortical thickness as a result of OFC deflection in this cohort. Skull growth restriction, as measured by OFC deflection, is one factor among others that contribute to ICH in a complex pathophysiology, which requires time to develop. Although a significant amount of time is required to develop both papilloedema and OFC curve deflection, we attribute differences in significance observed in this study to variability in what these parameters indicate. Deflection of OFC curves indicate only skull growth restriction, which is one of multiple contributors to ICH in these patients. Conversely, papilloedema reflects a state of ICH regardless of specific aetiology. Although many patients with skull growth restriction go on to develop papilloedema, it is not universally the case (32/56 patients with OFC deflection were found to have papilloedema in our cohort). This suggests that severity of ICH status, as determined by papilloedema, rather than aetiology, is more important with regard to cortical thinning.

Last, cerebellum tonsillar position did not correlate with altered cortical thickness. The association of Chiari malformation type I with craniosynostosis is well established, but the causes for descent of the tonsils may result from sustained intracranial pressure elevation or may present as syndrome-specific anomalies. Differing aetiologies of tonsillar position in our cohort could explain the lack of significance with regard to cortical thickness.

There are several limitations to our study which should be considered when interpreting our results. First, a significant portion of our data is cross-sectional, which makes

inferences concerning cortical development for patients without repeated MRI difficult. Additionally, patients who were excluded because of lack of successful thickness estimate outputs could unpredictably affect outcomes (107/147 patients were suitable for study), as a significant number may have pathology pertinent to cortical thickness development. Although excluded cases may potentially influence this analysis, an overwhelming majority (83%) of cases were too young (<2y) to expect consistent grey-white matter differentiation. Future efforts to evaluate potential differences in white matter maturation rates may shed more light on why these patients were unable to be included. Last, cortical development is a complex process which may be impacted by additional socio-economic or other factors not addressed in this study.

This study demonstrates that patients with syndromic craniosynostosis with a previous finding of papilloedema have reduced cerebral cortex thickness. This association is age-independent and is likely to be due to prolonged ICH exposure. Clinically, this supports the need for preventative rather than reactive treatment strategies. Although the effect of surgical intervention is not directly evaluated here, our craniofacial centre recommends early vault expansion during this critical period of brain development. Future studies should investigate potential changes in cortical thickness for patients who undergo a first operation at an older age, improved methods of ICH detection in younger patients, and the effect of ICH on neuropsychological development.

ACKNOWLEDGEMENTS

The authors have stated that they had no interests that might be perceived as posing a conflict or bias.

SUPPORTING INFORMATION

The following additional material may be found online:

Figure S1: Flow map of the inclusion of MRI scans.

REFERENCES

1. Johnson D, Wilkie AO. Craniosynostosis. *Eur J Hum Genet* 2011; **19**: 369–76.
2. Sharma VP, Fenwick AL, Brockop MS, et al. Mutations in TCF12, encoding a basic helix-loop-helix partner of TWIST1, are a frequent cause of coronal craniosynostosis. *Nat Genet* 2013; **45**: 304–7.
3. Christian EA, Imahiyerobo TA, Nallapa S, Urata M, McComb JG, Krieger MD. Intracranial hypertension after surgical correction for craniosynostosis: a systematic review. *Neurosurg Focus* 2015; **38**: E6.
4. Gault DT, Renier D, Marchac D, Jones BM. Intracranial pressure and intracranial volume in children with craniosynostosis. *Plas Reconstr Surg* 1992; **90**: 377–81.
5. Greene AK, Mulliken JB, Proctor MR, Meara JG, Rogers GF. Phenotypically unusual combined craniosynostoses: presentation and management. *Plas Reconstr Surg* 2008; **122**: 853–62.
6. Marucci DD, Dunaway DJ, Jones BM, Hayward RD. Raised intracranial pressure in Apert syndrome. *Plas Reconstr Surg* 2008; **122**: 1162–8.
7. Woods RH, Ul-Haq E, Wilkie AO, et al. Reoperation for intracranial hypertension in TWIST1-confirmed Saethre-Chotzen syndrome: a 15-year review. *Plas Reconstr Surg* 2009; **123**: 1801–10.
8. Abu-Sittah GS, Jeelani O, Dunaway D, Hayward R. Raised intracranial pressure in Crouzon syndrome: incidence, causes, and management. *J Neurosurg Pediatr* 2016; **17**: 469–75.
9. Rijken BF, den Ottelander BK, van Veelen ML, Lequin MH, Mathijssen IM. The occipitofrontal circumference: reliable prediction of the intracranial volume in children with syndromic and complex craniosynostosis. *Neurosurg Focus* 2015; **38**: E9.
10. Spruijt B, Mathijssen IM, Bredero-Boelhouwer HH, et al. Sleep Architecture linked to airway obstruction and intracranial hypertension in children with syndromic craniosynostosis. *Plas Reconstr Surg* 2019; **138**: 1019e–29e.
11. Steenwijk MD, Geurts JJ, Daams M, et al. Cortical atrophy patterns in multiple sclerosis are non-random and clinically relevant. *Brain* 2016; **139**: 115–26.
12. Kamson DO, Pilli VK, Asano E, et al. Cortical thickness asymmetries and surgical outcome in neocortical epilepsy. *J Neurol Sci* 2016; **368**: 97–103.
13. Romano A, Cornia R, Moraschi M, et al. Age-related cortical thickness reduction in non-demented down's syndrome subjects. *J Neuroimaging* 2016; **26**: 95–102.
14. Burgaleta M, Johnson W, Waber DP, Colom R, Karama S. Cognitive ability changes and dynamics of cortical thickness development in healthy children and adolescents. *NeuroImage* 2014; **84**: 810–9.
15. Karama S, Ad-Dab'bagh Y, Haier RJ, et al. Positive association between cognitive ability and cortical thickness in a representative US sample of healthy 6 to 18 year-olds. *Intelligence* 2009; **37**: 145–55.
16. Duncan NW, Gravel P, Wiebking C, Reader AJ, Northoff G. Grey matter density and GABAA binding potential show a positive linear relationship across cortical regions. *Neuroscience* 2013; **235**: 226–31.
17. Girault JB, Cornea E, Goldman BD, et al. Cortical structure and cognition in infants and toddlers. *Cereb*

Cortex 2019. doi: <https://doi.org/10.1093/cercor/bhz126>. [Epub ahead of print].

18. Tuite GF, Chong WK, Evanson J, et al. The effectiveness of papilledema as an indicator of raised intracranial pressure in children with craniosynostosis. *Neurosurgery* 1996; **38**: 272–8.
19. Berry RB, Budhiraja R, Gottlieb DJ, et al. Rules for scoring respiratory events in sleep: update of the 2007 AASM Manual for the Scoring of Sleep and Associated Events. Deliberations of the Sleep Apnea Definitions Task Force of the American Academy of Sleep Medicine. *J Clin Sleep Med* 2012; **8**: 597–619.
20. Spruijt B, Joosten KF, Driessen C, et al. Algorithm for the management of intracranial hypertension in children with syndromic craniosynostosis. *Plas Reconstr Surg* 2015; **136**: 331–40.
21. Rijken BF, Lequin MH, Van Veelen ML, de Rooi J, Mathijssen IM. The formation of the foramen magnum and its role in developing ventriculomegaly and Chiari I malformation in children with craniosynostosis syndromes. *J Craniomaxillofac Surg* 2015; **43**: 1042–8.
22. Rijken BF, Lequin MH, van der Lijn F, et al. The role of the posterior fossa in developing Chiari I malformation in children with craniosynostosis syndromes. *J Craniomaxillofac Surg* 2015; **43**: 813–9.
23. Clarkson MJ, Cardoso MJ, Ridgway GR, et al. A comparison of voxel and surface based cortical thickness estimation methods. *NeuroImage* 2011; **57**: 856–65.
24. Fischl B, Sereno MI, Dale AM. Cortical surface-based analysis. II: Inflation, flattening, and a surface-based coordinate system. *NeuroImage* 1999; **9**: 195–207.
25. Dale AM, Fischl B, Sereno MI. Cortical surface-based analysis. I. Segmentation and surface reconstruction. *NeuroImage* 1999; **9**: 179–94.
26. Fischl B, Dale AM. Measuring the thickness of the human cerebral cortex from magnetic resonance images. *Proc Natl Acad Sci U S A* 2000; **97**: 11050–5.
27. Cardinale F, Chinnici G, Bramerio M, et al. Validation of FreeSurfer-estimated brain cortical thickness: comparison with histologic measurements. *Neuroinformatics* 2014; **12**: 535–42.
28. Piccolo LR, Merz EC, He X, Sowell ER, Noble KG; Pediatric Imaging, Neurocognition, Genetics Study. Age-related differences in cortical thickness vary by socioeconomic status. *PLoS One* 2016; **11**: e0162511.
29. Paus T. Mapping brain maturation and cognitive development during adolescence. *Trends Cogn Sci* 2005; **9**: 60–8.
30. Hensch TK. Critical period regulation. *Ann Rev Neurosci* 2004; **27**: 549–79.
31. Knudsen EI. Sensitive periods in the development of the brain and behavior. *J Cogn Neurosci* 2004; **16**: 1412–25.
32. Petanjek Z, Judas M, Kostovic I, Uylings HB. Lifespan alterations of basal dendritic trees of pyramidal neurons in the human prefrontal cortex: a layer-specific pattern. *Cereb Cortex* 2008; **18**: 915–29.
33. Hayreh SS. Pathogenesis of optic disc edema in raised intracranial pressure. *Prog Retin Eye Res* 2016; **50**: 108–44.
34. Zhang S, Ye X, Bai G, et al. Alterations in cortical thickness and white matter integrity in mild-to-moderate communicating hydrocephalic school-aged children measured by whole-brain cortical thickness mapping and DTI. *Neural Plast* 2017; **2017**: 5167973.
35. Fletcher JM, McCauley SR, Brandt ME, et al. Regional brain tissue composition in children with hydrocephalus. Relationships with cognitive development. *Archiv Neurol* 1996; **53**: 549–57.
36. Olopade FE, Shokunbi MT, Sirén AL. The relationship between ventricular dilatation, neuropathological and neurobehavioural changes in hydrocephalic rats. *Fluids Barriers CNS* 2012; **9**: 19.
37. Collmann H, Sorensen N, Krauss J. Hydrocephalus in craniosynostosis: a review. *Child Nerv Syst* 2005; **21**: 902–12.
38. Castejon OJ. Submicroscopic pathology of human and experimental hydrocephalic cerebral cortex. *Folia Neuropathol* 2010; **48**: 159–74.
39. Inverso G, Brustowicz KA, Katz E, Padwa BL. The prevalence of obstructive sleep apnea in symptomatic patients with syndromic craniosynostosis. *Int J Oral Maxillofac Surg* 2016; **45**: 167–9.
40. Gonzalez S, Hayward R, Jones B, Lane R. Upper airway obstruction and raised intracranial pressure in children with craniosynostosis. *Eur Respir J* 1997; **10**: 367–75.
41. Breakey RWF, Knoops PGM, Borghi A, et al. Intracranial volume and head circumference in children with unoperated syndromic craniosynostosis. *Plas Reconstr Surg* 2018; **142**: 708e–17e.