

Cutaneous mucormycosis*

Ana Daniela Castrejón-Pérez¹
Ivett Miranda¹
Oliverio Welsh¹

Esperanza C. Welsh¹
Jorge Ocampo-Candiani¹

DOI: <http://dx.doi.org/10.1590/abd1806-4841.20176614>

Abstract: Cutaneous mucormycosis is an emerging fungal infection caused by opportunistic fungi of the phylum Glomeromycota. It is frequent in poorly controlled diabetic patients and individuals with immunosuppression. It is usually acquired by direct inoculation through trauma. The clinical presentation is nonspecific, but an indurated plaque that rapidly evolves to necrosis is a common finding. Diagnosis should be confirmed by demonstration of the etiological agent and new molecular diagnostic tools have recently been described. It is an invasive life-threatening disease and in order to improve survival, a prompt diagnosis and multidisciplinary management should be provided. The treatment of choice is amphotericin B, but new azoles, such as posaconazole and isavuconazole, must be considered.

Keywords: Mucormycosis; Mucorales; Mucor; Zygomycosis; Rhizopus

INTRODUCTION

Mucormycosis is an invasive fungal infection caused by opportunistic fungi of the phylum Glomeromycota, subphylum Mucormycotina. It usually affects poorly controlled diabetic patients and individuals with immunosuppression. Frequent clinical presentations include rhinocerebral, pulmonary and cutaneous forms, and less frequently, gastrointestinal, disseminated, and miscellaneous forms. This review will focus on cutaneous mucormycosis.

EPIDEMIOLOGY

In developed countries, patients with allogeneic hematopoietic stem cell transplantations and other hematologic malignancies frequently present mucormycosis.¹⁻³ In contrast, in developing countries, uncontrolled diabetes mellitus is the main associated disease.⁴

Its global incidence is unknown; however, in Spain the incidence was 0.43 cases per million per year in 2005. In France, between 1997 and 2006, an increase from 0.7 to 1.2 cases per million was found, mainly in patients with hematologic malignancies and bone marrow transplantation.¹ In the United States of America, there are no extensive prospective reports. In reports from the state of California, incidence was 1.7 cases per million per year.⁵

Zygomycetes are ubiquitous in nature and are usually isolated from decaying organic matter, soil, wood, cotton, bread, fruits, vegetables, and animal excreta.^{3,6} Primary cutaneous mucormycosis is often acquired by direct inoculation, contaminated dressings, sur-

gery, burns, motor vehicle accidents, and insulin injection sites.^{1,7,8} There are reports of outbreaks of mucormycosis in healthcare centers due to contaminated adhesive tape, wooden tongue depressors, ostomy bags, and building construction contamination. Other reports have associated this fungus with vascular devices and nitroglycerine patches.^{7,9-11} In a review of 196 cases of healthcare-associated mucormycosis, 57% involved the skin. Predominant populations were premature infants, surgical patients, and immunocompromised hosts.⁹

According to the largest review of reported cases, the age of presentation ranges from months to 87 years with a mean of 38 years. It is more frequent in men with a ratio of 1.1:1.^{1, 2-12}

The classic major risk factors are uncontrolled diabetes and ketoacidosis, but more recently, hematological malignancies and allogeneic hematopoietic stem cell transplantation have become more frequent. Other underlying conditions are solid organ transplantation, deferoxamine therapy, drug injections, renal failure, infant low birth weight, malnutrition, HIV infection, systemic lupus erythematosus, burns, trauma, aplastic anemia, and steroid use.^{1,2,7}

Mucormycosis can also occur in patients with no predisposing factors. According to Roden *et al*,¹³ in 50% of cases of cutaneous mucormycosis, there is no underlying condition; in another review, 40% of patients were immunocompetent.⁷

Received on 16.10.2016.

Approved by the Advisory Board and accepted for publication on 14.02.2017.

* Study conducted at the Universidad Autonoma de Nuevo Leon, Facultad de Medicina, Hospital Universitario Dr. Jose Eleuterio Gonzalez, Department of Dermatology - Monterrey, Mexico.

Financial support: none.

Conflict of interest: none.

¹ Department of Dermatology, Universidad Autonoma de Nuevo Leon, School of Medicine, University Hospital Dr. Jose Eleuterio Gonzalez - Monterrey, Mexico.

ETIOPATHOGENESIS

The fungi responsible for mucormycosis, also called zygomycosis, were previously classified in the class Zygomycetes, order Mucorales. Zygomycetes also include the order Entomophthorales, which are responsible for entomophthoramyosis. Recently, molecular phylogenetic analyses have found that Zygomycota are polyphyletic, and these fungi have been placed in the new monophyletic phylum called Glomeromycota, with the subphyla Mucormycotina and Entomophthoromycotina. In this context, the names "mucormycosis" and "entomophthoramyosis" should be preferred, and zygomycosis should be dismissed.¹³

Most clinical isolates belong to the genera *Rhizopus*. In reviews of cutaneous mucormycosis, the most frequent isolated strains are *Rhizopus oryzae*, *Lichtheimia corymbifera* and *Apophysomyces elegans*. Other isolates reported are *Mucor* sp, *Saksenaia vasiformis*, *Cunninghamella bertholletiae*, *Rhizomucor* spp, and *Rhizopus microsporus*.^{6, 7-14} In Mexico, there is a case report of a new species called *Apophysomyces mexicanus*.¹⁵

CLINICAL ASPECTS

Cutaneous mucormycosis can be classified as primary and secondary. In primary disease, the skin is infected by direct inoculation and in secondary form, by dissemination from other locations, more commonly from a rhinocerebral infection.³ It can be subcategorized according to the pattern of infection as localized, deep, or disseminated. In a review of 929 cases, 176 patients presented with skin involvement. Most of these cases remained localized to the total depth of the skin, with 24% showing extension to bone or muscle, and 20% developing hematogenous dissemination to other noncontiguous organs.¹

The most affected areas of the skin are the arms and legs. Other locations include the scalp, face, thorax, back, abdomen, perineum, breast, neck and gluteal area.^{7,10,16,17}

Primary cutaneous mucormycosis may be gradual in onset or fulminant. The clinical presentation varies. Initially, lesions are indurated plaques that are erythematous to purple. These become necrotic with an erythematous halo that can develop into an eschar.^{3, 14} Other presentations include targetoid lesions, tender nodules, ulcers, purpuric lesions, and swollen and scaly plaques (Figures 1 and 2).^{8,18-24} In patients with surgical wound infections and burns it often appears as cellulitis and necrosis.^{10,25}

In nosocomial infections, erythema and tenderness that rapidly evolves to necrosis is often found. In some cases, cutaneous lesions resemble contact dermatitis, which progresses to ulceration with necrosis or necrotic exophytic tissue.¹¹ The presence of a fistulous tract from skin to liver allograft has been reported.²⁶

Primary cutaneous mucormycosis by *R. variabilis* in immunocompetent hosts was reported in China and Japan. Unlike other mucorales, these presented as chronic infections.²⁷ These skin lesions were infiltrated plaques, ulcers and nodules, which usually remained localized and gradually expanded over months and years.²¹⁻²³

Secondary cutaneous mucormycosis usually results from a rhinocerebral or disseminated infection and is more frequent than primary disease. It has an acute onset and a high mortality. The disease usually starts as sinusitis and the most common cutaneous

finding is a necrotic eschar (Figures 3 and 4).^{3,28} The patients can also have oral involvement with necrotic, black or white ulcers (Figure 5). Other signs are fever, periorbital cellulitis, periorbital edema, ophthalmoplegia, proptosis, loss of vision, and other neurological deficits.^{29,30} The disease can be divided into three clinical stages: stage I, with signs and symptoms limited to the sino-nasal area; stage II, which is characterized by a sino-orbital infection; and stage III, which has intracranial involvement.³⁰

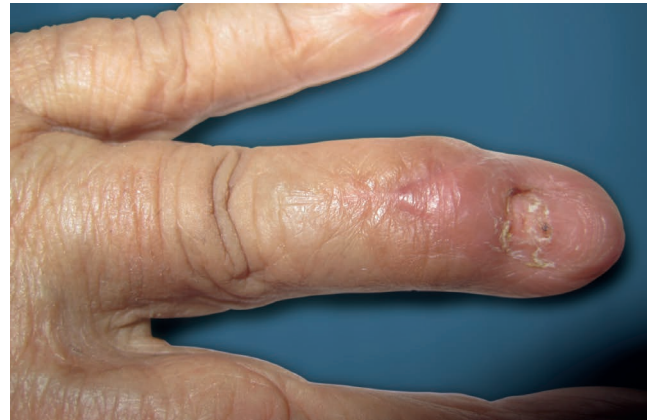

FIGURE 1: Cutaneous lesion of mucormycosis

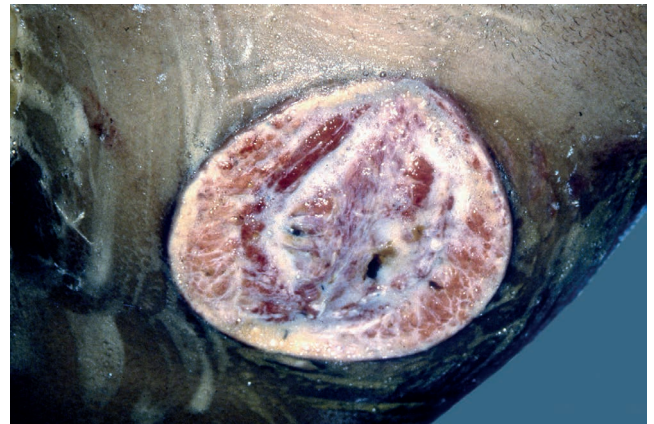


FIGURE 2: Cutaneous lesion of mucormycosis

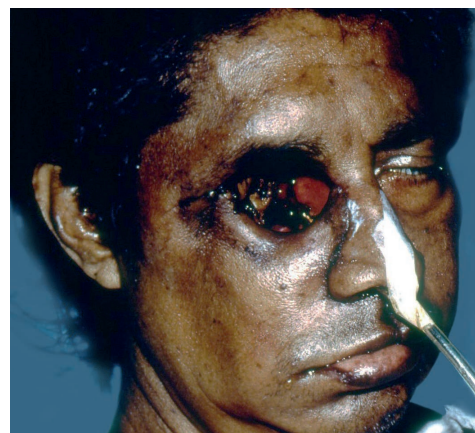

FIGURE 3: Ulceration with necrotic tissue in the eyelid with involvement of the eye

DIFFERENTIAL DIAGNOSIS

Primary cutaneous mucormycosis should be differentiated from aspergillosis and synergistic gangrene caused by bacterial infections. When targetoid lesions appear, the differential diagnoses include autoimmune disorders, drug reactions, infections, infiltra-

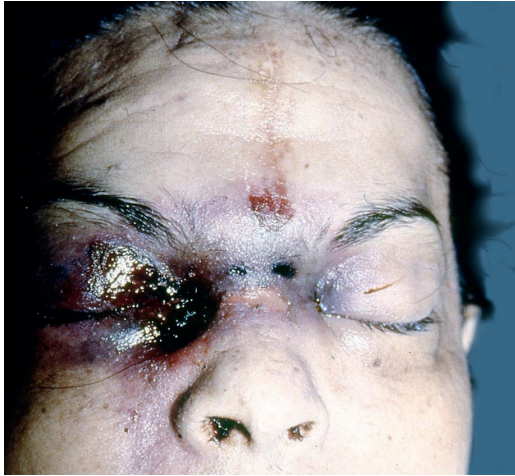

FIGURE 4: Necrotic eschar and edema of the right eyelid

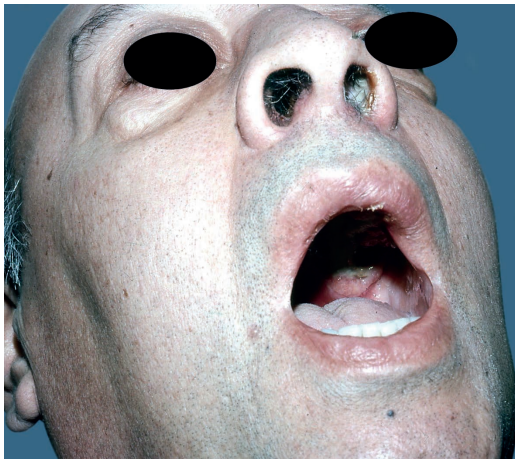

FIGURE 5: Ulceration of the soft palate

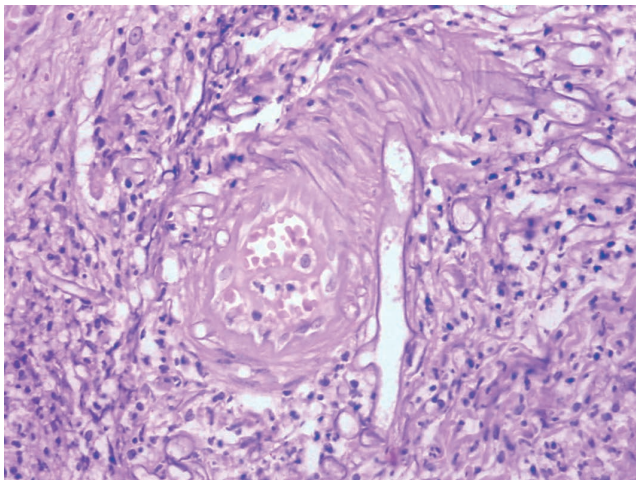


FIGURE 6: Skin biopsy that shows hyphae (Hematoxylin & eosin, X40)

tive diseases, and neoplastic disorders. In some cases, it can mimic tinea corporis or pyoderma gangrenosum.^{3,18,31}

In secondary mucormycosis with rhinocerebral involvement, the differential diagnoses include centrofacial lymphomas, rhinoscleromas, sinusitis, anaerobic infection, and aspergillosis.³

DIAGNOSIS

The clinical findings of cutaneous mucormycosis are non-specific. Early identification of the fungus is essential to establish prompt antifungal treatment. Early detection can be achieved by direct KOH microscopic examination, observing the presence of non-septated, hyaline, hyphae, 5µm wide and 20 to 50µm long, with irregular branching at right angles, mainly at the periphery of the lesion. Impression smears from the wound edges may also be useful.³

Fungal cultures are positive in 50% of cases, but in recent reviews there has been a clear increase in culture positivity from 72% to 89% in cutaneous locations.^{1,6,7} Cultures must be performed in Sabouraud and potato dextrose agar media, avoiding media with antibiotics that inhibit fungus growth.³

A biopsy and molecular diagnostic tests should be performed. The biopsy should be taken from the center of the lesion, including subcutaneous fat. Histology is more useful in primary cutaneous mucormycosis. Common findings are edema, thrombosis, infarctions, necrosis and an inflammatory reaction that includes polymorphonuclear cells, plasma cells, and eosinophils. Thick, hyaline, nonseptated and bifurcated hyphae may be seen with hematoxylin and eosin stain but are best visualized with periodic acid-Schiff and Grocott (Figure 6). Most of the microscopic features are nonspecific and a differential diagnosis with other filamentous fungi must be entertained.^{3,6}

New molecular diagnostic tools have been developed to provide precise identification of the fungus. Still, this technology is not available for most patients. These tests target the 18S ribosomal DNA and are highly specific with no cross-reactivity with other filamentous fungi.³²⁻³⁵

Real-time PCR provides identification of *Mucorales* in tissue samples and clinical isolates with high specificity. Nevertheless, more sensitivity has been reported in fresh frozen specimens than in formalin-fixed paraffin-embedded tissues.^{36,37} Bernal-Martinez *et al.*³⁸ developed a single tube multiplex real-time PCR to detect the genus *Mucor*, *R. oryzae* and *R. microsporus* from clinical and culture isolates. This method has 100% specificity, and provides results in 2 to 3 hours. Other techniques described are real-time PCR followed by high resolution meta-analysis and rolling circle amplification for the ITS region of ribosomal DNA.^{34,39} However, most of the studies are retrospective and with small samples.

TREATMENT

A multidisciplinary approach is necessary to improve survival in cutaneous mucormycosis. This should include extensive surgical debridement, antifungal therapy, correction of the underlying metabolic or impaired immunological status, and control of other concomitant infections (Table 1).

The antifungal of choice is deoxycolate amphotericin B (d-AmB); however, it is often substituted by lipid formulations be-

TABLE 1: Treatment of mucormycosis

Antifungal therapy		Non pharmacologic treatments	
AmB deoxycholate	IV	Standard dose 0.25 - 0.75mg/kg/ per day Severe cases 1.0 - 1.5mg/kg/ per day	Control underlying conditions Surgery of soft tissue rhino-orbito-cerebral disease
Liposomal AmB	IV	5 - 10mg/kg/ per day	
AmB Lipid complex	IV	5 - 7.5mg/kg/ per day	
Posaconazole	PO	400mg bid	
Isavuconazole	PO, IV	200mg tid for 6 doses, then 200mg qd	

AmB, Amphotericin B; PO, by mouth; IV, intravenous

cause of their better safety profile.⁴⁰ They are also less nephrotoxic allowing longer treatment periods with higher doses. Some studies have shown that amphotericin B (AmB) is the most active drug against mucorales clinical isolates, revealing MICs of ≤ 1 $\mu\text{g}/\text{mL}$ in the majority of the tested strains.⁴¹ In immunocompromised patients, the recommended doses for d-AmB are 1-1.5mg/kg/day, for liposomal amphotericin B (L-AmB), 5-10mg/kg/day, and for amphotericin B lipid complex 5 mg/kg/day. Increasing the dose does not achieve higher plasma levels. In order to increase the survival rate, treatment must be started in the first 5 days after clinical diagnosis. Improvement of comorbidities is imperative.^{26,42} The duration of therapy is unclear. Some authors recommend continuing AmB until clinical and radiological resolution, others recommend 6 to 8 weeks.^{42,43} Sometimes this is not possible because of intolerance, often secondary to renal failure.

Azole derivatives have exhibited variable activity against Mucorales in susceptibility *in vitro* essays. Posaconazole, followed by isavuconazole, is the most active; itraconazole has limited activity, and voriconazole is not active.^{41,44-46}

Posaconazole has been described as second-line therapy in mucormycosis.^{47,48} Several retrospective studies with this antifungal drug have reported good results. Mostly, this triazole was used in patients with failure or intolerance to AmB. The advantages of the oral formulation is that it allows earlier patient discharge and decreases relapse with prolonged administration.^{49,50} In a single prospective study of 21 patients refractory or intolerant to AmB, a good response was reported with posaconazole, with the exception of patients with disseminated disease.⁵¹ Posaconazole is recommended as second-line treatment for patients with refractory disease or intolerance to AmB or for those who need prolonged treatment maintenance. The suggested dose is 400mg bid, and in most reported cases therapy is provided for several months.⁵²

Isavuconazole is a new azole recently approved for treatment of invasive mucormycosis in the United States.⁵³ It has a safety profile similar to fluconazole with IV and oral formulations available.⁵⁴ There are three reported cases of immunocompromised patients with pulmonary, rhinocerebral, and disseminated mucormycosis refractory to AmB and posaconazole but treated successfully with isavuconazole.⁵⁵⁻⁵⁷ Recently a multicenter, clinical, single arm, open-label trial was conducted, including 34 patients with invasive mucormycosis. These

patients were treated with isavuconazole for a median of 84 days. At the end of treatment, 5 patients presented complete response, 6, partial response, 10, stable disease, and 15, disease progression. There was an analysis using matched historical controls treated with AmB that showed no difference in mortality. The most frequent adverse event were gastrointestinal symptoms, but less than 10% of the patients presented liver enzyme disturbances.⁵⁸

Monotherapy with amphotericin is first-line treatment. There are reports and preclinical data on the use of combinations of different antifungals but there is a lack of clinical studies to support this claim. If necessary, a lipid formulation of AmB should be the primary antifungal, combined with caspofungin or posaconazole.⁵⁹

There is a report on the use of frozen sections to help the pathologist and surgeon define the final surgical margins during surgical debridement of the affected tissue.⁶⁰

PROGNOSIS

The overall mortality of all mucormycosis variants has improved from 84% in the 1950s to 47% in the 1990s, mostly because of treatment with AmB. The overall mortality of cutaneous mucormycosis is less than other presentations of mucormycosis, and in three case series it ranged from 25% to 31%. In localized cutaneous mucormycosis, mortality ranged from 4% to 10%, and in deep extension presentations, it ranged from 26% to 43%. In the largest case series, the mortality rate for disseminated disease was 83%;¹ however, in recent reports it ranges from 26% to 50%.^{1,6,7}

Roden *et al.*¹ performed a multivariate regression analysis of risk factors for mortality in mucormycosis and found some significant mortality risk factors that included disseminated disease, renal failure, and infection due to *Cunninghamella* species. The use of antifungal therapy and surgical treatment, with no underlying condition or type 1 diabetes mellitus was associated with a significant decrease in mortality.^{1, 6, 7} In the experience of a Mexican center, where most cases are associated to uncontrolled diabetes mellitus and metabolic acidosis, the mortality rate was 85% in patients with extensive palpebral disease and with a Glasgow Coma Scale lower than 6.³

CONCLUSIONS

Mucormycosis is an emerging invasive fungal disease that requires a high level of clinical skill for a prompt clinical diagnosis

in order to improve survival. Where available, new molecular tests should be used to expedite diagnosis. First-line therapy is amphotericin B combined with surgery; second generation azoles derivatives can also be used. Controlling underlying conditions is also an important aspect of therapy. □

ACKNOWLEDGEMENTS

The authors would like to acknowledge Dr. Sergio Lozano, Dr. Kaylie del Bosque, and Veronica Camacho for his critical review of this manuscript.

This research did not receive any specific grant from funding agencies in the public, commercial, or not-for-profit sectors.

REFERENCES

- Roden MM, Zaoutis TE, Buchanan WL, Knudsen TA, Sarkisova TA, Schaufele RL, et al. Epidemiology and outcome of zygomycosis: a review of 929 reported cases. *Clin Infect Dis*. 2005;41:634-53.
- Skiada A, Pagano L, Groll A, Zimmerli S, Dupont B, Lagrou K, et al Zygomycosis in Europe: analysis of 230 cases accrued by the registry of the European Confederation of Medical Mycology (ECMM) Working Group on Zygomycosis between 2005 and 2007. *Clin Microbiol Infect*. 2011;17:1859-67.
- Bonifaz A, Vázquez-González D, Tirado-Sánchez A, Ponce-Olivera RM. Cutaneous zygomycosis. *Clin Dermatol*. 2012;30:413-9.
- Llata E, Blossom DB, Khoury HJ, Rao CY, Wannemuehler KA, Noble-Wang J, et al. A cluster of mucormycosis infections in hematology patients : challenges in investigation and control of invasive mold infections. *DiaDiagn Microbiol Infect Dis*. 2011;71:72-80.
- Rees JR, Pinner RW, Hajjeh RA, Brandt ME, Reingold AL.. The epidemiological features of invasive mycotic infections in the San Francisco Bay area, 1992-1993: results of population-based laboratory active surveillance. *Clin Infect Dis*. 1998;27:1138-47.
- Skiada A, Rigopoulos D, Larios G, Petrikos G, Katsambas A. Global epidemiology of cutaneous zygomycosis. *Clin Dermatol*. 2012;30:628-32.
- Skiada A, Petrikos G. Cutaneous zygomycosis. *Clin Microbiol Infect*. 2009;15:41-5
- Chambers C, Reyes M, Fung M, Huntley A, Sharon V. Primary cutaneous mucormycosis at sites of insulin injection. *J Am Dermatology* 2011;64(5):e79-81. Doi: 10.1016/j.jaad.2010.07.012.
- Rammaert B, Lanternier F, Zahar JR, Dannaoui E, Bougnoux ME, Lecuit M, et al. Healthcare-Associated Mucormycosis. *Clin Infect Dis*. 2012;54:S44-54.
- Simbli M, Hakim F, Koudieh M, Tleyjeh IM. Nosocomial post-traumatic cutaneous mucormycosis : A systematic review. *Scand J Infect Dis*. 2008;40:577-82.
- Lalayanni C, Baliakas P, Xochelli A, Apostolou C, Arabatzis M, Velegraki A, et al. Outbreak of cutaneous zygomycosis associated with the use of adhesive tape in haematology patients. *J Hosp Infect*. 2012;81:213-5.
- Bitar D, Van Cauteren D, Lanternier F, Dannaoui E, Che D, Dromer F, et al. Increasing Incidence of Zygomycosis (Mucormycosis), France, 1997-2006. *Emerg Infect Dis*. 2009;15:1395-401.
- Kwon-Chung KJ. Taxonomy of fungi causing mucormycosis and entomophthoromycosis (zygomycosis) and nomenclature of the disease: Molecular mycologic perspectives. *Clin Infect Dis*. 2012;54:S8-S15.
- Page AV, Evans AJ, Snell L, Liles WC. Primary cutaneous mucormycosis in a lung transplant recipient : case report and concise review of the literature. *Transpl Infect Dis*. 2008;10:419-25
- Bonifaz A, Stchigel AM, Guarro J, Guevara E, Pintos L, Sanchis M, et al. Primary cutaneous mucormycosis produced by the new species *Apophysomyces mexicanus*. *J Clin Microbiol*. 2014;52:4428-31.
- Thapar VK, Deshpande A, Jain VK, Bhowate P, Madiwale C. Isolated breast mucormycosis. *J Postgrad Med*. 2006;52:134-5.
- Tehmeena W, Hussain W, Zargar HR, Sheikh AR, Iqbal S. Primary cutaneous mucormycosis in an immunocompetent host. *Mycopathologia*. 2007;164:197-9.
- Rubin AI, Grossman ME. A bedside diagnosis confirmed by touch preparation. *J Am Acad Dermatol*. 2004;51:996-1001.
- Gadadhar H, Hawkins S, Huffstutter JE, Panda M. Cutaneous mucormycosis complicating methotrexate, prednisone, and infliximab therapy. *J Clin Rheumatol*. 2007;13:361-2
- Arnáiz-García ME, Alonso-Peña D, González-Vela Mdel C, García-Palomo JD, Sanz-Giménez-Rico JR, Arnáiz-García AM. Cutaneous mucormycosis : report of five cases and review of the literature. *J Plast Reconstr Aesthet Surg*. 2009;62:e434-41.
- Tomita H, Muroi E, Takenaka M, Nishimoto K, Kakeya H, Ohno H, et al. Rhizomucor variabilis infection in human cutaneous mucormycosis. *Clin Exp Dermatol*. 2011;36:312-4.
- Xia XJ, Shen H, Liu ZH. Primary cutaneous mucormycosis caused by *Mucor irregularis*. *Clin Exp Dermatol*. 2015;40:875-8.
- Matsudate Y, Muraok K, Urano Y, Yarita K, Kamei K, Takeichi H, et al. Primary cutaneous mucormycosis caused by *Mucor irregularis* in an immunocompetent patient *J Dermatol*. 2015;42:267-8.
- de Oliveira-Neto MP, Da Silva M, Fialho Monteiro PC, Lazera M, de Almeida Paes R, Novellino AB, et al. Cutaneous mucormycosis in a young, immunocompetent girl. *Med Mycol*. 2006;44:567-70.
- Tilak R, Raina P, Gupta SK, Tilak V, Prakash P, Gulati AK. Cutaneous zygomycosis : A possible postoperative complication in immunocompetent individuals Indian *J Dermatol Venereol Leprol*. 2009;75:596-9.
- Almyroudou NG, Sutton DA, Linden P, Rinaldi MG, Fung J, Kusne S. Zygomycosis in solid organ transplant recipients in a tertiary transplant center and review of the literature. *Am J Transplant*. 2006 Oct;6(10):2365-74
- Lu XL, Liu ZH, Shen YN, She XD, Lu GX, Zhan P, et al. Primary Cutaneous Zygomycosis Caused by *Rhizomucor variabilis* : A New Endemic Zygomycosis ? A Case Report and Review of 6 Cases Reported from China. *Clin Infect Dis*. 2009;49:e39-43.
- Petrikos G, Skiada A, Sambatakou H, Toskas A, Vaiopoulos G, Giannopoulou M, et al. Mucormycosis : Ten-Year Experience at a Tertiary-Care Center in Greece. *Eur J Clin Microbiol Infect Dis*. 2003;22:753-6.
- Kursun E, Turunc T, Demiroglu YZ, Alişkan HE, Arslan AH. Evaluation of 28 cases of mucormycosis. *Mycoses*. 2015;58:82-7.
- Chakrabarti A, Chatterjee SS, Das A, Panda N, Shivaprakash MR, Kaur A, et al. Invasive zygomycosis in India : experience in a tertiary care hospital. *Postgrad Med J*. 2009;85:573-81.
- Kerr OA, Bong C, Wallis C, Tidman MJ. Primary cutaneous mucormycosis masquerading as pyoderma gangrenosum. *Br J Dermatol*. 2004;150:1212-3.
- Hammond SP, Bialek R, Milner DA, Petschnigg EM, Baden LR, Marty FM. Molecular Methods To Improve Diagnosis and Identification of Mucormycosis. *J Clin Microbiol*. 2011;49:2151-3.
- Millon L, Larosa F, Lepiller Q, Legrand F, Rocchi S, Daguindau E, Scherer E, et al. Quantitative Polymerase Chain Reaction Detection of Circulating DNA in Serum for Early Diagnosis of Mucormycosis in Immunocompromised Patients. *Clin Infect Dis*. 2013;56:e95-101.
- Hrncirova K, Lengerova M, Kocmanova I, Racil Z, Volfova P, Palousova D, et al. Rapid Detection and Identification of Mucormycetes from Culture and

- Tissue Samples by Use of High-Resolution Melt Analysis Rapid Detection and Identification of Mucormycetes from Culture and Tissue Samples by Use of High-Resolution Melt Analysis. *J Clin Microbiol*. 2010;48:3392-4
35. Rickerts V, Just-Nübling G, Konrad F, Kern J, Lambrecht E, Böhme A, et al. Diagnosis of invasive aspergillosis and mucormycosis in immunocompromised patients by seminested PCR assay of tissue samples. *Eur J Clin Microbiol Infect Dis*. 2006;25:8-13.
 36. Hata DJ, Buckwalter SP, Pritt BS, Roberts GD, Wengenack NL. Real-Time PCR Method for Detection of Zygomycetes. *J Clin Microbiol*. 2008;46:2353-8.
 37. Dannaoui E, Schwarz P, Slany M, Loeffler J, Jorde AT, Cuenca-Estrella M, et al. Molecular Detection and Identification of Zygomycetes Species from Paraffin-Embedded Tissues in a Murine Model of Disseminated Zygomycosis: a Collaborative European Society of Clinical Microbiology and Infectious Diseases (ESCMID) Fungal Infection Stud. *J Clin Microbiol*. 2010;48:2043-6.
 38. Bernal-Martínez L, Buitrago MJ, Castelli MV, Rodríguez-Tudela JL, Cuenca-Estrella M. Development of a single tube multiplex real-time PCR to detect the most clinically relevant Mucormycetes species. *Clin Microbiol Infect*. 2013;19:E1-7.
 39. Dolatabadi S, Najafzadeh MJ, de Hoog GS. Rapid screening for human-pathogenic Mucorales using rolling circle amplification. *Mycoses*. 2014;57:67-72.
 40. Shoham S, Magill SS, Merz WG, Gonzalez C, Seibel N, Buchanan WL, et al. Primary treatment of zygomycosis with liposomal amphotericin B: analysis of 28 cases. *Med Mycol*. 2010;48:511-7.
 41. Chowdhary A, Kathuria S, Singh PK, Sharma B, Dolatabadi S, Hagen F, et al. Molecular characterization and in vitro antifungal susceptibility of 80 clinical isolates of mucormycetes in Delhi, India. *Mycoses*. 2014 Dec;57 Suppl 3:97-107.
 42. Blyth CC, Gilroy NM, Guy SD, Chambers ST, Cheong EY, Gottlieb T, et al. Consensus guidelines for the treatment of invasive mould infections in haematological malignancy and haemopoietic stem cell transplantation, 2014. *Intern Med J*. 2014;44:1333-49.
 43. Skiada A, Lanternier F, Groll AH, Pagano L, Zimmerli S, Herbrecht R, et al. Diagnosis and treatment of mucormycosis in patients with hematological malignancies: Guidelines from the 3rd European Conference on Infections in Leukemia (ECIL 3). *Haematologica*. 2013;98:492-504.
 44. Arikan S, Sancak B, Alp S, Hascelik G, McNicholas P. Comparative in vitro activities of posaconazole, voriconazole, itraconazole, and amphotericin B against *Aspergillus* and *Rhizopus*, and synergy testing for *Rhizopus*. *Med Mycol*. 2008;46:567-73.
 45. Kondori N, Svensson E, Mattsby-Baltzer I. In vitro susceptibility of filamentous fungi to itraconazole, voriconazole and posaconazole by Clinical and Laboratory Standards Institute reference method and E-test. *Mycoses*. 2011;54:e318-22.
 46. Guinea J, Peláez T, Recio S, Torres-Narbona M, Bouza E. In Vitro Antifungal Activities of Isavuconazole (BAL4815), Voriconazole, and Fluconazole against 1,007 Isolates of Zygomycete, *Candida*. *Antimicrob Agents Chemother*. 2008;52:1396-400.
 47. Tarani L, Costantino F, Notheis G, Wintergerst U, Venditti M, Di Biasi C, et al. Long-term posaconazole treatment and follow-up of rhino-orbital-cerebral mucormycosis in a diabetic girl. *Pediatr Diabetes*. 2009;10:289-93.
 48. Peel T, Daffy J, Thursky K, Stanley P, Buising K. Posaconazole as first line treatment for disseminated zygomycosis. *Mycoses*. 2008;51:542-5.
 49. Cornely OA, Vehreschild JJ, Rüppling MJ. Current experience in treating invasive zygomycosis with posaconazole. *Treatment Options for Zygomycosis*. *Clin Microbiol Infect*. 2009;15:77-81.
 50. Abboud CS, Bergamasco MD, Baía CE, Lallée MP, Zan AS, Zamorano MM, et al. Case Report of Hepatic Mucormycosis After Liver Transplantation: Successful Treatment With Liposomal Amphotericin B Followed by Posaconazole Sequential Therapy. *Transplant Proc*. 2012;44:2501-2.
 51. Greenberg RN, Mullane K, van Burik JA, Raad I, Abzug MJ, Anstead G, et al. Posaconazole as Salvage Therapy for Zygomycosis. *Antimicrob Agents Chemother*. 2006;50:126-33.
 52. van Burik JA, Hare RS, Solomon HF, Corrado ML, Kontoyiannis DP. Posaconazole Is Effective as Salvage Therapy in Zygomycosis: A Retrospective Summary of 91 Cases. *Clin Infect Dis*. 2006;42:e61-5.
 53. McCormack PL. Isavuconazonium: First Global Approval. *Drugs*. 2015;75:817-22.
 54. Falci DR, Pasqualotto AC. Profile of isavuconazole and its potential in the treatment of severe invasive fungal infections. *Infect Drug Resist*. 2013;6:163-74.
 55. Graves B, Morrissey CO, Wei A, Coutsovvelis J, Ellis S, Pham A, et al. Isavuconazole as salvage therapy for mucormycosis. *Med Mycol Case Rep*. 2016;11:36-9.
 56. Ervens J, Ghannoum M, Graf B, Schwartz S. Successful isavuconazole salvage therapy in a patient with invasive mucormycosis. *Infection*. 2014;42:429-32.
 57. Peixoto D, Gagne LS, Hammond SP, Gilmore ET, Joyce AC, Soiffer RJ, et al. Isavuconazole Treatment of a Patient with Disseminated. *J Clin Microbiol J Clin Microbiol*. 2014;52:1016-9.
 58. Marty FM, Ostrosky-Zeichner L, Cornely OA, Mullane KM, Perfect JR, Thompson GR 3rd, et al. Isavuconazole treatment for mucormycosis: a single-arm open-label trial and case-control analysis. *Lancet Infect Dis*. 2016;16:828-37.
 59. Candoni A, Aversa F, Busca A, Cesaro S, Girmenia C, Luppi M, et al. Combination antifungal therapy for invasive mould diseases in haematologic patients: An update on clinical data. *J Chemother*. 2015;27:1-12.
 60. Zimmermann N, Hagen MC, Schragar JJ, Hebbeler-Clark RS, Masineni S. Utility of frozen section analysis for fungal organisms in soft tissue wound debridement margin determination. *Diagn Pathol*. 2015;10:188.

MAILING ADDRESS:

Oliverio Welsh

Av. Madero y Gonzalitos, Colonia Mitras Centro

Monterrey

Nuevo Leon

Mexico C.P. 64460

Email: owelsh@yahoo.com

How to cite this article: Castrejon-Perez A, Welsh EC, Miranda I, Ocampo-Candiani J, Welsh O. Cutaneous mucormycosis. *An Bras Dermatol*. 2017;92(3):304-11.

QUESTIONS

1- In primary cutaneous mucormycosis the disease is most frequently acquired by:

- a. Direct inoculation.
- b. Trauma.
- c. Contaminated dressings.
- d. Surgery.

2- Recently, in developed countries, an emerging risk factor for cutaneous mucormycosis is:

- a. Allogenic hematopoietic stem cell transplantation.
- b. Diabetes Mellitus.
- c. HIV infection.
- d. Aplastic anemia.

3- Which is the most common species isolated in cutaneous mucormycosis?

- a. *Rhizopus oryzae*.
- b. *Lichtheimia corymbifera*.
- c. *Apophysomyces elegans*.
- d. *Rhizopus microsporus*.

4- In uncontrolled diabetic patients with secondary cutaneous mucormycosis it is frequent to find:

- a. Pulmonary mucormycosis.
- b. Rhinocerebral infection.
- c. Gastrointestinal disease.
- d. Miscellaneous mucormycosis.

5- In China, an emerging form of chronic infection with an indolent course has been reported. The etiological agent related to this variety is:

- a. *Rhizopus oryzae*.
- b. *Lichtheimia corymbifera*.
- c. *Apophysomyces elegans*.
- d. *Rhizomucor variabilis*.

6- The targeted region of DNA used in molecular diagnostic tools is:

- a. Mitochondrial DNA.
- b. 30S ribosomal DNA.
- c. 18S ribosomal DNA.
- d. Gene encoding a ferulic acid esterase.

7- The *in vitro* tests have showed that the most active antifungal is:

- a. Isavuconazole.
- b. Posaconazole.
- c. Caspofungin.
- d. Amphotericin B.

8- Which of the following factors is not associated with a higher rate of mortality?

- a. Disseminated disease.
- b. Stem cell receptor.
- c. Renal failure.
- d. Infection due to *Cunninghamella species*.

9- Which of the following factors is not associated with a significant increase in survival?

- a. Use of antifungal therapy.
- b. Surgical treatment.
- c. Having no underlying condition.
- d. Use of filgrastim.

10- Which of the following antifungals has good *in vitro* activity?

- a. Posaconazole.
- b. Echinocandins.
- c. Terbinafine.
- d. Itraconazole.

11- In which group of patients is it uncommon to find mucormycosis?

- a. Premature infants.
- b. Surgical patients.
- c. Atopic patients.
- d. HIV patients.

12- In cutaneous primary mucormycosis, extension of the infection usually involves:

- a. Only superficial skin.
- b. Total depth of the skin.
- c. Muscle extension.
- d. Bone extension.

13- What is the first clinical manifestation of rhinocerebral mucormycosis?

- a. Sinusitis.
- b. Periorbital edema.
- c. Ophthalmoplegia.
- d. Proptosis.

14- Which is the initial lesion of primary cutaneous mucormycosis?

- a. Targetoid lesions.
- b. Erythematous plaque.
- c. Tender nodules.
- d. Ulcers.

15- Which is the main differential diagnosis of primary cutaneous mucormycosis?

- a. Lymphoma.
- b. Rhinoscleroma.
- c. Drug reaction.

d. Aspergillosis.

16- Which is the clinical stage of a patient with mucormycosis affecting the sino-orbital area?

- a. Stage I.
- b. Stage II.
- c. Stage III.
- d. Stage IV.

17- What would you expect to observe in a direct KOH microscopic examination of the skin lesions?

- a. Septated hyphae with acute angle or dichotomous branches.
- b. Blastoconidial cells forming branched chains of pseudo-hyphae.
- c. Thick-walled spherules filled with endospores.
- d. Non-septated hyphae with right-angle branches.

18- Which of the following antifungals can be used as a strategy for early discharge of the patient?

- a. Posaconazole.
- b. Voriconazole.
- c. Terbinafine.
- d. Itraconazole.

19- Which phylum does mucormycosis fungus belong to?

- a. Chytridiomycota.
- b. Glomeromycota.
- c. Neoclimastigomycota.
- d. Blastocladiomycota.

20- Which is the gold standard for diagnosing mucormycosis?

- a. PCR.
- b. Skin biopsy.
- c. Culture.
- d. KOH microscopic examination.

Answer key

Melanoma: tumor microenvironment and new treatments . An Bras Dermatol. 2017;92(2):156-66

1.B	6.D	11.D	16.C
2.D	7.B	12.C	17.B
3.B	8.D	13.C	18.C
4.C	9.A	14.B	19.C
5.D	10.D	15.A	20.D

Papers

Information for all members: The EMC-D questionnaire is now available at the homepage of the Brazilian Annals of Dermatology: www.anaisdedermatologia.org.br. The deadline for completing the questionnaire is 30 days from the date of online publication.