



CREaTE

Canterbury Research and Theses Environment

Canterbury Christ Church University's repository of research outputs

<http://create.canterbury.ac.uk>

Please cite this publication as follows:

Lidgett, T., Bate, E. and Pittock, L. (2017) Superior shoulder suspensory complex fracture dislocation case report. *Radiography*, 23 (3). e68-e71. ISSN 1078-8174.

Link to official URL (if available):

<http://dx.doi.org/10.1016/j.radi.2017.03.002>

This version is made available in accordance with publishers' policies. All material made available by CReaTE is protected by intellectual property law, including copyright law. Any use made of the contents should comply with the relevant law.

Contact: create.library@canterbury.ac.uk



Superior Shoulder Suspensory Complex Fracture Dislocation Case Report

Tom Lidgett^a, Eunice Bate^b, Lisa Pittock^b

*Canterbury Christ Church University, School of Allied Health Professionals, North Holmes Road,
Canterbury CT1 1QU, United Kingdom*

^a*Trainee Radiographer Reporting Practitioner and Student Canterbury Christ Church University*

^b*Senior Lecturer Canterbury Christ Church University*

Corresponding Author:

Tom Lidgett

Present Address:

Current Affiliation

Student

t.w.lidgett167@canterbury.ac.uk

Canterbury Christ Church University
School of Allied Health Professionals
North Holmes Road
Canterbury
CT1 1QU

Permanent Address:

Preferred Contact Details

Trainee Radiographer Reporting Practitioner

tom.lidgett@pbh-tr.nhs.uk

Diagnostic Imaging Department
Peterborough City Hospital
Edith Cavell Campus
Bretton Gate
Peterborough
PE3 9GZ

Superior Shoulder Suspensory Complex Fracture Dislocation Case Report

Highlights

- Search for associated fractures in acromioclavicular joint dislocation
- Assess the clavicle, acromion process and coracoid process in particular
- Do not end the shoulder X-ray examination after seeing one injury
- Both axial and cranially angulated anteroposterior projections are beneficial
- Acromioclavicular joint fracture dislocation treatment may require further research

Key Words

Case Report, Superior Shoulder Suspensory Complex, Acromioclavicular, Coracoid, Fracture, Dislocation

Abstract

Background: Acromioclavicular joint dislocation can be more complex than it first appears. The presented case had an unusual combination of injuries to the superior shoulder suspensory complex, which yielded some interesting learning points.

Case Summary: The injuries were sustained after a fall from a push bike and included acromioclavicular dislocation with coracoid process, clavicle and acromion process fractures. These were identified on the initial X-ray examination, which was followed by computed tomography for surgical planning. The injuries were successfully treated by internal fixation.

Conclusion: The unexpected complexity of the injuries could have led to subtle but important findings being overlooked. This case highlights the importance of a thorough search strategy, consideration of injury biomechanics and knowledge of associated injuries.

Introduction

Acromioclavicular joint (ACJ) subluxation or dislocation is a relatively common injury of the shoulder although sometimes this can be more complex than it first appears¹. The bone and soft tissue ring of the shoulder girdle is described as the superior shoulder suspensory complex; this includes the glenoid process, the clavicle and its acromioclavicular ligament attachment to the acromion process, and the coracoid process and its coracoclavicular ligament attachment to the clavicle². The presented case had a complex injury to this structure including Rockwood Type III ACJ dislocation combined with each of the described associated fractures; acromion process, clavicle and coracoid process³.

Discussion

Clinical Presentation and Examination

The patient presented to the emergency department after falling from a push-bike onto his shoulder. An emergency nurse practitioner (ENP) took a clinical history and performed a clinical examination. On inspection there was local pain, swelling and deformity to the superior shoulder.

The arm was held to the chest, protected from movement, and was too tender to allow full palpation or range of movement assessments. The outer third of the clavicle was particularly painful to palpate and abduction was also painful. Although, the examination was incomplete the ENP was able to localise the patient's pain to the superolateral shoulder area and the clinical features were characteristic of ACJ dislocation³. On the basis of the findings the ENP requested a shoulder X-ray examination to look for any dislocation or fracture.

Diagnostic Imaging

The X-ray examination began with an anteroposterior shoulder projection on which the radiographer identified that the ACJ was dislocated with the inferior border of the outer end of the clavicle being superiorly displaced from the acromion process (Fig. 1). Due to their suspicion of clavicle and coracoid process fractures, the radiographer performed a cranially angulated anteroposterior clavicle projection (Fig. 2). The coracoid process is an anterior bony projection of the superoanterior aspect of the scapula, which can be difficult to visualise on standard anteroposterior shoulder projections; an anteroposterior projection with 35 degrees or more cranial angulation and axial shoulder projection are required to see it clearly⁴⁻⁵. In this case, the cranially angulated projection demonstrated a minimally displaced fracture at the superior aspect of the outer end of the clavicle and a fracture of the base of the coracoid process, which was markedly displaced from its normal position attached to the scapula. The modified axial projection also demonstrated an undisplaced acromion process fracture (Fig. 3). A subsequent true axial projection demonstrated the anterior displacement of the coracoid process fragment and also showed that there was no significant anterior or posterior displacement of the ACJ dislocation (Fig. 4).

The superimposed clinical manifestations of the injuries sustained demonstrate the importance of performing relevant projections and not prematurely ending the examination after identifying an abnormality on the anteroposterior projection. Each projection unveiled a different injury, which may have otherwise been missed. When interpreting the radiographic images, the unexpected complexity of the injuries sustained combined with satisfaction from identifying the ACJ dislocation could have led to significant injuries being overlooked, highlighting the importance of using a thorough systematic search strategy, considering injury biomechanics and knowing about associated injuries⁶.

Coracoid process fractures are uncommon but can occur with ACJ dislocation³⁻⁴. The main mechanisms postulated to cause coracoid process fractures are: superior avulsion by the coracoclavicular ligament in ACJ dislocation, direct blow to the superior shoulder region, extreme sudden traction avulsion through the biceps or coracobrachialis muscle attachments or collision from the humeral head in anterior dislocation⁶⁻⁸. In this case, the patient's description and radiographic findings suggested that the injuries were caused by a direct anterior blow to the superior shoulder suspensory complex.

The reporting radiographer practitioner identified the abnormalities and discussed the case with the ENP. The patient was urgently referred to fracture clinic with a computed tomography (CT) scan booked and the injured shoulder immobilised in a sling. The CT scan revealed no further scapula fractures that would change the surgical treatment and also provided three dimensional reconstructions for orthopaedic surgical planning (Fig. 5).

Injury Classification

A number of classification systems could have been applied to this injury depending on whether the coracoid process fracture or ACJ dislocation was considered the primary injury. Coracoid process fractures may be classified as posterior (type I) or anterior (type II) to the coracoclavicular ligament, with type II only requiring conservative treatment and type I requiring consideration for surgical treatment⁹. Our case could be described as a type I coracoid process fracture; however, this does not convey the full extent of the injuries that were sustained.

This case probably fits best with a more detailed Rockwood type III ACJ injury classification description that includes possible associated fractures of the lateral clavicle, acromion process or coracoid process, with our patient having suffered all three of these injuries³. However, using this classification could cause confusion as most Rockwood type III ACJ injuries involve coracoclavicular ligament rupture rather than the coracoid process fracture³.

These classification based descriptions of radiographic appearances may help to communicate a visual image of the injury and categorise treatment; however, their usefulness in this case is debatable. They probably do not save any words in a report and can over complicate an already complex injury description while being unclear to those who are not familiar with the chosen classification system (Tables 1 and 2).

Summary of Ogawa et al. Coracoid Process Fracture Classifications⁹

Type	Summary of Appearances
I	Fracture posterior to the coracoclavicular ligament
II	Fracture anterior to the coracoclavicular ligament

Table 1

Summary of Rockwood ACJ Injury Classifications³

Type	Summary of Appearances
I	Acromioclavicular ligament sprain Clavicle is not elevated in relation to the acromion
II	Widening of ACJ or superior subluxation of the clavicle Clavicle is not displaced above the superior border of the acromion
III	Superior dislocation of the clavicle Clavicle is displaced above the superior border of the acromion
IV	Posterior dislocation of the clavicle Clavicle is displaced into the trapezius muscle
V	Marked superior dislocation of the clavicle More severe than type III, coracoclavicular distance more than doubled
VI	Inferior dislocation of the clavicle Displaced into subacromial or subcoracoid location

Table 2

Treatment

ACJ dislocation treatment is controversial and there is a lack of high quality evidence to provide recommendations on the indications for surgical or conservative management^{3, 10}. It has been suggested that most Rockwood type III ACJ dislocations can be treated conservatively, with sling immobilisation and pain control, and still obtain good functional results. However, for ACJ

dislocation and coracoid process fractures, if the arm is used above the horizontal plane, in active young patients or in severe displacement, surgery may be preferential to prevent cosmetic deformity and reduced function^{6,11}. Literature regarding surgical management of coracoid process fractures is uncommon and largely consists of lower quality evidence such as case reports². Authors have described an isolated coracoid process base fracture where the ACJ was not dislocated and conservative treatment was successful⁵. However, when there is a type I coracoid process fracture and the scapuloacromioclavicular connection is disrupted, surgical fixation is recommended⁹.

In this case, surgical treatment was favoured due to complete disruption of the scapuloacromioclavicular connection by multiple injuries, significant coracoid process fracture displacement and because the patient was middle aged and physically active. The operation began with reduction of the ACJ dislocation using an acromion hook plate. A button hole suture device was then attached to the coracoid process tip and to the superior clavicle to angulate the coracoid process back into its correct anatomical position; this prevented the unopposed inferior pull of the muscle attachments of the short head of biceps and coracobrachialis causing persistent caudal angulation of the tip of the coracoid process. A cannulated screw was then used to re-unite the base of the coracoid process with the scapula. Similar cases have been successfully treated with these techniques^{6,12}. The orthopaedic surgeon was satisfied that a plate for the acromion fracture would not be required as the patient would be instructed to limit movement and physical activity during the recovery phase. Intraoperative fluoroscopic imaging was provided by a radiographer with the use of an image intensifier to confirm the position of the internal surgical fixations and to ensure that anatomical alignment was restored.

Outcome

At the first follow-up clinic appointment, X-ray examination was conducted and the internal fixation was considered to be in a satisfactory position with effective reduction of the coracoid process fracture and ACJ dislocation (Fig. 6). Acromion hook plates can be associated with complications such as acromion erosion, peri-prosthetic fracture or fixation failure if there is inadequate immobilisation; however, these did not occur and the plate was removed at six months post initial surgery to prevent any potential issues in the future¹²⁻¹³. The patient now has good function and range of movement that continues to improve with physiotherapy appointments.

Conclusion

This case report adds a rare and interesting combination of injuries to the literature. It highlights the importance of assessing the superior shoulder suspensory complex as an entire structure on radiographic images, where one injury can be accompanied by others, which should always be considered. In ACJ dislocation this particularly includes assessment for the presence of associated fractures to the acromion process, clavicle and coracoid process. A thorough X-ray examination enabled all of the injuries to be identified and demonstrated the importance of making a considered judgement on which projections are necessary for full diagnosis. This involves looking beyond standard protocols and performing relevant projections for the individual patient presentation.

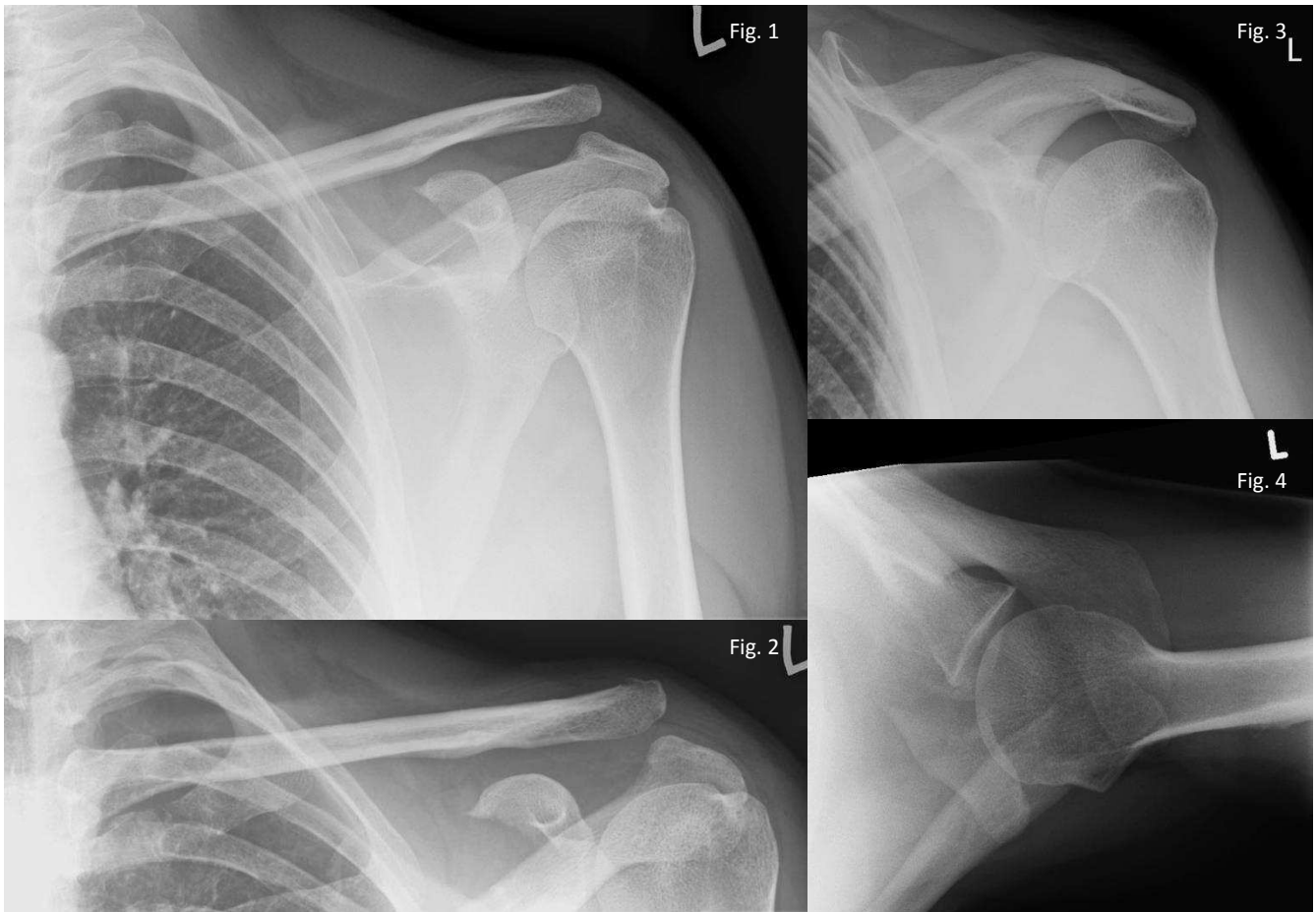Acknowledgements

The authors thank Canterbury Christ Church University for supporting this case report.

References

1. Warth RJ, Martetschläger F, Gaskill TR, Millett PJ. Acromioclavicular joint separations. *Curr. reviews in musculoskelet. medicine* 2013;6(1):71-8.
2. Anavian J, Wijdicks CA, Schroder LK, Vang S, Cole PA. Surgery for scapula process fractures: good outcome in 26 patients. *Acta orthopaedica* 2009;80(3):344-50.
3. Galatz LM, Williams GR. Acromioclavicular Joint Injuries. In: Bucholz RW, Heckman JD, Court-Brown C, editors. *Rockwood and Green's fractures in adults*, Lippincott Williams & Wilkins; 2006, p. 1331-1364
4. Butters KP. Fractures of the Scapula. In: Bucholz RW, Heckman JD, Court-Brown C, editors. *Rockwood and Green's fractures in adults*, Lippincott Williams & Wilkins; 2006, p. 1257-84
5. Alsey KJ, Mahapatra AN, Jessop JH. Coracoid fracture in an adolescent rugby player—Case report and review of the literature. *Radiography* 2012 Nov 30;18(4):301-2.
6. Li J, Sun W, Li GD, Li Q, Cai ZD. Fracture of the coracoid process associated with acromioclavicular dislocation: a case report. *Orthopaedic surg.* 2010;2(2):165-7.
7. Holt GM, Stanley D. The clavicle and the sternoclavicular and acromioclavicular joints. In: Bulstrode C, Buckwalter J, Carr A, Marsh L, Fairbank J, Wilson-MacDonald J, Bowden G editors. *Oxford textbook of orthopedics and trauma*. Oxford University Press; 2002, p. 691-704.
8. Cole PA, Freeman G, Dubin JR. Scapula fractures. *Curr. reviews in musculoskelet. medicine* 2013;6(1):79–87.
9. Ogawa K, Yoshida A, Takahashi MA, Ui MI. Fractures of the coracoid process. *J. Bone and Jt. Surg.-British Volume-* 1997;79:17-9.
10. Tamaoki MJ, Belloti JC, Lenza M, Matsumoto MH, Gomes dos Santos JB, Faloppa F. Surgical versus conservative interventions for treating acromioclavicular dislocation of the shoulder in adults. *The cochrane library* 2010.
11. Allagui M, Koubaa M, Aloui I, Zrig M, Hamdi MF, Abid A. Coracoid fracture combined with distal clavicle fracture without coracoclavicular ligament rupture: A case report. *J. of Clinical Orthopaedics and Trauma* 2013;4(4):190-3.
12. Duan X, Zhang H, Zhang H, Wang Z. Treatment of coracoid process fractures associated with acromioclavicular dislocation using clavicular hook plate and coracoid screws. *J. of Shoulder and Elbow Surg.* 2010;19(2):22-5.
13. Charity RM, Haidar SG, Ghosh S, Tillu AB. Fixation failure of the clavicular hook plate: a report of three cases. *J. of Orthopaedic Surg.* 2006;14(3):333-5.

Diagnostic Images



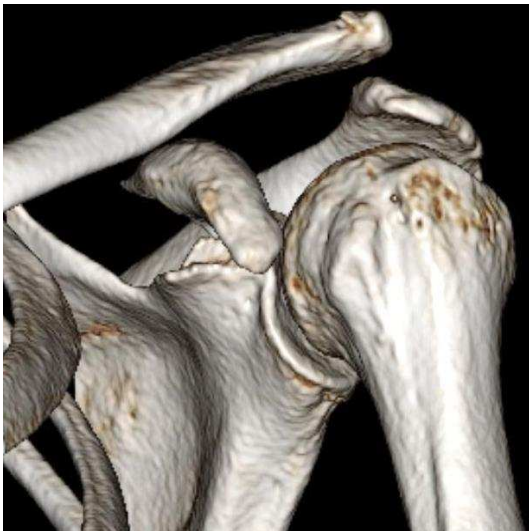Figures 1-4: Initial X-ray Examination Images

Fig. 1: Anteroposterior Shoulder Projection.

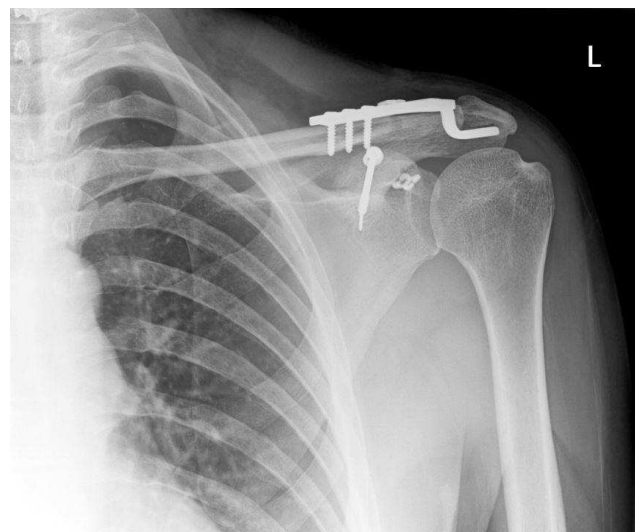
Fig. 2: Cranially Angulated Anteroposterior Clavicle Projection.

Fig. 3: Modified Axial Shoulder Projection.

Fig. 4: True Axial Shoulder Projection.



**Figure 5: Computed Tomography Scan
Three Dimensional Reconstruction.**



**Figure 6: Post-Operative X-ray Examination
Anteroposterior Shoulder Projection.**