



CREaTE

Canterbury Research and Theses Environment

Canterbury Christ Church University's repository of research outputs

<http://create.canterbury.ac.uk>

Please cite this publication as follows:

Williams, Ellie, Weinstock, J. and Spencer, N. (2017) Holey goats: multiple cases of supratrochlear foramina in the humerus of caprines from the New Kingdom pharaonic town of Amara West, northern Sudan. *Environmental Archaeology: Journal of Human Palaeoecology*. ISSN 1461-4103.

Link to official URL (if available):

<https://doi.org/10.1080/14614103.2017.1412005>

This version is made available in accordance with publishers' policies. All material made available by CReaTE is protected by intellectual property law, including copyright law. Any use made of the contents should comply with the relevant law.

Contact: create.library@canterbury.ac.uk



Holey Goats: multiple cases of supratrochlear foramina in the humerus of caprines from the New Kingdom pharaonic town of Amara West, northern Sudan.

Eleanor Williams^{a*}, Jaco Weinstock^b and Neal Spencer^c

^aArchaeology, Canterbury Christ Church University, Canterbury, UK; ^bArchaeology, University of Southampton, Southampton, UK; ^cDepartment of Ancient Egypt and Sudan, The British Museum, London, UK.

Supratrochlear foramina (STF) were recorded in fifteen per cent of goat and sheep/goat humeri from the New Kingdom pharaonic town of Amara West, in modern northern Sudan. To the authors' knowledge, this trait has never before been reported in the published literature for goats or sheep, whether from archaeological or modern contexts. The aim of this work is twofold: to contribute to the growing corpus of studies addressing the incidence and aetiology of STF, and to raise awareness for their possible presence in caprines, thus encouraging their identification and recording in archaeological assemblages.

Keywords: Amara West, anatomy, humerus, caprines, supratrochlear foramen, zooarchaeology

Introduction

The supratrochlear foramen is an anatomic variation in the distal end of the humerus. The olecranon fossa and the coronoid fossa of the humerus - situated between the lateral and medial epicondyles - are separated by a thin plate of bone known as the supratrochlear septum; this plate can sometimes be perforated resulting in a 'septal aperture' or a 'supratrochlear foramen' (STF) (Nayak *et al.* 2009; Erdogmus *et al.* 2013). This trait, first referenced in the 1820s (Mays 2008, 136), is nearly always present in some canids e.g. dogs and hyenas; it is often present in pigs, and can sometimes be found in humans and other primates (Benfer and Tappen 1968; Mays 2008). However, the trait is regarded as being absent in ruminants and equids (Lamb 1890; Nickel, Schummer, and Seiferle 1986; Budras, Sack, and Röck 2003, 2). Despite this assertion, Haziroglu and Ozer (1990) reported the presence of STF in six modern cattle humeri - representing three adult individuals - near Ankara, Turkey; to the authors' knowledge, no other cases of STF have been reported in the published literature for this species.

In this contribution, we present thirteen archaeological goat and sheep/goat specimens exhibiting a supratrochlear foramen. These finds were all recovered from Amara West, a late second millennium BC pharaonic settlement in modern northern Sudan, and represent the first reported cases of STF for either modern or sub-fossil caprines. This is the more remarkable given the high frequency of skeletal remains of

this group often recovered from archaeological sites; here we consider the potential significance of this finding to zooarchaeological enquiries.

Materials and Methods

The thirteen humeri form part of a large assemblage of faunal remains from the site of Amara West in northern Sudan (Figure 1). Founded c.1300 BC, and occupied through until around 1000BC, the town was founded as a new administrative centre to oversee the pharaonic colony of Upper Nubia (Kush). The settlement (including its cemeteries) has been the focus of a British Museum research project since 2008, under the direction of Dr Neal Spencer (see Spencer 2014; Spencer, Stevens, and Binder 2014).

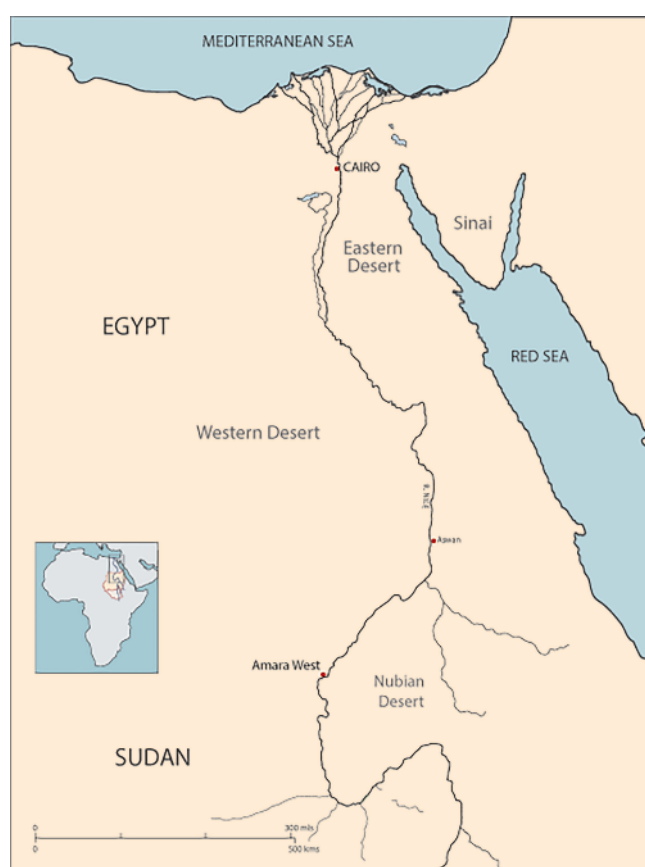

Figure 1: Location map of Amara West, northern Sudan (map: Claire Thorne).

As part of a pilot study, the authors undertook a detailed assessment of approximately 6800 animal bones and bone fragments from within, and in the immediate vicinity of, two houses: a large villa (E12.10) situated outside of the town walls, and a more modest house within the walled town (E13.3; for both see Spencer 2014, 466–80). The discovery of two goat specimens with STF prompted a rapid examination of the full faunal assemblage (estimated to be upwards of 40,000

identifiable bones and larger bone fragments) to determine the frequency of this trait in caprines by context, and for the entire site; eleven further cases were recorded.

Species identification was based on the diagnostic criteria of the medial epicondyle, lateral condyle, and olecranon fossa published over the years by a number of authors (Gromova 1953; Boessneck, Müller, and Teichert 1964; Boessneck 1970; Prummel and Frisch 1986; Clutton-Brock *et al.* 1990), and recently re-evaluated by Zeder and Lapham (2010). Those that could not be confidently assigned to either species were classified as ‘sheep/goat’. From all of the specimens that could be unambiguously identified as sheep or goat (for all skeletal elements in houses E12.10 and E13.3), the latter make up over 95% (calculated based on 65 out of 68 bones). Thus, there is a very high likelihood that humeri identified only as sheep/goat are actually goats.

To determine whether the distal humeri (six left and seven right) could represent thirteen separate individuals, metrical and visual assessments were conducted; digital callipers were used to determine the greatest breadth of the trochlea (BT) following von den Driesch (1976). Non-metric morphological characteristics, and the state of epiphyseal fusion, were also considered.

Macroscopic analysis with the aid of a magnifying glass enabled a true presence of the trait to be determined, as opposed to post-depositional damage. Where an STF was identified, digital callipers were used to measure the maximum height (vertical) and width (transverse) in millimetres. Overall shape (round, oval, round/oval, or irregular) was noted.

Results

For the 83 distal humeri of goats (n=21) and sheep/goat (n=62) that could be assessed for the presence or absence of an STF, eight goats and five sheep/goat exhibited this trait, providing a frequency of c. fifteen per cent for the site. They derived from archaeological deposits dating to three phases at Amara West: c.1210-1180BC; c.1180-1140BC; c.1180-1100BC (Table 1). The deposits were excavated from within houses, a repurposed storage facility, and outside spaces including an alleyway. Seven further distal humeri (four goats and three sheep/goat) had particularly thin and fragile supratrochlear septa with small holes. It was not possible to establish a true presence or absence of the trait in these specimens; as such they were excluded from the study.

The thirteen humeri were confidently assigned to separate individuals based on the assessments summarised above.

Macroscopic analysis confirmed the true presence of the trait in each specimen; the edges were mostly of smooth cortical bone with little or no evidence for post-depositional damage. However, across the sample, there was a large degree of variability between the form (e.g. thickness of margins), overall shape, and dimensions of the STF. In ten of the specimens, the margins of the STF were relatively well-formed, with up to 1mm in thickness in a few cases. For the remaining three (AW8, AW9, and AW11), the supratrochlear septum was particularly thin, and despite the STF

having clearly defined edges, these were fragile and more prone to damage (e.g. Figure 2, AW8 [5246]).

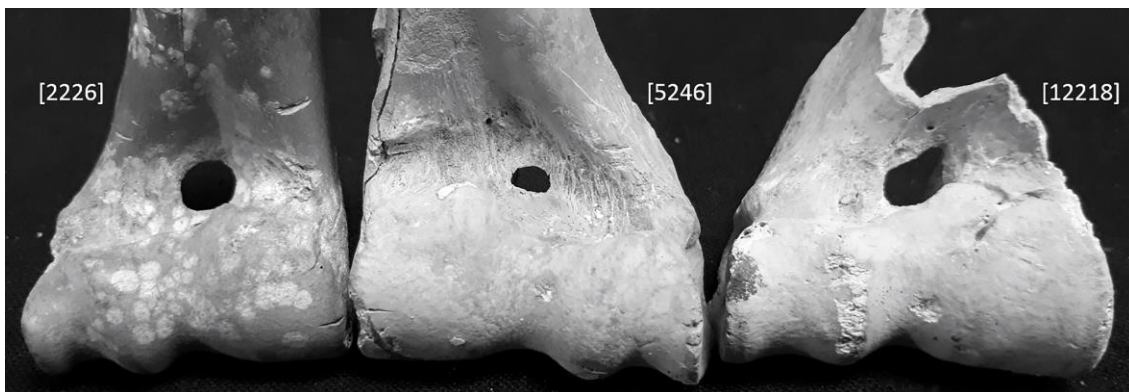

Figure 2: Supratrochlear foramina of the humerus in two goats (AW2 [2226]; AW8 [5246]) and a sheep/goat (AW12 [12218]) from Amara West. From left to right: round, oval, and irregular (photo: Eleanor Williams).

The STF varied greatly in size and shape; they ranged from 1.4mm in transverse diameter through to 6.4mm (Table 1), and represented a spectrum of shapes from rounded and oval, through to irregular (Figure 2). Two of the sheep/goat specimens, (AW6 and AW7), showed fusing distal epiphyses, indicating that they were under one year of age at death (see Zeder 2006). The presence of STF in immature individuals indicates that the trait cannot be attributed solely to repeated and prolonged activity-related stress or to the ageing process. Interestingly, the three specimens with the smallest greatest trochlea breadth (AW4, AW6, and AW10) had the three highest mean STF diameters: 6.1, 6, and 5.8cm, respectively. However, there is no inverse correlation for the overall sample; the humeri with the largest greatest trochlea breadth did not have the smallest mean diameter of STF.

Bone ID	Provenance (archaeological context)	Phase	Species	Side	Fusion	Greatest trochlea breadth, mm	Overall shape of STF	Transverse diameter, mm	Vertical diameter, mm
AW1	2223	c.1180-1100BC	Goat	L	Fused	33.3	Round	5.2	4.9
AW2	2226	c.1180-1100BC	Goat	R	Fused	28.3	Round	5	4.8
AW3	2325	c.1180-1100BC	Goat	R	Fused	28.1	Round	3.6	3.5
AW4	2333	c.1180-1100BC	Sheep/goat	R	Fused	28	Round	6.1	-
AW5	2517	c.1180-1000BC	Goat	R	Fused	32.8	Round	5.9	5.5
AW6	4494	c.1180-1100BC	Sheep/goat	L	Fusing	27.6	Oval	6.4	5.6
AW7	5111	c.1180-1140BC	Sheep/goat	R	Fusing	-	Round/Oval	4.4	5.1
AW8	5246	c.1210-1180BC	Goat	L	Fused	31.8	Oval	3.9	2.3
AW9	5246	c.1210-1180BC	Goat	L	Fused	31.5	Round	1.4	1.4
AW10	5700	c.1210-1180BC	Goat	L	Fused	27.1	Oval	6.2	5.4
AW11	12054	c.1180-1100BC	Sheep/Goat	R	Fused	-	Round/Oval	2.1	2.7
AW12	12218	c.1180-1100BC	Sheep/Goat	R	Fused	33.2	Irregular	5.3	-
AW13	12589	c.1180-1100BC	Goat	L	Fused	32.3	Oval	5.8	4.1

Table 1: Summary data for the thirteen caprine specimens from Amara West exhibiting STF. A dash denotes unobtainable data.

Two goat humeri (AW5 and AW13) had further well-defined foramina with smooth rounded edges in addition, and in close proximity, to the STF; the former was located superiorly to the STF, with the latter positioned distal to the STF (Figure 3).




Figure 3: Two goat humeri (AW5 [2517] and AW13 [12589]) from Amara West exhibiting an extra foramen positioned in close proximity to the STF (photo: Eleanor Williams).

Discussion and conclusions

Veterinary and comparative vertebrate anatomy textbooks commonly report on the presence of STF in domesticated mammals, but this is usually restricted to a basic reference to presence or absence (e.g. Adams and Crabtree 2008; Akers and Denbow 2013; Aspinall and Cappello 2015). There is, however, a growing body of literature discussing the presence of STF in archaeological and modern human populations, their possible aetiology, and implications for anthropological and clinical contexts (Glanville 1967; Mays 2008; Nayak *et al.* 2009; Erdogmus *et al.* 2013; Patel *et al.* 2013; Kubicka, Myszka, and Piontek 2015). Its incidence has been reported to vary greatly between different human populations, with figures ranging from close to 0% to almost 60% (Li *et al.* 2015, Table 2); a primarily genetic origin for the trait has thus been proposed (e.g. Hrdlička 1932; Singhal and Rao 2007). Mechanical causation has also been explored, with researchers relating STF to the conformation of the humero-ulna joint and/or the role of hypermobility in their formation (e.g. Benfer and Tappen 1968; Mays 2008; Kubicka, Myszka, and Piontek 2015).

Li *et al.* (2015) and Patel *et al.* (2013) have also suggested a mechanical aetiology for the presence of STF in animals such as dog, pig, and hyena, proposing that they could be a result of their posture whilst tearing foods; here, the position of the forelimb could produce pressure at the elbow joint, impacting upon the integrity of the supratrochlear septum. It should be noted that Lagomorphs (hares, rabbits, and pikas) also possess STF, although for these mammals (especially hare/*Lepus*), the skeletal dynamics are markedly different. Its apparent rare occurrence amongst non-carnivorous mammals such as caprines (present study) and cattle (Hazirolu and Ozer 1990), suggests that a purely mechanistic explanation for the presence of STF is insufficient.

Given the apparent rarity of this anatomical feature in caprines, its relatively high frequency of fifteen per cent at Amara West indicates that the presence of STF is highly unlikely to be the result of stochastic processes. An inherited component could be tentatively considered. It should be noted that the specimens derived from a diversity of contexts dated to three periods, with an overall date range of c.1210-c.1100 BC (Table 1). Only two of the specimens (from context 5246) can be ascribed to a relatively short time period within the existence of the site (c.1210-1180BC).

Presence/absence, as well as variation in the position, of particular non-metric traits in mammals has been the focus of some detailed investigation. For example, in most modern sheep populations, the location of the major nutrient foramen in the femur is normally positioned antero-proximally; only in a minority of cases the foramen is found towards the distal end of the shaft or at midshaft (O'Connor 2000, 121). However, in some modern British breeds, which are geographically restricted and which have been reduced to very small numbers, the uncommon location of the foramen can attain abnormal frequencies (O'Connor 2000, 121), a finding supported in an archaeological context (Noddle 1978, 137). Recording this trait, O'Connor (2000, 122) suggests, may convey information about limited gene-flow or the gene-pool of the founder population, as could varying prevalence rates of an absent or reduced hypoconulid in the lower third molars in bovids and some cervids (O'Connor 2000,

121; see also Dobney *et al.*, 181-183, 187; Thomas and Worley 2014, 36). As with STF, a systematic recording of non-metric traits – including the presence of other unusual skeletal anomalies in possible association with them (e.g. see Figure 3) – may provide important insight into breeding populations and herd management strategies within and between sites through time. For Amara West, only a few decades after it was founded, environmental deterioration in the region resulted in a partial drying up of the Nile, and an increase in aridity and Aeolian Saharan sand. The dramatic impact of these changing conditions on the daily lives of Amara West’s inhabitants has, and continues to be, clearly demonstrated through the human osteological, archaeological, architectural, and environmental evidence (Spencer, Stevens and Binder 2014; Woodward *et al.* 2016). The influence of such localised conditions is also likely to have had an impact on livestock sustainability and management practises; ongoing analyses of the faunal remains should provide further insight.

For a more comprehensive consideration of the factors resulting in the appearance of STF – which in turn could provide valuable contributory evidence to discussions within the clinical, veterinary, and archaeological literature - a more widespread reporting is required. As O’Connor has argued, ‘the investigation of non-metrical traits in animal skeletons is a poorly developed area of research, with little systematic published record’ (2000, 119), a viewpoint echoed in a veterinary science context (see Rinderknecht *et al.* 2005); nonetheless few detailed, systematic studies exist today. As with other non-metric traits, numerous cases of STF could have gone unobserved or unreported, thus concealing prevalence rates in different archaeological and modern caprine, or indeed bovine, populations. Furthermore, as the supratrochlear foramen is a commonly used anatomical feature for species identification – particularly for fragmentary remains - this finding commands caution.

It is hoped that the reporting of this discovery will, at the very least, highlight the possible presence of this trait in mammalian species other than those commonly cited in the literature, and thus encourage other researchers to document and investigate similar findings.

Acknowledgements

We would like to acknowledge the National Corporation of Antiquities and Museums [Sudan] for permitting the export of faunal material for analysis. We also wish to thank the two anonymous reviewers for their valuable comments.

References

- Adams, B. J. and Crabtree, P. J. 2008. *Comparative Skeletal Anatomy: A Photographic Atlas for Medical Examiners, Coroners, Forensic Anthropologists, and Archaeologists*. Totowa: Humana Press.
- Akers, R. M. and Denbow, D. M. 2013. *Anatomy and Physiology of Domestic Animals*. Oxford: John Wiley & Sons.

- Aspinall, V. and Cappello, M. 2015. *Introduction to Veterinary Anatomy and Physiology Textbook*. London: Elsevier.
- Benfer, R. A. and Tappen, N. C. 1968. The occurrence of the septal perforation of the humerus in three non-human primate species. *American Journal of Physical Anthropology* 29, 19–28. doi:10.1002/ajpa.1330290111.
- Boessneck, J. 1970. Osteological differences between sheep (*Ovis aries* Linné) and goat (*Capra hircus* Linné), pp. 331-358 in Brothwell, D. R. and Higgs, E. S. (eds.), *Science in Archaeology: A Comprehensive Survey of Progress and Research*. London: Thames & Hudson.
- Boessneck, J., Müller, H-H. and Teichert, M. 1964. Osteologische unterscheidungsmerkmale zwischen schaf (*Ovis aries* Linné) und zeige (*Capra hircus* Linné). *Kühn-Archiv* 78(1-2), 1-129.
- Budras, K-D., Sack, W. O. and Röck, S. 2003. *Anatomy of the Horse: An Illustrated Text*. Hannover: Schlütersche.
- Clutton-Brock, J., Dennis-Bryan, K., Armitage, P. L. and Jewell, P. A. 1990. Osteology of the Soay Sheep. *Bulletin of the British Museum of Natural History (zoology)* 56(1), 1-56.
- Dobney, K., Jaques, D., Johnstone, C., Hall, A., La Ferla, B. and Haynes, S. 2007. The Agricultural Economy, pp. 116-189 in Dobney, K. R., Jaques, D., Barrett, J. and Johnstone, C. (eds.), *Farmers, Monks and Aristocrats: The Environmental Archaeology of Anglo-Saxon Flixborough*. Excavations at Flixborough Volume 3. Oxford: Oxbow Books, 116-189.
- Erdogmus, S., Guler, M., Eroglu, S. and Duran, N. 2013. The importance of the supratrochlear foramen of the humerus in humans: an anatomical study. *Medical Science Monitor* 20, 2642-2650. doi:10.12659/MSM.892074.
- Glanville, E. V. 1967. Perforation of the coronoid-olecranon septum. Humero-ulnar relationships in Netherlands and African populations. *American Journal of Physical Anthropology* 26(1), 85-92. doi:10.1002/ajpa.1330260111.
- Gromova, V. 1953. Osteologicheskie otlichiya rodov *Capra* (kozly) i *Ovis* (barany). Rukovodstvo dlya opredeleniya iskopaemykh ostatkov. *Trudy Komissii po izucheniyu chetvertichnogo perioda* 10, 1–122.
- Haziroglu, R. M. and Ozer, M. A. 1990. A supratrochlear foramen in the humerus of cattle. *Anatomia, Histologia, Embryologia: Journal of Veterinary Medicine Serices C*, 19, 106-8. doi:10.1111/j.1439-0264.1990.tb00893.x
- Hrdlička, A. 1932. The humerus: septal aperture. *Anthropologie* 10, 31–96.
- Kubicka, A. M., Myszka, A. and Piontek, J. 2015. Geometric morphometrics: does the appearance of the septal aperture depend on the shape of ulnar processes? *The Anatomical Record* 298, 2030–2038. doi:10.1002/ar.23272.
- Lamb, D. S. 1890. The Olecranon Perforation. *American Anthropologist* 3, 159-174. doi:10.1525/aa.1890.3.2.02a00050.
- Li, J., Mao, Q., Li, W. and Li, X. 2015. An anatomical study of the supratrochlear foramen of the Jining population. *Turkish Journal of Medical Sciences* 45, 1369-1373. doi:10.3906/sag-1407-44.

- Mays, S. 2008. Septal aperture of the humerus in a mediaeval human skeletal population. *American Journal of Physical Anthropology* 136, 432-440. doi:10.1002/ajpa.20826.
- Nayak, S. R., Das, S., Krishnamurthy, A., Prabhu, LV. and Potu, B. K. 2009. Supratrochlear foramen of the humerus: an anatomico-radiological study with clinical implications. *Upsala Journal of Medical Sciences* 114, 90-94. doi:10.1080/03009730802688819.
- Nickel, R., Schummer, A. and Seiferle, E. 1986. *The Anatomy of Domestic Animals, Volume 1: The Locomotor System of the Domestic Mammals*. New York: Springer-Verlag.
- Noddle, B. A. 1978. Some minor skeletal differences in sheep, pp. 133-42 in Brothwell, D., Thomas, K. D. and Clutton-Brock, J. (eds.), *Research problems in zooarchaeology*. Institute of Archaeology Occasional Paper 3. London: Institute of Archaeology.
- O'Connor, T. 2000. *The Archaeology of Animal Bones*. Stroud: Sutton Publishing.
- Patel, S. V., Sutaria, L. K., Nayak, T. V., Kanjiya, D. P., Patel, B. M. and Aterkar, S. H. 2013. Morphometric study of supratrochlear foramen of humerus. *International Journal of Biomedical and Advance Research* 4(2), 89-92. doi:10.7439/ijbar.v4i2.892.
- Prummel, W. and Frisch, H-J. 1986. A guide for the distinction of species, sex and body size of sheep and goat. *Journal of Archaeological Science* 13, 567-577.
- Rinderknecht, A., Pérez, W., Bielli, A. and Möller, R. 2005. Inconstant Skull Foramina in Bovine (*Bos Taurus*) and Swine (*Sus scrofa*). *Journal of Animal and Veterinary Advances* 4(9), 798-800. doi=javaa.2005.798.800.
- Singhal, S. and Rao, V. 2007. Supratrochlear foramen of the humerus. *Anatomical Science International* 82(2), 105-107. doi:10.1111/j.1447-073X.2007.00172.x.
- Spencer, N. 2014. Amara West: considerations on urban life in colonial Kush, pp. 457-85 in Anderson, J. R. and Welsby, D. A (eds.), *The Fourth Cataract and Beyond*. Proceedings of the 12th International Conference for Nubian Studies. 1-6 August 2012, London. British Museum Publications on Egypt and Sudan 1. Leuven: Peeters.
- Spencer, N., Stevens, A. and Binder, M. 2014. *Amara West. Living in Egyptian Nubia*. London: The British Museum.
- Thomas, R. and Worley, F. 2014. Recording non-metric traits, p.36 in Baker, P. and Worley, F (eds.), *Animal Bones and Archaeology: Guidelines for Best Practice*. London: English Heritage
- von den Driesch, A. 1976. *A Guide to the Measurement of Animal Bones from Archaeological Sites*. Cambridge, MA: Peabody Museum of Archaeology and Ethnology.
- Woodward, J., Macklin, M., Spencer, N., Binder, M., Dalton, M., Hay., S. and Hardy, A. 2016. Living with a changing river and desert landscape at Amara West, pp.227-257 in Spencer, N. and Binder, M. (eds.), *Nubia in the New Kingdom*:

Lived Experience, Pharaonic Control and Indigenous Traditions. London: British Museum.

Zeder, M. A. 2006. Reconciling Rates of Lone Bone Fusion and Tooth Eruption and Wear in Sheep (*Ovis*) and Goat (*Capra*), pp. 87-118 in Ruscillo, D. (ed.), *Recent Advances in Ageing and Sexing Animal Bones*. Oxford: Oxbow Books.

Zeder, M. A. and Lapham, H. A. 2010. Assessing the reliability of criteria used to identify postcranial bones in sheep, ovis, and goat, capra. *Journal of Archaeological Science* 37, 2887-2905. doi:10.1016/j.jas.2010.06.032.