



UNIVERSITY OF LEEDS

This is a repository copy of *A radiographic analysis of alignment in 966 lower extremities with knee pain and its association with osteoarthritis in Indian population*.

White Rose Research Online URL for this paper:  
<http://eprints.whiterose.ac.uk/156549/>

Version: Accepted Version

---

**Article:**

Nayak, M, Kumar, V, Kanojiya, G et al. (4 more authors) (Cover date: July August 2020) A radiographic analysis of alignment in 966 lower extremities with knee pain and its association with osteoarthritis in Indian population. *Journal of Orthopaedics*, 20. pp. 207-212. ISSN 0972-978X

<https://doi.org/10.1016/j.jor.2019.12.003>

---

© 2019 Professor P K Surendran Memorial Education Foundation. Published by Elsevier B.V. All rights reserved. This manuscript version is made available under the CC-BY-NC-ND 4.0 license <http://creativecommons.org/licenses/by-nc-nd/4.0/>.

**Reuse**

This article is distributed under the terms of the Creative Commons Attribution-NonCommercial-NoDerivs (CC BY-NC-ND) licence. This licence only allows you to download this work and share it with others as long as you credit the authors, but you can't change the article in any way or use it commercially. More information and the full terms of the licence here: <https://creativecommons.org/licenses/>

**Takedown**

If you consider content in White Rose Research Online to be in breach of UK law, please notify us by emailing [eprints@whiterose.ac.uk](mailto:eprints@whiterose.ac.uk) including the URL of the record and the reason for the withdrawal request.



[eprints@whiterose.ac.uk](mailto:eprints@whiterose.ac.uk)  
<https://eprints.whiterose.ac.uk/>

# A radiographic analysis of alignment in 966 lower extremities with knee pain and its association with osteoarthritis in Indian population

Nayak<sup>a</sup>, Kumar V<sup>a</sup>, Kanojiya<sup>a</sup>, Mellon s<sup>b</sup>, Srivastava DN<sup>c</sup>, Pandit H<sup>d</sup>, Malhotra R<sup>a</sup>

## Authors Details

<sup>a</sup>Department of Orthopedics, All India Institute of Medical Sciences (AIIMS), New Delhi, 110029, India

<sup>b</sup>Botnar Research Centre, University of Oxford, Oxford, UK

<sup>c</sup>Department of Radiodiagnosis, All India Institute of Medical Sciences (AIIMS), New Delhi, 110029, India

<sup>d</sup>Orthopaedics and Honorary Consultant, Chapel Allerton Hospital, University of Leeds, UK

Mayur Nayak (corresponding author): mayur.nayak86@gmail.com, Department of Orthopedics, All India Institute of Medical Sciences (AIIMS), New Delhi, 110029, India

Vijay Kumar: vijayaiims@yahoo.com

Gourav Kanojiya: gouravkanojiya@gmail.com

Stephen Mellon: stephen.mellon@ndorms.ox.ac.uk

Deep Narayan Srivastava: drdeepsrivastava@rediffmail.com

Hemant Pandit: hemant.pandit@ndorms.ox.ac.uk

Rajesh Malhotra: rmalhotra62@gmail.com

## **Abstract**

### **Purpose**

This study aimed to investigate the alignment based on deformity in knees affected by osteoarthritis (OA) at different stages and evaluate its association with OA.

### **Material and methods**

The following radiological parameters were measured from weight bearing long leg radiographs of 966 legs in the Indian subjects via a morphometric software (Matlab R2009a) (1) Hip-Knee-Ankle angle (HKAA), (2) Femoral bowing, (3) Tibial Bowing, (4) Condylar Plateau angle (CPA). The knees were classified according to the Kellgren and Lawrence grading and these parameters were evaluated with OA for its association using appropriate statistical tests.

### **Results**

The mean HKAA angle was  $174.5^{\circ} \pm 6.5^{\circ}$ , 65.8% of the limbs were found to be in varus ( $<177^{\circ}$ ) and 3.8% in valgus ( $>183^{\circ}$ ). The mean femoral and tibial bowing was  $-1.19 \pm 4.95^{\circ}$  and  $-1.54 \pm 3.58^{\circ}$  respectively. 55.8% of femorae and 41.4% of the tibia were observed to have varus bowing while 24.12% of femorae and 12.11% the tibia were observed to have valgus bowing. An increase in odds of disease severity was observed with femoral and tibial bowing  $>2^{\circ}$ . With an increase in the grades of OA a significant increase in the lateral bow of both femur and tibia was observed. The mean condylar plateau angle was observed to be  $-2.53^{\circ} \pm 7.9^{\circ}$ . Positive association was seen between the varus CPA, HKA and OA ( $p < 0.01$ ).

### **Conclusion**

This study describes the various radiological parameters in Indian patients at different grades of OA and might elucidate the role of these factors in OA initiation and progression.

### **Keywords**

Osteoarthritis, Mechanical alignment, Coronal bowing, Condylar plateau angle  
Indian population

## 1. Introduction

Osteoarthritis (OA) is a major cause of disability in elderly people and affects the weight bearing joints such as the hip and the knee. The medial compartment of the knee is more commonly affected than the lateral side.<sup>1</sup> The factors implicated in causation and progression are mechanical, biological, traumatic or a combination of these.<sup>2,3</sup> Mechanical factors such as dynamic and the static alignment of the limb have been shown to be a strong predictor of the progression of knee osteoarthritis.<sup>4</sup> The static alignment which is defined as hip knee ankle axis angle in the coronal plane can be assessed by long leg weight bearing radiographs. In varus arthritic knee, the varus angulation is generally attributed to the medial ligamentous tightness, laxity of lateral ligaments and the medial condylar wear which are denoted by joint line convergence angle and joint orientation angles in a long leg radiograph.<sup>5</sup> These factors and their association with limb alignment have been researched extensively in the past. Cookes and colleagues in a series of studies showed that limb alignment deformity is significantly associated condylar plateau angle and femoral deformity.<sup>6, 7, 8</sup> Hip Knee Ankle Angle (HKAA) have also been shown to correlate positively with medial proximal tibial angle (MPTA) and lateral distal femoral angle (LDFA) by Mullaji et al. and Thienpont et al. respectively.<sup>9,10</sup> Apart from these explicit intra-articular factors, extra-articular factors such as femoral bowing and tibial bowing are generally overlooked even though they may also predispose a person to the development or the progression of osteoarthritis. Matsumo et al.<sup>4</sup> found that changes in the curvature of the femoral shaft is associated with aging and may contribute to the initiation of knee OA in Japanese population. Their study also showed an association between an increase in tibial plateau inclination and proximal tibial varus deformity with higher grades of OA. Although few Asian studies have described lateral femoral bowing and tibial bowing with OA,<sup>4,9, 12, 13, 14</sup> its association with the same has been inadequately described in detail such as the site of deformity or the progression of deformity with different grades of OA.

Keeping this in mind we conducted a cross sectional observational study and performed a detailed radiographic assessment of 966 lower limbs in Indian patients presenting with knee pain. The purpose of this study was<sup>1</sup> To calculate the incidence of malalignment of the lower limb in the coronal plane<sup>2</sup> To calculate the incidence of extra-articular femoral and tibial deformity in coronal plane<sup>3</sup> To calculate the condylar plateau angle<sup>4</sup> To look for the association of the above-mentioned factors with knee OA in this population<sup>5</sup> To look for the progression of these factors at different grades of OA.

## 2. Material and method

A prospective observational cross-sectional study was conducted at our centre where patients of age more than 30 years presenting to orthopaedics outpatient department (OPD) with knee pain were included in the study. Patients with prior history of trauma or any surgery of the knee, flexion deformity of the knee greater than 20°, as well as patients suffering from inflammatory arthritis were excluded, resulting in enrolment of 966 knees. The study was approved by the Institutional ethics review board (IRB Ref No.: IEC/NP-173) and adhered to the tenets of Helsinki declaration of 1964 (and its later amendments). Informed written consent was taken from all patients prior to inclusion in this study.

The patients' demographic profile was recorded which included age, gender, height, weight and duration of the complaint. The following X-rays of both knees were obtained for each participant in the study. 1 wt bearing antero-posterior (AP) view 2 Lateral view and 3 the Long leg view.

The tibio-femoral joint was assessed through AP view and the posterior aspect through the lateral view. The patellofemoral joint was assessed through the skyline view and the lateral view. All the assessment was by a single trained radiologist (DNS) who was blinded to the questionnaires.

The radiological grading of osteoarthritis (OA) was done according to Kellegren and Lawrence (K&L).

### 2.1. Radiographic assessment of the lower limb

Long legs films were taken in full extension under full weight bearing. The knee was so positioned that both the patellae were facing forward. The standard position ensured that the tibiae were vertical and there was minimal rotation. The digital copies were retrieved using Picture archive and communication system (PACS) and both the limbs were assessed using a custom written matlab (2009, Mathworks, USA) routine. This software uses the digital equivalent of a ruler, circle and goniometer tools to define landmarks and make measurements. The following landmarks were identified manually through the software for each limb. Centre of the femoral head (CFH), centre of the proximal (CPF) and the distal third of the intramedullary canal of the femur (CDF), medial femoral condyle (MFC), the intercondylar notch (ICN), lateral femoral condyle (LFC), medial (MTP) and lateral tibial plateau (LTP), medial (MTS) and lateral tibial spine (LTS), centre of the proximal (CPT) and distal third of the intramedullary canal of the tibia (CDT) and the centre of the tibial plafond (CTPF) (Fig. 1). The centre of intramedullary canal was marked by connecting mid-cortical points at various levels for both proximal and distal half of both the bones. Superior

and inferior aspect of lesser trochanter along with a point 5 cm distal to the latter was used for proximal femur. Two mid-cortical point proximal to MFC at 5 and 10 cm and ICN was used for distal femur. For proximal tibia, mid-point between MTS and LTS was taken as the first point along with two mid cortical point at 5 and 10 cm distal to MTP and for distal half the first point taken was CTPF along with two points which were 3 and 5 cm proximal to it. Using these landmarks the following parameters were calculated.

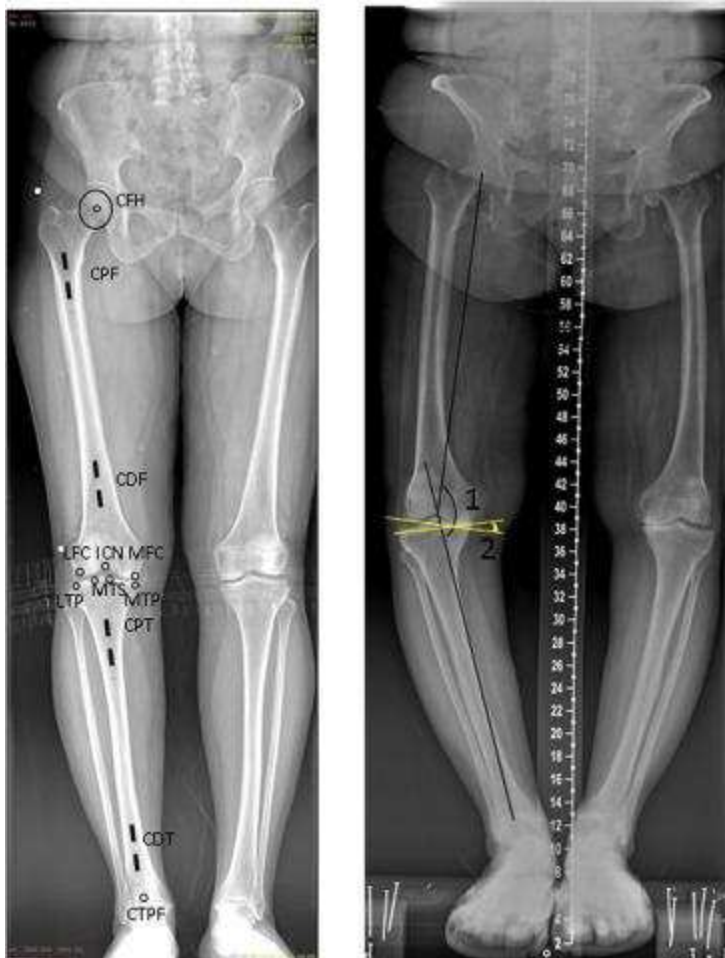

Fig. 1. Following landmarks were identified manually through the software for each limb. Centre of the femoral head (CFH), centre of the proximal (CPF) and the distal third of the intramedullary canal of the femur (CDF), medial femoral condyle (MFC), the intercondylar notch (ICN), lateral femoral condyle (LFC), medial (MTP) and lateral tibial plateau (LTP), medial (MTS) and lateral tibial spine (LTS), centre of the proximal (CPT) and distal third of the intramedullary canal of the tibia (CDT) and the centre of the tibial plafond (CTPF). With the help of these landmarks following angles were calculated. Hip-Knee-Ankle Angle<sup>1</sup>; the angle subtended between the line connecting CFH, ICN and point between MTS and LTS and CTPF, Condylar plateau

angle(2) angle formed angle between the line tangential to both the femoral condyles and tibial plateau.

### 2.1.1. Coronal alignment of the lower limb

The coronal alignment of all lower limbs was assessed with the Hip Knee Ankle axis angle (HKAA) (Fig. 1). Similar to the study by Hagstedt et al.,<sup>15</sup> three reference points CFH, ICN and CTPF were used for the calculation. Values of HKAA between 177 and 183° were categorised as normal, below 177° were varus and greater than 183° were valgus.

### 2.1.2. Extra-articular deformity of femur and tibia

The line that connected the centre of the femoral head to the intercondylar notch defined the mechanical axis of the femur. For the anatomical axis of the femur, a line that connected the mid-cortex centres of the proximal and distal thirds of the femur was used. When this line did not pass through the centre of the mid diaphysis, centre of rotation of angulation (CORA) was defined and the angle was measured. The deformity of the femur was calculated through the software and was defined as varus if there was a lateral bowing of the femoral shaft and valgus if there was a medial bowing and the angle of the CORA greater than 2° similar to yau et al.<sup>13</sup>(Fig. 2A,B). Similarly, with tibia, the mechanical axis was defined by the line connecting the centre of the tibial spine to the centre of the talus and the anatomical axis was defined by the line connecting multiple mid-cortex centres of the proximal and the distal third of the tibia. Normally both of these lines are parallel to each other but when these lines are not parallel, the CORA of the tibia was defined and the angle was measured. As with the femoral bowing, tibial deformity was classified as varus or valgus depending upon the tibial bow and if the angle at the CORA was greater than 2°. <sup>13</sup> Positive sign (+) was used to denote the valgus deformity and negative sign (-) was used to denote the varus deformity (Fig. 2C and D).

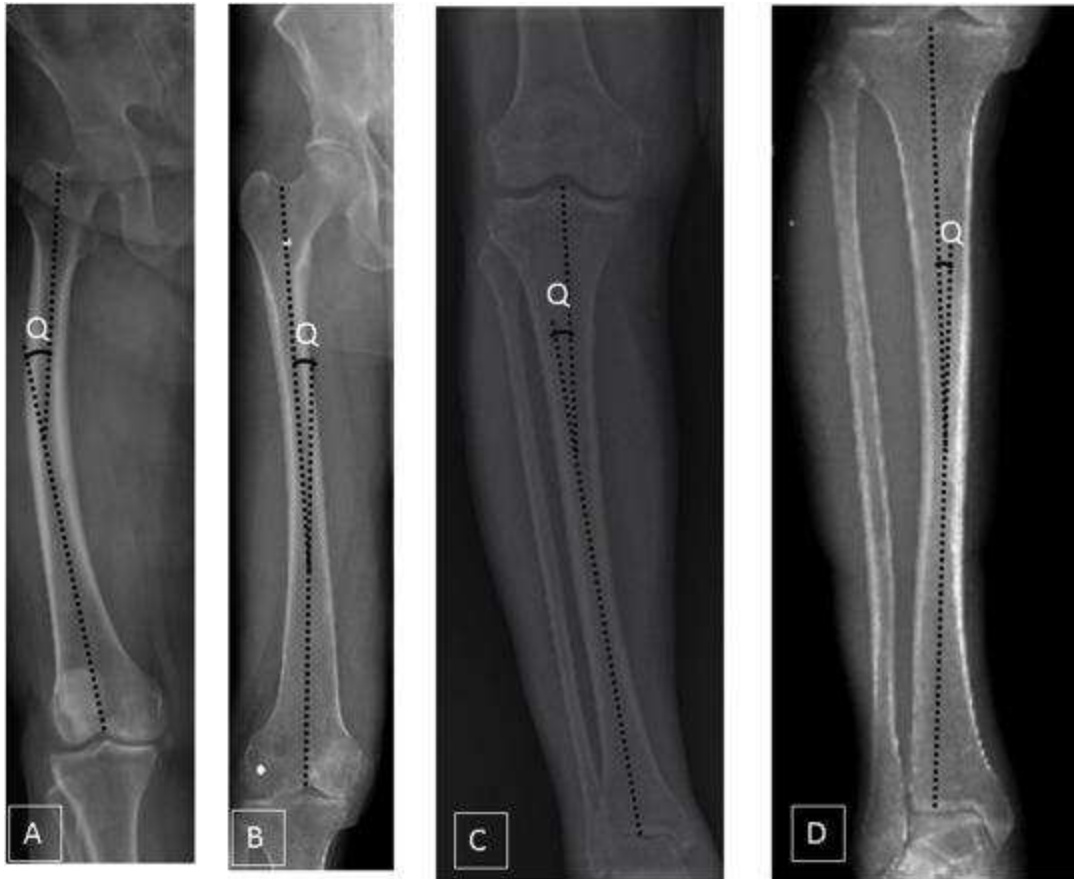

Fig. 2. Bowing was calculated from the angle formed between the line connecting proximal and distal mid-cortical centres for both femur and tibia (Q). It was defined as vara if there was a lateral bowing greater  $2^{\circ}$  (A,C) and valgus if there was medial bowing greater than  $2^{\circ}$  (B,D).

### 2.1.3. Condylar plateau angle

The condylar plateau angle (CPA) was calculated by finding the angle between the line tangential to the femoral condyles and a line tangential to both the tibial plateau (Fig 1). When the lines converged at the medial side of the joint, it was denoted by a negative sign and by a positive value when it diverged. Values that were greater than  $0^{\circ}$  were considered as valgus and lesser than  $-3$  as varus.<sup>5</sup>

To determine intra and inter-observer reliabilities of the radiographic assessment 2 investigators performed all the radiographic assessment in 30 randomly selected radiographs. The Interclass correlation coefficient (ICC) was used to measure intra and inter-observer reliabilities for the radiographic assessment. The ICC measured to be  $> 0.85$  for all measurements. Based on the observed reliability of the results, measurements taken by a single investigator (DNS) were used for the analysis.



### 3. Statistical analysis

All analyses were done using Stata software version 14.2. Quantitative data was described using mean and standard deviation with 95% confidence intervals. Ordinal logistic regression was used to evaluate the odds of OA outcome (severity of osteoarthritis) according to the parameters assessed. Thereafter a multivariate regression analysis was performed to predict the effect of each parameter on the severity of OA (Table 2). We performed repeated measures of analysis of variance (ANOVA) to compare the values among 5 different subgroups (grades of OA), and performed a post hoc analysis by Fisher's PLSD test to document the trend of deformity. A P-value of <0.05 was considered indicative of a statistically significant difference.

Table 1. Baseline demographic characteristic of study population.

AGE	53.56 (±11.08)		
GENDER	56.56% females		
BMI	23.09 (±6.20)		
Other joint pain	44.6%		
Mean duration of symptoms	2.5 years		
Co-morbidities			
Hypertension	32%		
Diabetes mellitus	25%		
Thyroid disorder	8%		
OA classification (K &L)	Percentage of limbs involved	Right	Left
o	14.59%	7.24	7.35
I	22.77%	11.49	11.28
II	21.01%	10.45	10.55
III	22.98%	12.21	10.76
IV	18.53%	8.48	10.04

Table 2. Showing Multivariate Ordinal logistic regression analysis of assessed parameters and their significance.

		Odds Ratio [95% Conf. Interval]	Adjusted Odds Ratio [95% Conf. Interval]	P value
Mechanical angle	varus	2.93(2.28–3.77)	1.97(0.70–1.34)	<0.01
	valgus	3.14(1.72–5.71)	1.78 (0.96–3.32)	0.06
Femoral bowing	varus	1.60(0.45–0.82)	1.69(0.50–0.94)	0.02
	valgus	0.20(0.14–0.28)	0.24(0.16–0.37)	<0.01
Tibial bowing	varus	4.47(3.46–5.78)	4.44(3.36–5.86)	<0.01
	valgus	1.46(1.03–2.08)	1.59(1.09–2.31)	0.01
Con-plat angle	varus	2.09(1.56–2.79)	2.46(1.79–3.38)	<0.01
	valgus	2.96(1.003–8.75)	1.96(0.68–5.64)	0.21

## 4. Results

The study comprised of 966 limbs. The mean age was 53.56 years and 56.56% of the participants were women. Table 1 characteristics of the total study population and percentage of limbs affected by different grades of OA respectively.

### 4.1. Key parameters assessed

#### 4.1.1. Hip knee ankle axis angle (HKAA)

The mean HKAA angle was 174.5° (Range- 22.27val –27.3varus; SD 6.48). 65.8% of the limbs were in varus (<177°) and 3.8% of the limb were in valgus (>183°). Positive association was seen between the varus malalignment of the knee and OA (OR 1.97, 95% CI: 0.70–1.34, p < 0.01) as opposed to valgus malalignment, where no association was seen. An increase in the varus alignment was noted with an increase in grade of OA (P < 0.01 for grade 0 vs grade 1, grade 1 vs grade 2, grade 2 vs grade 3 and grade 3 vs grade 4) (Fig. 3).

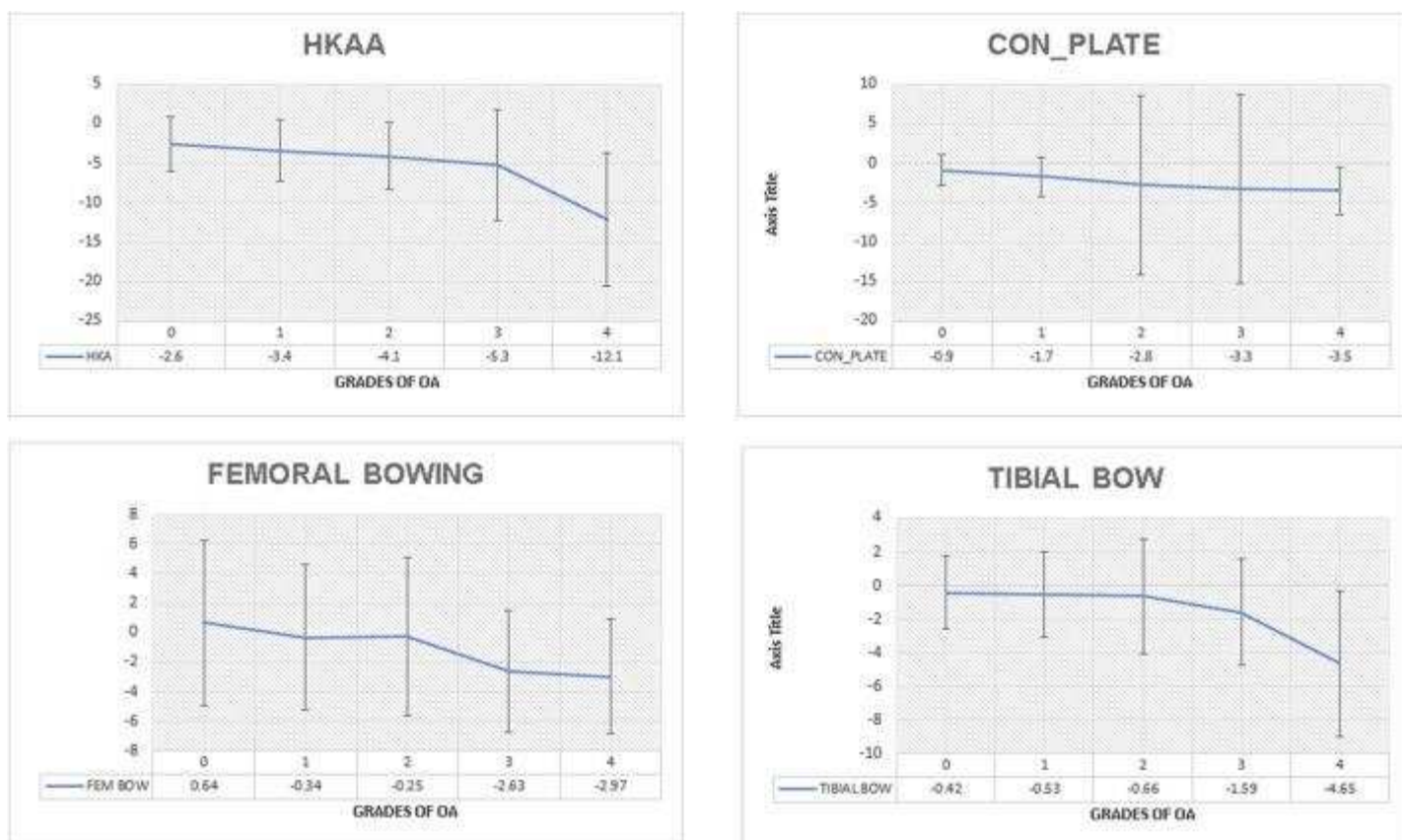


Fig. 3. Showing mean value of parameters assessed with grades of OA. An increase in varus can be seen with a subsequent increase in grade of OA. (X-axis depicts the grade and y-axis depicts the value).

#### 4.1.2. Femoral bowing

The mean femoral bowing was  $-1.19^\circ$  (Range- $13.5^\circ$ val  $-9.82^\circ$ var, SD 4.95). 55.8% of the limbs had femoral varus  $>2^\circ$ . A positive association was seen between OA and femoral varus (OR 1.69, 95% CI: 0.50–1.94,  $p = 0.02$ ) (Table 2). The lateral bowing of femur was seen in those with early stage OA (Grade 1) and increased with an increase in the grades of OA ( $P < 0.01$  for grade 0 vs grade 1, grade 2 vs grade 3, and grade 3 vs grade 4) (Fig. 3). On the other hand femoral valgus bowing had a negative association on OA (OR 0.24, 95% CI: 0.16–0.37,  $p < 0.01$ ).

#### 4.1.3. Tibial bowing

The mean tibial bowing was  $-1.54^\circ$  (Range- $8.16^\circ$ val  $-17.58^\circ$ var; SD 3.58). 41.4% of the limbs had tibia vara  $>2^\circ$  and 12.11% of the limbs had tibia valga. A positive association was seen with both tibia valga and vara with OA (Table 2). Also a significant decrease in the value of the tibial bowing was observed with an increase in the severity of the OA grades ( $p < 0.01$ ).

for grade 0 vs grade 1, grade 1 vs grade 2, grade 2 vs grade 3, and grade 3 vs grade 4) (Fig. 3).

#### 4.1.4. Condylar plateau angle (CPA)

81.88% of the limbs were found to have varus angulation as compared to 12.5% of the limbs having valgus. A positive association was seen between the varus CPA and OA (Table 2) A decreased in the values was observed with an increase in grade of OA (p < 0.01 for Grade 0 vs Grade 1, Grade 1 vs Grade 2 and Grade 2 vs Grade 3) (Fig. 3). No significant association was observed between the valgus CPA and OA.

No significant difference was seen with respect to side. Percentage of limbs involved and respective values of different parameters assessed have been summarised in Table 3, Table 4

Table 3. Percentage of limbs with respective deformity having different grades of osteoarthritis.(HKA-Hip knee ankle axis angle; CON-PLAT-Condylar plateau)

	HKA VARUS	HKA VALGUS	FEMORAL VARUS	FEMORAL VALGUS	TIBIA VARUS	TIBIA VALGUS	CON- PLAT VARUS	CON- PLAT VALGUS
Grade 0 (n = 141)	46.09%	2.8%	43.9%	39.71%	6.77%	11.97%	20.73%	33.33%
Grade 1 (n = 221)	58.82%	2.26%	51.54%	33.48%	15.79%	29.06%	23.76%	16.66%
Grade 2 (n = 203)	64.03%	3.94%	53.20%	33.49%	16.04%	25.64%	20.6%	16.66%
Grade 3 (n = 222)	69.36%	5.85%	65.76%	9.4%	27.57%	24.79%	21.99%	25%
Grade 4 (n = 179)	86.59%	3.91%	59.21%	6.7%	33.83%	8.55%	12.89%	8.33%

Table 4. Mean values of assessed radiological parameters of different groups (HKAA var = varus, val = Valgus, femoral bowing; -ve: lateral bowing, +ve: medial bowing; tibial bowing; -ve: lateral bowing, +ve: medial bowing, CPA -ve: medial convergence, +ve lateral convergence).

	MEAN	RANGE	MEAN	RANGE	MEAN	RANGE
HKAA	174.50 deg	22.27val- -27.3var	183.04 deg	0.01val- 2.27val	173.04 deg	3var-27.3var
FEMORAL BOWING	-1.19 deg	13.5val- -9.82var	0.78 deg	13.5val- 9.5var	-1.54 deg	9.15 valgus - 9.82 varus
TIBIAL BOWING	-1.54 deg	8.16val- 17.58var	0.88 deg	8.16val- 4.6var	-1.96 deg	5.9 valgus - 17.58 varus
CONDYLAR PLATEAU ANGLE	-2.53 deg	9.49val- 12.69var	-1.4 deg	9.49val- 6.57var	-2.74 deg	6.69 valgus - 12.69 varus

MEAN	RANGE	MEAN	RANGE	MEAN	RANGE
OVERALL (N = 966)		VALGUS GROUP (N = 141)		VARUS GROUP (N = 825)	

## 5. Discussion

The present study provides an insight into the factors associated with osteoarthritis by analysis of 966 limbs. Malalignment is an important risk factor for initiation and progression of osteoarthritis (OA).<sup>4</sup> There have been few studies that have considered the effect of anatomy on the incidence and severity of OA.<sup>4, 8, 9, 12</sup>

In concordance with other studies we found a significant association of varus malalignment (HKA<177°) and osteoarthritis. Although most previous studies<sup>8, 10, 20</sup> suggest that valgus malalignment is associated with degenerative changes, the current study did not find this association. We think that this might be due to a very low percentage of limbs having valgus malalignment (3.8%, assessed by HKA). Crookes and colleagues<sup>8</sup> showed a significant association of OA and with femoral abnormality and condylar plateau angle. They reported that a reduced distal femoral valgus angle and an enlarged condylar plateau angle with a pattern of focal joint degradation in the tibiofemoral compartment and malalignment of the limb were the main indicators of the progression of OA. However, their study did not take femoral and tibial bowing into account. To include these details, we calculated the same through our morphometric software. In the current study it was observed that the odds of having OA increased with an increase in the bowing and there was a significant switch from the medial femoral bowing to the lateral femoral bowing with increasing grade of OA suggesting a role in the progression of OA. Our result is supported by the findings of Matsumo and colleagues<sup>4</sup> who analysed 454 OA affected knees and reported a change of the lateral femoral bowing with increasing severity of OA. Yazdi et al.<sup>16</sup> conducted a study in normal healthy subjects, wherein they found proximal and distal half of anatomical axis to pass medial to the intercondylar notch in 82% and 84% respectively. Nakano et al. too observed a medial femoral bowing in young Japanese population. This is the first study to document the negative association of OA with medial femoral bowing (Table 2) wherein we also observed lower percentage of limbs having valgus bowing at higher OA grades (Table 3), thus putting forth the relevance of medial bowing with OA. However, further studies are required to find its clinical significance. We found an average lateral femoral bowing of 1.96° and an average medial bowing of 0.88° in the knees having varus and valgus alignment similar to study conducted by Shetty et al.<sup>17</sup> (Table 4). 88% of the limbs undergoing TKA were observed to have a mean lateral bowing of 5.4° and 77% of limbs in the control group with 3.0° in the control group by Lasam et al.<sup>14</sup> Interestingly, 23.3% of the control group exhibited knee symptoms and mild OA changes despite having medial or no bowing which

would agree with our results. We found that 14.59% of the limbs with symptoms had a mean medial femoral bow of  $0.64^\circ$  and no sign of radiographic OA.

Tibial bowing has gained a lot of importance recently. It is not uncommon to see tibial bowing with end stage osteoarthritis in Asian populations. Yau et al.<sup>13</sup> studied the incidence of femoral or tibial bowing in the coronal plane in a Chinese population and found out that 44% of the femorae and 30% of the tibiae had bowing greater than  $2^\circ$  in limbs undergoing TKA. Saibaba et al.<sup>18</sup> studied 48 osteoarthritic Indian knees radiologically and reported that 58.3% of the limbs had extra articular varus deformity of the tibia ( $5\text{--}19^\circ$ , mean  $9^\circ$ ). Our results suggest that in the Indian population with knee pain, 41.4% had extraarticular tibial varus deformity at different stages of OA. The percentage of limbs having tibia vara is less as compared to Saibaba et al.,<sup>18</sup> since the number of limbs recruited in our study is greater and the study group recruited in their study were suffering from end stage knee OA. Shetty et al. showed a positive correlation of MPTA with HKA and suggested that tibial plateau inclination might be involved in OA etiopathogenesis. Matsumo et al.<sup>4</sup> observed an increased tibial plateau steeping in knees affected with severe OA. Victor JM et al.<sup>19</sup> in his study concluded that advanced medial arthritis is the result of joint line divergence from parallel to the floor. Algahamdi et al.<sup>20</sup> found 53% of the tibia having valga deformity in patients with OA. Our study added a new speculation that both tibial vara and valga is positively associated with OA ( $p < 0.01$ ) and as with femoral bowing there is a significant increase in the lateral tibial bowing with higher grade of OA (Fig. 2). We also observed an increase in the proportion of limbs having varus femoral bowing and tibial bowing (both varus and valgus) at higher OA grades (Table 3). None of the studies so far have enlisted tibial bowing as one of the factors associated with OA.

In our study, varus condylar plateau angle was found to have a positive association with OA though we did not see the same with valgus CPA. A significant increase in the varus as observed with increasing OA grade. This finding of ours suggest that there is increased articular surface erosion of both the femur and the tibia causing with an increase in severity of OA. Moreover, this may also hint towards increased varus condylar orientation and the varus tibial plateau inclination with higher grade of OA suggesting their role in the aetiopathogenesis of OA.

## **6. Limitation of the study**

There were certain limitations to this study. Firstly, our design was cross-sectional rather than longitudinal although sufficient subjects were included to assess the limb alignment. Secondly it lacked ethnic diversity, and thus our observation may not reflect the same in other population. Thirdly, our result may lack clinical relevance which should be addressed

by further research, and more verification tests. And lastly, we were unable to assess torsional deformities as it necessitated 3D imaging.

## **7. Conclusion**

We analysed 966 Indian limbs with knee pain in different grades of OA and found a prevalence of 55.79% of the femur having varus bowing and 41.7% of the tibia having varus bowing. Positive association was seen between the HKAA, Condylar plateau angle, femoral and the tibial bowing with OA, reflecting its role in etiopathogenesis of OA. Change in the HKAA, curvature of femur and the tibia and the condylar plateau angle was also seen with higher grades of OA.

## **Contributions**

Nayak M; Drafting of the article, Critical revision of the article for important intellectual content, Collection and assembly of data, Final approval of the article.

Kumar V; Conception and design, Provision of study materials or patients, Final approval of the article.

Kanojiya G; Provision of study materials or patients and analysis and interpretation of the data.

Srivastava D N; Analysis and interpretation of the data, Critical revision of the article for important intellectual content, final approval of the article.

Mellon S; Analysis and interpretation of the data, Critical revision of the article for important intellectual content, final approval of the article.

Pandit H; Conception and design, Final approval of the article.

Malhotra R; Conception and design, Drafting of the article, Critical revision of the article for important intellectual content, final approval of the article.

## **Role of the funding source**

The study was conducted under project approved by UK-India Education and Research Initiative (UKIERI) and funded by Department of Science and technology, Ministry of Science and Technology, New Delhi, India.

## Declaration of competing interest

All authors have no potential conflicts of interest, including financial interests, activities, relationships, and affiliations, to disclose.

## References

- 1 J.T. Dearborn, C.L. Eakin, H.B. Skinner Medial compartment arthrosis of the knee  
Am J Orthop Belle Mead NJ, 25 (1) (1996 Jan), pp. 18-26
- 2 J.H. Kellgren Osteoarthritis in patients and populations  
Br Med J, 2 (5243) (1961 Jul 1), pp. 1-6
- 3 J. Kraus, E. Smith, J.V. Meter, N. Borhani, C. Franti, P. Lipscomb An epidemiological study of severe osteoarthritis  
Orthopedics, 1 (1) (1978 Jan 1), pp. 37-42
- 4 T. Matsumoto, M. Hashimura, K. Takayama, et al. A radiographic analysis of alignment of the lower extremities--initiation and progression of varus-type knee osteoarthritis  
Osteoarthr Cartil, 23 (2) (2015 Feb), pp. 217-223
- 5 D. Paley, J.E. Herzenberg, K. Tetsworth, J. McKie, A. Bhave Deformity planning for frontal and sagittal plane corrective osteotomies  
Orthop Clin N Am, 25 (3) (1994 Jul), pp. 425-465
- 6 T.D.V. Cooke, L. Harrison, B. Khan, A. Scudamore, M.A. Chaudhary Analysis of limb alignment in the pathogenesis of osteoarthritis: a comparison of Saudi Arabian and Canadian cases  
Rheumatol Int, 22 (4) (2002 Aug), pp. 160-164
- 7 D. Siu, T.D. Cooke, L.D. Broekhoven, et al. A standardized technique for lower limb radiography. Practice, applications, and error analysis  
Investig Radiol, 26 (1) (1991 Jan), pp. 71-77
- 8 T.D. Cooke, R.A. Scudamore, J.T. Bryant, C. Sorbie, D. Siu, B. Fisher A quantitative approach to radiography of the lower limb. Principles and applications  
J Bone Joint Surg Br, 73 (5) (1991 Sep), pp. 715-720
- 9 A.B. Mullaji, S.V. Marawar, V. Mittal A comparison of coronal plane axial femoral relationships in Asian patients with varus osteoarthritic knees and healthy knees  
J Arthroplast, 24 (6) (2009 Sep), pp. 861-867
- 10 E. Thienpont, P.E. Schwab, O. Cornu, J. Bellemans, J. Victor Bone morphotypes of the varus and valgus knee  
Arch Orthop Trauma Surg, 137 (3) (2017 Mar), pp. 393-400
- 12 R. Nagamine, H. Miura, C.V. Bravo, et al. Anatomic variations should be considered in total knee arthroplasty  
J Orthop Sci Off J Jpn Orthop Assoc, 5 (3) (2000), pp. 232-237



- 13 W.P. Yau, K.Y. Chiu, W.M. Tang, T.P. Ng Coronal bowing of the femur and tibia in Chinese: its incidence and effects on total knee arthroplasty planning  
J Orthop Surg Hong Kong, 15 (1) (2007 Apr), pp. 32-36
- 14 M.P.G. Lasam, K.J. Lee, C.B. Chang, Y.G. Kang, T.K. Kim Femoral lateral bowing and varus condylar orientation are prevalent and affect axial alignment of TKA in Koreans  
Clin Orthop, 471 (5) (2013 May), pp. 1472-1483
- 15 B. Hagstedt, O. Norman, T.H. Olsson, B. Tjörnstrand Technical accuracy in high tibial osteotomy for gonarthrosis  
Acta Orthop Scand, 51 (6) (1980 Dec), pp. 963-970
- 16 H. Yazdi, A. Nazarian, J.Y. Kwon, et al. Anatomical axes of the proximal and distal halves of the femur in a normally aligned healthy population: implications for surgery  
J Orthop Surg, 13 (1) (2018 Jan 31), p. 21
- 17 G.M. Shetty, A. Mullaji, S. Bhayde, K.W. Nha, H.K. Oh Factors contributing to inherent varus alignment of lower limb in normal Asian adults: role of tibial plateau inclination  
The Knee, 21 (2) (2014 Mar), pp. 544-548
- 18 B. Saibaba, M.S. Dhillon, D.K. Chouhan, R.K. Kanojia, M. Prakash, V. Bachhal Significant incidence of extra-articular tibia vara affects radiological outcome of total knee arthroplasty  
Knee Surg Relat Res, 27 (3) (2015 Sep), pp. 173-180
- 19 J.M.K. Victor, D. Bassens, J. Bellemans, S. Gürsu, A.A.M. Dhollander, P.C.M. Verdonk Constitutional varus does not affect joint line orientation in the coronal plane  
Clin Orthop, 472 (1) (2014 Jan), pp. 98-104
- 20 A. Alghamdi, M. Rahmé, M. Lavigne, V. Massé, P.-A. Vendittoli Tibia valga morphology in osteoarthritic knees: importance of preoperative full limb radiographs in total knee arthroplasty  
J Arthroplast, 29 (8) (2014 Aug), pp. 1671-1676

