

LONDON
SCHOOL of
HYGIENE
& TROPICAL
MEDICINE



LSHTM Research Online

Bonavina, Luigi; Ariani, Andrea; Ficano, Leonardo; Iannuzziello, Domenico; Pasquale, Luigi; Aragona, Salvo Emanuele; Drago, Lorenzo; Ciprandi, Giorgio; On Digestive Disorders, Italian Study Group; (2019) Lactobacillus plantarum LP01, Lactobacillus lactis subspecies cremoris LLC02, and Lactobacillus delbrueckii LDD01) in patients undergoing bowel preparation. Acta bio-medica : Atenei Parmensis, 90 (7-S). pp. 13-17. ISSN 0392-4203 DOI: <https://doi.org/10.23750/abm.v90i7-S.8650>

Downloaded from: <http://researchonline.lshtm.ac.uk/id/eprint/4656131/>

DOI: <https://doi.org/10.23750/abm.v90i7-S.8650>

Usage Guidelines:

Please refer to usage guidelines at <https://researchonline.lshtm.ac.uk/policies.html> or alternatively contact researchonline@lshtm.ac.uk.

Available under license: <http://creativecommons.org/licenses/by/2.5/>

<https://researchonline.lshtm.ac.uk>

Lactobacillus plantarum LP01, *Lactobacillus lactis subspecies cremoris* LLC02, and *Lactobacillus delbrueckii* LDD01 in patients undergoing bowel preparation

Luigi Bonavina¹, Andrea Arini², Leonardo Ficano³, Donato Iannuzziello⁴, Luigi Pasquale⁵, Salvo Emanuele Aragona⁶, Lorenzo Drago⁷, Giorgio Ciprandi⁸, and Italian Study Group on digestive disorders*

¹Surgery Unit, San Donato Hospital, Milan, Italy; ²Gastroenterology Unit, Policlinico Paolo Giaccone, Palermo, Italy; ³Gastroenterology Unit, University of Palermo, Palermo, Italy; ⁴Digestive Endoscopy, Mater Dei Hospital, Bari, Italy; ⁵Gastroenterology Unit, Avellino Hospital, Avellino, Italy; ⁶Center of Regenerative Medicine, Humanitas Mater Domini, Castellanza (VA), Italy; ⁷Microbiology Department, University of Milan, Italy; ⁸Allergy Clinic, Casa di Cura Villa Montallegro, Genoa, Italy

Summary. Bowel preparation (BP) for colonoscopy induces significantly changes in gut microbiota and elicit intestinal symptoms. Impaired microbiota causes an intestinal dysbiosis. Consequently, probiotics may counterbalance the disturbed microbiota after BP. The current survey evaluated the efficacy and safety of Abincol[®], an oral nutraceutical containing a probiotic mixture with *Lactobacillus plantarum* LP01 (1 billion of living cells), *Lactobacillus lactis subspecies cremoris* LLC02 (800 millions of living cells), and *Lactobacillus delbrueckii* LDD01 (200 millions of living cells), in 2,979 outpatients (1,579 males and 1,400 females, mean age 56 years) undergoing BP. Patients took 1 stick/daily for 4 weeks after colonoscopy. Abincol[®] significantly diminished the presence and the severity of intestinal symptoms and improved stool form. In conclusion, the current survey suggests that Abincol[®] may be considered an effective and safe therapeutic option in the management of patients undergoing BP. (www.actabiomedica.it)

Key words: bowel preparation, gut microbiota, colonoscopy, probiotics, survey

Introduction

The human intestinal tract contains a large number of diverse microbes, some of which are associated

with the faeces, while others are associated with the gut mucosa. Most of these microbes are bacteria and constitute a unique and dense ecosystem named microbiota (1). Many studies investigated human gut

***Italian Study Group of digestive disorders:** Annicchiarico Raffaele, Antongiulio Bucci, Arrigoni Arrigo, Bargiggia Stefano, Beretta Paolo, Berni Canani Marcella, Bertino Antonino, Bova Filippo, Bresci Giampaolo, Buda Carmelo, Camilleri Salvatore, Caronna Stefania, Cavallo Gregorio, Chahin Nabil Jamil, Clara Virgilio, Corrado Selvaggio, Cozzoli Giovanni, Crescenzi Ugo, Dario Raimondo, D'arpa Francesco, Dattola Antonello, Deiana Davide, Dell'Anna Armando, Di Fenza Sergio, Di Lorenzo Fernando, Di Napoli Angelo, D'onofrio Vittorio, Ferrini Giovanni, Ferrulli Domenico, Finizio Roberto, Gaffuri Nicola, Garcea Maria Rita, Genova Salvatore, Giorgio Pietro, Giovannone Maurizio, Giuseppe Giuliana, Guarnieri Giovanni, Gullotta Renzo, Leonardi Giuseppe, Magri Giovanni, Maisto Tamaro, Mancino Mariagrazia, Manes Gianpiero, Marchi Santino, Marin Renato, Marino Maria, Mazzi Manuele, Menasci Francesca, Morabito Lo Prete Antonio, Murer Francesca, Neri Bortoluzzi Francesco, Pallio Socrate, Palma Antonio, Pardocchi Davide, Pinto Antonio, Pio Palieri Antonio, Pisani Antonio, Privitera Antonello, Pulitanò Raffaella, Pumpo Rossella, Quattraro Francesco, Raguzzi Ivana, Rainisio Cesarina, Razzolini Giulia, Revello Olimpia, Rinaldo Nicita, Rivellini Giuseppe, Sabadini Guidorenato, Salvia Marcello, Sarrantonio Gennaro, Savarino Edoardo, Scarcelli Antonella, Schettino Pietro, Schicchi Angelo, Schifino Luigi, Sediari Luca, Shaini Endrit, Spada Cristiano, Spinelli Fernando, Tifi Lorenza, Trovato Claudio, Vassallo Roberto, Vinti Maurizio, Zappatore Francesca, Zulli Claudio.

microbiota, including the Human Microbiome Project in the United States, to define its physiological and pathological role (2).

It is well known that antibiotics may significantly affect the intestinal microbiota (3). Bowel preparation (BP) may also modify critically microbiota (4). BP consists of large doses of laxatives to evacuate most if not all of the stool from the colon. Typically, such a preparation is taken by the patient overnight before the procedure, resulting in 10–20 bowel movements, most of which are diarrheal stools. Therefore, BP significantly affect the colonic ecosystem. In particular, polyethylene glycol-type BP causes loss of superficial mucus in 96% of patients: it contributes consequently to profound alteration of microbiota (5). In addition, BP effects vary in health and in disease as it has been reported that BP affects various microbiota-related diversity metrics in inflammatory bowel disease (IBD) and non-IBD samples and the mucosal and luminal compartments, differently (4). Overweight also influences microbiota changes after BP (6).

The relevance of these concepts relies on the huge number of colonoscopies performed worldwide, e.g. just 14 millions/year in the United States (7). In addition, colonoscopy induces also symptoms persistence for some days; symptoms can be also so severe as to cause the loss of working days (8). These symptoms mainly depend on BP-induced microbiota disturbance (9). Notably, microbiota changes may persist until one month after colonoscopy (10, 11). Therefore, there is the need to counterbalance microbiota alteration in a short time. In this regard, probiotics may offer a potential therapeutic option to restore the altered gut microbiota. Two recent studies provided evidence that probiotic may significantly improve both symptoms and gut microbiota after BP (12, 13).

Abincol® is an oral nutraceutical containing a probiotic mixture with *Lactobacillus plantarum* LP01 (1 billion of living cells), *Lactobacillus lactis subspecies cremoris* LLC02 (800 millions of living cells), and *Lactobacillus delbrueckii* LDD01 (200 millions of living cells) and it has been recently placed on the market.

On the basis of this background, an Italian survey explored the pragmatic approach of a group of gastroenterologists in the management of intestinal dysbiosis after BP in clinical practice. Therefore, the aim of the

current survey was to evaluate the efficacy and safety of Abincol® in outpatients after colonoscopy.

Materials and Methods

The current survey was conducted in 83 Italian Gastroenterology centers, distributed in the whole Italy, so assuring a wide and complete national coverage, during the fall-winter 2018–2019. Gastroenterologists were asked to recruit all consecutive outpatients undergoing BP for colonoscopy.

Patients were consecutively recruited during the specialist visit. The inclusion criteria were: to have the indication for colonoscopy, such as presence of intestinal complaints, both genders, and adulthood. Exclusion criteria were to have comorbidities and concomitant medications able to interfere the evaluation of outcomes.

All patients signed an informed consent. All the procedures were conducted in a real-world setting.

The treatment course lasted 4 weeks. The oral nutraceutical Abincol® (Aurora Biofarma, Milan, Italy) was taken following the specific indications, such as one stick/daily. Patients were visited at baseline (T0), and after 4 weeks (T1).

Clinical examination was performed in all patients at T0, and T1. The following symptoms were investigated: abdominal pain, abdominal bloating, flatulence, and borborygmia. They were evaluated before BP and at T1.

These symptoms were assessed as present/absent and were scored using a four-point scale (0=absent, 1=mild, 2=moderate, 3=severe), but for abdominal pain the scale was 5-point (4=very severe).

A physical examination of stool was performed using the Bristol stool form scale (16).

Safety was measured by reporting the occurrence of adverse events.

All clinical data were inserted in an internet-platform that guaranteed the patients' anonymity and the findings' recording accuracy.

The paired T-test was used. Statistical significance was set at $p < 0.05$. Data are expressed as medians and 1st and 3rd quartiles. The analysis was performed using STATA, College Station, Texas, USA.

Results

Globally, 2,979 outpatients (1,579 males and 1,400 females, mean age 56 years) were visited and completed the treatment course.

The frequency of symptoms (abdominal pain, abdominal bloating, flatulence, and borborygmi) at baseline (T0) and at T1 is reported in Table 1 and 2. In particular, abdominal pain and abdominal bloating were the most common symptoms at baseline. The frequency of both significantly diminished after the treatment course.

Consistently, the severity of the most relevant symptoms did significantly diminish after the treatment (Figure 1). In particular, abdominal pain and bloating significantly diminished at T1 ($p < 0.001$ respectively for both symptoms).

Table 1. Frequency of patients for each symptom at baseline (T0). M=males; F=females, Mean age in years

N=2,979	T0		M/F	Mean age
	n	%		
Abdominal pain	2387	80.1%	1256/1131	55
Abdominal bloating	2102	70.6%	1090/1012	56
Flatulence	1936	65.0%	1037/899	56
Borborygmi	1690	56.7%	872/818	56

Table 2. Comparison of proportion of patients with symptoms at baseline (T0) and at T1

	T0		T1		p
	n	n	%	Diff %	
Abdominal pain	2387	1124	47.1%	-52.9%	<0.001
Abdominal bloating	2102	1039	49.4%	-50.6%	<0.001
Flatulence	1936	948	49.0%	-51.0%	<0.001
Borborygmi	1690	677	40.1%	-59.9%	<0.001

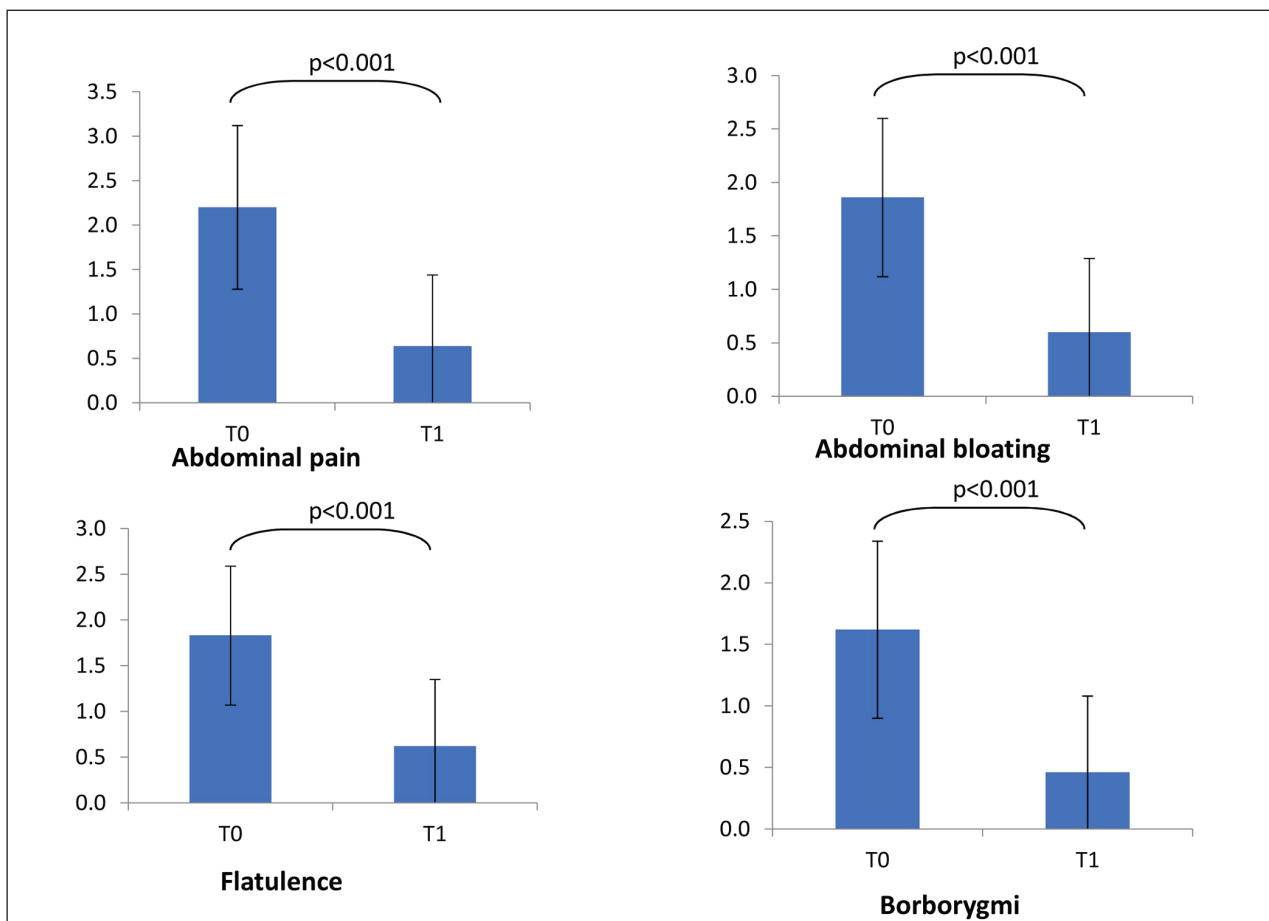


Figure 1. Symptoms severity at baseline (T0) and at T1. Symptoms' score scale was 0-3 for all symptoms but abdominal pain (0-4). Comparisons were made by paired Wilcoxon test. * = $p < 0.001$

In addition, stool form significantly improved as a normal form (type 3 and 4) was detectable in 36.3% at baseline, and in 53.5% at T1 ($p < 0.001$ as linear trend).

The treatment was well tolerated by all patients and no clinically relevant adverse event was reported.

Discussion

Drago and colleagues reported relevant and persistent changes in the intestinal bacteria composition after colonic lavage (10). Actually, the relative abundance among the different bacterial phyla had reduced after the BP, in particular, there was a significant increase in *Proteobacteria* abundance and a decrease in *Firmicutes* abundance. This intestinal dysbiosis has been linked to diarrhea, and more interestingly, it has been reported an association between the increase in *Proteobacteria* and the onset of moderate to severe diarrhea in children from low-income countries (14). An increased frequency of *Enterobacteriaceae* has been observed immediately after BP (10). It has to be noted that *Enterobacteriaceae* include a number of nosocomial pathogens with considerable antibiotic resistance, which may proliferate and act as pathogens when not counteracted by the physiological gut microbiota, but also act as a clinically relevant antibiotic-resistance reservoir in the intestinal environment (15). Moreover, *Enterobacteriaceae* were markedly changed even after one month (10). These microbiota changes are associated with BP-dependent clinical feature. Hence, there is the need to improve the impaired gut microbiota after BP: in this regard, probiotics could be an attractive therapeutic strategy.

The current survey demonstrated that a 4-week course of Abincol® was able to significantly improve digestive symptoms and stool form. These outcomes are consistent with a previous randomized and placebo-controlled study showing that a single capsule of a probiotic containing 2.5×10^{10} CFUs of *L. acidophilus* NCFM and *B. lactis* Bi-07 taken daily starting on the night after colonoscopy resulted in an earlier resolution of abdominal pain from 2.78 to 1.99 days (12). Nevertheless, a sub-analysis of that study revealed that there was no significant difference between groups in post-procedural discomfort, bloating nor time to re-

turn of normal bowel function (13). However, a subgroup analysis of the patients with preexisting symptoms showed a reduction in incidence of bloating with the use of probiotics. This subset of patients is consistent with our population as presented symptoms before BP.

Therefore, the current survey demonstrated that an oral probiotic mixture with *Lactobacillus plantarum* LP01 (1 billion of living cells), *Lactobacillus lactis subspecies cremoris* LLC02 (800 millions of living cells), and *Lactobacillus delbrueckii* LDD01 (200 millions of living cells) administered for 4 weeks after colonoscopy was able to significantly reduce intestinal symptoms. The significantly improvement of stool form in many patients could be considered the indirect proof of the mechanism of action of Abincol® as it modified the intestinal microbiota inducing a physiological digestive function.

In addition, Abincol® was safe and well tolerated.

It is conceivable that the present survey cannot be considered a formal investigative study. Consequently, further studies should be conducted by a rigorous methodology, such as designed according to randomized-controlled criteria.

On the other hand, the strength of this survey is the huge number of enrolled patients and the real-world setting. The outcomes could therefore mirror the facts observable in clinical practice.

In conclusion, the current survey suggests that Abincol® may be considered an effective and safe therapeutic option in the management of patients undergoing BP.

The current article was supported by Aurora Biofarma, Italy

References

1. Eckburg PB, Bik EM, Bernstein CN. Diversity of the human intestinal microbial flora. *Science* 2005; 308: 1635-8.
2. Turnbaugh PJ, Ley RE, Hamady M. The human microbiome project. *Nature* 2007; 449: 804-10.
3. Dethlefsen L, Relman DA. Incomplete recovery and individualized responses of the human distal gut microbiota to repeated antibiotic perturbation. *Proc Natl Acad Sci USA* 2011; 108(Suppl 1): 4554-61.
4. Shobar RM, Velinei S, Keshavarzian A, Swanson G, DeMeo MT, Melson JE, et al. The effects of bowel preparation

- on microbiota-related metrics differ in health and inflammatory bowel disease and for the mucosal and luminal microbiota compartments. *Clin Translat Gastroenterol* 2016; 7: e143.
5. Rappé MS, Giovannoni SJ. The uncultured microbial majority. *Annu Rev Microbiol* 2003; 57: 369-94.
 6. Chen HM, Chen CC, Chen CC, Wang SC, Wang CL, Huang CH, et al. Gut microbiome changes in overweight male adults following bowel preparation. *BMC Genomics* 2018; 19(Suppl 10): 904.
 7. Seeff LC, Richards TB, Shapiro JA. How many endoscopies are performed for colorectal cancer screening? Results from CDCs survey of endoscopic capacity. *Gastroenterology* 2004; 127: 1670-7.
 8. Ko C, Riffle S, Shapiro J, et al. Incidence of minor complications and time lost from normal activities after screening or surveillance colonoscopy. *Gastrointest Endosc* 2007; 65: 648-56.
 9. Dai M, Zhang T, Li Q, Cui B, Xiang L, Ding X, et al. The bowel preparation for magnetic resonance enterography in patients with Chron's disease: study protocol for a randomized controlled trial. *Trials* 2019; 20: 1.
 10. Drago L, Toscano M, De Grandi R, Casini V, Pace F. Persisting changes of intestinal microbiota after bowel lavage and colonoscopy. *Eur J Gastroenterol Hepatol* 2016; 28: 532-7.
 11. Nagata N, Tohya M, Fukuda S, Suda W, Nishijima S, Takeuchi F, et al. Effects of bowel preparation on the human gut microbiome and metabolome. *Scientific reports* 2019; 9: 4042
 12. D'Souza B, Slack T, Wong SW, Lam F, Muhlmann M, Koestenbauer J, et al. Randomized controlled trial of probiotics after colonoscopy. *ANZ J Surg* 2017; 87: E65-E69.
 13. Mullaney TG, Lam D, Kluger R, D'Souza B. Randomized controlled trial of probiotic use for post-colonoscopy symptoms. *ANZ J Surg* 2019; 89: 234-8.
 14. Pop M, Walker AW, Paulson J, Lindsay B, Antonio M, Hossain MA, et al. Diarrhea in young children from low-income countries leads to large-scale alterations in intestinal microbiota composition. *Genome Biol* 2014; 15: R76.
 15. Pace NR, Olsen GJ, Woese CR. Ribosomal RNA phylogeny and the primary lines of evolutionary descent. *Cell* 1986; 45: 325-6.
-
- Received: 27 May 2019
Accepted: 27 June 2019
Correspondence:
Giorgio Ciprandi
Via P. Boselli, 5 - 16146 Genoa, Italy
E-mail: gio.cip@libero.it