

Citation for published version:

Antony, A, Allard, A, Rambojun, A, Lovell, CR, Shaddick, G, Robinson, G, Jadon, DR, Holland, R, Cavill, C, Korendowych, E, McHugh, NJ & Tillett, W 2019, 'Psoriatic nail dystrophy is associated with erosive disease in the distal interphalangeal joints in psoriatic arthritis: a retrospective cohort study', *The Journal of Rheumatology*, vol. 46, no. 9, pp. 1097-1102. <https://doi.org/10.3899/jrheum.180796>

DOI:

[10.3899/jrheum.180796](https://doi.org/10.3899/jrheum.180796)

Publication date:

2019

Document Version

Peer reviewed version

[Link to publication](#)

This is a pre-copy-editing, author-produced PDF of an article accepted for publication in *The Journal of Rheumatology* following peer review. The definitive publisher-authenticated version Anna S. Antony, Andrew Allard, Adwaye Rambojun, Christopher R. Lovell, Gavin Shaddick, Graham Robinson, Deepak R. Jadon, Richard Holland, Charlotte Cavill, Eleanor Korendowych, Neil J. McHugh, William Tillett, 'Psoriatic Nail Dystrophy Is Associated with Erosive Disease in the Distal Interphalangeal Joints in Psoriatic Arthritis: A Retrospective Cohort Study', *The Journal of Rheumatology* Sep 2019, 46 (9) 1097-1102 is available online at: [10.3899/jrheum.180796](https://doi.org/10.3899/jrheum.180796)

University of Bath

General rights

Copyright and moral rights for the publications made accessible in the public portal are retained by the authors and/or other copyright owners and it is a condition of accessing publications that users recognise and abide by the legal requirements associated with these rights.

Take down policy

If you believe that this document breaches copyright please contact us providing details, and we will remove access to the work immediately and investigate your claim.

The Journal of Rheumatology

Psoriatic nail dystrophy is associated with erosive disease in the distal interphalangeal joints in psoriatic arthritis: a retrospective cohort study

A. Antony, A. Allard, A. Rambojun, C.R Lovell, G. Shaddick, G. Robinson, D.R. Jadon, R. Holland, C. Cavill, E. Korendowych, N.J. McHugh and William Tillett

DOI: 10.3899/jrheum.180796

<http://www.jrheum.org/content/early/2019/02/25/jrheum.180796>

1. Sign up for TOCs and other alerts
<http://www.jrheum.org/alerts>
2. Information on Subscriptions
<http://jrheum.com/faq>
3. Information on permissions/orders of reprints
http://jrheum.com/reprints_permissions

The Journal of Rheumatology is a monthly international serial edited by Earl D. Silverman featuring research articles on clinical subjects from scientists working in rheumatology and related fields.

Psoriatic nail dystrophy is associated with erosive disease in the distal interphalangeal joints in psoriatic arthritis: a retrospective cohort study

A. Antony¹, A. Allard¹, A. Rambojun², C.R Lovell,³ G. Shaddick⁴, G. Robinson⁵, D.R. Jadon^{6,9}, R. Holland⁷, C. Cavill^{1,8}, E. Korendowych¹, N.J. McHugh^{1,8} and W. Tillett^{1,8}.

Royal National Hospital for Rheumatic Diseases, Bath, UK¹

Department of Mathematics, University of Bath, Bath, UK²

Department of Dermatology, Royal United Hospital, Bath, UK³

Department of Mathematics, University of Exeter, Exeter, UK⁴

Department of Radiology, Royal United Hospital, Bath, UK⁵

Department of Rheumatology, Cambridge University Hospitals, Cambridge, UK⁶

Department of Rheumatology, Concord Repatriation General Hospital, Sydney, Australia⁷

Department of Pharmacy and Pharmacology, University of Bath, UK⁸

Department of Medicine, University of Cambridge, Cambridge, UK⁹

Contact author: Dr. William Tillett

Email: w.tillett@nhs.net

tel: +44 (0)1225448444

Mobile: +44 (0)7980960722

Fax: +44 (0)1225336809

MeSH terms: Psoriatic Arthritis, Radiography, Outcome assessment

Short title: Radiographic damage and Nail disease in Psoriatic Arthritis

Manuscript word count: 2647/3500

Abstract word count: 249/250

Abstract

Objective: To assess if the association between psoriatic nail dystrophy and radiographic damage in the hands of patients with psoriatic arthritis (PsA) is specific to the distal interphalangeal joints.

Methods: A convenience sample of patients were collated from the Bath longitudinal PsA cohort. All patients had PsA according to the CASPAR criteria, scored radiographs of their hands, and documented nail scores as measured by the Psoriatic Nail Severity Score (PNSS). Chi-square tests were performed to examine for association between features of nail dystrophy and radiographic damage in the distal interphalangeal joints (DIPjs), and proximal interphalangeal or metacarpophalangeal joints (non-DIPjs) of the corresponding digits.

Results: 134 patients were included, with a median age of 53 (IQR 44, 61) years and disease duration of 7 (IQR 3, 15) years. The presence of any form of psoriatic nail dystrophy was associated with erosion at the DIPjs of the corresponding digit (OR 1.9; 95% CI 1.23, 2.83; $p < 0.004$) and this association was primarily driven by the presence of nail onycholysis (OR 1.72; 95% CI 1.12,

2.62; $p=0.02$). Nail subungal hyperkeratosis was more strongly associated with joint space narrowing, erosions and osteoproliferation at the corresponding DIPjs compared to non-DIPjs ($p<0.001$). Nail pitting was not associated with erosions or osteoproliferation.

Conclusion: The presence of psoriatic nail dystrophy, particularly onycholysis, is associated with erosive disease at the DIPjs. Subungal hyperkeratosis is more strongly associated with erosive damage at the DIPjs than non-DIPjs. These findings support the anatomical and pathological link between nail and DIP joint disease.

Introduction:

Nail psoriasis affects between 80 to 90% of patients with psoriasis at some point in their disease course(1). There are a number of different manifestations of nail disease. Some manifestations arise from the nail bed, such as onycholysis (separation of the nail bed from the plate), subungal hyperkeratosis (thickening or lifting of the nail plate) and oil drop discolouration (red spots on the lunula), whilst others arise from the nail matrix including pitting (shallow depressions), leukonychia (pale/ white discoloration) and Beau's lines (horizontal groves in the nail)(2).

The relationship between nail disease and small joint involvement in PsA has been examined in a number of studies(3-5), as the anatomical relationship between the distal interphalangeal joint, extensor tendon insertion and the nail matrix is of significant importance in PsA. Seminal work by McGonagle and colleagues has demonstrated that extensor tendon fibres link closely with the periosteum of the distal phalanx, the nail bed and the nail matrix(6, 7), and the enthesal complex is now proposed as the initiating site of inflammation in PsA(6).

While clinical and radiographic studies appear to support the anatomical and pathological link between nail disease and distal interphalangeal joint involvement⁹⁻

¹¹, none have concurrently assessed the presence of radiographic damage at non-DIPJs to ascertain if this relationship is specific to the DIPJs.

The aim of this study was to assess if previously demonstrated associations between psoriatic nail dystrophy (pitting, onycholysis, subungal hyperkeratosis and severe nail deformity) and radiographic damage (erosion, osteoproliferation and joint space narrowing) (Figure 1) in patients with PsA are unique to the distal interphalangeal joints.

Patients and Methods:

Study Subjects:

Patients were selected from the Bath PsA cohort, in which patients have clinical and patient-reported outcomes collected during routine clinical appointments. A convenience sample of patients was selected for inclusion if there were completed nail assessments and scored radiographs of hands. All patients were ≥ 18 years old and met the Classification criteria for Psoriatic ARthritis (CASPAR)(8). Demographic data collected included age, sex and duration of disease at the time of radiographic assessment. Medical records were retrospectively reviewed to determine the presence of co-existing diagnoses of osteoarthritis and gout.

Nail Assessment:

Nail disease was measured using the Psoriatic Nail Severity Score (PNSS, range 0-40 in hands) which documents the presence or absence of pitting, onycholysis, subungal hyperkeratosis and severe nail destruction, with a maximum score of one per feature in each nail(5, 9). Severe nail destruction is defined as the presence of psoriatic nail dystrophy on both sides of the nail (5). Cross-sectional PNSS data was selected at the time point where psoriatic nail dystrophy was most severe in each patient.

Radiographic Scoring:

Antero-posterior radiographs of the hands, wrists and feet are taken every two years for clinical monitoring in the Bath PsA cohort. Radiographs are not formally scored routinely; instead subpopulations of the cohort are identified and scored to answer study-specific questions. Scored hand radiographs which were most contemporaneous to an available assessment time point were included in this study. Radiographs were scored by WT, DJ, ASA and AA. Training in radiographic scoring has been supported by a consultant musculoskeletal radiologist (GR). The presence and severity of erosive disease was graded using either the modified Sharp/van der Heijde score or the Ratingen Score for PsA(10). Proliferation was scored using the Ratingen Score for PsA and the severity of joint space narrowing was graded using the modified Sharp/van der Heijde score(10). Osteoproliferation

Accepted Article

data were missing for 29 patients. The time between clinical assessment and date of radiograph were calculated for all patients. The equipment and methods of viewing and inter-rater reliability have been reported elsewhere(10, 11), with the intraclass correlation (ICC) for intra- and interrater reliability exceeding 0.9 for all individual features of radiographic damage.

Statistical Analysis:

Demographic data reported include age, gender, disease duration, biologic use and time between clinical assessment and radiograph. The overall frequencies of radiographic and nail variables were determined. Associations between the psoriatic nail dystrophy and radiographic damage in the joints of each individual corresponding digit were assessed using Chi-squared testing (χ^2), and odds ratio (OR) with 95% confidence intervals (95% CI) were calculated. Radiographic damage was assessed separately at 1340 distal interphalangeal joints (DIPJs), i.e. joints with a close anatomical relationship to the nail, and 2680 proximal interphalangeal or metacarpophalangeal joints (non-DIPJs), i.e. joints with a distant anatomical relationship to the nail. All statistical analyses were performed using SPSS v.23 (IBM Corp.).

Ethical consent:

The data collection was approved by the South West 3 Research Ethics Committee (Reference number BA74/00-01) and this study has been conducted in accordance with the Declaration of Helsinki. All participants signed informed consent.

Results:

There were 134 patients identified from the database for analysis (Table 1). The median [IQR] age was 53 [44.0-61.0] years and the median [IQR] disease duration of psoriatic arthritis was 7 [3.0-17.0] years. Of the participants, 47.8% were female and 26.5% were on biologics. The median [IQR] time between nail score and radiograph was 0 [-578-686] days. Retrospective review of medical records determined that 39 patients had a documented co-existing diagnosis of small and/or large joint osteoarthritis and 4 patients had a co-existing diagnosis of gout.

Nail disease was present in 70.1% of patients, affecting 25.8% of nails. Onycholysis was the most frequent manifestation (24.2% of all nails), followed by pitting (22.8%), subungal hyperkeratosis (5.5%) and severe nail deformity (2.8%). Pitting was the only subtype of nail disease that was not associated with the presence of any other subtype of nail disease.

The median PNSS was 2.5 (IQR 0, 9) and the median number of nails affected per patient was 2 (IQR 1,7). The median PNSS in patients with radiographic damage at the DIPJs was 3 (IQR 0.0, 9.8) while the median PNSS in patients without radiographic damage at the DIPJs was 1 (IQR 1,8), but this difference was not statistically significant (Mann-Whitney U Test, $p=0.148$).

Joint space narrowing was the most frequent radiographic damage variable at the DIPJs (34.3% of 1340 joints scored) and non-DIPJs (30.2% of 2680 joints scored), followed by osteoproliferation (11.8% and 13.9% respectively) and erosions (7.8% and 12.6% respectively).

The presence of nail disease was associated with radiographic damage at the DIPJs (OR 1.4 [95% CI: 1.11-1.82], $p=0.005$) but not at the non-DIPJs (Table 2). This association was driven by the association between nail disease and erosion at the DIPJs (OR 1.9 [95% CI: 1.23-2.83], $p=0.004$).

Onycholysis was associated with erosion at the DIPJs (OR 1.7 [95% CI 1.12-2.62], $p=0.02$), but not at non-DIPJs. Digits affected by onycholysis had corresponding erosions in 11.1% of DIPJs compared to 6.8% in digits without onycholysis (Figure 2).

Subungal hyperkeratosis was associated with the presence of overall damage, proliferation and joint space narrowing at the DIPjs (Table 2). Subungal hyperkeratosis was also associated with overall damage, erosion and proliferation at non-DIPj. However the magnitude of the association was stronger between the presence of subungal hyperkeratosis and erosion at the DIPjs (OR 4.4 [95%CI: 2.45-7.73], $p < 0.001$) than at the non-DIPjs (OR 2.6 [95%CI: 1.49-5.39], $p = 0.002$).

Pitting was not associated with an increased risk of radiographic damage in either DIPjs nor non-DIPjs. Conversely, pitting was associated with a lower risk of joint space narrowing at the DIPjs (OR 0.7 [95% CI: 0.51-0.90], $p = 0.007$) and non-DIPjs (OR 0.7 [95% CI 0.49-.88], $p = 0.005$).

Further analyses on digits affected by severe nail disease are not included due to the very low frequency of occurrence.

Discussion

We report an association between the presence of nail disease and radiographic damage at the DIPjs, driven by the association between nail dystrophy arising from the nail bed (onycholysis and subungal hyperkeratosis), and erosions at the

DIPjs. The DIPj damage is a reflection of disease activity in the distal interphalangeal joint, and emphasizes the close anatomical relationship between inflammation in the nail bed-matrix complex and the DIPj. These associations were not reproduced at non-DIPjs, which are anatomically distant from the nail-enthesal complex.

The relationship between nail disease and DIP joint involvement was described in 1994 by Jones et al.(9), who noted that nail disease was more common in patients with DIP joint disease and more likely to be associated with adjacent DIP joint disease, and later confirmed in a prospective study of patients with early PsA(12). Further studies have demonstrated that patients with clinical or radiographic DIP involvement tend to have higher nail scores as measured by the PNSS and mNAPSI (modified Nail Psoriasis Severity Index)(4, 5). We have confirmed the association between nail disease and erosive change in the corresponding DIPj, but whilst patients with DIPj damage did have higher nail scores than patients without DIPj, this did not reach statistical significance in our cohort.

The association between onycholysis and radiographic DIP involvement has previously been investigated by Lai et al in 45 patients. Whilst an association between nail crumbling, onycholysis, and radiographic damage was found,

Accepted Article

multivariate analysis did not confirm an association with subtypes of nail disease, and non-DIP joints were not assessed⁽⁴⁾. Our study reinforces these findings with larger numbers, validated radiographic scoring methods, and examination of non-DIP joints. As onycholysis has also been shown to be associated with overall clinical small joint disease in the hands and the feet in patients with PsA⁽³⁾ and with more severe osteolysis in patients with PsA mutilans⁽¹³⁾, separate radiographic assessment of non-DIP joints is particularly important to illustrate the specificity of the relationship between onycholysis and DIPj damage.

We also demonstrated an association between subungual hyperkeratosis and all types of radiographic damage at the DIPs; this was a less specific finding, as similar associations were also demonstrated between subungual hyperkeratosis and erosion, proliferation and overall damage at non-DIPjs. The approach of analysing of metacarpophalangeal and proximal interphalangeal joints in the corresponding digit is also relevant - the appreciation of PsA being a disease that affects digit 'rays' rather than across 'rows' of joints as seen in rheumatoid arthritis, mediated perhaps by dactylitis or tenosynovitis of the digits⁽⁷⁾, does make it more challenging to demonstrate a significance between associations at the DIPjs versus non-DIPjs when the number of patients affected is small, which is the case with subungual hyperkeratosis. Another possible hypothesis is that subungual

hyperkeratosis may be a more persistent feature of nail disease, and therefore more likely to be captured during routine clinical assessments.

The lack of association between pitting and radiographic damage in our study may reflect the lack of specificity of pitting in PsA⁽¹⁴⁾. In one study where the presence of pitting was defined as >20 pits, the prevalence of pitting in PsA patients was found to be much lower at 26% compared to 56.7% in our study, where the presence of pitting was defined as ≥ 1 pit⁽⁵⁾. Similarly, the lack of positive association between nail variables and joint space narrowing may reflect the poor specificity of joint space narrowing for inflammatory disease. The mean age of our cohort was 51.9 years, and radiographic scoring methods do not discriminate between joint space narrowing related to PsA or osteoarthritis.

The inverse association between pitting and joint space narrowing is an interesting finding. The possible rationales for this include the presence of a confounder, such as the impact of treatment on subtypes of nail disease, and the lack of specificity of both pitting and joint space narrowing to PsA.

The strengths of our study include the cohort size, the formal scoring of nails and joints and data analysis by individual joint (as opposed to group level analysis of total nail and joint score). This is the largest study examining the association

between individual features of nail disease and radiographic damage, and the only study in which formal radiographic scoring methods were used in all small joints of the digits.

The main limitations of our study are the lack of complete longitudinal clinical data such as the Psoriasis Area and Severity Index Score (PASI) and Body Surface Area (BSA) which may serve as confounders, and the absence of serial radiographic data which precludes meaningful regression analysis to analyse the impact of subtypes of nail disease. However existing observational studies, which utilise multivariate analysis to demonstrate the independence of the association between psoriatic nail dystrophy and radiographic damage in DIPJs, are also fettered by their lack of complete longitudinal data, the fluctuating nature of nail dystrophy, and variable treatment exposure. We utilised a study design to offset this limitation by analysing the differences in association between nail disease and radiographic damage in the joints of the corresponding DIPj and comparing this to the association between nail disease and radiographic damage in the joints of the corresponding metacarpophalangeal or proximal interphalangeal joints (non-DIPJs). The presence of an association with the former but not the latter adds confidence to the hypothesis that there is a relationship between the presence of nail disease and radiographic damage at the DIPJs.

This study did not assess all potentially relevant radiographic measures of damage related to psoriatic arthritis, such as periostitis, which may have affected the significance of the relationship between overall radiographic damage and individual features of psoriatic nail disease. Furthermore, the Nail Psoriasis Severity Index (NAPSI) score which scores individual nail quadrants is not routinely used in our longitudinal cohort; therefore the effect of the severity of a nail lesion is not accounted for in our analysis.

Another consideration in the interpretation of our findings is the concept of subclinical nail disease. In one study of 23 patients with PsA, 42% of patients with MRI nail disease had DIP involvement compared to 0% of patients without MRI nail disease; importantly, most patients without clinical nail disease had MRI nail disease(15). This suggests that clinical examination is not as sensitive as MRI for detecting nail disease. While utilising MRI to assess nail disease is difficult to justify clinically and financially, the use of clinical nail assessment in assessing the association with radiographic damage is a limitation of this study.

Finally, PsA is a heterogenous condition with various proposed subtypes such as polyarticular disease, oligoarticular disease, DIP-predominant disease, spondyloarthritis and arthritis mutilans(16, 17). Our study does not stratify patients by disease subtype; it may be that the demonstrated associations are driven by

particular disease subtypes and may not necessarily apply to all patients with PsA.

In conclusion, there is an association between the presence of psoriatic nail dystrophy, in particular onycholysis, and erosive damage at the distal interphalangeal joints. The association between subungual hyperkeratosis and erosive disease is stronger at the distal interphalangeal joints than in non-DIPJs. These findings support studies that demonstrate the anatomical, radiological and clinical association between psoriatic nail dystrophy and DIP disease and support the clinical utility of assessing the nail-enthesal-DIP complex in clinical practice.

References:

1. Kyriakou A, Patsatsi A, Sotiriadis D. Detailed analysis of specific nail psoriasis features and their correlations with clinical parameters: A cross-sectional study. *Dermatology* 2011;223:222-9.
2. Sobolewski P, Walecka I, Dopytalska K. Nail involvement in psoriatic arthritis. *Reumatologia* 2017;55:131-5.
3. Love TJ, Gudjonsson JE, Valdimarsson H, Gudbjornsson B. Small joint involvement in psoriatic arthritis is associated with onycholysis: The reykjavik psoriatic arthritis study. *Scand J Rheumatol* 2010;39:299-302.
4. Lai TL, Pang HT, Cheuk YY, Yip ML. Psoriatic nail involvement and its relationship with distal interphalangeal joint disease. *Clin Rheumatol* 2016;35:2031-7.
5. Williamson L, Dalbeth N, Dockerty JL, Gee BC, Weatherall R, Wordsworth BP. Extended report: Nail disease in psoriatic arthritis--clinically important, potentially treatable and often overlooked. *Rheumatology (Oxford)* 2004;43:790-4.
6. McGonagle D, Benjamin M, Tan AL. The pathogenesis of psoriatic arthritis and associated nail disease: Not autoimmune after all? *Curr Opin Rheumatol* 2009;21:340-7.
7. Tan AL, Benjamin M, Toumi H, Grainger AJ, Tanner SF, Emery P, et al. The relationship between the extensor tendon enthesis and the nail in distal interphalangeal joint disease in psoriatic arthritis--a high-resolution mri and histological study. *Rheumatology (Oxford)* 2007;46:253-6.
8. Taylor W, Gladman D, Helliwell P, Marchesoni A, Mease P, Mielants H, et al. Classification criteria for psoriatic arthritis: Development of new criteria from a large international study. *Arthritis Rheum* 2006;54:2665-73.
9. Jones SM, Armas JB, Cohen MG, Lovell CR, Evison G, McHugh NJ. Psoriatic arthritis: Outcome of disease subsets and relationship of joint disease to nail and skin disease. *Br J Rheumatol* 1994;33:834-9.
10. Tillett W, Jadon D, Shaddick G, Robinson G, Sengupta R, Korendowych E, et al. Feasibility, reliability, and sensitivity to change of four radiographic scoring methods in patients with psoriatic arthritis. *Arthritis Care Res (Hoboken)* 2014;66:311-7.
11. Allard A, Antony A, Shaddick G, Jadon D, Cavill C, Korendowych E, et al. The trajectory of radiographic progression slows amongst patients with psoriatic arthritis treated with anti-tnf. 2018.
12. Kane D, Stafford L, Bresnihan B, FitzGerald O. A prospective, clinical and radiological study of early psoriatic arthritis: An early synovitis clinic experience. *Rheumatology (Oxford)* 2003;42:1460-8.
13. Jadon DR, Shaddick G, Tillett W, Korendowych E, Robinson G, Waldron N, et al. Psoriatic arthritis mutilans: Characteristics and natural radiographic history. *J Rheumatol* 2015;42:1169-76.
14. Eastmond CJ, Wright V. The nail dystrophy of psoriatic arthritis. *Ann Rheum Dis* 1979;38:226-8.
15. Scarpa R, Soscia E, Peluso R, Attenuo M, Manguso F, Del Puente A, et al. Nail and distal interphalangeal joint in psoriatic arthritis. *J Rheumatol* 2006;33:1315-9.
16. Moll JM, Wright V. Psoriatic arthritis. *Semin Arthritis Rheum* 1973;3:55-78.

17. Gladman DD, Antoni C, Mease P, Clegg DO, Nash P. Psoriatic arthritis: Epidemiology, clinical features, course, and outcome. *Ann Rheum Dis* 2005;64 Suppl 2:ii14-7.

Figure 1 A) Representative clinical image of a patient with psoriatic nail dystrophy, with onycholysis, pitting and hyperkeratosis. B) Contemporaneous radiographs from the same patient of the left 5th distal interphalangeal joint demonstrating early erosive and osteoproliferative change. C) Illustrative radiograph of the Distal Interphalangeal Joint demonstrating more advanced changes of psoriatic arthritis, with erosions, osteoproliferation and joint space narrowing, with early pencil-in-cup deformities.

Figure 2 Chi-square tests demonstrating associations between sub-types of psoriatic nail disease and radiographic damage at the corresponding DIPjs and non-DIPjs

Table 1: Baseline demographics

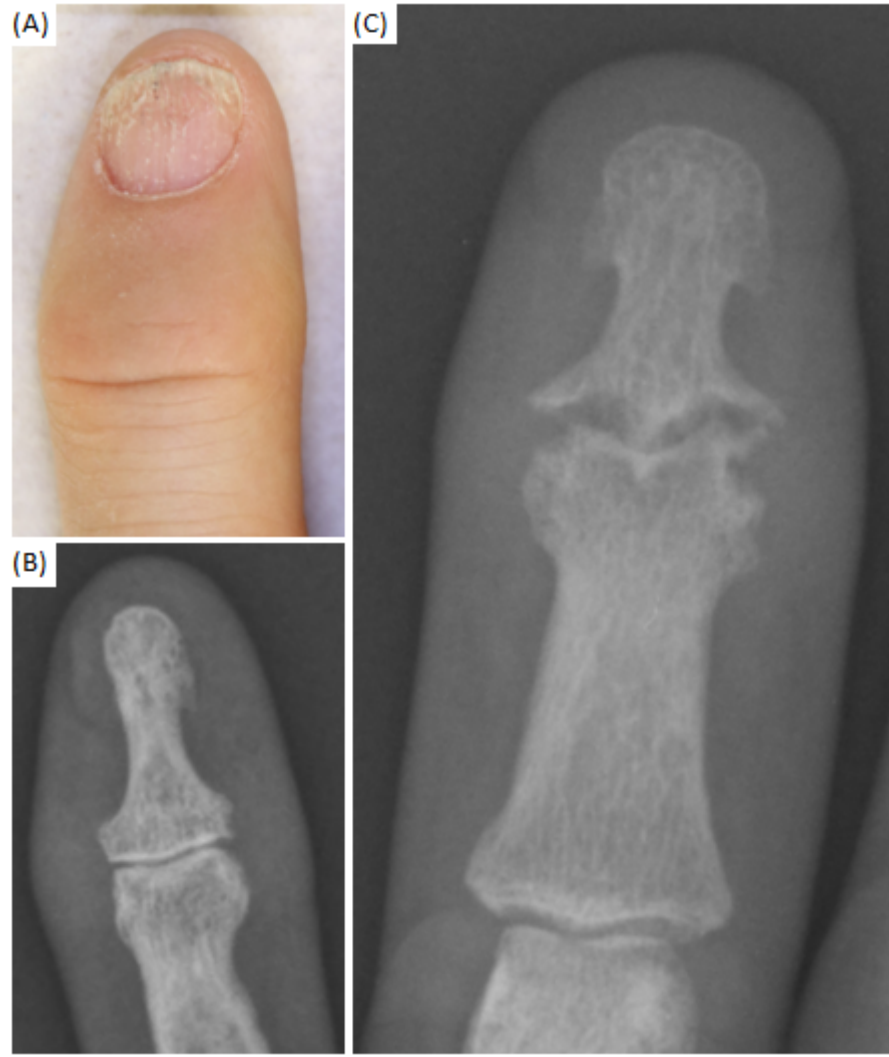
	Digits (n = 1340)
Age (years) [SD]	53 [44.0-61.0]
Gender	52.4% Female
PsA Disease Duration (years) [SD]	7 [3.0-15.0]
Biologic Use	26.5%
Time Between Clinical Assessment and XR (days) [SD]	0 [-543.5-659.5]
Radiographic Damage	
DIPj Joint Space Loss	34.3%
DIPj Erosion	7.8%
DIPj Osteoproliferation	11.8%
Non-DIPj Joint Space Loss	30.2%
Non-DIPj Erosion	12.6%
Non-DIPj Osteoproliferation	13.9%
Psoriatic Nail Dystrophy	
Pitting	22.8%
Onycholysis	24.2%
Subungal Hyperkeratosis	5.5%
Severe nail deformity	2.8%

DIPj: Distal interphalangeal joint.

Table 2: Univariate analysis of associations between psoriatic nail dystrophy and features of radiographic joint damage

Radiographic Damage	Any Nail Dystrophy			Onycholysis			Subungual Hyperkeratosis			Pitting		
	OR	95% CI	p-value	OR	95% CI	p-value	OR	95% CI	p-value	OR	95% CI	p-value
Any												
DIPj	1.4	(1.11-1.82)	0.005*	0.9	(0.72-1.23)	0.687	2.7	(1.68-4.34)	<0.001*	0.8	(0.62-1.07)	0.150
Non-DIPj	1.0	(0.89-1.32)	0.493	0.8	(0.57-1.00)	0.058	3.1	(1.90-4.90)	<0.001*	1.0	(0.75-1.32)	1.000
Joint Space Narrowing												
DIPj	1.3	(1.00-1.67)	0.059	0.9	(0.92-1.54)	0.687	1.9	(1.18-3.01)	0.008*	0.7	(0.51-0.90)	0.007*
Non-DIPj	1.0	(0.76-1.30)	1.000	0.8	(0.69-1.20)	0.532	1.4	(0.89-2.34)	0.152	0.7	(0.49-0.88)	0.005*
Erosion												
DIPj	1.9	(1.23-2.83)	0.004*	1.7	(1.12-2.62)	0.017*	4.4	(2.45-7.73)	<0.001*	1.2	(0.75-1.88)	0.452
Non-DIPj	1.2	(0.87-1.77)	0.232	1.1	(0.76-1.62)	0.564	2.6	(1.49-4.45)	0.002*	0.8	(0.56-1.25)	0.433
Osteoproliferation												
DIPj	1.4	(0.91-2.03)	0.133	1.3	(0.88-1.99)	0.188	3.2	(1.82-5.75)	<0.001*	1.0	(0.67-1.61)	0.910
Non-DIPj	1.2	(0.81-1.73)	0.423	1.1	(0.72-1.59)	0.759	3.1	(1.78-5.39)	<0.001*	1.5	(1.01-2.17)	0.057

* p<0.05. DIPj: Distal interphalangeal joint.



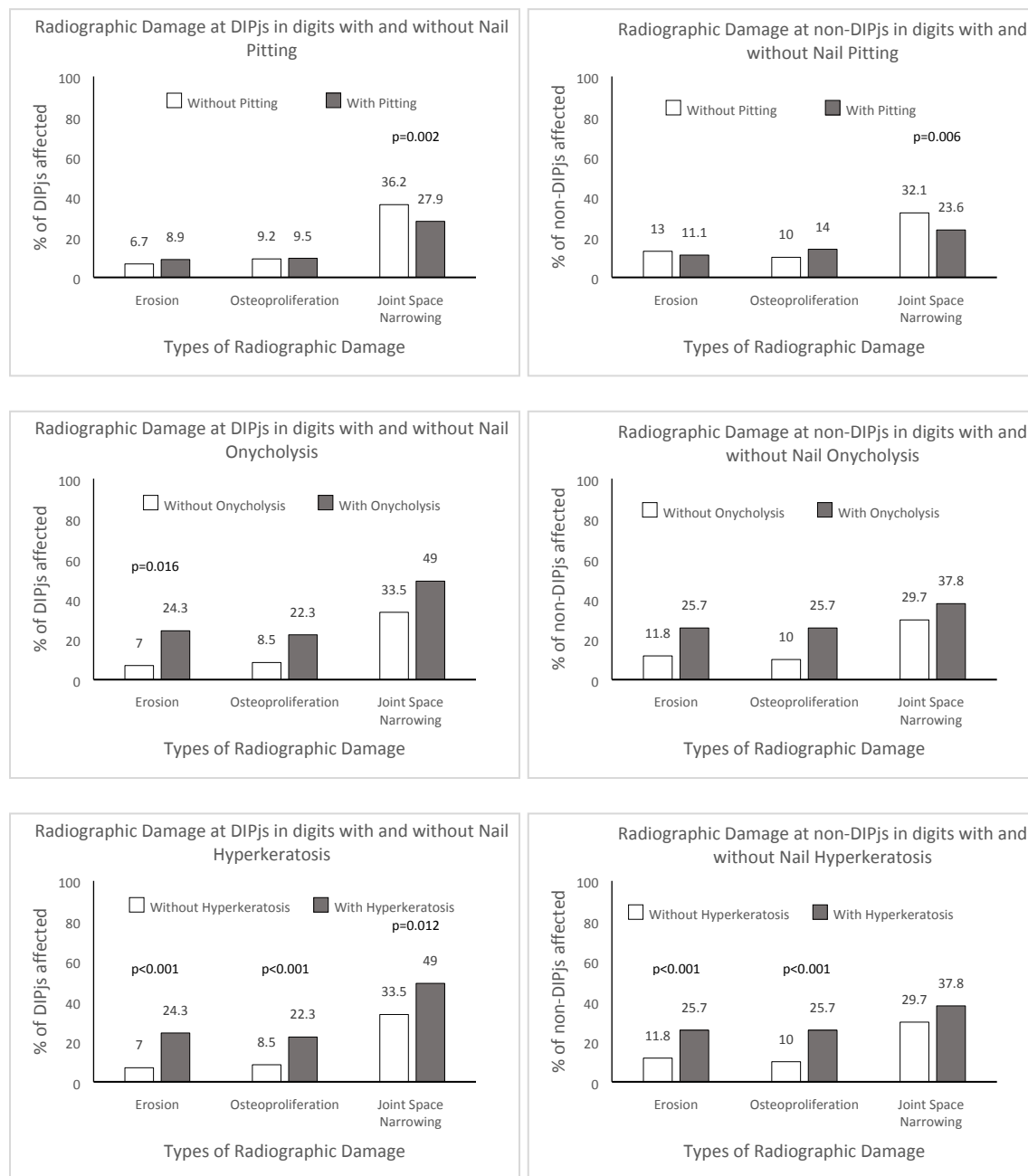


Figure 2: Chi-square tests demonstrating associations between sub-types of psoriatic nail disease and radiographic damage at the corresponding DIPJs and non-DIPJs