

AETIOLOGY OF REFRACTIVE ERRORS

Mechanical stretch of the sclera has long been suspected as a cause of myopia but no investigation of such stretch or its relationship to the refractive state has yet been attempted. The diagnosis of scleral stretch cannot be made from the refractive state, the lengths of ocular axes, the ocular volume or changes in these because they may all be similarly influenced by growth. It is only in the fundus that scleral stretch can be studied clinically.

The present investigation originated as a study of the visual fields in eyes with non-temporal crescents. Attempts to correlate the visual fields and fundus appearances did not meet with much success but it was deduced from careful study of these fundi that non-temporal crescents probably result from the action of scleral stretch on Bruch's membrane. No essential difference could be detected between temporal and non-temporal crescents. The investigation was then extended to include all fundus signs of scleral stretch. From the findings of this investigation it was concluded that the crescent is merely an inconstant feature of a complex group of fundus appearances produced by scleral stretch, that practically all eyes are stretched and that the physiological cup is produced by stretch of the sclera. Further study was then directed to the incidence of various fundus appearances attributable to stretch of the sclera and their relationship to the refractive state. From this study it was concluded that the refractive state in most, if not all eyes, is to a large extent determined by mechanical stretch of the sclera.

The results of the present investigation will be presented in five parts.

The first part is an account of the fundus appearances attributable to stretch of the sclera and is based on observations made over a period of many years. In order to avoid repetition the probable significance of each feature is presented with the description. Some unorthodox and controversial views are expressed in this part but they will not be fully considered until later because much substantiating evidence only becomes available in the second part.

The second part is mainly concerned with fundus appearances and their relationship to the refractive state, as found in two series of cases.

Unorthodox and controversial views expressed in the first part are considered in some detail in the third.

ProQuest Number: 13850826

All rights reserved

INFORMATION TO ALL USERS

The quality of this reproduction is dependent upon the quality of the copy submitted.

In the unlikely event that the author did not send a complete manuscript and there are missing pages, these will be noted. Also, if material had to be removed, a note will indicate the deletion.



ProQuest 13850826

Published by ProQuest LLC (2019). Copyright of the Dissertation is held by the Author.

All rights reserved.

This work is protected against unauthorized copying under Title 17, United States Code
Microform Edition © ProQuest LLC.

ProQuest LLC.
789 East Eisenhower Parkway
P.O. Box 1346
Ann Arbor, MI 48106 – 1346

The fourth section deals with the effects of scleral stretch on the fields of vision. While this problem is by no means solved, the findings provide evidence which supports some of the views expressed earlier.

The fifth part is devoted to the evolution of scleral stretch and the refractive state together with the aetiology of refractive errors.

The illustrations have been placed at the end of the text because most are referred to on more than one occasion. Many of the features described are present in several of the illustrations. Figs. 17, 42 and 46 are included for comparative purposes only and are not mentioned in the text. Fig. 77 is a photograph of a fundus showing several of the less common features, and is also omitted from mention in the text. Sufficient illustrations and visual field charts to provide a reasonably comprehensive picture of variations encountered in the present investigation have been included.

Except where references are given, the observations presented and the views expressed are almost all new.

FUNDUS SIGNS OF SCLERAL STRETCH

Most of the appearances produced by stretch of the sclera are in the region of the optic disc where the continuity of various layers is interrupted and the retina is anchored by the passage of its nerve fibres from the eye. They tend to follow two general patterns, depending on whether stretch is greater in one part than another or fairly uniform relative to the optic disc. The two will be considered separately.

Appearances resulting from non-uniform stretch.

The scleral and retinal appearances will be considered individually. Those of Bruch's membrane, pigment epithelium and choroid will be considered as a group.

Obliquity of the scleral canal and alterations in the size and shape of the optic disc are the dominant scleral changes. The canal is inclined towards the region of greatest stretch. This obliquity is due to the movement of scleral lamellae on each other. It indicates that stretch of the outer lamellae is of greater degree than that of the corresponding inner lamellae in the region of greatest stretch. It also indicates that stretch is more uniform in the inner than the outer lamellae and that the state of the outer lamellae probably determines the site of greatest ectasia. The lamina cribrosa, being more deeply situated than the inner surface of the surrounding sclera is relatively displaced, in a direction away from the region of greatest stretch. The blood vessels piercing it are displaced in the same direction and may be hidden from view posterior to the margin of the physiological cup, (figs. 13, 14, 20, 40, and 49). They are occasionally visible as far as the scleral disc margin, deep to which they disappear from view, (figs. 10, and 11). That they indeed pass deep to the scleral disc margin and not to choroid which has encroached on the disc area is obvious from fig. 67 where senile cupping of the disc is present and the projecting scleral margin casts a shadow on the lamina cribrosa. It is doubtful if the choroid ever overlaps the disc because it never appears to be depressed, with the disc surface, in senility. The size and shape of the optic disc are the size and shape of the inner opening of the scleral canal. Five varieties of disc occur with non-uniform stretch. They will be described as they appear when greatest ectasia is temporal to the optic disc. Corresponding appearances are present, and will be illustrated, where greatest ectasia is located elsewhere. Common to all five

varieties is temporal obliquity of the nasal wall of the scleral canal as evidenced by nasal displacement of the blood vessels at the lamina cribrosa. Variation is largely in the position of the temporal margin of the disc. The five varieties will now be considered.

Circular. This is present when the scleral canal is oblique but otherwise unaltered. The blood vessels at the lamina cribrosa are displaced nasally. The temporal margin of the disc is more pale and defined than the nasal because it is covered by a more stretched, and consequently less thick, layer of nerve fibres, (fig. 17). This prominence is not due to a lesser number of overlying nerve fibres, as commonly stated, because its position varies with the location of greatest ectasia as shown in figs. 50, 60, 68, 71 and 72.

Reduced Oval. The horizontal axis and the area of the disc are reduced. The nasal wall of the scleral canal is inclined temporally as in all varieties. The oval shape is therefore due to lack of displacement of the temporal margin. The temporal wall of the scleral canal tends to remain vertical and because the overlying nerve fibres are stretched, may cast a visible shadow on the lamina cribrosa (fig. 33). The oval shape of the disc is not merely an appearance due to foreshortening because there is no significant difference in refraction at its various parts. It is not due to dragging of the choroid over the nasal part of the disc because the disc is still oval in the presence of senile cupping (fig. 26). The lack of displacement of the temporal margin must be due to local excess stretch of the inner lamellae immediately temporal to the disc. The corresponding outer lamellae are not affected because this part of the fundus is rarely ectatic. It cannot be due to unusually firm union of the lamellae forming the lateral wall of the scleral canal because the latter shows well marked nasal inclination when greatest ectasia is nasal to the disc, (fig. 68). Corresponding appearances, where greatest ectasia is other than temporal to the optic disc, are shown in figs. 4, 38, 66 and 67.

D-Shaped. This resembles the reduced oval disc with the exception that the temporal margin is straight instead of curved (fig. 47). The difference is due to the local weakness of the inner lamellae being of greater degree, nearer to the disc margin or more sharply demarcated than is the case where the disc is oval. Where greatest ectasia is not temporal to the disc the appearances correspond as shown in figs. 15, 19, 23 and 45.

Pear-Shaped. This is an intermediate form of the previous two, (figs. 7 and 39). Its appearance is that of a D-shaped disc with one angle rounded off. It probably results from local excess stretch of the inner lamellae being more sharply demarcated at one part than another.

Enlarged Oval. The area of the disc is increased due to lengthening of its horizontal axis, (fig. 1). As with other varieties of disc, the nasal wall is temporally inclined. The increased horizontal axis is therefore due to excessive displacement of the temporal margin. The distance between the temporal margin of the disc and the point where the blood vessels pierce the lamina cribrosa may exceed an average disc diameter. The fenestrae of the lamina cribrosa are elongated parallel to the long axis of the disc suggesting that this variety of disc is due to weakness of the inner scleral lamellae forming its upper and lower margins. This variety of disc, when associated with greatest ectasia inferiorly and nasally, is shown in figs. 2 and 3.

It appears that the inner and outer scleral layers tend to stretch differently. It also appears that the state of the outer layers determines the site of greatest ectasia while that of the inner layers, at the same site, determines the size and shape of the optic disc. This matter will receive further consideration later.

The retina is fairly free to move, and therefore more uniformly stretched than the sclera. There is a widespread movement towards the most ectatic part of the sclera. This movement is accompanied by distortion of the retina in the region of the disc because the retinal nerve fibres are anchored at the lamina cribrosa. The appearances about to be described are largely due to this distortion. The appearances of the retina and its blood vessels will be considered separately.

When greatest ectasia is temporal to the disc, the inner opening of the physiological cup is displaced, towards the posterior pole, with the neighbouring retina while the base of the cup retains its position relative to the lamina cribrosa. The nerve fibres on the temporal half of the disc become more straight and slope more gradually to the disc margin. Those on the nasal half of the disc are displaced as a fold, whose free margin forms the nasal border of the physiological cup. As a result of this folding the area of the cup is increased. The increase in area of the cup ceases when its temporal margin reaches that of the disc. Further

displacement is confined to the nasal margin, with resulting diminution of the cup area, when retinal displacement is marked. The nasal margin of the cup may extend as far as, or even beyond, the temporal margin of the disc, (fig. 11). The inner opening of the cup is then directed laterally or posteriorly and is hidden from view. As the retinal fold forming the nasal margin of the cup enlarges the retina at the upper and lower margins of the disc becomes heaped up as ridges, continuous with the ends of the fold. These ridges obscure the upper and lower disc margins (fig. 10). Further retinal displacement converts these ridges to folds (fig. 11). The accumulation of retina at the nasal part of the disc produces an increased concavity of the related fundus. This concavity is responsible for the Weiss-Otto reflex, commonly seen in young myopic eyes. The reflex diminishes with increasing age, due to a general depression of the tissues on the disc. The appearances described above are due to retinal displacement, which depends on the degree of non-uniformity, rather than the amount, of scleral stretch.

The retinal blood vessels are displaced with the retina. When greatest ectasia is temporal to the optic disc the physiological cup is inclined temporally so that the vessels may not be visible on its nasal wall, (fig. 60g). This disappearance of the vessels does not involve all branches with equal frequency. The upper ones are hidden from view on the wall of the cup much more frequently than the lower and it is seldom that the lower ones alone are hidden. The reason for this is that the centre of greatest ectasia is usually somewhat below and seldom above the horizontal meridian. The veins are more frequently hidden than the arteries (fig. 60). This is attributable to the thin-walled veins, with their low blood pressure, being less resistant to the intra-ocular pressure than the arteries. It is not strictly a phenomenon of scleral stretch and will be considered further when discussing non-stretch factors influencing the physiological cup. When retinal displacement is marked the vessels emerge from deep to the nasal margin of the cup. The angle subtended by the temporal branches at the disc is reduced and may be considerably less than 90° (figs. 10 and 12). The nasal branches are stretched and, since they are anchored to the nasal periphery and the larger temporal branches, tend to leave the latter at an obtuse angle (figs. 11 and 12). The lower temporal branches make a wider sweep round the posterior pole than do the upper ones because greatest ectasia is, as a rule, below the horizontal meridian (figs. 18 and 52). This feature may be detected in over 80% of all eyes. Cilio-retinal arteries, contrary to general opinion, neither enter the eye nor curve temporally at the disc margin. They usually enter the eye through the sclera and extend on to the disc for a variable distance before bending sharply to supply the retina. They

are displaced with the retina and in the presence of a temporal crescent, may fail to reach the disc (fig. 28). Since they usually extend for some distance on to the disc, a considerable degree of retinal displacement may be required to carry them beyond the disc margin. That they may fail to reach the disc is important because it cannot be accounted for except on the basis of retinal stretch. Occasionally a small vessel crossing a temporal crescent shows a double bend in the crescent area (fig. 73). With the fundus microscope the proximal bend can be seen to lie deep to the distal one. It is probable that the double bend is due to inclusion of the vessel in a loop of nerve fibres which has been dragged from the margin of the disc by Bruch's membrane, as suggested by Heine (1899).

When greatest ectasia is inferior to the disc the retina and its vessels are displaced downwards. The cup is directed downwards and the blood vessels on its upper wall may be hidden. The upper temporal branches curve sharply near the upper margin of the disc and follow an unusually horizontal course (fig. 19). The lower temporal branches are not hidden on the disc and course downwards in a wide curve before passing temporally (fig. 16). The inferior temporal arterial branch is occasionally cilio-retinal and may fail to reach the disc margin in the presence of an inferior crescent (fig. 31). The blood vessel loop, already noted in association with temporal crescent, may also accompany inferior crescents (figs. 22, 23 and 43). It is much more obvious than that which accompanies temporal crescent because the affected vessel is larger. It is accompanied by a loop of nerve fibres which may consist of the outer fibres alone (figs. 22 and 23) or the entire thickness of the nerve fibre layer, (figs. 41 and 43). The loop is internal to the choroid so that it must result from traction by Bruch's membrane. Where the whole thickness of the nerve fibre layer is involved the vessel loop may be obscured in the same way that the vessels may be hidden on the wall of the physiological cup. The appearances in these cases suggest that part of the crescent is ectatic but it should be noted that the depression is less deep than the lamina cribrosa. The vessel loop is almost always venous because the veins are less resistant to bending.

When greatest ectasia is nasal to the optic disc the retina and its vessels are displaced nasally. The cup is inclined in the same direction. The vessels on its nasal wall may emerge from deep to its projecting temporal margin (fig. 13, 68). They course nasally across the disc (figs. 14 and 65). The temporal branches make a wide nasal sweep before passing temporally (fig. 14 and 65). This nasal sweep is greater below than above because greatest ectasia is usually centred below and seldom above the horizontal meridian. Cilio-retinal arteries and vascular loops have not been encountered nasal to the disc.

Irrespective of the distribution of scleral stretch there is a general tendency to straightening of the retinal vessels and diminution of fundus reflexes with increasing amounts of stretch.

The appearances produced by changes in the choroid, pigment epithelium and Bruch's membrane, while very complex and varied, can be attributed to the following three processes.

- a. Displacement of Bruch's membrane from the disc margin, with or without rupture and retraction.
- b. Atrophy of the choroid and pigment epithelium where isolated from Bruch's membrane,
- c. Proliferation of pigment epithelium at the margin of Bruch's membrane.

When greatest ectasia is temporal to the optic disc the following appearances are most common.

1. A single dense discrete pigment line may coincide with the temporal margin of the disc. It occurs where Bruch's membrane is not displaced but is under sufficient tension to render its margin stimulant to pigment epithelial cells.
2. Instead of a single pigment line there may be a double line with a pale crescentic interspace (fig.61b). The pigment lines are due to proliferation of pigment epithelium at the initial and ultimate sites of the margin of Bruch's membrane. Proliferation of pigment epithelium does not take place in the interspace because the margin of Bruch's membrane is not stationary when in this area. The interspace is pale because the choroid and pigment epithelium undergo atrophy where Bruch's membrane is absent. The proximal pigment line, being isolated from Bruch's membrane, may atrophy (fig.51).
3. The pale interspace may be crossed obliquely by a third line of pigment (fig.61f). This oblique line is part of the proximal line which has been dragged away by Bruch's membrane; the corresponding part of the proximal line may be absent.

4. The wedge shaped ends of the pale interspace may be filled with pigment (fig.61c). These pigmented wedges may be due to continuous pigment epithelial proliferation as a result of the slower movement of Bruch's membrane at these sites or to dragging away and shedding of cells from the proximal pigment line. For the same reasons, the entire interspace may be pigmented (fig.61d).
5. A narrow, pale, crescentic area which has no pigmented border whatever may be present at the temporal margin of the disc, (fig.60g). There is a failure of pigment epithelial proliferation in these cases.

More marked changes, explainable on the same basis are shown in figs. 62, 63 and 61, e.g,h.

Similar appearances commonly occur simultaneously at the nasal margin of the optic disc, not because Bruch's membrane is dragged away from the disc but because the nasal margin of the disc moves away from Bruch's membrane (figs. 25, 62 and 70).

A distinct crescent at the disc margin results when there is greater displacement of Bruch's membrane. Such crescents will be classified as primary, secondary and tertiary.

Primary crescent. Not more than one may occur in any individual eye. It is due to dragging of Bruch's membrane away from the disc in the direction of greatest scleral ectasia. It is situated in line with the shortest axis of the reduced disc but the longest axis of the enlarged oval disc. When associated with a reduced disc it represents a lesser displacement of Bruch's membrane than does one of similar extent associated with an enlarged disc. The reason for this is that the former crescent is partly determined by a lack of movement of the corresponding disc margin while the latter is determined by the degree to which displacement of Bruch's membrane exceeds that of the disc margin. The chief difference between figs. 40 and 41, where greatest ectasia is inferiorly situated, is the location of the lower margin of the disc. In the former it has moved to the same extent as Bruch's membrane while in the latter there is a marked lack of such movement. Figs. 1 and 26 show the same type of difference when greatest ectasia is temporal to the disc and figs. 44 and 2 show it when greatest ectasia is situated nasally.

10

The presence and size of the crescent thus depend to some extent on the disc type. The extent to which the crescent extends along the disc margin also shows a tendency to vary with the disc type, it being greater when the disc is enlarged than when it is reduced.

The central margin of the crescent coincides with the disc margin. It may be marked by a pale ridge which is the underlying anterior margin of the scleral canal. This ridge is most prominent when the disc is of reduced type. It is part of the crescent because remnants of a pigment line, representing the original limit of the pigment epithelium, are occasionally present along its central margin, figs. 56 and 70. Pigment epithelial cells stranded at a distance from Bruch's membrane usually however disappear. The physiological cup slopes gradually to the central margin of the crescent but the ophthalmoscopic appearance of this part of the cup may resemble that of moderate glaucomatous cupping (fig. 19). This appearance is due to a shadow cast by the non-sloping wall of the scleral canal on the lamina cribrosa and is usually associated with one of the reduced varieties of optic disc. The shadow is rendered visible by stretching, and consequent thinning, of the overlying nerve fibres. The peripheral margin forms a regular curve reaching the disc at both ends. It is commonly marked by a complete or incomplete line of proliferated pigment epithelium. Frequently the line is double or treble in parts, indicating recent stages in the movement of Bruch's membrane (figs. 63 and 30).

The area of the crescent is never quite white; some choroidal and supra-choroidal remnants are always present. They usually consist of large choroidal vessels and dark patches. Unlike proliferated pigment epithelial cells, the dark patches are neither dense nor discrete. In heavily pigmented eyes they may fill the interspaces of a persistent choroidal vascular network (fig. 5). Irrespective of the location of the crescent, members of the same family tend to have crescents of similar appearance so far as persistence of choroidal tissue is concerned. Figs. 32 and 33 show crescents in a mother and son respectively. Both have a persistent network of choroidal vessels and heavy pigmentation. Diffuse pigment is commonly located near the central margin of the crescent (fig. 4). A different form of pigmentation which is rather uncommon is shown in figs. 26, 27 and 11. It consists of multiple dense and fairly discrete lines parallel to the disc margin. Those further from the disc are wider apart and less well defined than those nearer to it. They probably result from pigment epithelial proliferation between stages in the movement of Bruch's membrane. They do not indicate that scleral stretch occurs in stages.

Choroidal vessels may persist in all or any part of the crescent (figs. 5, 10, 29).

A primary crescent may appear ectatic (fig. 41). There may, however, be no true ectasia because no part is deeper than the lamina cribrosa. The appearance probably results from the formation of a full thickness nerve fibre loop by traction of Bruch's membrane. The lower edge of the "ectasia" is very similar to the retinal supertraction fold on the upper part of the disc. The retinal vessels are obscured by both. There is probably no scleral overhang below because in fig. 43 there is a venous loop which is completely visible. A large arterial branch is not included in the nerve fibre loop because it has a higher intra-vascular pressure and is more resistant to bending than the veins. As a rule only the outer nerve fibres are included in a loop and the venous loop is the only clinical indication of its presence (figs. 22, 23).

Secondary crescents. It is single and situated at the opposite pole of the disc to the primary crescent (figs. 12, 25, and 53). It may be somewhat obscured by the thickness of the overlying retina. It may result from movement of the scleral disc margin from that of Bruch's membrane since it tends to be present at an early age.

Tertiary crescents. It results from rupture and retraction of Bruch's membrane. Since stretch of the membrane is more uniform and widespread than that of the sclera, retraction may occur in any direction. The crescent may be related to the disc margin (fig. 36) or the peripheral margin of a primary crescent (fig. 27, 69). An ill-defined part of the crescent margin may indicate the site of membrane rupture (figs. 27, 22, 48, and 10). Tertiary crescents may be multiple (fig. 37). They are less pale than the primary crescent, but when of long standing, choroidal atrophy is marked (fig. 36, and 8) and the appearances are those of peripapillary choroidal atrophy. Choroidal atrophy spreading from a primary crescent is also due to rupture of Bruch's membrane (figs. 9, 64, and 65), and may be festooned (fig. 9). A loop of retinal nerve fibres may be produced (fig. 24). Various other appearances attributed to rupture of Bruch's membrane are shown in figs. 28 and 29, and 26 and 27. Tertiary crescents may occur in the absence of a primary crescent in young persons with enlarged oval discs, (figs. 3 and 40) and in senility (fig. 24).

12

Tertiary crescents tend not to develop until some time after scleral stretch has ceased. They are therefore not determined by scleral stretch alone but also by the time during which such stretch has been present. In general, the greater the amount of stretch the shorter is the time required for Bruch's membrane to rupture. The resistance of the membrane is reduced by stretch acting over a period of time. This weakening process is no doubt accelerated by the fact that the membrane is stretched between two pressurised compartments, the vitreous chamber and the choroidal network of blood vessels, in which pressure variations are constantly taking place. When the stretch is well marked tertiary crescents may form in early adult life. Such eyes have usually a highly myopic refraction and a well marked primary crescent. With lesser amounts of stretch, tertiary crescents may not develop until a much later age. The amount of stretch may have been insufficient to produce a primary crescent and the refraction may be hypermetropic. In this way crescents and peripapillary choroidal atrophy may, as a result of scleral stretch, occur in senile non-myopic eyes. In the majority of eyes, however, the degree of stretch is insufficient to produce such changes even in senility.

Isolated patches of choroidal atrophy are not uncommon in the presence of marked scleral stretch (fig. 21). These may result from the formation of holes in Bruch's membrane as a result of prolonged stretch. Like tertiary crescents they occur some time after the stretching process has ceased.

Appearances resulting from uniform stretch.

Stretch of the posterior parts of the sclera is probably never quite uniform. The following account applies to fundi lacking obvious signs of non-uniform stretch.

The optic disc is circular but may be large. The large size of the disc is not merely an appearance because the ratio of the disc diameter to that of the overlying vessels is increased and may be markedly so (fig. 59).

The physiological cup is rarely absent and is produced by centrifugal displacement of the nerve fibres on the optic disc. Depending on the degree of scleral stretch it may be a small central funnel-shaped depression (fig. 54) or a large saucer-shaped depression occupying the entire disc area. It is approximately symmetrical although the retinal vessels which lie on its nasal wall may give an appearance of slight temporal obliquity. The margin of the disc is more

uniformly defined than in eyes with non-uniform stretch because the overlying nerve fibre layer is of more uniform thickness (fig. 57) and the more marked the stretch the more clearly defined is the margin. The Weiss-Otto reflex is absent because there is no tendency for the nerve fibres to become heaped up on the disc.

The retinal vessels on the nasal wall of the cup tend to be somewhat nasally directed on the disc (fig. 55) and when the degree of stretch is marked their pattern resembles that associated with greatest stretch nasal to the optic disc (fig. 59). Unlike the latter the vessels pierce the lamina cribrosa near the centre of the disc.

Bruch's membrane is stretched and may be dragged from the entire disc margin. Slight drag on the membrane gives rise to pigment epithelial proliferation so that the disc may be outlined by pigment (fig. 56). The pigment line may be double in parts (fig. 56) corresponding to the double pigment line associated with non-uniform stretch. Where the membrane is dragged from the disc margin the uncovered choroid and related pigment epithelium undergo atrophy. The margin of Bruch's membrane stimulates the pigment epithelium in its vicinity to proliferate. The resulting appearances are those of peripapillary choroidal atrophy bounded peripherally by a pigmented line (fig. 58). Since stretch is rarely quite uniform the width of the ring of choroidal atrophy is seldom uniform (fig. 57). This form of peripapillary choroidal atrophy differs from that described in association with non-uniform stretch in that it does not result from fusion of tertiary crescents. Bruch's membrane may however, rupture in these, as in all eyes, with resulting widespread choroidal atrophy (fig. 59).

As with crescents cilio-retinal arteries may fail to reach the disc margin (fig. 30).

It may be noted that, irrespective of the amount of uniform stretch, retinal supertraction and crescents do not occur.

PART II

The account of fundus appearances attributable to stretch of the posterior sclera has so far been based on the observation of fundi in general over a period of years. On the present section consideration will be given to these appearances and their relationship to the refractive state as found in two series of cases. The first series consists of 128 cases, examined in hospital and private practice, who had a primary non-temporal crescent in one or both eyes (table 1). The second consists of 500 consecutive cases examined in private practice. On neither series was selection made except to exclude those with defects likely to influence the refractive state or fundus signs of posterior scleral stretch. Those excluded were essentially ones with opacities of the cornea or lens, aphakia and glaucoma. The examination carried out was much the same in both series. The fundus was examined and the region of the optic disc drawn. Sketches rather than finished drawings were made in the second series. The refractive state was determined by retinoscopy and the findings checked subjectively using Snellen's chart. On the second series the duochrome was also used. Neither mydriatics nor cycloplegics were used when determining the refractive state. The first series was examined when interest was largely centred in non-temporal crescents. For this reason, fundi which did not have such a crescent were not drawn and signs of stretch, other than temporal crescents, were not recorded. In 12 cases of this series the records are incomplete.

The two series will be considered simultaneously because the findings in each will, in many instances, be compared. The following classification of scleral stretch will be used throughout.

- a. Temporal stretch - where greatest ectasia was diagnosed as within 30° of temporal to the optic disc.
- b. Non-temporal stretch - where greatest ectasia was diagnosed as 30° or more from temporal to the optic disc.
- c. Uniform - where no localization of ectasia was detected.

The incidence of each class of stretch in the eyes of the second series is shown in table II. Of the three classes, temporal stretch is most common. The relative temporal pallor of the optic disc, which is a feature of the majority of eyes, is largely a result of this class of stretch. Non-temporal stretch and uniform stretch make up 27.4% and 14.7% respectively. The latter incidence

is almost certainly too high because these eyes are merely ones in which no local ectasia was detected. Comparable figures are not provided by the first series.

Any individual case may have one of six possible combinations of the three classes of stretch. The incidence of each combination in the second series is shown in table III. The eyes of individual cases tend to have similarly distributed stretch. Those with bilateral uniform and bilateral temporal stretch have an approximately similar distribution of stretch. Those with bilateral non-temporal stretch may have greatest ectasia anywhere within an angle of 150° . Any pair of such eyes may therefore have a quite different distribution of stretch. Of 102 cases in this group however, 79% had greatest ectasia within 30° of symmetry. Of 60 cases with non-temporal stretch in one eye and temporal in the other, greatest ectasia was within 30° of symmetry in 20%. All of the cases in the remaining two groups had a different distribution of stretch in the two eyes. The distribution of stretch was thus approximately the same in 404 (81%) cases of the second series. Of 72 cases in the first series with bilateral non-temporal crescent (80%) had greatest ectasia with 30° of symmetry. This corresponds closely to the 79% obtained for those with bilateral non-temporal stretch in the second series. Of 112 cases with non-temporal crescent in the first series 40 (36%) had the crescent in one eye only. Of 171 cases with non-temporal stretch in the second series 69 (40%) had one eye only affected. The incidence of unilateral cases is substantially the same, as is to be expected if non-temporal crescents and non-temporal stretch are different degrees of the same process. Of 40 cases in the first series with unilateral non-temporal crescent, 17 had a primary temporal crescent and two had peripapillary choroidal atrophy. This alone, is almost conclusive evidence that temporal and non-temporal crescents have the same aetiology since two primary crescents do not occur in the same eye.

Table 4 shows the incidence of greatest ectasia in 10° sectors as found in each of the two series. In compiling the table, the figures from left eyes were transposed and combined with those from right eyes. Fig. 60 shows several examples from the second series, in which the estimated direction of greatest scleral stretch from the optic disc is indicated. The incidence shows four peaks in the range of 30° - 180° which is common to both series. In each, the peaks correspond in position. They are situated at 30° - 40° , 90° - 100° , 120° - 150° and 180° . An additional peak at 5° - 10° contains about half of the eyes with non-uniform stretch in the second series.

There are thus five regions in which greatest ectasia tends to occur. It is probable that in most eyes the entire lower half of the posterior sclera, including all five regions, stretches to a greater degree than the upper half, because irrespective of the location of greatest ectasia the temporal branches of the retinal vessels make a wider sweep below than above the posterior pole.

The type of optic disc varies, to some extent, with the location of greatest ectasia. Tables 5 and 6 show this relationship in the first and second series respectively. In the first series the round disc is of highest incidence when greatest ectasia is at 30° - 40° , the D-shaped disc at 90° - 100° , the reduced oval disc at 120° - 130° and the enlarged oval at 180° . There are few pear-shaped discs on which to base conclusions but it does appear that the incidences of this type of disc is that of the D-shaped and reduced oval disc combined. The findings in the second series are largely the same as in the first. The essential difference is that the round disc is more frequent in the former, irrespective of the location of greatest ectasia. The incidence of greatest ectasia in those with circular discs has five peaks which correspond in position to those of the second series as a whole. The peaks are therefore not caused by the same factors which determine the disc type. As already deduced, the location of greatest ectasia depends on the distribution of stretch in the outer scleral layers while the disc shape and size depend on that in the inner layers. It appears that the inner layers tend to have a distinct resistance pattern and that the part of this pattern revealed, as an alteration in the shape and size of the disc, depends on the site of greatest stretch in the outer layers. The relationship between the disc type and the site of greatest ectasia thus reflects a degree of constancy in the resistance pattern of the inner layers. The five regions in which greatest ectasia tends to occur, reflect the resistance pattern of the outer layers.

Spherical refraction.

The incidence of refractive errors, as spherical equivalents, in each series and in each of the three groups derived from the second series is shown in table VII and fig. 78. The group with uniform stretch has the greatest proportion of hypermetropes (50%) and the lowest of myopes (12%). Since the eyes are grouped on the basis of scleral stretch it may be presumed that those of this group have the shortest average axial length. The group with temporal stretch has a smaller proportion of hypermetropes (28%) and a greater proportion of myopes (38) than the previous group. This

shift towards myopia indicates that the average axial length is greater in this group than the previous and also that temporal stretch is a local excess rather than a mere local stretch because more widespread uniform stretch would increase the axial length to a greater degree than would local stretch at the posterior pole. The group with non-temporal stretch has an incidence of hypermetropia (38%) which is intermediate to that in the other two groups. Since stretch in these cases is situated away from the posterior pole the increase of axial length is less and the incidence of hypermetropia greater than in the group with temporal stretch. The incidence of hypermetropia is less than in the group with uniform stretch indicating that this class of stretch, like temporal stretch, is a local excess rather than a purely local stretch. The incidence of myopia (42%) is greater than in either of the other groups. The probable reason for its exceeding that in the group with uniform stretch has already been given. It also exceeds that in those with temporal stretch. The probability is that non-temporal stretch is a local excess which may accompany local excess stretch temporal to the optic disc.

Generally, temporal rather than non-temporal stretch is considered to be characteristic of myopic eyes. This generalization remains correct in spite of the above findings because only 33% of the myopes in the second series have non-temporal stretch. The above findings do however, indicate that an eye with non-temporal stretch is more frequently myopic than one with temporal stretch.

The incidence of emmetropia is much lower in the group with non-temporal stretch than in either of the other groups. Asymmetrical eyes tend to be ametropic while symmetrical tend to be emmetropic. This feature will be referred to again when considering astigmatism and the aetiology of refractive errors.

Astigmatism

The eyes of the second series were divided into three groups, each with a different class of scleral stretch. The incidence of astigmatism in each group is shown in table 8. 39% of those with non-temporal stretch have one dioptré or more of astigmatism while those with temporal and uniform stretch have an incidence of only 15% and 13% respectively. Non-temporal stretch produces greater posterior asymmetry than do the other classes of stretch. Asymmetry anteriorly and posteriorly thus tend to be

associated. In the first series, 60% of the eyes with primary non-temporal crescent had one dioptre or more of astigmatism, (table 9). There is thus also a quantitative relationship between anterior and posterior asymmetry, suggesting that the former, like the latter results from stretch of the sclera. Shapland (1953) showed that the corneal curvature is increased in a direction at right angles to the long axis of a sclerectomy and that the resulting astigmatism is about 4 dioptres. For example, resection below produces direct astigmatism. Local lack of stretch anteriorly might be expected to act in the same way while local excess stretch in the same location might be expected to produce inverse astigmatism. Since scleral stretch is present in all eyes it may, when abnormal, be excessive or deficient. As already mentioned, greatest scleral stretch is seldom above the horizontal meridian posteriorly; the upper half of the posterior sclera is generally more resistant than the lower half. If this applies also to the anterior sclera, deficient stretch will tend to be in the upper half with resulting direct astigmatism and excessive stretch will tend to be in the lower half with resulting inverse astigmatism. Considered on this basis, astigmatism is the product of two processes having opposite effects on the corneal curvature. It is on this basis that an attempt will now be made to elucidate the relationship between the angle of astigmatism and fundus signs of scleral stretch.

The angle of astigmatism and the location of greatest stretch posteriorly in left eyes with non-uniform scleral stretch were transposed in both series so as to correspond to those of the right eyes. Table 10 and fig. 79 show the incidence of astigmatism at various angles with greatest scleral stretch in various locations. They represent the combined findings from both series of cases and have several features requiring to be accounted for.

a. Irrespective of the location of greatest scleral ectasia, direct astigmatism is most common. This probably reflects a general tendency of the upper anterior sclera to resist stretching as does the upper posterior sclera. It is most marked when greatest stretch is temporal to the optic disc and, as already stated, somewhat below the posterior pole. This feature is less marked as greatest ectasia is located further from the posterior pole, except when greatest ectasia is nasal to the optic disc. The non-conformity of the latter will be considered in the next paragraph. It appears that when greatest ectasia is directly below the posterior pole the region of least stretch has the greatest tendency to be directly above the anterior pole as if they have a tendency to lie at opposite poles.

b. There is a distinct tendency for the least refracting axis to correspond to the location of greatest ectasia posteriorly. This feature is evident in all except those with temporal stretch. It is most marked where greatest ectasia is somewhat nasally situated and therefore relatively anterior. In this position it may directly reduce the curvature of the corresponding corneal axis. That this feature is present when greatest ectasia is infero-temporal to the optic disc indicates that such an ectasia is, at least in some instances, also infero-temporal to the posterior pole. That the least refracting axis does not, in the majority of cases, correspond to the location of greatest ectasia is probably due to the neutralising effect of deficient stretch antero-superiorly. It is possible that the tendency of the least refracting axis to correspond to the location of greatest ectasia merely reflects a corresponding local excess stretch both anteriorly and posteriorly.

c. The further from temporal to the optic disc the location of greatest ectasia the more frequently is the least refracting axis inclined infero-temporally. This does not, however, apply where greatest ectasia is nasal to the optic disc. It indicates a tendency for the least and most stretched parts of the sclera to be located as opposite poles. The upper temporal quadrant anteriorly tends to be most resistant and the lower nasal quadrant posteriorly least resistant. Greatest ectasia infero-temporal to the optic disc may be infero-temporal, inferior or even infero-nasal to the posterior pole. That it is most frequently infero-temporal to the posterior pole is suggested by the relatively high frequency with which the least curved corneal axis is at 60° - 80° and 150° - 180° . When greatest ectasia is nasal to the optic disc both the resistance to stretch antero-superiorly and the excess stretch nasally summate to produce direct astigmatism.

d. The relatively high incidence of inverse astigmatism in eyes with temporal stretch probably reflects the general tendency of the lower half of the eye to undergo greater stretch than the upper half.

The various features of table 10 and fig. 79 lend support to the suggestion that astigmatism is largely a product of two opposing factors, local lack of stretch and local excess stretch, acting on the cornea. The former tends to be located above and the latter below the horizontal meridian. The posterior sclera shows a similar distribution of stretch in that the lower parts tend to be less resistant than the upper. Since the posterior sclera develops later than the anterior, excess stretch in its lower half tends to

be most prominent while anteriorly lack of stretch in the upper half tends to be the most prominent feature. When stretch of the sclera posteriorly is fairly symmetrical relative to the posterior pole that anteriorly tends to be fairly symmetrical relative to the anterior pole with resulting relative lack of astigmatism. The characteristics of stretch anteriorly and posteriorly however, do not always correspond closely, because eyes with essentially similar fundi may have equally high degrees of astigmatism at quite different angles. The problem of astigmatism will be considered further in Part V of the present work.

The above view on the significance of astigmatism may not be quite correct because, on naked eye inspection, it appears that the variation of scleral curvature is largely above the cornea. There appears to be flattening when astigmatism is direct and bulging when it is inverse. If this observation is correct the relationship between anterior and posterior asymmetry of the eye, however, becomes difficult to explain.

Anisometropia

The second series was divided into six groups each consisting of cases with a different combination of the three classes of scleral stretch. The incidence of anisometropia in each is shown in Table 11.

The lowest incidence of anisometropia, 33%, is in the group with bilateral uniform stretch. Generally speaking, the eyes of this group are more hypermetropic and less stretched than those of the other groups. It therefore appears that those with lesser amounts of stretch tend to be relatively free of anisometropia.

Of those with bilateral temporal stretch, 51.8% have anisometropia. As a group, they are more stretched than the previous. The greater incidence of anisometropia is due to the fact that differences of stretch increase with the total amount of stretch.

The group with bilateral non-temporal stretch show a 67.0% incidence of anisometropia. In these eyes the axial length depends not only on the amount of stretch but also on the location and extent of local excess stretch, slight differences in either of which give rise to clinically detectable anisometropia. This largely accounts for the greater incidence of anisometropia in this group than in the previous.

In the remaining three groups 75.6% have anisometropia. These cases have a different class of stretch in the two eyes. Since they have the greatest difference in the distribution of stretch they have also the highest incidence of anisometropia.

It appears that scleral stretch may be largely responsible for the presence of anisometropia. In view of this, an attempt was made to diagnose the presence or absence of anisometropia from fundus signs of stretch in the second series of cases. By the same means, an attempt was also made to diagnose the more hypermetropic or less myopic eye. Cases with a different class of stretch or with differently located local excess stretch in each eye were omitted from this investigation because the correct diagnosis in such cases requires an estimation of the relative effects of differently distributed, and frequently unequal, stretch on the axial length. Even in these it was usually possible however, to give a correct diagnosis when the degree of anisometropia was one dioptré or more. They represent only 20% of all the anisometropes. The remaining 80% are cases in which the amount rather than the distribution of stretch is different in the two eyes and it is with these that the following part of the investigation is concerned.

The diagnosis of anisometropia was made largely on the shape and size of the physiological cup, A difference in these was taken as an indication of the presence of anisometropia. With the following exceptions the larger cup was considered to belong to the more myopic or less hypermetropic eye.

a. Those with marked retinal supertraction in which the more myopic eye may, as already mentioned, have the smaller cup.

b. Those in which glial tissue on the disc hinders enlargement of the cup.

c. Unequal bulbous cups which may be due to unequal stretch of the lamina cribrosa.

All of these exceptions can usually be correctly diagnosed from other features of scleral stretch such as pigment changes at the disc margin, crescents and the degree of displacement of retinal vessels.

Of 500 cases in the second series, 389 were considered suitable for the present investigation. Of the latter, 188 had isometropia and 201 anisometropia of 0.25 dioptries or more. The cups were diagnosed as similar in 152 (80.9%) of those with isometropia and in only 36 (19%) were they diagnosed as dissimilar. The cups in isometropia have thus a distinct tendency to be similar.

The findings in those with anisometropia are shown in table XII. The most significant features are the high proportion of correct diagnoses in those with only 0.25 dioptries of anisometropia and the almost invariably correct diagnosis in those with 1.00 dioptrie or more of difference.

While 0.25 dioptrie of anisometropia can represent no more than about 0.08 mm. difference between the axial lengths it probably represents at least 0.25 mm. difference in the lengths of the posterior half of the sclera which equals about 1/6 of a disc diameter. This is still a small difference but it is probably not distributed uniformly throughout the retina because adaptation of the latter to scleral stretch takes place to a large degree as a straightening out of the nerve fibres on the optic disc. This concentration of the retinal response at the disc renders even small differences of scleral stretch clinically detectable as differences in the appearance of the physiological cup.

Of those with 0.25 dioptre of anisometropia, 29% were correctly diagnosed from the fundi while only 12% were wrongly diagnosed. The conclusions which may be drawn from this are that the eyes of an individual are, as a rule, practically alike except for their axial lengths and that anisometropia is largely due to differences in the degree of scleral stretch.

Of those with 1.00 dioptre or more of anisometropia, 93% were correctly diagnosed from the fundi. The limit of difference between the powers of the refracting media in any pair of eyes is therefore about 1.00 dioptre. This agrees with the findings of Joseph (1936). He found that among 50 cases with 3.00 dioptres or more of anisometropia none had more than 1.00 dioptre of corneal difference and that such differences could only account for 1/17 of the total anisometropia. He concluded, without taking into account the possibility of variation in the lenticular refracting power, that anisometropia is largely due to differences of axial length. The findings of the present investigation confirm this view and indicate that the differences of axial length are caused by stretch of the sclera. The development or change in degree of anisometropia in healthy growing eyes indicates, therefore, the presence of active scleral stretch. An equal degree of change in both eyes of such cases may however, result from either growth or stretch.

The refraction incidence in isometropes and anisometropes of the second series is shown in table XIII and fig. 80. The anisometropes tend to be more ametropic than the isometropes and are more frequently myopic than hypermetropic. This may be accounted for in the following manner. When the degree of stretch differs in a pair of eyes at least one of the eyes has either deficient or excessive stretch. In either case the refraction tends to be ametropic. Since differences of stretch must increase with the amount of stretch, anisometropia is more frequent in myopic than hypermetropic eyes.

PART III

Some of the views so far expressed are controversial or unorthodox and the supporting evidence has been scattered. The present section will therefore be largely devoted to a more compact and comprehensive consideration of the evidence on which these views are based.

Significance of crescents.

Choroidal pigment and blood vessels may be visible in all or any part of the crescent area (figs. 5, 10 and 29). The crescent is therefore an area previously occupied by choroid. Since the disappearance of choroid in the crescent area is incomplete the crescent is not produced by dragging of the choroid from the disc margin. Primary atrophy or inflammation may account for the disappearance of choroidal tissue but not for the crescent shape because the choroid lacks anatomical features which might limit the defect to such an area. The factor responsible for the crescent shape, and hence the disappearance of choroid, must be extra-choroidal. The tissues directly related to the choroid are Bruch's membrane and the sclera. Of these, only the former has anatomical features which, under the influence of stretch, can account for the crescent shape. The assumption, made previously, that choroid which is uncovered by Bruch's membrane undergoes atrophy appears therefore to be justified. As shown in the first section of the present work, the action of stretch on Bruch's membrane can account for all of the features of the highly complex and varied picture presented by crescents and peripapillary choroidal atrophy

That the well-being of the choroid should depend on that of Bruch's membrane is not easily accounted for but it should be noted that choroid related to defects in the membrane is seldom normal. Angioid streaks which result from defects in Bruch's membrane overlies defective choroid and are commonly associated with disciform degeneration of the macula in which the membrane is also defective. It is also probable the appearances of "choroidal rupture" are in fact due to rupture of Bruch's membrane with secondary choroidal atrophy because the choroid is elastic and firmly supported by the sclera while the membrane is inelastic and supported only by spongy choroid from which blood may be expressed by the force of a blow. It is also possible that some unexplained degenerative lesions of the choroid and retina are primarily due to faults in Bruch's membrane.

Significance of non-temporal crescents

For the following reasons, they, like temporal crescents, are caused by scleral stretch as suggested by Elschmig (1903).

1. The clinical appearances correspond to those of temporal crescents.
2. The associated fundus appearances correspond to those which accompany temporal crescents.
3. A primary temporal crescent never occurs in an eye with a primary non-temporal crescent irrespective of the refractive state.
4. In spite of the previous, almost half of the cases with unilateral non-temporal crescent have a temporal one in the other eye.
5. They may increase in size as shown in figs. 6, 7, 8, 9, 27.
6. Choroido-retinal atrophy, as extension of the crescent or as isolated patches, takes place in the direction of the crescent.
7. The refraction is usually myopic. In a series of 62 eyes, Beeler (1929) found 24 with over 5 dioptries of myopia and only 9 with hypermetropia. Worton (1911) found 25 out of 44 myopic. Among 189 eyes reported in the present work 157 were myopic of which 55 had over five dioptries.
8. The most ectatic part of the fundus is located in the direction of the crescent. Beeler (1929) detected such an ectasia in 69.5% of cases.
9. Where one eye has a temporal crescent and the other a non-temporal, the appearances of the crescents are similar. The same is true where differently situated crescents occur in members of the same family. Figs. 32 and 33 show crescents in a mother and son respectively. In both the crescents are occupied by a network of choroidal vessels with heavily pigmented interspaces; only the location of the crescents differs in the two patients. Both had a highly myopic refraction.

10. The size of the crescent tends to vary directly with the degree of myopia as does that of temporal crescents. Beeler (1929) noted this relationship between the crescent size and the refractive state. The relationship is very close in cases of anisometropia with correspondingly located crescents but not in the eyes of different individuals.

Those who hold the view that these crescents do not result from scleral stretch support it by pointing out they do not progress, are frequently found in hypermetropic eyes, are present at birth, may be associated with temporal crescent, may accompany coloboma of the choroid and differ in incidence from temporal crescents. The effectiveness of these points against the scleral stretch view will now be considered.

These crescents not only show signs of increase but do so in a manner similar to that of temporal crescents (figs. 64, 65 and 66). They may develop after birth (fig. 109). It is true that the refraction may be hypermetropic but this is also true of eyes with temporal crescents. It has been pointed out previously that the vast majority have a myopic refraction. That non-temporal crescents may be present at birth need not indicate that they are not due to scleral stretch; it merely shows that the degree of stretch before birth may be sufficient to produce a crescent. That temporal and non-temporal crescents may be present in the same eye is true but as already mentioned not more than one is primary. Choroidal colobomata are frequently stretched and ectatic. It is therefore to be expected that a crescent might occur at the corresponding part of the disc margin in such cases. The association of a crescent with choroidal coloboma does not therefore indicate that they have the same aetiology. There is, indeed, no certainty that choroidal coloboma itself is not a manifestation of scleral stretch. The difference in incidence of temporal and non-temporal crescents is definite but does not constitute evidence against either view. It is, if anything, in favor of the stretch view because the highest incidence of crescents is temporal to the disc and the posterior pole is the last part of the sclera to develop.

The fundus appearances which constantly accompany crescents are displacement of the retinal vessels and obliquity of the physiological cup. Less constantly the disc shape is altered and scleral ectasia can be detected in the direction of the crescent. These, with crescents, form a group of clinical signs. The crescent is not however, an assential part of the group as can be seen on comparing figs. 15 and 16 or 44 and 45. In view of this it is almost certain that the views of both Jager and Mann are incorrect.

Significance of the Physiological cup.

Since atrophy of Bergmeister's papilla is almost complete it does not play any significant part in the determination of the size or shape of the physiological cup. It is merely a process which reveals the cup.

For the following reasons it is probable that the presence, size and shape of the cup are determined by lengthening and displacement of the retina as a result of scleral stretch.

1. In cases of anisometropia having similarly distributed stretch in both fundi the smaller cup generally belongs to the less myopic or more hypermetropic eye. This is true no matter how small the cups may be and is evidence that the cup is produced by stretch.
2. Strands of glial tissue may bridge the physiological cup (figs. 51 and 52) and tags which may be the ends of ruptured strands are occasionally attached to the cup margin. These are most easily seen with the slit lamp and Rhuby lens but are visible with the focused beam of the ophthalmoscope. Fig. 53 shows a ledge of glial tissue projecting from the temporal margin of the cup. Its free border corresponds in outline to that of the nasal margin of the cup suggesting that they were previously united and had been dragged apart. If this is correct it can be said that at least this individual cup is a result of stretch. For illustrative purposes the glial strands in figs. 51 and 52 have been exaggerated.
3. The configuration of the cup is characteristic for each of many complex fundus pictures which can only be fully accounted for on the basis of scleral stretch.

The observations of Pickard (1923) are of interest regarding the significance of the physiological cup. He observed an increase in the size of the cup in eleven eyes. Of these, seven were aged 8 - 14 years and four 44 - 68 years. The former group alone will be considered meantime; the latter will be considered with senile cups. An increase

of 6-18% in the cup area was noted in a period of 11-19 months. This rate of increase could not have been present since birth. The increase could hardly be due to retinal growth because there is no acceleration of neural growth at this age period, and, in any case, growth would tend to decrease rather than increase the cup area. No instances of diminution of the cup area were noted by Pickard. There are several ways in which the spasmodic nature of the enlargement may be explained.

a. The rapid increase in size of the cup may indicate that excess retina has to be taken up by scleral stretch before actual stretch of the retina takes place.

b. It may be that the retina slips in stages as does Bruch's membrane.

ac. More rapid retinal growth at an earlier age may neutralize, to varying extents, the enlarging influence of scleral stretch.

Further observations made by Pickard were that the enlargement was conical and largely towards the inferior temporal quadrant. Both of these are consistent with the view that the enlargement was due to retinal stretch.

Factors other than stretch which may influence the physiological cup.

1. Senility. In elderly persons, there is commonly a general depression of the disc. This senile cupping is not due to stretch of the lamina cribrosa because no part is excessively deep. Although it is very like the early glaucomatous cup the intra-ocular pressure is not raised. It is not due to stretching of the nerve fibres on the disc because the projecting margin of the original cup is occasionally visible in its depths (fig. 34). It appears to be due to inability of the nerve fibres to resist the normal intra-ocular pressure. A similar state of the retina in the general fundus may account for the relative lack of fundus reflexes in senility. The lack of neural resistance on the disc is related to stretch because it is much more common in myopic than in hypermetropic eyes. Figs. 34 and 35 show the optic discs of a 65 year old patient whose right eye alone was myopic and which alone had senile cupping of the disc. In this way the senile cup in anisometropic patients tends to be longer in the more myopic or less hypermetropic eye. Of the four cases aged 44-68 years in which Pickard noted an increase in size of the physiological cup, all were unilateral. The refractive state was not noted in these cases but it may be significant that of the affected eyes one had unilateral crescent and another, unilateral peripapillary choroidal atrophy. It is probable that the enlargement of the cups was of senile type.

2. Stretch of the lamina cribrosa: It is probable that the bulbous shaped cup, which is widest in its deeper parts, is determined by this factor. The greater part or all of its margin is sharply defined and projects towards the centre of the disc. It differs from the glaucomatous cup in that its projecting margin is internal to that of the disc, is rounded, of good color and does not constrict the retinal vessels which cross it. The nerve fibres do not atrophy. The cup may be small or large but is characteristically deep (figs. 74, 75). The lamina cribrosa is more posteriorly situated than usual and its fenestrae tend to be large. These suggest that the lamina cribrosa is stretched. The projecting margin rules out retinal stretch as the cause of this type of cup. Its appearances are influenced however by stretch like those of other cups and the inner opening may be displaced as far as the disc margin in the direction of greatest scleral ectasia. The part of the cup margin which reaches that of the disc in such eyes does not project (fig. 76). It is interesting that the arteries alone but never the veins alone may bridge the bulge in the cup wall. This is in keeping with the view expressed earlier that the arteries are more resistant to bending than the veins and indicates that the bulbous shape is acquired.

3. The degree of retinal growth relative to the length of the sclera: Where the former is marked there may be abundant neural tissue at the disc and a very small physiological cup, even when scleral stretch is sufficient to produce a crescent. In this way pseudo-neuritis of the optic disc may occur in emmetropic or myopic eyes although most frequent in those with higher degrees of hypermetropic.

4. Rarely strong bands of glial tissue obstruct opening of the physiological cup, (fig. 70).

30

PART IV

Scleral stretch and the visual fields.

Fairly characteristic changes may occur in the visual fields of eyes with well marked fundus signs of scleral stretch. In 100 cases of high myopia, most of whom had greatest ectasia temporal to the optic disc, Jayle and Bérard (1955) found 91 with defective visual fields. The most common abnormalities were enlargement of the blind spot into the superior temporal quadrant with occasional extension to the superior nasal quadrant and the fixation area. They also noted an occasional extension of the blind spot below fixation, annular scotomata, concentric contraction and hemianopia. Of the latter, three, with no other evidence of a neurological lesion, had bitemporal hemianopia. They found that while such defects may be present in young adults they are most frequently encountered after the age of 50 years. No attempt was made to account for the defects. In eyes with non-temporal crescents and "tilted" discs without crescents Rucker (1946) found superior temporal defects breaking through from the blind spot to the periphery. All of the above defects were only detectable with small targets.

The present investigation was originally of the visual fields in eyes with non-temporal crescents but was later extended to include those with other fundus signs of scleral stretch. The Lister recording perimeter and the Bjerrum's screen were used in all of the earlier cases. Later cases were frequently examined with the screen alone. Most of the screen examinations were carried out at a distance of one metre in bright diffuse daylight; otherwise constant artificial illumination was used. The distance correction was worn for all of the screen examinations. The optic discs were drawn. The intra-ocular pressure was recorded with the Schiøtz tonometer at each examination. Several isopters were recorded and the examination was repeated at intervals of a few days to several months. Cases with defects of the refractive media or fundus disease, other than crescents were omitted. In all, defective visual fields were recorded in 130 eyes.

The most common abnormality was an area of depressed vision extending from the blind spot into the upper temporal quadrant and breaking through to the periphery, (figs. 81, 83 and 87). In older persons, it is seldom detectable with white targets larger than 3 mm. at a distance of one metre. A large proportion of the defects were found to be sectors which did not break through to the periphery, (figs. 82 and 106). Some which showed a defect breaking through to the periphery with the Bjerrum's screen showed a sector which did not do so when examined with a perimeter of one metre radius (figs. 82, 83).

3)

The appearances of the visual fields vary from one eye to another. The essential defect appears to be a sector or combination of sectors. The following variations are most frequently encountered.

a) The defect may extend into the superior nasal quadrant (figs. 84, 85 and 108). It may extend as far as the nasal meridian (figs. 100, 101 and 102).

b) A second but less marked sector may extend inferiorly from the blind spot (figs. 103 and 104). The greater part of the temporal field may be absent when using small targets and the tangent screen (figs. 82 and 93).

c) Defect may be separated from the blind spot or may be most dense at some distance from it (figs. 105, 91 and 107).

d) Any or all of the isopters may be contracted, especially above the horizontal meridian (figs. 88, 92 and 107). The defect may come very close to the fixation area (figs. 83, 85 and 87).

On repeating the visual field examination the extent and density of the defect was found to vary whether the illumination used was diffuse daylight or constant artificial light. In some, marked change occurred in a period of days (fig. 86 and 90) while in others, very little change took place in a period of months (fig. 88 and). The latter were usually over 50 years of age, although a constant defect may occur in children of school age (fig. 91). It may be significant that this fluctuation of the visual field defect is also a feature in early cases of glaucoma where the intraocular pressure fluctuates. No relationship between the intraocular pressure and visual field variations was found in the present investigation. The defect increased in some (figs. 85 and 105) and decreased in others (figs. 83, 97, and 108). An increase followed by a decrease was also noted (figs. 86). The defect may disappear only to reappear later (fig. 89). This is one of the reasons why the incidence of such defects is uncertain. The defect may increase in one eye and decrease in the other (fig. 90). An unduly large proportion showed reduction or disappearance of the defect on repeated examination. It is possible however, that it was the visual field defect, causing disturbance of vision, which induced these patients to attend for eye examination.

In a few older people the defect was detectable with white targets as large as 2 - 3 mm. at 1/3 of a metre (figs. 92, 93, 108). The following cases are worthy of mention individually.

a. Fig. 94 shows a dense peripheral sector defect in the upper nasal quadrant. It is unconnected to the blind spot and associated with an inferior nasal crescent. Unlike the defect of glaucoma it showed a progressive decrease over a period of months. The intra-ocular pressure was at no time recorded as over 22 mm. of mercury and no increase follows instillation of 1% homatropine drops. There was no evidence of arterial obstruction in the retina and the visual field defect was accidentally discovered. The other eye was emmetropic with a normal fundus and no crescent.

b. Fig. 95 is from an eye with a primary inferior temporal crescent and two dense sector defects, one extending below fixation to the nasal meridian and a second extending to the inferior temporal periphery. The visual field defects showed no significant change over a period of months. While the disc was rather pale there was no obvious glaucomatous cupping and the intra-ocular pressure remained below 20 mm. of mercury even after instillation of 1% hematropine drops. A notable feature of the optic disc was elongation and narrowing of the fenestrae of the lamina cribrosa. The retinal arteries appeared normal. The left eye was similar but had sectors both above and below the fixation area. The cause of the field defects is not known but it appears a possibility that the nerve fibres are constricted at the lamina cribrosa.

Significance of Visual Field Defects.

The visual field defect is not due to a crescent because it may be present when the latter is absent (fig. 96). Defects exactly the same as some of those found in the present investigation were reported by Rucher (1946) in cases with "tilted" optic discs but no crescents. The field defects are however, not entirely unrelated to crescents. They are most common in eyes with crescents and are usually located above while the crescent is usually below the horizontal meridian. Also noteworthy in this respect is the finding that of two cases with superior crescent one had no defect of the visual field while the other was the only case in which an inferior sector defect alone was present (fig. 97).

Choroido-retinal lesions other than crescents were not present in the eyes investigated and cannot therefore account for the visual field defects. There was no evidence of retinal artery obstruction. Stretch of the retinal nerve fibres is not likely to be the chief factor because many of the most markedly stretched eyes have full visual fields and a large part of the retinal response to scleral stretch is a straightening out, rather than a stretch, of the nerve fibres at the optic disc.

The intra-ocular pressure was under 30 mm. of mercury in all cases so that the visual field defect can hardly be glaucomatous. Hematropine 1% drops were used when fundus drawings were made and in no case did it produce a rise of intra-ocular pressure.

Kinking of the nerve fibres forming a loop at the disc margin does not appear to depress their function because no field defect may be detected in such cases (e.g. fig. 23).

Since the visual field defect is sector shaped and associated with scleral stretch the lesion must affect the nerve fibres at the optic disc. There are indications that the lamina cribrosa constricts the perforating nerve fibre bundles and produces the visual field changes.

Where a crescent or other signs of marked scleral stretch are present the fenestrae of the lamina cribrosa may be narrow, elongated and slit-like. Only part of the lamina cribrosa may show this (fig. 76). The lamina cribrosa is, however, not usually visible in eyes with marked scleral stretch so it is not possible to estimate the frequency with which the fenestrae are elongated. The elongation appears to be related to the type of optic disc and the distribution of scleral stretch. Where the disc is circular or enlarged oval, the elongation of the fenestrae is in the direction of greatest scleral ectasia (figs. 1, 50 and 58). In one case with a D-shaped disc the elongation was at right angles to the direction of greatest ectasia (fig. 48). In eyes with glaucomatous cupping of the disc, in which the lamina cribrosa is often extensively visible, elongation and narrowing of the fenestrae is commonly present near the disc margin.

The findings so far agree with those of Ruckev as well as Jayle and Berard.

On repeating the visual field examinations at intervals rather surprising results were obtained. The extent and density of the defect varied whether the illumination used, was diffuse daylight or constant artificial light. The rate of variation differed

from one patient to another. In some, well marked variation was noted in a period of days while in others, especially older people, there was negligible variation over a period of months. It may be significant that the early sector defects and general depression of glaucomatous eyes may show rapid fluctuation with the intra-ocular pressure. Three eyes with both glaucoma and primary non-temporal crescent were examined. All had previously an intra-ocular pressure of at least 45 mm. of mercury and had been only partially controlled with miotics. The visual fields showed a dense sector defect breaking through to the upper periphery and failing to reach the nasal meridian (figs. 98, 99R and 99L). This defect resembles those already attributed to stretch of the sclera rather than the typical defect with nasal step of glaucoma. It appears likely that in glaucoma the high intra-ocular pressure produces field defects by the same mechanism as does scleral stretch. The fluctuation of the visual field defect does not suggest a progressive disease process. It resembles that which commonly takes place in the early field changes of glaucoma. It is most probably due to slight fluctuations in scleral stretch with intermittent compression of the nerve fibres by the lamina cribrosa. The marked decrease in extent and density of the defect is probably comparable to that which follows removal of a pituitary tumor pressing on the optic chiasma. The tendency of the defect to increase in density and constancy from childhood to senility may be due to structural damage resulting from repeated compression of the nerve fibres or to increasing loss of scleral elasticity.

The conclusion is that compression of the nerve fibres by the lamina cribrosa is probably responsible for the visual field defects in eyes with marked scleral stretch and that a similar mechanism may account for the defects in glaucomatous eyes. It is also probable that the distribution of the field defects and scleral stretch are not unrelated.

35

PART V

From the previous sections it appears that astigmatism and anisometropia are largely due to stretch of the sclera. It also appears that stretch has a distinct influence on the spherical refraction. Still to be considered is the evolution of scleral stretch and its relationship to that of the refractive state.

Evolution of Scleral Stretch

Fundus signs of scleral stretch are well marked at birth. The physiological cup is almost always present and its range of appearances approximates that in adults. The distribution of the retinal blood vessels does not differ markedly from that in mature eyes. Although pigment and scleral rings are common at the disc margin, the choroidal and pigment epithelial changes are in general much less marked than in adults. The relative lack of such changes is attributable to their being secondary to the effects of stretch on Bruch's membrane rather than a direct result of scleral stretch. Both temporal and non-temporal crescents may, however, be present at birth. Elwyn and Knighton (1943) reported well marked signs of stretch in an 8 months old child. Hoffman and Carey (1943) reported nasal displacement of the retinal vessels at the lamina cribrosa in female twins aged 3 years. Morgan (1939) saw ten cases aged 2 - 3 years with myopic fundus changes in a series of 494 myopic children. It is apparent that most rapid stretch takes place before or soon after birth. The only force capable of producing such stretch is the intra-ocular pressure. The latter is, however, 12 mm. of mercury or less until about the 200th pre-natal day when it rises rapidly to over 20 mm. (Brockhurst 1955). Stretch must therefore take place after the 200th day.

The anterior sclera develops some considerable time before the posterior. There is little development of the latter until the fourth month of foetal life and the sclera is not well differentiated, all round, until the fifth month (Mann 1928). Stretch anteriorly tends therefore, to be less marked and of shorter duration than that posteriorly. It has already been deduced, from study of astigmatism and fundus signs of scleral stretch that greatest resistance is usually located in the upper half of the anterior sclera while least resistance tends to be diametrically opposite in lower half of the posterior sclera.

This suggests that scleral development commences antero-superiorly and is completed at the opposite pole postero-inferiorly. The most common site of least resistance, and hence of latest scleral development, is however slightly below the posterior pole.

Stretch posteriorly may continue well into post-natal life. Pickard (1923) noted enlargement of the physiological cup between the ages of 14 and 16 years. Sourasky (1928) noted a change of one dioptré or more in the degree of anisometropia in 18 cases between the ages of 5 and 16 years. I have noted a similar change at the age of 20 years in the absence of ocular disease. As already shown, these changes usually indicate the presence of scleral stretching. It is probable therefore, that stretch of the posterior sclera may continue until at least the age of 20 years.

Evolution of the Refractive State

Since this varies from one eye to another only the average refractive state will be considered meantime. That the pre-natal refraction might be myopic was suggested by Gleiss and Pau (1952). This was confirmed by Fletcher and Brandon (1955) who found that premature infants weighing less than 1250 grams have 10 - 20 dioptrés of myopia which fluctuates markedly and diminishes rapidly. They also noted a well marked and fluctuating astigmatism in these cases. Cook and Glasscock (1950) found that 25% of newborn infants have myopia and that of these, 12% have 5 dioptrés or more. Brown (1938) found that the average refraction in 97 eyes examined before the age of two years was 1.52 dioptrés of hypermetropia. He found an average annual increase of 0.18 dioptrés in the degree of hypermetropia until the age of 7 years following which an average decrease of 0.23 dioptrés took place until the age of 13 years. From the age of 14 to 20 years the decrease continued at the reduced annual rate of 0.14 dioptrés. Subsequent changes were slight.

Scleral stretch and the Refractive State.

Most rapid scleral stretch takes place before or soon after birth. Increase of axial length is most rapid at the same time. In spite of the rapid stretch and increase of axial length there is at the same time a marked and rapid decrease

of myopia indicating that changes in the refractive media are influencing the refractive state to greater extent than the increase of axial length. The reduction of myopia is accompanied by marked and rapid fluctuations in both astigmatism and the spherical refraction. These fluctuations cannot result from growth. They must result from fluctuations of the intra-ocular pressure which alone can account for the fluctuations of both the spherical refraction and astigmatism. The changes must result from the action of the intra-ocular pressure on the outer fibrous coat of the eye because pressure acting on the lens, while it might account for fluctuation of the spherical refraction, cannot account for that of astigmatism. The fluctuation of refraction indicates that the outer fibrous coat undergoes stretch at this time.

Since all eyes are probably stretched it is necessary to take the evolution of the refractive state in the average eye, undergoing average growth and stretch, as the basis on which to study the relationship between stretch and the refractive state.

When an average eye undergoing average growth has an excessive degree of scleral stretch the pre-natal reduction of myopia is less marked and, depending on the degree and distribution of stretch, the refraction is less than 1.52 dioptries hypermetropic, emmetropic or even myopic at birth. Most commonly the degree of excessive stretch will be slight and the refraction slightly hypermetropic. The post-natal increase of hypermetropia will be below average and the subsequent decrease of earlier onset and above average. The refraction will thus tend to become myopic between the ages of about 8 and 20 years. Greater degrees of excessive stretch will be less common. The refraction in such eyes may fail to attain hypermetropia and may show increasing myopia from an early age or even from birth.

When scleral stretch is deficient and the eye is otherwise average the degree of hypermetropia at birth is greater than 1.52 dioptries. The post-natal increase is above average and the subsequent decrease may be below average or absent. The refraction remains hypermetropic.

So far, only the degree of stretch has been considered as varying but there is no doubt that growth also may vary from one eye to the other. Signs of stretch in the fundus may be slight in highly myopic eyes and well marked in hypermetropic eyes. Stretch alone does not, therefore, determine the refractive state. There is a considerable range of refraction in eyes with

Similar signs of scleral stretch. It is probable, for this reason, that myopic eyes may change little while hypermetropic eyes may show a marked reduction of hypermetropia. There is, nevertheless, a general tendency for myopic eyes to progress and hypermetropic eyes to show little change, reflecting the general tendency of the former to be more stretched than the latter.

The findings of Kronfeld and Devney (1930) indicate that the incidence of higher degrees of astigmatism increases with the degree of ametropia. The reason for this is probably that lack of stretch antero-superiorly is more likely to predominate in relatively unstretched, highly hypermetropic eyes while stretch antero-inferiorly is more likely to predominate in excessively stretched myopic eyes. Menestrina (1926) found that the incidence of inverse astigmatism is almost five times as great in myopic as in emmetropic and hypermetropic eyes. This also reflects the general tendency of stretch antero-inferiorly to predominate in excessively stretched eyes. The general tendency of astigmatism to show less marked post-natal changes than the spherical refraction is probably due to the earlier development and consolidation of the anterior than the posterior sclera. The racial and familial tendencies shown by refractive errors are attributable to inherited characteristics of scleral growth. These characteristics determine both the degree and distribution of stretch.

Irrespective of the refractive state or its post-natal behaviour, stretch of the sclera is a diminishing process which commences before birth. The majority of eyes developing myopia in school life have signs of excessive scleral stretch when first seen and most, if not all, of the scleral stretch has already taken place by this time. It is therefore not surprising that efforts to treat myopia have so far been very ineffective. If choroido-retinal degenerative changes are, as suggested, due to the effects of stretch on Bruch's membrane there is the possibility that relief of such stretch might prevent the development of this most serious accompaniment of high myopia.

To obtain a satisfactory result it would be necessary to relieve the tension on the membrane before degenerative changes involve the macular area. It may be significant however, that Borley and Tanner (1945) obtained an apparent improvement of visual acuity in a case of high myopia, with degenerative changes in the fundus and markedly reduced visual acuity, by means of scleral resection.

It may be noted that no refractive error can be considered as a disease and that scleral stretch can only be considered pathological when it produces defects in Bruch's membrane with resulting choroido-

retinal atrophy. While this is more common in myopic eyes than in others, both emmetropic and hypermetropic eyes may be pathological.

Location of
 crescent in
 degrees

Disc type

| <u>No.</u> | <u>Name</u> | <u>Age</u> | <u>Sex</u> | <u>Refraction</u> | | <u>Disc type</u> |
|------------|-------------|------------|------------|-----------------------------|-----|------------------|
| 19 | E.G. | 17 | F | -7.50 D.S. c -0.50 D.C. 150 | 100 | P |
| | | | | -8.00 D.S. c -0.25 D.C. 180 | 75 | D |
| 20 | J. McC | 70 | M | +1.00 D.S. | 90 | D |
| | | | | +1.00 D.S. c -1.00 D.C. 90 | 75 | D |
| 21 | M. McC | 60 | M | +3.50 D.S. c -0.50 D.C. 105 | 180 | O+ |
| | | | | +3.00 D.S. c -0.50 D.C. 75 | 0 | O+ |
| 22 | D.K. | 21 | M | Emmetropic | 35 | R |
| | | | | +2.75 D.S. c -0.50 D.C. 70 | - | R |
| 23 | C.M. | 26 | M | -1.25 D.S. c -0.25 D.C. 30 | - | R |
| | | | | -1.00 D.S. c -0.25 D.C. 120 | 140 | R |
| 24 | T.E. | 45 | F | -5.00 D.S. | 90 | P |
| | | | | -4.25 D.S. | 75 | P |
| 25 | M.M. | 40 | F | +1.25 D.S. c -0.25 D.C. 20 | 30 | D |
| | | | | +0.75 D.S. c -0.25 D.C. 160 | 135 | D |
| 26 | S.S. | 34 | F | -2.50 D.S. | 10 | D |
| | | | | -2.75 D.S. c -0.25 D.C. 130 | 145 | D |
| 27 | A.S. | 24 | M | +0.25 D.S. | 35 | R |
| | | | | +3.50 D.S. c -0.50 D.C. 60 | - | R |
| 28 | J. McL | 36 | M | -0.50 D.C. 130 | 40 | R |
| | | | | +0.25 D.S. c -0.75 D.C. 15 | 120 | R |
| 29 | D.P. | 42 | M | +1.50 D.S. c -3.00 D.C. 180 | 75 | R |
| | | | | -3.00 D.C. 180 | 105 | O- |
| 30 | R.L. | 36 | M | -1.75 D.S. c -3.50 D.C. 175 | 105 | O- |
| | | | | -2.50 D.S. c -4.00 D.C. 180 | 75 | D |
| 31 | D.L. | 10 | F | +1.50 D.S. c -1.50 D.C. 210 | 135 | D |
| | | | | +1.00 D.S. c -2.50 D.C. 160 | 55 | D |
| 32 | A.G. | 16 | M | -3.25 D.S. c -0.50 D.C. 100 | 50 | O- |
| | | | | -3.25 D.S. | 135 | R |
| 33 | W.J.S. | 82 | M | +0.25 D.S. c -0.50 D.C. 90 | 180 | R |
| | | | | +1.50 D.S. c -0.50 D.C. 75 | 0 | O+ |
| 34 | M.C. | 74 | F | -1.50 D.C. 135 | 105 | O+ |
| | | | | -1.00 D.S. c -1.00 D.C. 80 | 75 | O- |
| 35 | M.B.C. | 54 | F | -4.50 D.S. c -0.50 D.C. 90 | 45 | O- |
| | | | | -4.00 D.S. c -1.00 D.C. 25 | 165 | D |
| 36 | E.W. | 16 | F | +0.50 D.S. c -0.25 D.C. 180 | 30 | R |
| | | | | +0.50 D.S. c -0.25 D.C. 180 | 15 | F |
| | | | | | | R |

| <u>No.</u> | <u>Name</u> | <u>Age</u> | <u>Sex</u> | <u>Refraction</u> | <u>Location of crescent in degrees</u> | <u>Disc types</u> |
|------------|-------------|------------|------------|------------------------------|--|-------------------|
| 37 | J.D.T. | 70 | M | +0.50 D.S. c -1.50 D.C. 10° | 105 | D |
| 38 | C.M. | 19 | F | +0.50 D.S. c -1.50 D.C. 30 | 115 | D |
| 39 | B.McK | 17 | F | -1.00 D.S. c -1.50 D.C. 5 | 45 | D |
| 40 | O.S. | 34 | F | -2.25 D.S. c -1.00 D.C. 10 | 135 | D |
| 41 | E.T. | 37 | F | +1.50 D.S. c -2.50 D.C. 15 | 165 | R |
| 42 | M.F. | 55 | F | +1.00 D.S. c -1.00 D.C. 170 | - | R |
| 43 | R.B. | 16 | F | -5.00 D.S. | 55 | P |
| 44 | S.R.M. | 15 | F | -6.00 D.S. | 135 | O- |
| 45 | J.S. | 17 | F | -7.00 D.S. c -0.50 D.C. 40 | 75 | P |
| 46 | Y.K. | 46 | F | -7.00 D.S. c -0.50 D.C. 140 | 180 | D |
| 47 | L.C. | 18 | M | -8.00 D.S. c -2.00 D.C. 75 | 180 | O+ |
| 48 | W.H. | 47 | M | Detached retina | 0 | O+ |
| 49 | A.McI. | 40 | M | -0.50 D.S. | 180 | R |
| 50 | A.Z. | 18 | F | -2.00 D.S. c -2.50 D.C. 165 | 80 | O- |
| 51 | O.R. | 60 | F | -1.25 D.S. | 30 | O- |
| 52 | W.M. | 55 | M | -0.375 D.S. | 135 | O+ |
| | | | | -7.50 D.S. c -0.50 D.C. 15 | 0 | O- |
| | | | | -6.00 D.S. c -0.50 D.C. 45 | 30 | O- |
| | | | | -7.00 D.S. c -6.00 D.C. 170 | 15 | D |
| | | | | -4.00 D.S. c -3.00 D.C. 15 | 150 | D |
| | | | | +2.75 D.S. c -3.00 D.C. 10 | 75 | D |
| | | | | +0.75 D.S. | 135 | D |
| | | | | +2.00 D.S. c -3.00 D.C. 80 | 30 | R |
| | | | | +6.50 D.S. | 80 | D |
| | | | | -10.00 D.S. c -4.00 D.C. 45 | 180 | O+ |
| | | | | -12.00 D.S. c -5.00 D.C. 160 | 0 | O+ |
| | | | | +1.50 D.S. c -3.50 D.C. 25 | 105 | D |
| | | | | -0.50 D.S. c -0.50 D.C. 180 | 165 | R |
| | | | | -2.50 D.S. c -1.50 D.C. 90 | 105 | O- |
| | | | | -3.00 D.S. c -0.50 D.C. 90 | 60 | O- |
| | | | | +1.50 D.S. c -0.50 D.C. 180 | 135 | D |
| | | | | -1.50 D.S. c -1.00 D.C. 35 | 50 | O- |

| <u>No.</u> | <u>Name</u> | <u>Age</u> | <u>Sex</u> | <u>Refraction</u> | <u>Location of crescent in degrees</u> | <u>Disc types</u> |
|------------|-------------|------------|------------|--|--|-------------------|
| 53 | C.T. | 9 | F | +1.25 D.S. c -2.75 D.C. 160° +1.50 D.S. c -3.50 D.C. 160 | 110 75 | D D |
| 54 | M.C. | 45 | F | Detached retina -8.00 D.S. c -1.50 D.C. 155 -8.00 D.S. c -1.00 D.C. 15 | 45 135 90 | D O- O- |
| 55 | G.S. | 55 | M | -5.00 D.S. c -1.00 D.C. 90 -1.50 D.S. c -1.00 D.C. 50 | 55 90 | O- D |
| 56 | | 59 | F | -0.50 D.S. -2.50 D.S. c -1.00 D.C. 20 | - 105 | R O- |
| 57 | C.P. | 49 | F | -10.00 D.S. c -1.00 D.C. 165 +2.00 D.S. | 180 | R R |
| 58 | J. McL. | 60 | M | +1.00 D.S. c -1.00 D.C. 100 -1.00 D.C. 180 | - 45 105 | O- R R |
| 59 | J.C. | 68 | F | -4.50 D.S. c -2.50 D.C. 180 11.75 D.S. c -1.75 D.C. 125 | 25 30 | P O+ |
| 60 | W.H. | 47 | F | -2.00 D.S. c -1.50 D.C. 55 -4.50 D.S. | 150 135 | O+ O- |
| 61 | M.K. | 76 | F | -4.00 D.S. -6.50 D.S. c -1.50 D.C. 10 | 30 90 | O- D |
| 62 | B.C. | 12 | F | -10.00 D.S. c -3.00 D.C. 180 -6.00 D.S. c -3.00 D.C. 60 | 90 45 | R R |
| 63 | C.B. | 64 | F | -0.50 D.S. c -2.00 D.C. 30 -7.00 D.S. c -0.50 D.C. 90 | 45 0 | R P |
| 64 | C.O. | 15 | F | -6.00 D.S. c -0.50 D.C. 90 -14.00 D.S. c -3.00 D.C. 15 | 85 35 | O+ D O- |
| 65 | S.M. | 50 | M | -11.00 D.S. c -2.00 D.C. 140 -14.00 D.S. c -2.00 D.C. 30 | 135 100 | O- P O- |
| 66 | L.C. | 69 | F | -18.00 D.S. c -2.00 D.C. 150 Occluded pupil. | 60 | P O- |
| 67 | I.M. | 65 | F | -2.50 D.S. c -2.00 D.C. 60 -9.00 D.S. c -1.50 D.C. 180 | 35 135 | O- O- |
| 68 | I.C. | 39 | F | -6.00 D.S. c -3.00 D.C. 160 | 45 | P |

Location of
 crescents in
degrees

Disc types

| <u>No.</u> | <u>Name</u> | <u>Age</u> | <u>Sex</u> | <u>Refraction</u> |
|------------|-------------|------------|------------|------------------------------|
| 69 | J.C. | 11 | F | -2.50 D.S. |
| 70 | W.K. | 17 | F | -6.00 D.S. c -1.00 D.C. 30° |
| 71 | C.C. | 13 | F | -3.50 D.S. c -0.50 D.C. 75 |
| 72 | E.J. | 51 | M | -4.50 D.S. c -1.00 D.C. 60 |
| 73 | A.B. | 15 | M | -2.00 D.S. c -2.00 D.C. 180 |
| 74 | D.N. | 10 | M | +2.75 D.S. c -6.00 D.C. 45 |
| 75 | A.S. | 47 | F | +2.50 D.S. c -6.00 D.C. 135 |
| 76 | F.S. | 45 | M | -2.50 D.S. c -0.50 D.C. 180 |
| 77 | J.R. | 60 | F | -3.50 D.S. c -2.00 D.C. 180 |
| 78 | K.W. | 67 | F | -6.00 D.S. c -1.75 D.C. 150 |
| 79 | C.B. | 31 | F | -5.50 D.S. c -3.50 D.C. 15 |
| 80 | J.McC | 66 | M | -15.00 D.S. c -2.00 D.C. 120 |
| 81 | E.G. | 50 | F | -15.00 D.S. |
| 82 | W.B. | 65 | M | +2.50 D.S. c -1.50 D.C. 135 |
| 83 | J.M. | 69 | M | -6.00 D.S. c -3.00 D.C. 140 |
| | | | | -3.00 D.S. c -0.75 D.C. 60 |
| | | | | -2.50 D.S. c -1.00 D.C. 135 |
| | | | | -4.00 D.S. c -3.00 D.C. 15 |
| | | | | +0.50 D.S. c -3.00 D.C. 60 |
| | | | | +1.00 D.S. c -1.00 D.C. 45 |
| | | | | +1.50 D.S. c -1.50 D.C. 180 |
| | | | | +0.50 D.S. c -0.50 D.C. 180 |
| | | | | -1.00 D.C. 45 |
| | | | | -1.50 D.S. c -2.00 D.C. 150 |
| | | | | +2.00 D.S. c -5.50 D.C. 60 |
| | | | | -1.50 D.S. c -0.50 D.C. 90 |
| | | | | -10.00 D.S.c -2.00 D.C. 40 |

30
 180
 -
 90
 75
 55
 180
 0
 40
 140
 140
 55
 60
 120
 120
 60
 -
 120
 55
 130
 60
 -
 -
 110
 90
 45
 135
 50
 150
 P.P.A.
 R

| <u>No.</u> | <u>Name</u> | <u>Age</u> | <u>Sex</u> | <u>Refraction</u> | <u>Location of crescents in degrees</u> | <u>Disc type</u> |
|------------|-------------|------------|------------|------------------------------|---|------------------|
| 84 | M.M. | 45 | M | +1.00 D.S. c -1.50 D.C. 180° | - | R |
| 85 | A.B. | 47 | M | -0.50 D.S. c -0.50 D.C. 180 | 0 | O- |
| 86 | L.B. | 58 | F | +1.25 D.S. c -2.50 D.C. 65 | 90 | D |
| 87 | F.S. | 25 | F | +1.00 D.S. c -0.75 D.C. 120 | 180 | R |
| 88 | B.P. | 22 | M | -10.00 D.S. | P.P.A. | |
| 89 | J.S. | 44 | M | -5.00 D.S. | 90 | D |
| 90 | F.J. | 24 | F | +0.50 D.S. c -3.50 D.C. 135 | - | R |
| 91 | L.McK | 7 | M | -2.50 D.S. c -3.50 D.C. 80 | 60 | D |
| 92 | H.A. | 55 | F | -1.00 D.S. c -4.00 D.C. 25 | 80 | D |
| 93 | E.G. | 44 | F | -1.00 D.S. c -4.00 D.C. 165 | 90 | D |
| 94 | M.B. | 35 | F | -9.00 D.S. | 125 | D |
| 95 | J.C. | 11 | F | -9.00 D.S. | 55 | D |
| 96 | M.C. | 36 | F | -9.00 D.S. | 130 | D |
| 97 | E.B. | 69 | F | -0.50 D.S. c -1.00 D.C. 25 | 50 | D |
| 98 | J.W. | 48 | M | -0.50 D.S. c -2.00 D.C. 155 | 115 | D |
| | | | | +2.00 D.S. c -2.00 D.C. 10 | 75 | D |
| | | | | +1.50 D.S. c -1.50 D.C. 170 | - | R |
| | | | | +2.25 D.S. c -2.50 D.C. 20 | 20 | D |
| | | | | +2.25 D.S. c -2.00 D.C. 175 | 0 | R |
| | | | | +0.25 D.S. c -0.25 D.C. 165 | 85 | R |
| | | | | +0.25 D.S. c -0.50 D.C. 15 | 30 | R |
| | | | | -3.50 D.S. c -0.50 D.C. 180 | 150 | R |
| | | | | -3.50 D.S. c -1.00 D.C. 15 | 60 | D |
| | | | | -9.00 D.S. c -1.00 D.C. 105 | 85 | D |
| | | | | -10.00 D.S. | - | R |
| | | | | -5.00 D.S. | 80 | O- |
| | | | | -5.00 D.S. | 105 | P |
| | | | | -3.50 D.S. c -1.50 D.C. 165 | 180 | R |
| | | | | -4.50 D.S. c -2.00 D.C. 60 | | |
| | | | | Anophthalmos | | |
| | | | | -3.50 D.S. c -2.00 D.C. 80 | 70 | O- |

26

| No. | Name | Age | Sex | Refraction | Location of crescents in degrees | Disc types |
|-----|--------|-----|-----|--|----------------------------------|--------------|
| 99 | H. McL | 54 | M | +1.00 D.S. c -2.00 D.C. 75° | - | R |
| 100 | J.F. | 50 | M | -2.50 D.C. 105 -7.00 D.S. c -1.50 D.C. 15 | 45 55 | O- D R |
| 101 | J.H. | 35 | F | +1.00 D.S. Detached retina | - | O- |
| 102 | B.C. | 34 | M | -7.00 D.S. c -2.00 D.C. 170 +1.00 D.S. c -4.00 D.C. 180 | 125 55 | O- O- |
| 103 | M.W. | 22 | M | +1.00 D.S. c -1.00 D.C. 30 -3.00 D.S. c -2.50 D.C. 180 | 105 145 | O- R |
| 104 | J.S. | 60 | F | -2.50 D.S. c -2.50 D.C. 170 Cataract | 150 130 | D D |
| 105 | J.F. | 54 | M | -10.00 D.S. c -2.00 D.C. 80 EMM | 125 | D |
| 106 | I.D. | 52 | F | -1.00 D.S. c -3.00 D.C. 150 -1.50 D.S. c -0.50 D.C. 150 | - | R |
| 107 | G.B. | 17 | M | +0.25 D.S. c -0.25 D.C. 90 Cataract | 40 | R |
| 108 | A. McD | 15 | M | -5.00 D.S. c -1.00 D.C. 50 Cataract | 90 | P |
| 109 | M.C. | 19 | F | -4.00 D.S. c -1.00 D.C. 90 -1.00 D.S. c -1.50 D.C. 5 | 80 55 | P D |
| 110 | | 14 | | -2.25 D.S. c -1.00 D.C. 10 -2.25 D.S. | 125 30 | D O+ |
| 111 | J.S. | 27 | M | -2.00 D.S. -6.00 D.S. c -2.50 D.C. 10 | 150 180 | R D |
| 112 | R.S. | 5 | M | -6.50 D.S. c -1.50 D.C. 155 -2.75 D.S. c -0.75 D.C. 10 | 0 60 | O- P |
| 113 | G.C.K. | 42 | M | -2.50 D.S. c -0.75 D.C. 170 +0.50 D.S. c -2.50 D.C. 35 +2.25 D.S. c -2.50 D.C. 170 | 120 90 75 | P D O- |

| <u>No.</u> | <u>Name</u> | <u>Age</u> | <u>Sex</u> | <u>Refraction</u> | <u>Location of crescents in degrees</u> | <u>Disc types</u> |
|------------|-------------|------------|------------|--|---|-------------------|
| 114 | H.S. | 34 | F | -3.00 D.S. c -1.25 D.C. 15° | 105 | D |
| 115 | A.M. | 18 | F | -2.00 D.S. c -1.00 D.C. 165 | - | R |
| 116 | J.C. | 46 | M | -5.75 D.S. -5.25 D.S. -0.75 D.S. c -0.50 D.C. 25 -6.50 D.S. c -1.00 D.C. 10 | 40 140 90 90 | D D R P |

Cases with incomplete records.

| | | | | | | |
|----|------|----|---|--------------------------------|----------|---------|
| 1 | J.P. | 75 | F | R Cataract | 130 | D |
| 2 | J.H. | 60 | F | L. -1.50 D.S. c -1.00 D.C. 150 | 90 | D |
| 3 | W.B. | | M | R | 80 | 0- |
| 4 | J.B. | 20 | F | R - | 125 | D |
| 5 | G.K. | | M | L | 50 | D |
| 6 | M.G. | 93 | F | L | 130 | D |
| 7 | S.R. | 15 | F | L | 30 | D |
| 8 | G.R. | | M | R | 140 | D |
| 9 | A.D. | 40 | F | L | 45 | D |
| 10 | W.F. | 45 | M | R | 90 | D |
| 11 | J.H. | 60 | M | R | 50 | D |
| 12 | W.O. | | M | L | 45 70 | R 0- |

Class of Scleral Stretch.

TABLE II

| | Incidence |
|--------------|-------------|
| Temporal | 579 (57.9%) |
| Non-temporal | 274 (14.7%) |
| Uniform | 147 (24.7%) |

Incidence of each class of scleral stretch in the second series.

TABLE III

Scleral stretch combination

| | Incidence |
|----------------------------|-----------|
| Temporal in both eyes. | 251 (40%) |
| Uniform in both eyes. | 60 (12%) |
| Non-temporal in both eyes | 102 (20%) |
| Temporal and non-temporal. | 60 (12%) |
| Uniform and non-temporal. | 10 (2%) |
| Uniform and temporal | 17 (3%) |

Incidence of each of the six possible combinations of scleral stretch in the second series.

TABLE IV

| | 1st Series | 2nd Series |
|---------------------------------------|------------|------------|
| Location of greatest scleral ectasia. | | |
| 0° | | 447 |
| 10° | | 107 |
| 20° | | 25 |
| 30° | 24 | 45 |
| 40° | 26 | 42 |
| 50° | 11 | 10 |
| 60° | 9 | 15 |
| 70° | 8 | 3 |
| 80° | 4 | 5 |
| 90° | 21 | 30 |
| 100° | 23 | 18 |
| 110° | 10 | 6 |
| 120° | 17 | 8 |
| 130° | 20 | 12 |
| 140° | 5 | 8 |
| 150° | 4 | 12 |
| 160° | 3 | 4 |
| 170° | | 3 |
| 180° | 15 | 53 |

Locational incidence of greatest ectasia in both series.

TABLE V

Type of Optic Disc

| Location of greatest scleral ectasia | Circular | Enlarged oval | D-shaped | Reduced oval | Pear-shaped |
|--------------------------------------|----------|---------------|----------|--------------|-------------|
| 30° | 13 | 4 | 6 | 1 | |
| 40° | 10 | 1 | 13 | 2 | |
| 50° | 4 | | 6 | | 1 |
| 60° | 3 | | 2 | 2 | 2 |
| 70° | 3 | | 1 | 2 | 2 |
| 80° | | | 3 | 1 | |
| 90° | 3 | | 16 | 2 | |
| 100° | | | 12 | 8 | 3 |
| 110° | | | 4 | 2 | 4 |
| 120° | | | 6 | 10 | 1 |
| 130° | 1 | | 10 | 6 | 3 |
| 140° | | | 3 | 1 | 1 |
| 150° | | | 2 | 1 | 1 |
| 160° | 2 | | 1 | | |
| 170° | | | | | |
| 180° | 2 | 11 | 1 | 1 | |

Incidence of disc type relative to the location of greatest ectasia in the first series.

TABLE VI

| Location of greatest scleral ectasia . | Type of Optic Disc | | | | |
|--|--------------------|---------------|----------|--------------|-------------|
| | Circular | Enlarged oval | D-shaped | Reduced oval | Pear-shaped |
| 0° | 408 | 7 | 20 | 12 | |
| 10° | 86 | 2 | 13 | 6 | |
| 20° | 17 | 6 | 1 | 1 | |
| 30° | 40 | | 4 | 1 | |
| 40° | 34 | | 8 | | |
| 50° | 10 | | | | |
| 60° | 12 | | 3 | | |
| 70° | 3 | | | | |
| 80° | 2 | | 3 | | |
| 90° | 18 | 3 | 8 | | 1 |
| 100° | 5 | 1 | 6 | 3 | 3 |
| 110° | 1 | | 5 | | |
| 120° | 1 | | 3 | 3 | 1 |
| 130° | 5 | | 1 | 5 | 1 |
| 140° | 4 | | 3 | 1 | |
| 150° | 3 | | 3 | 6 | |
| 160° | 3 | | | 1 | |
| 170° | 3 | | | | |
| 180° | 34 | 14 | 1 | 4 | |

Incidence of disc type relative to the location of greatest ectasia in the second series.

TABLE VII

| | Second Series | | | First Series | |
|--------|---------------|-----------------|------------------|----------------------|-----------------------|
| | All Cases | Uniform stretch | Temporal stretch | Non-temporal stretch | Non-temporal Crescent |
| + 8.00 | 3 | 2 | | 1 | |
| + 7.00 | 3 | 1 | 1 | 1 | |
| + 6.00 | 6 | 1 | 3 | 2 | 1 |
| + 5.00 | 10 | 5 | 1 | 4 | |
| + 4.00 | 19 | 8 | 7 | 4 | |
| + 3.00 | 51 | 12 | 19 | 20 | 4 |
| + 2.00 | 77 | 15 | 39 | 23 | 1 |
| + 1.00 | 174 | 29 | 95 | 50 | 19 |
| 0.00 | 312 | 56 | 202 | 54 | 27 |
| - 1.00 | 123 | 8 | 92 | 23 | 18 |
| - 2.00 | 79 | 7 | 52 | 20 | 15 |
| - 3.00 | 58 | 1 | 31 | 26 | 23 |
| - 4.00 | 29 | 1 | 16 | 12 | 19 |
| - 5.00 | 20 | | 10 | 10 | 11 |
| - 6.00 | 9 | | 6 | 3 | 9 |
| - 7.00 | 10 | | 3 | 7 | 7 |
| - 8.00 | 4 | | | 4 | 8 |
| - 9.00 | 4 | | | 4 | 7 |
| -10.00 | 3 | | 1 | 2 | 5 |
| -11.00 | 1 | | 1 | | 1 |
| -12.00 | 1 | | | 1 | 4 |
| -13.00 | | | | | 1 |
| -14.00 | 1 | | | 1 | |
| -15.00 | 1 | | | 1 | 3 |
| -16.00 | 1 | 1 | | 1 | 2 |

Incidence of refraction in both series and in eyes of the second series with each class of scleral stretch.

TABLE VIII

Class of Scleral Stretch

| Diopres of Astigmatism. | Temporal | Uniform | Non-temporal |
|-------------------------|--------------|--------------|--------------|
| 0.00 | 490 (84.81%) | 128 (87.14%) | 169 (60.79%) |
| 1.00 | 53 (9.21%) | 11 (7.41%) | 54 (19.42%) |
| 2.00 | 22 (3.82%) | 2 (1.30%) | 23 (8.26%) |
| 3.00 | 8 (1.39%) | 3 (1.94%) | 20 (7.73%) |
| 4.00 | 2 (0.35%) | | 8 (2.88%) |
| 5.00 | | 2 (1.29%) | 2 (0.72%) |
| 6.00 | | 1 (0.65%) | 1 (0.36%) |
| 7.00 | | | 1 (0.36%) |

Incidence of astigmatism in eyes with each class of scleral stretch in the second series.

TABLE IX

Degree of Astigmatism (DIOPTERS)

| | Incidence | |
|------|-----------|--------|
| 0.00 | 78 | -40.2% |
| 1.00 | 50 | -25.8% |
| 2.00 | 34 | -10.8% |
| 3.00 | 21 | -3.1% |
| 4.00 | 6 | -1.0% |
| 5.00 | 2 | -1.5% |
| 6.00 | 3 | |

Incidence of astigmatism in eyes of the first series with non-temporal crescent.

TABLE X

| | 0°-25° | 30°-55° | 60°-85° | 90°-115° | 120°-145° | 150°-180° |
|-----------|--------|---------|---------|----------|-----------|-----------|
| 0°-25° | 52 | 19 | 10 | 30 | 14 | 20 |
| 30°-55° | 3 | 2 | 2 | 11 | 7 | 5 |
| 60°-85° | 5 | 6 | 2 | 3 | 4 | 1 |
| 90°-115° | 14 | 4 | 1 | 8 | 3 | 5 |
| 120°-145° | 2 | 2 | | 2 | 10 | 5 |
| 150°-180° | 16 | 10 | 3 | 8 | 6 | 11 |

Angle of least refracting axis.

Incidence of astigmatism at various angles with greatest ectasia in various locations.

TABLE XI

Anisometropia in dioptries.

| | 0.00 | 0.25 | 0.50 | 1.00 | 2.00 | 3.00 | 4.00 | >4.00 |
|----------------------------|------|------|------|------|------|------|------|-------|
| Temporal in both eyes | 120 | 58 | 41 | 25 | 7 | | | |
| Uniform in both eyes | 40 | 10 | 6 | 4 | | | | |
| Non-temporal in both eyes. | 38 | 17 | 21 | 17 | 3 | 2 | 1 | 3 |
| Temporal and non-temporal. | 14 | 14 | 13 | 7 | 6 | 3 | 1 | 2 |
| Uniform and Non-temporal | 2 | | 2 | 3 | 2 | | | 1 |
| Uniform and Temporal | 5 | 4 | 3 | 3 | 2 | | | |

Incidence of anisometropia in cases of the second series with each of the six possible combinations of the three classes of scleral stretch.

TABLE XII

| Degree of Anisometropia | Diagnosis from fundi | |
|-------------------------|----------------------|----------|
| 0.25 Dioptres | Diagnosed correctly | 51 - 59% |
| | Not diagnosed | 25 - 29% |
| | Diagnosed wrongly | 10 - 12% |
| 0.50 Dioptres | Diagnosed correctly | 45 - 66% |
| | Not diagnosed | 15 - 22% |
| | Diagnosed wrongly | 8 - 12% |
| 1.00 Dioptres | Diagnosed correctly | 63 - 93% |
| | Not diagnosed | 2 - 3% |
| | Diagnosed wrongly | 3 - 4% |

The results of an attempt to diagnose anisometropia from fundus signs of scleral stretch in the second series. Those in which the location of greatest ectasia differed by more than 25° in the two eyes were omitted.

TABLE XIII

| | Incidence of Isometropia | Incidence of Anisometropia. |
|-------|-----------------------------|--------------------------------|
| +8.50 | 1 | |
| +7.50 | 1 | 2 |
| +6.50 | 1 | 1 |
| +5.50 | | 2 |
| +4.50 | 2 | 7 |
| +3.50 | 4 | 13 |
| +2.50 | 9 | 14 |
| +1.50 | 24 | 26 |
| +0.50 | 62 | 18 |
| 0.00 | 139 | 24 |
| -0.50 | 35 | 20 |
| -1.50 | 20 | 15 |
| -2.50 | 13 | 11 |
| -3.50 | 5 | 5 |
| -4.50 | 3 | 8 |
| -5.50 | 1 | |
| -6.50 | 2 | 8 |
| -7.50 | 1 | 1 |
| -8.50 | | 3 |

Incidence of refraction in isometropes and anisometropes of second series.

- Fig. 1 W.H.; Male; Age 47;
Right eye. Enlarged oval disc. Elongated fenestrae of lamina cribrosa. Temporal crescent.
- Fig. 2. M.A.; Female; Age 35; Refraction -1.25D.S. with -3.00 D.C.60°
Left eye. Enlarged oval disc. Nasal crescent with nasally directed blood vessels. Retinal supertraction from the temporal side.
- Fig. 3. R.M.; Female; Age 15; Refraction -0.75 D.S. with ~~2.50~~ 2.50 D.C.100°
Left eye. Enlarged oval disc. Inferior displacement of retina and blood vessels. Compare with fig. in which the disc is D-shaped. The temporal crescent is tertiary type. No primary crescent is to be seen because the disc margin has been displaced with Bruch's membrane. The blood vessels are distributed as in eyes with primary inferior crescent.

FIG. 1

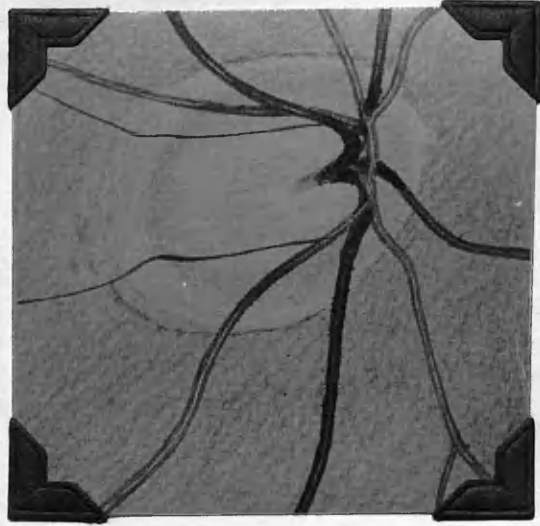


FIG. 2

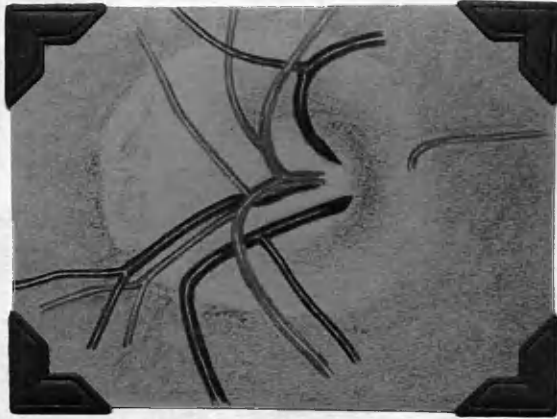


FIG. 3

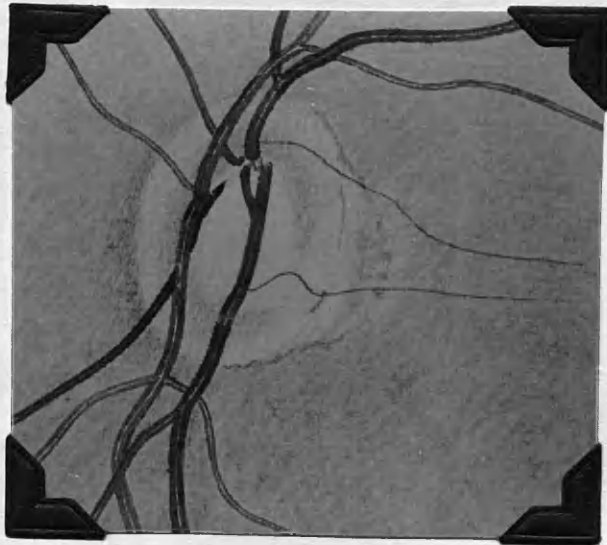


Fig. 4. G.S.; Male; Age 55; Refraction -5.0 D.S. with -1.0 D.C. 90°
Left eye. Inferior nasal crescent with choroidal pigment at its central border. Inferior nasal displacement of retina and vessels with retinal supertraction above. Reduced oval disc.

Fig. 5. M.M.; Female; Age 65; Refraction -2.50 D.S. with -2.00 D.C. 60°
Similar to Fig. 5, but choroidal vessels crossing entire crescent area and crescent considerably larger.

Fig. 6. L.M.; Female; Age 68; Refraction -18.00D.S. with -2.00D.C. 150°
Similar to previous two but spreading choroidal atrophy towards inferior nasal quadrant. The vessel distribution is similar to that in the previous two. There is some senile depression of the disc surface.

The essential difference between each of these fundi is the amount of scleral stretch. In spite of marked myopia there is no temporal crescent in fig. 6.

FIG 4

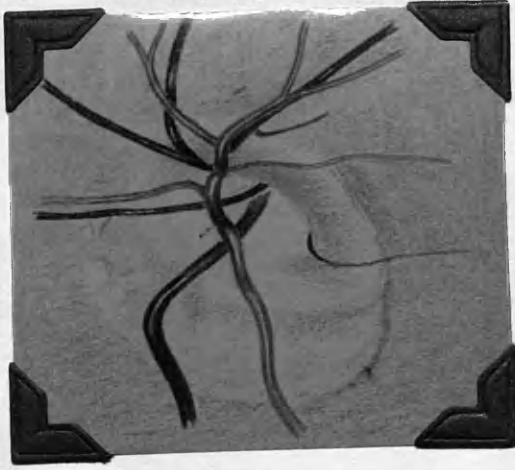


FIG. 5

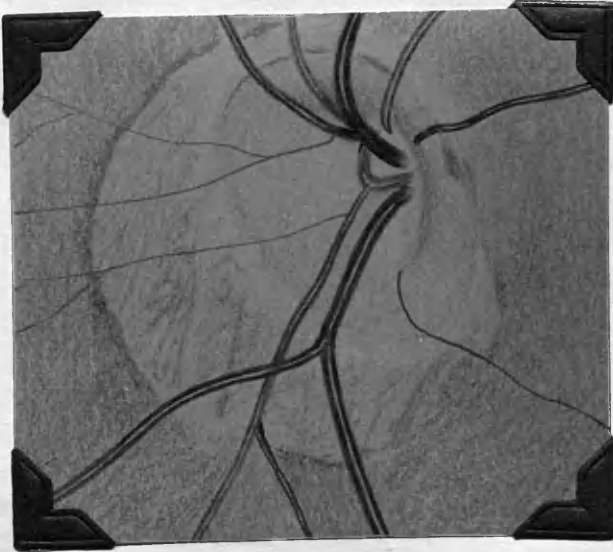


FIG 6

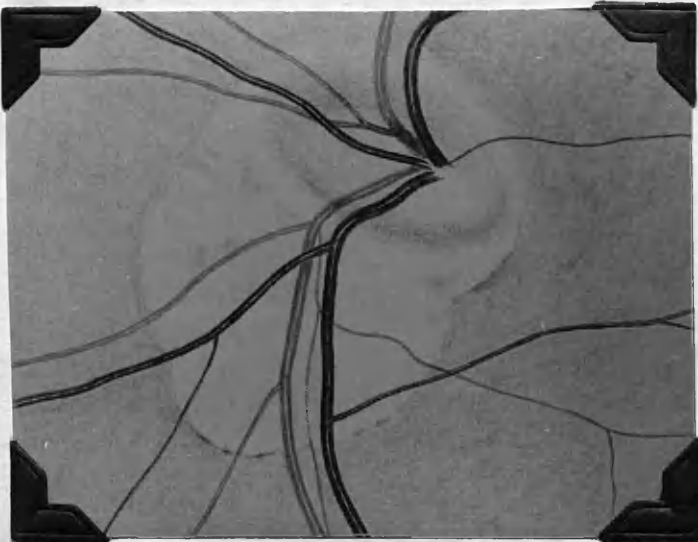


Fig. 7. J.B.; Male; Age 31; Refraction -3.0 D.C. 180°.
Right eye. Pear-shaped disc. Inferior nasal crescent.
Lower vessels make wider sweep below than the upper do
above the posterior pole. Retinal supertraction is from
above.

Fig. 8. E.B.; Female; Age 69; Refraction -3.50 D.S. with -2.00D.C.165°
Right eye. Similar to previous but repeated ruptures of
Bruch's membrane have resulted in peri-papillary choroidal
atrophy and there is some degree of senile cupping of the
disc. Note the festooned margin of the choroidal atrophy.

Fig. 9. L.C.; Female; Age 68; Refraction -14.00 D.S.with -2.00D.C.30°
Right eye. Similar to previous but choroidal atrophy is
more extensive. The senile cupping is not so marked in
this case. It should be noted that there is no temporal
crescent in spite of the high degree of myopia.

FIG. 7

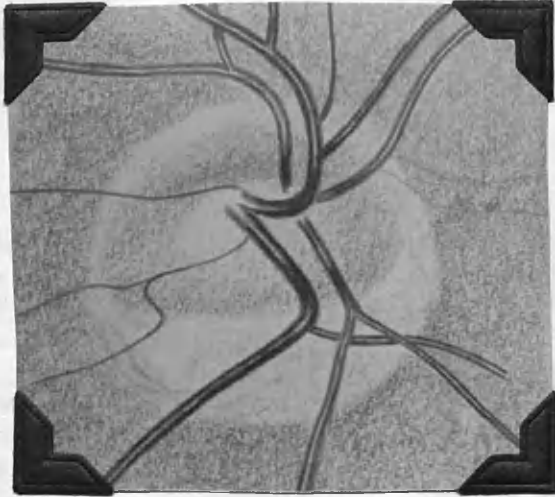


FIG. 8.

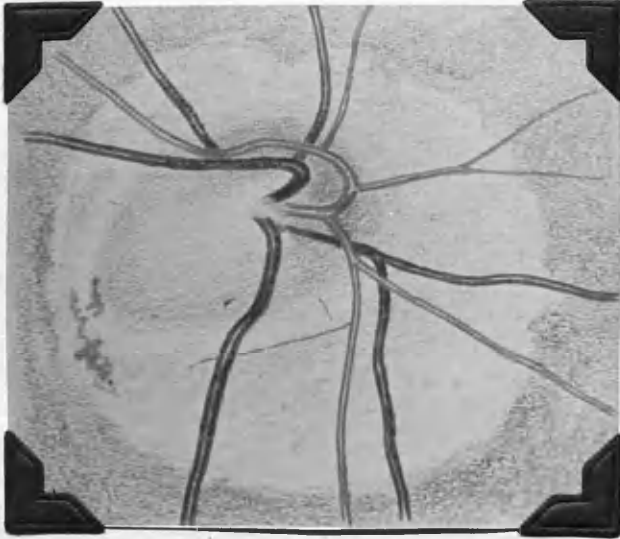


FIG. 9

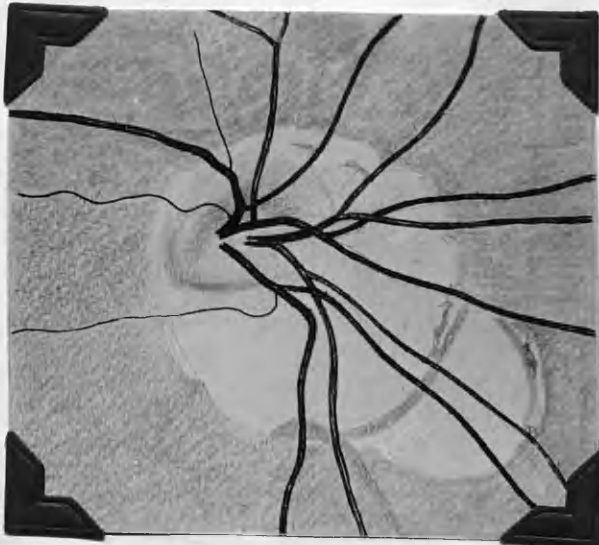


Fig. 10. N.P.; Female; Age 12; Refraction -9.00 D.S.
Left eye. Marked supertraction of retina from nasal side with ridges extending, above and below, across ends of crescent. Angle between superior and inferior temporal vessels is very small. Vessels visible to nasal margin of disc through supertracted retina. Mottling of crescent margin due to either rupture or recent movement of Bruch's membrane.

Fig. 11. F.N.; Female; Age 19; Refraction -12.00D.S. with -3.00D.C.150°
Left eye. Similar to previous. Disc entirely hidden by retinal supertraction which extends as folds across both ends of the crescent. Pigmentation of the crescent is faintly visible through these folds. Note the series of parallel pigment lines produced by pigment epithelial proliferation between stages in the movement of Bruch's membrane. The nasal branches leave the temporal ones at a somewhat obtuse angle because they are stretched between the latter and the nasal periphery.

Fig. 12. K.; Male; Age 25; Refraction -19.00 D.S.
Left eye. Photograph showing obtuse branching of nasal vessels from temporal and reduced angle between temporal branches as a result of excessive stretch temporal to the optic disc. The oval shape of the disc is clearly defined. The vessels run a very straight course as is to be expected when the retina is stretched.

FIG 10

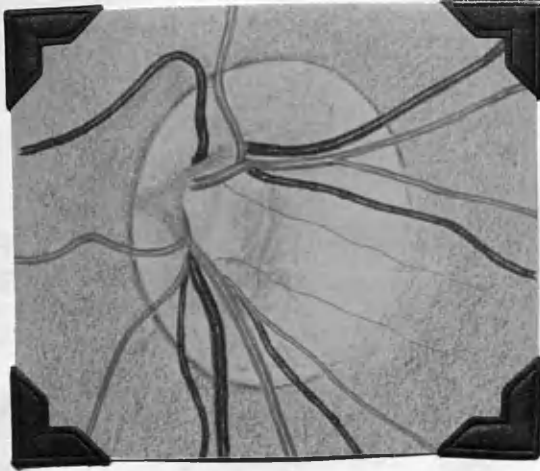


FIG 11

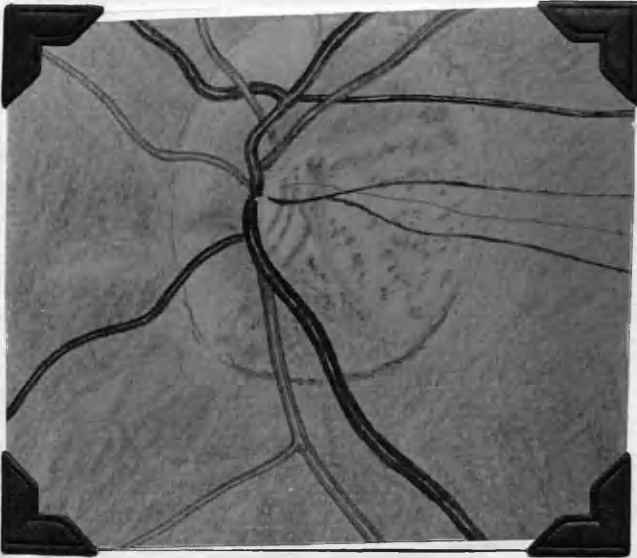
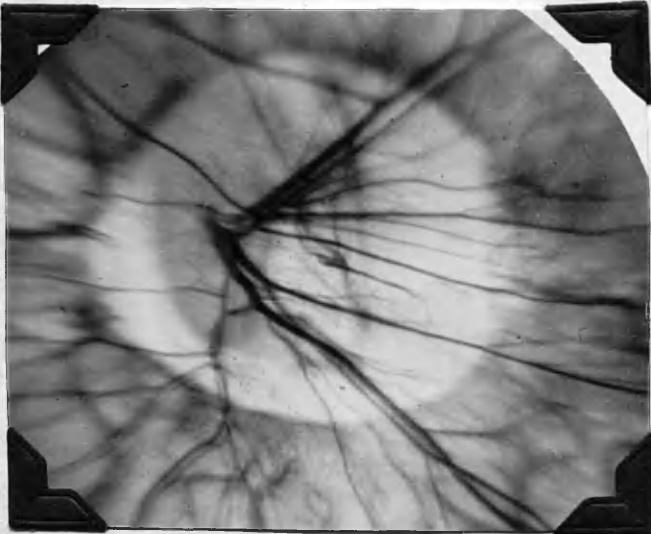


FIG 12



- Fig. 13. M.P.; Female; Age 28; -1.50 D.S. with -1.50 D.C. 180°
Right eye. Nasal displacement of retina. Round disc. Absence of crescent. Temporal displacement of vessels at lamina cribrosa relative to the disc. Nasal margin of disc is pale and distinct, indicating that the heaping up of retinal nerve fibres, which is common at this margin, is not due to their excessive number as usually suggested.
- Fig. 14. J.B.; Male; Age ; $+2.75$ D.S. with -6.00 D.C. 45° .
Right eye. Similar to previous but the changes are more marked. Primary nasal crescent bordered with pigment. Note the wide nasal sweep of the vessels which is more marked below than above.
- Fig. 15. W.G.; Male; Age 59; -1.50 D.S. with -1.00 D.C. 50°
Right eye. D-shaped disc with inferior displacement of the retina. Lower disc margin well defined with a thinner covering of nerve fibres than the upper. Lower temporal vessels make a wider sweep round the posterior pole than the upper; both are inferiorly displaced with the retina. The physiological cup is inclined downwards.
- Fig. 16. C.T.; Female; Age 9; $+1.25$ D.S. with -2.75 D.C. 15° .
Right eye. Similar to previous except for presence of inferior crescent. Most of the other changes are more marked than in the previous.
- Fig. 17. H.B.; Male; Age 73; $+3.00$ D.C. 90° .
Right eye. Temporal displacement of the retina. The temporal disc margin is most pale and defined because the overlying nerve fibres are stretched. The lower temporal vessels make a wider sweep round the posterior pole than the upper because greatest stretch is, as usual, somewhat below the horizontal meridian. The physiological cup is inclined temporally. The vessels at the lamina cribrosa are nasally displaced relative to the optic disc.
- Fig. 18. R.M.; Female; Age 15; -0.5 D.S. with $+0.75$ D.C. 90° .
Right eye. Similar to previous except for the presence of a temporal crescent and other changes being more marked.

FIG. 13

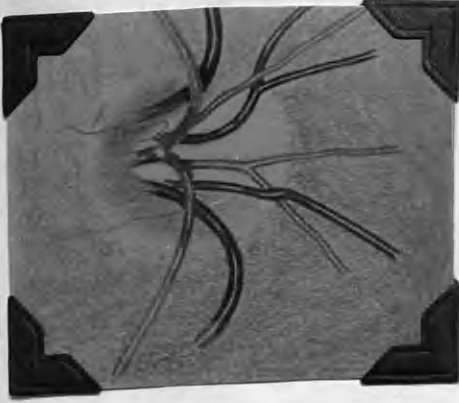


FIG. 14




FIG. 15

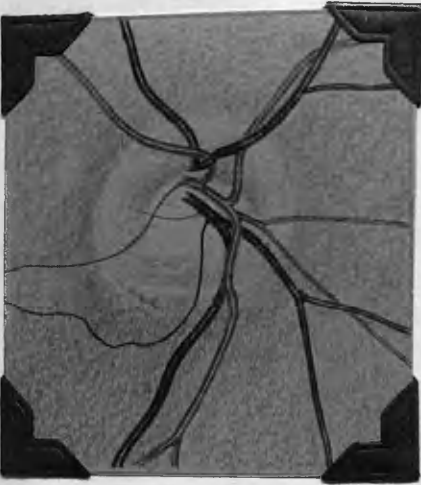


FIG. 16

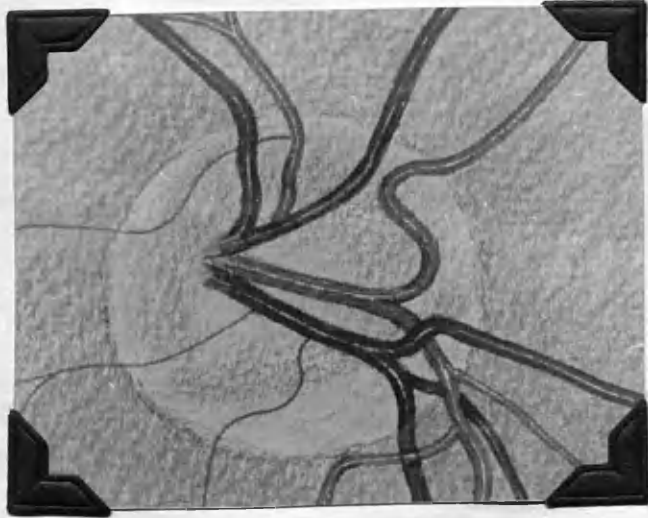


FIG. 17

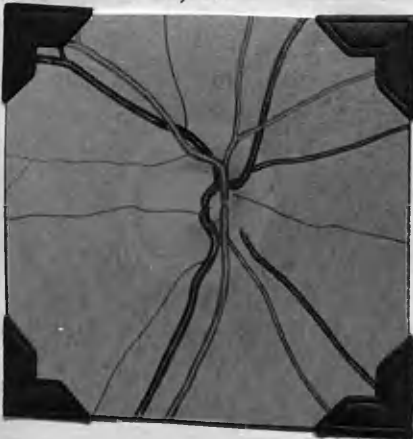
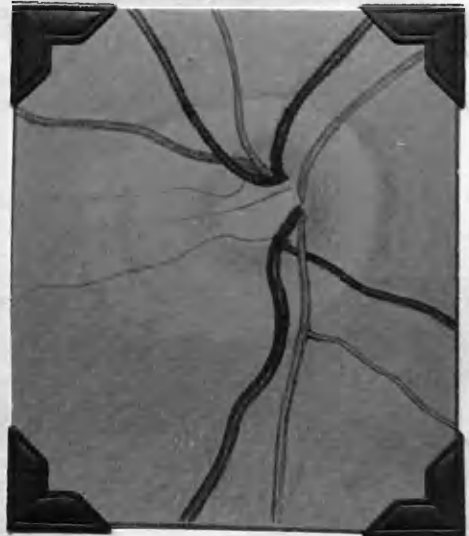


FIG. 18



67

Fig. 19. F.T.; Female; Age 37; Refraction -7.00 D.S. with -0.50 D.C.140°
Left eye. D-shaped disc with inferior temporal crescent.
Appearance similar to glaucomatous cupping infero-temporally
due to shadow cast by wall of scleral canal being visible
through the thin and stretched overlying nerve fibre layer.
Inferior temporal displacement of the retina and blood vessels.

Fig. 20. J.S.; Female; Age 49; Refraction -10.00D.S. with -2.00D.C.80°
Left eye. Similar to previous but crescent is larger and
other changes are more marked. Marked displacement of the
vessels at the lamina cribrosa so that they emerge from deep
to the upper margin of the physiological cup. Disc is more
oval than D-shaped. Indistinct part of crescent margin
nasally may indicate site of rupture of Bruch's membrane.

Fig. 21. S.M.; Male; Age 50; Refraction -11.00D.S. with -2.00 D.C.140°.
Left eye. As in previous but disc shows some senile cupping
and there are two isolated patches of choroidal atrophy.
The latter may result from hole formation in Bruch's
membrane. Parallel pigment lines on crescent. Secondary
crescent up and in.

10
FIG 19

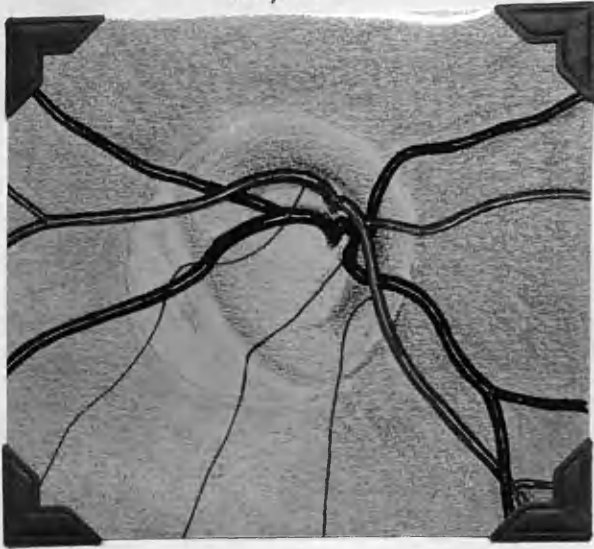


FIG 20

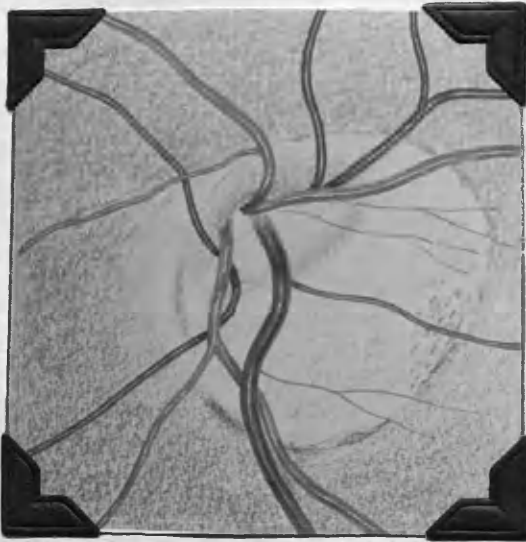
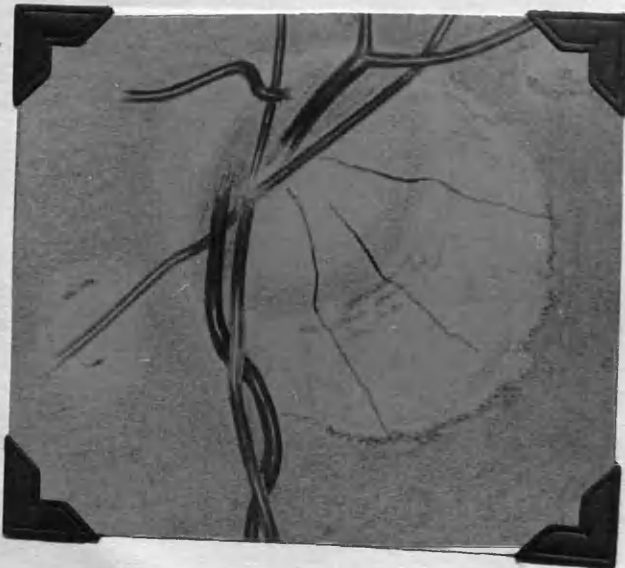


FIG 21



- 71
- Fig. 22. S; Female; Age 25; Refraction -2.50D.S. with -3.5D.C. 80°
Left eye. D-shaped disc. Inferior nasal crescent with related tertiary crescent and venous loop internal to the choroid. Like most tertiary crescents part of the margin is indistinct.
- Fig. 23. G.K.; Male; Age 20;
Left eye. Similar to the previous. Cilio-retinal artery replaces inferior branches of central artery; enters through the sclera and passes to the disc before curving back to supply the retina. This course is followed by the vast majority of cilio-retinal arteries. A minority enter via the disc.
- Fig. 24. E.P.; Female; Age 62; Refraction \nearrow 7.00D.C. with \nearrow 1.0 D.C. 160° (Aphakia)
Right eye. Fairly uniform scleral stretch. Peri-papillary choroidal atrophy with small venous loop above. This suggests that retraction following rupture of Bruch's membrane may produce a venous loop in the absence of a primary crescent.
- Fig. 25. B.I.; Male; Age 6; Refraction Emmetropic.
Left eye. Venous loop associated with temporal crescent. The upper half of the retina is supplied by a cilio-retinal artery entering the eye through the sclera.

FIG 22

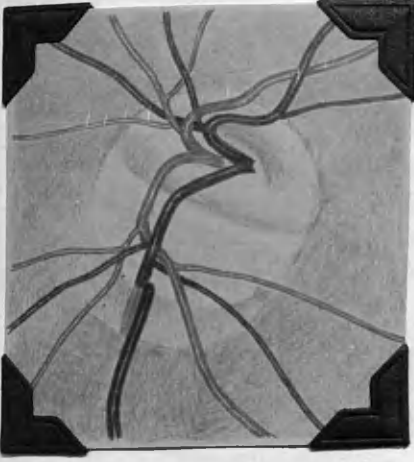


FIG 23

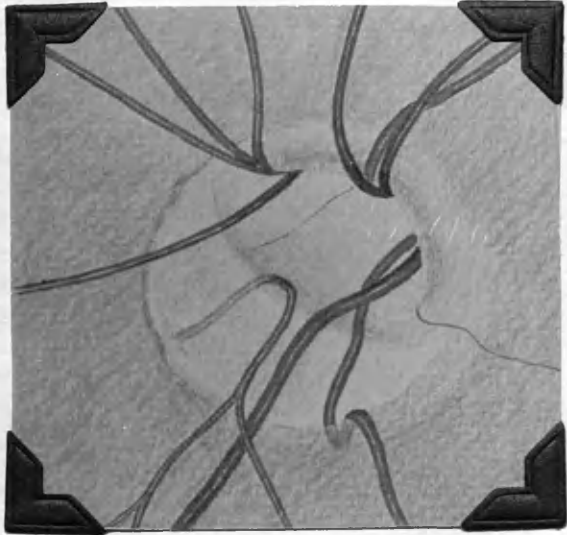


FIG 24

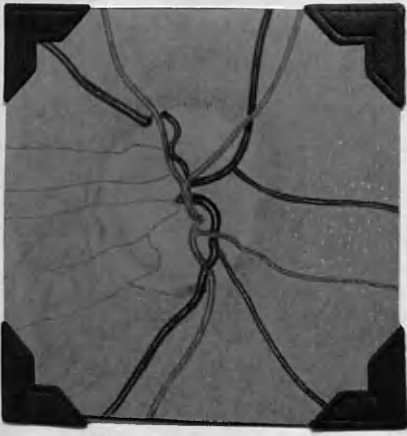
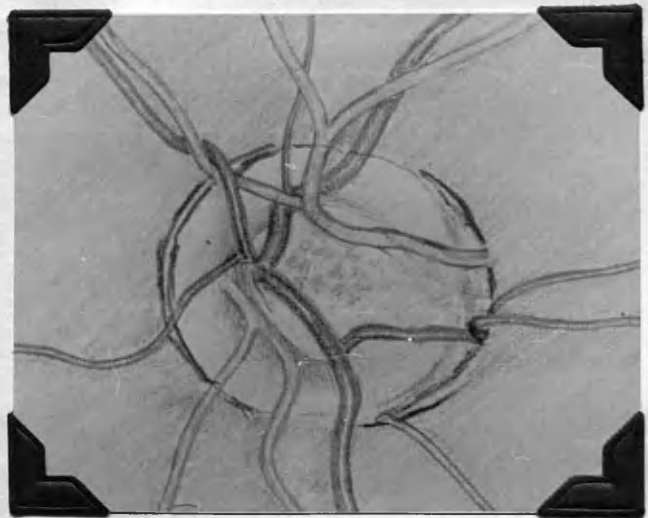


FIG 25



72

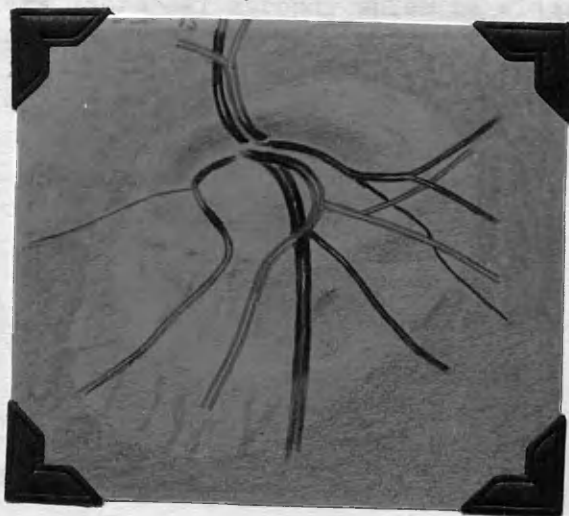
Fig. 26. S.M.; Male; Age 50; Refraction -14.00D.S. with -3.00 D.C.15°. Right eye. Reduced oval disc with some degree of senile cupping. Pigment lines parallel to disc margin on crescent suggesting pigment epithelial proliferation between stages in movement of Bruch's membrane. Crescent margin indistinct in part, probably indicating increase.

Fig. 27. G.S.; Male; Age 55; Refraction -8.00 D.S. with -1.00 D.C.15°. Right eye. Inferior primary and tertiary crescents. Note irregular temporal margin of crescent, possibly indicating site of rupture of Bruch's membrane. Suggestion of parallel pigment lines on crescent, similar to those in fig. .

FIG. 26.

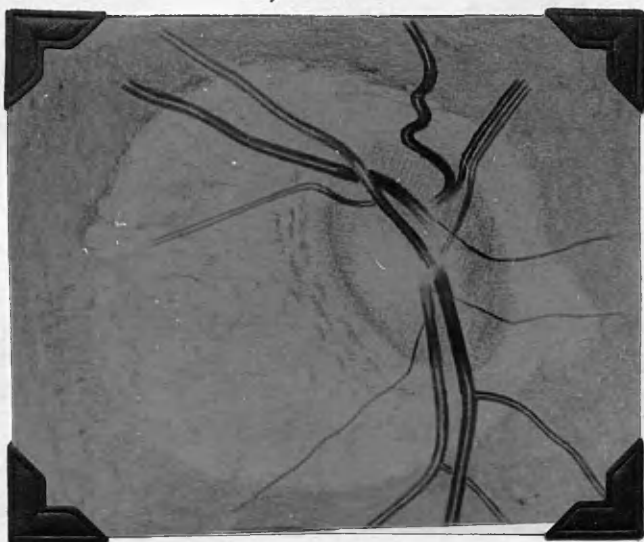

FIG. 27



- Fig. 28. B.F.; Female; Age 16; Refraction -6.50 D.S.
Right eye. Temporal primary crescent with related tertiary crescent. Cilio-retinal artery fails to reach disc margin.
- Fig. 29. E.C.; Female; Age 24; Refraction -3.25 D.S.
Right eye. Temporal crescent with cilio-retinal artery failing to reach disc margin. D-shaped disc.
- Fig. 30. E.C.; Male; Age 13; Refraction -6.50D.S. with -0.50 D.C.
180°.
Left eye. Fairly uniform scleral stretch with peripapillary choroidal atrophy which is widest inferiorly. The pigment line bordering the atrophic zone is double in parts. The disc surface is flattened. Cilio-retinal arteries fail to reach the disc margin.
- Fig. 31. L.McK.; Male; Age 7; Refraction \neq 1.50 D.C. 80°.
Left eye. Inferior nasal crescent with cilio-retinal artery hooking round peripheral margin.

FIG 28

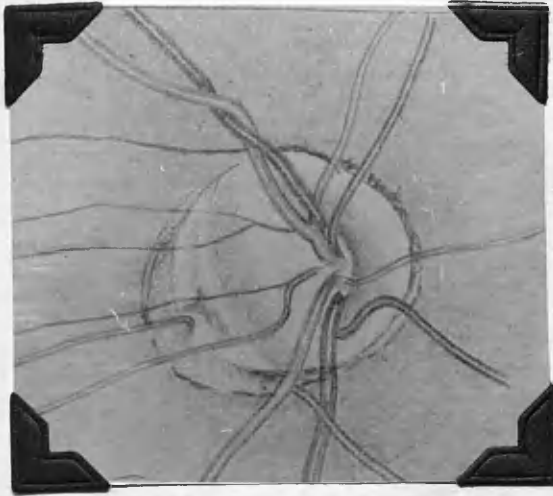


FIG 29




FIG 30

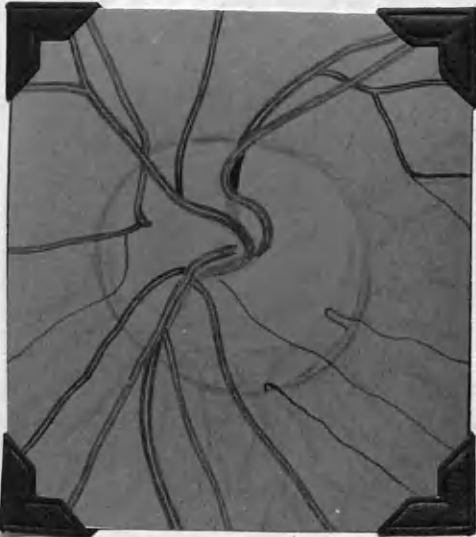
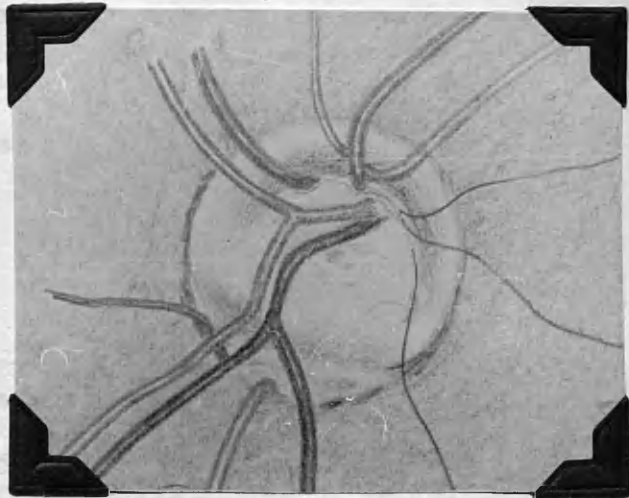


FIG 31



... ..

Fig. 32. M.C.; Female; Age 40; -11.00 D.S. with -2.00 D.C. 70°. Left eye. Inferior choroidal crescent with reduced oval disc. The crescent is heavily pigmented. There is no temporal crescent in spite of the high degree of myopia.

Fig. 33. G.C.; Male; Age 12; Refraction -9.00 D.S. Right eye. Son of previous patient. Temporal crescent of appearances similar to those of mother's inferior crescent. There is little doubt that both the mother and son's crescents are due to scleral stretch.

Fig. 34. M.M.; Female; Age 60; Refraction -6.00 D.S. Right eye. Temporal crescent. Senile cupping in which retinal supertraction is pushed back but retains its sharp margin. This is not usual in senile cupping, as a rule the nerve fibres are straightened out. In senility the physiological cup enlarges as the nerve fibres are depressed, as a rule.

Fig. 35. M.M.; Female; Age 60; Refraction - Emmetropic. Left eye of same patient as previous. Note the absence of senile cupping. This is due to the fact that less stretched eyes are less prone to develop senile cupping. This picture is typical of a moderate degree of excess scleral stretch temporal to the optic disc. The cup is temporally inclined and vessels at the lamina cribrosa are nasally placed. The temporal part of the disc is less pink than the nasal due to the thinner layer overlying nerve fibres.

FIG 32

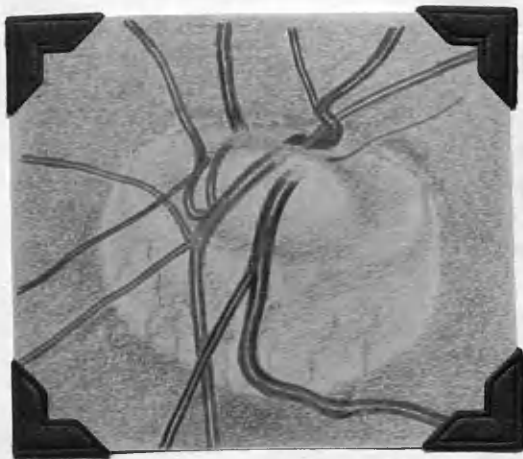


FIG 33.

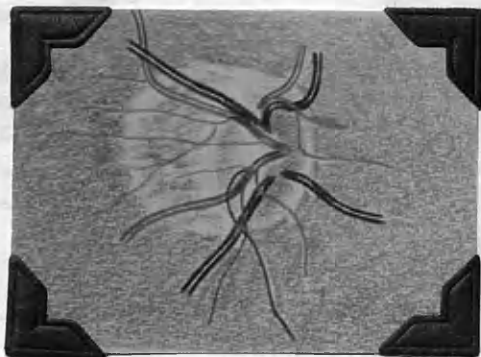


FIG 34

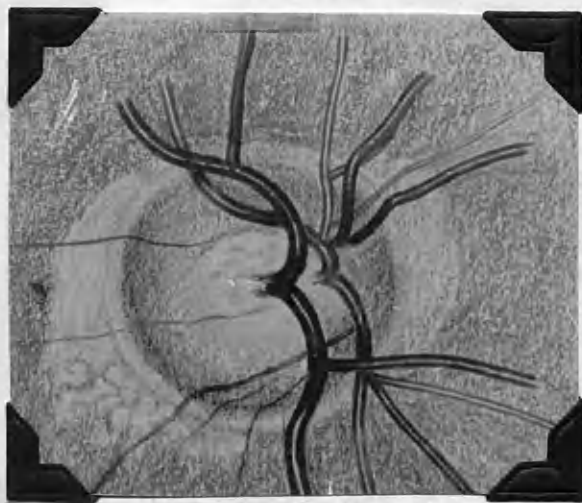
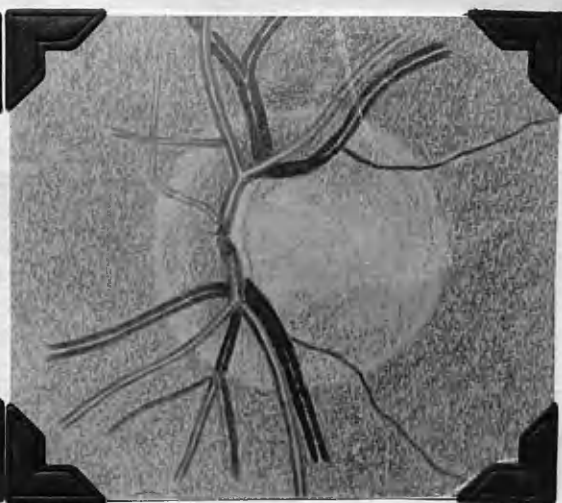


FIG 35



79

Fig. 36. J.M.; Male; Age 69; Refraction -1.5 D.S with -0.5 D.C. 90°. Right eye. D-shaped disc with inferior nasal crescent obscured by extension of atrophy. Recently formed tertiary crescent infero-temporal to the disc. The site of the original crescent can only be deduced from factors such as the distribution of vessels, the shape of the disc and the configuration of the physiological cup.

Fig. 37. J.K.; Female; Age 76; Refraction -4.50 D.S. Right eye. Similar to previous except that choroidal atrophy is not so extensive. Of the three crescents only that infero-nasal is primary. Each crescent is of uniform color suggesting sudden slippage of Bruch's membrane.

Fig. 38. I.C.; Age 39; Female; -9.00 D.S. with -1.50 D.C. 180°. Right eye. Scleral stretch distributed as in previous. There appears to have been rupture of Bruch's membrane temporal to the disc with retraction around the upper pole. The disc shows some senile cupping in spite of the 39 years age. This form of cupping is predisposed to by scleral stretch.

Fig. 39. I.C.; Female; Age 39; -6.00 D.S. with -3.50 D.C. 160°. Left eye. Pear-shaped disc. Inferior nasal crescent with rupture of Bruch's membrane and its retraction from the upper part of the disc. The irregular margin suggests that the membrane near the disc is degenerate.

FIG 36

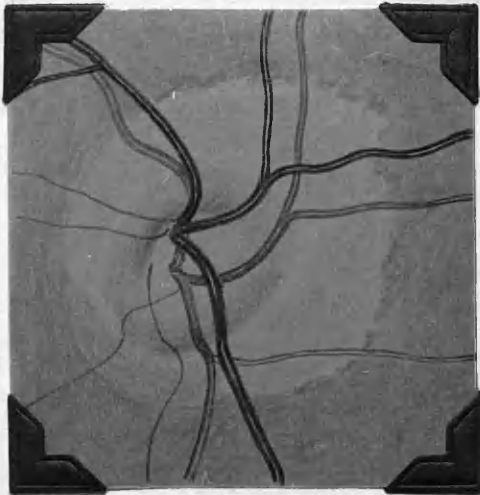


FIG 37

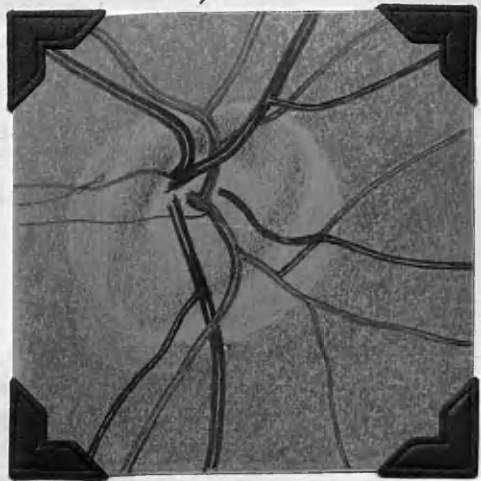


FIG. 38

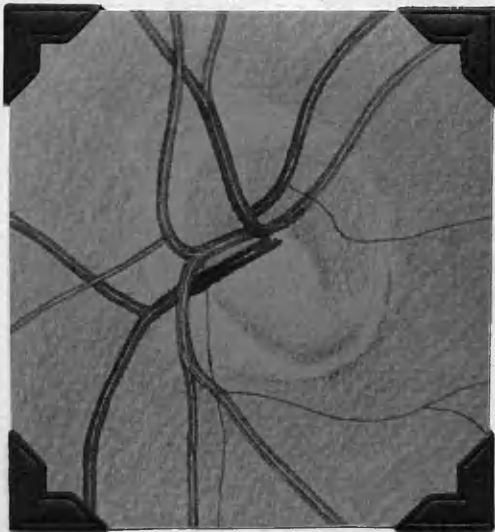
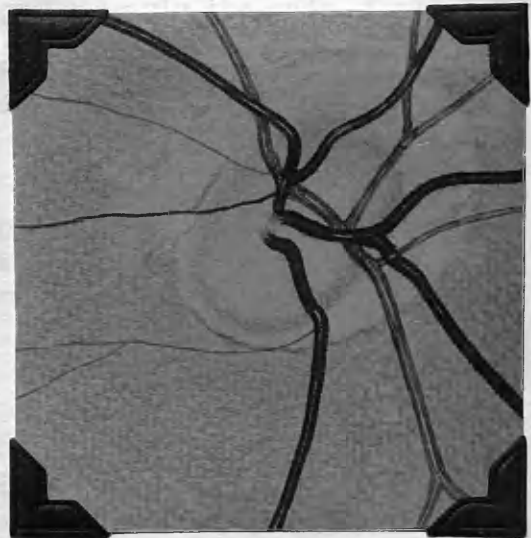


FIG 39



- 87
- Fig. 40. H.B.; Male ; Age 73; -5.00 D.S. with -2.00 D.C. 180°. Left eye. Enlarged oval disc with vertical long axis. Two tertiary crescents but no primary crescent. Retina displaced inferiorly with vessels emerging near upper margin of disc. Fenestrae of lamina cribrosa vertically elongated (not well shown in drawing).
- Fig. 41. A.D.; Female; Age 40; -1.00 D.S. with -3.00 D.C. 10°. Right eye. In many respects similar to the previous. The vessel distribution is similar, the retina is displaced downwards in both and the vessels emerge from deep to the retinal supertraction fold near the upper margin of the disc. The inferior margin of the disc has not been displaced however, and the disc is D-shaped. All of the inferior vessels except one artery are included in a whole-thickness nerve fibre loop. The fold thus produced resembles the supertraction retinal fold above and is equally effective in obscuring the underlying vessels. Retinal ridges corresponding to those in fig. 40 overlie the ends of the crescent and serve to accentuate an appearance of ectasia in the crescent. There is, however, no such ectasia and the crescent is at no part deeper than the lamina cribrosa.
- Fig. 42. A.B.; Female; Age 47; -1.25 D.S. with \neq 2.50 D.C. 155°. Right eye. Inferior crescent with retinal supertraction covering entire optic disc and extending as folds across ends of crescent.
- Fig. 43. M.B.; Female; Age 58; Refraction -5.00 D.S. Left eye. Similar to previous except for presence of whole-thickness nerve fibre loop at lower margin of crescent. Note that the venous branch is faintly visible in its entire course while the small arterial branch is hidden as in fig. 41.

FIG 40

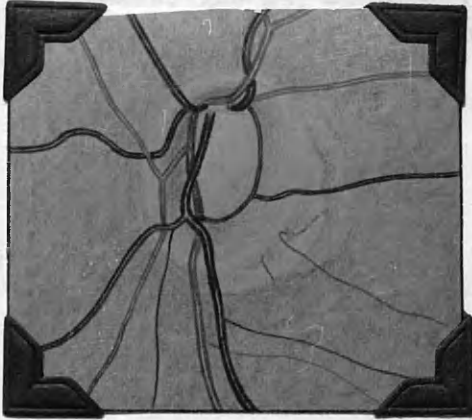


FIG 41

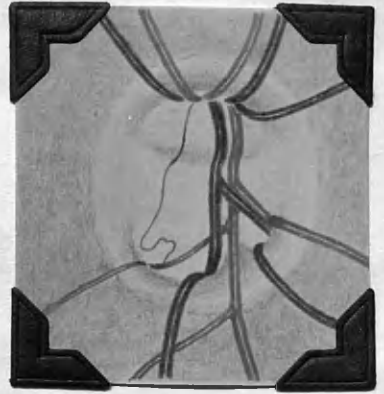


FIG 42

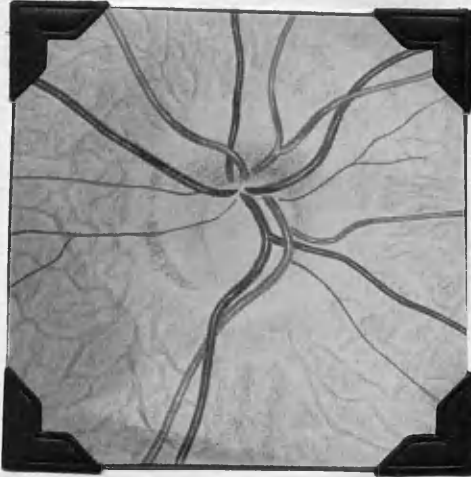


FIG 43

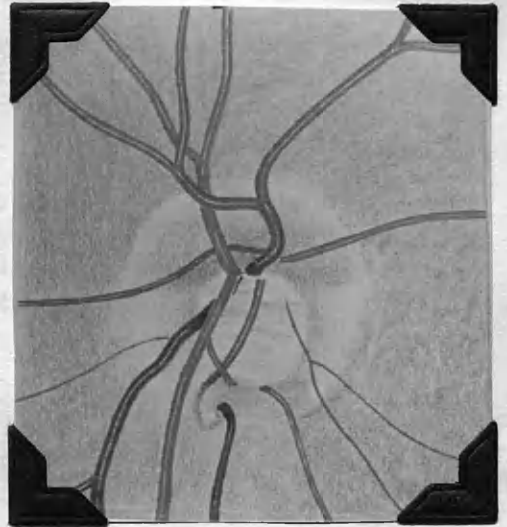


Fig. 44. M.M.; Male; Age 45; -0.50 D.S. with -0.50 D.C. 180°. Left eye. Reduced oval disc with nasal creseent.

Fig. 45. C.F.; Female; Age 29; -1.0 D.S. with -5.00 D.C. 25°. Left eye. Compare with previous. Similare except for the absence of a crescent.

Fig. 46. J.C.; Female; Age 20; Refraction -5.00 D.S. Right eye. D-shaped disc with temporal crescent. Temporal displacement of retina with characteristic appearances.

Fig. 47. W.K.; Female; Age 17; -6.00 D.S. with -1.00 D.C. 30°. Right eye. Compare with previous. Similar except for absence of a crescent.

It may be noted that differences of refraction may bear no relationship to the relative fundus appearances when the eyes are from different individuals. This is not so when the eyes belong to the same individual.

FIG 44

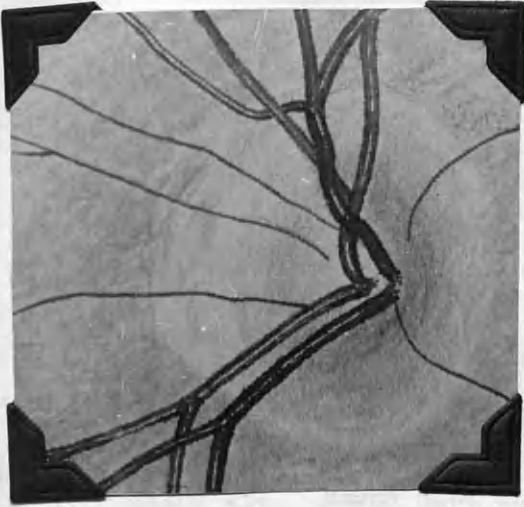


FIG. 45.

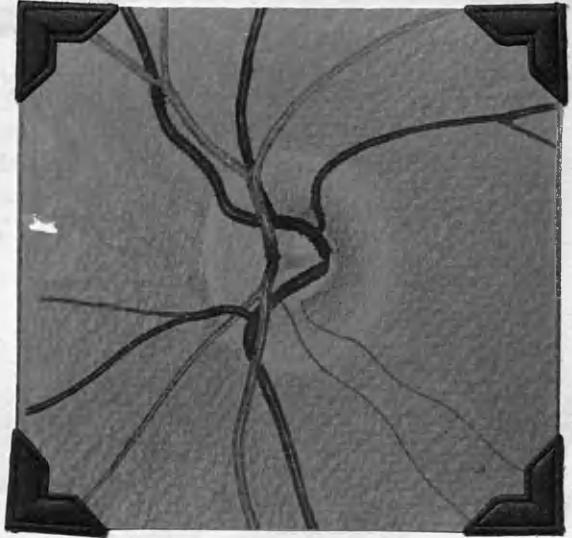


FIG 46

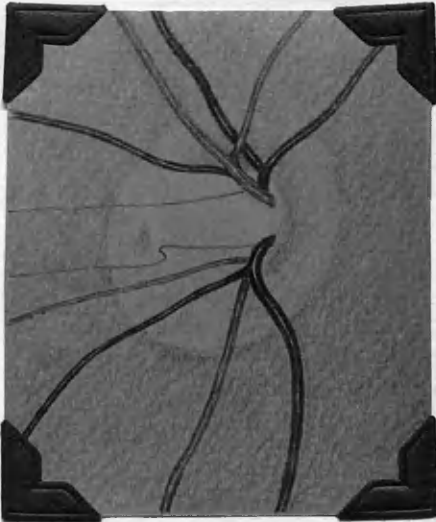


FIG 47




Fig. 48. R.D.; Female; Age ; -1.50 D.S. with -0.50 D.C. 150°. Right eye. D-shaped disc with inferior crescent. Elongated fenestrae of lamina cribrosa with long axes parallel to straight part of disc margin.

Fig. 49. E.W.; Male ; Age 34; Refraction -0.50 D.C. 20°. Right eye. Round disc with temporal crescent. Fenestrae of lamina cribrosa elongated in the direction of greatest ectasia.

Fig. 50. J.W.; Female; Age 67; -3.00 D.S. with -0.75 D.C. 60°. Right eye. Round disc with temporal crescent and lamina cribrosa as in the previous. Secondary crescent supero-nasal.

FIG 48

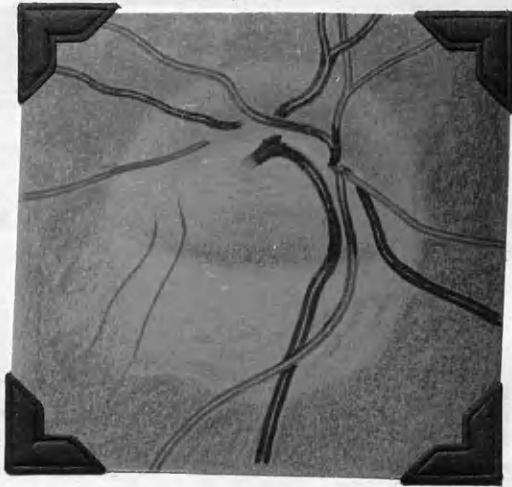


FIG 49

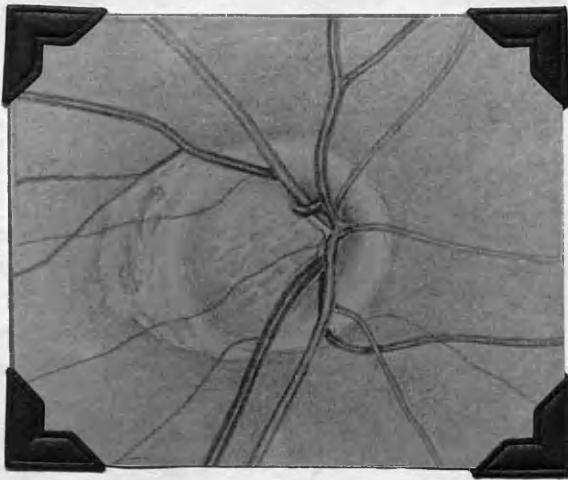
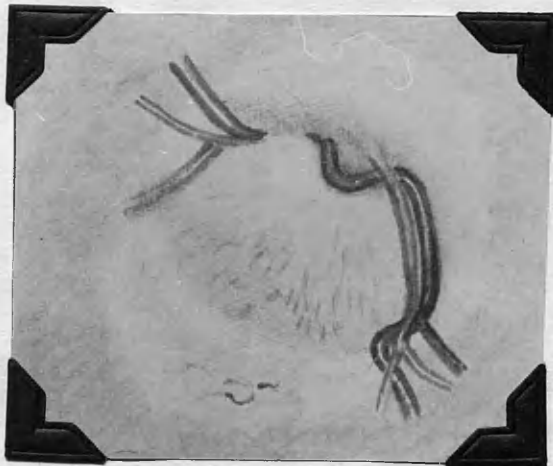


FIG 50



27

Fig. 51. F.C.; Female; Age 15; Refraction -0.375 D.S.
Left eye. Note glial strand bridging physiological cup.

Fig. 52. J.C.; Female; Age 13; Refraction -2.00 D.S.
Left eye. Similar to previous.

Fig. 53. J.G.; Female; Age 12; Refraction - Emmetropic.
Left eye. Note triangular shelf of glial tissue
projecting from temporal margin of the physiological
cup. The free edge looks as if it had been torn from
the nasal margin of the cup.

These glial remnants are extremely common,
especially in young persons, but are difficult to see
with the ophthalmoscope. They are most easily seen
with the slit lamp and Ruby lens.

FIG 51




FIG 52

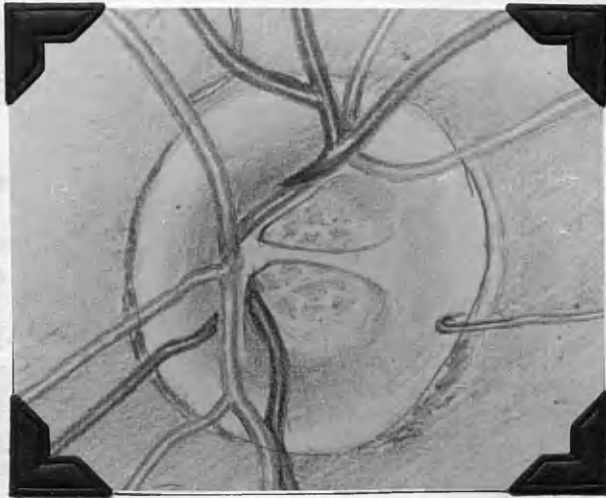


FIG 53

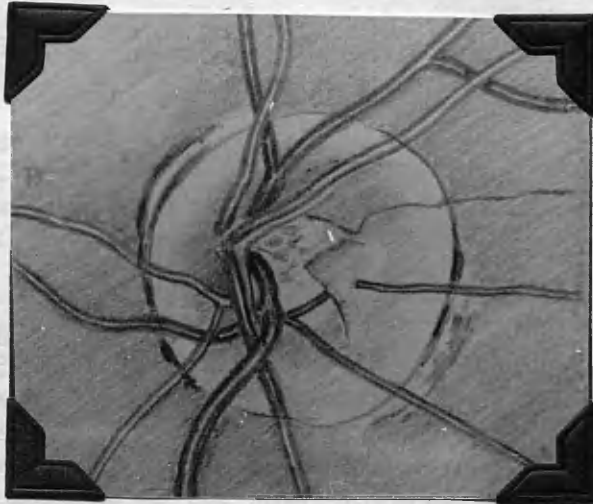


Fig. 54. G.T.; Male; Age 16; Refraction -0.50 D.C. 165°. Right eye. Uniform stretch with central symmetrical cup.

Fig. 55. C.F.; Female; Age 29; Refraction -8.00 D.S. Right eye. As previous but cup widely opened up so that disc surface is almost flat. The vessels are somewhat nasally directed on the disc since they follow the nerve fibres of the nasal wall of the physiological cup. The disc is circular and its margin is uniformly defined.

Fig. 56. L.Y.; Male; Age 37; Refraction -6.5 D.S. Left eye. Fairly uniform stretch with slight excess inferiorly. The disc margin is outlined by proliferated pigment epithelium which forms a double line below. The inner pigment line lies within the scleral disc margin and is incomplete.

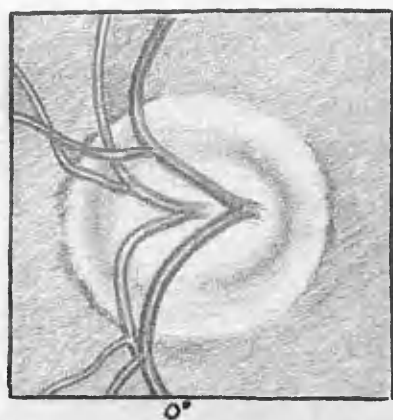
Fig. 57. B.C.; Female; Age 12; -10.00 D.S. with -3.00 D.C. 180°. Left eye. More marked stretch than in previous but otherwise similar. The inner pigment line is absent and the disc is surrounded by a narrow rim of choroidal atrophy bounded by a pigment line. The physiological cup is saucer-shaped and occupies the entire disc area. The scleral disc margin is uniformly well defined. There is no abundance of nerve fibres crossing the nasal margin of the disc.

Fig. 58. A.L.; Female; Age 20; Refraction -9.00 D.S. Right eye. Similar to previous except that there is slight relative excess stretch temporal to the disc. The rim of choroidal atrophy is narrowest, and the nerve tissue overlying the disc margin greatest, nasally.

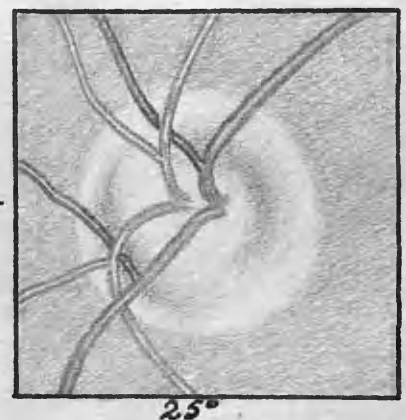
Fig. 59. E.S.; Female; Age 66; Refraction -2.00 D.C. 140°. Left eye. Uniform stretch with fairly wide rim of choroidal atrophy whose margin is somewhat irregular, suggesting degeneration at the margin of Bruch's membrane.

Fig. 60. Drawings of the optic disc from selected eyes of the second series showing the estimated direction of greatest scleral ectasia from the disc. They are all left eyes and show, fairly well, the tendency for the upper branches of the central retinal vein to be obscured by retinal supertraction from above. The lower branches tend to be visible in their entire course as do the upper branches of the central retinal artery.

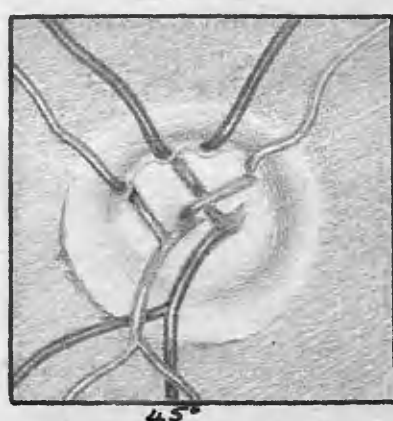
Fig. 60.



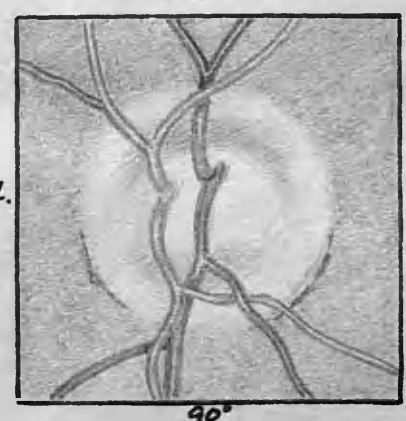
a.



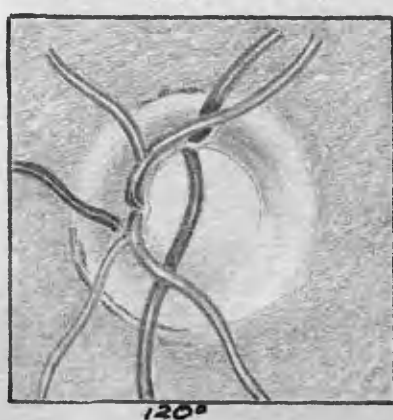
b.



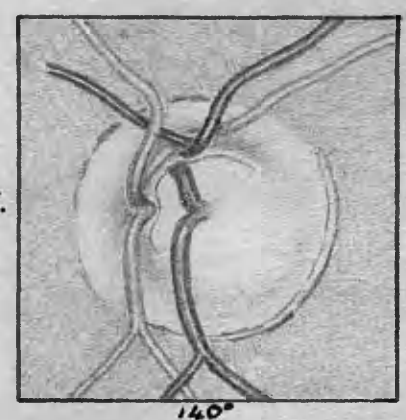
c.



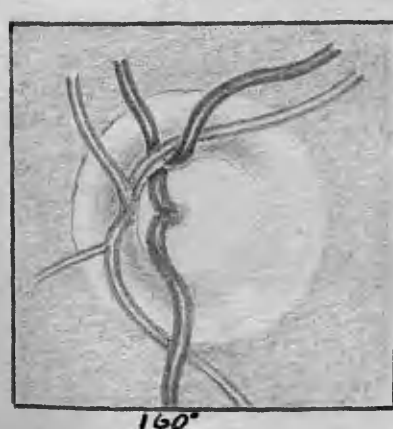
d.



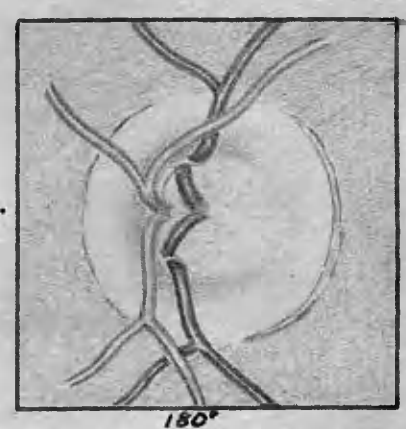
e.



f.



g.



h.

FIG 54

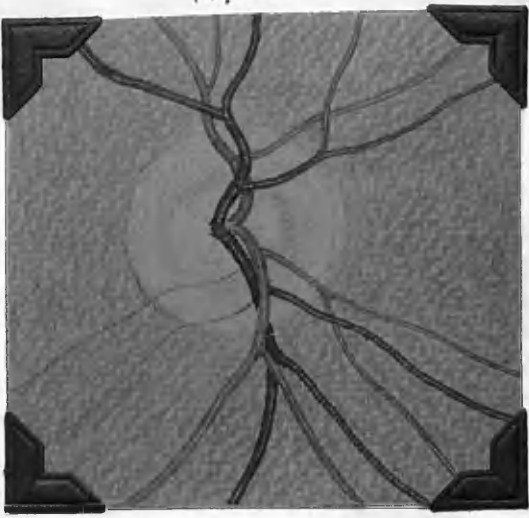


FIG 55

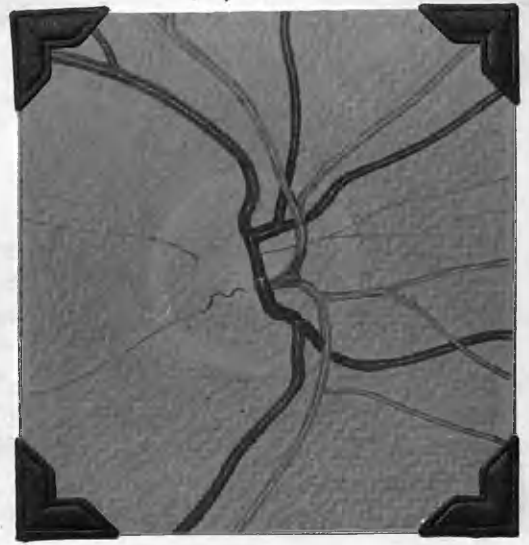


FIG 56

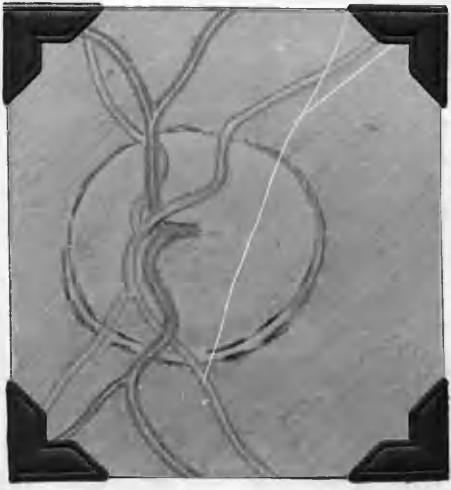


FIG 57

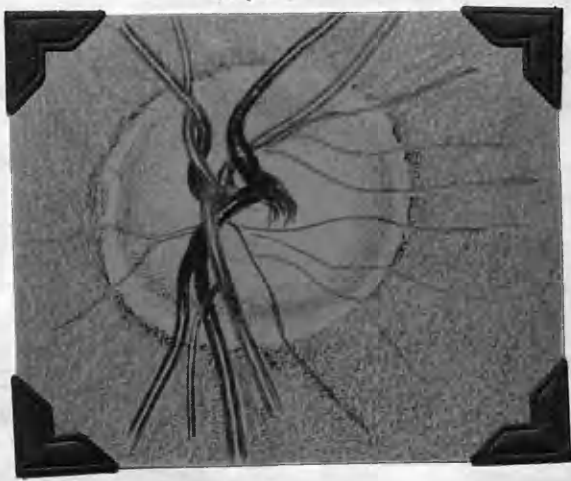


FIG 58

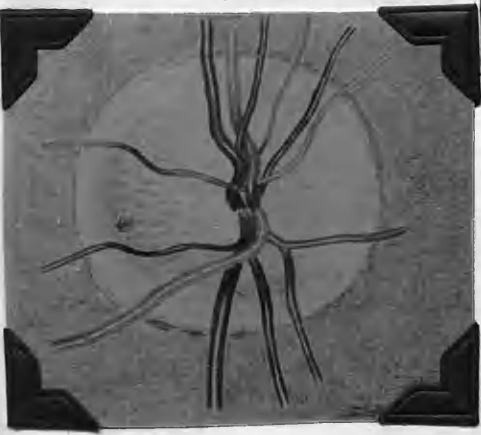


FIG 59

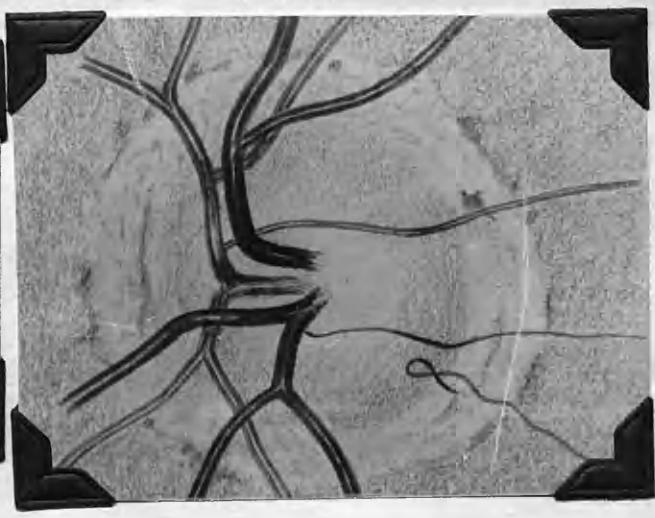


Fig. 61. Various appearances commonly produced by pigment epithelial proliferation at the margin of Bruch's membrane when the latter undergoes slight displacement. They tend to occur at that part of the disc margin related to the region of greatest ectasia but also occur, although somewhat less frequently, at the opposite part of the margin. Their significance is considered in the text.

Fig. 62. A.R.; Female; Age 12; Refraction -3.25 D.S. with -0.5D.C.75°. Left eye. Temporal stretch and displacement of the retina. An example of the appearances very commonly encountered at the margin of the optic disc.

Fig. 63. W.B.; ; Age 15; -3.50 D.S. with -0.50 D.C. 180°. Left eye. More marked pigment changes at the disc margin than in the previous. There are indications of three stages in the movement of Bruch's membrane, each small crescent having a different degree of choroidal atrophy.

Fig. 61.

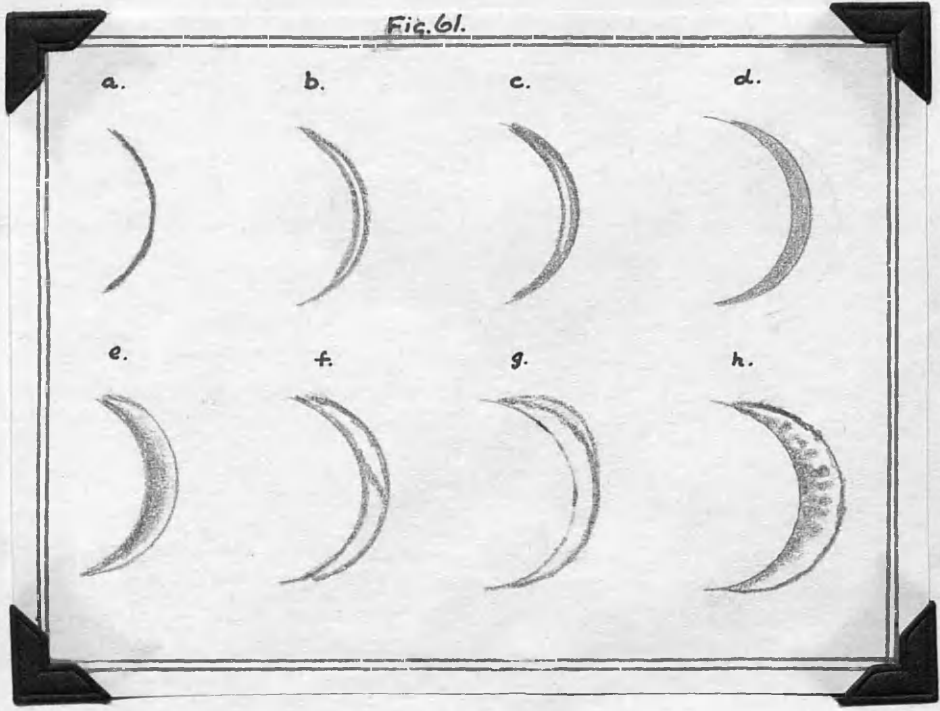


FIG 62.

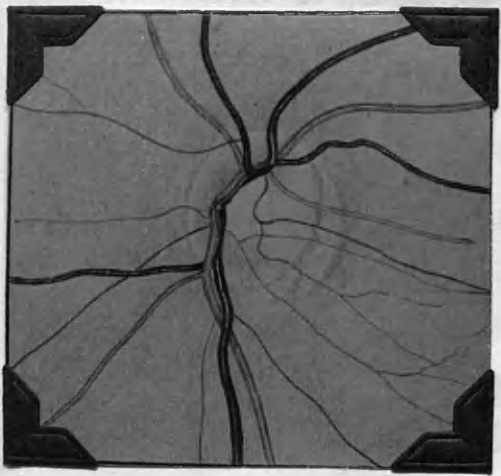
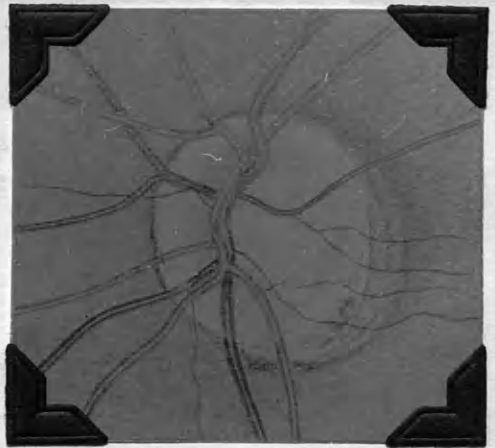


FIG 63



- Fig. 64. O.R.; Female; Age 60; Refraction, R.E.
Reduced oval disc with inferior nasal crescent showing extension towards inferior nasal quadrant. There is well marked senile cupping of the disc although the superior nasal branches of the central retinal vessels are obscured in part by the remains of retinal supertraction on the upper part of the disc.
- Fig. 65. A.McI; Male; Age 40; L.E. -12.00D.S. with -5.00 D.C. 160°. Enlarged oval disc with nasal crescent showing extension nasally. The primary crescent must have been very small and it is possible that all of the choroidal atrophy has resulted from rupture of Bruch's membrane.
- Fig. 66. J.P.; Female; Age ; Refraction R.E. \neq 2.00 D.S.(Aphakia). Inferior nasal crescent. Small recent tertiary crescent above. Oval disc with senile cupping. The retinal vessels are visible as far as the scleral disc margin on the temporal side.
- Fig. 67. H.W.; Male; Age 53; L.E. -10.00 D.S. with -0.50 D.C. 165°. Similar to the previous. These two optic discs show well the oval shape of the inner opening of the scleral canal.

FIG 64

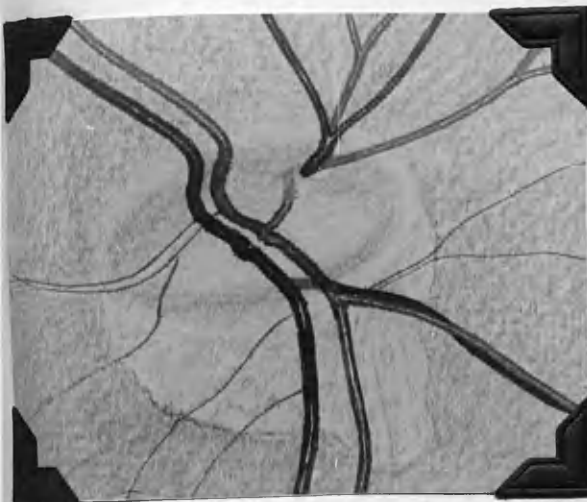


FIG 65

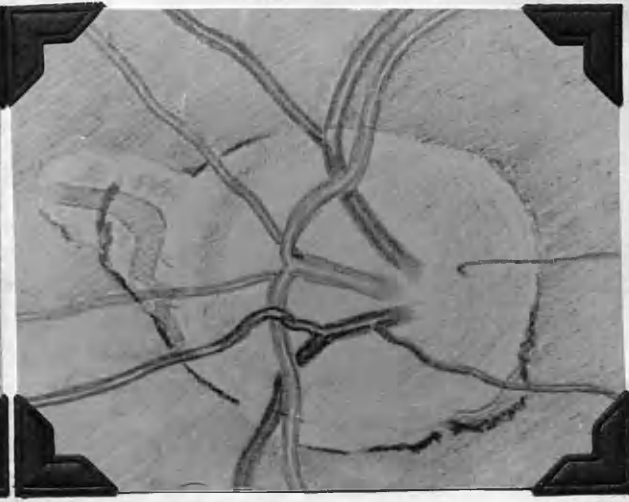


FIG 66

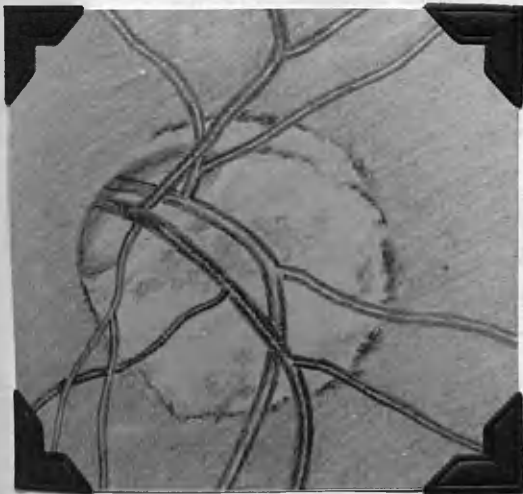
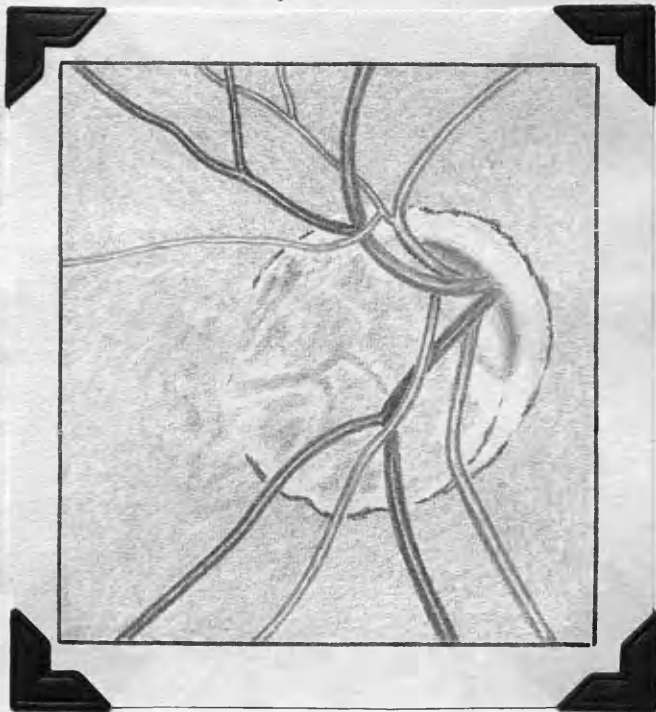


FIG 67



- Fig. 68. M.F.; Female; Age 55; R.E. -8.00 D.S. with -2.00 D.C. 75°. Enlarged oval disc with nasal crescent. The layer of nerve fibres is thick over the temporal margin of the disc and thin over the nasal margin. The common appearance of a thick layer of nerve fibres on the nasal margin of the disc is not therefore due to a greater number of nerve fibres at this site. Note the sharp temporal margin of the physiological cup and the blood vessels emerging from deep to it.
- Fig. 69. U.D.T. Male; Age 68; R.E. -1.00 D.S. with \nearrow 1.50 D.C. 100°. Inferior nasal crescent with two tertiary crescent. Disc is intermediate between D-shaped and oval.
- Fig. 70. J.A.T.; Male; Age 34; Refraction L.E. Early temporal crescent and secondary crescent at nasal margin. Note remains of proximal pigment line internal to pale scleral disc margin showing that the latter was not originally part of the disc. A strong band of glial tissue has prevented full opening of the physiological cup in its upper part.
- Fig. 71. McK.; Female; Right eye. Round disc with inferior nasal crescent. Note that the layer of nerve fibres is thickest over the upper temporal part of the disc margin.
- Fig. 72. C.C.; Female; Age 13; Refraction R.E. -4.50 D.S. with -1.00 D.C. 60°. Corresponds in appearance to the previous.

FIG 68

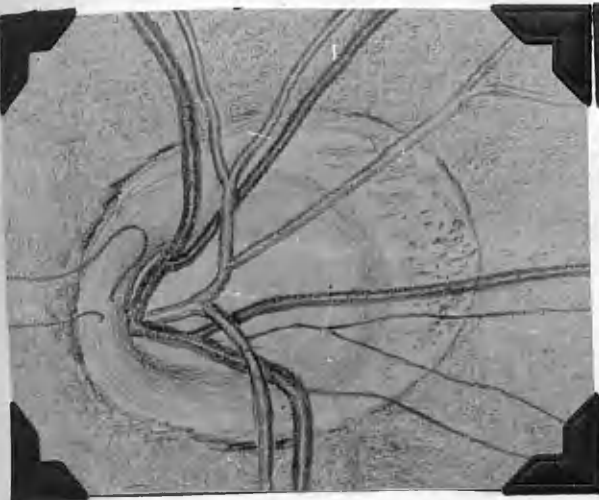


FIG 69

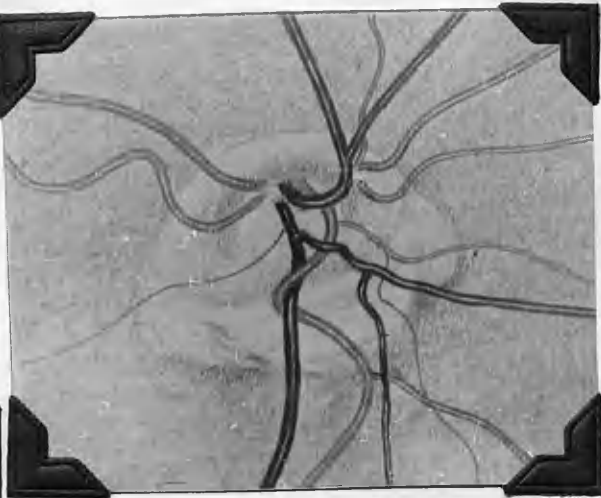


FIG 70

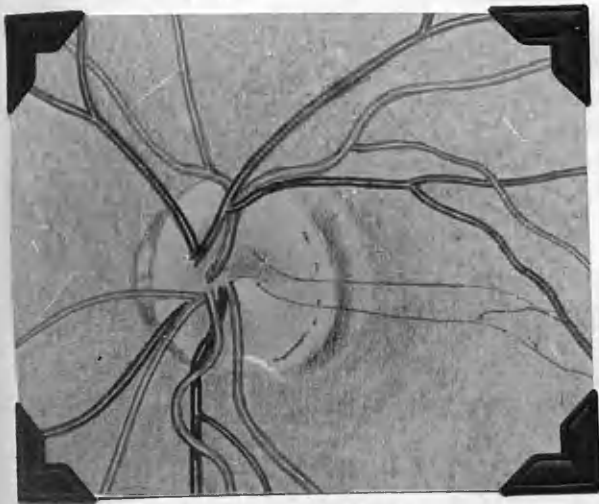


FIG 71

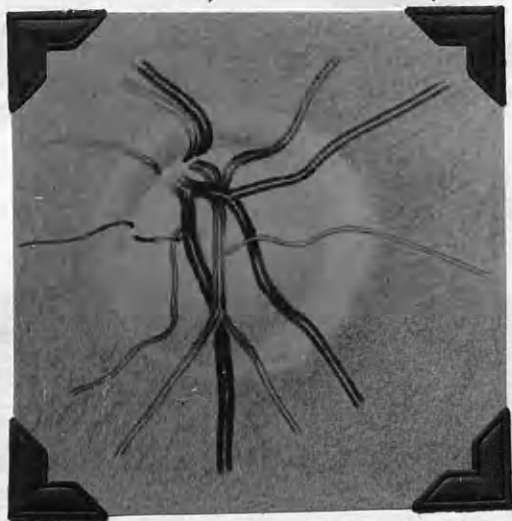


FIG 72

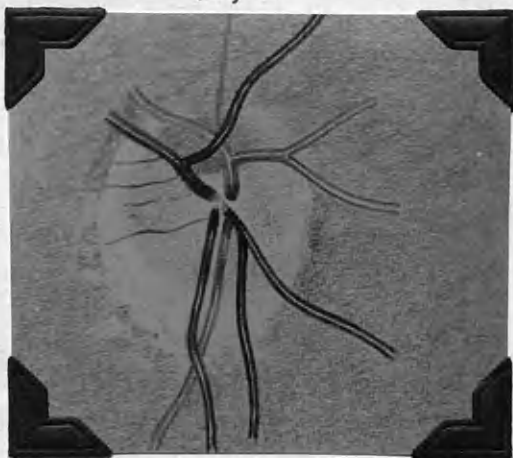


Fig. 73. E.P.; Female; Age 68; L.E. -15.00 D.S. with -1.00 D.C.180°. Large disc with temporal crescent. Secondary crescent on nasal side. The fold of nerve fibres on the nasal part of the disc shows some senile depression. The central retinal artery appears to have branched behind the globe and the upper branch sends a secondary branch to the choroid. There is a small vessel loop on the crescent. The crescent is covered with a choroidal network. The physiological cup is deep and the fenestrae of the lamina cribrosa enlarged, suggesting that this is a bulbous cup in an eye with greatest ectasia temporal to the optic disc.

Fig. 74. MR.; Female; Age 34; Left Eye. Bulbous cup. Deep with stretched lamina cribrosa showing large fenestrae. The vessels on the nasal part of the disc appear to support the related nerve fibres preventing their being pushed out by the intra-ocular pressure.

Fig. 75. ; Female; Age 11; Refraction R.E. / 3.50 D.C. 90°. Small bulbous cup with well defined projecting margin.

Fig. 76. W.; Male; Age ; Left eye. Large deep cup with local elongation of the fenestrae of the lamina cribrosa. Note how the superior temporal branch of the central retinal artery bridges the cup while the corresponding veins do not. The lamina cribrosa is visible nasal to the superior temporal arterial branch so that it is fairly certain that the upper part of this cup has been partly determined by pressure on the disc with or without yielding of the lamina cribrosa. The significance of this physiological cup is probably like that of fig. 73.

FIG 73

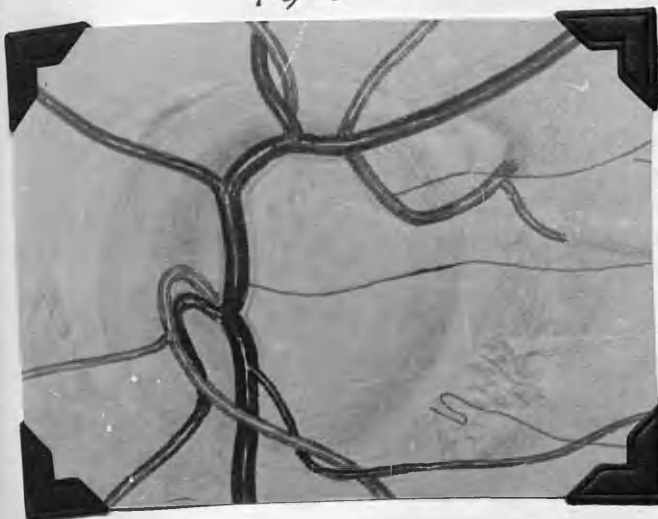

FIG 74

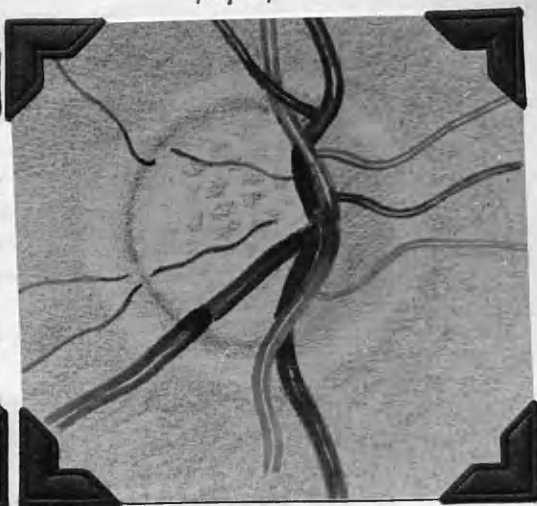


FIG 75

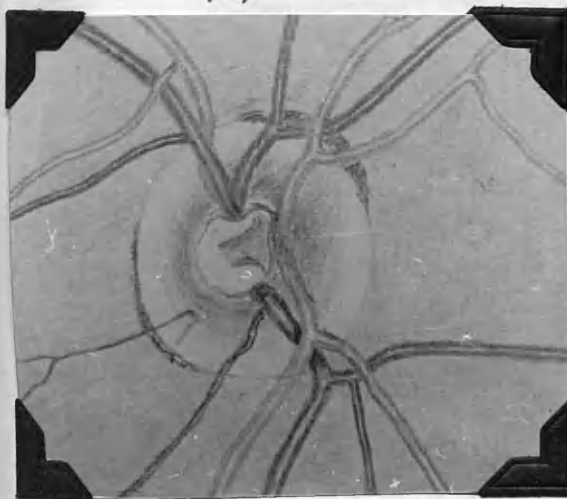
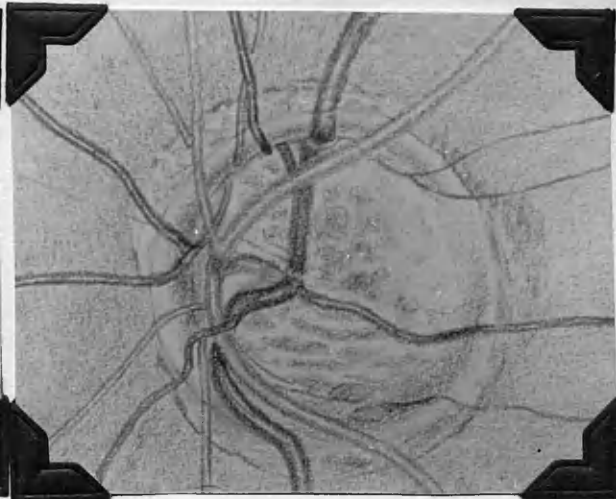


FIG 76



77
Fig. 77. G.K.; Male; Age 25; Refraction R.E. -20.00 D.S.
Reduced oval disc with primary temporal crescent.

Note: a. Senile type of cupping occurring at an early age in a markedly stretched eye.

- b. Shadow cast by temporal margin of disc.
- c. Reduced angle between superior and inferior temporal vessels.
- d. Cilio-retinal artery failing to reach the disc margin.
- e. Vessel loop on crescent.
- f. Nasal branches leaving temporal branches at an obtuse angle.
- g. Absence of retinal supertraction fold due to presence of senile cupping.

FIG 77.

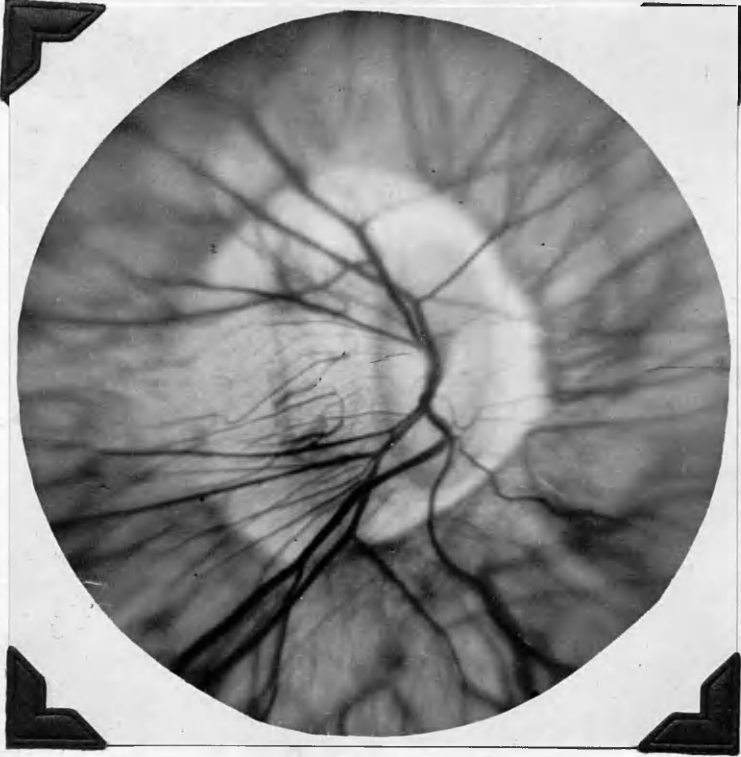
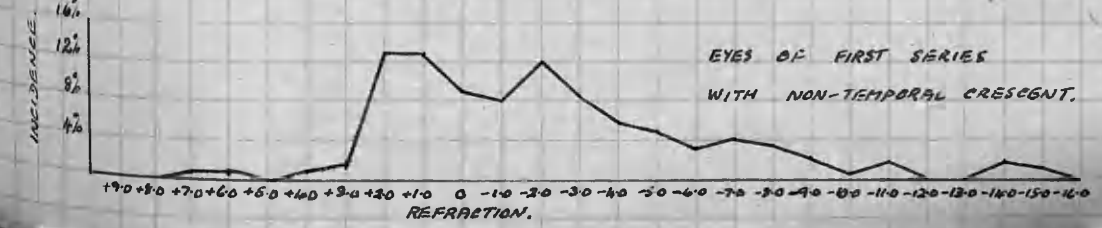
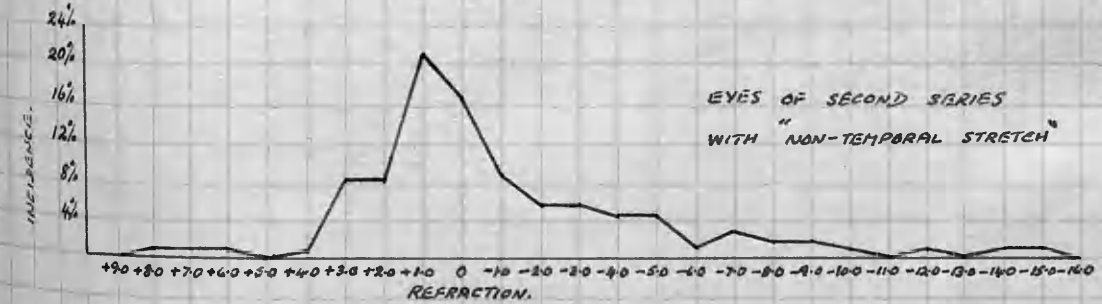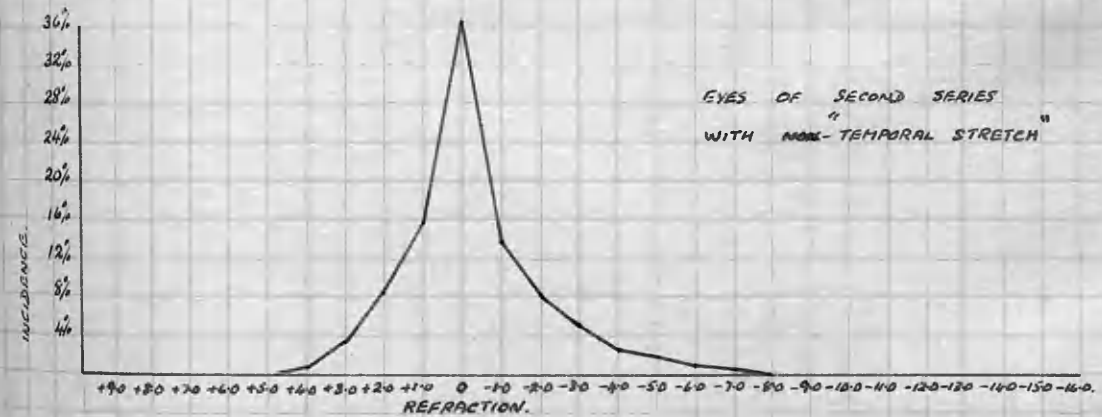
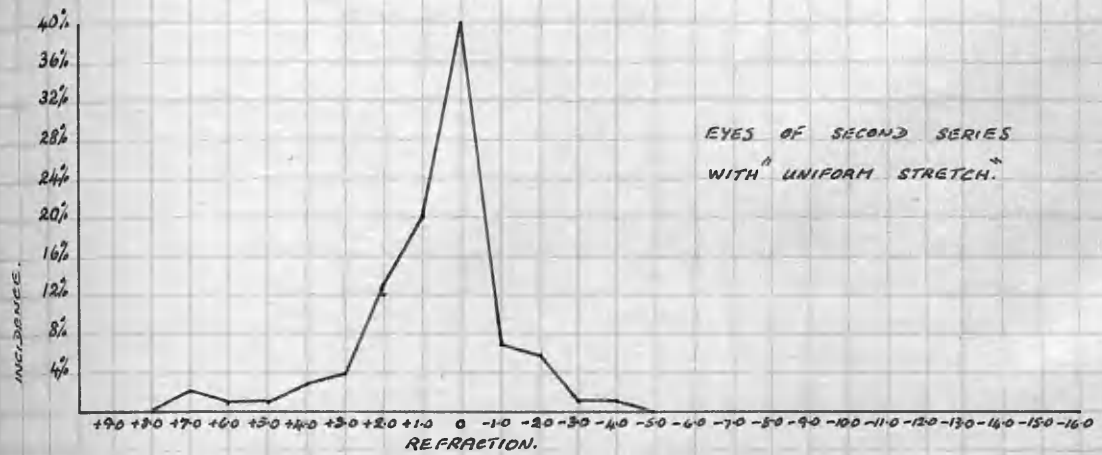
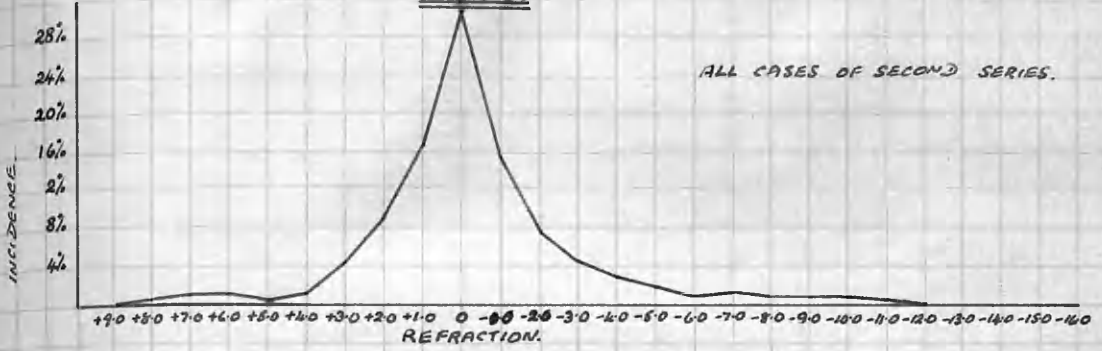
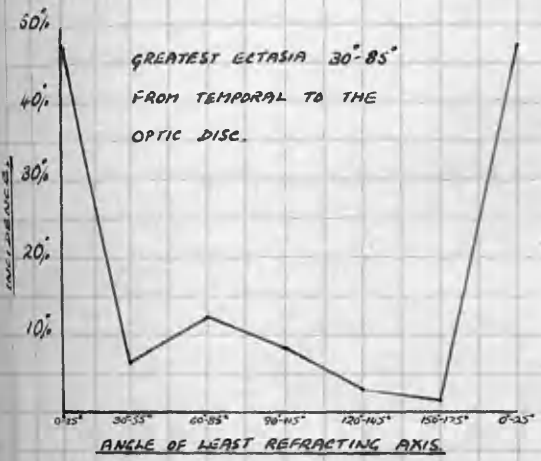
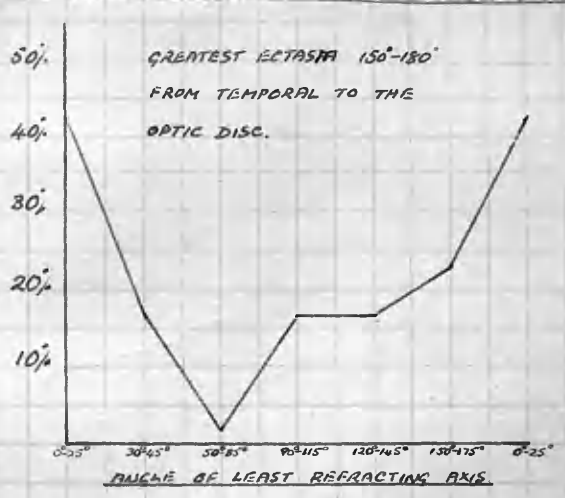
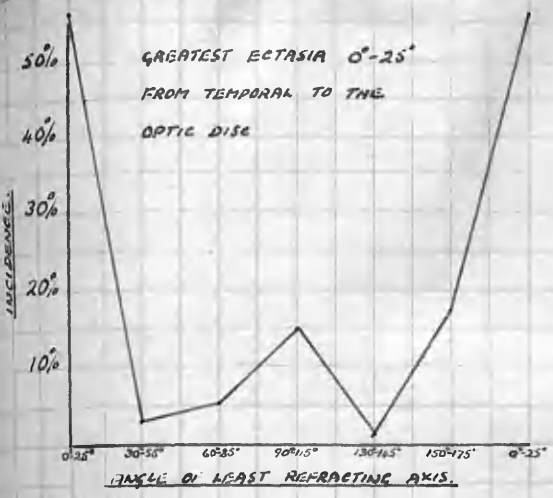


Fig. 78.





INCIDENCE OF ASTIGMATISM AT VARIOUS ANGLES WITH GREATEST ECTASIA IN VARIOUS LOCATIONS. THE NUMBER OF CASES, ON WHICH THESE GRAPHS ARE BASED, IS ADEQUATE TO SHOW THE RELATIONSHIP BETWEEN ANTERIOR AND POSTERIOR ASYMMETRY OF THE EYE.

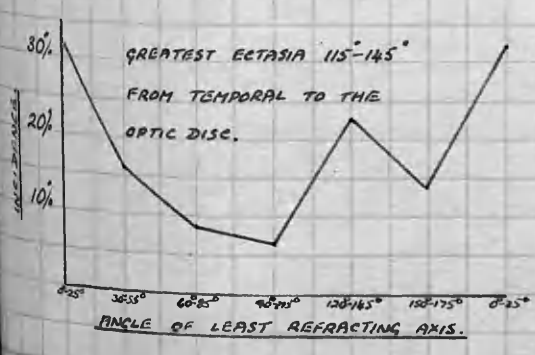
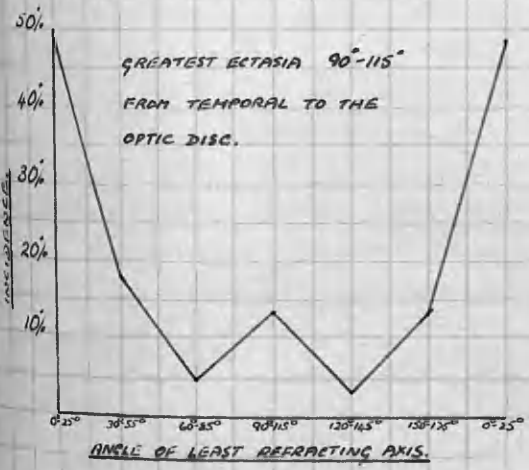
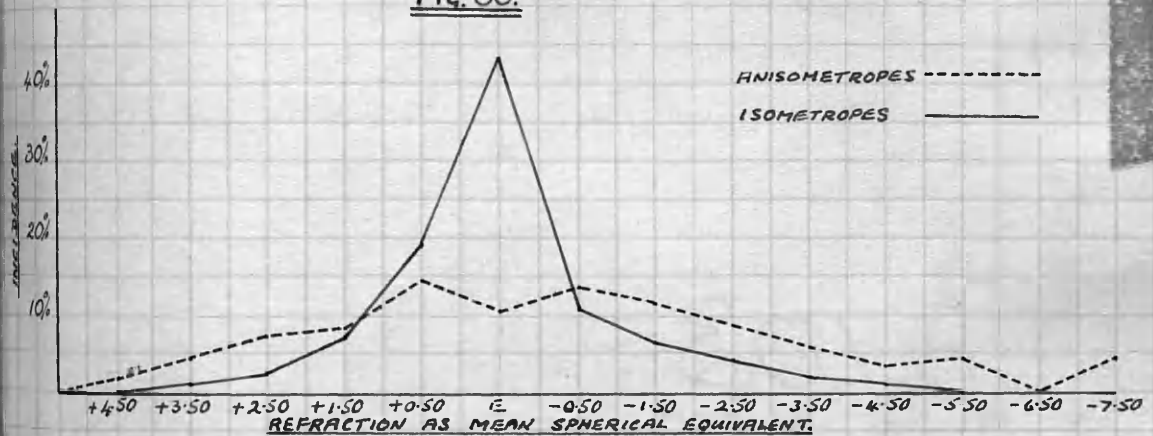


Fig. 80.



INCIDENCE OF REFRACTION IN ISOMETROPE AND ANISOMETROPE OF SECOND SERIES. THE FIGURES OF THE REFRACTIVE SCALE ARE THE LOWEST VALUES INCLUDED IN EACH OF THE CORRESPONDING POINTS ON THE GRAPHS. THE INCIDENCE OF EMMETROPIA IS THEREFORE TOO LOW. THIS DOES NOT, HOWEVER, ALTER THE VALUE OF THE CURVES FOR PURPOSES OF COMPARISON.

Fig. 81. A.B.; Male; Age 51; Refraction:

R.E. \neq 2.75 D.S. with -6.00 D.C. 45° .

L.E. \neq 2.50 D.S. with -6.00 D.C. 135° .

Nasal crescent in both eyes with typical superior temporal defects.

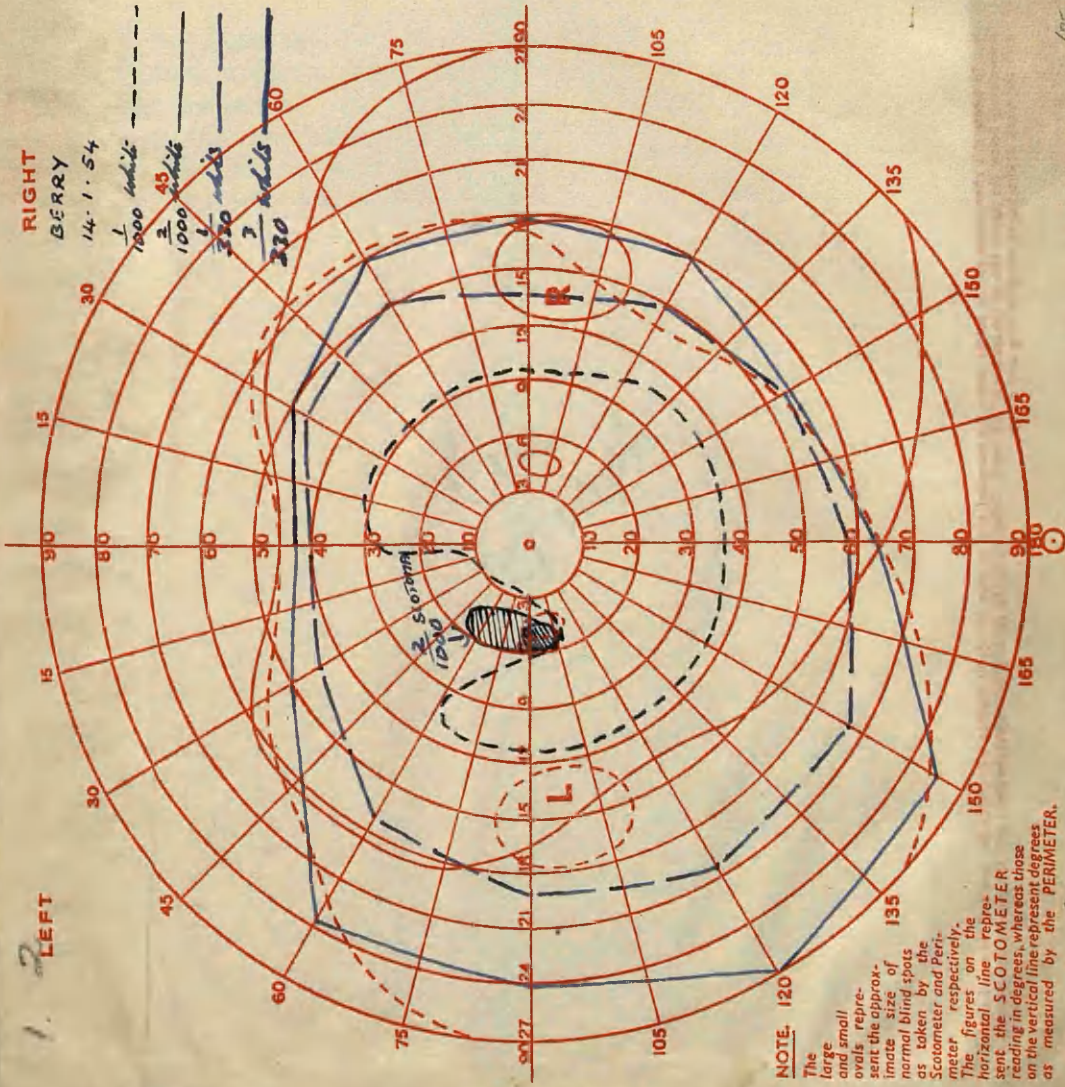
105



RIGHT
BERRY

14.1.54

- 1 1000 white
- 2 45
- 3 1000 white
- 4 330
- 5 330
- 6 60



NOTE 120
The large and small ovals represent the approximate size of normal blind spots as taken by the Scotometer and Perimeter respectively. The figures on the horizontal line represent the SCOTOMETER reading in degrees, whereas those on the vertical line represent degrees as measured by the PERIMETER.

PERIMETER AND SCOTOMETER CHART.

THEODORE HAMBLIN LTD. LONDON, W.1.


105

LEFT

RIGHT
BERRY

14.1.54

- 1 1000 white
- 2 45
- 3 1000 white - no defect
- 4 330
- 5 330
- 6 60



NOTE 120
The large and small ovals represent the approximate size of normal blind spots as taken by the Scotometer and Perimeter respectively. The figures on the horizontal line represent the SCOTOMETER reading in degrees, whereas those on the vertical line represent degrees as measured by the PERIMETER.

PERIMETER AND SCOTOMETER CHART.

THEODORE HAMBLIN LTD. LONDON, W.1.

105

Fig. 82. E.G.; Female; Age 50; Refraction L.E. -1.00 D.C. 45°. Visual fields recorded on the flat screen and the perimeter of one metre radius on the same occasion. Note the presence of an island of vision infero-temporal to the blind spot in the perimeter recording. This island was not detected with the screen.

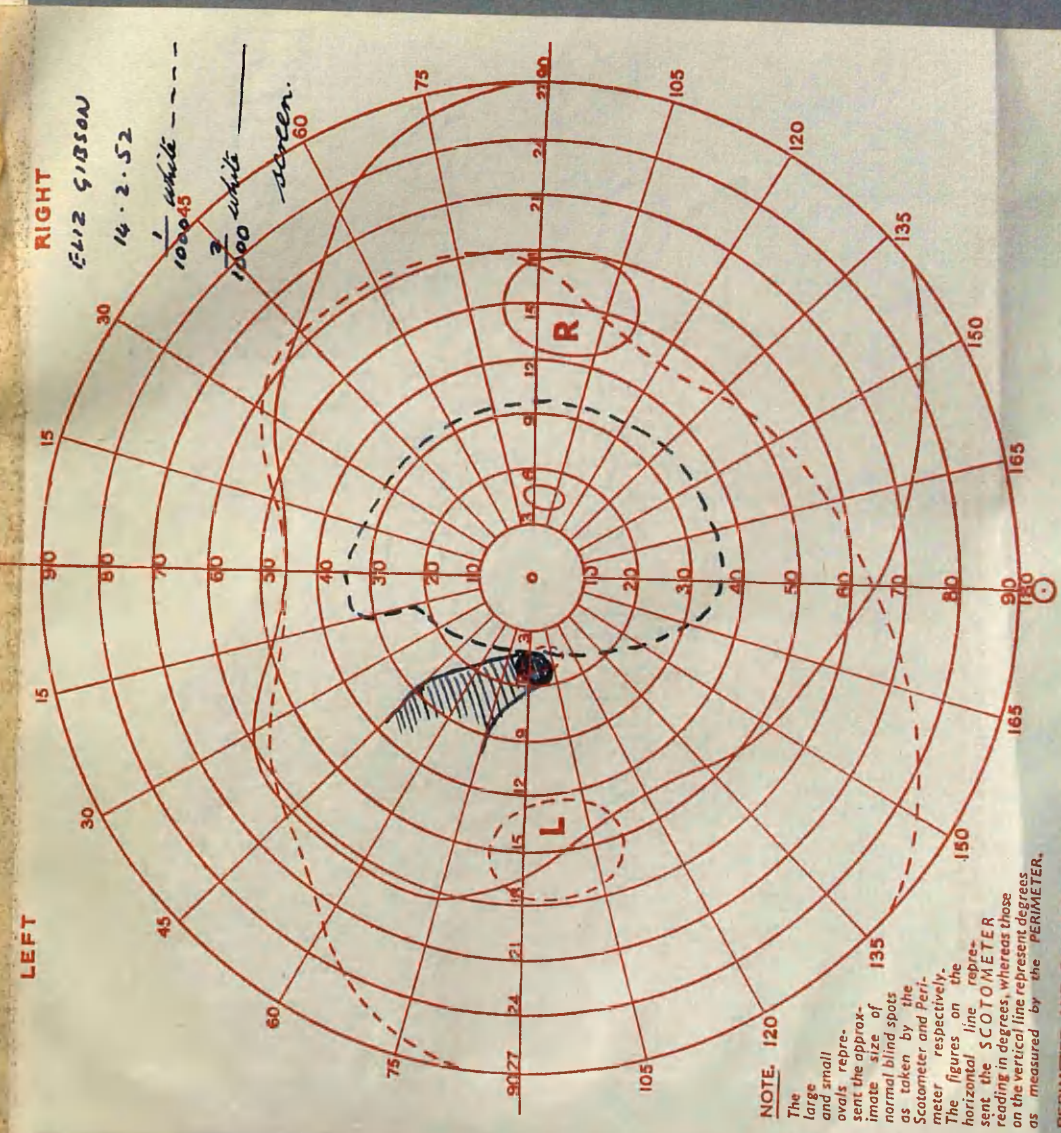
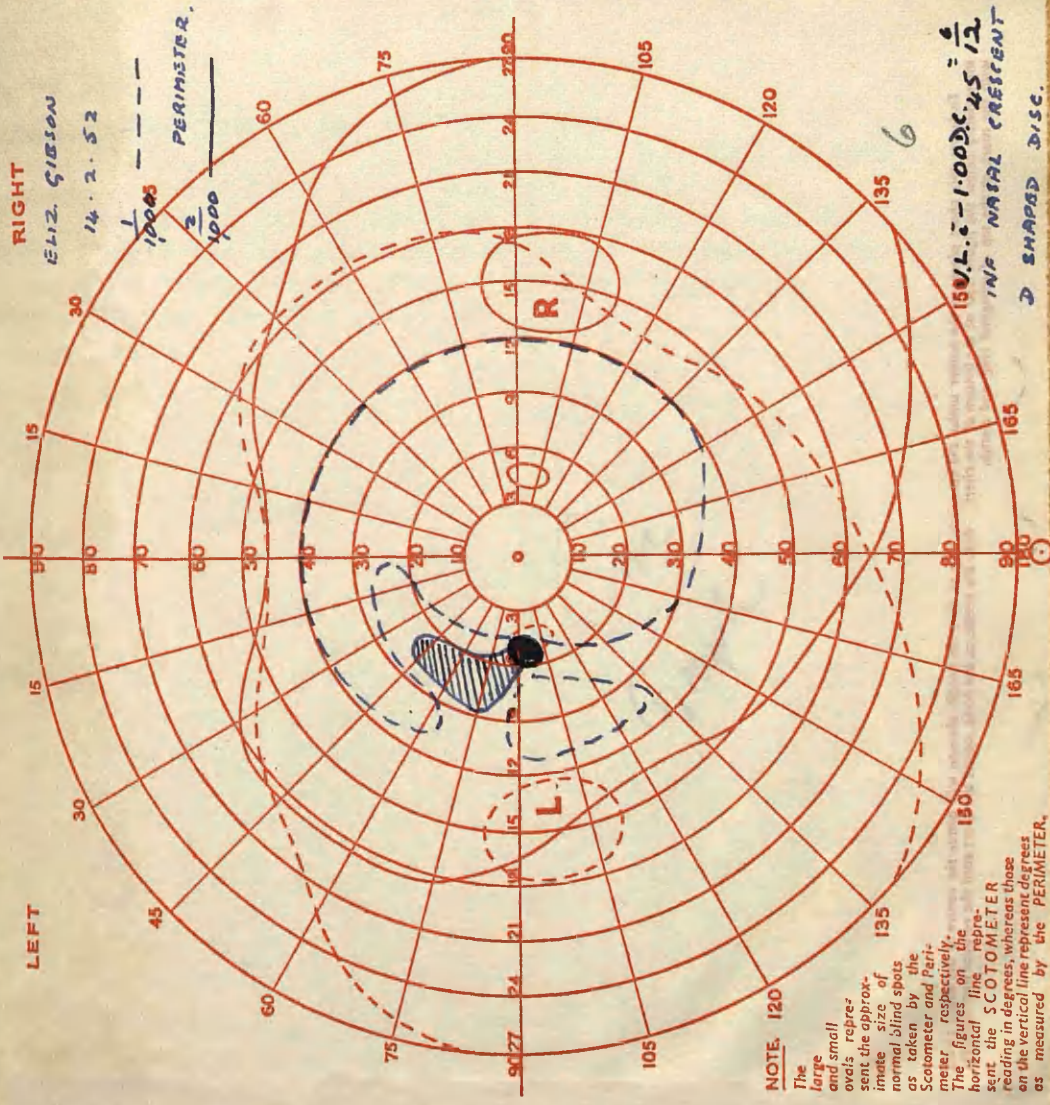



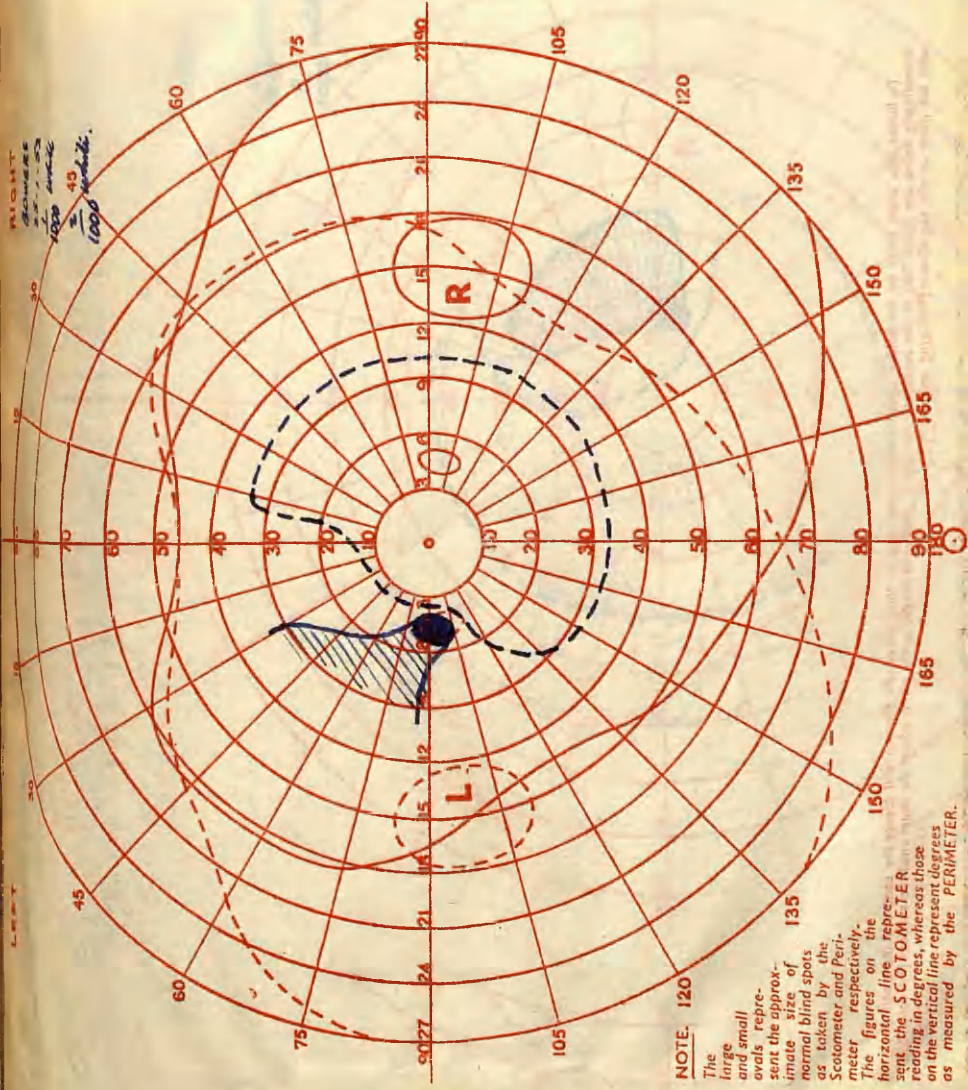
Fig. 83. E.B.; Female; Age 16; Refraction:

r.e. -10.00 D.S. with -0.50 D.C. 90°.

l.e. -9.50 D.S.

Defect of visual field as found with the one metre radius
perimeter and Bjerrum's screen at the same examination.
The inner isopter in the right eye approaches very close
to the fixation spot.

HEIGHT
BOMBS
1000 yards
45
1000 yards



NOTE. 120

The large and small ovals represent the approximate size of normal blind spots as taken by the Scotometer and Perimeter respectively. The figures on the horizontal line represent the SCOTOMETER reading in degrees, whereas those on the vertical line represent degrees as measured by the PERIMETER.

PERIMETER AND SCOTOMETER CHART.

THEODORE HAMBLIN LTD. LONDON, W. 1.

2. LEFT

RIGHT

BOWLER.

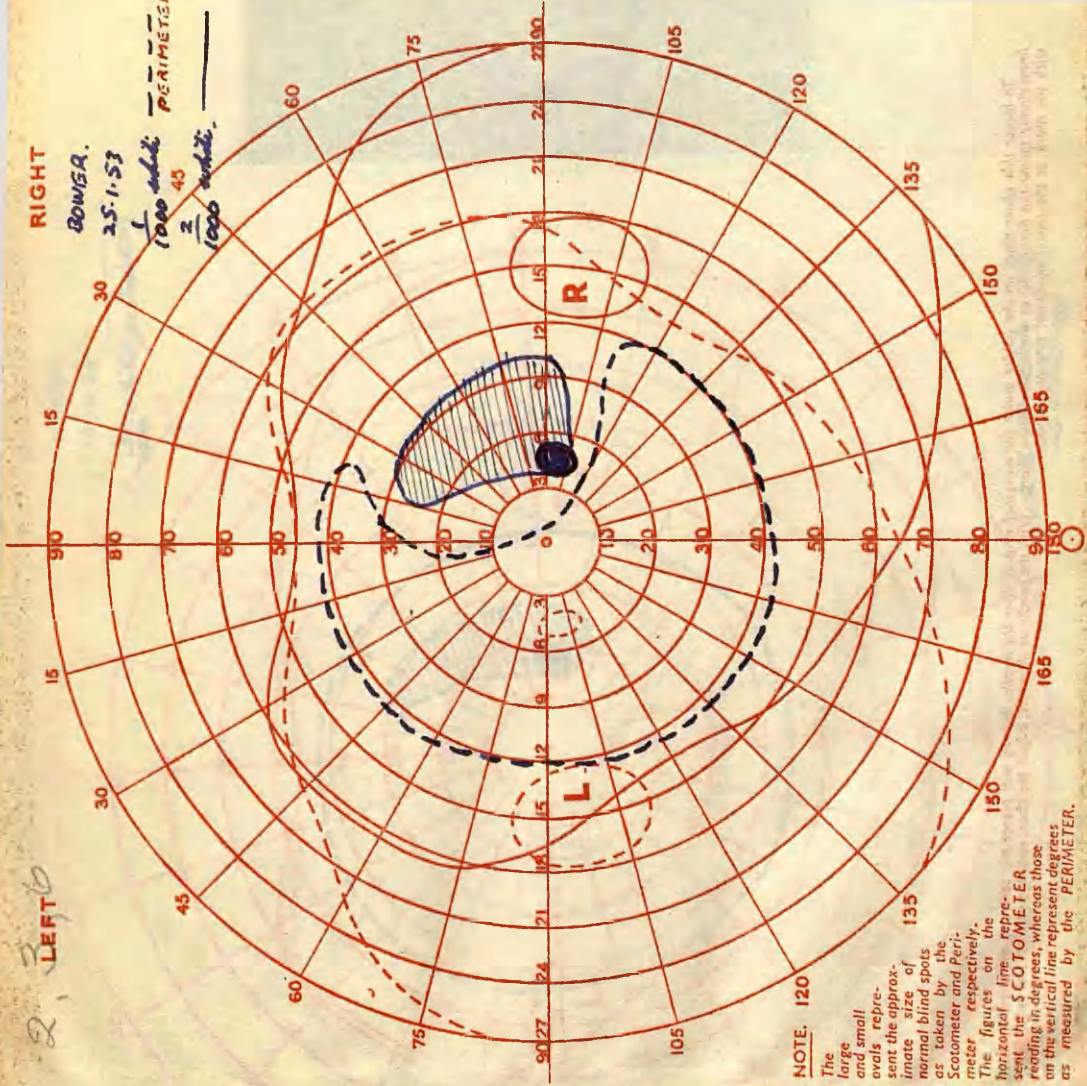
25.1.53

1000 white

45

1000 white

PERIMETER



NOTE. 120

The large and small ovals represent the approximate size of normal blind spots as taken by the Scotometer and Perimeter respectively. The figures on the horizontal line represent the SCOTOMETER reading in degrees, whereas those on the vertical line represent degrees as measured by the PERIMETER.

RIGHT


OWERS

18.2.52

$\frac{1}{1000}$ scale (Perimeter)

LEFT

109




NOTE. 120

The large and small ovals represent the approximate size of normal blind spots as taken by the Scotometer and Perimeter respectively. The figures on the horizontal line represent the SCOTOMETER reading in degrees, whereas those on the vertical line represent degrees as measured by the PERIMETER.

V.R. E-10-0022 = $\frac{6}{12}$
 -0.5022 C-90

RIGHT
BOWERS
18-2-52

$\frac{1}{1000}$ white (perimeter)




NOTE. 120

The large and small ovals represent the approximate size of normal blind spots as taken by the Scotometer and Perimeter respectively. The figures on the horizontal line represent the SCOTOMETER reading in degrees, whereas those on the vertical line represent degrees as measured by the PERIMETER.

$$V.L. \bar{c} - 9.5238 = \frac{6}{12}$$

RIGHT

BOWERS
25.1.52
 $\frac{1}{1000}$ adult. PERIMETER
 $\frac{2.45}{1000}$ adult.



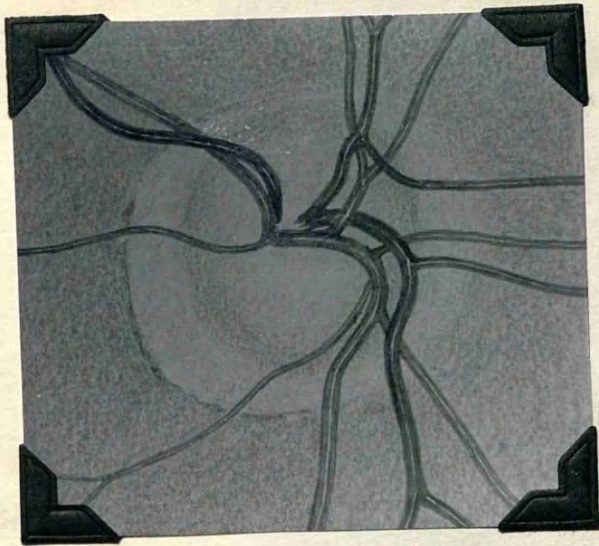
LEFT

NOTE. 120

The large and small ovals represent the approximate size of normal blind spots as taken by the Scotometer and Perimeter respectively. The figures on the horizontal line represent the SCOTOMETER reading in degrees, whereas those on the vertical line represent degrees as measured by the PERIMETER.

PERIMETER AND SCOTOMETER CHART.

THEODORE HAMBLIN LTD. LONDON, W. 1.



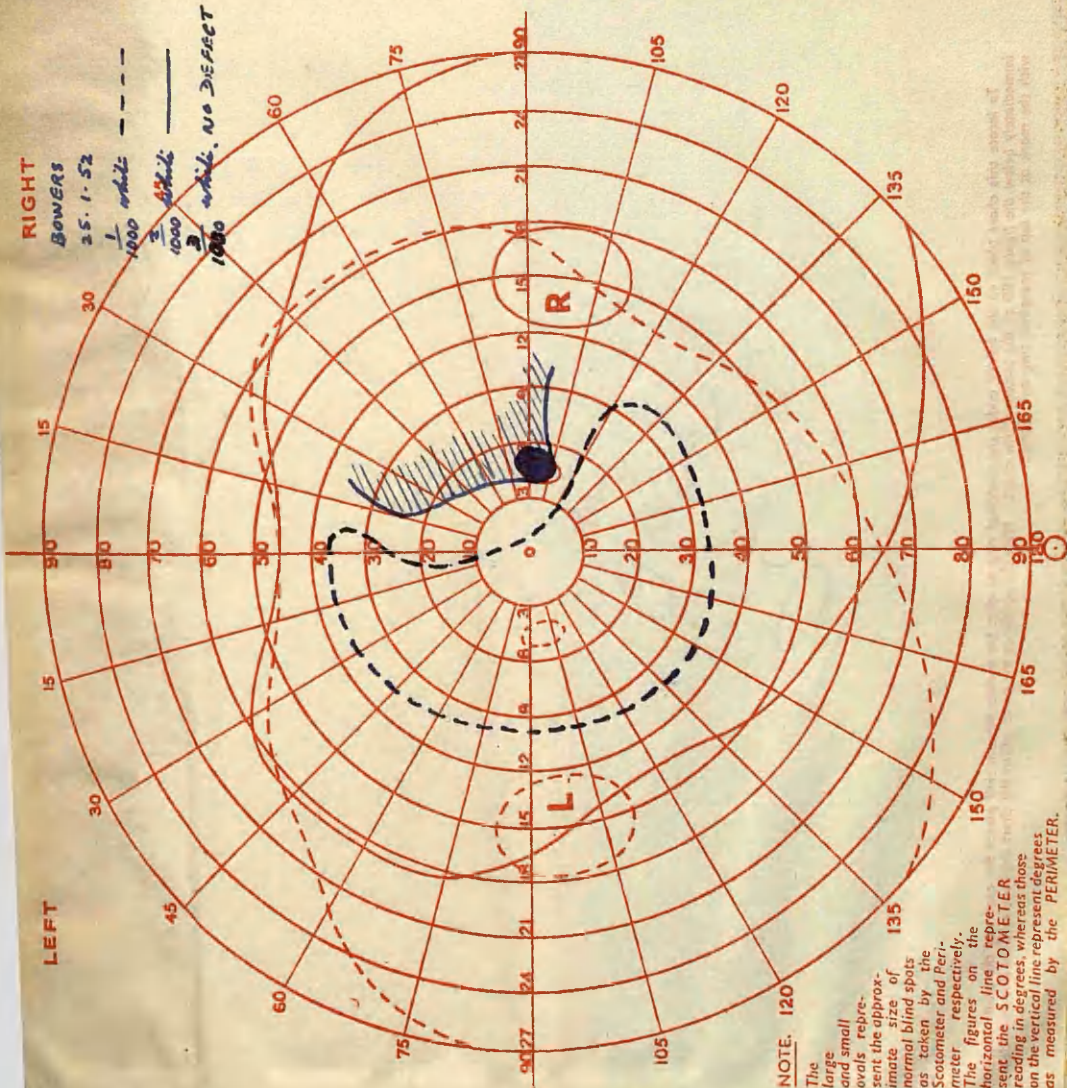
RIGHT
BOWERS

25.1.52

1000 white - - - -

3000 black - - - -

10000 white. NO DEFECT



NOTE. 120

The large small and oval represents the approximate normal blind spots as taken by the Scotometer and Perimeter respectively. The figures on the horizontal line represent the SCOTOMETER reading in degrees whereas those on the vertical line represent degrees as measured by the PERIMETER.






Fig. 84. J.F.; Male; Age ; Refraction:
R.E. -7.00 D.S. with -1.50 D.C. 15°.
L.E. / 1.00 D.S.

The right eye has a primary inferior-temporal crescent with a typical superior temporal field defect extending into the superior nasal quadrant. The left eye had an optic disc which was recorded as normal and its visual field shows no defect.

Fig. 85. O.R.; Female; Age 60; Refraction:

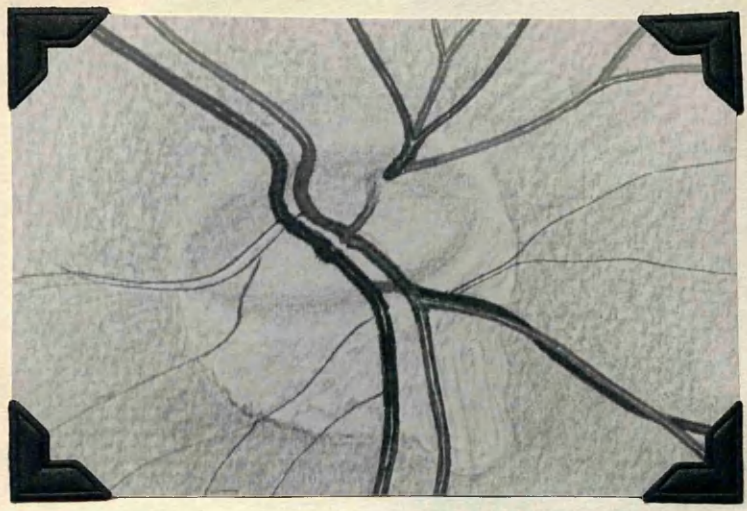
R.E. -2.50 D.S. with -1.00 D.C. 90°.

Right eye. Increasing defect with extension into superior nasal quadrant and involvement of fixation area.



THEODORE HAMBLIN LTD. LONDON, W.1.

THEODORE HAMBLIN LTD. LONDON, W.1.

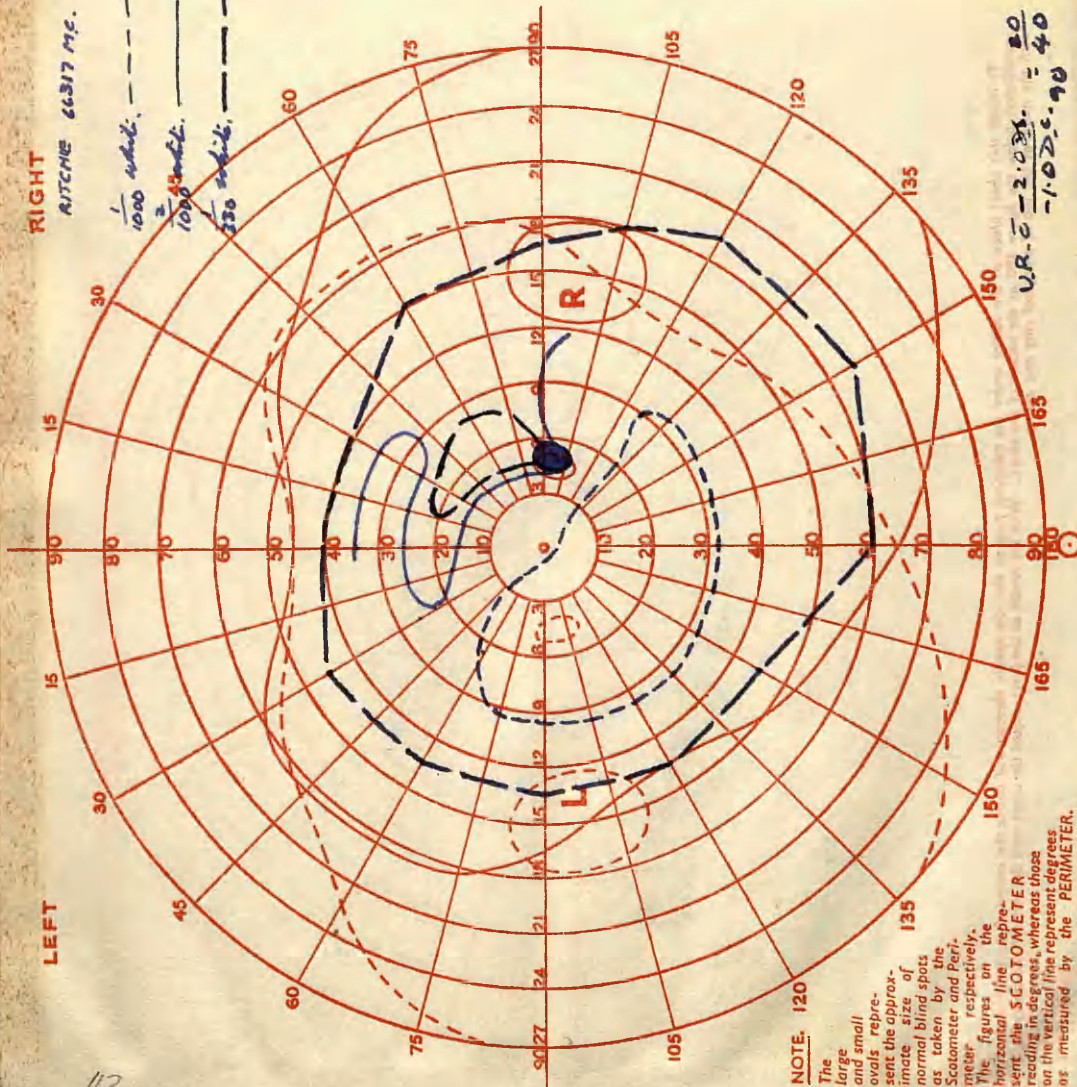


LEFT

RIGHT

ALTITUDE 66317 MFC.

1000 whk.
 = 1000 whk.
 330 whk.



113

NOTE. 120

The large and small ovals represent the approximate size of normal blind spots as taken by the Scotometer and Perimeter, respectively. The figures on the horizontal line represent the SCOTOMETER reading in degrees, whereas those on the vertical line represent degrees as measured by the PERIMETER.

U.R.C - 2.031.
 - 1.025.90 = 40

Fig. 86. A.L.; Female; Age 20; Refraction: R.E. -9.00 D.S.
L.E. -9.00 D.S.

Right eye. Superior temporal defect which increased in extent and density in a period of seven days and cleared up within five weeks. At the second examination the isopter for 1/1000 white closely approached the fixation point up and out.

Left eye. Superior temporal defect encroaching on superior nasal quadrant. The second chart shows an island of vision superiorly, with 2/1000 white target, which has been cut off by a band of depression extending nasally from the temporal defect. The third chart shows marked diminution in the extent and density of the defect. The optic discs were similar.


LEFT

RIGHT

LOG ME.
31.3.57

1000 white ---
 $\frac{1}{330}$ white ---
 $\frac{1}{330}$ white ---
 $\frac{2}{1000}$ white ---

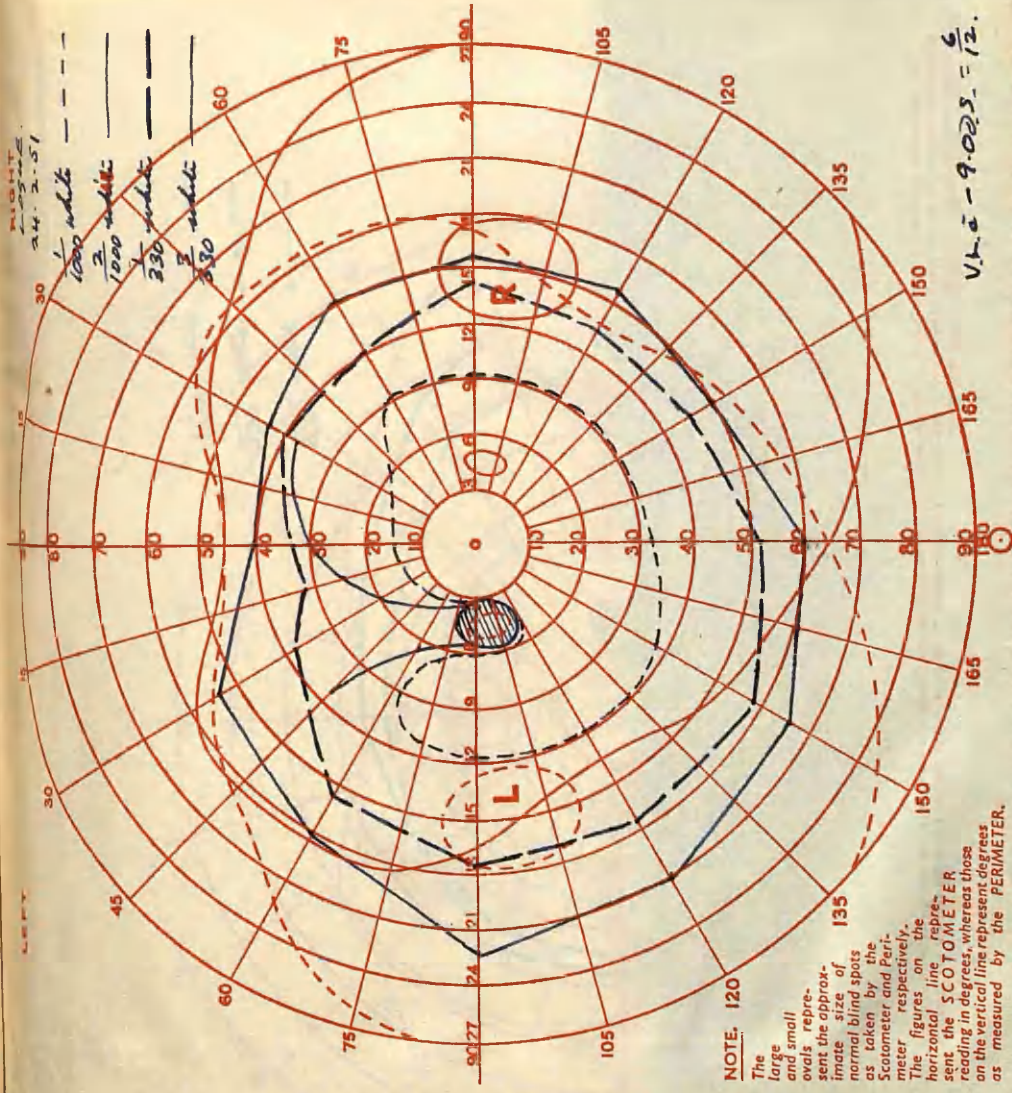
2 white NO DEFECT.



NOTE. 120

The large and small ovals represent the approximate size of normal blind spots as taken by the Scotometer and Perimeter respectively. The figures on the horizontal line represent the SCOTOMETER reading in degrees, whereas those on the vertical line represent degrees as measured by the PERIMETER.


V.L. E-9022 = $\frac{6}{12}$.



NOTE. 120
 The large and small ovals represent the approximate size of normal blind spots as taken by the Scotometer and Perimeter respectively. The figures on the horizontal line represent the SCOTOMETER reading in degrees, whereas those on the vertical line represent those as measured by the PERIMETER.

PERIMETER AND SCOTOMETER CHART.

THEODORE HAMBLIN LTD. LONDON. W. 1.




NOTE. 120
 The large and small ovals represent the approximate size of normal blind spots as taken by the Scotometer and Perimeter respectively. The figures on the horizontal line represent the SCOTOMETER reading in degrees, whereas those on the vertical line represent those as measured by the PERIMETER.

PERIMETER AND SCOTOMETER CHART.

THEODORE HAMBLIN LTD. LONDON. W. 1.

LONG



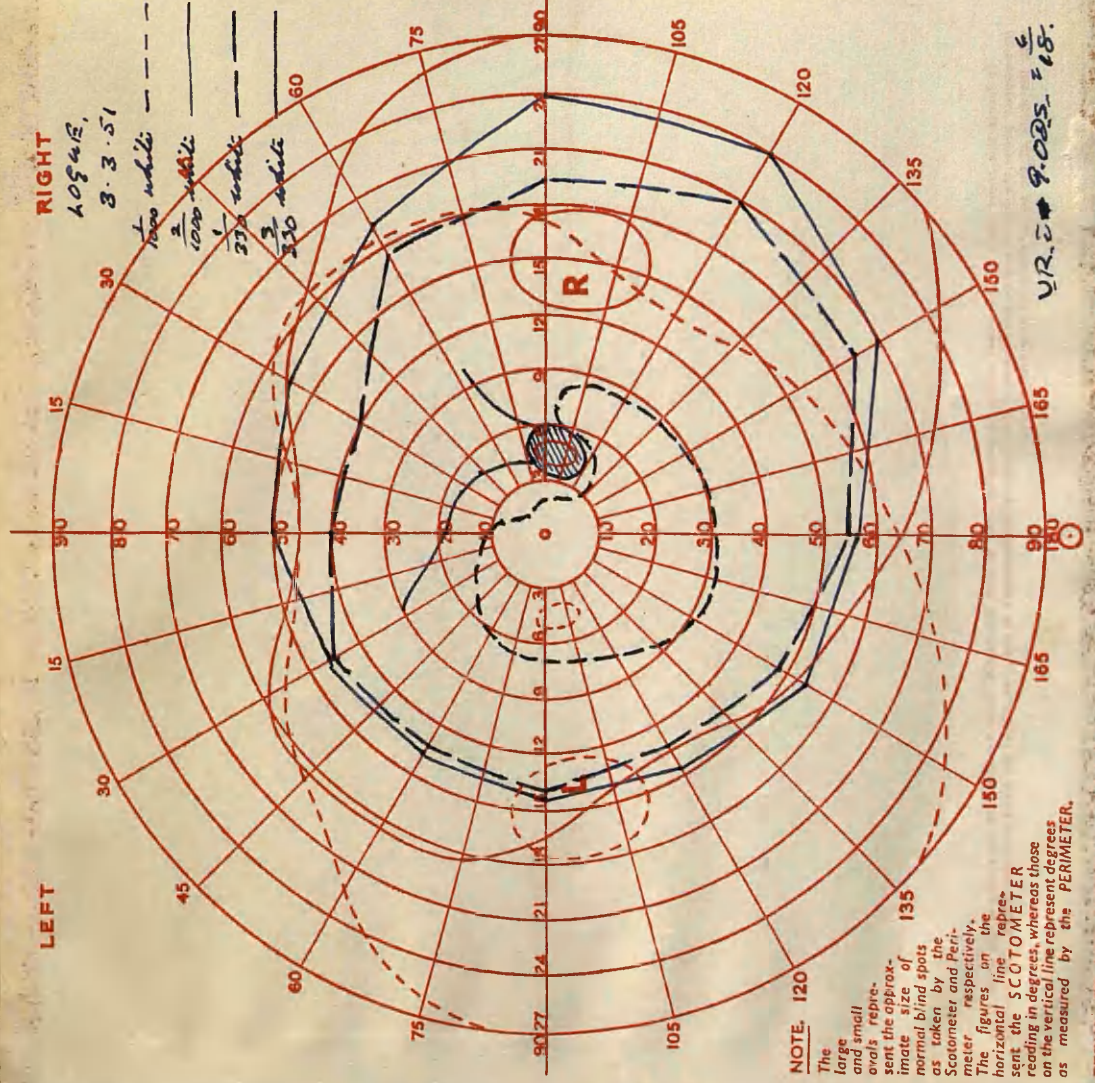
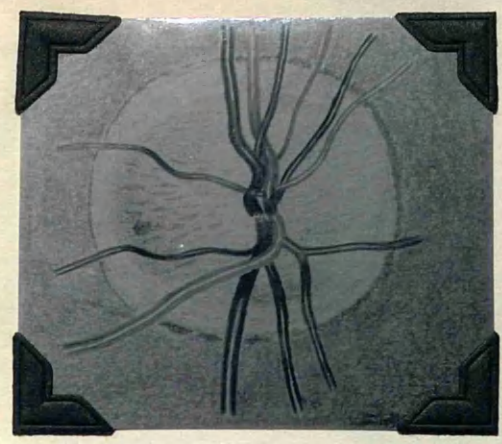
NOTE. 120
 The large and small ovals represent the approximate size of normal blind spots as taken by the Scotometer and Perimeter respectively. The figures on the horizontal line represent the SCOTOMETER reading in degrees, whereas those on the vertical line represent degrees as measured by the PERIMETER.

PERIMETER AND SCOTOMETER CHART.

THEODORE HAMBLIN LTD. LONDON, W.I.

VR. 2 - 9.025. = 18.

115



NOTE. 120
 The large and small ovals represent the approximate size of normal blind spots as taken by the Scotometer and Perimeter respectively. The figures on the horizontal line represent the SCOTOMETER reading in degrees, whereas those on the vertical line represent degrees as measured by the PERIMETER.

PERIMETER AND SCOTOMETER CHART.

THEODORE HAMBLIN LTD. LONDON, W.I.


VR. 2 - 9.025. = 18.

H, LEFT

RIGHT

LOGUE
31.3.51

$\frac{1}{1000}$ white ---
 $\frac{1}{330}$ white ---
 $\frac{3}{330}$ white ---



115

NOTE. 120

The large and small ovals represent the approximate size of normal blind spots as taken by the Scotometer and Perimeter respectively. The figures on the horizontal line represent the SCOTOMETER reading in degrees, whereas those on the vertical line represent degrees as measured by the PERIMETER.

Vh. E-9022 = $\frac{6}{18}$


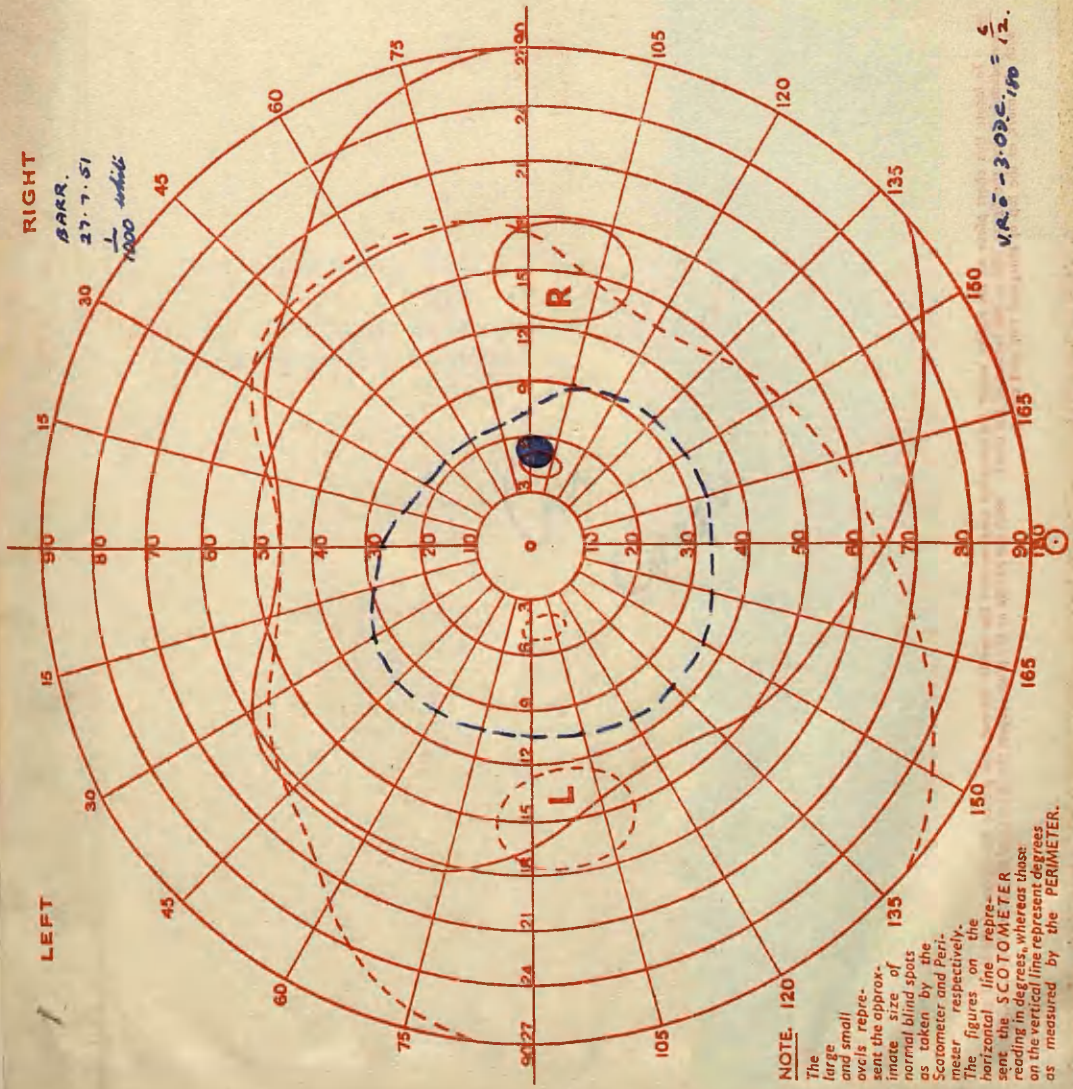
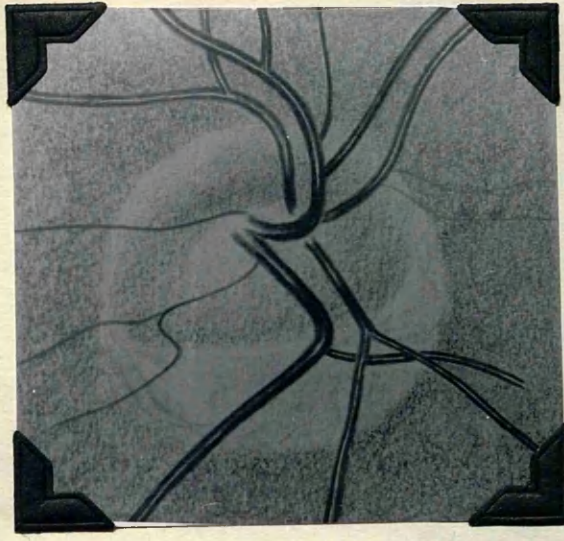
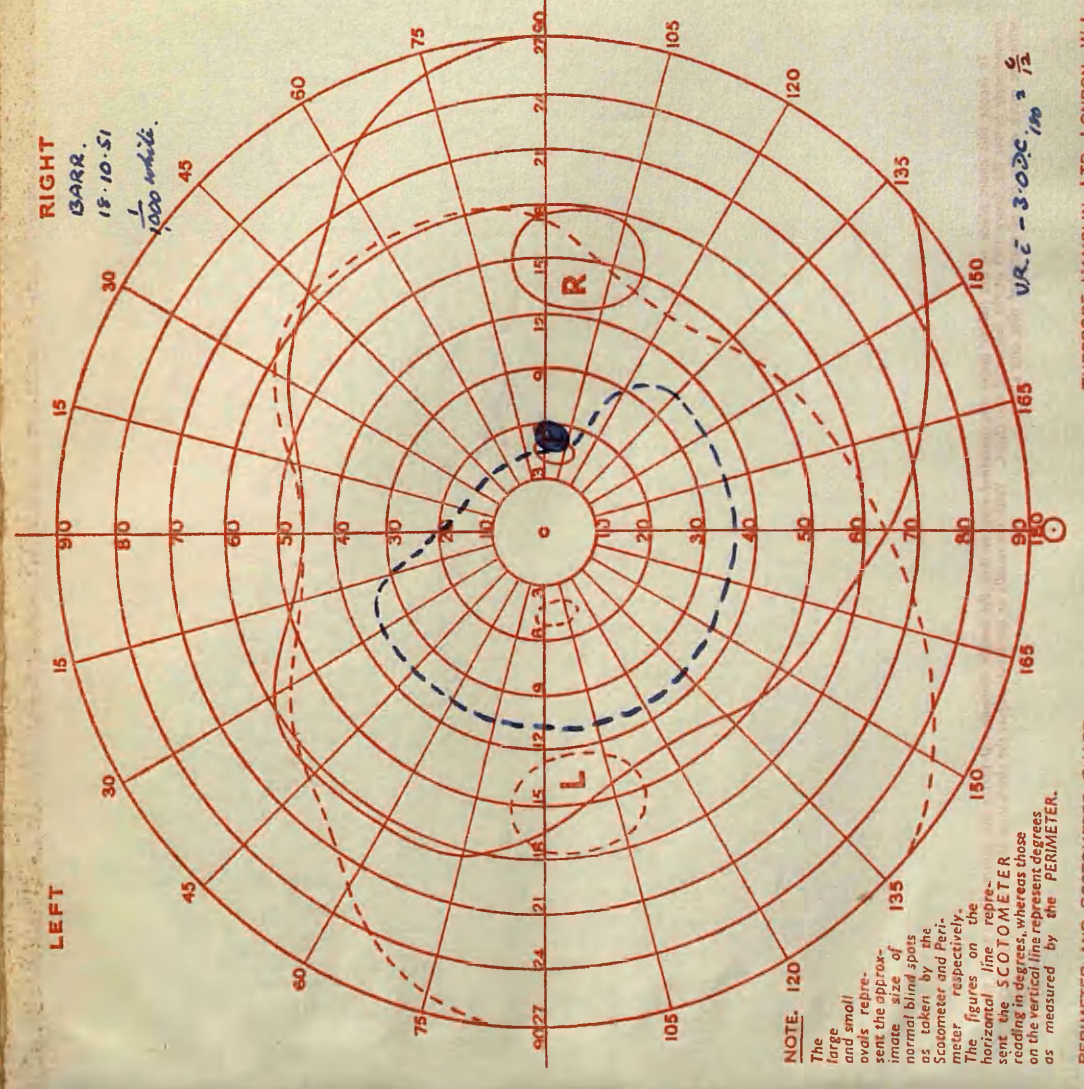


Fig. 87. J.B.; Male; Age 31; Refraction: R.E. -3.00 D.C. 180°. Right eye. Superior temporal contraction without evidence of sector. Compare the fundus appearances and the field changes with those of the figs. 88 and . They show some resemblance.

117



THEODORE HAMBLIN LTD. LONDON, W.1.

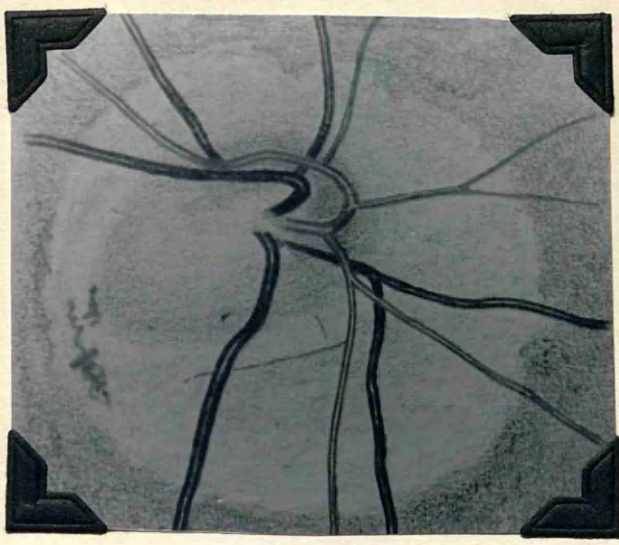


THEODORE HAMBLIN LTD. LONDON, W.1.



Fig. 88. E.B.; Female; Age 69; Refraction:
R.E. -3.00 D.S. with -1.50 D.C. 165°.
Right eye. Constant dense superior temporal defect with
considerable general depression.

119



RIGHT
BLINDON

28.3.51.

$\frac{1}{1000}$

$\frac{2}{1000}$

$\frac{1}{330}$

$\frac{2}{330}$

$\frac{3}{330}$

75

90

105

120

135

150

165

180

195

210

225

240

LEFT

10.1.12

30

45

60

75

90

105

120

135

150

165

180

195

210

225

240

NOTE. 120
The large and small ovals represent the approximate size of normal blind spots as taken by the Scotometer and Perimeter respectively. The figures on the horizontal line represent the SCOTOMETER reading in degrees, whereas those on the vertical line represent degrees as measured by the PERIMETER.

INF NASAL CRESC.

$-3.0 \pm$
 $-1.5 \pm$
 $\frac{6}{18}$

unchanged in six months

PERIMETER AND SCOTOMETER CHART.

THEODORE HAMBLIN LTD, LONDON, W.1.

9
24

119





Fig. 89. M.C.; Female; Age 40; Refraction: L.E. -5.00 D.S.
Left eye. Typical defect disappearing and reappearing.

RIGHT

LEFT



SUTHERLAND,
15.3.51
1000 white
300 white

NOTE. 120

The large and small ovals represent the approximate size of normal blind spots as taken by the Scotometer and Perimeter respectively. The figures on the horizontal line represent the SCOTOMETER reading in degrees, whereas those on the vertical line represent degrees as measured by the PERIMETER.

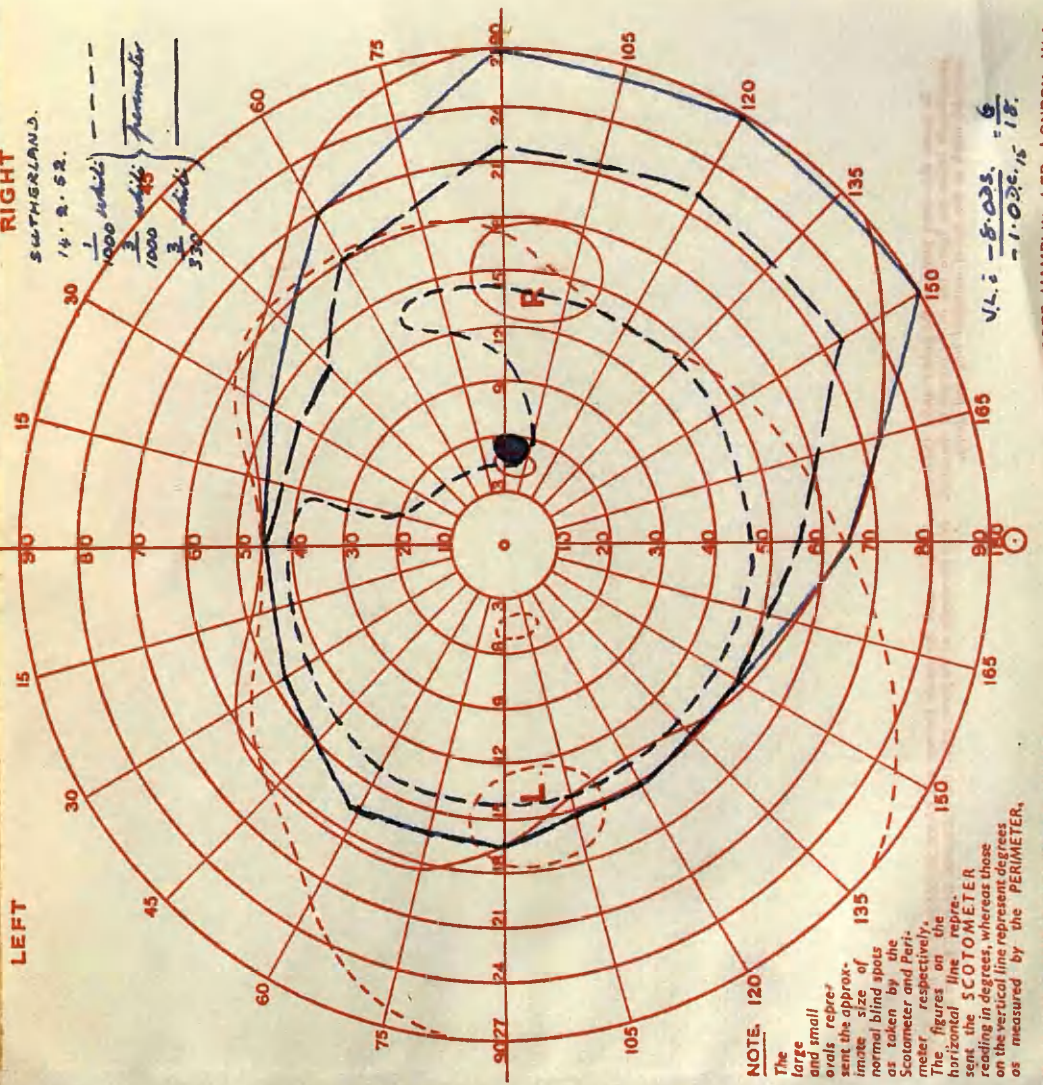
$$V.R. = \frac{8.025}{1.025 \times 18} = \frac{6}{18}$$

PERIMETER AND SCOTOMETER CHART.

THEODORE HAMBLIN LTD. LONDON, W.1.

RIGHT

LEFT



SUTHERLAND,
14.3.52.
1000 white
300 white
Perimeter

NOTE. 120

The large and small ovals represent the approximate size of normal blind spots as taken by the Scotometer and Perimeter respectively. The figures on the horizontal line represent the SCOTOMETER reading in degrees, whereas those on the vertical line represent degrees as measured by the PERIMETER.

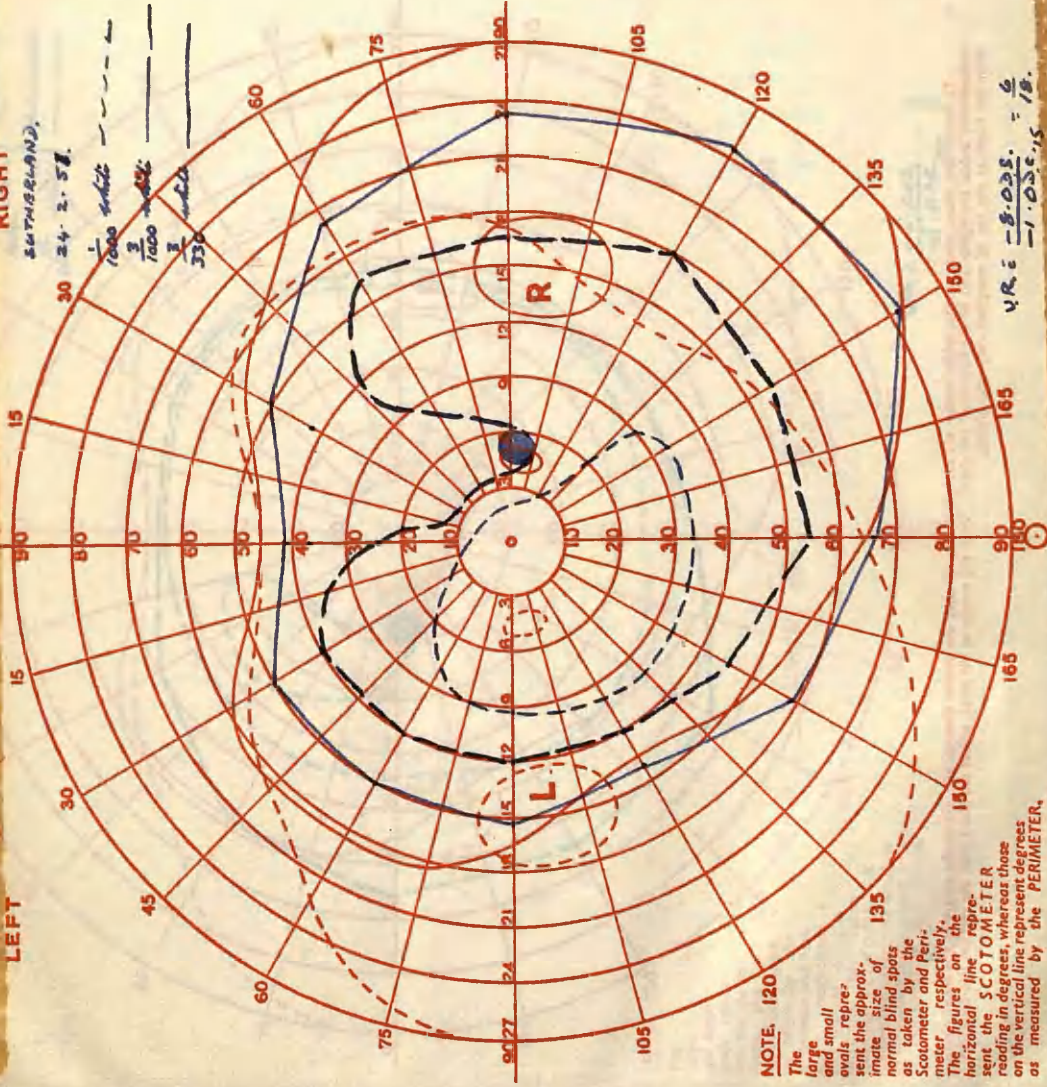
$$V.L. = \frac{8.025}{1.025 \times 18} = \frac{6}{18}$$

PERIMETER AND SCOTOMETER CHART.

THEODORE HAMBLIN LTD. LONDON, W.1.

LEFT

RIGHT

NOTE. 120


The large and small ovals represent the approximate size of normal blind spots as taken by the Scotometer and Perimeter respectively. The figures on the horizontal line represent the SCOTOMETER reading in degrees, whereas those on the vertical line represent degrees as measured by the PERIMETER.

PERIMETER AND SCOTOMETER CHART.

THEODORE HAMBLIN LTD. LONDON, W.1.

LEFT

RIGHT

NOTE. 120

The large and small ovals represent the approximate size of normal blind spots as taken by the Scotometer and Perimeter respectively. The figures on the horizontal line represent the SCOTOMETER reading in degrees, whereas those on the vertical line represent degrees as measured by the PERIMETER.

PERIMETER AND SCOTOMETER CHART.

THEODORE HAMBLIN LTD. LONDON, W.1.

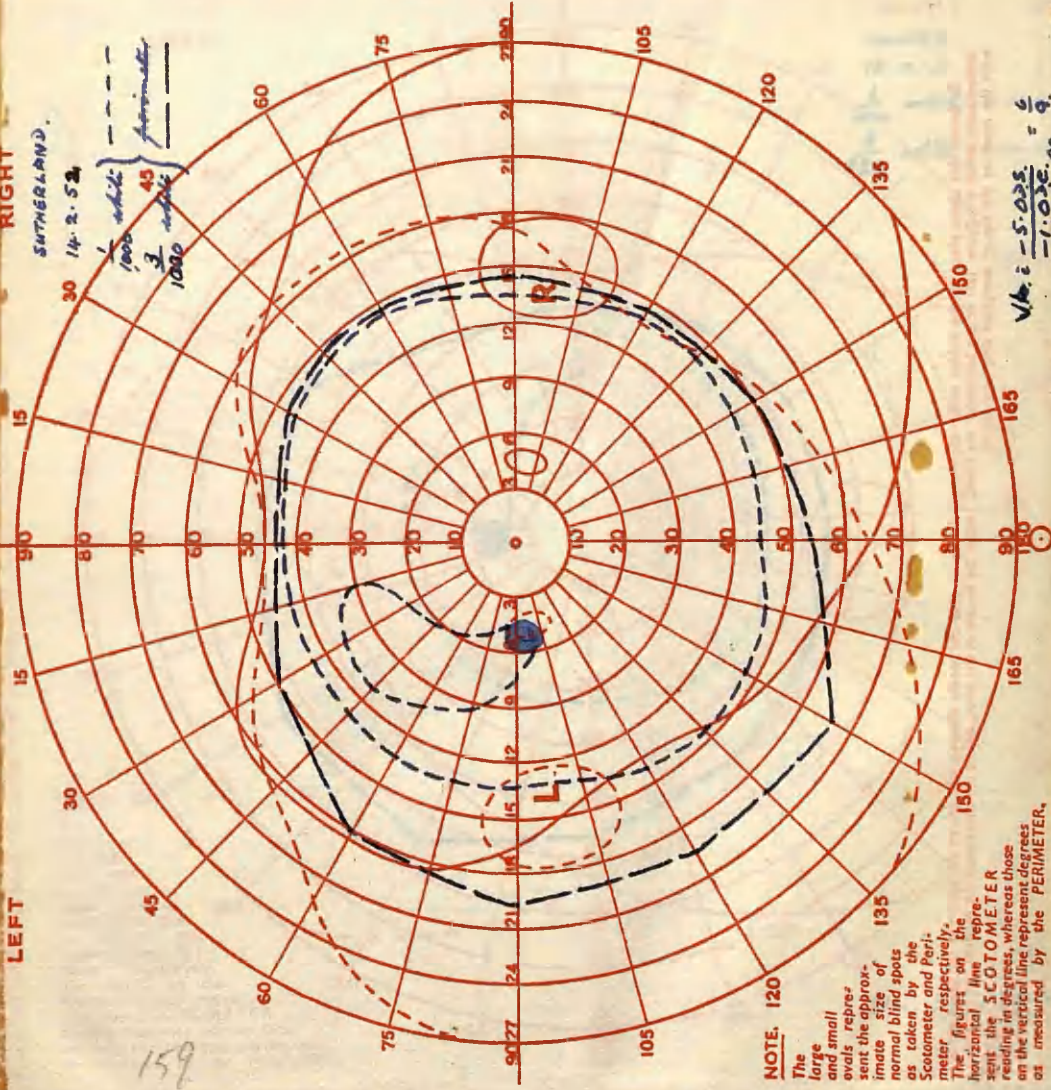
LEFT

RIGHT

SUTHERLAND.

14.2.52

$\frac{1}{1000}$ white } Perimeter
 $\frac{45}{3}$ white }
 1000

**NOTE.** 120

The large and small ovals represent the approximate size of normal blind spots as taken by the Scotometer and Perimeter respectively. The figures on the horizontal line represent the SCOTOMETER angle in degrees, whereas those on the vertical line represent degrees as measured by the PERIMETER.

$$V.M. = \frac{-5.03E}{-1.03E \cdot 90} = \frac{5}{9}$$

159

LEFT

RIGHT

29.

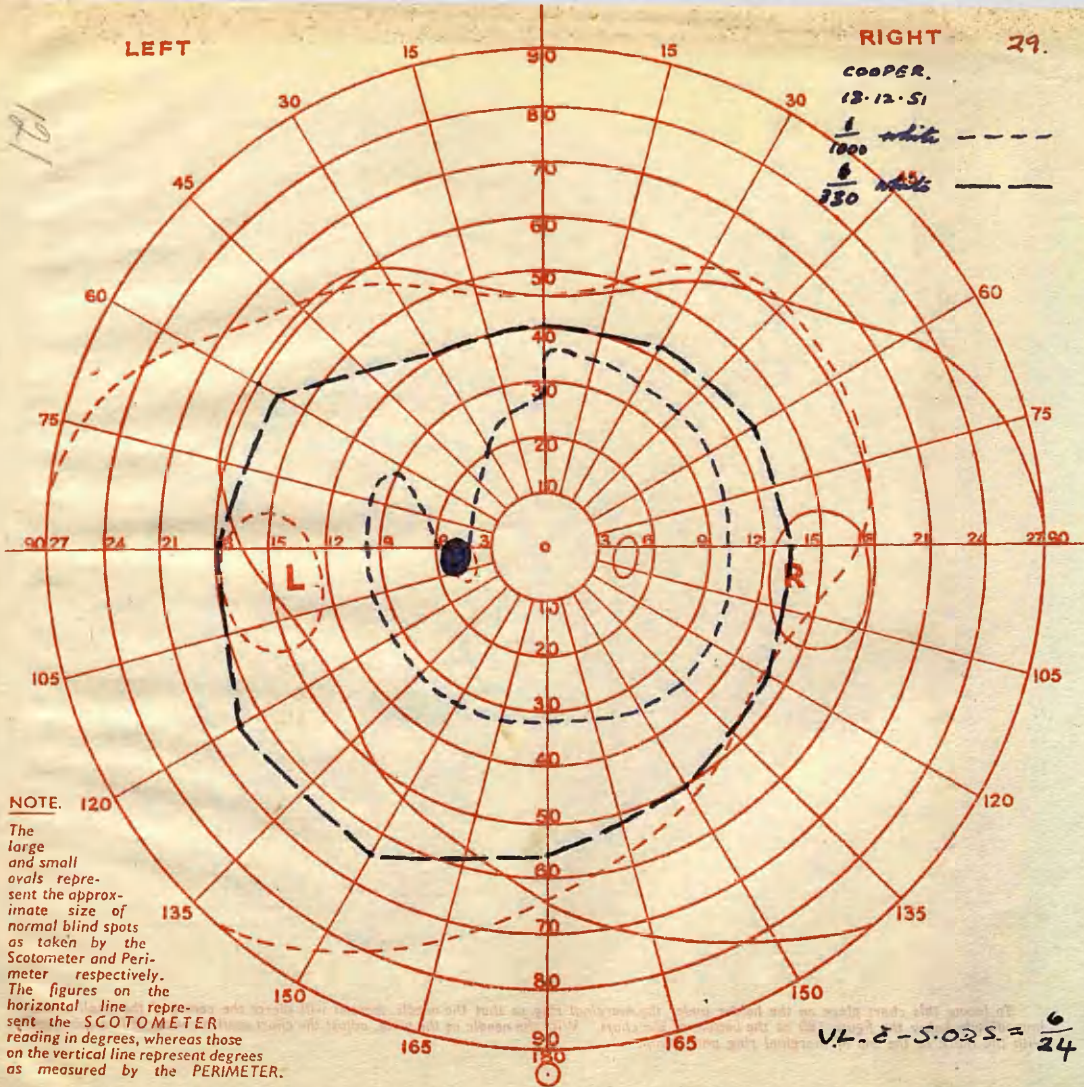
COOPER.

13-12-51

$\frac{1}{1000}$ white - - - - -

$\frac{6}{350}$ white - - - - -

121



NOTE. 120

The large and small ovals represent the approximate size of normal blind spots as taken by the Scotometer and Perimeter respectively. The figures on the horizontal line represent the SCOTOMETER reading in degrees, whereas those on the vertical line represent degrees as measured by the PERIMETER.

V.L.-S-O.R.S. = $\frac{6}{24}$

RIGHT

LEFT

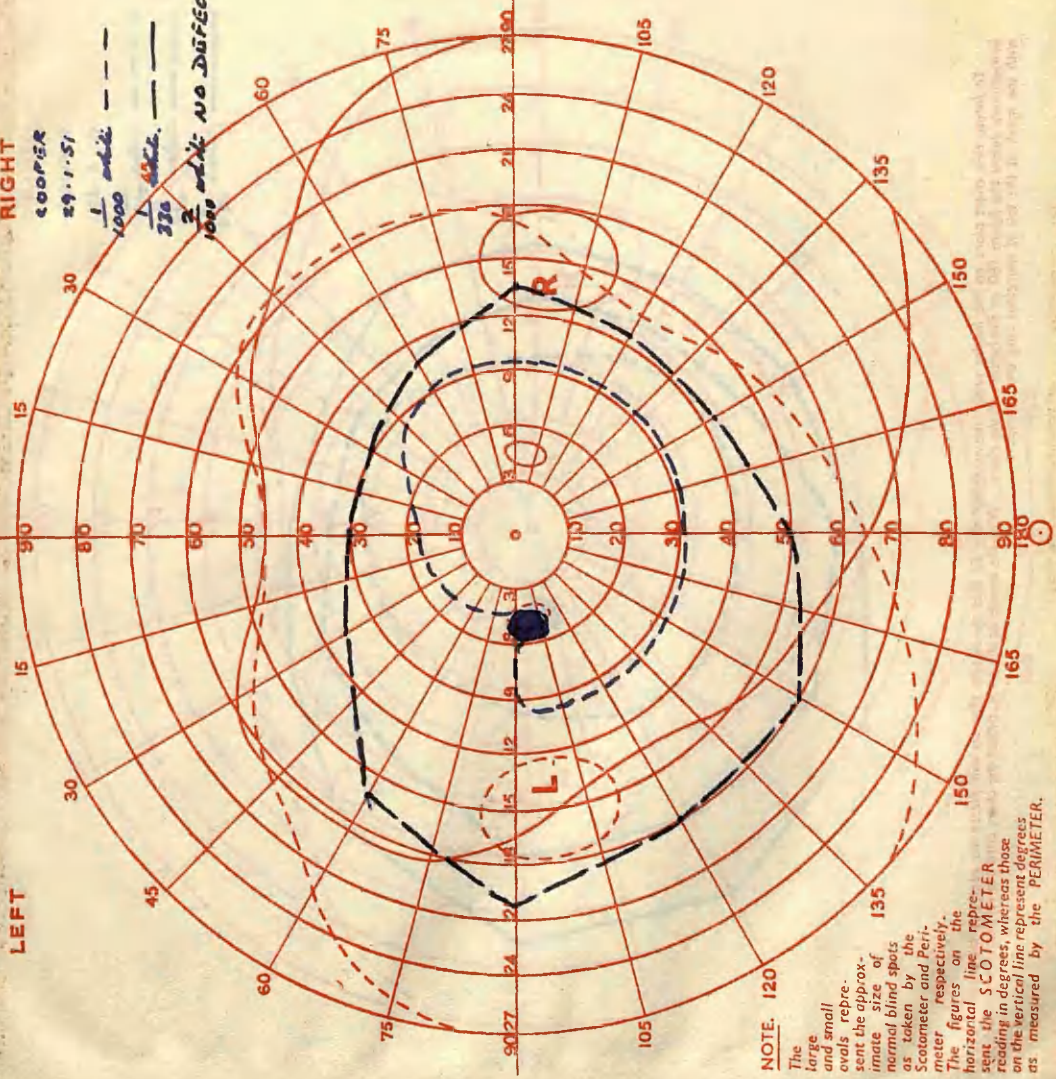
COOPER

29.1-51

$\frac{1}{1000}$ mile

$\frac{1}{330}$ mile

2 mile NO DEFECT.



NOTE. 120

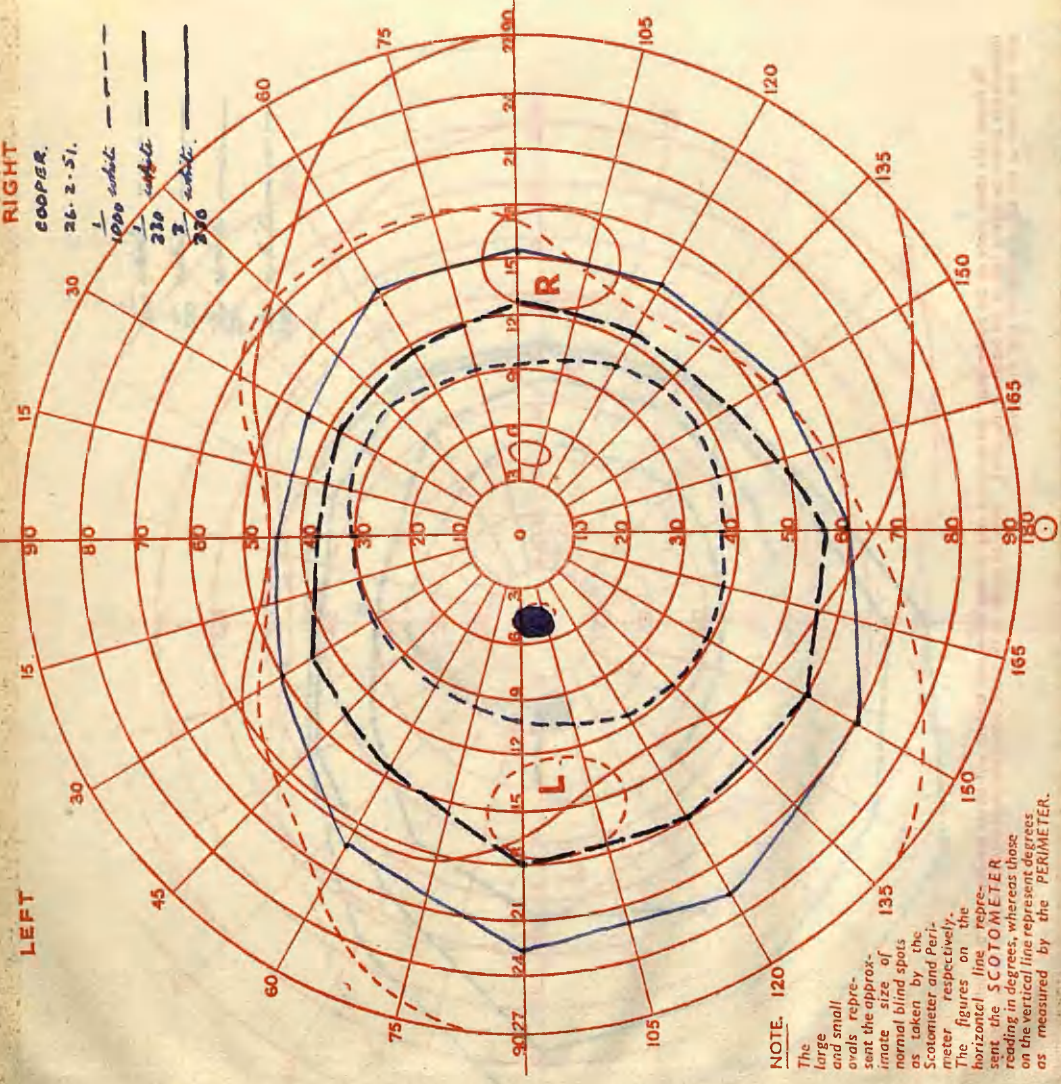
The large and small ovals represent the approximate size of normal blind spots taken by the Scotometer and Perimeter respectively. The figures on the horizontal line represent the SCOTOMETER reading in degrees, whereas those on the vertical line represent degrees as measured by the PERIMETER.

PERIMETER AND SCOTOMETER CHART.

THEODORE HAMBLIN LTD. LONDON, W. 1.

RIGHT
COOPER.
26. 2. 51.

$\frac{1}{1000}$ white
 $\frac{1}{220}$ white
 $\frac{1}{270}$ white



NOTE. 120

The large and small ovals represent the approximate size of normal blind spots as taken by the Scotometer and Perimeter respectively. The figures on the horizontal line represent the SCOTOMETER reading in degrees, whereas those on the vertical line represent degrees as measured by the PERIMETER.

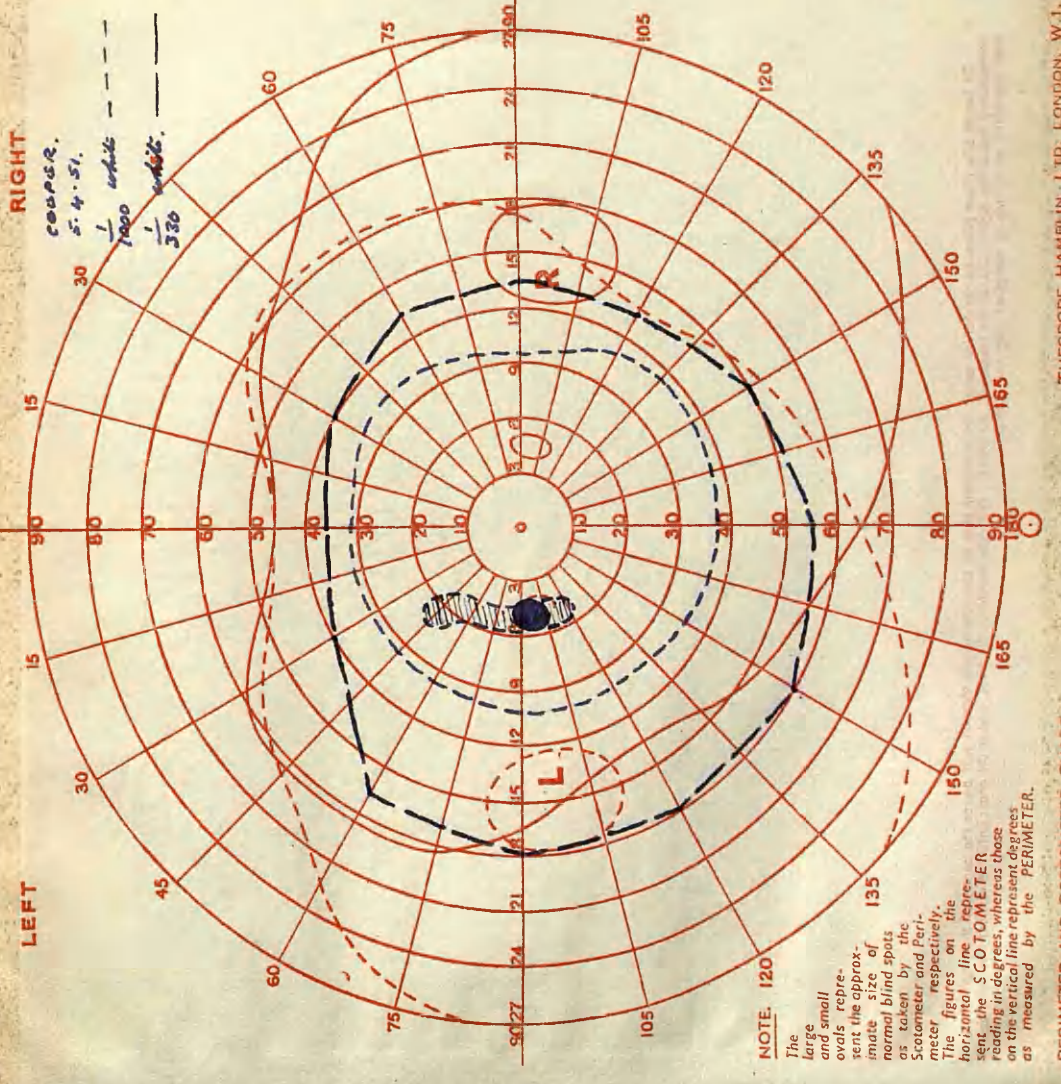
PERIMETER AND SCOTOMETER CHART.

THEODORE HAMBLIN LTD. LONDON, W. 1.

LEFT

RIGHT
COOPER.
5. 4. 51.

$\frac{1}{1000}$ white
 $\frac{1}{220}$ white



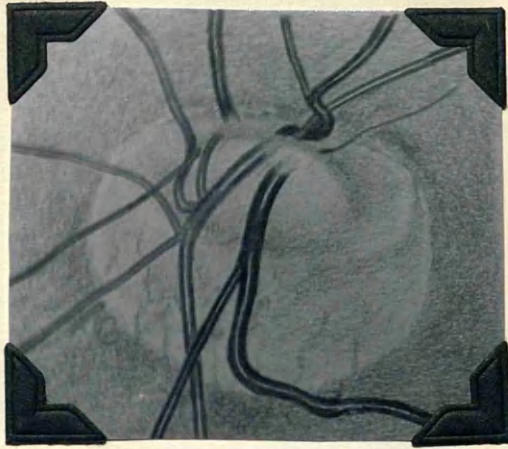
NOTE. 120

The large and small ovals represent the approximate size of normal blind spots as taken by the Scotometer and Perimeter respectively. The figures on the horizontal line represent the SCOTOMETER reading in degrees, whereas those on the vertical line represent degrees as measured by the PERIMETER.

PERIMETER AND SCOTOMETER CHART.


THEODORE HAMBLIN LTD. LONDON, W. 1.

LEFT



RIGHT
COOPER.
23-1-51

1/100 white ---
1/120 white ---
2/170 white ---
3/200 white ---



$$V.L.C. - \frac{5.0DS}{24} = \frac{6}{24}$$

13, LEFT 2

NOTE 120
The large and small ovals represent the approximate size of normal blind spots as taken by the Scotometer and Perimeter respectively. The figures on the horizontal line represent the SCOTOMETER reading in degrees, whereas those on the vertical line represent degrees as measured by the PERIMETER.

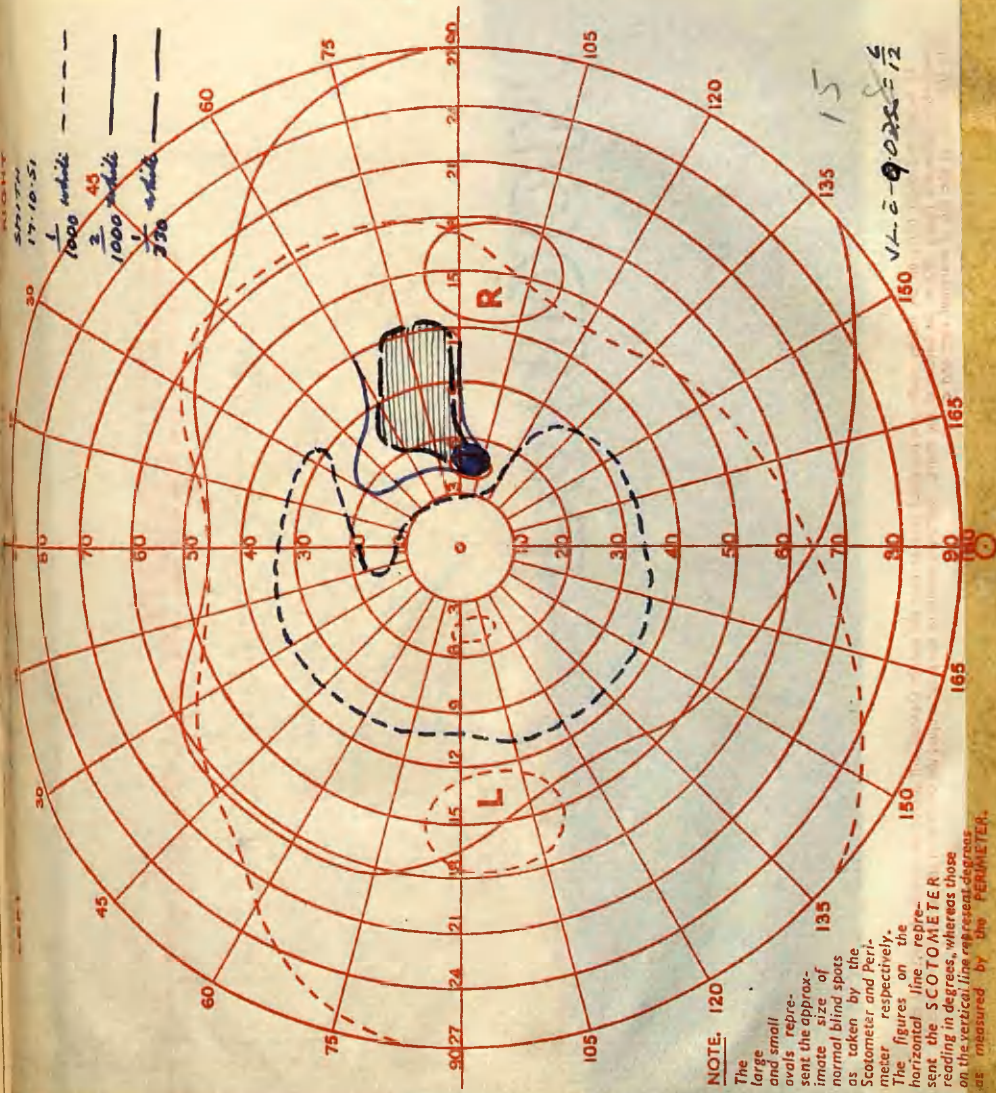
Fig. 90. J.S.; Male; Age 44; Refraction: R.E. -9.00 D.S.
L.E. -9.00 D.S.

Right eye. Typical field defect with typical changes on repeated examination.

Left eye. Similar to right eye.

Note that the field defect in each eye behaves independently in this case.

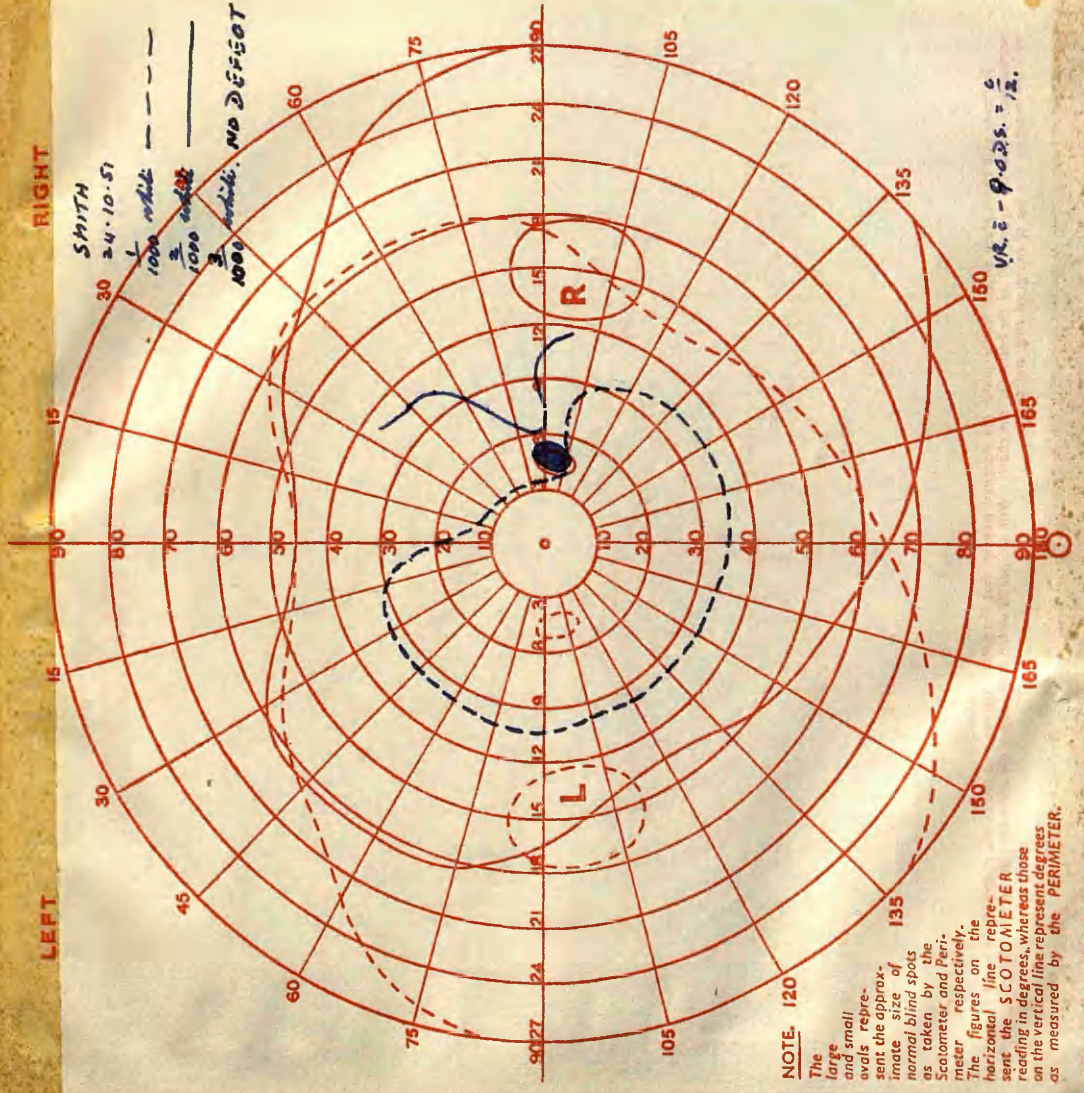
The appearances of the fundus were similar in the two eyes.



NOTE. 120
The large and small ovals represent the approximate size of normal blind spots as taken by the Scotometer and Perimeter respectively. The figures on the horizontal line represent the SCOTOMETER reading in degrees, whereas those on the vertical line represent degrees as measured by the PERIMETER.

PERIMETER AND SCOTOMETER CHART.

THEODORE HAMBLIN LTD. LONDON, W. 1.




NOTE. 120
The large and small ovals represent the approximate size of normal blind spots as taken by the Scotometer and Perimeter respectively. The figures on the horizontal line represent the SCOTOMETER reading in degrees, whereas those on the vertical line represent degrees as measured by the PERIMETER.

PERIMETER AND SCOTOMETER CHART.

THEODORE HAMBLIN LTD. LONDON, W. 1.

LEFT

RIGHT

**NOTE. 120**

The large and small ovals represent the approximate size of normal blind spots taken by the Scotometer and Perimeter respectively.

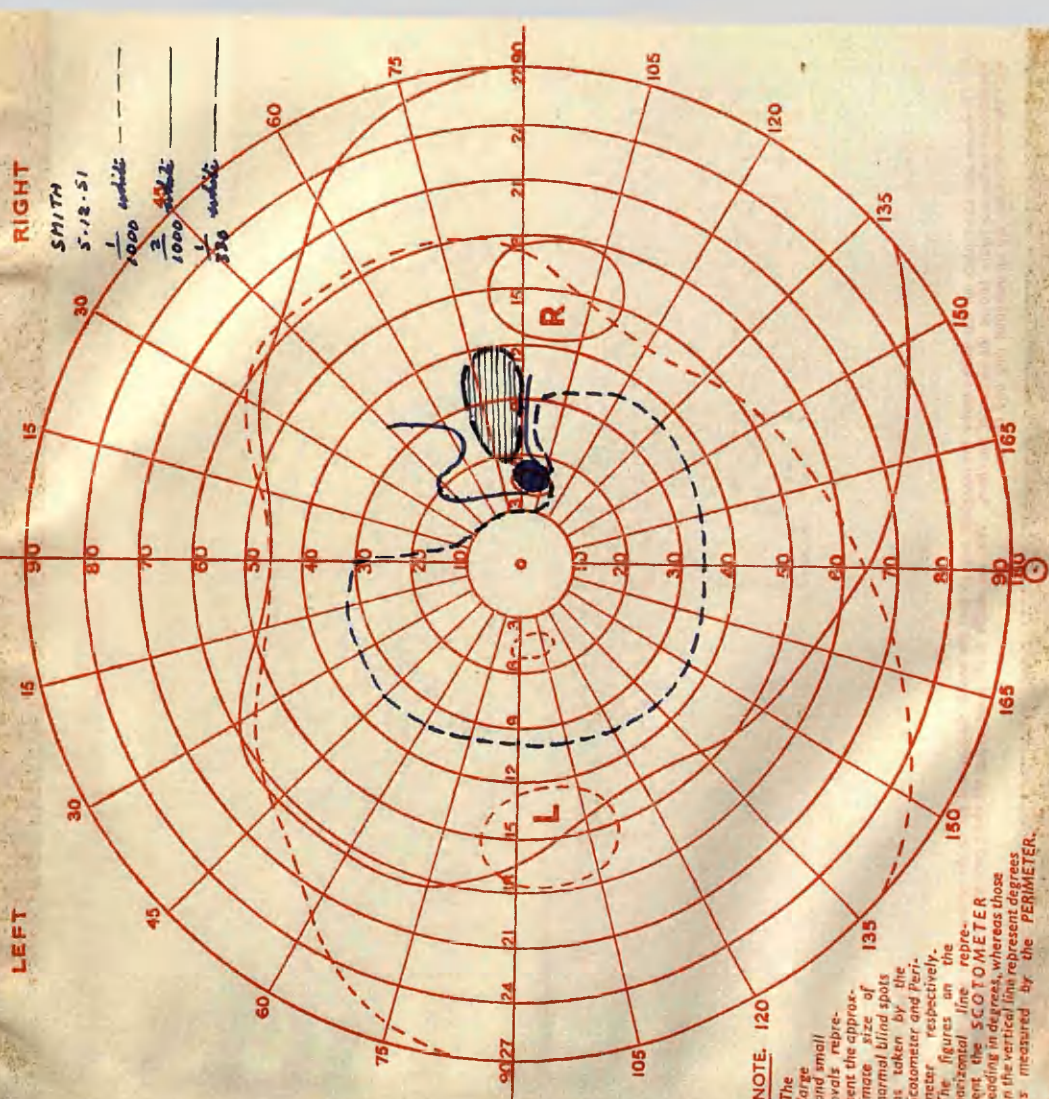
The figures on the horizontal line represent the SCOTOMETER reading in degrees, whereas those on the vertical line represent degrees as measured by the PERIMETER.

PERIMETER AND SCOTOMETER CHART.

THEODORE HAMBLIN LTD. LONDON, W.1.

LEFT

RIGHT

**NOTE. 120**

The large and small ovals represent the approximate size of normal blind spots taken by the Scotometer and Perimeter respectively.


The figures on the horizontal line represent the SCOTOMETER reading in degrees, whereas those on the vertical line represent degrees as measured by the PERIMETER.

PERIMETER AND SCOTOMETER CHART.

THEODORE HAMBLIN LTD. LONDON, W.1.

LEFT

RIGHT



NOTE. 120

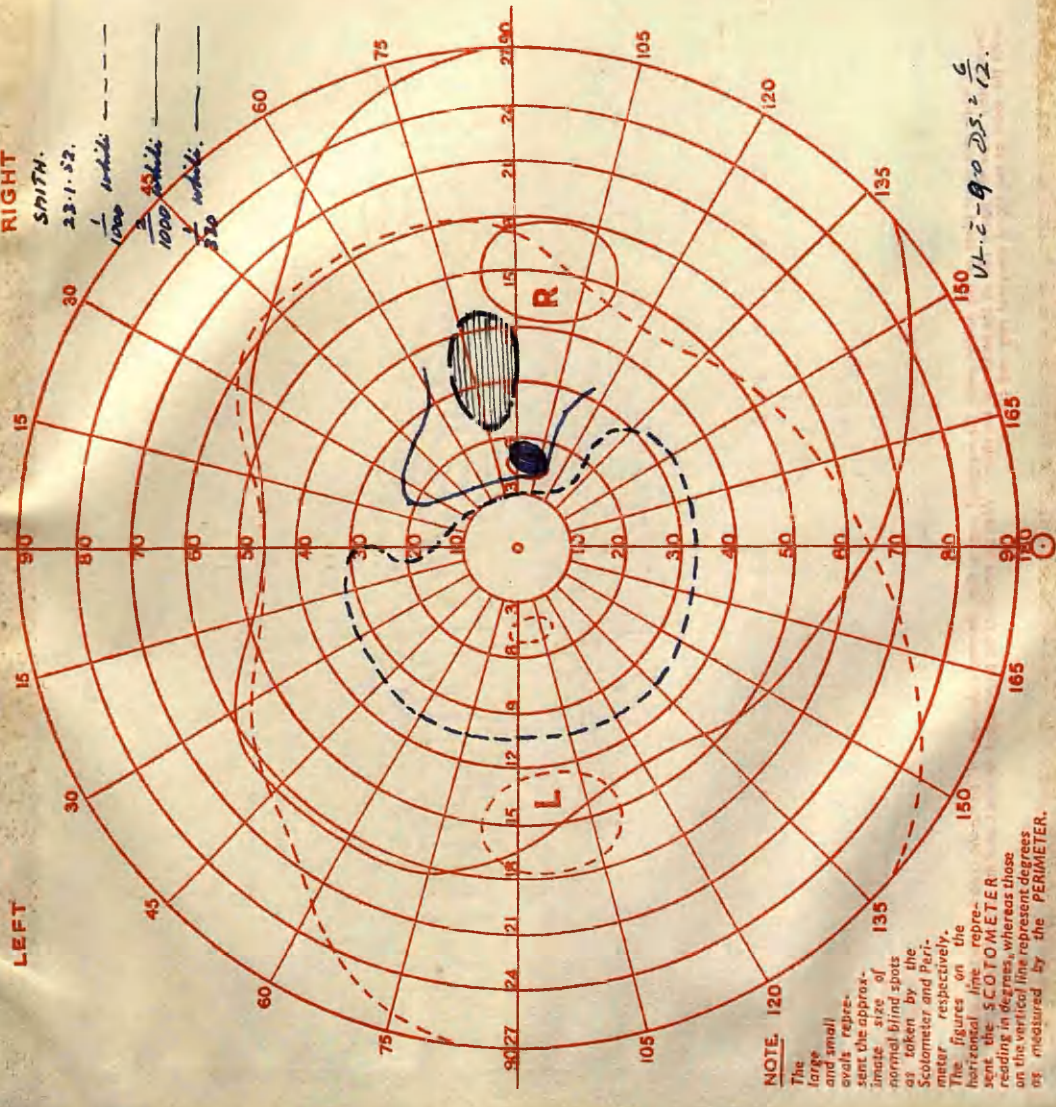
The large and small ovals represent the approximate size of normal blind spots as taken by the Scotometer and Perimeter respectively. The figures on the horizontal line represent the SCOTOMETER reading in degrees, whereas those on the vertical line represent degrees as measured by the PERIMETER.

PERIMETER AND SCOTOMETER CHART.

THEODORE HAMBLIN LTD. LONDON, W.1.

LEFT

RIGHT



NOTE. 120

The large and small ovals represent the approximate size of normal blind spots as taken by the Scotometer and Perimeter respectively. The figures on the horizontal line represent the SCOTOMETER reading in degrees, whereas those on the vertical line represent degrees as measured by the PERIMETER.

PERIMETER AND SCOTOMETER CHART.

THEODORE HAMBLIN LTD. LONDON, W.1.


LEFT

RIGHT

SMITH
19-3-52.

1000 white } perimeter
2000 white }

123




NOTE. 120

The large and small ovals represent the approximate size of normal blind spots as taken by the Scotometer and Perimeter respectively. The figures on the horizontal line represent the SCOTOMETER reading in degrees, whereas those on the vertical line represent degrees as measured by the PERIMETER.

LEFT

RIGHT



SMITH.
24.10.51.
1000 white
45/1000 white
NO DEFECT

$U.L. \bar{c} - 9.025 = \frac{6}{12}$

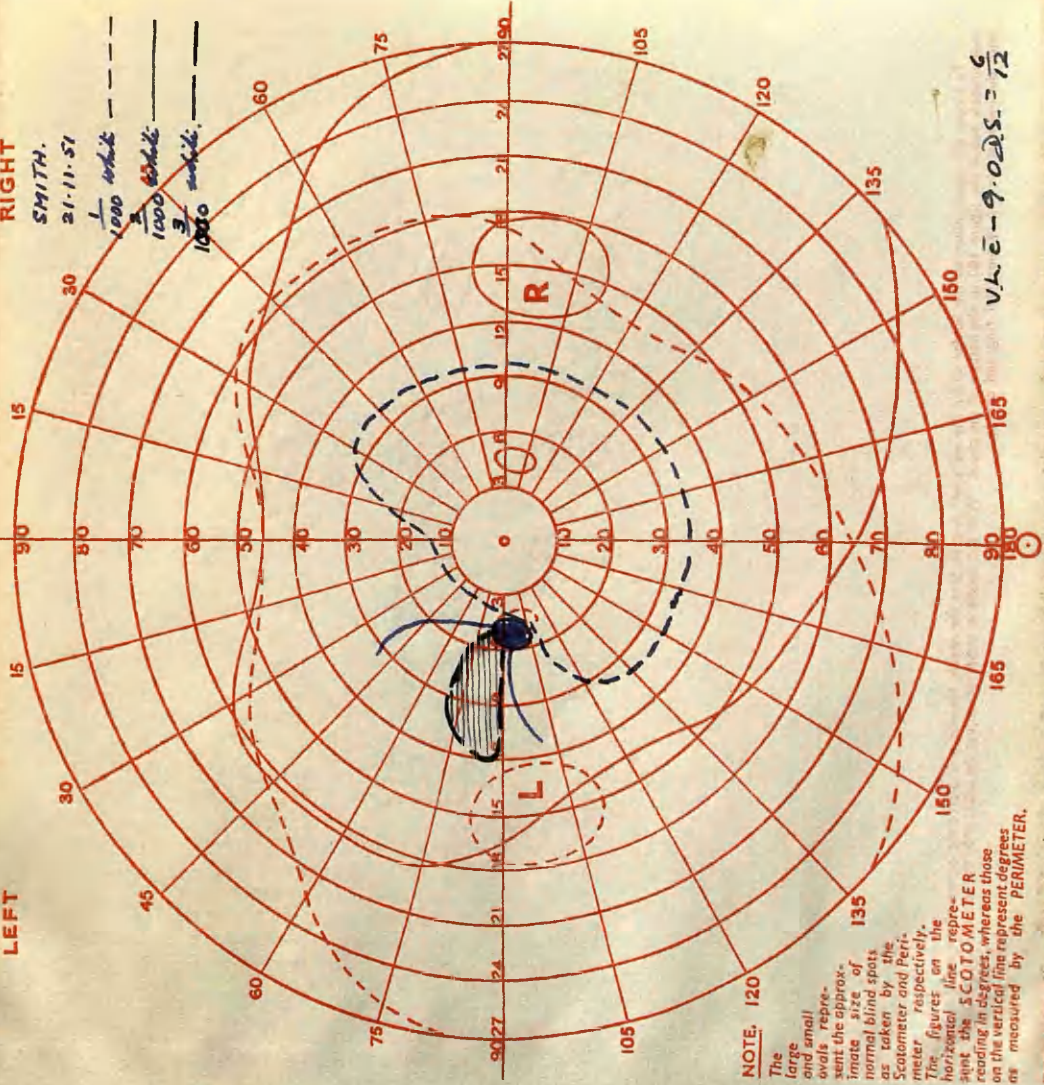
NOTE. 120
The large and small ovals represent approximate size of normal blind spots as taken by the Scotometer and Perimeter respectively. The figures on the horizontal line represent the SCOTOMETER reading in degrees, whereas those on the vertical line represent degrees as measured by the PERIMETER.

PERIMETER AND SCOTOMETER CHART.

THEODORE HAMBLIN LTD. LONDON, W.1.

LEFT

RIGHT



SMITH.
21.11.51.
1000 white
45/1000 white
NO DEFECT

$U.L. \bar{c} - 9.025 = \frac{6}{12}$

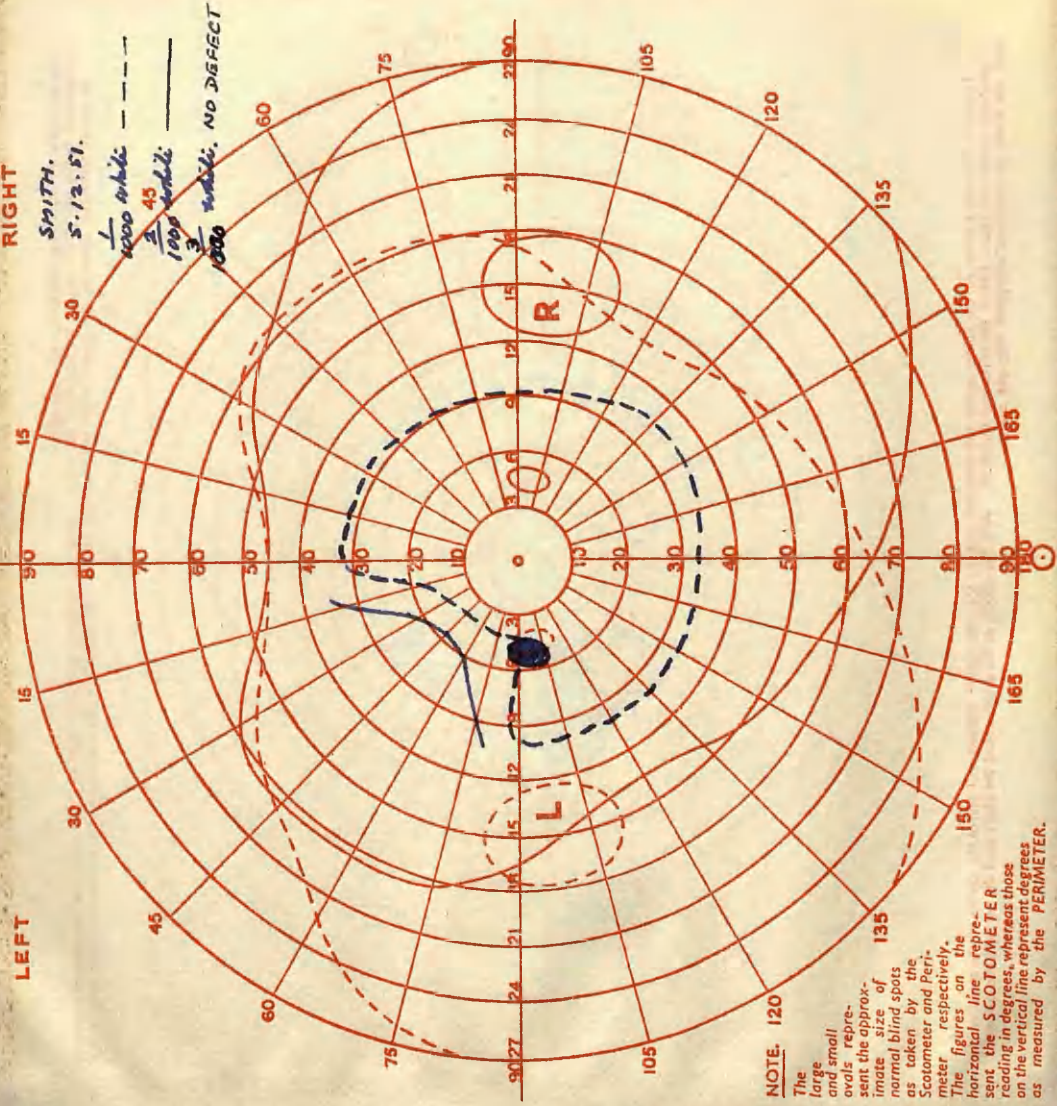
NOTE. 120
The large and small ovals represent approximate size of normal blind spots as taken by the Scotometer and Perimeter respectively. The figures on the horizontal line represent the SCOTOMETER reading in degrees, whereas those on the vertical line represent degrees as measured by the PERIMETER.

PERIMETER AND SCOTOMETER CHART.

THEODORE HAMBLIN LTD. LONDON, W.1.

LEFT

RIGHT

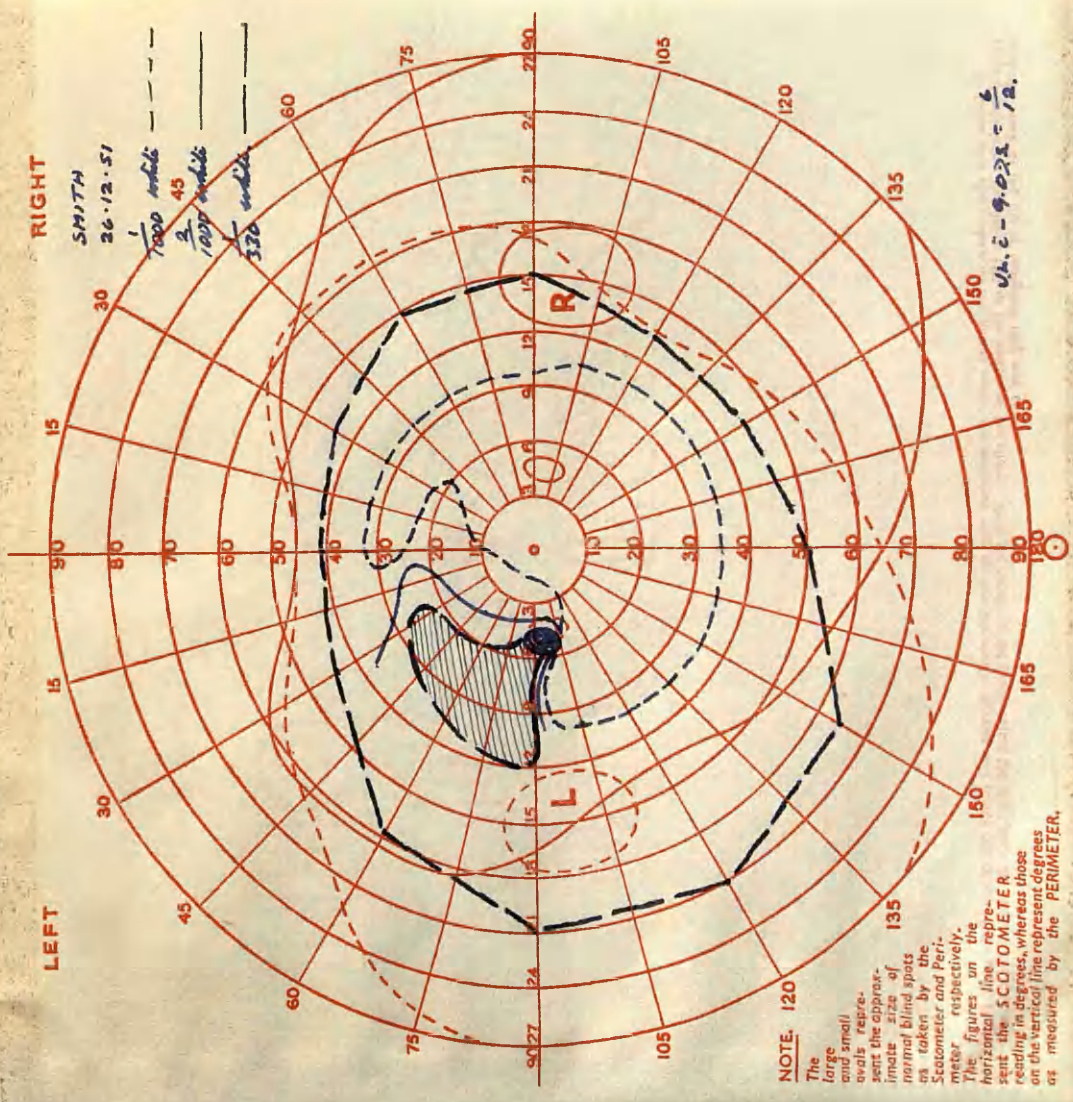


PERIMETER AND SCOTOMETER CHART.

THEODORE HAMBLIN LTD. LONDON, W.1.

LEFT

RIGHT



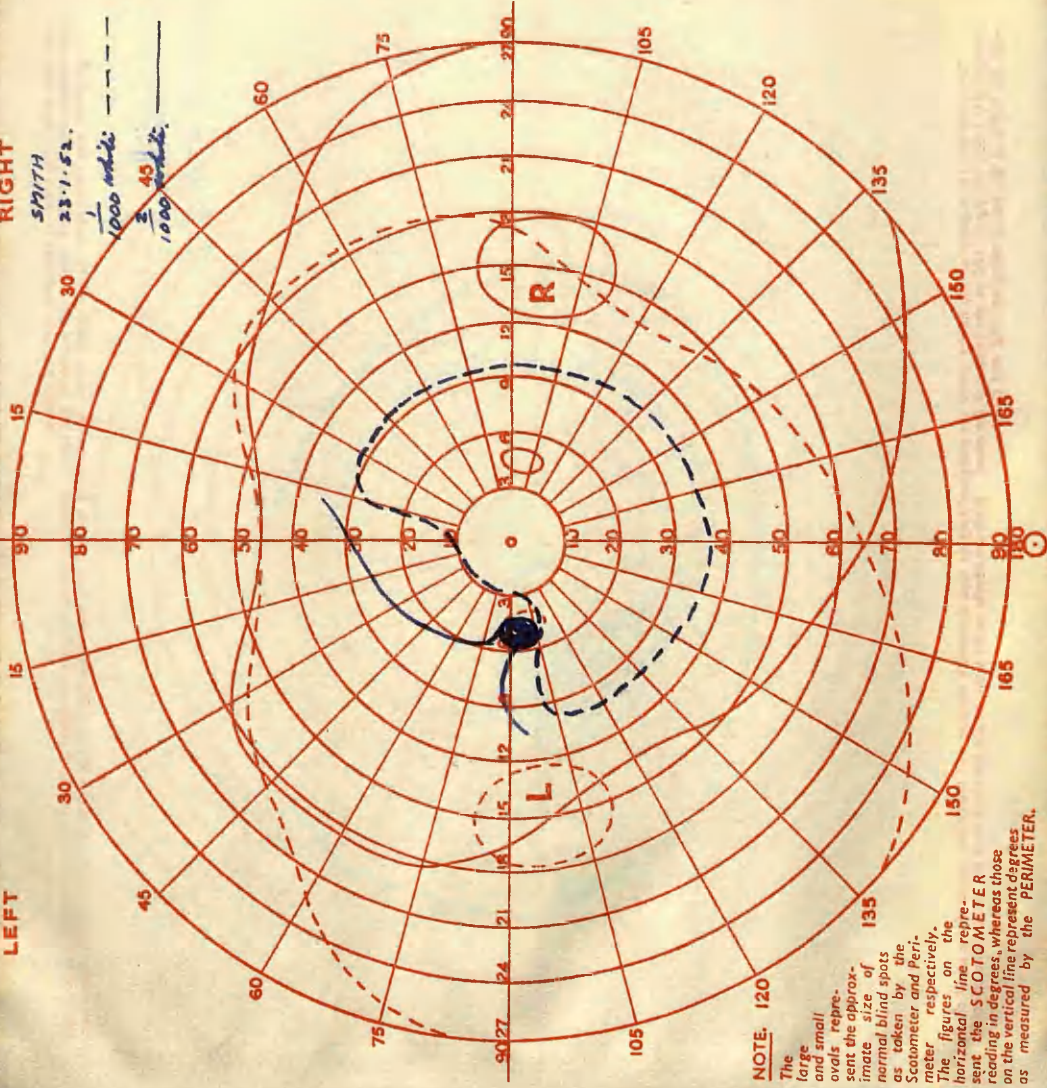
PERIMETER AND SCOTOMETER CHART.

THEODORE HAMBLIN LTD. LONDON, W.1.

$$\frac{1000}{3} = 330 \text{ white} = \frac{6}{12}$$

LEFT

RIGHT



NOTE. 120

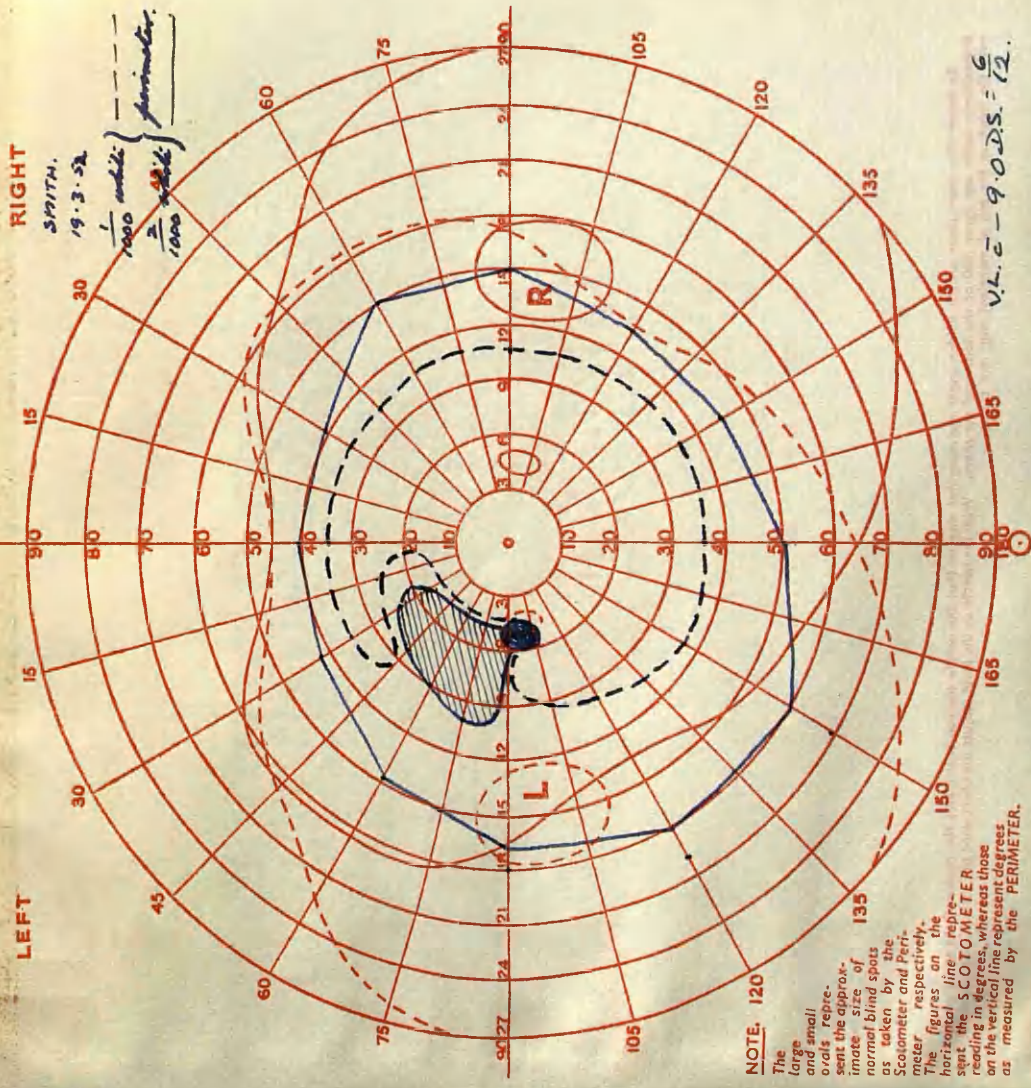
The large and small ovals represent the approximate size of normal blind spots as taken by the Scotometer and Perimeter respectively. The figures on the horizontal line represent the SCOTOMETER reading in degrees, whereas those on the vertical line represent degrees as measured by the PERIMETER.

PERIMETER AND SCOTOMETER CHART.

THEODORE HAMBLIN LTD. LONDON, W.1.

LEFT

RIGHT




NOTE. 120

The large and small ovals represent the approximate size of normal blind spots as taken by the Scotometer and Perimeter respectively. The figures on the horizontal line represent the SCOTOMETER reading in degrees, whereas those on the vertical line represent degrees as measured by the PERIMETER.


PERIMETER AND SCOTOMETER CHART.

THEODORE HAMBLIN LTD. LONDON, W.1.

123



To locate this chart place on the holder under the marginal ring so that the needle thereon will pierce the centre of the small circle immediately below the figure 180 at the bottom of the chart. With the needle as the pivot, adjust the chart until the vertical line coincides with the mark at the top of marginal ring and clamp.






Fig. 91. N.P.; Female; Age 12; Refraction: L.E. -9.00 D.S.
Left eye. Incomplete sector which is relatively constant
in child of school age. The defect is separated from the
blind spot and extends into the superior nasal quadrant.


8, 16, 3, 12

RIGHT

NDRMA PROVAN

25°-10-51

1080 white
1000 horizon



NOTE. 120

The large and small ovals represent the approximate size of normal blind spots as taken by the Scotometer and Perimeter, respectively. The figures on the horizontal line represent the SCOTOMETER reading in degrees, whereas those on the vertical line represent degrees as measured by the PERIMETER.

8, 16, 3
V.L.E.-

PERIMETER AND SCOTOMETER CHART

THEODORE HAMBLIK LTD. LONDON, W.1.

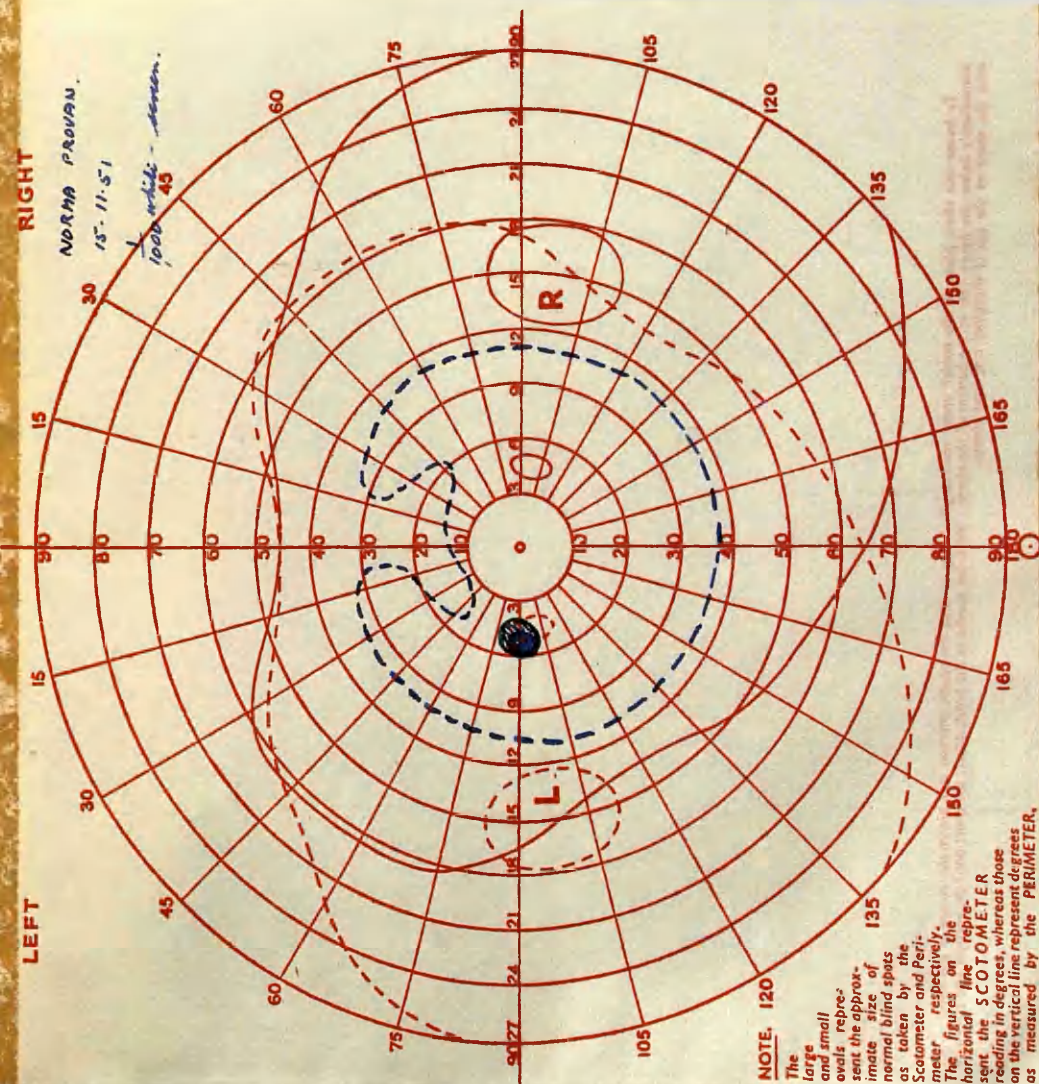
LEFT

RIGHT

NDRMA PROVAN

15°-11-51

1000 white - horizon
45



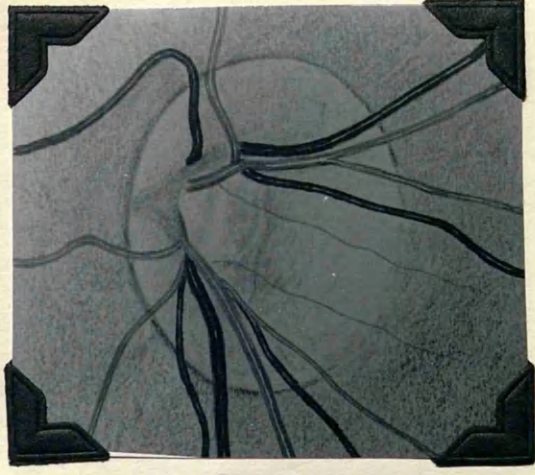
NOTE. 120

The large and small ovals represent the approximate size of normal blind spots as taken by the Scotometer and Perimeter, respectively. The figures on the horizontal line represent the SCOTOMETER reading in degrees, whereas those on the vertical line represent degrees as measured by the PERIMETER.

PERIMETER AND SCOTOMETER CHART

THEODORE HAMBLIK

LONDON, W.1.

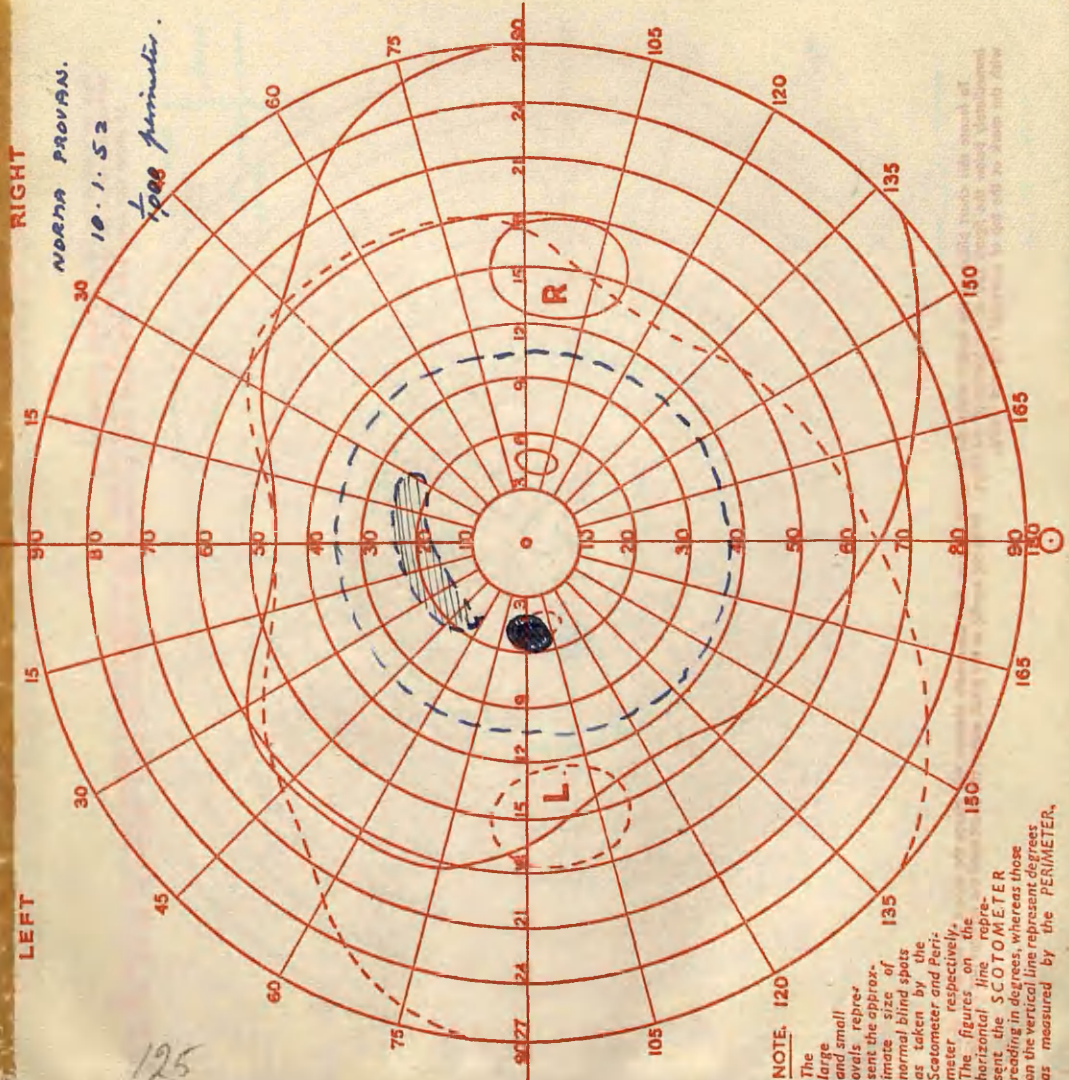


RIGHT

NOENA PROVAS.

10.1.52

1000 Perimeter.



NOTE. 120
 The large ovals represent the approximate size of normal blind spots as taken by the Scotometer and Perimeter respectively. The figures on the horizontal line represent the SCOTOMETER reading in degrees, whereas those on the vertical line represent degrees as measured by the PERIMETER.

PERIMETER AND SCOTOMETER CHART.

THEODORE HAMBLIN LTD. LONDON, W.1.

Fig. 92. V.D.T.; Male; Age 68; Refraction:

R.E. -1.0 D.S. with / 2.0 D.C. 120°.

L.E. -1.0 D.S. with / 2.0 D.C. 120°.

Right eye. Superior temporal defect with general depression. Defect is present in the isopters up to 3/330 white. The 2/1000 isopter shows a slight extension of the defect below the blind spot.

Left eye. Superior temporal defect which is much less dense and extensive than that in the right eye. in spite of its much better visual acuity.

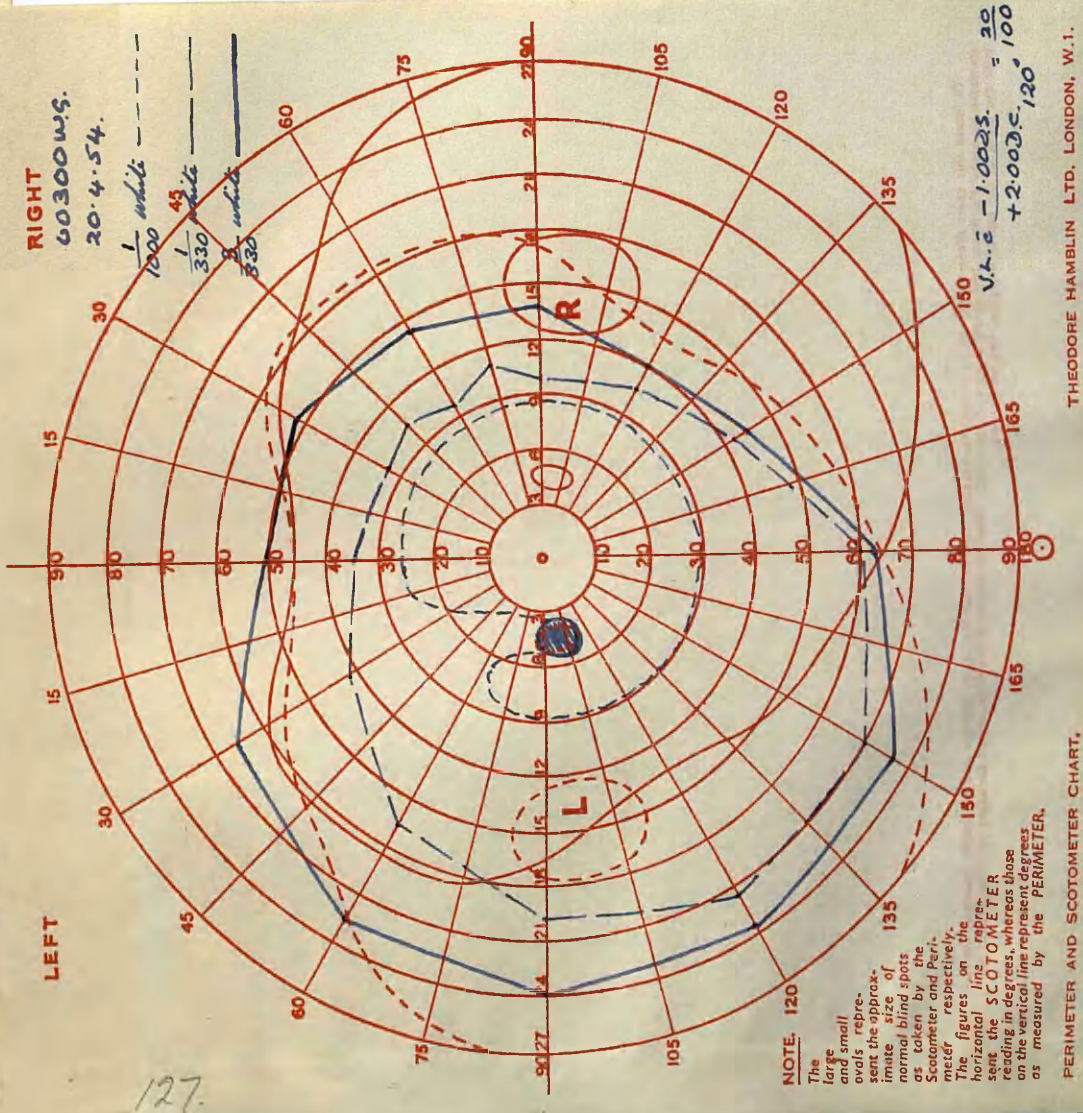

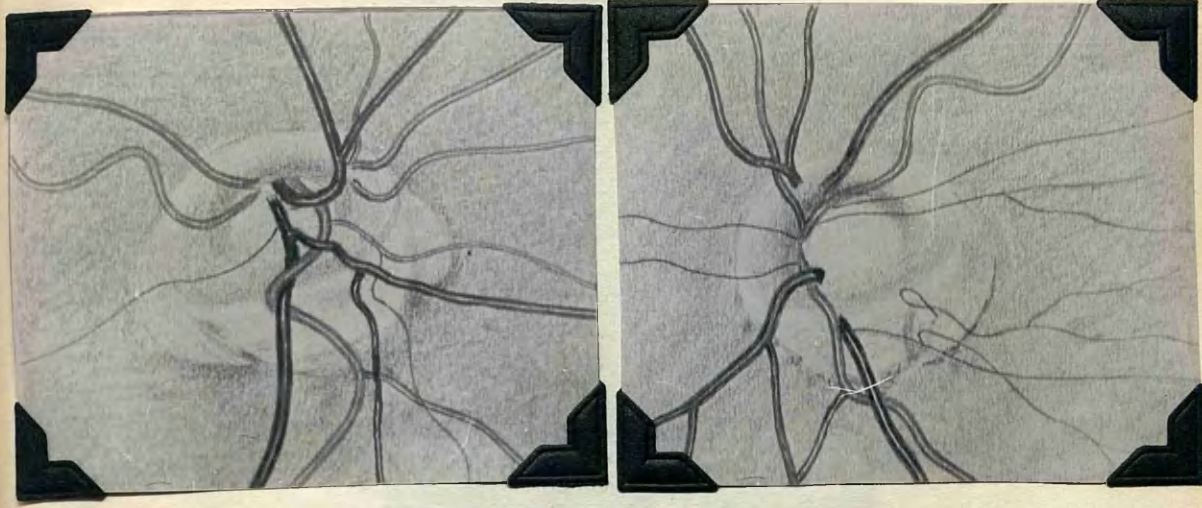
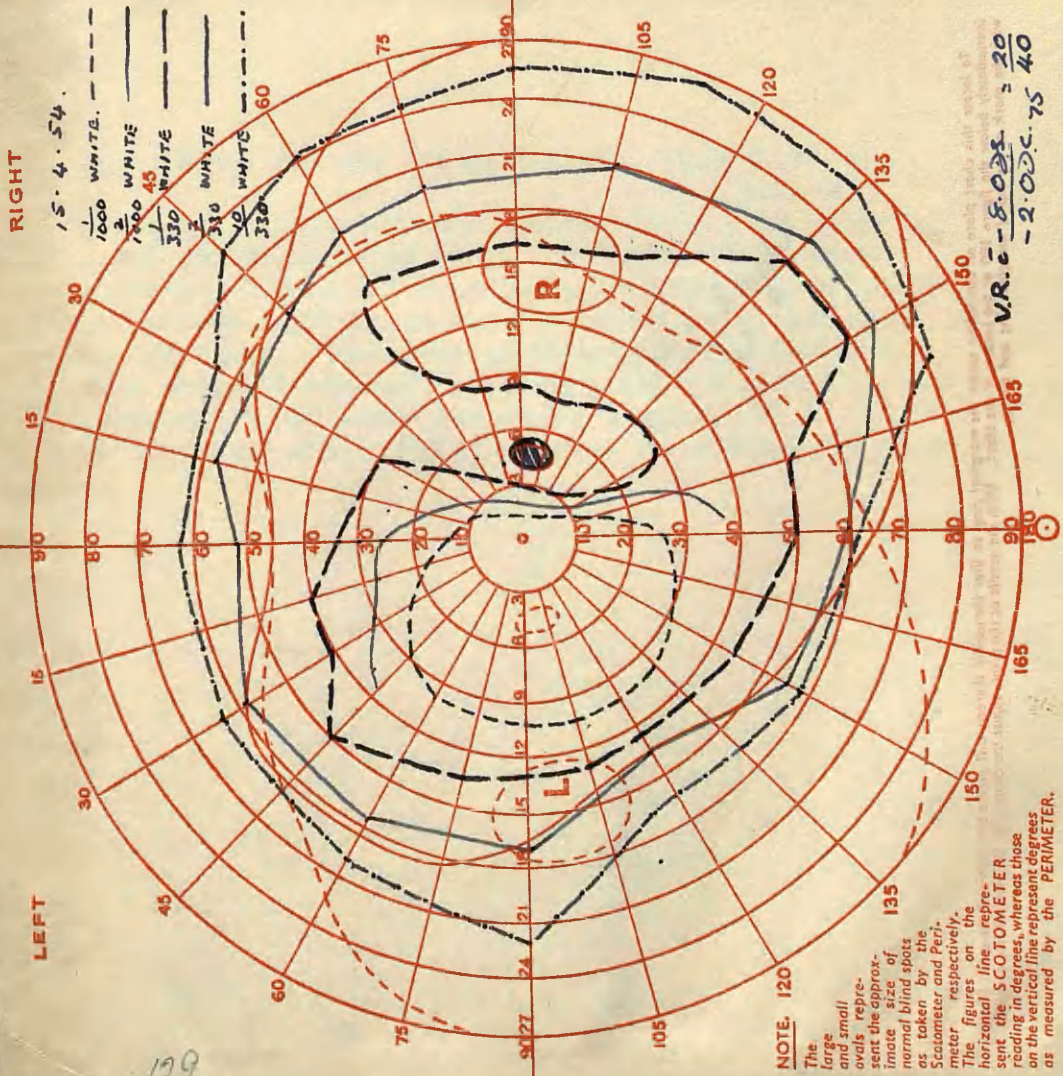
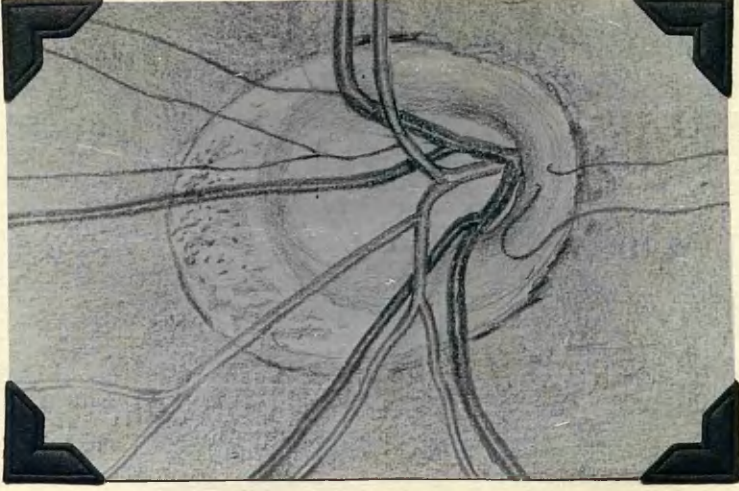


Fig. 93. M.F.; Female; Age 55; Refraction:

R.E. -8.00 D.S. with -2.00 D.C. 75°.

Right eye. Superior temporal defect connected to the blind spot and inferior defect extending from the blind spot but not reaching the periphery. The isopter for 1/1000 white shows a temporal hemianopia which may correspond to that found by Jayle and Berard.

129




129



Fig. 94. J.M.; Male; Age 69; Refraction R.E. -1.50 D.S. with
-0.5 D.C. 90°.

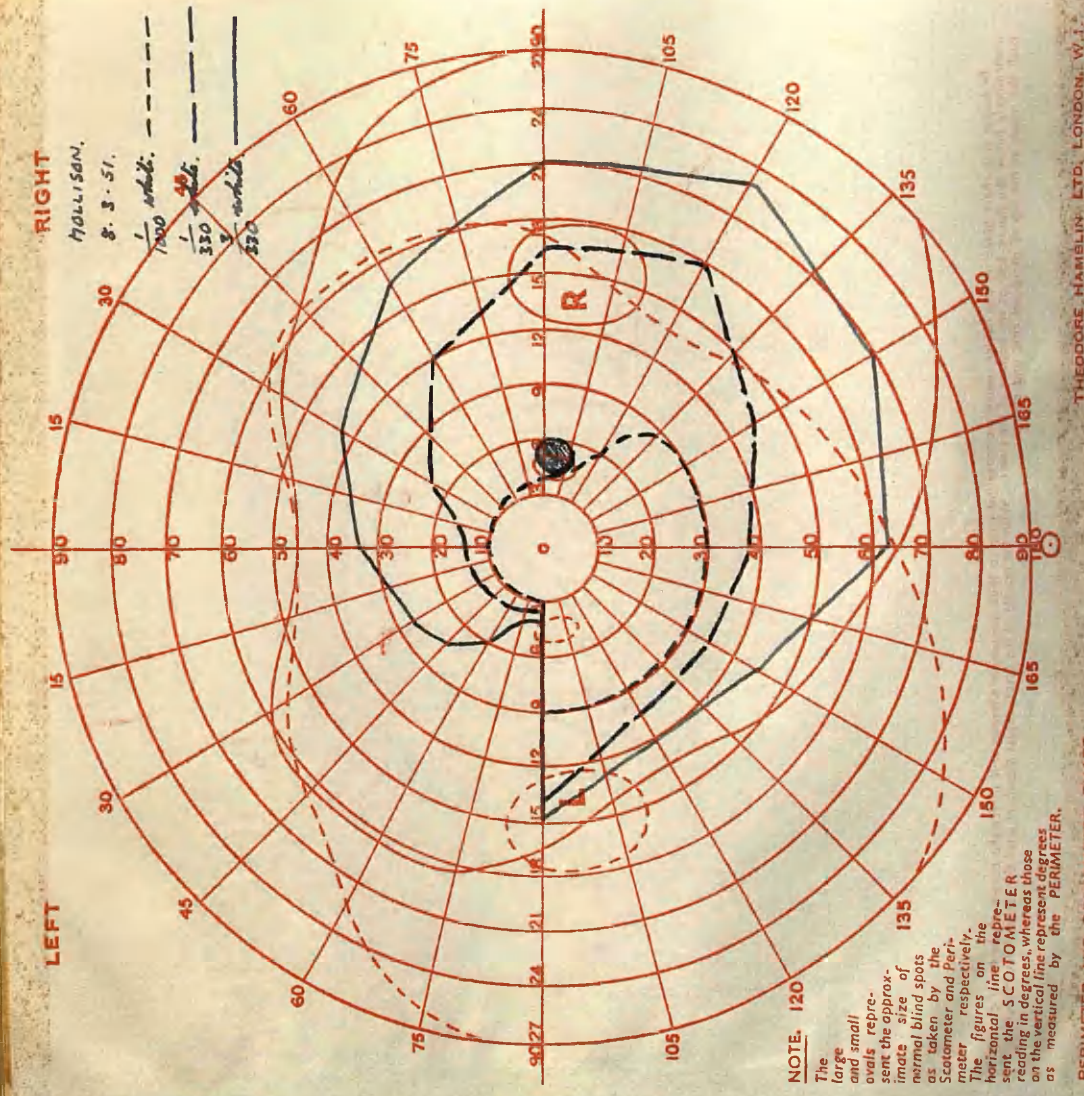
Right eye. Superior nasal sector defect most dense at nasal meridian. Five weeks later there was a more extensive defect and some general depression. There was marked improvement when the fields were examined five months later. There was no obvious fundus lesion other than those of stretch to account for the defect and the intra-ocular pressure was at no time over 22 mm. of mercury even after instillation of 1% homatropine drops.

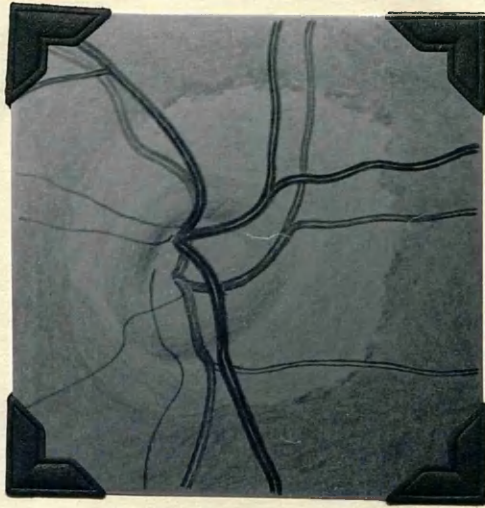

25

$V.R. = -1.5DS = \frac{8}{64}$

$-0.5DS = 90$





RIGHT

MOLLISON.

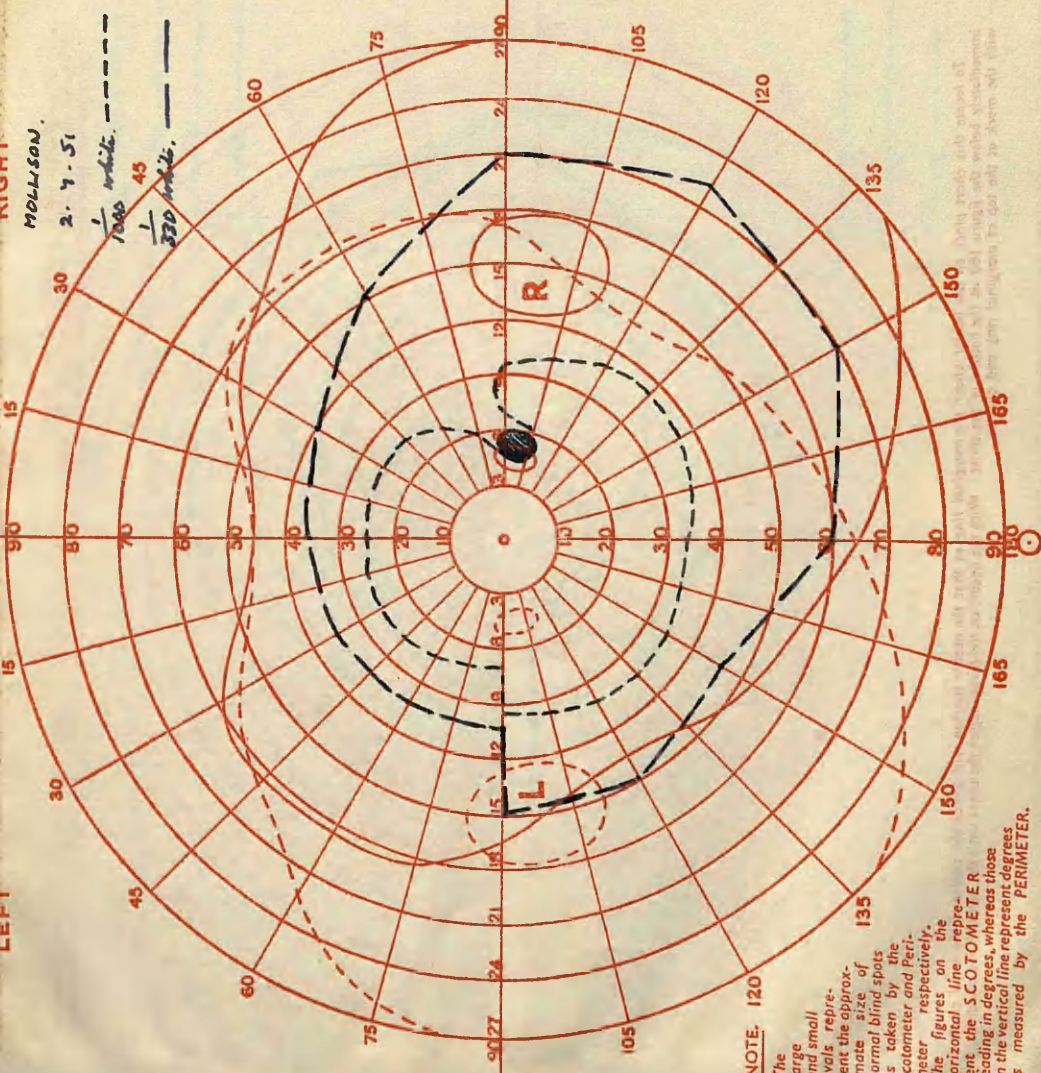
2. 7. 51

1000 white. ---

45

330 white. ---

LEFT



NOTE. 120

The large and small circles represent the approximate normal sizes of spots as taken by the Scotometer and Perimeter respectively. The figures on the horizontal line represent the SCOTOMETER reading in degrees, whereas those on the vertical line represent degrees as measured by the PERIMETER.

PERIMETER AND SCOTOMETER CHART, 131


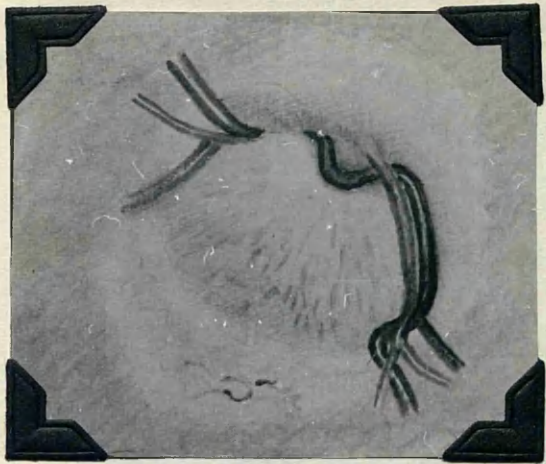
THEODORE HAMBLIN LTD. LONDON, W.1.

Fig. 95. K.W.; Female; Age 67; Refraction:

R.E. -2.50 d.s. with -1.00 D.C. 135°.

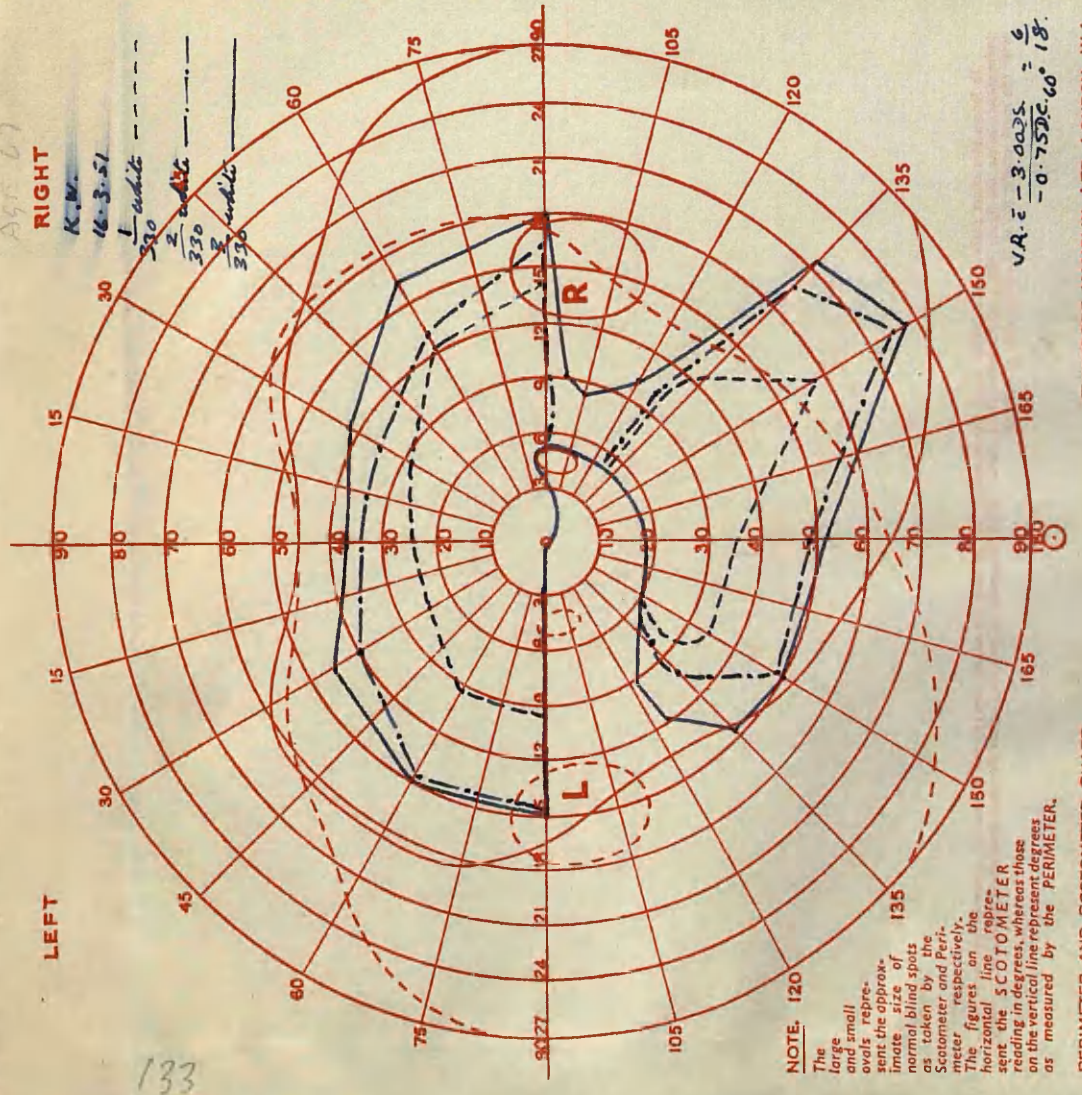
L.E. -3.00 D.S. with -0.75 D.C. 60°.

Right disc similar to left. Visual fields are those of glaucoma except for the presence of an inferior temporal sector. The intra-ocular pressure was recorded on several occasions but was at no time over 20 mm. of mercury. The cupping of the disc is that which would be expected to accompany inferior temporal crescent rather than glaucoma. The visual field defect may be attributable to narrowing of the fenestrae of the lamina cribrosa which is very obvious in the illustration.



THEODORE HAMBLIN LTD. LONDON, W.1.

V.A. = 2.50DS
-1.00DC/135 9

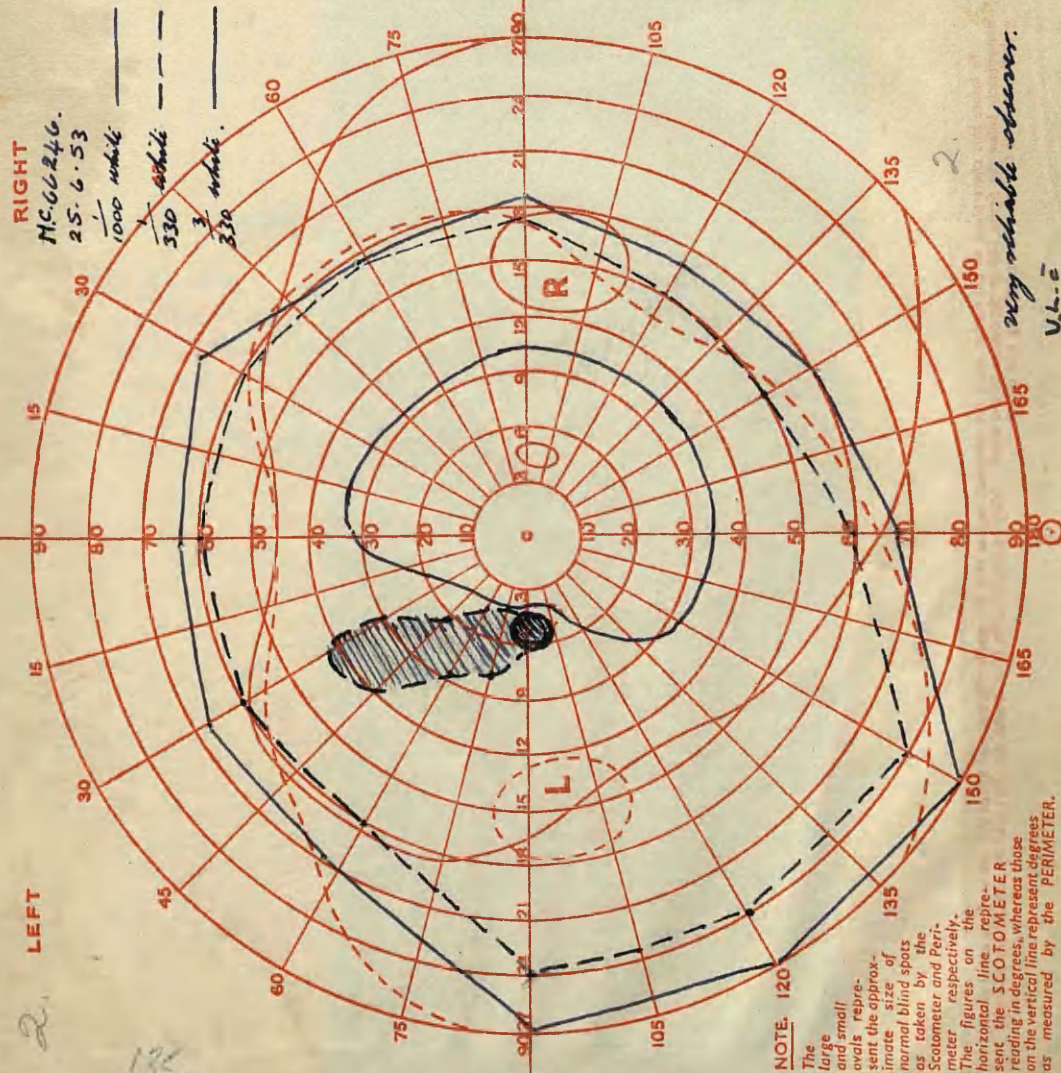
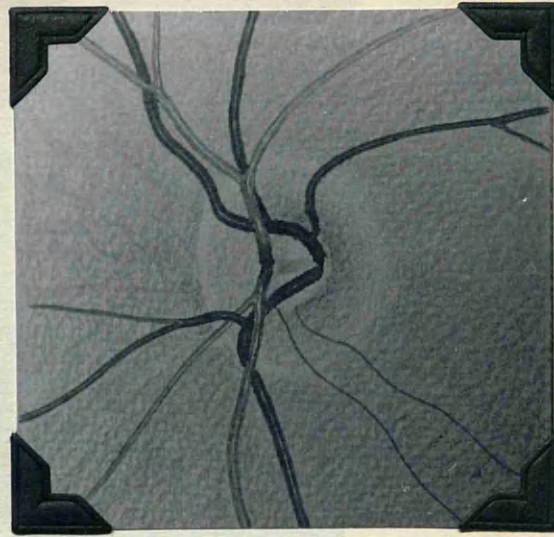
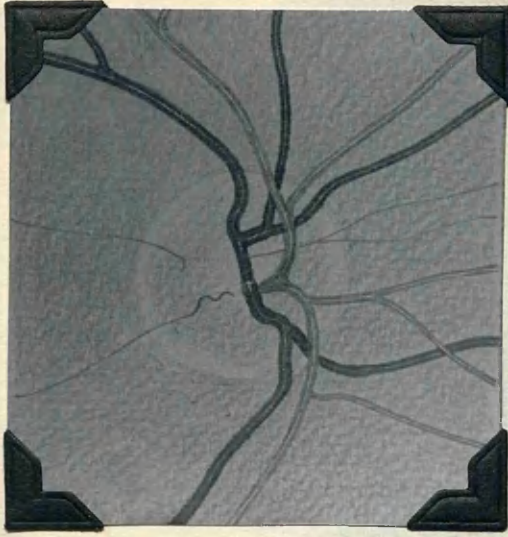


THEODORE HAMBLIN LTD. LONDON, W.1.

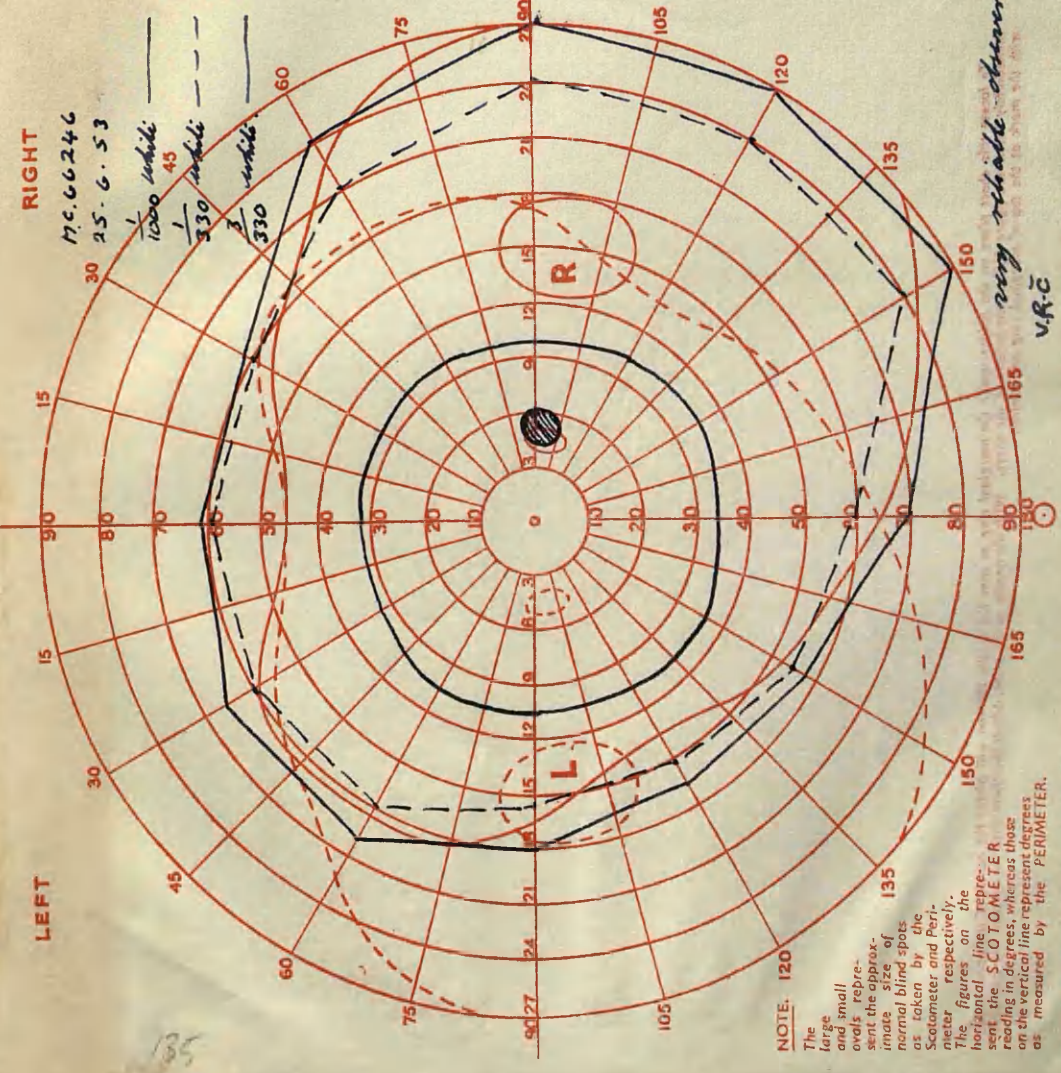
V.A. = 3.00DS
-0.75DC/60 18

Fig. 96. C.F.; Female; Age 29; Refraction: R.E. -8.00 D.S.
L.E. -1.00 D.S. with -5.00 D.C. 25°.

The right optic disc is as shown and may be considered normal. The visual field of this eye is within normal limits. The left fundus shows local excess scleral stretch nasal to the optic disc. but with no crescent. The visual field shows a typical superior temporal sector defect not breaking through to the periphery.



THEODORE HAMBLIN LTD. LONDON, W.1.



THEODORE HAMBLIN LTD. LONDON, W.1.

Fig. 97. M.B.; Female; Age 45; Refraction.:

R.E. / 1.00 D.S. with -2.50 D.C. 180°.

Right eye. Inferior temporal defect associated with superior crescent. The defect varies in the same way that does a superior defect. This is the only case with an inferior sector encountered in the present investigation and is also the only one with defective visual fields and a superior crescent.

LEFT

RIGHT

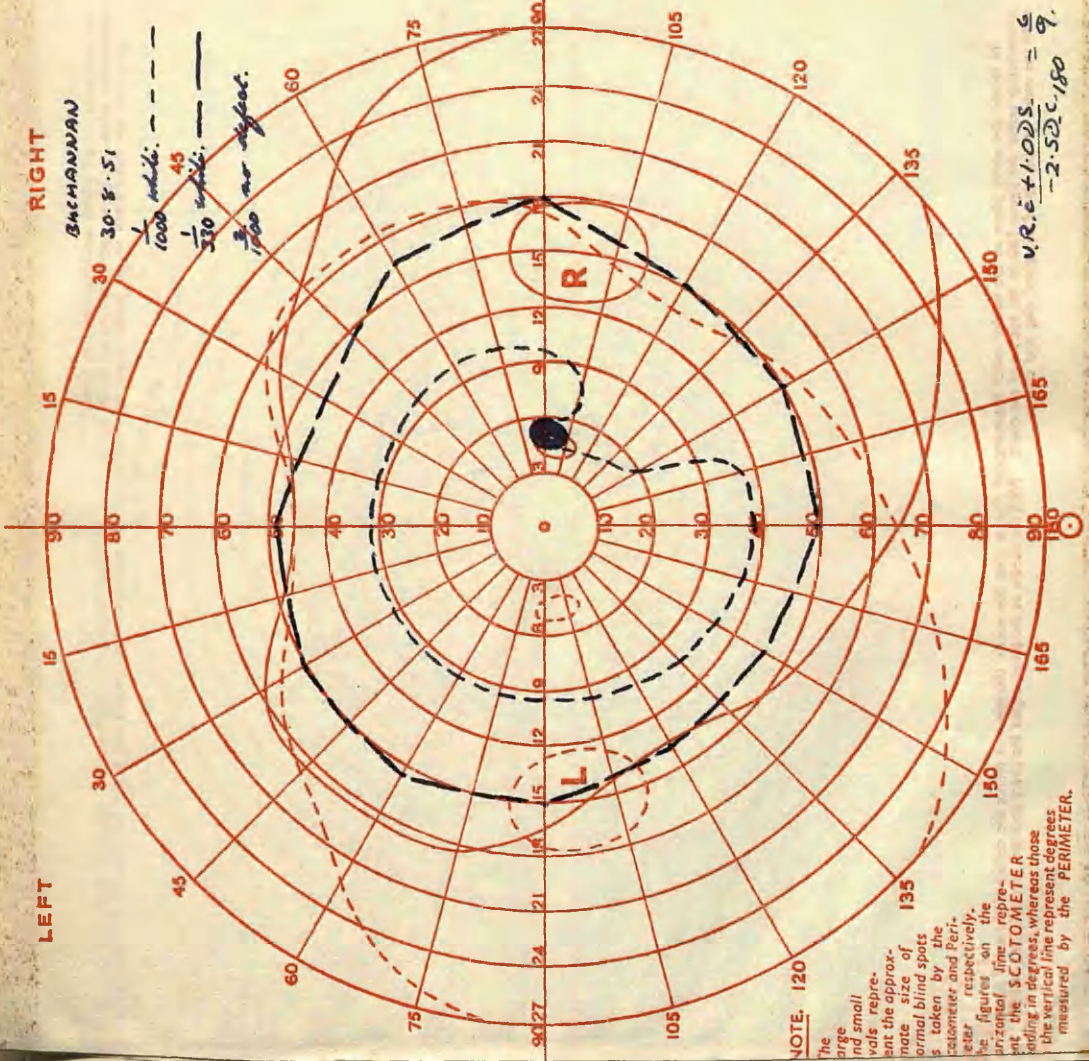
BACHMANN

30.8.51

$\frac{1}{1000}$ melli. ---

$\frac{1}{370}$ melli. ---

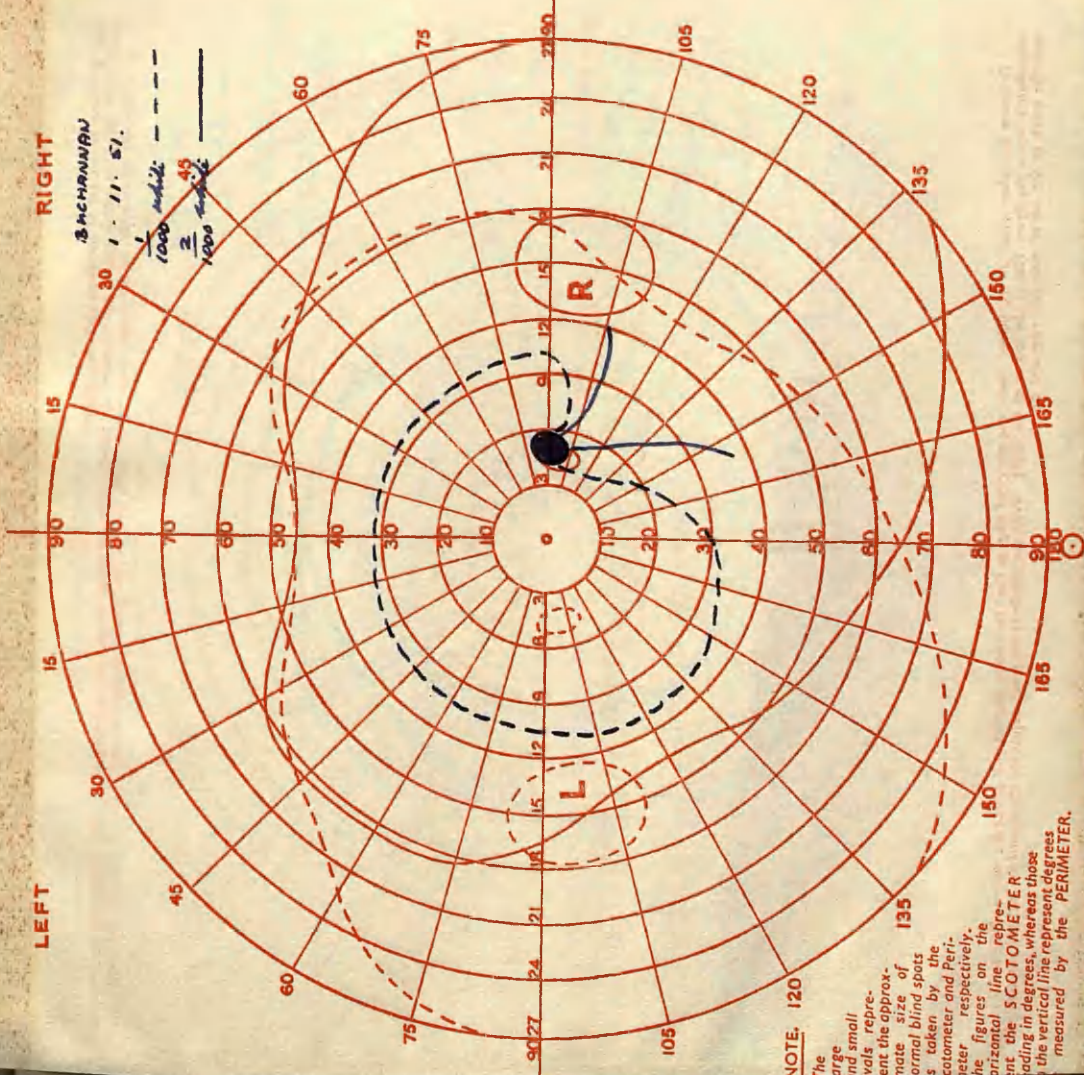
3000 m. effect.



NOTE. 120

The large and small values represent the approximate size of normal blind spots taken by the scotometer and Perimeter respectively. The figures on the horizontal line represent the SCOTOMETER reading in degrees, whereas those on the vertical line represent degrees measured by the PERIMETER.

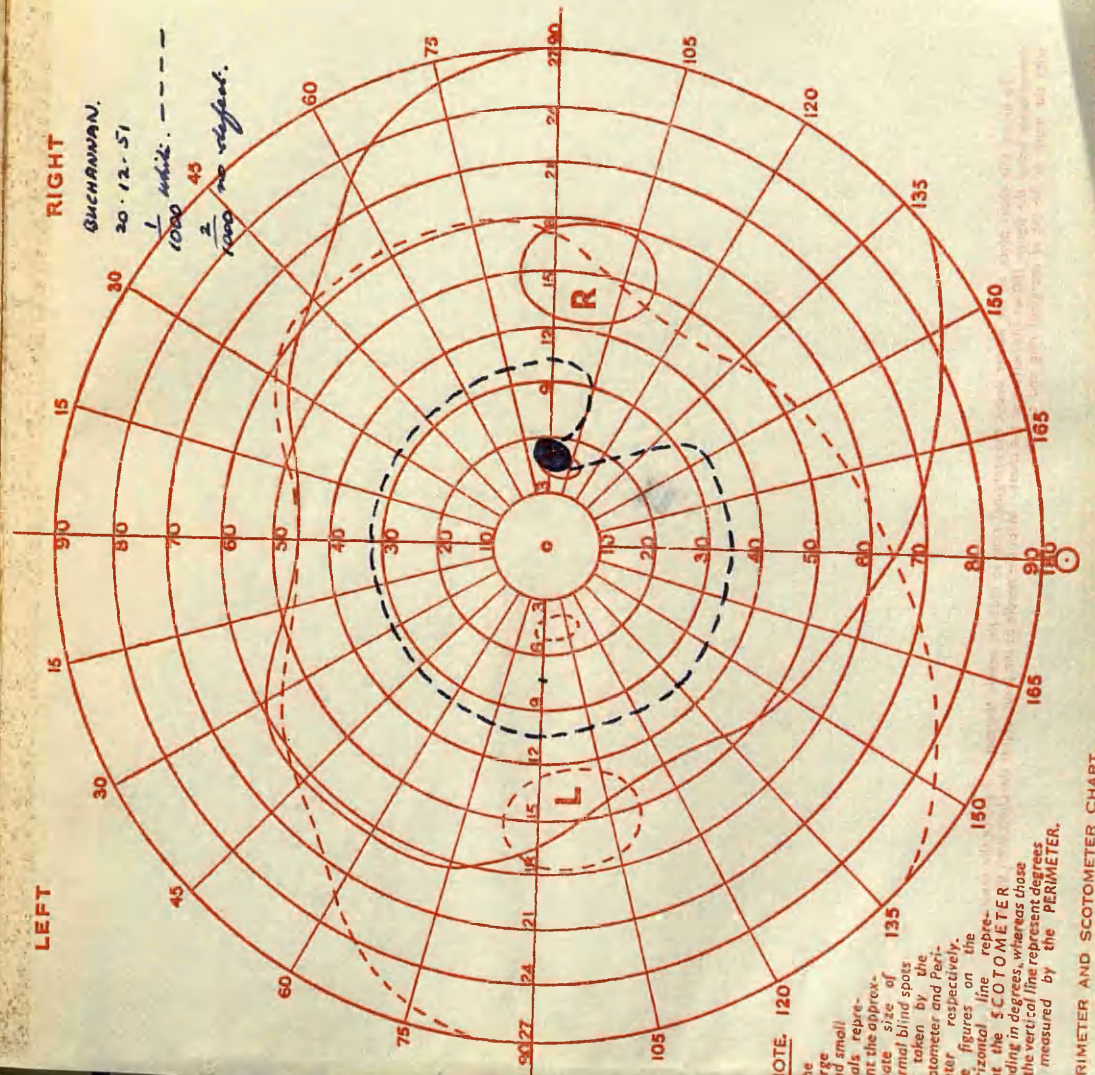
$$\frac{V.R. \times 1.025}{-2.52 \times 180} = \frac{9}{9}$$



The large and small fields represent the approximate size of normal blind spots taken by the Perimeter and Perimeter respectively. The vertical line represents the SCOTOMETER reading in degrees, whereas those measured by the PERIMETER.

PERIMETER AND SCOTOMETER CHART.

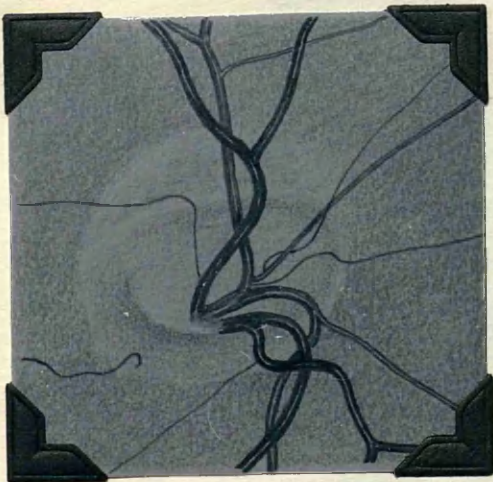
THEODORE HAMBLIN LTD, LONDON, W.1.



The large and small fields represent the approximate size of normal blind spots taken by the Perimeter and Perimeter respectively. The vertical line represents the SCOTOMETER reading in degrees, whereas those measured by the PERIMETER.

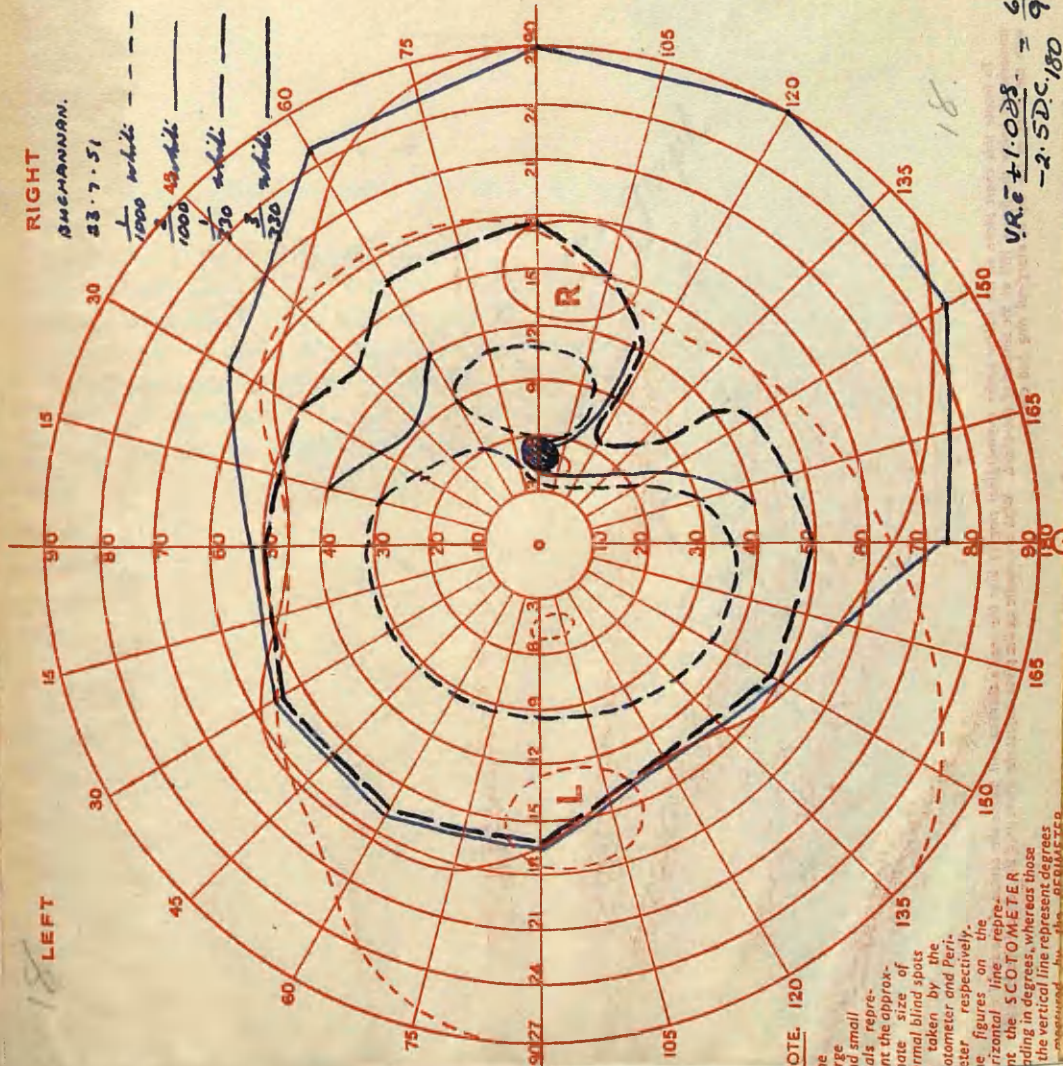
PERIMETER AND SCOTOMETER CHART.

THEODORE HAMBLIN LTD, LONDON, W.1.



RIGHT
BUCHANAN.

83.7.51
1000 white ---
1000 48 white ---
150 white ---
320 white ---



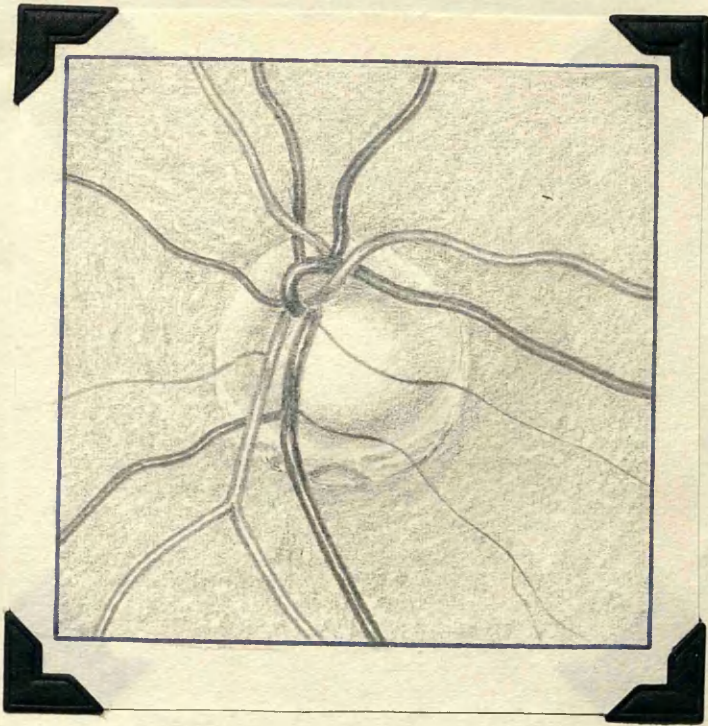
18.
$$\text{V.R.} = +1.02\text{D.} = \frac{6}{9}$$

$$-2.5\text{D.C. } 180$$

NOTE. 120
The large and small circles represent the approximate size of normal blind spots taken by the Perimeter and Perimeter respectively. The horizontal line represents the SCOTOMETER field in degrees, whereas those vertical lines represent degrees measured by the PERIMETER.

Fig. 98. E.S.; Female; Age 77; Refraction:
L.E. \nearrow 8.00 D.S. with \nearrow 0.50 D.C. 90°.
Left eye. Aphakic. Superior sector defect with sloping margins. The defect resembles that which results from scleral stretch. The intra-ocular pressure has ranged between 25 and 40 mm. of mercury for several years in spite of treatment with miotics. The disc does not show cupping characteristic of glaucoma but rather of scleral stretch which is greatest below the optic disc.

139



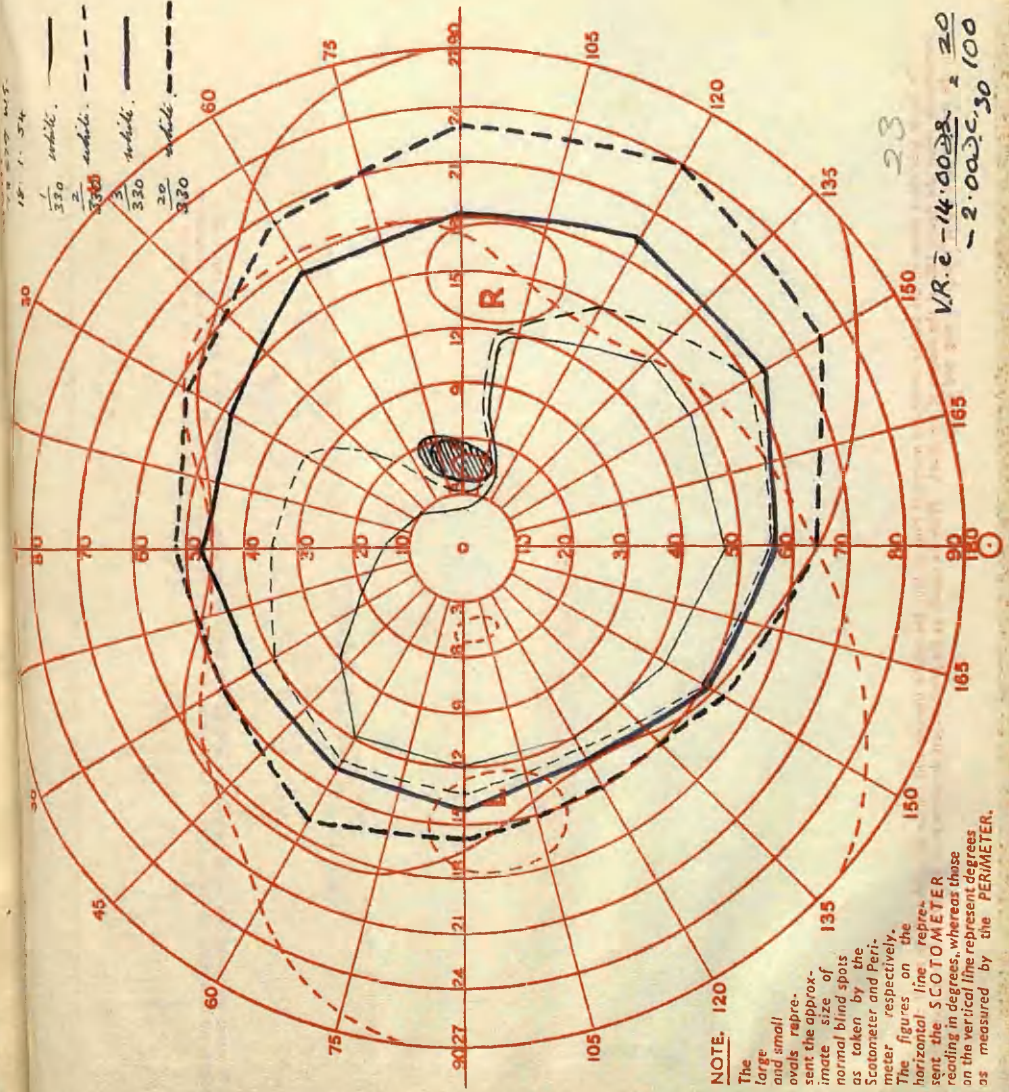
1 cm
Graph

Fig. 99. L.C.; Female; Age 69; Refraction;
 R.E. -14.00 D.S. with -2.00 D.C. 30°.
 L.E. -18.00 D.S. with

Right eye. Superior temporal defect not extending to nasal meridian. Three months later the intensity of the defect had increased and approached the fixation area. A dense sector unconnected to the periphery extended from the disc to just beyond the midline above. The field was generally depressed.

Left eye. Dense superior temporal defect typical of that resulting from stretch of the sclera except in density. Marked general depression.

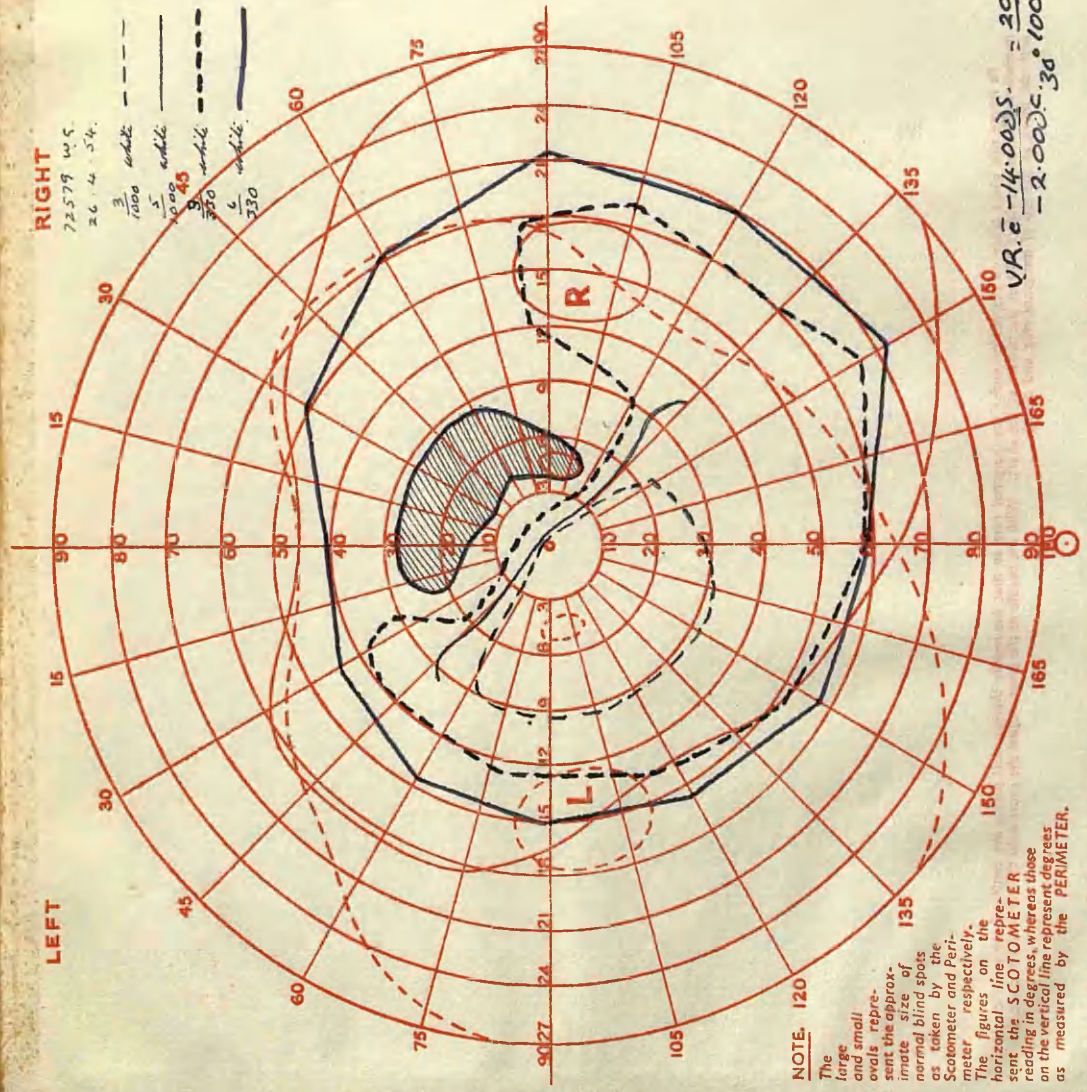
This case had primary chronic glaucoma with the intra-ocular pressure varying between 22 and 43 mm. of mercury over a period of years.



NOTE. 120
 The large and small ovals represent the approximate size of normal blind spots as taken by the Scotometer and Perimeter respectively. The figures on the horizontal line represent the SCOTOMETER reading in degrees, whereas those on the vertical line represent degrees as measured by the PERIMETER.

PERIMETER AND SCOTOMETER CHART.


THEODORE HAMBLIN LTD. LONDON, W.1.



NOTE. 120
 The large and small ovals represent the approximate size of normal blind spots as taken by the Scotometer and Perimeter respectively. The figures on the horizontal line represent the SCOTOMETER reading in degrees, whereas those on the vertical line represent degrees as measured by the PERIMETER.

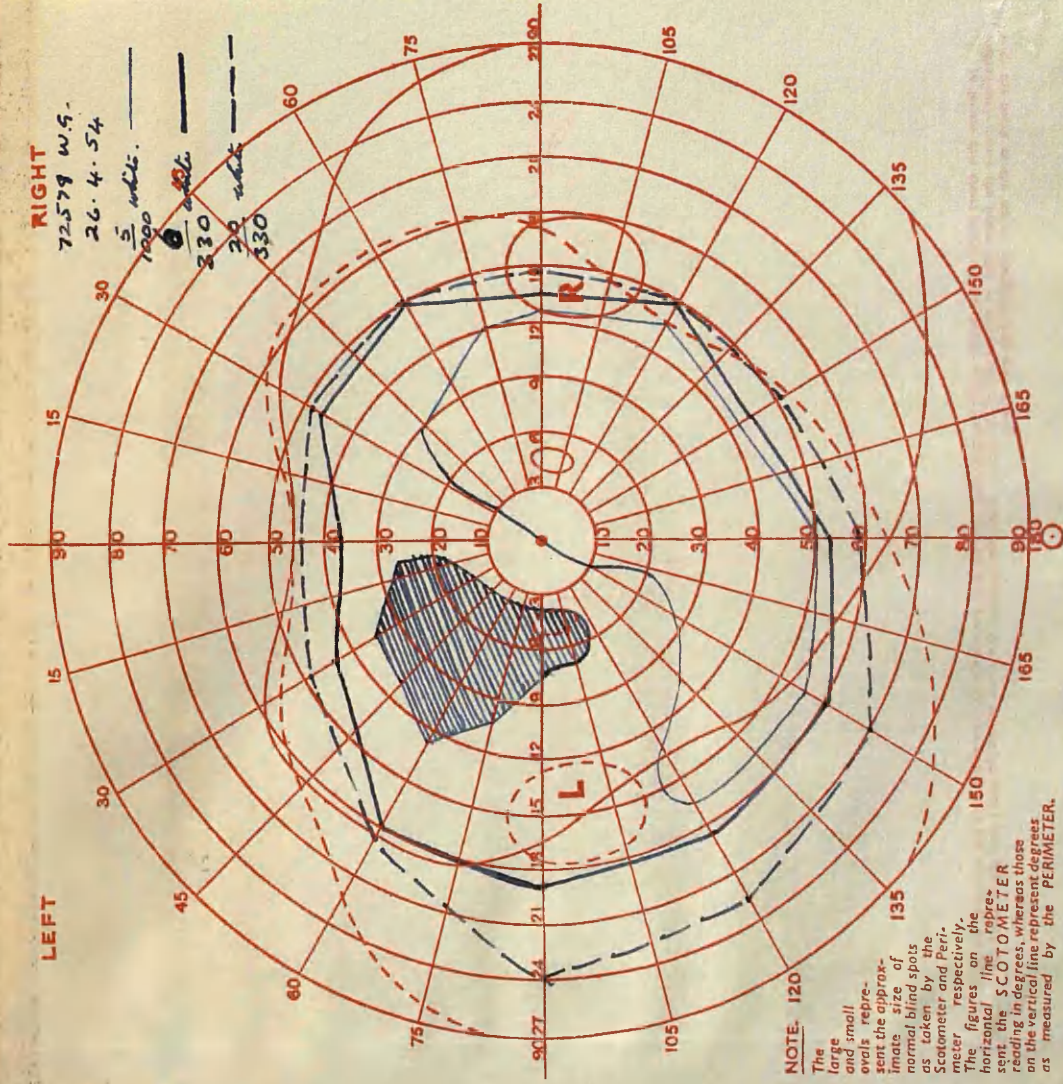
PERIMETER AND SCOTOMETER CHART.

THEODORE HAMBLIN LTD. LONDON, W.1.



PERIMETER AND SCOTOMETER CHART.

THEODORE HAMBLIN LTD. LONDON, W.1.



PERIMETER AND SCOTOMETER CHART.

THEODORE HAMBLIN LTD. LONDON, W.1.

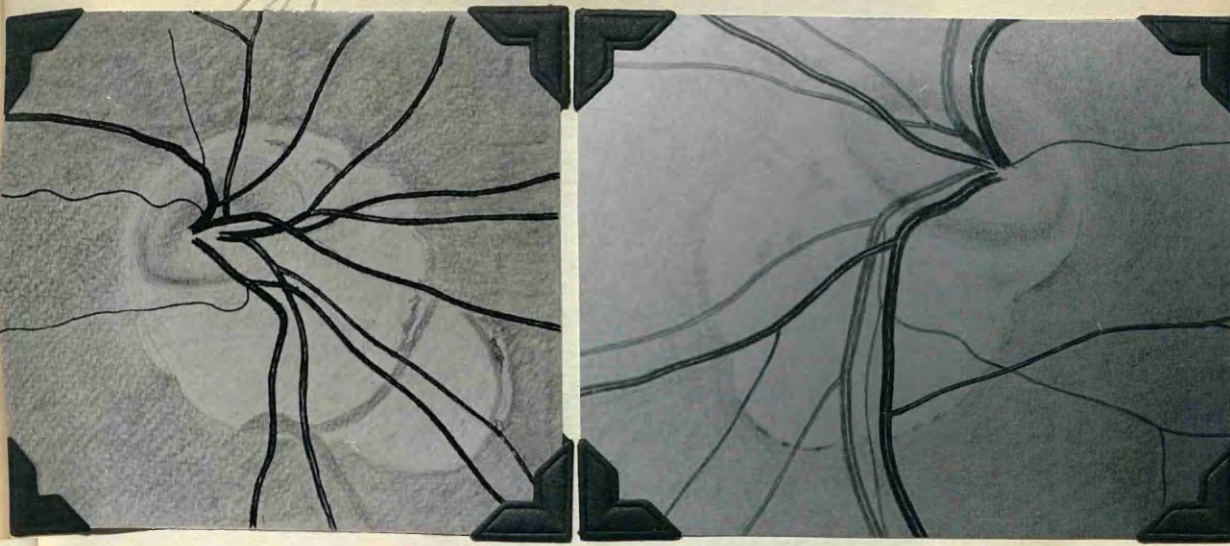


Fig. 100. S.M.; Male; Age 50; Refraction:



R.E. -14.0 D.S. with -3.0 D.C. 15°.

L.E. -11.0 D.S. with -2.0 D.C. 140°.

Right eye. Temporal field defect extending from the blind spot with some temporal contraction.

Left eye. Fairly dense superior sector defect. The isopter for 1/1000 white shows a nasal step.

143



4, LEFT, 9

143

143

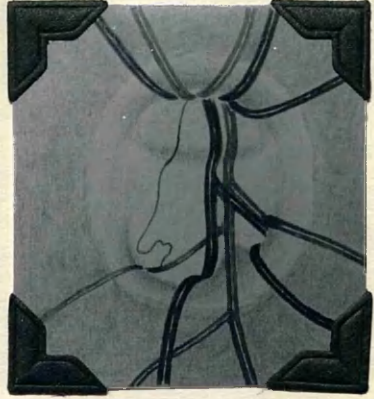


Fig. 101. A.D.; Female; Age 40; Refraction.

R.E. -1.00 D.S. with -3.00 D.C. 10°.


Right eye. Inferior crescent with superior sector defect and nasal step.

145



RIGHT
DOLMERTY. 14.

16.2.57
 $\frac{1}{1000}$ white. ---
 $\frac{1}{330}$ white. ---
 $\frac{1}{750}$ white. ---



4
LEFT

L

R

NOTE. 120

The large small circles represent the approximate size of normal blind spots as taken by the Scotometer and Perimeter respectively. The figures on the horizontal line represent the SCOTOMETER reading in degrees, whereas those on the vertical line represent degrees as measured by the PERIMETER.

4
V.R. $\bar{e} = 1.028$. = $\frac{9}{-3.02 \times 10}$

Fig. 102. J.C.; Female; Age 68; Refraction:

L.E. -4.50 D.S. with -2.50 D.C. 180°.

Left eye. Fields show a nasal step which is unusual in that each isopter, instead of lying along the nasal meridian, slopes gradually towards it. The defect resembles, in many respects, that in fig. 102. It is most dense at the nasal meridian. The 2/1000 isopter shows an island of vision in the superior temporal quadrant resembling that in fig. 86. The optic disc shows senile cupping. The intra-ocular pressure was at no time recorded over 30 mm. of mercury in spite of instillation of 1% homatropine drops.

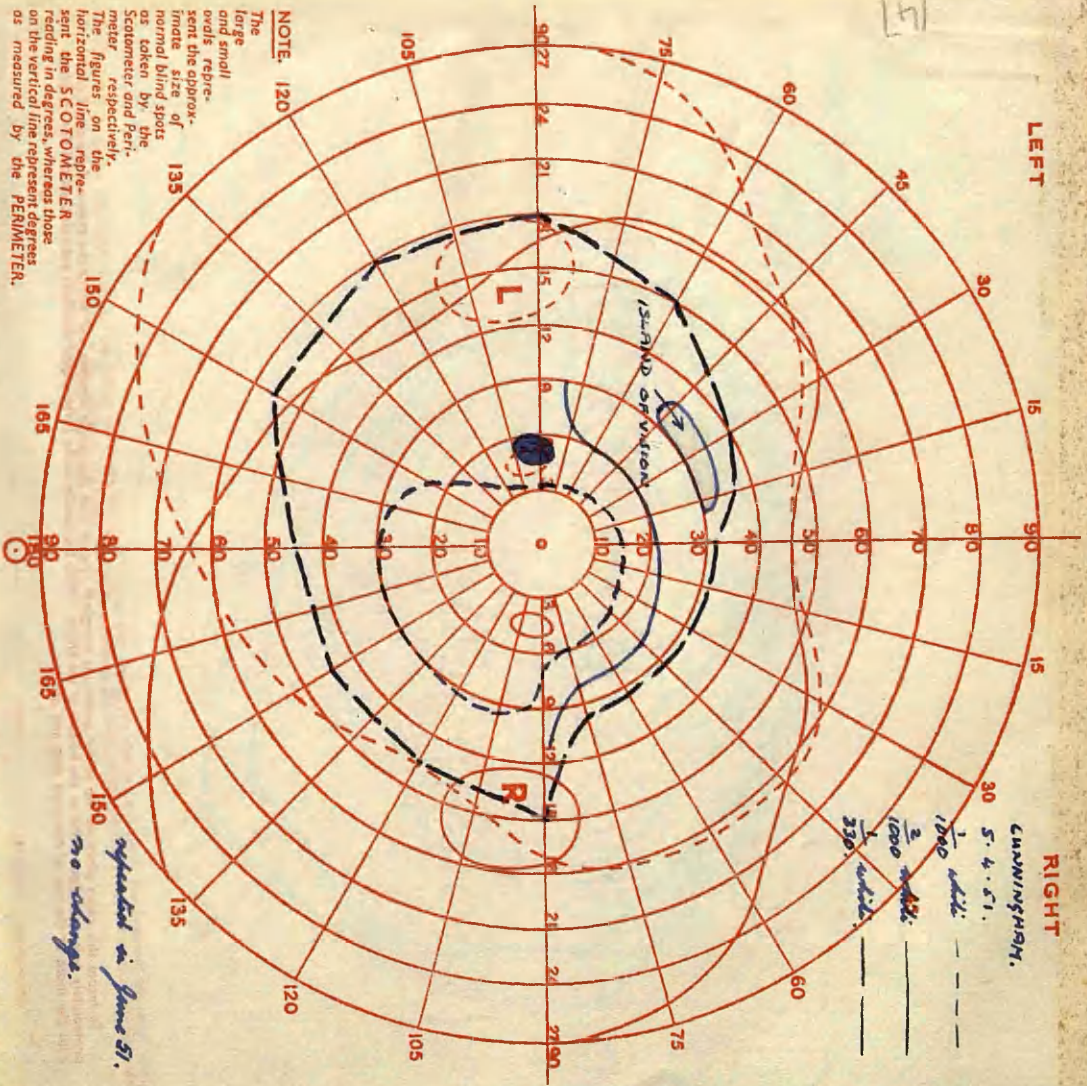
LEFT

RIGHT

CUNNINGHAM.

5. 4. 51.

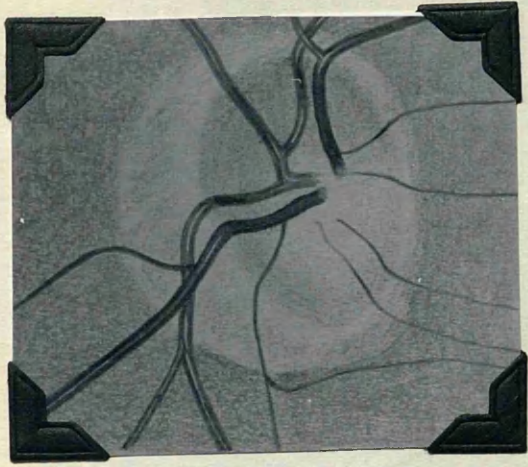
- 1000 white. ———
- 1000 white. - - - -
- 1000 white. ———
- 330. ———




NOTE 120

The large and small ovals represent the approximate size of normal blind spots as taken by the Scotometer and Perimeter respectively. The figures on the horizontal line represent the SCOTOMETER reading in degrees, whereas those on the vertical line represent degrees as measured by the PERIMETER.


*repeated on page 51.
no change.*



RESIDUAL STATIONARY BLIND



THEODORE HAMBELIN LTD. LONDON, W.1.



THEODORE HAMBELIN LTD. LONDON, W.1.

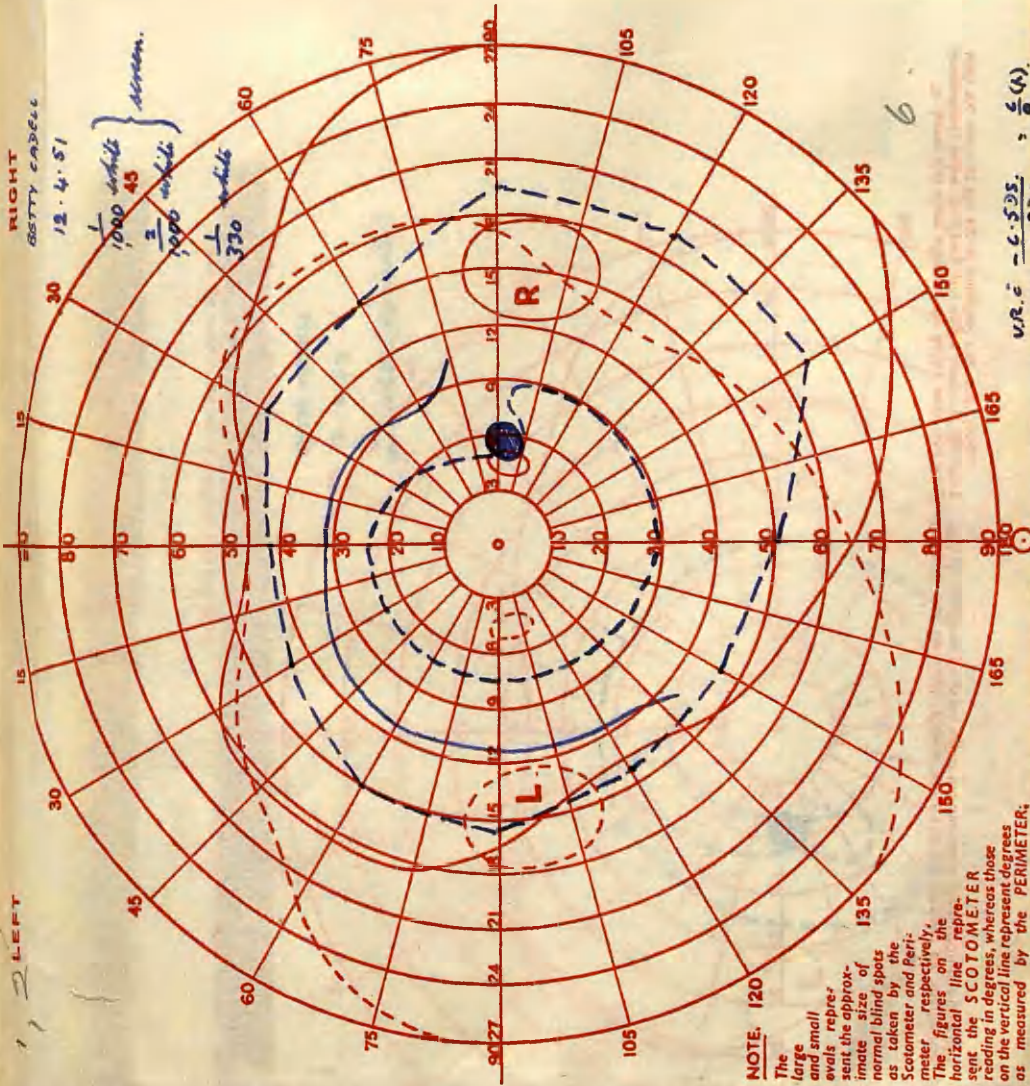
Fig. 103. B.C.; Female; Age 12; Refraction:

R.E. -10.00 D.S. with -3.00 d.C. 180°.

L.E. -6.50 D.S. with -1.50 D.C. 10°.

Right eye. Upper temporal quadrant shows typical defect for small targets, and some general depression. Nine months later the only defect consisted of two sectors, extending above and below the blind spot, and only detectable with a one mm. white target at a distance of one metre. Left eye. Similar fields to right eye but defect is less marked.

LEFT



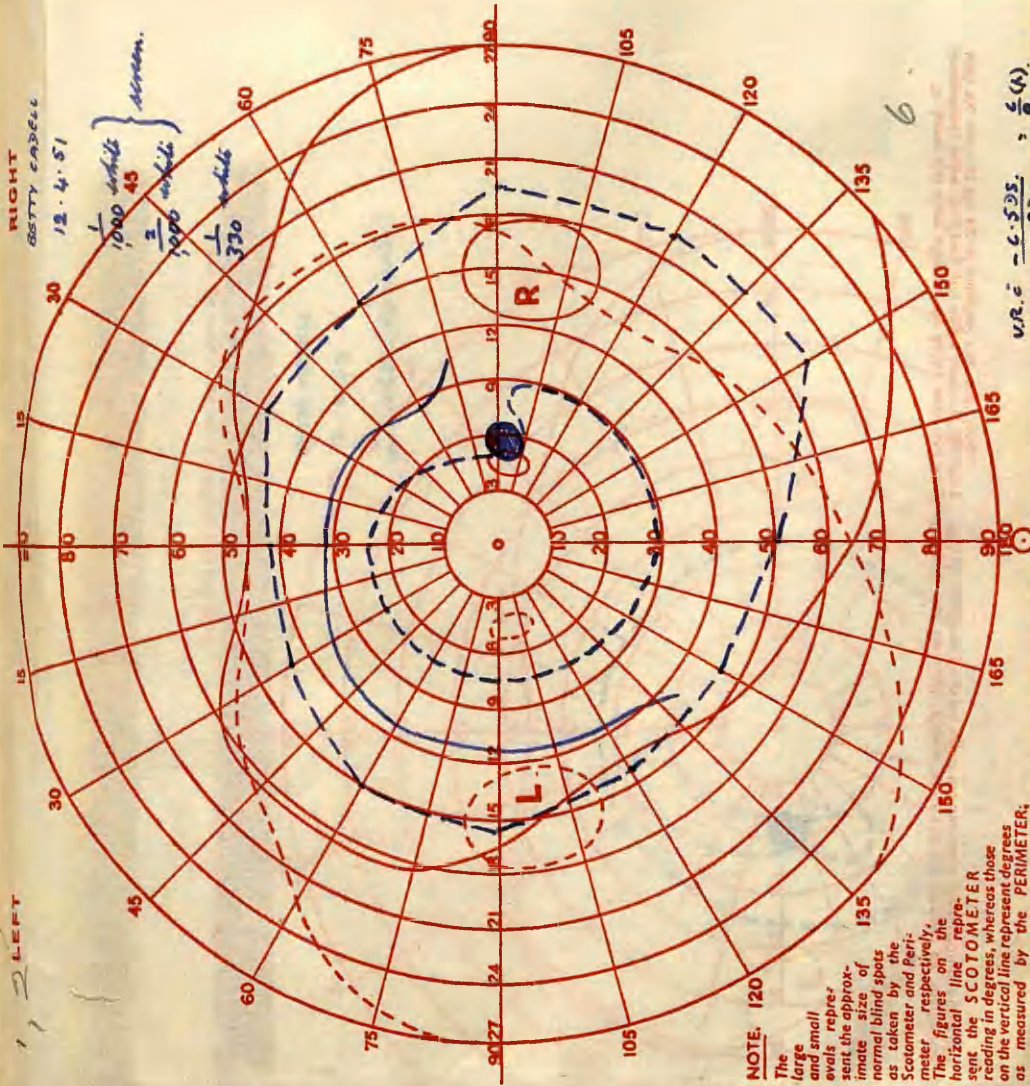
NOTE. 120
The large and small ovals represent the approximate size of normal blind spots as taken by the Scotometer and Perimeter respectively. The horizontal line represents the SCOTOMETER reading in degrees, whereas those on the vertical line represent degrees as measured by the PERIMETER.

PERIMETER AND SCOTOMETER CHART

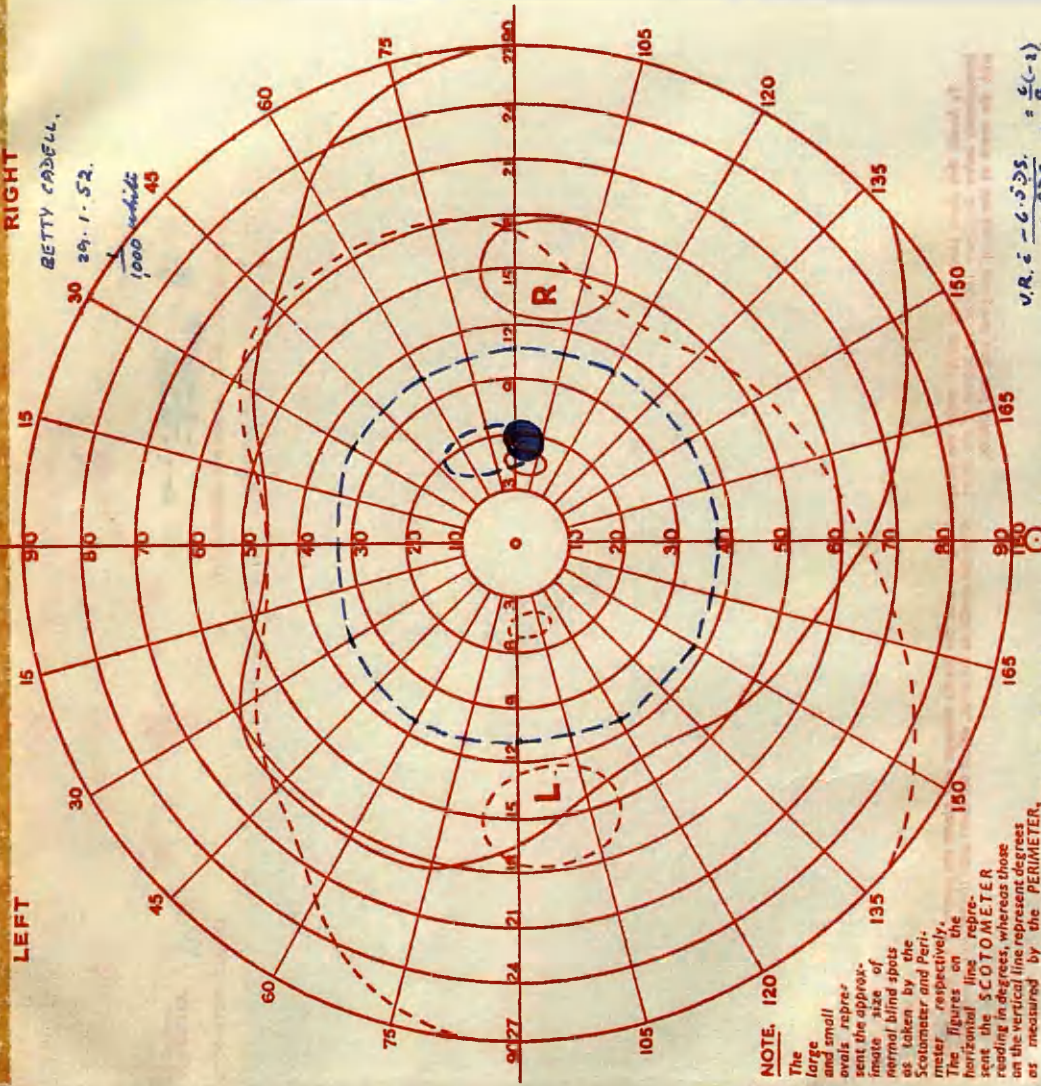
$$V.R. \frac{6.535}{1.535} = \frac{6(4)}{9}$$

6

RIGHT



LEFT



NOTE. 120
The large and small ovals represent the approximate size of normal blind spots as taken by the Scotometer and Perimeter respectively. The horizontal line represents the SCOTOMETER reading in degrees, whereas those on the vertical line represent degrees as measured by the PERIMETER.

PERIMETER AND SCOTOMETER CHART

12.2.52 shows no change.

$$V.R. \frac{6.535}{1.535} = \frac{4(-1)}{9}$$

THEODORE HAMBLIN LTD. LONDON, W.1.

THEODORE HAMBLIN LTD. LONDON, W.1.

LEFT

RIGHT

BETTY CADELL

30 12.2.52

1000 white (perimeter)

45

45

60

60

75

75

90

90

105

105

105

NOTE. 120

The large and small ovals represent the approximate size of normal blind spots as taken by the Scotometer and Perimeter respectively. The figures on the horizontal line represent the SCOTOMETER reading in degrees, whereas those on the vertical line represent degrees as measured by the PERIMETER.

L

R

135

135

150

150

165

165

180



$$V.L.C. - 10.035. - \frac{6}{18}(-1).$$

$$-3.035.100$$

PERIMETER AND SCOTOMETER CHART.

THEODORE HAMBLIN LTD, LONDON, W.1.

149



149

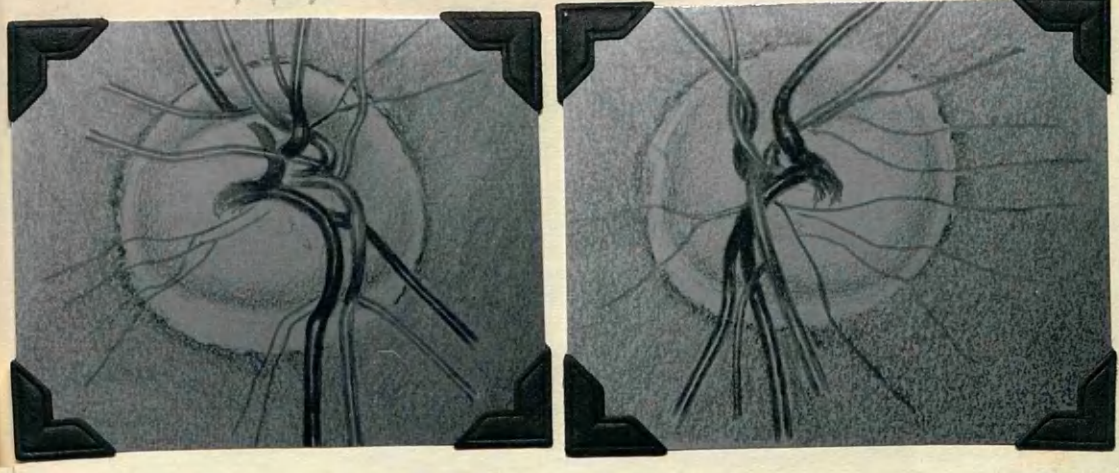
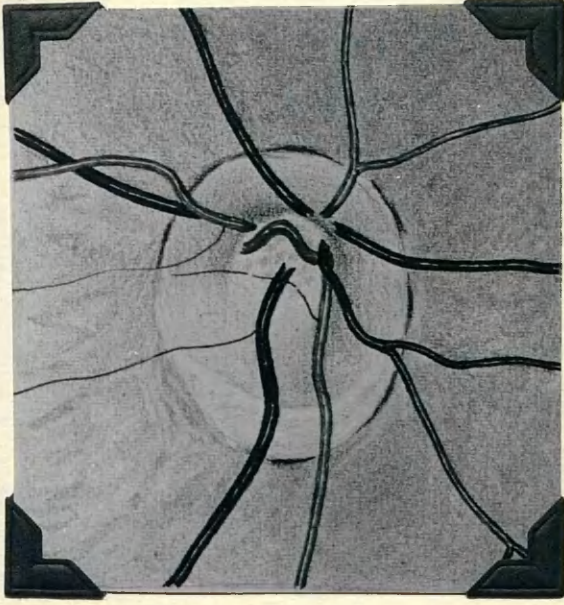


Fig. 104. E.T.; Male; Age 37; Refraction:
R.E. -7.00 D.S. with -0.50 D.C. 40°.
Right eye. Double sector defect, one above and one
below the blind spot.

151



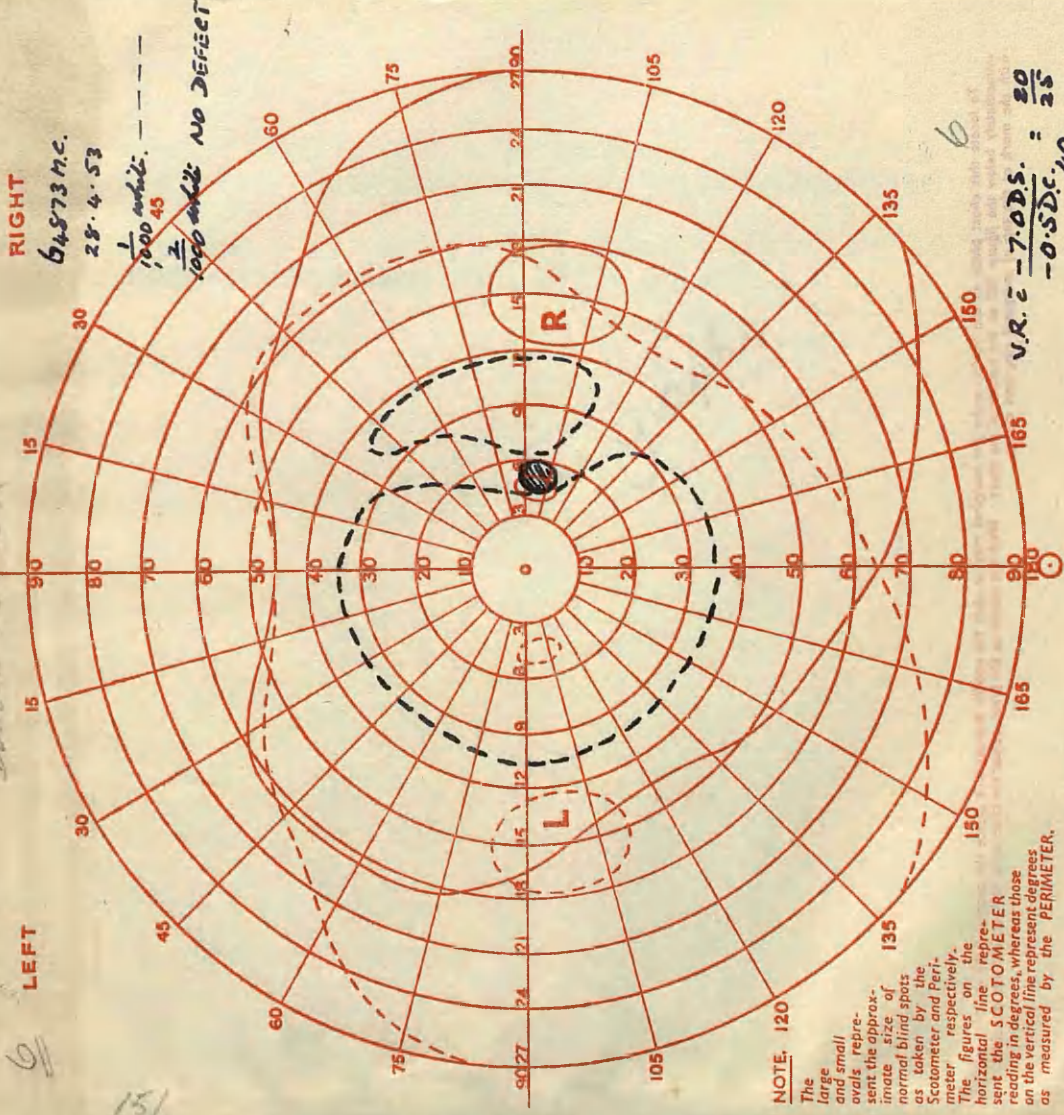
DOUBLE SECTOR

RIGHT

64573 n.c.

28.4.53

1000 white. ---
45
1000 white NO DEFECT



LEFT

6

151

NOTE. 120

The large and small ovals represent the approximate size of normal blind spots as taken by the Scotometer and Perimeter respectively. The figures on the horizontal line represent the SCOTOMETER reading in degrees, whereas those on the vertical line represent degrees as measured by the PERIMETER.

$$V.R. = \frac{7.0DS.}{-0.5DC.40} = \frac{20}{25}$$

6

PERIMETER AND SCOTOMETER CHART,

THEODORE HAMBLIN. LTD. LONDON, W.1.

Fig. 105. A.McK.; Female; Age ; Refraction.
Right eye. Increasing defect in superior temporal quadrant.
Left eye. Increasing defect with nucleus of defect separated from blind spot in second chart.

RIGHT

RIGHT

N. KINNOR.

27. 7. 51

$\frac{1}{1000}$ white.

$\frac{1}{1000}$ $\frac{1}{2}$

$\frac{1}{320}$ $\frac{1}{2}$

LEFT

15

30

45

60

75

90

105

120

135

150

165

90

150

135

120

105

90

90

75

60

45

30

15

90

30

60

75

90

90

75

60

45

30

15

90

30

60

75

90

90

75

60

45

30

15

90

30

60

75

90

90

75

60

45

30

15

90

30

60

75

90

90

75

60

45

30

15

90

30

60

75

90

90

75

60

45

30

15

90

30

60

75

90

90

75

60

45

30

15

90

30

60

75

90

90

75

60

45

30

15

90

30

60

75

90

90

75

60

45

30

15

90

30

60

75

90

90

75

60

45

30

15

90

30

60

75

90

90

75

60

45

30

15

90

30

60

75

90

90

75

60

45

30

15

90

30

60

75

90

90

75

60

45

30

15

90

30

60

75

90

90

75

60

45

30

15

90

30

60

75

90

90

75

60

45

30

15

90

30

60

75

90

90

75

60

45

30

15

90

30

60

75

90

90

75

60

45

30

15

90

30

60

75

90

90

75

60

45

30

15

90

30

60

75

90

90

75

60

45

30

15

90

30

60

75

90

90

75

60

45

30

15

90

30

60

75

90

90

75

60

45

30

15

90

30

60

75

90

90

75

60

45

30

15

90

30

60

75

90

90

75

60

45

30

15

90

30

60

75

90

90

75

60

45

30

15

90

30

60

75

90

90

75

60

45

30

15

90

30

60

75

90

90

75

60

45

30

15

90

30

60

75

90

90

75

60

45

30

15

90

30

60

75

90

90

75

60

45

30

15

90

30

60

75

90

90

75

60

45

30

15

90

30

60

75

90

90

75

60

45

8.12

INCREASE

RIGHT


M'ANNON.

7.7.51

$\frac{1}{1000}$ white


$\frac{1}{1000}$ white

$\frac{1}{220}$ white



NOTE. 120

The large and small ovals represent the approximate size of normal blind spots as taken by the Scotometer and Perimeter respectively. The figures on the horizontal line represent the SCOTOMETER reading in degrees, whereas those on the vertical line represent degrees as measured by the PERIMETER.



RIGHT
 17 MINUTES.
 23.7.57
 $\frac{1}{1000}$ white
 $\frac{2}{1000}$ white
 $\frac{3}{1000}$ white

NOTE. 120

The large and small ovals represent the approximate size of normal blind spots as taken by the Scotometer and Perimeter respectively. The horizontal line represents the SCOTOMETER reading in degrees, whereas those on the vertical line represent degrees as measured by the PERIMETER.

Fig. 106. G.T.; Male; Age 16; Refraction:

L.E. -4.50 D.S. with -3.00 D.C.

Left eye. Typical superior temporal defect detectable with white targets up to 3 mm. at a metre. The defect is more dense than is usual at this age.

155

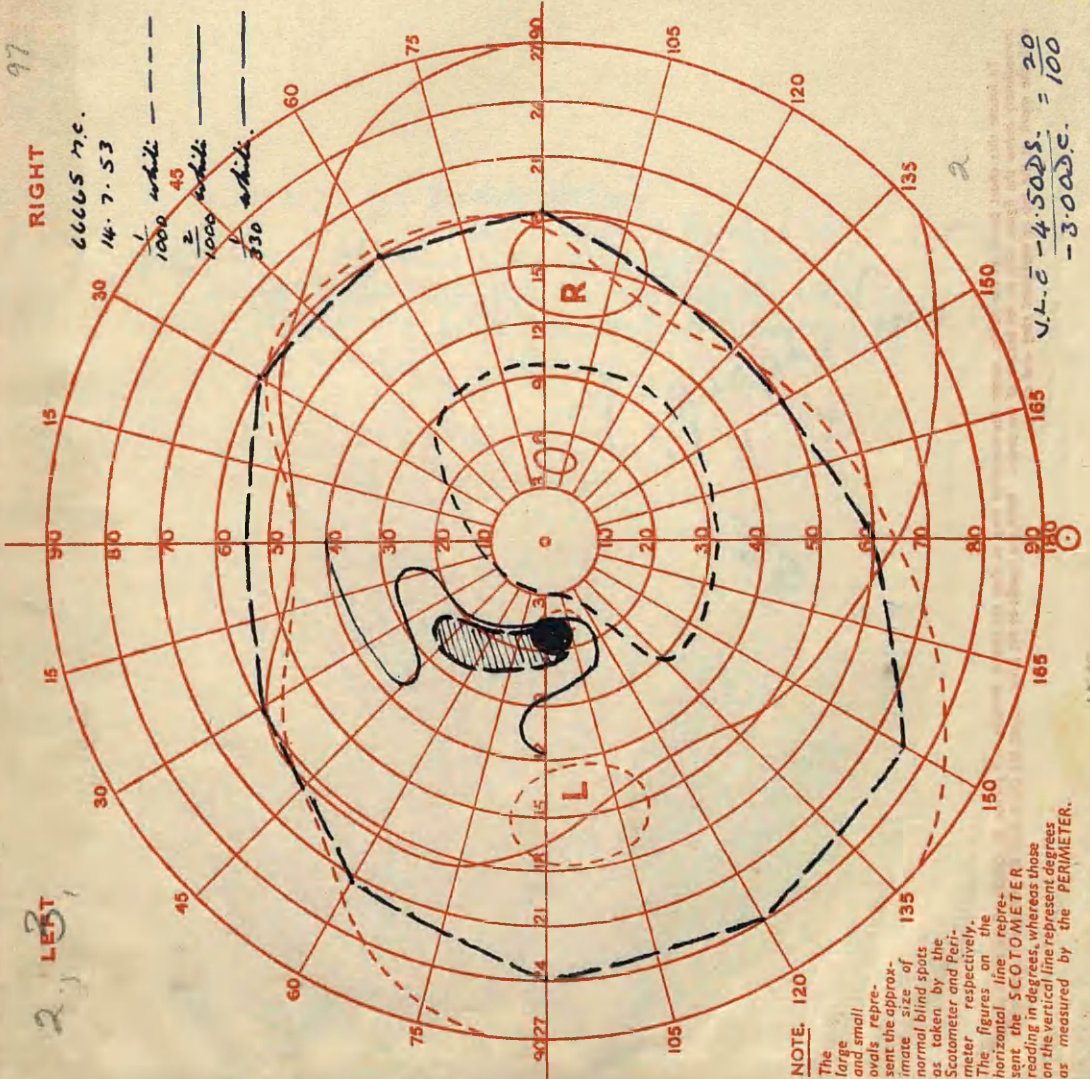
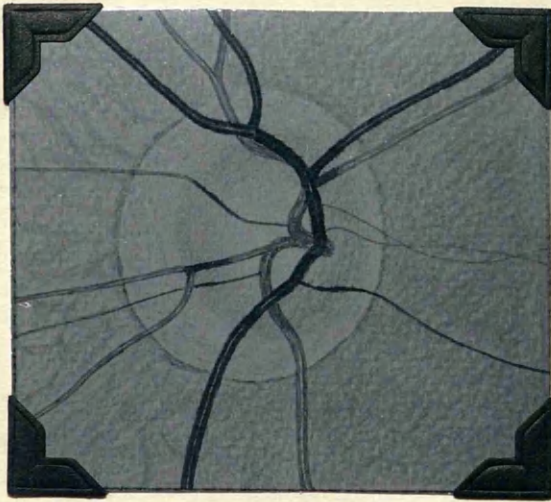


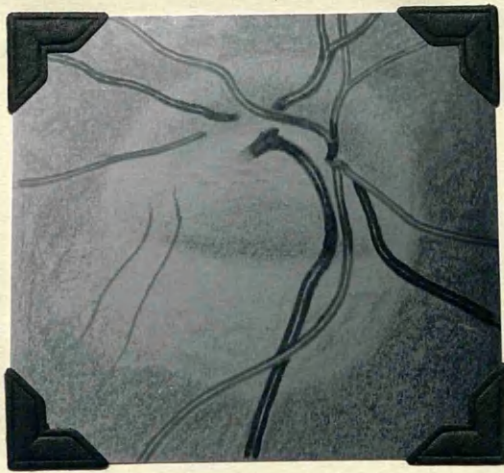




Fig. 107. I.D.; Female; Age ?; Refraction:
R.E. -1.50 D.S. with -0.50 D.C. 150°.
Right eye. Superior temporal defect with the isopter
for 2/1000 white indented but failing to reach the blind
spot. Isopter for 1/1000 white much constricted above.



157



92.

RIGHT

DOEMERTY.
B. 8. 51

- 1000 white ---
- 1000 white ---
- 330 white ---
- 380 white ---

LEFT

V.R. = 1.50 D.S. = 6/9
-0.50 D.S. 1.50

NOTE 120
The large and small ovals represent the approximate size of normal blind spots as taken by the Scotometer and Perimeter respectively. The figures on the horizontal line represent the SCOTOMETER reading in degrees, whereas those on the vertical line represent those as measured by the PERIMETER.

157

Fig. 108. G.S.; Male; Age 55; Refraction:

R. E. -8.00 D.S. with -1.00 D.C. 15°.

L.E. -5.00 D.S. with - 1.00 D.C. 90°.

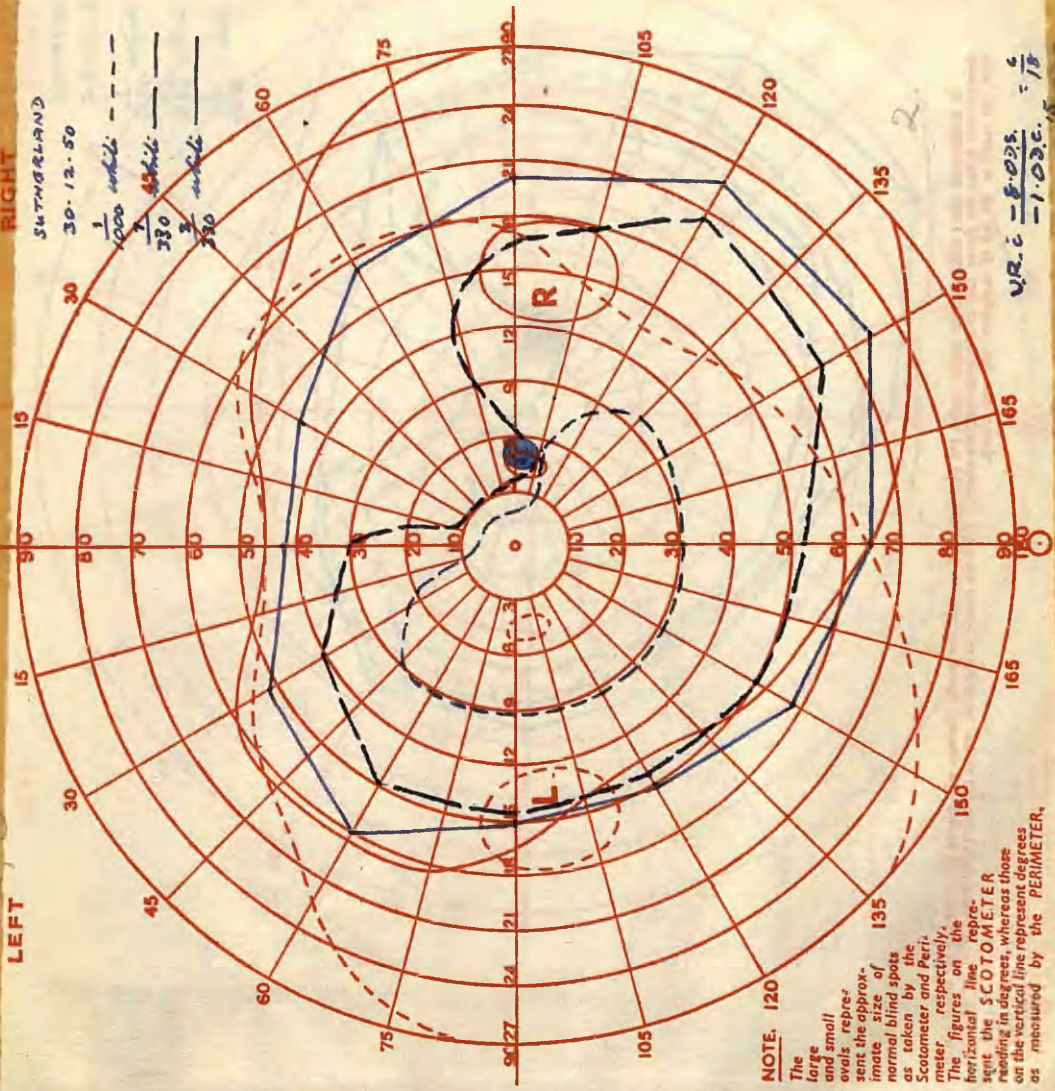
Typical superior temporal field defect showing increase and decrease in a period of a few months. The defect, in both eyes, crosses the midline at some stage and is of greater density than usual.

LEFT

RIGHT

SWITZERLAND
30. 12. 50

$\frac{1}{1000}$ white ---
 $\frac{1}{330}$ white ---
 $\frac{2}{350}$ white ---



NOTE. 120

The large and small ovals represent the approximate size of normal blind spots as taken by the Scotometer and Perimeter respectively. The figures on the horizontal line represent the SCOTOMETER reading in degrees, whereas those on the vertical line represent degrees as measured by the PERIMETER.

$$UR. C = \frac{5.025}{1.025} = \frac{5}{15}$$

LEFT


RIGHT
SUTHERLAND.

25-11-50

$\frac{1}{370}$ white

$\frac{2}{330}$ white

$\frac{3}{250}$ white



NOTE. 120

The large and small ovals represent the approximate size of normal blind spots as taken by the Scotometer and Perimeter respectively. The figures on the horizontal line represent the SCOTOMETER reading in degrees, whereas those on the vertical line represent degrees as measured by the PERIMETER.

$$V.R. = \frac{5.00 \times 2}{-1.00 \times 90} = \frac{6}{18}$$

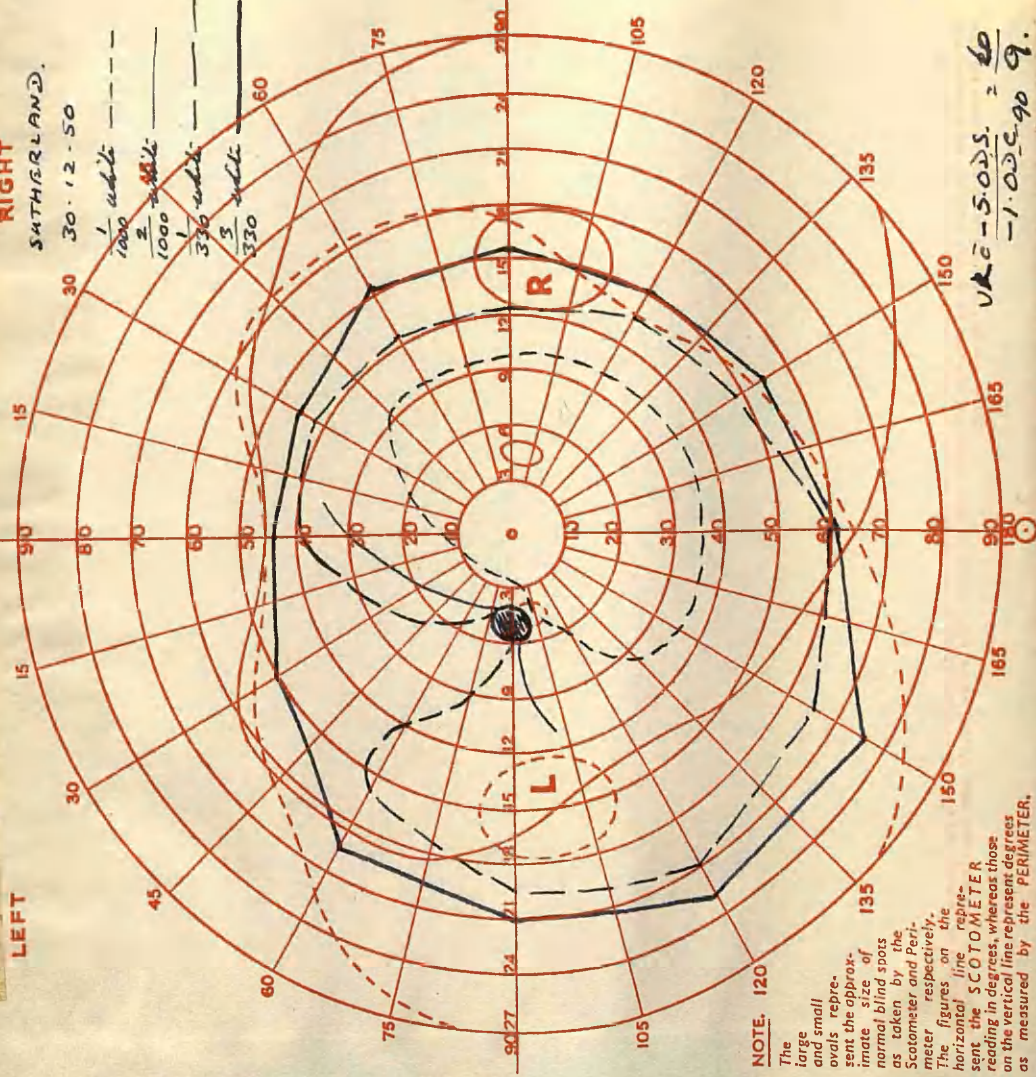
LEFT

RIGHT

SATHERLAND.

30. 12. 50

| | | | |
|------|---|-------|-----|
| 1000 | 1 | white | --- |
| 1000 | 2 | white | --- |
| 336 | 1 | white | --- |
| 330 | 3 | white | --- |



NOTE. 120

The large and small ovals represent the approximate size of normal blind spots as taken by the Scotometer and Perimeter respectively. The figures on the horizontal line represent the SCOTOMETER reading in degrees, whereas those on the vertical line represent degrees as measured by the PERIMETER.

PERIMETER AND SCOTOMETER CHART.

THEODORE HAMBLIN LTD., LONDON, W.1.


$$V.L. = \frac{5.025}{1.025} = \frac{40}{9}$$

LEFT

SATHERLAND.

24. 2. 51.

| | | | |
|------|---|-------|-----|
| 1000 | 1 | white | --- |
| 1000 | 2 | white | --- |
| 330 | 1 | white | --- |
| 330 | 2 | white | --- |
| 330 | 3 | white | --- |
| 330 | 3 | white | --- |



NOTE. 120

The large and small ovals represent the approximate size of normal blind spots as taken by the Scotometer and Perimeter respectively. The figures on the horizontal line represent the SCOTOMETER reading in degrees, whereas those on the vertical line represent degrees as measured by the PERIMETER.

PERIMETER AND SCOTOMETER CHART.

THEODORE HAMBLIN LTD.

$$V.L. = \frac{5.025}{1.025} = \frac{9}{9}$$


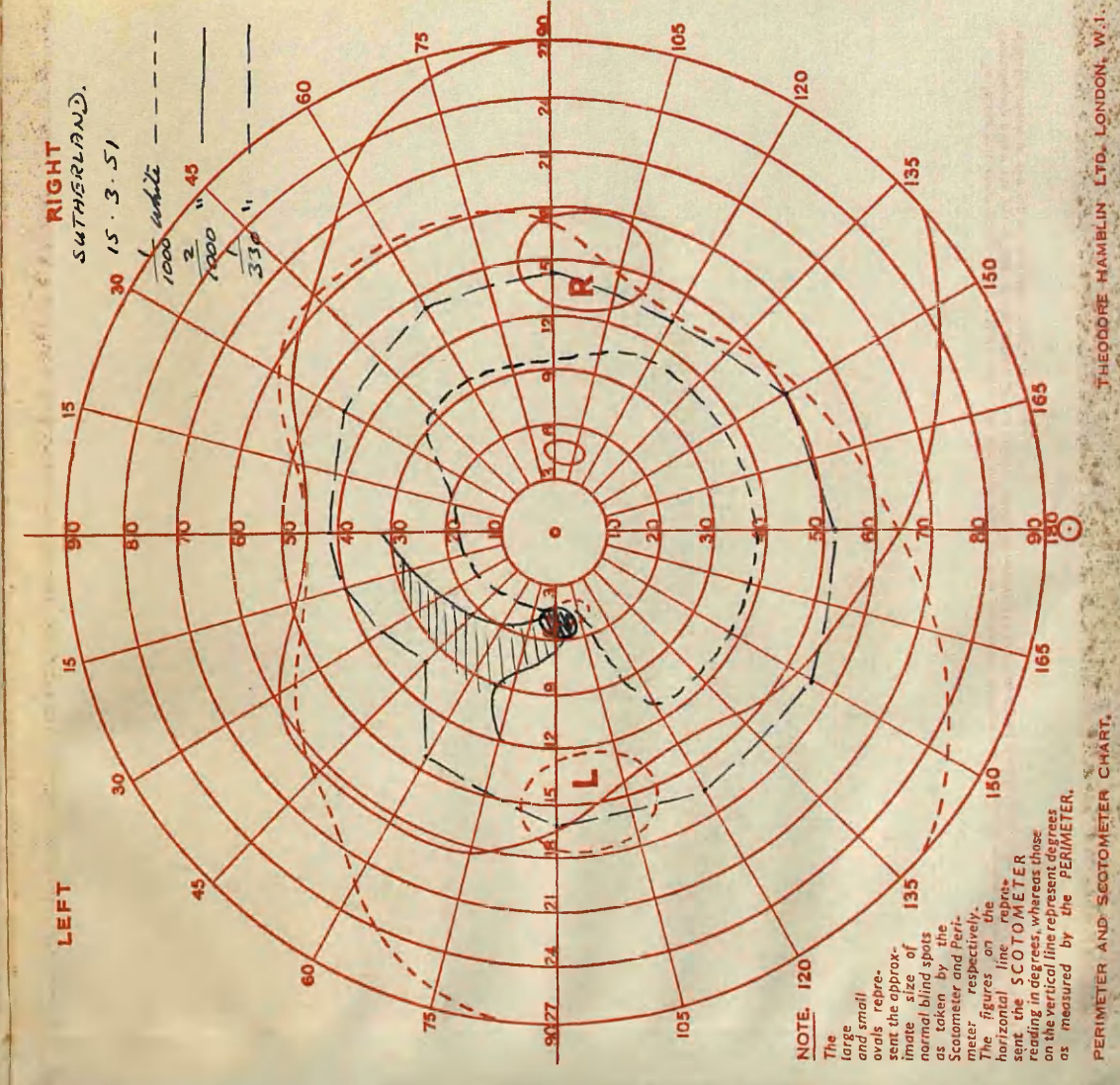
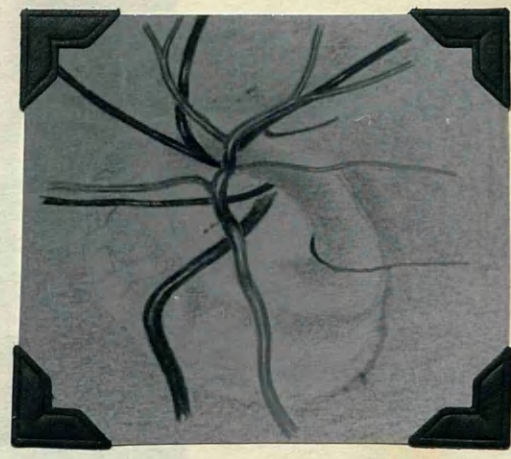
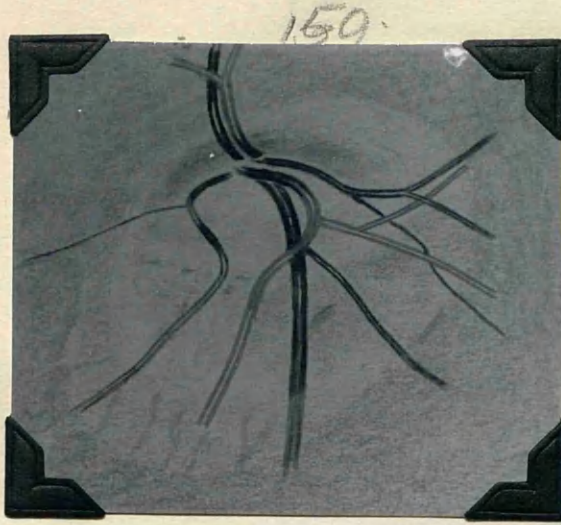


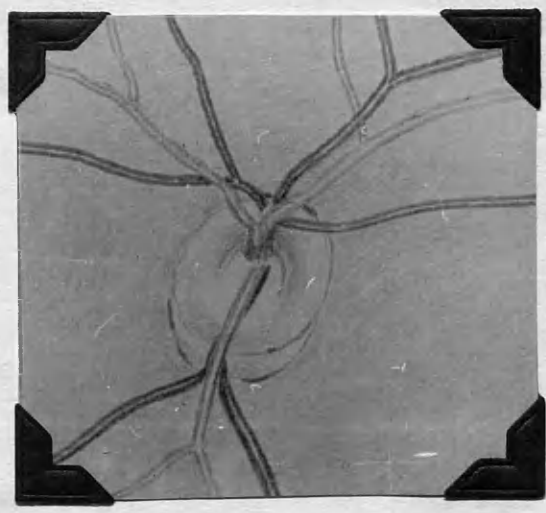


Fig. 109. J.H.W.; Male; Age 12; Refraction -2.00 D.C. 165°. Right eye. Drawings made before and after development of inferior crescent. The first was made on 2:2:53 and the second on 18:1:56. When the first drawing was done a note was made on this patient's record that he had no crescent and that there was no distinct margin to the physiological cup. The refraction on 2:2:53 was \neq 1.5 D.S. with -2.00 D.C. 180°.

109 a.



109 b.



167

REFERENCES

1. Heine, L. (1899) Arch. f. Augenh. 38, 277.
2. Shapland, C.D. (1953) Trans. Ophthal. Soc. U.K. 73, 205.
3. Joseph, H. (1936) Bull. Soc. Ophthal. Paris. P.420. June.
4. Elschmig, (1903) Arch. fur. Ophthal., 56(1), 49.
5. Beeler, A. (1929) Arch fur. Ophthal., 122, 342.
6. Worton, A.S. (1911) Ophthalmoscope, 9, 833.
7. Mann, I.C. (1923) Brit. Jl. Ophthalm. 7, 359.
8. Pickard, R. (1923) Brit. Jl. Ophthal. 7, 81.
9. Jayle, G.E. and Berard, P.V. (1955) Ann. Oculist. 188, 431.
10. Ruckmer, C. W. (1946) Arch. Ophthal. 35, 546.
11. Elwyn, H. and Knighton, W.S. (1943) Amer. Jl. Ophthal. 26, 969.
12. Hofmann, W.P. and Carey, E.T. (1942) Amer. Jl. Ophthal. 25, 1495.
13. Morgan, A.L. (1947) Canad. Med. Ass. J., 56, 406.
14. Brockhurst, R.J. (1955) Amer. Jl. Ophthal., 39, 808.
15. Mann, I.C., Development of the Human Eye, P.250. Cambridge University Press, (1928).
16. Sourasky, A. (1928) Brit. Jl. Ophthal. 12, 625.
17. Gleiss, J. and Pau, H. (1952) Klin. Monatsbl. f. Augenh, 121, 440..
18. Fletcher, M.C. and Brandon, S. (1955) Amer. Jl. Ophthal., 40, 474.
19. Cook, R.C. and Glasscock, R.E. (1951) Amer. Jl. Ophthal., 34, 1407.
20. Brown, E.V.L. (1938) Arch. Ophthal., 19, 719.

- 21. Kronfeld, P.C. and Devney, C. (1930) Arch. Ophthal., 4, 873.
- 22. Menestrina, G. (1926) Boll. Oculist., 5, 106.
- 23. Borley, W.E. and Tanner, O.R. (1945) Amer. Jl. Ophthal., 28, 517.