

**OBSERVATIONS ON THE CORONARY ARTERIES**

**Thesis Presented to the University of Glasgow  
for the Degree of Doctor of Medicine**

**by**

**William F. M. Fulton**

**B.Sc., M.B., Ch.B., M.R.C.P.**

---

**Glasgow.**

**1960**

ProQuest Number: 13850720

All rights reserved

INFORMATION TO ALL USERS

The quality of this reproduction is dependent upon the quality of the copy submitted.

In the unlikely event that the author did not send a complete manuscript and there are missing pages, these will be noted. Also, if material had to be removed, a note will indicate the deletion.



ProQuest 13850720

Published by ProQuest LLC (2019). Copyright of the Dissertation is held by the Author.

All rights reserved.

This work is protected against unauthorized copying under Title 17, United States Code  
Microform Edition © ProQuest LLC.

ProQuest LLC.  
789 East Eisenhower Parkway  
P.O. Box 1346  
Ann Arbor, MI 48106 – 1346



Thesis presented to the University of Glasgow  
for the Degree of Doctor of Medicine

---

OBSERVATIONS ON THE CORONARY ARTERIES

A STUDY OF THE ANATOMY OF THE CIRCULATION OF THE HUMAN HEART  
IN HEALTH AND IN DISEASE, AIDED BY STEREOARTERIOGRAPHY TOGETHER  
WITH OBSERVATIONS ON THE MICROANATOMY OF CORONARY ATHEROSCLEROSIS  
AND THROMBOSIS AND NOTES ON THE PATHOGENESIS OF THESE CONDITIONS

by

William F.M. Fulton, B.Sc., M.B.,Ch.B., M.R.C.P.

---

In this thesis are presented my observations on the coronary arteries examined by certain specially devised techniques. The first stage of the investigation was undertaken in 1952 and 1953, during the tenure of a Research Assistantship in Cardiology in the University of Edinburgh. The appointment was created on the initiative of Dr. A. Rae Gilchrist and was sponsored by the Atherosclerosis Committee of the Department of Health for Scotland. The work was carried out in the Departments of Pathology in the University of Edinburgh and the Royal Infirmary, Edinburgh.

The second stage of the investigation comprised the analysis and correlation of observations made in Edinburgh. This part of the work was pursued concurrently with the writing of the thesis during the course of my present appointment of Lecturer in Materia Medica and Therapeutics in the University of Glasgow, with clinical duties at Stobhill General Hospital, Glasgow.

The first stage:Scope and aims of the investigation as projected,

My terms of reference were unrestricted. The appointment was created for the investigation of pathological aspects of coronary artery disease. The scope of the examination and its objectives were neither defined nor directed. In preliminary discussion Dr. Gilchrist expressed the opinion that there was room for further study of this subject by the aid of an injection method. Subsequent experience has confirmed the wisdom of this suggestion and has convinced me that a comprehensive pathological examination of the coronary circulation demands not merely arteriography but arteriography which is three-dimensional. It will be apparent that injection and the preparation of stereograms were but the initial stages of my investigation of the heart and its arteries.

A preliminary survey of recent post-mortem studies revealed that the pathology of coronary artery disease had already been the subject of extensive investigation. It was evident that the literature abounded with records of injection studies of the coronary arteries, of surveys of gross pathological features of coronary heart disease, and of investigations of the intimate histology of diseased arteries. I soon formed the impression that previous investigators had concentrated mainly on one, or a selected few, aspects of this subject at a time. It occurred to me that correlation of all concurrently obtainable data in a small number of cases was a desirable alternative to selective observations on a large number of cases. While pursuing this objective I have had cause to reflect on the wisdom of those who have restricted the field of their observations within more manageable limits. When I set out on this journey of pathological exploration I did not realise how many fascinating problems would be uncovered and how many obstacles there would be to overcome.

The first step was the development of a method of examination which would meet the exacting requirements of the investigation which I projected. I aimed at achieving an arteriographic technique which would provide a three-dimensional view of the intact coronary circulation; would demonstrate even the smallest communication between arterial branches; would reveal small vessels, if any, in the diseased artery wall; would outline the detail of obstructive lesions and the processes of their canalization. At the same time I required that injected tissues should offer no technical difficulty on sectioning in the microtome; and that the histological structure and tinctorial characters of the myocardium and coronary arteries should not be materially altered. Further, I wished to preserve my findings in such a manner that I could study the original material repeatedly. In this way I hoped to ensure uniform interpretation of observations throughout the investigation, and also to be enabled to search the same ground anew as experience was gained and as discoveries were made.

The reader may judge for himself the extent to which these objectives were attained. I found no record in the literature of investigations which have sought to reveal at once in the same specimen, in gross and in minute detail, so many aspects of coronary artery disease; and which have thereby permitted correlation of the assembled pathological features of each case in the manner which I have attempted.

Note on originality of method.

The method which I elaborated is detailed in Chapter 1. Naturally various features were influenced by methods recorded by others but for the most part my technique was the outcome of original experimentation. In particular the preparation by precipitation of the injection medium,

upon which much depended, was entirely original; although I later found that precipitation had also been used by Shillingford (personal communication). The immersion method of radiography, likewise of importance, owed inspiration solely to Archimedes. The method of partial dissection of the heart was my own and, so far as I know, the method of block dissection and serial mounting of 2 mm. thick sections of the coronary arteries is without precedent.

Methods of stereoradiography were worked out by trial. Helpful advice on the choice of X-ray film was obtained from Kodak Ltd. and Ilford Ltd. It was not found possible to obtain satisfactory examination of larger stereograms with commercially available instruments. Accordingly, I designed and constructed a special stereoscope suited to this purpose.

I must express my gratitude to Professor A. Murray Drennan and Dr. R.F. Ogilvie for the facilities made available in the Departments of Pathology in the Edinburgh Medical School and for the welcome extended to me.

I wish to record my appreciation of the skill, careful work and cheerful cooperation of Mr. Stewart Rankeillor, technician in the Department of Pathology, University of Edinburgh, who undertook all the special histological preparation of coronary arteries and myocardium.

Histology of post-mortem tissues other than cardiac was undertaken by the technicians of the Pathology Department, Royal Infirmary, Edinburgh.

Selected sections were stained by additional methods at a later date by Mr. Ian Mackie, Department of Pathology, Stobhill General Hospital, by courtesy of Dr. J.C. Dick.

I am grateful also to the late Professor J.C. Brash for allowing me the use of radiological equipment in the Department of Anatomy in the University of Edinburgh, and to Dr. K.A. McKenzie for instruction in its operation.

Technical aspects of the first stage of investigation which were conducted personally included:

Design and construction of apparatus for injection, and other apparatus.

Design and construction of two special stereoscopes.

Post-mortem examination (with a few exceptions where only the heart was examined personally).

Preparation of injection medium.

Injection of the coronary arteries.

All aspects of partial dissection of the heart.

All aspects of radiography, including film processing.

Processing of tissues for gross examination, and serial mounting of 2 mm. thick sections of the coronary arteries.

Preparation of frozen sections.

Supervision of serial sectioning of selected arterial paraffin blocks.

Aspects of the investigation not personally conducted.

1. Histological preparation of tissues, including coronary artery blocks, for paraffin embedding, sectioning and staining. (See acknowledgement to technicians above.)
2. Clinical records. I am grateful for the high standard of documentation which made clinico-pathological correlation

possible; and to Dr. M.F. Oliver for discussing in detail the clinical and electrocardiographic features, in relation to my post-mortem findings, of cases which had been under the care of the Cardiology Department in the Royal Infirmary, Edinburgh.

The second stage of the investigation was started in Edinburgh but was carried out mainly after return to Glasgow in 1953. The time required for this part of the work and for the writing of the thesis were seriously underestimated. It entailed detailed review of material collected, and of observations made, during the preceding 2 years of full-time research. The work was pursued as opportunity presented during the years 1954 to 1960. Over this period all data have been reviewed several times. Photographic and other illustrations have been assembled and the manuscript prepared, concurrently with this study. Thus it comes about that I submit in 1960 observations and conclusions which were for the most part reached in 1953, though with less security. Much therefore that is presented in this thesis would have been the more noteworthy but for observations and opinions of others which have been published in the last few years. On the other hand it should be a matter of satisfaction to find my own views confirmed.

Note on the originality of observations.

I have tried so far as was feasible to observe and to form my own conclusions before consulting the literature extensively. Most of the observations which I have recorded were in fact original at the time they were made. I discovered in course of time that most of these observations had already been made severally by different authors.

As noted above, certain others have been subsequently described.

It is inevitable in a survey of this order that much of the work must lead simply to confirmation of established points of view. There remain however a number of features which do not seem to have been demonstrated or described hitherte.

I wish here to acknowledge the helpfulness of discussion with colleagues in the University of Edinburgh who expressed interest in my work, and the guidance given by them to a clinician struggling in the field of Pathology. In particular I recall the stimulus given to me by Dr. R.F. Ogilvie to pursue the thrombotic origin of atherosclerosis. At that time this was to me, and to most others, a new concept.

#### Presentation of observations in the thesis.

The thesis is presented in chapters. Apart from the first two, which are devoted to material and methods, each chapter is more or less self-contained and has its own summary at the end. Where possible I have tried to illustrate my observations by photography; and, where appropriate, to illustrate my data by graphs and my interpretation by line drawings.

In some instances I have drawn attention to certain features by means of drawings on transparent sheets, mounted in front of the photographs. In no instance has the photographic print, or negative, or radiograph been "touched up".

Aspects of the presentation undertaken personally include:

All line drawings, diagrams and graphs.

All photography of 2 mm. thick sections of coronary arteries, except colour transparencies.

Printing of some arteriograms.

Mounting and annotating of all but a few illustrations; and over-drawing on transparent sheets where used.

(The mounting of photographs on both sides of relatively thin paper cannot be regularly accomplished by dry-mounting processes. For this purpose I required to develop a special mountant, using a plastic base in organic solvents.)

Design of small stereoscope, to be found in back cover of Volume I.

Acknowledgement of technical assistance in the presentation.

I have been fortunate in the competence and willing cooperation of those who have taken part in the photographic illustrations of this thesis. The heaviest load has fallen on Mr. P.S. Waldie who, with the help of his assistants, has been responsible for most of the prints made from my arteriograms, including all the enlargements in Chapter 7, and for photography of all line drawings and diagrams throughout. I wish to record my gratitude for his careful workmanship, skill and, where needed, ingenuity. Results, however, are more eloquent than words. I record my appreciation of the most competent photographic support given me while still in Edinburgh from Mr. T.C. Dodds and his assistants; and in Glasgow by Mr. Donald McAllister, Mr. George Marshall and Miss Sheila Grace.



P.S. Waldie, and assistants, Department of Medical  
Photography, Stobhill General Hospital.

Prints from my arteriograms.

Photographic reproduction of all line drawings and diagrams.

Other photographs, Chapter 1.

T.C. Dodds, and assistants, Department of Photomicrography,  
University of Edinburgh.

Prints from arteriograms.

Photomicrographs (6).

Donald McAllister, Department of Physiology, University of Glasgow,  
by courtesy of Professor Garry and Dr. H.S.D. Garven.

Photomicrography.

George Marshall, Department of Anatomy, by courtesy of  
Professor Wyburn and Dr. Paul Bacsich.

Colour transparencies, Chapter 8.

Sheila Grace, Department of Materia Medica, section of  
Experimental Pharmacology, by courtesy of Professor Alstead and  
Mr. J.J. Lewis.

Printing of photographs of 2 mm. thick sections of  
coronary arteries, Chapters 7, 8.

---

Typing was carried out by:

Miss Janetta Hutton - Chapters 1, 5, 7, 8 and Introduction.

Miss J. Kennedy - Chapters 3, 4, 6, References and part of  
Chapter 2.

It is fitting to conclude this introduction with expression of gratitude to three persons:

Dr. A. Rae Gilchrist for the original concept of this investigation and for his continued support throughout its prosecution.

Professor Stanley Alstead for sustained confidence in the importance of bringing this work to completion; for making available certain departmental funds to facilitate its continuance after return to Glasgow; and for excusing me from a departmental literary commitment at a time which would have embarrassed the progress of this work.

Frances, my wife, for reading the manuscript; and for her patience and encouragement while witnessing a gestation exceeding in time that of the elephant.

---

- 2 -

## OBSERVATIONS ON THE CORONARY ARTERIES

### Chapter

- INTRODUCTION.
- 1. NOTES ON TECHNIQUE.
- 2. THE MATERIAL OF THIS INVESTIGATION.
- 3. NOTES ON THE ANATOMY OF THE CORONARY ARTERIES.
- 4. ARTERIAL ANASTOMOSES IN THE CORONARY CIRCULATION.
- 5. THE RELATIONSHIP OF CORONARY OCCLUSIONS TO MYOCARDIAL DAMAGE.
- 6. THE EXTENT AND DISTRIBUTION OF MYOCARDIAL DAMAGE IN RELATION TO THE PATTERN OF ANASTOMOTIC ENLARGEMENT.
- 7. CANALIZATION OF THROMBOTIC OCCLUSIONS.
- 8. THROMBOSIS AND ATHEROSCLEROSIS: *An Essay on the Genesis and Microanatomy of Atherosclerosis of the Coronary Arteries.*
- REFERENCES.

---

### Volume

- I. INTRODUCTION, CHAPTERS 1, 2 and 3.
- II. CHAPTERS 4, 5 and 6.
- III. CHAPTERS 7 and 8; REFERENCES.

## ILLUSTRATIONS

A list of illustrations is to be found at the beginning of chapters.

Some illustrations are grouped. For convenience of reference the location of certain main groups is noted below:-

### Chapter 2.

1. DIAGRAMS OF ARTERIOGRAMS.
2. STEREOGRAMS OF INTACT HEARTS.

### Between Chapters 7 and 8.

1. STEREOGRAMS OF ISOLATED CORONARY ARTERIES WITH ORIENTATED PHOTOGRAPHS OF SELECTED CROSS-SECTIONS ON OPPOSITE PAGE.
2. PHOTOGRAPHS OF 2 mm.-thick CROSS-SECTIONS OF CORONARY ARTERIES AND PHOTOGRAPHS, not interpolated elsewhere in the text.

### Chapter 8.

MOUNTED COLOUR TRANSPARENCIES OF 2 mm.-thick CROSS-SECTIONS OF CORONARY ARTERIES.

---

- C -

LIST OF LINE DRAWINGS

		<u>Page</u>
Apparatus for injection.	Fig. 1:1,2	1:8a
Methods of X-ray exposure.	Fig. 1:5	opp. 1:24
Partial dissection of the heart.	Fig. 1:8,9	1:29a
Incisions used in unfolding Basal Block.	Fig. 1:10,11	1:30a
Shadows cast by wires at various distances.	Fig. 1:14	1:47a
Diagrams of the coronary circulation.		2:16a -m
Subendocardial plexus of the left ventricle.	Diag. 4:1	4:20a
Phasic conditions of blood flow in deep vessels of left ventricle.	Diag. 4:2	4:20a
Examples of anastomosis counts.	Diag. 4:3,4	4:28a
Distribution of anastomoses in normal hearts.	Diag. 4:5	4:28b
Comparison of numerical distribution of anastomoses:		
in normal controls and total coronary group.	Diag. 4:6	4:28b
in coronary artery disease group, graded A,B & C according to duration of histories of angina.	Diag. 4:7	4:90a
Comparison of aggregate cross-sectional areas presented by anastomoses in normal hearts and in coronary artery disease.	Diag. 4:8	4:31
Comparison of potential capacities for blood flow through anastomoses in normal hearts and in coronary artery disease, graded A, B & C according to duration of histories of angina.	Diag. 4:11	4:90a
Subdivision of the coronary arteries.		5:8
Myocardial damage related to final episode of coronary artery occlusion and to previous narrowing.	Diag. 5:1	5:21b
The artery of death.	Diag. 5:2	5:46
Site of occlusions in 45 arteries.	Diag. 5:3	5:49a
Canalisation of thrombotic occlusion (1).	Diag. 7:1,2	7:14a
Canalisation of thrombotic occlusion (2).	Diag. 7:3,4	7:14b
Position of the new lumen.	Diag. 7:5	7:51a

LIST OF LINE DRAWINGS

		<u>Page</u>
An artefact of shrinkage.	Diag. 8:1	8:9
Evolution of the compound atherosclerotic plaque.	Diag. 8:2	8:10a
Distribution of lipid in atherosclerotic plaques.	Diag. 8:3	8:42a
Atheromatous abscess.	Diag. 8:4	8:42a
Intimal thickening and lipid accumulation.	Diag. 8:5	8:62
The intima as a filter.	Diag. 8:6	8:96

---

# CHAPTER 1

NOTES ON

# TECHNIQUE

## CHAPTER 1: NOTES ON TECHNIQUE

	Page
<u>INTRODUCTION:</u> Injection techniques.	1
Summary of method used in present investigation.	4
Summary of injection methods used by others.	5
<u>INJECTION OF THE CORONARY ARTERIES.</u>	
Apparatus for injection.	8
Technique of injection.	9
Comments on the technique of injection.	12
Preparation of the injection medium.	13
Comments on the preparation of the injection medium.	16
Characters of the injection medium.	17
Differential colours in the injection medium.	18
<u>RADIOGRAPHY OF INJECTED SPECIMENS.</u>	20
The limitations of arteriography.	20
Some details of the radiographic technique:	20
1. Resolution of detail and choice of film material.	20
2. Exposure and contrast.	23
3. Stereo-shift.	23
4. Reproducibility	23
The immersion method.	24
Summary of points in regard to radiography.	25
<u>STEREO-VIEWING.</u>	
Notes on the methods available.	26
A special stereoscope.	27
Stereo-viewing of smaller arteriograms.	28
<u>METHOD OF OPENING THE HEART FOR DEMONSTRATION OF VASCULAR CHANGES.</u>	
Notes on methods.	29
Detail of the method of partial dissection.	30
Discussion of the method of partial dissection.	33
Its application to general pathology.	35
<u>FURTHER RADIOGRAPHIC DEMONSTRATION OF THE CORONARY ARTERIES:</u>	36
In situ, and isolated by dissection.	
<u>METHOD OF EXAMINING THE STRUCTURAL CHANGES IN THE CORONARY ARTERIES THEMSELVES.</u>	
Other methods used.	37
Method used in this investigation.	38
Detail of method.	38
Glycerin-agar mounting medium.	42
<u>HISTOLOGICAL EXAMINATION OF THE CORONARY ARTERIES AND MYOCARDIUM.</u>	43
Methods used.	43
Notes on the correlation of arteriograms, mounted 2 mm. thick sections and histological sections of the coronary arteries.	44
<u>METHOD OF MEASURING ARTERIAL DIAMETERS ON THE RADIOGRAPHS.</u>	45



ILLUSTRATIONS: Chapter 1.

Figure 1:1	Apparatus for injection.(diagram)	page 1: 8a
2	Some details of injection apparatus.(diagram)	1: 8a
3	Arteriogram of intact normal heart: Conventional radiography.	1:23a' /
4	The same: Radiography by immersion method.	1:23b
4a	Stereocararteriogram of Atrial Cap, Transventricular Section and Apex.	1:23b
4b	Stereocararteriogram of Basal Block, unfolded.	1:23d
5	Methods of X-ray exposure. (diagram)	1:23d'
6	A special stereoscope.	1:27a
7	A stereoscope of Brewster type.	1:28
8	Partial dissection of the heart, first stages.(diagram)	1:29a
9	Portions of the heart yielded by partial dissection. (diagram)	1:29a
10	Incisions used in unfolding Basal Block. (diagram)	1:30a
11	" " " " " " (diagram)	1:30a
12A	Two examples of serially mounted 2 mm.-thick sections of coronary arteries.(monochrome)	1:39a
12B	The same. (colour transparencies)	1:39b
13	Radiograph of wires.	1:47a
14	Shadows cast by wires at various distances. (diagram)	1:47a

---

/ 1:23a,b, etc. refers to pages following p.1:23.

1:23a' " " obverse side of p.1:23a.

THE DEMONSTRATION OF CHANGES IN THE CORONARY ARTERIES  
WITH THE AID OF STEREO-ARTERIOGRAPHY

NOTES ON TECHNIQUE

INTRODUCTION

The injection of a radio-opaque medium into the coronary arteries after death, followed by radiography has been employed in the investigation of coronary artery disease by a number of workers since the beginning of this century.

The increasing prevalence of clinically important coronary artery disease prompted the present investigation, which was intended to take the form of a detailed survey of the pathological picture in a number of carefully documented cases. From the outset arteriography was used as an aid to analysis of the arterial changes. Gradually a comprehensive technique of investigation was evolved, which has permitted detailed investigation of the vascular changes without impairment of the morbid anatomical and histological picture.

In a review of the techniques already published it became apparent that most later workers investigating coronary artery disease by an injection technique have followed the method described by Schlesinger (1938). It was recognised that this method gave a useful demonstration of the main coronary vessels. Departure from it was however made early in this investigation for a variety of reasons, amongst which was the feeling that repetition of a method that had already been employed on a large scale was less likely to provide additional information than was an approach made by a different method.

It /

It is hoped that this point of view may have been justified by the results: for it seems that a more complete picture of the changes demonstrable by injection have been obtained by this than by other published methods.

The arteriographic technique to be described differs from those of previous workers mainly in three respects: the injection medium itself, the methods of partial dissection and the method of radiography. Other points of difference will be recognised in the detailed description. Emphasis will be placed on the value of stereo-arteriography, which was universally employed in this investigation.

The method as described has been employed for the greater part of a series of 25 cases of advanced coronary artery disease and 34 controls, of which 17 were of severe valvular disease or hypertensive hypertrophy and the remainder "normal". One case in the coronary group also had valvular disease. Two cases in the control group showed evidence of myocardial infarction, which was presumed to be embolic in origin.

It is realised that some details of the method to be described have been commonly employed by others and for the most part no attempt is made to separate these from features that are original or that are in disagreement with established practice.

Two points are emphasised at the outset. Firstly, the full technique as described is suited only to a detailed research investigation. It cannot be recommended as an adjuvant to routine post-mortem examination. In order to reproduce the results obtained in this investigation much time and meticulous attention to detail must be given to each case. There can be no question of presenting the radiograph of the dissected heart before the completion of the autopsy (cf. Schlesinger, 1938).

Secondly /

Secondly, while certain information may be derived from arteriographic evidence alone, the arteriographic picture has its main importance as a skeleton on which to position the changes found in the myocardium and arterial walls. Conversely, original interpretation of abnormal arteriograms can be made only on a basis of closely correlated and detailed examination of the tissue changes involved. For this purpose it is inadequate to rely upon memory and notes. It is desirable that the actual evidence be still available at the time the correlation is made, so far as may be possible. The degree to which this object was achieved in this investigation will be evident in the text.

A summary of the method which I used appears overleaf. It will be seen that with this technique the investigation is conducted in a progressive, integrated fashion; and the evidence obtained step by step is largely preserved. Not only does it allow a comprehensive pathological study of the changes in coronary artery disease, but also review and synthesis of the information held in the arteriograms, in the serially-mounted, arterial sections and other specimens, and in the micro-slides. A single observer could survey and correlate not only the recorded but the actual results obtained by several workers.

In this investigation however the entire technique was conducted personally, with the exception of the routine preparation of histological sections.

SUMMARY OF THE METHOD USED IN THE PRESENT INVESTIGATION  
OF THE CORONARY ARTERIES

In addition to routine pathology and histology the method included:-

1. Injection of the heart with a radio-opaque mass (Bismuth oxychloride in gelatin).
2. Radiography of the intact heart and inspection of the stereo-pair so produced.
3. Partial dissection of the heart into atrial "cap", apex, transverse section(s) and the "unfolded" basal block.
4. Stereo-radiography of these portions.
5. Isolation of the main arterial stems preceded by decalcification and followed by gelatin embedding.
6. Stereo-radiography of the isolated arteries.
7. Free-hand sectioning of each arterial block from end to end at 2 mm. intervals and mounting of the sections in series by a specially devised method.
8. Selection of blocks of special interest from this arterial series, preferably before mounting, and cutting, staining and mounting of frozen sections.
9. After frozen sections had been taken, the small selected arterial blocks were passed to the technician for paraffin embedding, section cutting, mounting in semi-serial grouping, and staining by several methods.
10. Myocardial blocks were also passed to the technician. These were taken from a number of selected sites, varying in different cases. In all cases of coronary artery disease an entire cross-section of the ventricles at a representative level was included. This was divided into portions for convenience in section cutting.
11. A representative cross-section of the ventricles, usually the neighbour of the previous one, was mounted as a specimen for reference.
12. Examination of all this information with documentation of results and correlation with the clinical findings.

SUMMARY OF PUBLISHED INJECTION METHODS

This list refers solely to published investigations of the coronary arteries and only to those which have included an injection method for purposes of visual or radiographic demonstration. References marked with an asterisk are quoted from Gross, "The Blood Supply to the Heart", 1921, or from Spalteholz, "Die Arterien der Herzwand", 1924. These works contain a larger list of investigations of historical interest. The other references have been examined in the original publications. Doubtless the list is far from complete.

Injection and Corrosion.

Hyrtl <sup>**</sup>	1855	Metal of low melting point.
Henle <sup>**</sup>	1866	" " " " "
Nussbaum <sup>**</sup>	1912	" " " " "
Whitten	1930	Collodion.
Wearn	1933	"
Smith and Henry	1945	Neoprene-latex.
Salans and Tweed	1947	Barium in Neoprene latex.
Wagner and Poidexter	1949	Nylon.
Van der Ghinst	1949	Plexene.

Injection and Clearing.

Spalteholz	1907-1924	Chrome yellow in gelatin.
Amenomiya	1910	Spalteholz' method.
Tandler <sup>**</sup>	1913	" "
Koch <sup>**</sup>	1922	" "
Gross	1921	Barium-Gelatin.
Winternitz et al.	1938	Indian ink, diluted in water.
Barboni	1956	" " " " serum.

Injection and Radiography.

Baumgarten <sup>**</sup>	1899	Bismuth Subnitrate and Starch.
L'Heureux <sup>**</sup>	1912	Lead - Collodion.
Schlesinger	1938	Lead phosphate - agar.
Zoll, Blumgart et al.	1951 etc.	" " "
Holyoke	1945	" " "
Ravin and Geever	1946	" " "
Brink	1949	" " "
Salans and Tweed	1947	Barium in Neoprene latex.
Scott et al.	1949	" " " "
Myers, Klein and Stofer	1948	

Injection and Stereo-radiography. /

Injection and Stereo-radiography.

Jamin and Merkel	1907	Red lead in gelatin.
Amenomyia	1910	" " " "
Smith	1918	Barium in Tragacanth.
Gross	1921	Barium sulphate - gelatin.
Crainiciamu	1922	Red lead in oil.
Oberhelman and Le Court	1924	Metallic mercury.
Ritter, Gross and Kugel	1928	Barium sulphate - gelatin.
Campbell	1929	Röntyum (Ba-emulsion)
Harrison and Paul Wood	1949	-
Shillingford	1950	Lead phosphate - agar.
		Bismuth - gelatin.
Snow et al.	1952	Lead phosphate - agar.

Miscellaneous Injection Methods.

Fr. Ruysch <sup>##</sup>	1704	Secret injection and maggot removal of tissues.
Lower <sup>##</sup>	1728	Masses passed from one coronary artery to the other.
Langer <sup>##</sup>	1880	Resin.
Hartman <sup>##</sup>	1881	-
West	1883	Gelatin - carmine.
Bianchi <sup>##</sup>	1885	Plaster of Paris.
Hoffman and Rauber <sup>##</sup>	1886	-
Sternberg <sup>##</sup>	1888	Coloured masses.
Koester <sup>##</sup>	1888	Leimassen and coloured fluids.
Neelsen <sup>##</sup>	1888	-
Dragneff <sup>##</sup>	1896	Teichmann's Mass.
Banchi <sup>##</sup>	1904	Plaster of Paris.
Piquand <sup>##</sup>	1910	not specified.
Hudson et al.	1932	-

intact heart provided by the paired radiographic comparison technique

with the corrosion specimen; and the detail revealed in the

stereopairs prepared from serials of the heart approaches the degree

of detail which can be obtained from the surface and internal structure

Note on clearing and corrosion methods.

The cardiac tissues may be rendered semi-transparent in a variety of reagents. The most effective of these methods involve the use of fat solvents (e.g., Spalteholz's Fluid) and for this reason was considered undesirable in an investigation which included examination of atherosclerotic lesions. It is evident from published photographs of specimens prepared by this method that clear visualisation of the injected vessels is restricted to within a few millimetres of the surface. The lesser degree of translucency conferred by glycerin has been used in the present investigation as an adjuvant to the examination of certain details but would have been inadequate for the primary investigation.

In corrosion methods the tissues are digested away in chemical reagents leaving the skeleton of the injected lumen of the arteries. While this method lends itself to the preparation of demonstration specimens and to the investigation of purely anatomical features, it is obvious that it is unsuited to a comprehensive pathological enquiry. And indeed, where the tissues have been destroyed before examination, no original interpretation of abnormal findings revealed by injection can be possible.

The stereo-arteriographic method used in this investigation does not share these objections. The three-dimensional view of the intact heart provided by the paired radiographs compares favourably with the corrosion specimen; and the detail revealed in the arteriograms prepared from portions of the heart approaches the degree obtainable by clearing methods near the surface, and exceeds it in the depths of the myocardium.



INJECTION OF THE CORONARY ARTERIESApparatus for Injection

A twin-manometer apparatus in principle similar to that recommended by Schlesinger (1938) was constructed. This is shown diagrammatically in Fig.(1) and no full description is repeated here.

Modifications were made in the delivery apparatus (Fig. 2). Test tubes of the usual bore ( $\frac{5}{8}$ " ) were drawn out at the end to form nozzles to which tubing could be directly attached. This had several advantages, the chief of which were the economy of medium and the ease with which the entire delivery apparatus could be kept submerged in warm saline.

Instead of the usual rubber tubing, fine-bore, translucent polyvinyl (P.V.C.) tubing was used. This light-weight, pliable tubing caused less back-lash strain on the cannulae tied into the sometimes delicate coronary ostia when the heart was handled. "Vinyl C" with a bore of 2 mm. and thin wall was generally the most satisfactory but "Vinyl B" with 1 mm. bore was also used.

The cannulae themselves were made from "Polythene" tubing. This was readily drawn in the cold to fit the plastic tubing, while the other end was moulded with the heat of a flame to form a bulbous flange. Polythene cannulae were more easily prepared than glass cannulae; were lighter and more radio-translucent; and the ligatures were less liable to cut through. On occasion the cannulae were sectioned with the artery.

The Technique of Injection /

FIGURE 1

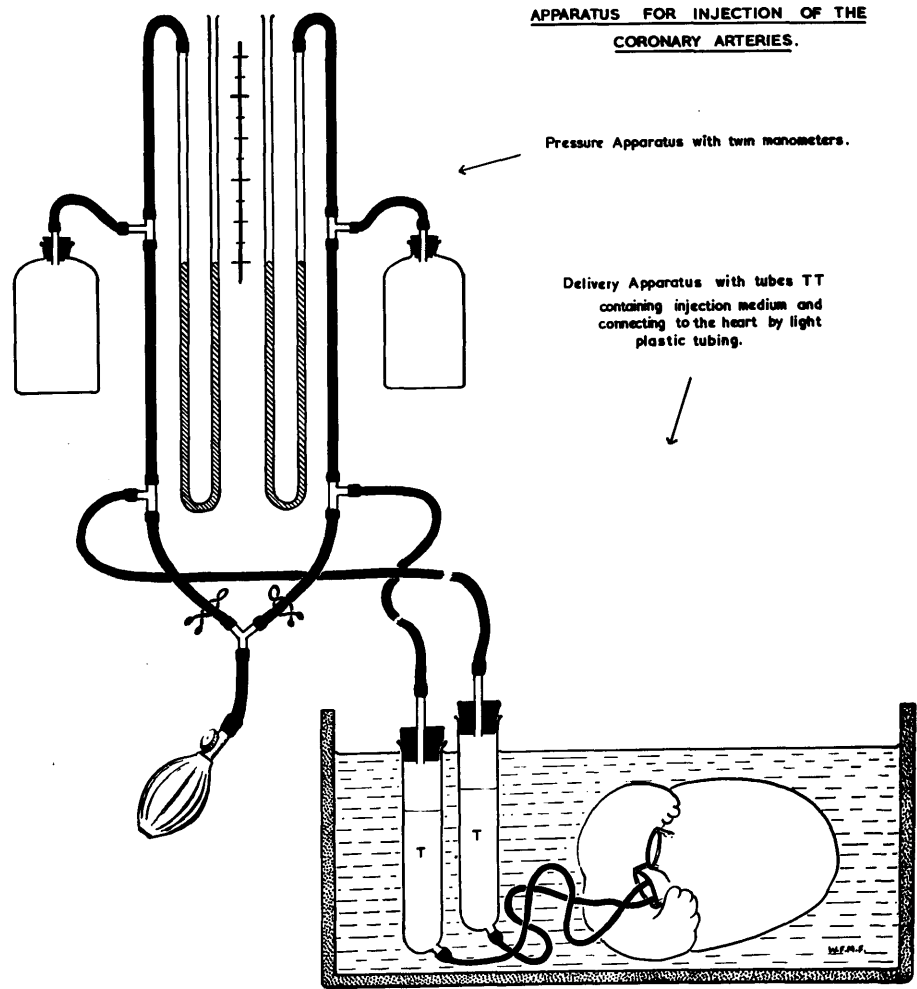
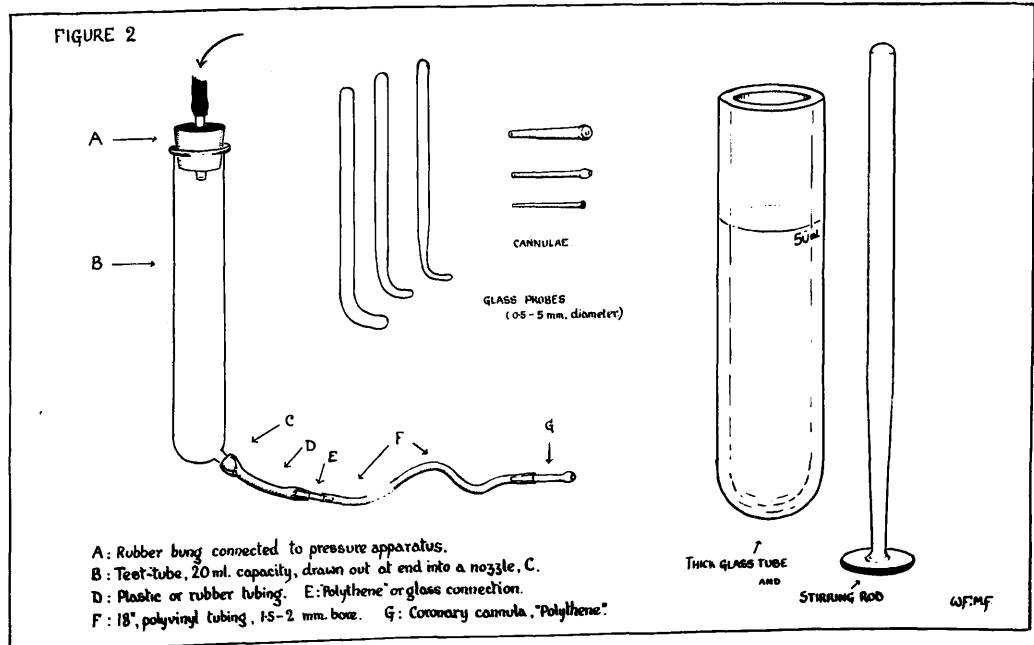


FIGURE 2



### The Technique of Injection

Injection was undertaken after rigor mortis had passed off and was usually performed 36-48 hours after death. Injection was occasionally performed in the presence of rigor, but the filling of the smaller vessels seemed to be less complete and less regular. In the case of very flabby hearts that had undergone autolytic softening, excellent injections were obtained; but in such circumstances the penetration of the medium was occasionally excessive, and even reached capillary level.

Curved glass probes were introduced via the aorta into each coronary ostium in turn. These probes were of graded size and the one which fitted snugly without force was used as a measure of the orifice and as an aid to guiding a ligature round the coronary artery, as closely as possible to the aortic wall. Catgut was found to be the most satisfactory ligature material.

The passage of the ligature round the coronary neck was sometimes a matter of great delicacy. A fine curved glass probe or hook was worked round the neck with the minimum of blunt dissection until its point was clear at the other side. Fine-bore plastic tubing was slipped over the point and drawn round the artery. The ligature was then threaded into the tubing and it in turn drawn through. This was found to be the most satisfactory method. Glass was used in preference to a needle or other metal instrument simply because the smoothness of surface made it less liable to damage the artery wall and the small vessels in its neighbourhood. In this way troublesome leakage when using a highly penetrating medium was largely avoided.

Before insertion the cannulae were connected to the delivery apparatus, and the tubes were filled with saline. The heart was submerged in warm saline and bubbles of air were encouraged to escape from the coronary arteries.

With /

With saline trickling from their ends, the cannulae were introduced into the coronary orifices. The ligatures were drawn tight and tied. A selection of cannulae allowed the use of one which fitted neatly into the ostium, which in different cases might be any size from less than 1 up to 6 mm. in diameter.

Before the injection of the radio-opaque medium a relatively small quantity (20-30 ml.) of saline was infused into each coronary artery. This was accomplished by raising each test-tube in turn to a height of 18 inches, accompanied by very gentle kneading of the heart along the line of the arteries and in the direction of the apex. The aim was to drive the remaining bubbles at least as far as the smaller arterial twigs, to wash through the anastomotic connections and to dilute the blood. The addition of a wetting agent to the saline appeared to assist this procedure and to increase the penetration of the injection medium later.

Perfusion of the heart with a large volume of saline is a common practice before injection. The volume was intentionally restricted in this technique after considerable trial. Extensive perfusion was not found to have any advantages, but had the disadvantage of promoting oedema of the post-mortem tissues. This in turn impaired both the arteriolar and anastomotic filling and the histological picture. Oedema was more readily induced by introduction of the saline under high pressure, and by simultaneous injection of the two coronary arteries.

The saline bath was maintained at approximately 35°-37° F., and injection was commenced when sufficient time had been allowed for the heart to have become warmed through-and-through. Ten-fifteen minutes was usually allowed for this. With a gelatin medium, temporary slight variations in temperature during injection appeared to have little influence on the result.

Disastrous /

Disastrous effects may occur when an agar medium is employed if any portion of the apparatus is allowed to cool below  $40^{\circ}$  C. and solidification takes place. Thermostatic control therefore is essential when using agar but has not the same importance where gelatin is employed.

After the medium had been melted and thoroughly stirred, the saline remaining in each test-tube was tipped out and replaced by about 20 ml. of injection medium. The quantity required by each artery varied greatly. Initially the medium was introduced into each coronary artery simultaneously and at the same pressure. Starting with 75 mm.Hg. this was worked up to 150 mm. as the vessels became fully charged. Where possible the direction and sequence of flow in the superficial arteries was observed and was often seen in the reverse direction below the level of an occlusion. Within 2-3 minutes of commencement of injection the pressure in the left coronary artery was lowered to 50 mm., so that a differential pressure of 150/50 mm. favoured the passage of medium from right to left through anastomotic channels. In cases of coronary artery disease quite brisk transference from one side to the other often took place. In normal hearts a slow movement of medium occurred. The appearance in the left coronary cannula of the red pigmented medium introduced into the right coronary artery proved the presence of arterial communication. This usually required about 2 minutes.

After a flow right to left had been established, or at any rate within 5 minutes, the procedure was reversed for a similar length of time. Pressures were then equalised at 150 mm. and maintained at this pressure for a period of 15 minutes.

At the conclusion of injection any medium that had leaked into the cavities of the heart was washed away by a jet of saline and the heart was immersed /

immersed in a bath of cold saline. The pressure within the apparatus was maintained until the heart had cooled thoroughly and the gelatin solidified.

Comments on the technique of injection.

1. The maintenance of pressure over a relatively long period is important; for in course of time fluid is expressed from the medium as it lies in the smallest vessels. In these vessels the concentration of the solid bismuth particles accordingly rises. When the particles are tightly packed together the radio-opacity of the medium is increased. This increase in opacity appeared to be greater than might be expected from a simple increase in total solid mass in a given fine vessel. Advantage was taken of this circumstance to obtain greatly improved pictures, in which the finest vessels were clearly visualised at the same order of exposure that also revealed detail in the larger vessels. That is to say, the larger vessels did not need to be "blacked out" by density in order that detail of the finer branches might be retained. Such pictures are not only more pleasing but are more informative.
2. Differential pressures should be used early in the course of injection, before the medium in the smaller vessels has become concentrated.
3. The greatest variable in an otherwise standardised procedure is the interruption of injection technique sometimes occasioned by leakage from atrial vessels that have been cut in removing the heart; or, in cases of infarction, from the necrotic area into the ventricles.

If care had been taken to excise the heart widely at all orifices, leakage at these points was uncommon, or was slight and unimportant. In a proportion of hearts, including, but not restricted to, cases of coronary disease, quite brisk leakage could take place in the region of the pulmonary artery, aorta and /

and the atria from vessels connecting with the mediastinal arteries.

Good injection of mediastinal structures, such as lymph nodes, demonstrated clearly the existence of anatomical communications between coronary and mediastinal arteries.

4. Leakage from an accessory right coronary artery, filled in retrograde fashion through anastomoses, was sometimes sufficiently copious to require its ligation. If small and situated very close to the right coronary artery itself, the accessory artery was usually caught in the ligature used to secure the cannula.

5. Thorough stirring of the injection medium without the introduction of bubbles was simply accomplished by the use of a plunger-type stirring rod, which fitted the tube loosely (Fig. 2).

6. With my injection medium it was found possible to obtain satisfactory filling of the coronary vessels with pressures not exceeding 80 mm.Hg.

The pressure of 150 mm.Hg. was not abandoned however once it had been adopted as the standard. Occasional instances of rupture of the intimal wall were thought possibly to have been related to over-stretching, and it might therefore have been preferable to have adopted a lower standard injection pressure. Nevertheless, it may be noted that Schlesinger injected the coronary arteries at 200 mm.Hg., while Winternitz et al. used pressures up to 1000 mm.Hg. for the same purpose.

#### The Preparation of the Injection Medium

Difficulty was experienced in obtaining a commercial preparation of reliably fine grain size and complete absence of larger particles. Bismuth oxychloride was selected as being the most suitable, and was recommended by Hill (1929) who used a commercially milled preparation suspended in gum acacia. Among the preparations used by other workers are - Ba. Sulphate in gelatin (Gross, 1921) /

(Gross, 1921) and lead phosphate in agar (Schlesinger, 1938).

Barium sulphate was found to require a concentration of more than 30% wt./vol. to give a shadow of sufficient density, and at this concentration the medium was too viscous to penetrate the smallest vessels. Gelatin was used as it is more easily handled as an injection medium than agar, has reliably good penetration and is a good suspending medium for bismuth granules. Under the climatic conditions in which it was to be used the tendency to melt at laboratory air temperature, such as might be encountered elsewhere, gave rise to no difficulties.

It was felt that the most certain method of ensuring the absence of any large particles and at the same time of obtaining very fine grain size, was to prepare the medium by precipitation. It was fortunate that in the case of bismuth oxychloride, which was selected for its other properties, preparation by precipitation may readily be accomplished. The method which was devised is as follows:-

100 Gm. bismuth oxychloride were dissolved in concentrated hydrochloric acid, forming bismuth chloride. Bismuth chloride is stable in excess of chloride ions. The concentration of chloride ions was maintained on the addition of a concentrated solution of sodium chloride. About 85 ml. of conc. HCl. were required to dissolve the bismuth oxychloride, when several volumes of 18% sodium chloride<sup>π</sup> had been added. When dissolved the solution was made up to 800 ml. with 18% saline.

Diluted in this way the solution was suitable for filtering through fine cloth. The filtered solution was then added in a steady flow to a large volume (20 litres) of filtered tap-water under vigorous agitation.

<sup>π</sup> (18% saline was used simply because it was kept available in large quantities for the preparation of normal saline by dilution 1:20. )



(No trials were made with water from different districts). The cloud of bismuth oxychloride so formed was allowed to sediment and most of the supernatant fluid was syphoned off. The precipitate was placed in a 1000 ml. cylinder for more complete sedimentation. The volume of the precipitate had usually fallen to 500 ml. in the course of 24 hours, and often in a much shorter period. After thorough stirring the precipitate was divided equally into ten tubes. The tubes were of thick glass, suitable for centrifuging if need be, and had a capacity of 60-70 ml. They were marked at 50 ml.

The sediment in the tubes was now spun down in the centrifuge at low speeds until its volume was about 30 ml. This could also occur on standing but sometimes took weeks. Tight packing of the precipitate was avoided.

After a measured volume below the 50 ml. mark had been removed the tubes were warmed in a water bath at about 50°C. The volume was then restored to 50 ml. by the addition of filtered, hot, concentrated gelatin, such that its final concentration was between 5 and 15% (No exact figure for the strength of gelatin is given, for this varies with the different brands, and may be adjusted until the optimum concentration is found). In this investigation with the batch of gelatin used, 15 ml. of 30% wt./vol. were added to give a total volume of 50 ml. In making the calculations the volume occupied by solid bismuth has been ignored. Finally 1 drop of wetting agent may be added.

The medium prepared in this way had the following composition:

Bismuth oxychloride	20%	(10 Gm.)
Gelatin	9%	
Sodium chloride	0.5%	
Hydrochloric acid	0.3%	
Thymol (added to the gelatin in its preparation)		
Wetting agent (added)	1 drop	
Water	to	50 ml.

Comments on preparation of injection medium.

- (1) The volume of water to which the medium is added should be of the order of 20 litres. If this is inconvenient the medium may be precipitated in moities and then pooled.
- (2) It will be noted that no washing has been carried out and no addition of any chemical takes place before mixing with gelatin. Once the precipitate has been formed the addition of water or any other substance seems to encourage aggregation of particles.
- (3) Excess of chloride ions together with slight acidity are intentionally preserved, for under these conditions bismuth oxychloride appears to be more stable. If complete neutralisation (or worse, alkalinisation) is effected, in course of time solid aggregations of bismuth particles form and ruin the medium for fine injection. This change is thought to be associated with the formation of hydroxides of bismuth.
- (4) The amount of acid remaining in the bismuth-gelatin medium appears to have no deleterious effect on the tissues. Tissues injected with this medium according to the method described have not been found impaired for histological examination beyond the degree shared by uninjected tissues in which fixation has not been possible until 36-48 hours after death. Where, however, the dense injection medium remained in close contact with the endothelium, this structure was sometimes obscured. Also in larger vessels differential shrinkage sometimes led to the detachment of the endothelium, where the endothelium remained adherent to the injection mass.
- (5) The addition of wetting agents to the water before precipitation may be of benefit but is not essential. Wetting agents incorporated in the medium appear to improve the evenness of penetration. It seems that

penetration is definitely increased and made more reliable by the addition of wetting agent to the initial saline infusion.

"Tween 80", "Teepol" and Ilford "Wetting Agent" have been used for this purpose.

(6) The incorporation in the medium of gums, acacia and arabic, was tried without evident advantage over gelatin alone, where a suspension of such fine grain size was used.

(7) Perfusion with dilute gelatin or gum acacia was tried in the place of saline and seemed to impair the penetration of injection medium.

(8) Covered and stored in the dark, the medium will keep for many months, provided there is sufficient thymol to prevent mould. Used according to the method described 100 Gms. bismuth oxychloride is sufficient for the injection of 10-15 hearts, provided that leakage during injection is not excessive.

#### Characters of the injection medium.

The particle size was in the region of 0.5 - 2.0 microns but loose aggregation of particles to form clumps 10 - 12 microns in diameter took place. This may not have been a disadvantage for it possibly limited penetration into capillaries while giving regular filling of all but the very finest arterial channels. When the method of injection was used as described, good penetration of vessels of 10 - 15 microns lumen diameter was regularly obtainable. Except in traces, capillaries were rarely entered. Traces of medium occasionally entered veins, where it could be detected in the histological section. The dilution however was always so great that no appreciable radiological shadow was cast. Veins were only entered in regions of severe myocardial damage where there were extensive changes in the small vessels.

Radiological visualisation was obtained of vessels down to 15 - 20 microns as measured on the film. These measurements were made by micro-projection onto a scale. Direct measurements were also made from frozen sections which had been fixed in formalin, in preference to paraffin sections in the preparation of which considerable shrinkage occurred.

The concentration of gelatin used was sufficient to hold the bismuth particles in place under dissection, and the medium cut well with the microtome knife. There was practically no dispersion of particles over the surface of the section.

#### Differential Colours in the Injection Medium

It is helpful to use contrasting colours to trace the course taken by the media injected into the two arteries. Diffusible dyes have been commonly used for this purpose but interfere with the naked eye examination of the tissues and tend to be discharged by the reagents used in fixation and decalcification. A search for suitable pigments of fine particle size was accordingly made.

Finely divided vermilion was entirely satisfactory. The colour of vermilion is a rough guide to the particle size and only the orange ranges were suitable. In order to remove the larger particles, which were present in all the commercial preparations tried, the vermilion was thoroughly mixed with a solution of a wetting agent and then diluted in moieties with larger volumes of water, in which it was filtered through fine cloth. No force or rubbing was used, and no suction. In this process considerable loss of vermilion occurred. After concentration of the filtered vermilion by

sedimentation it was stored in 15% gelatin 50% wt./vol. (approximately). Vermilion packs tightly and is much denser than water, so that a rough guide to the quantity was obtained by placing the sediment in a weighed tube, and, after settling, the supernatant fluid was tipped off and the container weighed again. As required a small quantity was added to a tube of bismuth medium. In practice it was found that the quantity of vermilion required was so small that only if a very strong colour were desired would it be necessary to make allowance for the radio-opacity of the added vermilion. Bismuth oxychloride and mercuric sulphide did not appear to react with one another physically or chemically, under the conditions used.

A blue pigment makes a good contrast with vermilion and for most purposes one of the ferrocyanide or Prussian blue preparations is very satisfactory, save for a slight tendency to diffusion and staining of the artery wall. However, for the purposes of this investigation Prussian blue was also unsuitable, lest confusion occur with the Prussian blue reaction later to be used on the histological sections of the arteries. Unfortunately, nearly all permanent blue pigments are of this composition. Ultramarine also gives a good colour contrast, but is discharged by decalcifying fluids. A satisfactory pigment which is not of ferrocyanine composition and which in addition stands up to the criteria of fine division, permanency in the reagents used, and good contrast with vermilion has not been found. A variety of pigments used in art materials and biological injection media were tried and discarded.

In the greater part of this series it was the practice to introduce vermilion-tinted medium by the right coronary cannula and untinted pure white medium by the left. It was not difficult to distinguish the paler shades that occurred on mixture of the media. Often stream-lining made this finding more pronounced. Right to left shunt was always used first and the second reversal never succeeded in removing all traces of right coronary pigment that had entered the left coronary territory.

RADIOGRAPHY OF INJECTED SPECIMENS

Radiography of injected specimens was introduced at the close of last century and the first important published demonstration of the coronary arteries by this method was made by Jamin and Merkel (1907). Most recent workers have employed two dimensional views of the "unrolled" heart (Schlesinger, 1938 and others). Stereoscopic views of the whole heart were used by Gross (1921) and by Snow et al. (1952). In addition, radiography of portions of the heart was used by Campbell (1929) and Gross and Kugel (1933-34).

In the present study the possibilities of stereo-radiography have again been explored and techniques of radiography and of dissection followed by radiography of finer detail have been devised. These are thought to have made some advance over previously existing methods. Of particular note is the method used for the elimination of tissue shadow.

The Limitations of Arteriography

A refined stereo-radiographic technique was found capable of demonstrating in the ventricular wall the great majority of arterial vessels down to about 20 microns in diameter, as measured on the film. Detail of measurements will be discussed later. In this investigation it was found that a high quality stereogram viewed at magnification was not only a reliable but, in the case of the smaller anastomoses, the only available method of examination that was without objectionable features. These remarks are in direct contrast to the views expressed by Schlesinger (1938) who placed little reliance on the roentgenogram for the recognition of anastomoses (See also pp.4:40-51, where the position is discussed critically in detail). It is to be noted that radiological demonstration by his technique was evidently not obtained of vessels less than 200 microns in diameter; moreover there is no mention of

stereo-viewing.

These are important differences. It is to be emphasised that the two dimensional view is almost entirely unreliable in demonstrating arterial communications. Only occasionally can one be certain that apparent continuity is not due merely to superimposition, a point that was well appreciated over 30 years ago (Crainiacianu, 1922).

### Some Details of Radiographic Technique

In principle stereo-arteriography is simple. In practice there are many snags and it is thought that most of these have been overcome in the course of this investigation.

#### 1. Resolution of detail and the choice of film material.

Where an injection of high penetration is used, the critical demands made on radiography are increased. Using a tube with a focal spot of 1 sq.mm., a long tube distance was required - 60 inches tube distance was employed in the radiography of the whole heart, 40 inches for the unrolled heart and transverse sections, and 30 inches for the isolated coronary arteries.

The choice of film was of paramount importance. It was pointless to prepare a specimen of the finest detail and then to use a film which was unable to record it. Brilliant pictures were initially obtained on standard X-ray films (such as "Ilfex") but these films are necessarily of coarse grain and did not stand magnified viewing. Less brilliant but more informative pictures were obtained on finer grain films such as Ilford "Industrial B" and "Kodirex". These films required an exposure of at least twice that of standard film, and were used for the radiography of the unopened heart, as a compromise between resolution of detail and exposure time. Even better results could be obtained

on crystallography film but for the unopened heart the exposure required was unduly long.

For the radiography of the selected portions of the heart where not more than a single thickness of myocardium was present, and where it was essential that the available detail be viewed at higher magnification, a film of finer grain was desirable. But, of course, finer grain could only be obtained at the expense of increased exposure time. Ilford "Industrial C" and Kodak "Crystallex" were found to be satisfactory.

The crystallography films mentioned left little to be desired for the purposes of this type of investigation. Where however it was required to record the finest detail obtainable with the injection used, and without using extremes of exposure times, greater resolution was obtained by using process film. When enlargements were made, the single coating of these films had some advantage over the double-coated X-ray films. Accordingly the use of process film was made routine practice in the radiography of isolated coronary arteries, in which detail of vasa vasorum and intimal vessels was desired (See Chapter 7).

Fine-grain developers increased the resolving power of the emulsion but entailed a longer exposure. Accordingly they were little used.

Several other photographic films were tried, with orthochromatic and panchromatic emulsions, and none were found to compare favourably with process film. Films such as "Kodakline" and "Maximum Resolution" film were not tried on account of their extreme slowness. The demonstration of micro-radiographic detail such as was obtained by Barclay ("Microarteriography", 1951) was outwith the scope of this investigation. Had a medium which penetrated the capillary-bed been used, radiography of the gross specimen would have been valueless.



## 2. Exposure and contrast.

For best contrast exposure can be reduced and development time increased within limits. If this principle was carried to excess impaired results were instead obtained. Best contrast was obtained at lower K.V. ranges. In this investigation 35 K.V. at 75 M.A. was used, being the lowest available on the apparatus. Specification of the apparatus used: "Dynamax 25", Fine focus = 1 sq.mm.

## 3. Stereo-shift.

Stereo-shift should not be excessive. A shift of 3 inches to either side of the centre was found satisfactory at 60 inches tube distance and 2-2½ inches at 40 inches tube distance. The exaggerated effects of increased stereo-shift were sometimes used to advantage with thin portions of tissue.

## 4. Reproducibility.

This was a matter of the greatest importance when results came to be recorded. The varying thicknesses of myocardium cast tissue shadows on the film, causing a wide range of density and contrast in the vascular shadows in different areas. For this contrast range on film material the eye has no difficulty in making adjustment; but no photographic paper has sufficient latitude to record it. The contrast range of film is so great that this point was not properly appreciated until paper reproduction was attempted. It is evident from the published reproductions of arteriograms, that this difficulty has been encountered by other workers and has either been accepted or only partly overcome. It was found that denser medium allowed the use of more penetrating radiography, and in this way the soft tissue shadows could be rendered relatively less conspicuous; but only at the expense of detail of the smaller vessels. An example is shown in Fig.3.

Early in this study attempt was made to overcome the difficulty encountered

# ARTERIOGRAMS OF A NORMAL HEART

NOTES ON Figures 1:3, 1:4, :4a, :4b

Figures 1:3 and :4 are prints made from radiographs of the same injected heart, taken by different methods. In either instance, the best quality of print obtainable has been faithfully prepared without resort to local shading, reduction or other photographic subterfuge.

In figure :3 the central area of the left ventricle has been obscured by dense tissue shadow ; while at the margins lack of tissue shadow has led to loss of arteriographic detail. Figure :4 shows the extent to which the immersion method has overcome these disadvantages.

The radiographic methods which were used are illustrated in figure 1:5. The principles involved and the importance of the immersion method for photographic reproduction of arteriograms are topics which are discussed in the text.

---

Figures 1:4a and :4b show stereo-grams of the portions of the heart displayed by the first stages of dissection : atrial cap, transventricular section, apex and basal block.

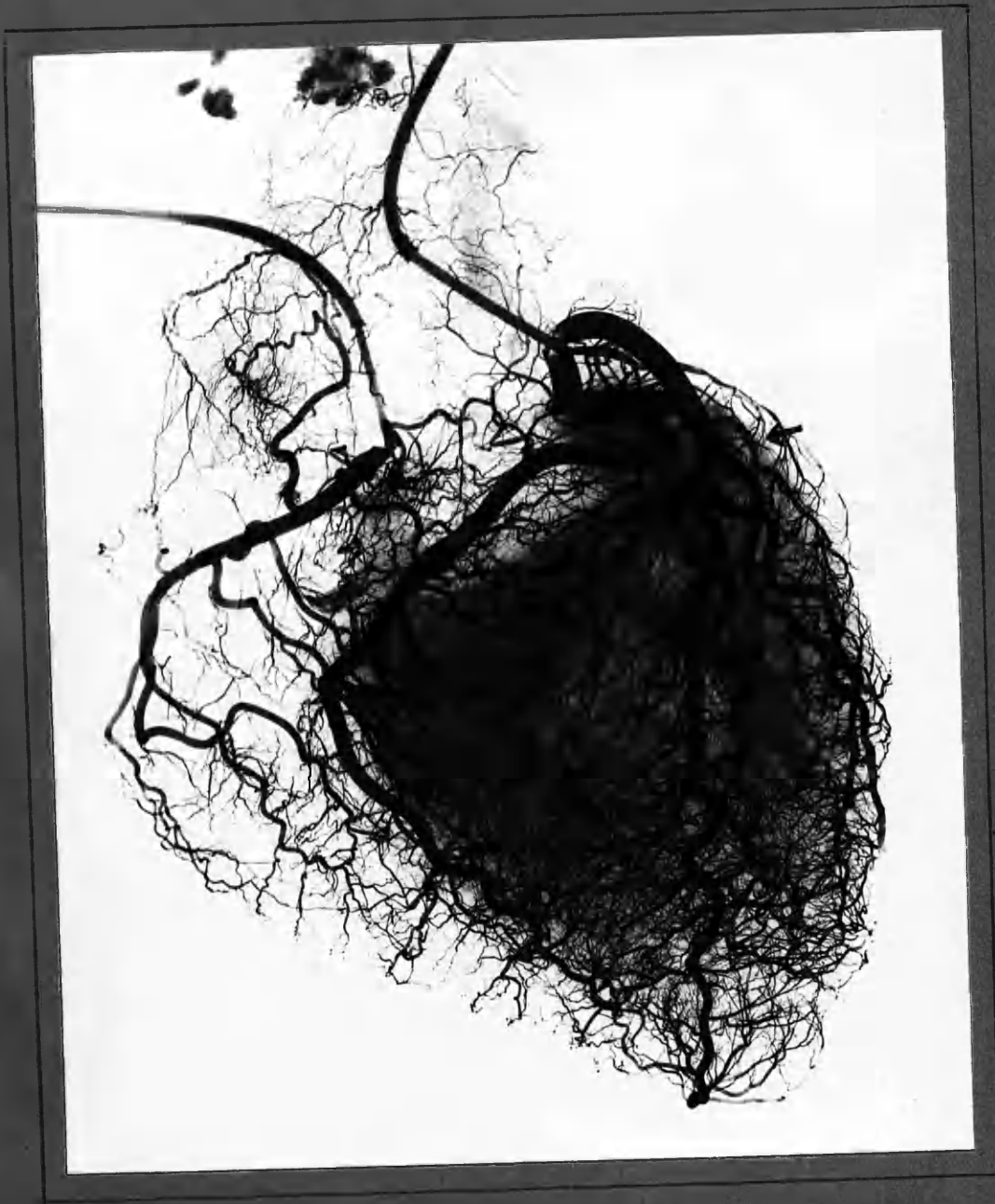
All these portions were placed together in the dish, immersed in saline. A single pair of X-ray exposures provided satisfactory arteriograms, despite the disparity of thickness in the several specimens. This is a further advantage of the immersion method.

---

A gap in the continuity of a branch of the left circumflex coronary artery may be observed. This lies between two ligatures which were applied before injection . Filling of the artery distal to the ligatures took place rapidly in retrograde fashion through arterial communications.

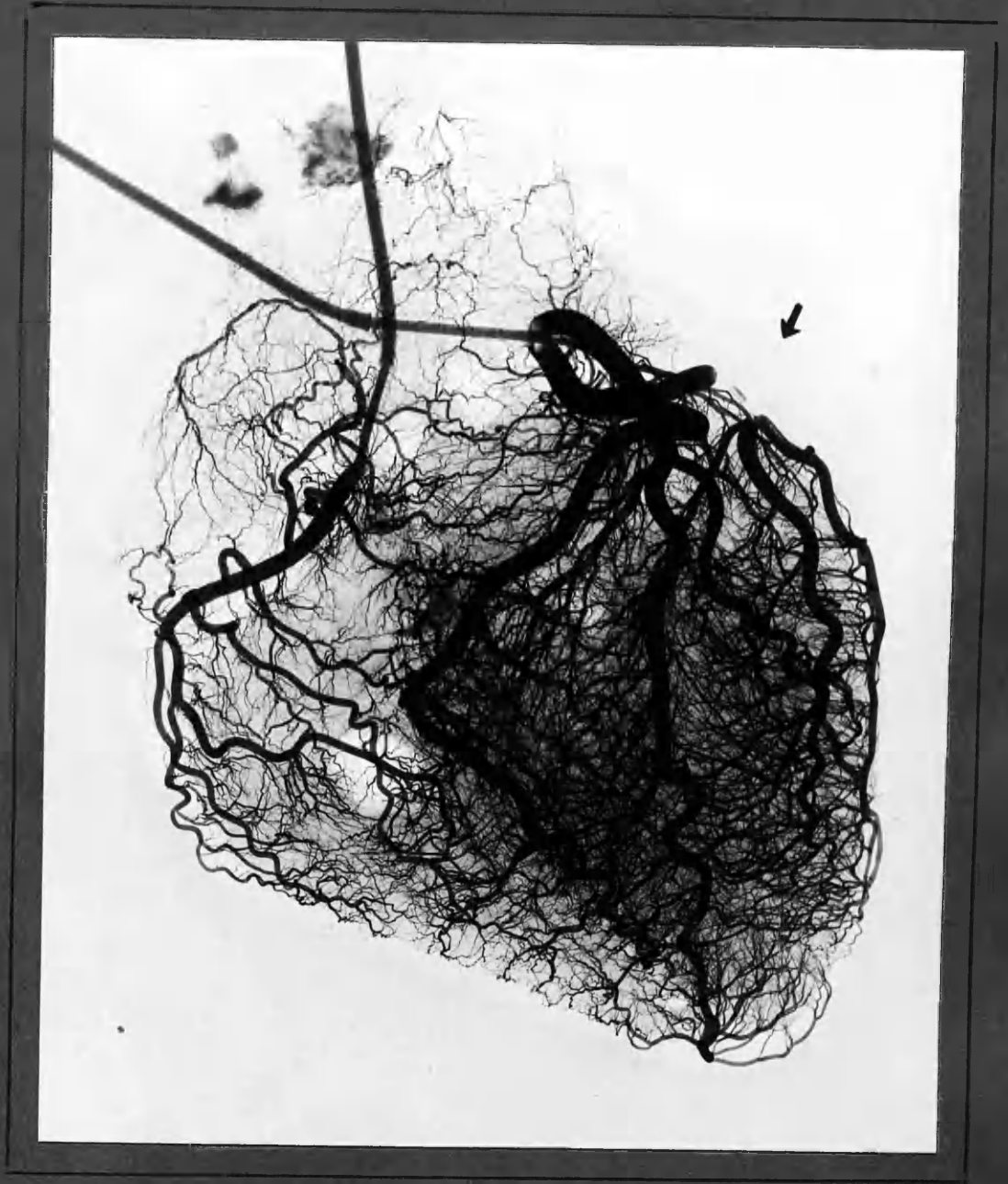
---

Fig. 1:3



Case N9 · NORMAL.

Radiography as in Fig. 1:5 A = Conventional method.



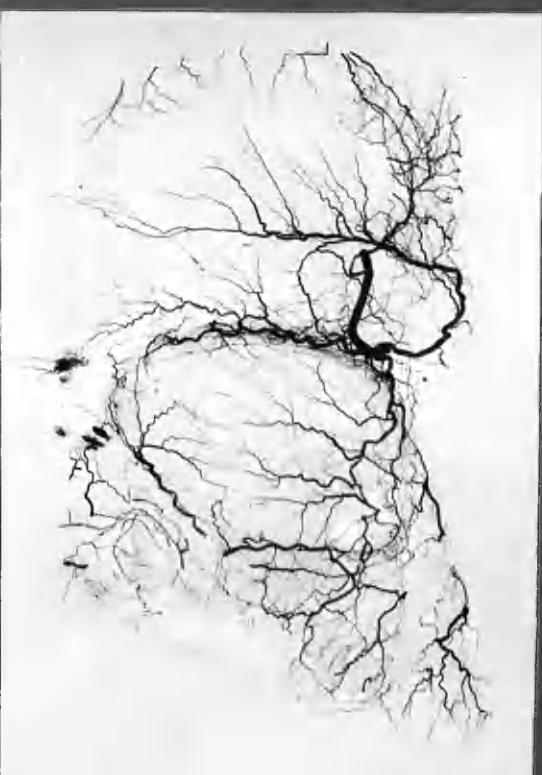
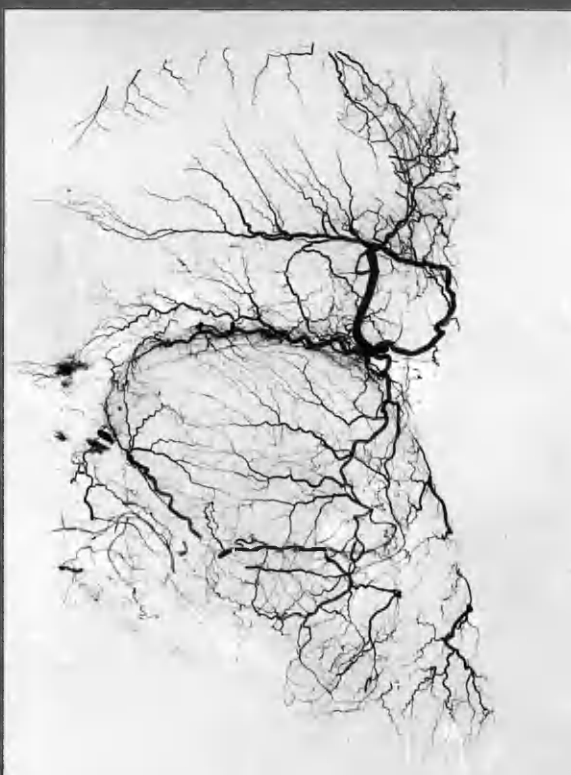
Case No. . NORMAL.

Radiography as in Fig 1:5 C : Immersion method

R. atrium

Post --- Ant.

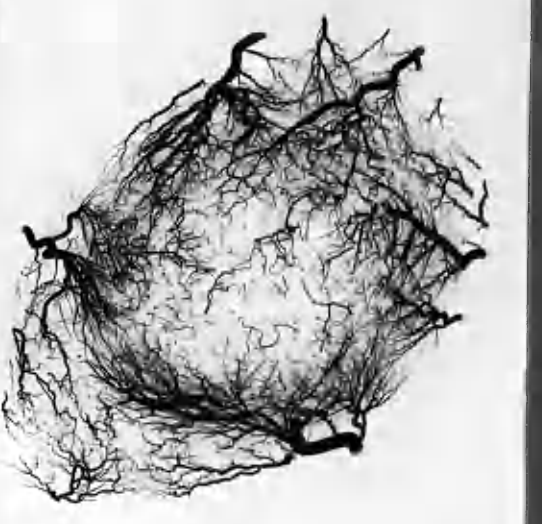
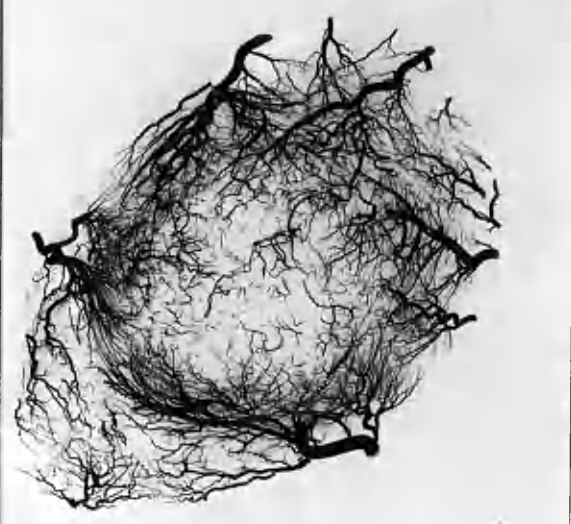
L. Atrium



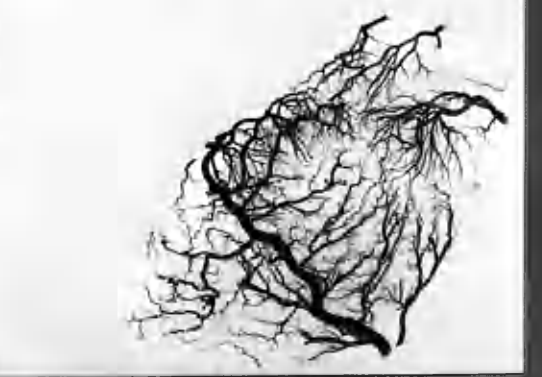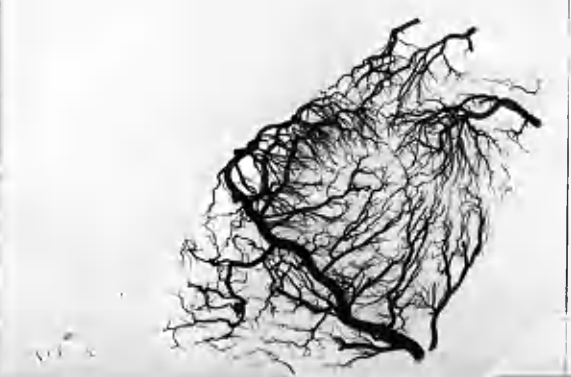Post --- Ant.

L.V.

R.V.

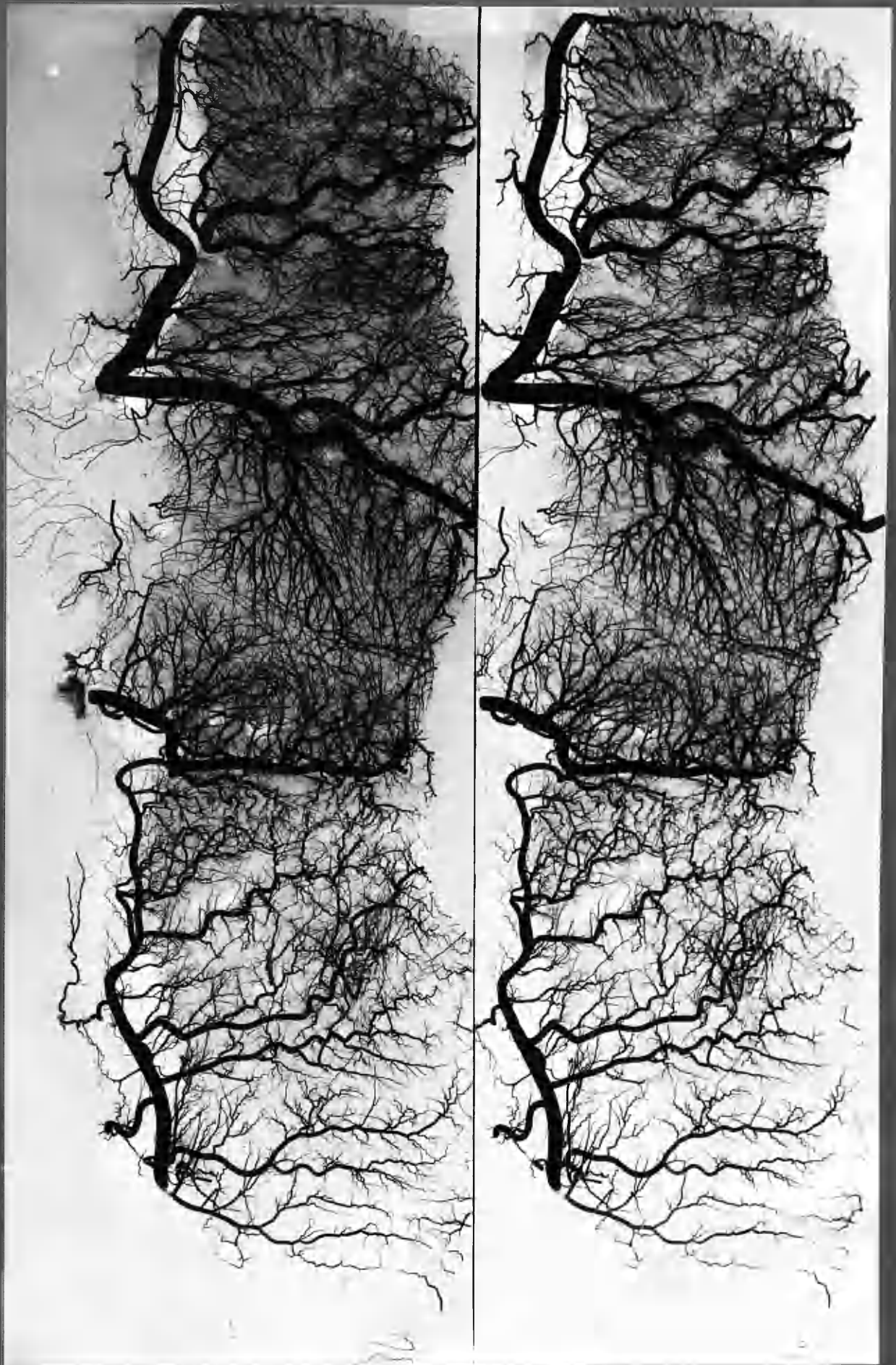


Post --- Ant.



Case N9 - NORMAL.  
"ATRIAL CAP"  
TRANSVENTRICULAR SECTION  
APEX

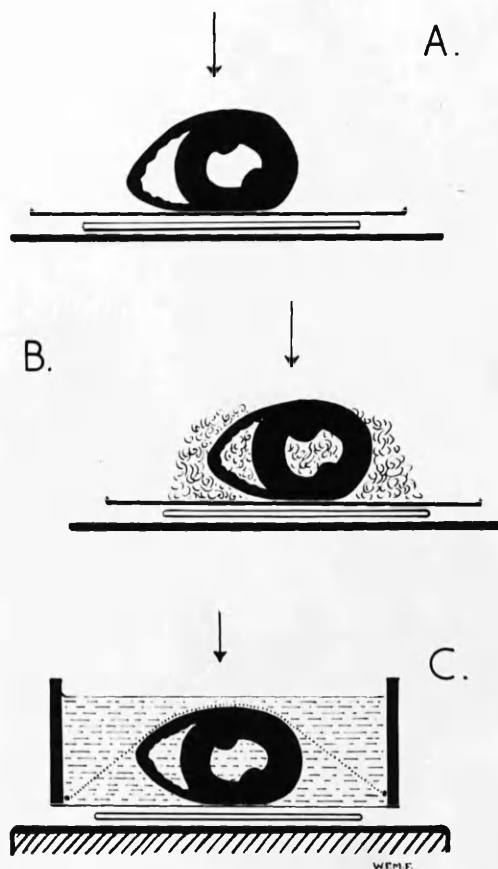




Case No : NORMAL.  
"BASAL BLOCK", unfolded.

17  
18  
19  
20  
21

METHODS OF X-RAY EXPOSURE



- A. USUAL METHOD - WITHOUT COVERINGS
- B. PACKED WITH SALINE-SOAKED COTTON WOOL
- C. TOTALLY IMMERSSED IN SALINE

FIGURE 1:5

from tissue shadows by stuffing the chambers of the heart with cotton-wool soaked in saline, and by placing similar cotton-wool padding on the outside of the heart, in order to build the whole into a block of approximately equal thickness (Fig. 5b). This gave greatly improved pictures but still left much to be desired.

A method was accordingly devised which has solved the problem and has eliminated "soft-tissue" shadow almost entirely.

A faint difference may still be discerned between myocardium and fat, but this interferes with contrast only in extreme cases, and not to an important degree (Fig. 4).

#### The immersion method:

The unfixed heart was immersed completely in normal saline in a special bath constructed from acrylic sheet<sup>¶</sup>, with a flat bottom 1/16 inch in thickness. All bubbles within the cavities of the heart were expelled. Thoroughly saturated cotton wool packing was sometimes used with advantage to the three-dimensional picture, but its use increased the difficulty of eliminating bubbles. For perfect results it was important that no part of the heart project above the surface of the saline and for this purpose a net sling was placed over the heart and fixed down (Fig. 5c).

In most cases the heart was completely immersed in about 2 inches of saline. The exposure was calculated directly from the depth of saline, thereby eliminating the guess-work and compromise required when the uncovered heart is to be radiographed. Moreover exactly comparable results could be obtained in this way. In Fig. 4 is reproduced an injected heart that was radiographed by the immersion method (c) with for comparison the same heart radiographed by the more usual method, (a) Fig. 5. In making these reproductions the best possible results obtainable by the two methods have been faithfully attempted,

¶ "Perspex" I.C.I.



without resort to local reduction.

In addition to its value in the radiography of the whole heart and of the "unfolded" heart, in which its use was equally important, the immersion technique had another advantage. The several portions of myocardium of greatly varying thickness could be placed together in the dish, under, say, 1 inch of saline. Calculated on the tube distance and saline depth, a single exposure onto a large film was then made with the assurance that it would give a satisfactory picture of the injected vessels in each portion of tissue. This greatly reduced the number of exposures necessary in a comprehensive technique - a matter of no small importance when using slow films and where the procedure was conducted without technical assistance.

Further notes on radiography of the arteries are found on page 1:36. Notes on the measurement of finer vessels are to be found on page 1:45.

#### Summary of Points in Regard to Radiography

1. A finely penetrating medium and method of injection permitted the radiological visualisation of fine vessels at the same order of density, on the film, as found in the major vessels.
2. A method is described which completely eliminated the difficulties usually encountered from tissue shadow.
3. The quality of the published arteriograms of injected coronary arteries bears witness that this difficulty has not previously been overcome.
4. The use of crystallography film together with certain refinements of injection technique allowed the radiological visualisation of vessels of a

finer order than has been recorded in the heart by other workers.

5. Magnified stereoviewing of high-quality arteriograms provided a plastic representation of fine detail throughout the entire thickness of the myocardium, comparable with the results obtained by clearing methods for vessels near the surface and without the objectionable features of clearing and of corrosion methods.

6. The unfixed heart is found to be completely satisfactory for radiography, in contrast to the practice of others (Gross, 1921; Campbell, 1929).

### STEREO-VIEWING

#### Notes on the Methods Available

The simple wedge-lens stereoscope (Brewster type) is limited in regard to the size of the picture which can be viewed by its means. The optimum separation of the corresponding points of a stereo-pair is of the order of  $2\frac{3}{4}$  inches, or less, depending on the separation of the observer's eyes. When using lenses of short focal length very little departure from this may be made. Even at low magnification the separation cannot be increased beyond narrow limits. It is thus not possible with the simple lens stereoscope to view a stereo-pair with a separation of 5 - 8 inches - the size encountered in the arteriograms of the unopened heart.

There are at least two standard methods of overcoming this difficulty:-

(a) The use of stereo-binoculars, in which angulation is achieved by internally reflecting prisms. The available models of this style of instrument which I have examined provided a reduced and distant image.

(b) The Wheatstone stereoscope. The standard modification of this for

the viewing of large radiographs is a cumbersome instrument with two viewing boxes. The stereo-pairs have to be kept separate and before viewing must be carefully orientated on the two separate screens. In the standard model the image is likewise somewhat reduced in size and is distant.

#### A Special Stereoscope

For the purposes of this investigation a special stereoscope was devised and constructed. In principle it resembles the Wheatstone stereoscope but uses four mirrors instead of two. Because of the relatively small size of the pictures for which it was to be employed, an attachment for carrying low-power lenses was incorporated. By its use an image may be obtained with the illusion of nearness to the observer, and with magnification  $1\frac{1}{2}$  - 2 times. By manipulation of the mirrors, it is possible to select different planes of the image for special scrutiny, a point which is helpful where there is much overlapping of vessels. The instrument can readily be used with any standard viewing box and is portable. Orientation of the stereo-pairs is a simple matter of placing them side by side on the viewing screen, a procedure that is aided by marking the films or by mounting them in pairs.

The instrument is illustrated in Fig. 6. It is of simple design and was personally constructed from black acrylic sheet. Ordinary thin glass mirrors were used and 5 diopetre spectacle lenses. With the lenses in position a satisfactory view of the entire heart could be obtained only in the case of hearts of normal size or smaller. For larger hearts the instrument was moved so that the entire area might be scanned.

Adjustment may be made in the angulation of all four mirrors in one plane. Lateral movement of the lateral mirrors allows correct adjustment for the varying degrees of separation required. By tilting the lens mount vertical

A  
STEREOSCOPE


MAY BE FOUND  
IN THE  
BACK COVER  
OF  
VOLUME I

---

Artereograms have been presented as stereo-pairs in chapters 1, 2, 4, 6, 7, 8. In many instances the features which have been so illustrated could not be convincingly demonstrated, or satisfactorily appreciated, without stereoscopy.

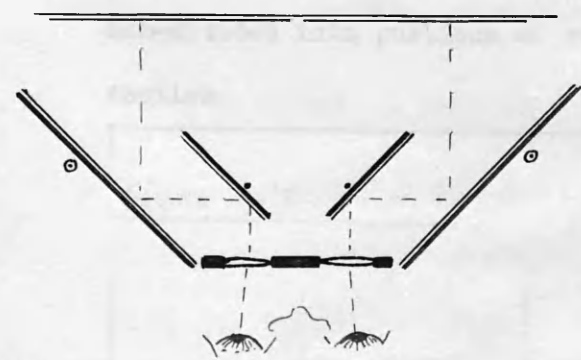
---

A SPECIAL STEREOSCOPE



A.

B.



C.

Stereoscope specially designed for viewing arteriograms where corresponding points had a separation of about 6". Constructed from black acrylic sheet, plane mirrors and simple convex lenses.

- A. Aspect which would face viewing box when in use.
- B. Instrument mounted on stand, which allowed adjustment in three directions.
- C. Optical diagram.

adjustment may be made within narrow limits to correct faulty alignment of the films.

Double reflections from the plane mirrors were only disturbing where radiographs of excessive contrast were viewed.

For the purposes for which it was designed this instrument was satisfactory. Modifications could readily be made to suit it to particular requirements.

#### Stereo-viewing of Smaller Arteriograms

For viewing the arteriograms of separate portions of the heart, which could be trimmed and mounted with a separation of  $2\frac{3}{4}$  inches, a stereoscope of the usual Brewster type was also constructed. It had no special features, except that the lenses were more powerful than usually provided in commercially available instruments of this type (magnification x 5), and that accurate lens separation was obtainable by adjustment. The method of dissection by which the heart was sub-divided into portions of suitable size is described in the next section.

Figure 1:7



STEREOSCOPE constructed from black acrylic sheet, designed for viewing arteriograms not more than 3" across. Compound lenses, magnification x 5. Adjustments for focussing and lateral separation of lenses.

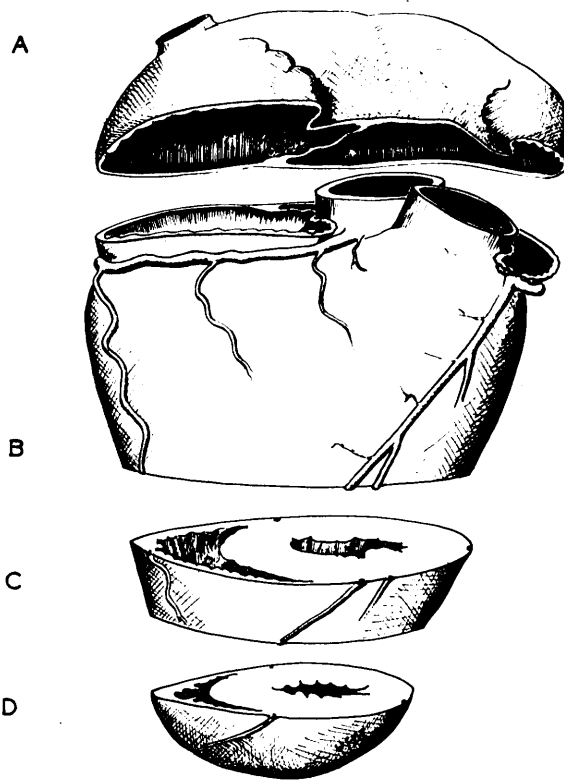
METHOD OF OPENING THE INJECTED HEART FOR DETAILED DEMONSTRATION  
OF VASCULAR CHANGES

Notes on Methods

In order to obtain demonstration of greater detail and clarity than can be achieved in the intact heart, several workers have subdivided the fixed heart into portions before subsequent radiography (Crainicianu, 1922; Campbell, 1929; Gross and Kugel, 1933 and others). Schlesinger (1938) developed a method of "unrolling" the entire heart, except for the interventricular septum which was excised, and in this way displayed the major coronary arteries in a single plane. This method has been widely adopted both in the centre where it was developed, and by other workers (Holyoke, 1945; Ravin and Geever, 1946; Salans and Tweed, 1947; Brink, 1949; Shillingford, 1950; Snow et al., 1952). Objecting to the trisection of the aortic valve, Scott (1949) made a minor modification. It was felt that removal of the interventricular septum was an unsatisfactory feature of the Schlesinger method. Since, as is well known, interarterial anastomoses may reach a high degree of development in the interventricular septum, it seemed a pity that this structure should be excised.

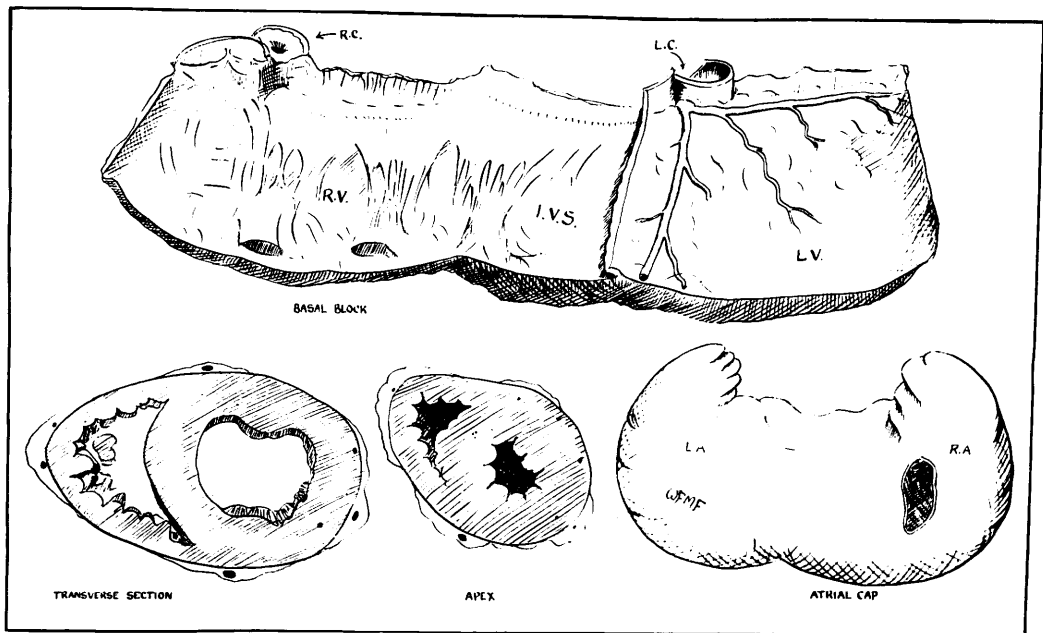
My technique of dissection made departure from previously described methods, although it combined several features contained in them. I was attempting to obtain as much information as possible in the one specimen in regard to the general distribution of the major vessels, detail of finer vessels and anastomoses, detail of diseased major vessels and demonstration of myocardial and valvular changes. It is felt that no published method has combined these features so completely or destroyed so little of the available information. It must, however, be pointed out that no method of opening the heart can fail to transect some portion of the vascular tree, and accordingly a certain amount

FIGURE 8



A: ATRIAL CAP  
B: BASAL BLOCK

C: TRANSVERSE SECTION  
D: APEX



PARTIAL DISSECTION : PORTIONS PLACED IN DISH READY FOR RADIOGRAPHY.

FIGURE 9



of information must necessarily be sacrificed or obscured. This objection is minimized if stereo-radiographs of the intact heart are taken before the heart is opened. In the Schlesinger technique this stage is omitted.

#### Detail of Method of Partial Dissection

Before the dissection was undertaken the stereoscopic radiographs of the intact heart were inspected and the following method modified in order to include the most important information in the individual case. Basically the method was seldom departed from in practice. In the description reference will be made to Figures 8, 9, 10 and 11. The entire dissection could be accomplished with a pair of semi-sharp-pointed scissors and a knife.

##### A. Removal of the atrial "cap".

(1) Right atrium. The right atrium was opened first by a scissor cut from the orifice of the inferior vena cava parallel to the atrio-ventricular groove and about 1 cm. above it. The interior of the right atrium, its auricle and the interatrial septum was then inspected.

(2) Left atrium. The left atrium was similarly treated. The entire atrial "cap" was then removed, cutting round both atria and auricles about 1 cm. from the atrioventricular groove and across the interatrial septum.

In this way an excellent view was obtained of the mitral and tricuspid valves from above, their orifices were measured and their competence tested. The pulmonary and aortic valves were then measured and tested, and the pulmonary artery and aorta were trimmed close to the valves.

##### B. Transverse section of the ventricles.

The ventricles were opened by a transverse slice parallel to the atrioventricular groove and about half way between this groove and the apex.

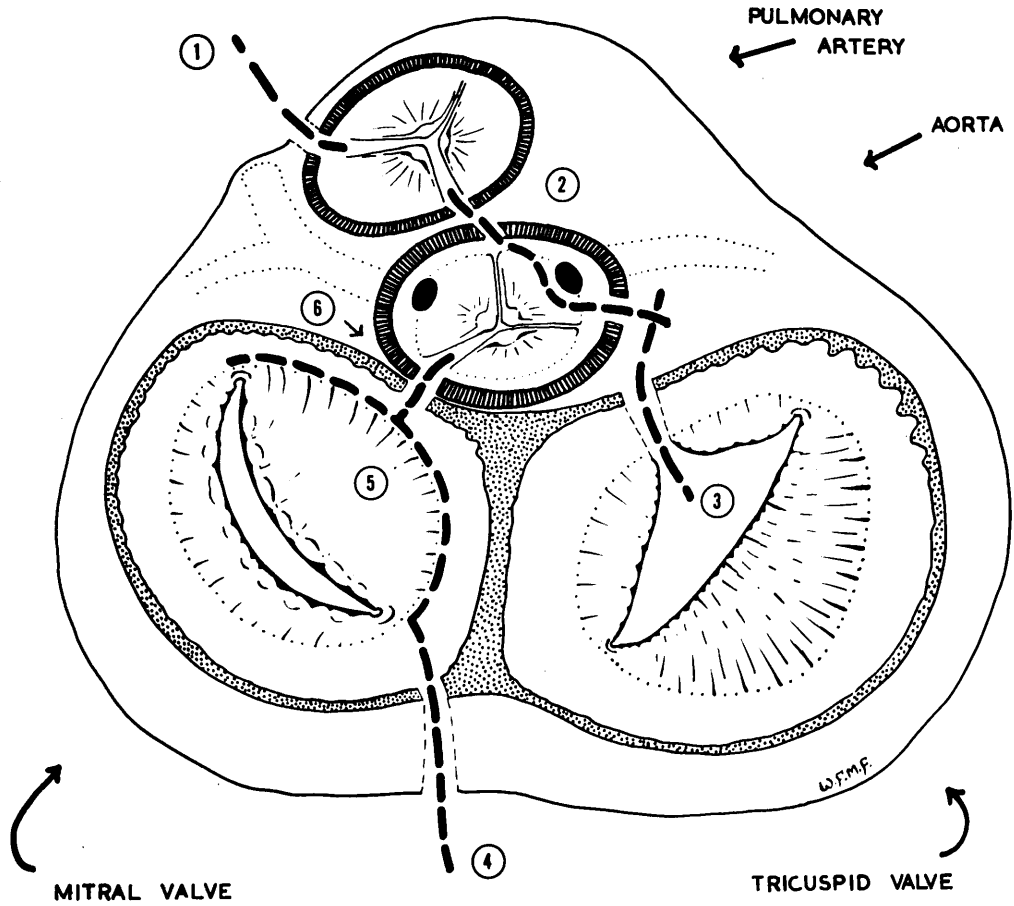


FIGURE 10

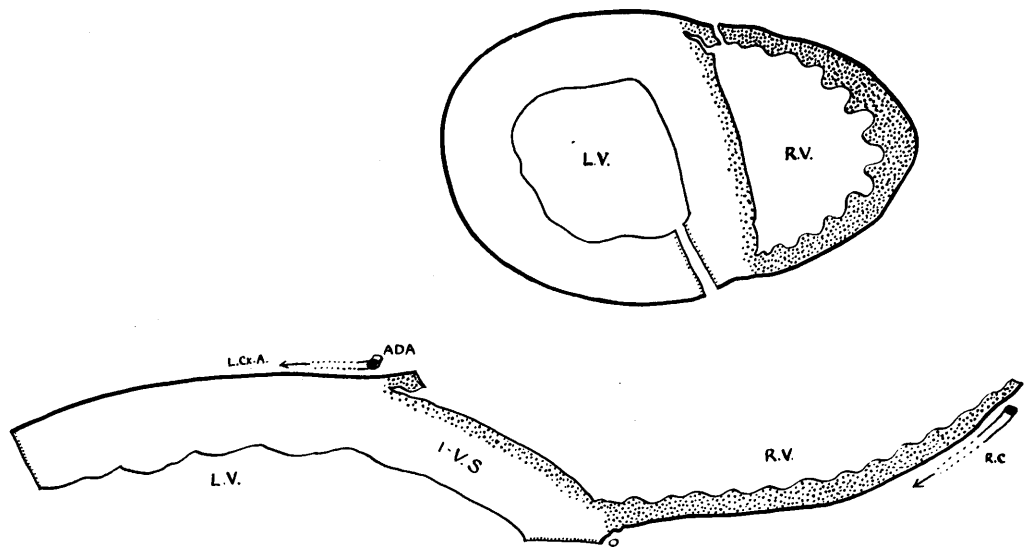


FIGURE 11

INCISIONS USED IN UNFOLDING THE BASAL BLOCK OF THE HEART.

This was best accomplished with the heart laid on its ventral surface and care was taken in the direction of the cut.

This incision usually passed through an area of anterior myocardial infarction, if present, and at the same time was below the level of important arterial changes. Except as an extension from higher up it was uncommon for occlusion to be found below this level. Posterior infarcts, however, were often situated too near to the atrioventricular groove to be revealed by this incision.

The lower half of the ventricles was then sliced into one or more transverse sections of approximately 1 cm. in thickness until the apex was approached. An apical portion of about 2 cm. in depth was preserved.

These sections gave a good picture of the relative sizes of the ventricles and their actual thickness, and gave a clear demonstration of the distribution of muscle damage in the lower half of the ventricles. Examination of myocardial changes in the upper half of the ventricles had to await a later stage.

#### C. Unfolding of the basal block.

Turning to the main "Basal Block" of the heart the interior of the ventricles was inspected and the valves examined from below. The incision had usually passed through the papillary muscles. The basal block was then opened by a special "unfolding" technique. The position of the incisions as seen from above are shown in Figure 10. It is difficult to give a brief description which can be followed without the aid of a heart under dissection. When this is to hand it becomes quite obvious where the incisions should be placed. The description is much more formidable to read than the dissection to carry out.

Incisions C.1, 2, 3 (Fig. 10) were more easily executed if the pulmonary artery and aorta had been trimmed fairly close to their valves, so that a clear view of the cusps was obtained.

Incision (1). The right ventricle was opened from below by a scissor or bistoury cut close to the interventricular septum and was carried through the pulmonary valve between the most conveniently placed cusps.

Incision (2). Working from above, the pulmonary valve was divided between the posterior and right anterior cusps with a scissor cut that included the adjacent aortic wall. Below the level of the pulmonary valve the right ventricular myocardium (Crista supraventricularis) was divided from below. The incision in the aortic wall was carried in a curve through the right coronary sinus of Valsalva in such a way that the orifice of the right coronary together with the artery itself was reflected with the anterior flap of the right ventricle and the valve cusp was left in situ.

Incision (3). The tricuspid ring was then divided and the right ventricle completely opened out.

Incision (4). The opening of the left ventricle was commenced by dividing the posterior wall close to the interventricular septum, extending the incision as far as the fibrous ring of the mitral valve, keeping all the time external to the valve itself. The left atrial wall was incised from above to meet the first part of this incision.

Incision (5). Cutting round at the junction of the anterior (aortic) cusp of the mitral valve with the fibrous ring, this cusp was separated at its root from its attachments. The incision was continued until the anterior commissure was approached and the ventricle could be opened out. Sometimes it was necessary to divide the chordae tendineae or to divide the posterior papillary muscle, in order to let this be done.

Incision (6). In some hearts the left ventricle was sufficiently opened out without Incision (6). Where, however, the aortic valve required to be

divided, the cut was placed between the posterior and the left coronary cusps.

In this way the basal block of the heart was unfolded into a slab a single ventricle in thickness, in which all the major branches of the coronary arteries were contained. The method has some advantages over other methods of unrolling the heart, which will be discussed shortly.

It will be appreciated that this dissection was made on the unfixed heart. The basal slab and other portions of the heart could then be radiographed; or placed in formalin and the radiography carried out at convenience. In either event, they were placed in cold 5% formol-saline as soon after dissection as was practicable, the different portions being arranged in a flat-bottomed dish in the desired position.

#### Discussion of the Method of Partial Dissection

The following advantages of this method may be noted:-

- (a) The upper half of the interventricular septum, including the conducting system, is preserved in situ.
- (b) The aortic and mitral valves are preserved almost intact.
- (c) The atrial circulation can be studied to much better advantage than in methods which slice the atria into several pieces.
- (d) The transverse section method of examining the ventricles has a number of advantages both in regard to myocardial and vascular changes. These include (1) a helpful correlation of the distribution of infarction with the electrocardiographic findings and with the territories of occluded vessels; (2) the findings are readily recorded graphically; (3) the radiographs of ventricular sections and apex provide interesting information not readily appreciated by other views.

There are few important disadvantages beyond those already mentioned, and these are common to all methods.

(a) At first glance it might seem that the removal of the apical portions of the ventricles prior to unfolding the block compares unfavourably with the Schlesinger method in which the entire heart is unrolled and the entire coronary circulation is presented on the one arteriogram (apart from the interventricular septum, of course, which has been excised). But as already explained in the section on stereo-viewing, the maximum useful width of the basal arteriogram is 3 inches, if it is to be viewed stereoscopically with the aid of an ordinary stereoscope. The Schlesinger arteriogram could, of course, be subdivided, but only with loss of its sole advantage in regard to this argument.

(b) Either (1) the posterior terminal portion of the right coronary or of the left coronary circumflex branch is divided and separated from its parent trunk, or (2) the posterior left ventricular incision passes through the interarterial zone in which interesting anastomoses may be transected. The first of these objections is unimportant. The second is sufficiently important to have made it worth while in a few instances to modify the posterior incision radically. Instead of cutting through the posterior wall of the left ventricle, the posterior part of the interventricular septum was divided and the heart opened out. The slab opened in this way resembled the Schlesinger preparation except that the interventricular septum was not separated from the left ventricular wall anteriorly.

Further points:-

1. The stereogram of the whole heart gave a great deal of information and was helpful in co-ordinating the findings in the separate portions. It should not in my opinion be omitted from a comprehensive investigation.

2. On the other hand it had important limitations. For the finer points of vascular anatomy it was essential also to use some method of opening out the heart prior to radiography.

Application to general pathology.

The technique that has been described was primarily devised for the optimum demonstration of vascular changes. Nevertheless, in comparison with the usual routine techniques of opening the heart in the post-mortem room, it has been found to have some advantage and no disadvantage in the examination of myocardial and valvular changes. In practice, the technique of unfolding the basal block of the heart was much less complicated to carry out than the description would suggest, and could in fact be accomplished quite quickly.

FURTHER RADIOGRAPHIC DEMONSTRATION OF THE CORONARY ARTERIES

The various portions of the heart obtained by the method of partial dissection were radiographed by the saline immersion method, using a tube distance of 40 inches. This stage could be undertaken with the tissue fixed or unfixed. Immersion was most important for the reproducibility of the basal block, apex and atria, and the transverse sections were usually included in the saline bath for convenience. On the other hand, the loss of tissue shadow in the latter may sometimes be regarded as a disadvantage, and separate radiographs taken. As already mentioned, with the immersion method a single pair of radiographs using large film sufficed for all portions. The slight distortion caused by off-centre stereography was unimportant.

While magnified viewing of the main vessels in situ was highly informative and was an essential step in the analysis of the vascular changes, the picture was confused by the multiplicity of smaller branches and sometimes by heavy deposits of calcium. Further advantage was accordingly sought from radiography of the arteries after they had been decalcified and excised. This was especially helpful in the demonstration of intimal vessels and recanalisation, and of the changes in the vasa vasorum. Examples are shown in Chapter 7.

In the excision of the main arterial trunks, a blind block-dissection was made, using the stereo-radiographs of the basal block as a guide. This was a matter of some delicacy and judgement. Three blocks at least were removed, each with cross section of the order of 1 x 1.5 cm. and containing, in their centres, if the dissection had been accurate, the three arteries: (a) the left coronary and anterior descending arteries; (b) the left coronary circumflex artery; (c) the right coronary artery. If indicated, blocks were also taken of the main collateral branches.

Process film and a tube distance of 30 inches was used for radiography of the arterial blocks. Immersion was not usually necessary.



METHOD OF EXAMINING THE STRUCTURAL CHANGES IN THEARTERIES THEMSELVESOther Methods Used

Previous investigators have examined the coronary arteries after injection and radiography mainly by one of two methods:

- (a) By dissection on the basis of the radiograph (Schlesinger, 1938, and followers of his method).
- (b) By sectioning the arteries in situ at intervals throughout their length, with the selection of portions for histology (Friedberg and Horn, 1939; Horn and Finkelstein, 1940; Horn and Master,\* 1950).

Both these methods were found to be inadequate. Snipping the artery with one scissor point leading down the lumen has the objection that much of the evidence is destroyed or distorted before it is even seen and was regarded as unsuited to a research investigation of detailed changes in diseased coronary arteries. It was, however, used in the examination of control cases; but only where the radiograph had demonstrated a normal, or nearly normal, contour.

Sectioning of a coronary artery in situ was found to be fraught with artefact distortion and sometimes important damage, except in fixed and decalcified specimens.

\* i.e. Horn et al., 1950

### Method Used in this Investigation

It soon became apparent that there was no short cut to an accurate examination of pathological changes in the coronary arteries and an extensive technique was evolved. In this method the evidence was preserved in the form of 2 mm. thick sections prepared from the full length of the artery, mounted in series.

#### Detail of method.

The heart was injected, stereoradiographs examined, and the arteries excised as already described. Each arterial block was 1-1.5 cm. in cross section. At least three blocks were taken, containing: (a) the left coronary artery and its continuation as the anterior descending artery; (b) the left circumflex artery; and (c) the right coronary artery. The block dissection was performed with the aid of the stereoradiographs. In doing so attempt was made to cut wide of the artery at all points and to damage it and its surrounding tissues as little as possible.

If decalcification had not already been carried out it was done so at this point. In this series 48 to 72 hours immersion in Perenyi's fluid was found to be adequate.

After thorough washing, the blocks were embedded in gelatin at 37 degrees C.: 24 hours in 10% gelatin was followed by 48 and sometimes 72 hours in 20% gelatin. (Even so it was sometimes felt that the penetration into the depths of unusually large atheromatous "abscesses" could have been improved with longer time).

After cooling, the blocks were fixed for 48 hours or as long as was convenient in 5% formol saline.

Free-hand sections were then cut using a thin blade. Safety razor blades

of the wafer type were found to be the best but more rigid blades were more easily controlled. The sections were approximately 2 mm. in thickness. Wedge-shaped sections were sometimes necessary in order to negotiate a bend in the artery.

As they were cut the sections were individually laid in series on wet paper according to a standardised plan of orientation, and a cover was placed over them to prevent drying. It was an advantage to lower the temperature of the block by placing on ice before cutting, but actual freezing was a disadvantage when cutting such thick sections.

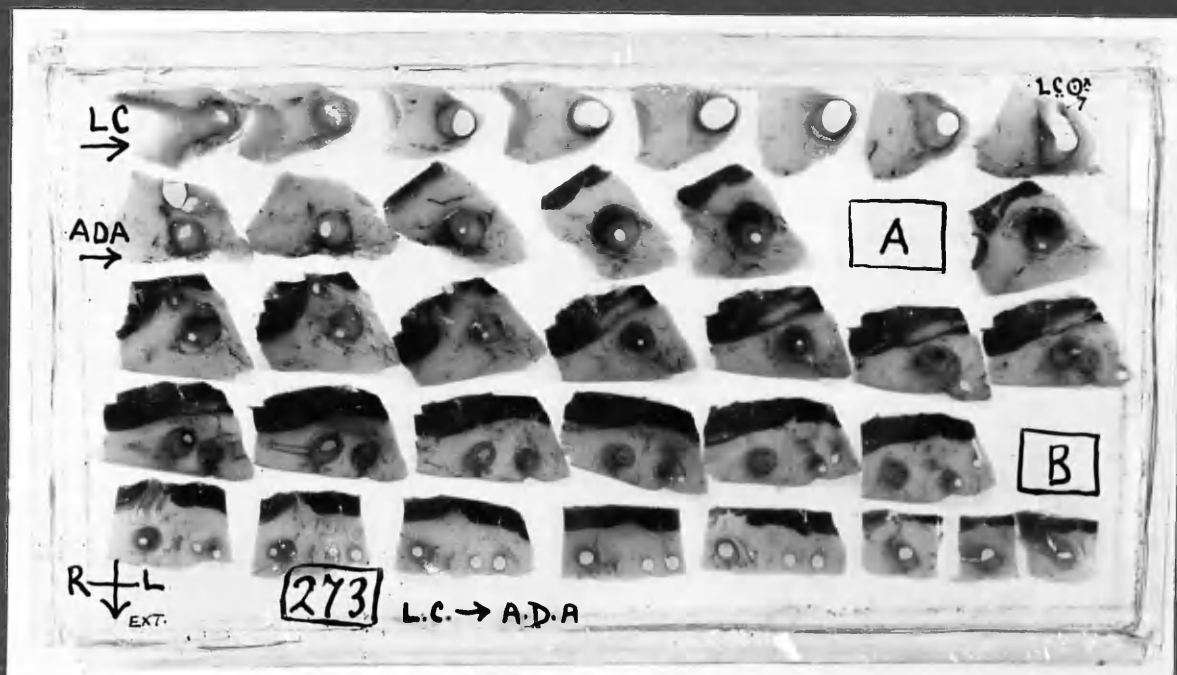
When the series was complete, the sections were examined with the aid of a dissecting microscope, or strong hand-lens. Several sections might be selected for histology. From a single section 2 mm. in thickness it was possible to obtain 10 frozen sections 20-30 microns in thickness and 50 or more paraffin sections at 8 microns without undue difficulty.

The remaining arterial sections were now mounted in series by the following method:-

A rectangle of suitable size was cut from acrylic sheet, 1 mm. in thickness.<sup>⌘</sup> A note on cutting is included below. Glycerin agar (formula below) was melted in a water-bath and allowed to cool to about 40 degrees C. in moieties in a small dish and maintained at this temperature while in use. Each section was picked up with a needle point, inserted well away from the artery, and was dipped into the warm glycerin-agar. It was then placed on the acrylic sheet in correct position and orientation. Three or four rows of about 10 sections each were commonly required for the one artery. Care was taken to leave a blank space for each section that had been removed for histology.

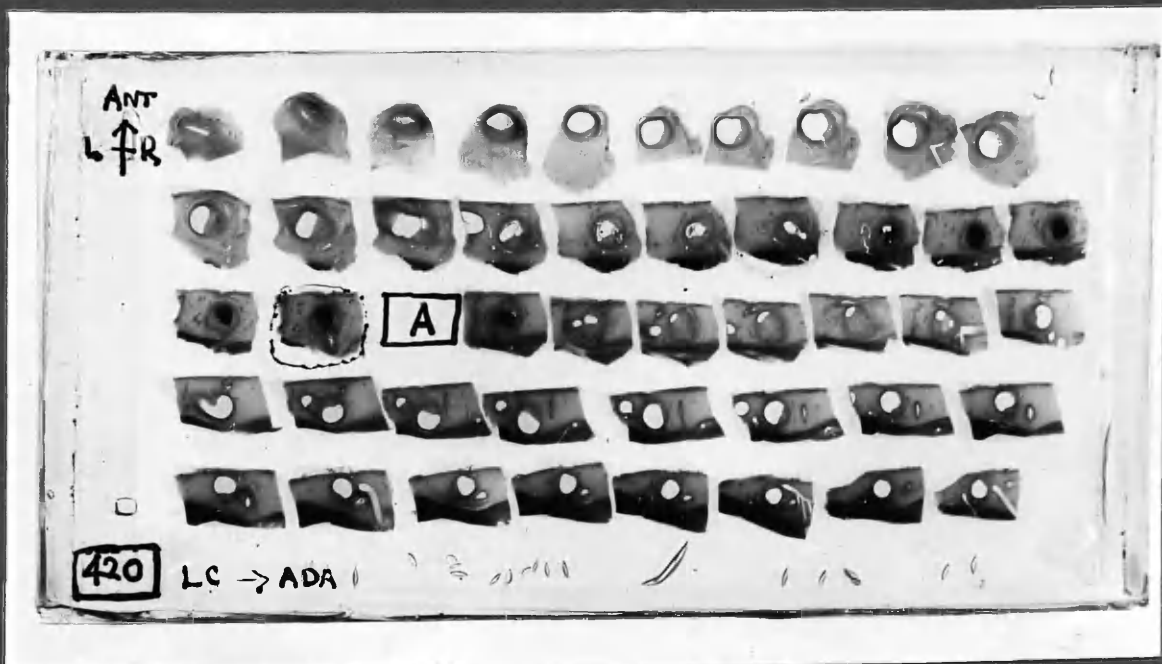
⌘ Perspex I.C.I.

1:1 → 2  
2: → 2  
3: → 2  
4: → 2  
5: → 8



Old standing occlusion of Ant. Descending artery, with canalisation.

1: → 2  
2: → 2  
3: → 2  
4: → 2  
5: → 2



Recent thrombotic occlusion.

Photographs of serially mounted 2 mm. thick sections of coronary arteries, actual size. 2 examples - Cases 22, 24.

(The same in COLOUR, overleaf)

Blocks [A] & [B] were removed for histology.



1.



2.

COLOUR TRANSPARENCIES of serially mounted  
2 mm. thick sections of coronary arteries. (see previous page).

LIFT PAGE AND ALLOW LIGHT TO BE REFLECTED  
FROM THE BLANK PAGE WHICH FOLLOWS.

As each section was placed side by side the excess glycerin-agar ran together and on solidifying the sections were held in position. The acrylic sheet was then placed in a flat-bottomed dish (the lid of an aluminium container of suitable size was convenient) and the dish placed on a level surface. Warm glycerin-agar was poured gently over the sections until they were just covered. No difficulty was experienced with sections coming adrift, as encountered when the same process was attempted with gelatin, for of course agar did not re-melt under the conditions used once it had solidified.

When the glycerin-agar block had set, a thin bladed knife was run round the margin of the acrylic sheet. The sheet was then carefully lifted out of the dish together with the mounted sections supported on it. The undersurface was wiped free of any medium clinging to it.

Various methods of completing the mount were tried. The simplest was to place some form of support at the corners, to place a second sheet of acrylic on the top of the block and to fix in position with cellophane tape. A more permanent mount may be made by placing strips of acrylic of the same thickness as the agar block at each end and cementing with chloroform. It was, however, desirable that the mount could be readily opened at any time should it be decided that further histology from a particular section be required. When this was done it was found necessary to take the section slowly back through progressive dilutions of glycerin and to handle it with great delicacy. Valuable sections were lost by the swelling that occurred in over hasty rehydration.

Figure 12 shows two examples of mounted 2 mm. thick arterial sections. Sections mounted in this way have been kept for over 6 years without evident deterioration. A final statement, however, cannot yet be given. In some

cases there was little or no leakage of glycerin while in others a gradual exudation of glycerin took place over months but thereafter seemed to cease. The latter is thought to have been the result of too high a percentage of glycerin. Too high a percentage of water on the other hand led to shrinkage from evaporation. At present it is believed that a concentration of glycerin about 70% in 1-2% agar gives a compromise between shrinkage and the tendency to leak from exudation. Of course, both these difficulties would be of no importance in a mount that was finally sealed. The method is still under trial and there is no knowledge of reference in the literature to such a method, which would act as a guide.

Solidification of the medium occurred rapidly on cooling. In course of time there was a gradual replacement of the water in the tissues by glycerin in the medium. As this appeared to take place slowly, undesirable shrinkage effects did not commonly occur.

As the sections take up the glycerin they become more translucent. Also, it is sometimes helpful to warm the whole mount in an incubator before examining. In this way fat in the tissues becomes liquid and a clearer view of the vasa vasorum and other features may temporarily be obtained.

"Perspex" was used in place of glass for several reasons:-

1. Flexibility made the original mounting without bubbles a simpler procedure; and the reopening of the temporary mounts for the extraction of selected sections could be accomplished with less risk of damage.

2. Permanent identification marks in regard to case number, artery, orientation of sections, and reference to sections removed could be readily scratched on the surface, without the pressure needed for a diamond on glass. Labels and glass-writing ink tended to be loosened by glycerin.

Glycerin-agar mounting medium.Glycerin-agar.

Agar ..... 2%  
 Glycerin ..... 70% approx.  
 Water ..... 30% approx.

Characters: When set this medium is slightly turbid and is suitable only for the mounting of thin specimens. Where the layer of glycerin agar through which the specimen is to be viewed is thin, as in the case of sections mounted as described, the turbidity is so slight as to be unimportant.

The medium melts at about 90 degrees C. and solidifies rapidly at 30 degrees C. Solidification sets in slowly between 40 and 30 degrees, but at the higher ranges its progress is so slow as to be unimportant in regard to its use in this technique.

NOTE: This "Glycerin" should be cut in one way with to  
 some facility and accuracy as this glass.



Note on the cutting of thin acrylic sheet (Perspex).

"Perspex" was used in preference to glass. One of the difficulties to be overcome was the need for a simple, neat method of cutting the "Perspex" to suitable sizes as required. Thin sheet of the order of 1 mm. and 1/16th inch tends to fragment when cut in a band-saw. It was found, however, that a simple method was effective.

A sharp knife point was drawn across the "Perspex" sheet with moderately heavy pressure, making a deep score. The sheet was then reversed and placed over a sheet of thin cardboard in such a way that the score lay beyond the edge of the cardboard and parallel to it. The free portion of the "Perspex" rested on the surface of the bench. The distance between the edge of the cardboard and the score on the "Perspex" sheet was found by trial and error. Using cardboard of 1 mm. thickness (or the edge of another sheet of "Perspex") a distance of about 5 mm. was used. A blunt edge, such as the smoothed handle of a scalpel, was now pressed against the upper surface of the acrylic sheet directly over the score, which was now on the undersurface. Pressure was increased until the sheet cracked. The split so formed was extended in both directions by sliding the blunt edge along the line of the score, all the time maintaining pressure. It was best to commence the split well away from either end of the score. Thin "Perspex" sheet could be cut in this way with the same facility and sureness as thin glass.

ON  
Vascular Elastic Tissue and the Elasticity of  
Coronary artery sections  
1. Vascular Elastic Tissue and the Elasticity of  
2. Vascular Elastic Tissue and the Elasticity of  
CK/MS

HISTOLOGICAL EXAMINATION OF THE ARTERIES

From each block selected for histology, frozen sections were cut and mounted. These were stained by the benzidine method for haemoglobin and ferrocyanide stain for iron, and counterstained with Scharlach R. An unstained section was also mounted. The sections were examined by transmitted and by polarised light. For mounting, the glycerin-agar medium was found to be superior in some respects to glycerin-gelatin.

The remainder of the small arterial block was then passed to the technician for paraffin embedding and section cutting. The sections were mounted in semi-serial fashion, divided between four slides, to be stained routinely, and two spares. I assisted at the section cutting in order to obtain the optimum division of the available sections from each arterial block. The paraffin embedding, cutting of paraffin sections and staining were undertaken throughout the investigation by Stewart Rankeillor, Department of Pathology, University of Edinburgh.

The following is a summary of the methods used by Stewart Rankeillor.

Coronary artery and myocardial blocks for paraffin embedding were post-fixed in Bouin's fixative for 36-48 hours; dehydrated in methylated spirit and absolute alcohol; cleared in chloroform. The tissues were vacuum embedded, using 48 degree C.M.P. paraffin and finally embedded in 54 degree C. paraffin.

**Staining procedures:-****Myocardial sections:**

1. Mayer's Acid Alum Haematoxylin and Eosin.
2. Weigert's Elastic Tissue stain and Van Gieson's stain  
OR  
Verhoeff's Elastic Tissue stain and Van Gieson's stain.

**Coronary artery sections:**

1. Mayer's Acid Alum Haematoxylin and Eosin.
2. Weigert's Elastic Tissue stain and Van Gieson's stain  
OR/AND  
Verhoeff's Elastic Tissue stain and Van Gieson's stain.
3. Weigert's Fibrin stain.  
(Differentiated in equal parts aniline and xylol).
4. Prussian Blue reaction, counterstained basic fuchsin.

Selected sections for illustration have also been stained with Lendrum's Acid Picro-Mallory Film stain by Ian Mackie, Department of Pathology, Stobhill General Hospital, Glasgow.

Paraffin sections were mounted in Canada Balsam, or Gurr's neutral mountant in the case of Van Gieson preparations.

#### Notes on the Method Described

By the method of mounting the free-hand thick sections of the arteries, changes in the entire artery were available for reference. The atherosclerotic changes themselves, the complications of thrombosis and intimal haemorrhage and the phenomenon of recanalisation would all be viewed to advantage time and time again. Intimal vessels were sometimes seen and their origins traced from adventitial vessels or from the lumen. And, perhaps as important as any, the histological sections could be accurately identified and considered in relation to the naked-eye appearances and also in relation to the changes above and below the level from which they were taken. Careful examination of the thick sections allowed accurate correlation with the arteriograms. The illustrations to be found in Chapter 7 bear out these points.

METHOD OF MEASURING ARTERIAL DIAMETER ON THE RADIOGRAPHS

It was first necessary to establish what relation the lumen diameter of small vessels bore to the radiographic shadow cast by them. The radiographs upon which measurement was to be made were almost invariably exposed at a tube distance of 40 inches and with a focal spot 1 mm. square. In almost every instance crystallographic film was used, and the tissue was rarely more than 1 inch in thickness. Occasionally, it was desirable to measure vessels in the radiographs of the whole heart, where the maximum distance of any vessel from the film during exposure was 2 inches.

Accordingly a series of wires of different gauges were attached to a strip of acrylic sheet. This was placed over a crystallographic film at an incline such that the one end of the wires was almost in contact while the marker placed across them was 2 inches from the film. As might be expected, it was found to make no difference whether the exposure was made with the wires supported in air or in saline.

Exposure was made with a tube distance of 40 inches and the film was given normal development time.

A contact print of the radiograph is shown (Fig.13). The wires themselves and the radiograph were then calibrated by projection micrometry at a magnification of  $\times 100$ . The diameter of the wires ranged from 40 microns to 1.25 mm. It will be seen from the table that there was a very close correspondence between the diameter of the wires and the width of the radiographic shadow cast by them, when the wires were close to the film. When the wires were one inch distant from the film a slight loss of definition occurred, which was more pronounced at 2 inches distance. This is represented diagrammatically in Figure 14 which is a direct tracing of the projected shadow at a magnification of  $\times 100$ . There is a slight spread of the shadow, which is negligible at the

"contact" end, and which increases the diameter by 5-10 microns at one inch and 10-20 microns at 2 inches. This discrepancy was unimportant (for practical purposes) in the vessels of 200 microns and over, but needed to be taken into consideration in the smaller vessels.


Comparison of Diameter of Fine Wires and Width of the Radiographic Shadow Cast by them, as Measured by Projection Micrography.

S.W.G.	Projected shadows in microns		
	Wires	X-ray shadows of wires:	
		"in contact" with film	at 2 inches from film Penumbra Umbra
48	40	40	60 - 70
47	50	50	70 - 720
46	60	60	70 - 35
44	80	80	90 - 50
38	140	150	160 - 110
36	180	180	190 - 150
30	310	300	320 - 270
26	440	440	460 - 400
22	590	600	630 - 570
-	1250	1250	1280 - 1180

It may be noted however that the diagram in Figure 14 represents measurements made at high magnification. It was found that at a magnification of x 5, the eye naturally sought a point midway between the margins of umbra and penumbra, and the visual impression of size at this magnification needed no important correction.

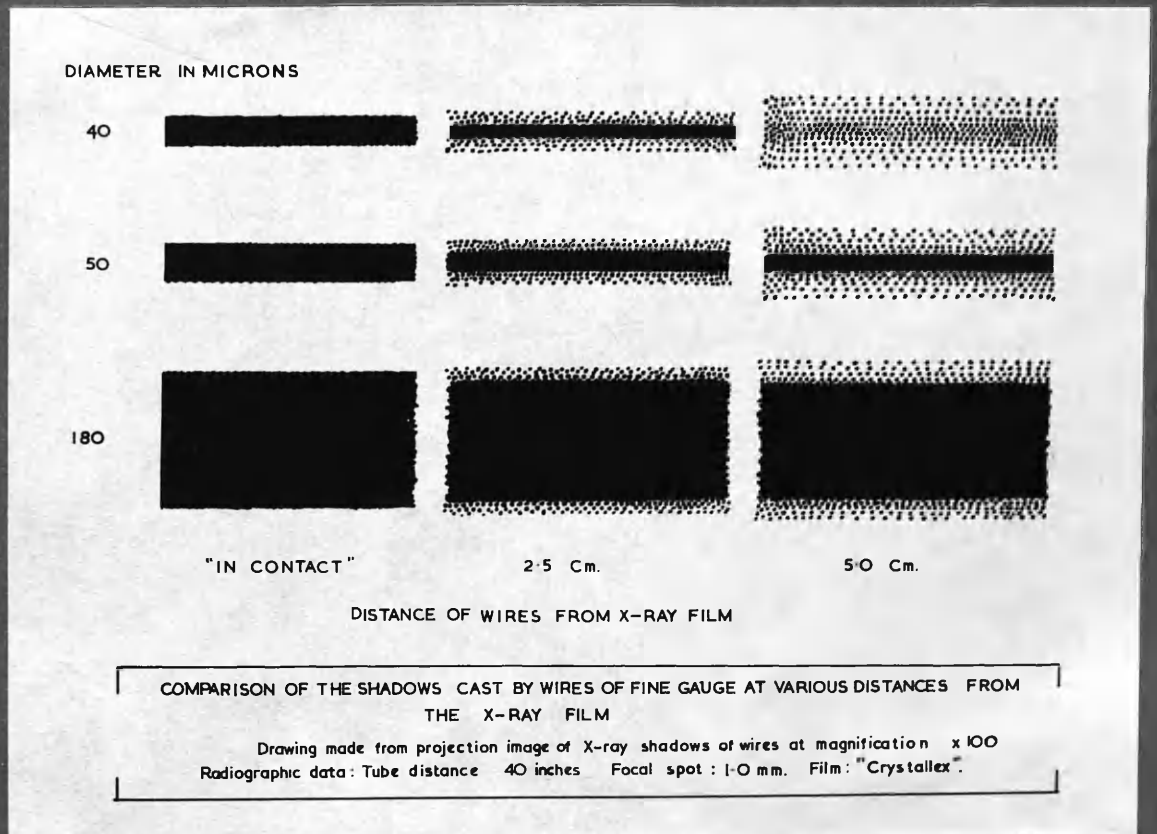
Measurement of anastomoses was made by direct comparison of the calibrated radiograph of graded wires with the stereograms viewed at x 5 magnification. For this purpose the calibrated radiograph was introduced in front of the film and in contact with it and was moved until the vessel in question lay between the wire shadows of the nearest size.

The method was controlled by projection measurement of the shadows of a few vessels of known calibre, as measured in the glycerin mounted specimen. When the vessels lay within about  $\frac{1}{2}$  inch of the film the definition allowed accurate measurements to be made and even at one inch the discrepancy was less than 10%. The tendency was for the more distantly placed small vessels to appear a fraction wider than their true size. Measurement could be made on the film with a fair degree of accuracy down to 20 microns. A less well defined and less intense shadow could be traced to about 10 microns and less in some instances.



:13

RADIOGRAPH OF WIRES, 40-1250 microns in diameter.  
Contact print.



14

## CHAPTER 2

### THE MATERIAL



Chapter 2: THE MATERIAL OF THIS INVESTIGATION

GENERAL STATEMENT.	page	2: 1
CRITERIA FOR THE DIVISION OF THE MATERIAL INTO GROUPS:		
I Normal		3
II Nearly normal.		4
III Heart disease other than coronary artery disease.		4
IV Coronary artery disease.		5
TABLES.		
Table 2: Composition of Group I.		9
Table 2: Composition of Group II.		10
Table 2: Composition of Group III.		11-12
Table 2: Composition of Group IV.		13-15
DIAGRAMS OF THE CORONARY CIRCULATION: and notes on their preparation and interpretation.		16
CASE RECORDS.		
REPRESENTATIVE STEREOARTERIOGRAMS OF INJECTED HEARTS.		

---

## CHAPTER 2

## THE MATERIAL OF THIS INVESTIGATION

After preliminary experiment with methods, the results of which were discarded, 25 cases of coronary artery disease and 34 control cases were examined. The control cases were divided into three groups. 17 were cases of heart disease other than coronary artery disease, and were mainly cases of rheumatic heart disease (Group III). The remainder were cases without cardiac abnormality (Group I), or with only slight departure from normality (Group II). One case in the coronary artery disease group (Group IV) also had mitral stenosis. Two cases in Group III also had evidence of myocardial infarction. In these cases muscle damage was thought to have resulted from embolism:

Table 2: 1

Group	No. of Cases	Reference symbol
I      NORMAL HEARTS	12	N
II     NEARLY NORMAL HEARTS	5	N
III    HEART DISEASE OTHER THAN CORONARY ARTERY DISEASE	17	D
IV     CORONARY ARTERY DISEASE	25	(none)
Total :	59	

Note:- Reference symbols: After "Groups I-IV" had been employed in the preparation of diagrams, it was found less confusing in the type-written text to use the reference symbols noted in the table above, when referring to individual cases. Thus:-

Case N3/

Note (ctd.):

- Case N3 = Control case no.3 in Group I (normal).  
 Case N'16 = Control case no.16 in Group II (nearly normal).  
 Case D 7 = Case no.7 in Group III in which were placed all control cases with heart disease other than coronary artery disease.

- N.B. (a) Cases N and N' are numbered consecutively, the last case in Group I being N12 and the first in Group II N'13.
- (b) NO SYMBOL precedes the cases in the coronary artery disease Group IV, to which reference is made much more frequently than to the others.

Sub-groups: Selection of cases within groups I-IV was sometimes necessary for the analysis of certain features that were insufficiently demonstrated at the time, or were inadequately preserved for review. The detail of such selection appears in the appropriate chapters, as for instance in chapters 4 and 5. In each instance the cases which were discarded were examined early in the investigation, and those retained were consecutive.

## CRITERIA FOR THE DIVISION OF THE MATERIAL INTO GROUPS I-IV

I. Normal

Of the hearts classed as "Normal", none showed left ventricular hypertrophy, atrial enlargement or valvular disease. Two cases, which showed a slight degree of right ventricular enlargement accompanying emphysema and bronchial carcinoma were not excluded from this group on that account (cases N8, 12). No case showed evidence of arterial hypertension.

There was no congenital malformation, with the exception of an anomalous origin of a branch of the left coronary artery (N6), which was not felt to have had any important haemodynamic influence on the coronary circulation as a whole.

The coronary arteries were free from disease except for very localised atherosclerosis in cases N2, 4, 5, 8. In case N2 the lesions were small and shallow, and there was no detectable alteration of the arterial lumen or contour. In the others the lesions were minute. There could have been no haemodynamic effects arising from them.

As may be seen in table 2: 2, the subjects died from a variety of diseases. Anaemia (Haemoglobin less than 70%) was known to have been present during life in one case (N.7).

The hearts were all of normal size. Smith's criteria for the upper limit of normal heart weight were used, being 412 gm. for a man and 371 gm. for a woman (Smith, 1928).

II. Nearly Normal/

## II. Nearly Normal

The hearts classed as "Nearly Normal" were from individuals in whom there was no clinical knowledge or post-mortem renal evidence of hypertension. There was no cardiac abnormality other than generalised increase in size. In two cases (N'14 and 15) adiposity accounted for a considerable proportion of the heart weight. Two other hearts were from unusually large and muscular individuals who had died from head injuries, having been in good health beforehand. No record was available in these cases of blood pressure prior to the accidents.

In case N15 there was slight to moderate atherosclerosis without obvious alteration in the arterial lumen. Consequently it was felt that the lesions of the arterial wall could have had no influence on the rest of the coronary circulation and that the heart was properly included in this group. The coronary arteries in the other 4 cases were healthy, or nearly so. Detail appears in Table 2:3.

## III. Heart Disease Other Than Coronary Artery Disease

Group III was largely composed of cases of rheumatic valvular disease. It included one case of essential pulmonary hypertension with marked right ventricular hypertrophy and also one case in which left ventricular hypertrophy was presumed to have resulted from essential systemic hypertension, but there were no records of blood pressure.

As already indicated, two cases also showed evidence of myocardial infarction. The muscle damage was thought to have been embolic in origin.

In/

In one instance it was of old standing and in the other was fresh and of small size.

The coronary arteries in this group were either healthy or the seat of slight atherosclerosis. There were however changes in the detail of the coronary "tree" related to the underlying cardiac disease. Some of these changes are dealt with in Chapter 4.

When planning this presentation it was intended to devote a chapter to changes in the coronary circulation in non-coronary heart disease, with hypertrophy of the chambers. In view of the dimensions of the thesis it has been decided to restrict this to the comments on anastomoses which are to be found in Chapter 4 and to some illustrations as the topics have arisen in other chapters.

Most of the cases of this group had been under the care and observation of the Department of Cardiology, Royal Infirmary, Edinburgh. Those which arose in Municipal Hospitals Autopsies had been under the care of Mr. Logan at the Eastern General Hospital, Edinburgh.

Some details appear in Table 2:4.

#### IV. Coronary Artery Disease

Cases of severe coronary artery disease were included in Group IV on account of the presence of obliterative coronary artery disease. In each instance there was at least one occlusion, complete or canalised. Most cases had died as the direct result of coronary artery disease. Of these, all/

all but one had been under the care or observation of Dr. Rae Gilchrist and staff in the Royal Infirmary, Edinburgh, as in-patients at the time or previously. Indeed, they comprised almost every autopsy on cases of ischaemic heart disease which had been under the observation of the Department of Cardiology during the period covered by this study. In this respect they were consecutive and unselected; and were fully documented.

' In the remaining 2 cases, severe coronary artery disease and myocardial infarction were incidental findings at autopsy. As might be expected, clinical information referable to ischaemic heart disease was scanty or absent in these cases.

It so happened that this series did not include cases in which there was coronary artery disease of intermediate grades only. Nearly all the cases in Group IV were selected by the severity and long duration of symptoms and/or death directly attributable to coronary artery disease of severe degree. In sharp contrast, atherosclerosis, where present at all, was of slight degree only in the hearts included in the other three groups. There was therefore no difficulty in allocating the cases to the coronary artery disease group or otherwise.

On general grounds it would have been desirable to have had a fifth group in which grades of atherosclerotic disease short of coronary occlusion could have been studied. It is doubtful however if this was a matter of fundamental importance; for in the individual hearts of Group IV all gradations from healthy arteries to severe obliterative disease were commonly represented.

A few details of the cases of Group IV appear in Table 2:5. When these/

these cases were under review for purposes of analysis, the data obtained were recorded on a large and complex abstract sheet. Selected portions of this abstract feature in Chapter 5, in which aspects of the relationships of coronary artery occlusion and myocardial damage are examined. The data relevant to other topics, such as arterial anastomoses, canalisation of occlusions, and the micro-anatomy of atherosclerotic lesions of the coronary arteries appear in the appropriate chapters.

In the case records which are included in this chapter a summary of the clinical features is followed by a brief description of the pathological findings. Each case record is accompanied by a drawing of the coronary circulation and a representative trans-ventricular section showing the distribution of the myocardial damage. Unless otherwise indicated, this section was taken approximately mid-way between the atrio-ventricular groove and the apex. In some instances arteriograms of the intact heart are included. Further description and numerous illustrations are distributed throughout the text. Only to a few of these is reference made in the protocols.



Table 2:2

Composition of Group I : NORMAL.					Average age: 37.2 years			
Case No.	Init.	Age	Sex	Heart Weight in gm.	Athero-sclerosis grade.	Cause of death	Associated conditions	P.M.No.
N 1	G.B.	35	F	200	-	Asphyxia	Epilepsy	190/52
N 2	M. C.	45	F	300	+	Pulmonary embolism	Appendix abscess paradoxical cerebral emb.	267/52
N 3	T. H.	52	M	400	-	Leptospirosis	-	359/52
N4	C. T.	19	M	N.size	(+)	Tuberculous meningitis	-	362/52
N 5	F.T.	11	M	N.Size	(+)	Astrocytoma	-	373/52
N 6	J.B.	59	F	320	-	Astrocytoma	-	272/53
N 7	D.F.	14	M	230	-	Haematemesis	Cirrhosis of liver.	274/53
N 8	J.G.	52	M	320	(+)	Sub-arachnoid haemorrhage.	Emphysema	369/53
N 9	J.O.	43	F	240	-	Tuberculous meningitis.	Addison's disease.	402/53
N 10	A.M.	8	M	140	-	Lymphosarcoma	-	RHSC 53/45
N 11	J.L.	67	M	380	-	Bronchial carcinoma	-	MHA 5247
N 12	J.M.	41	M	270	-	Bronchial carcinoma	Gastric ulcer	MHA 5253

Table 2:3/

Table 2:3

Composition of Group II : NEARLY NORMAL. Average age : 52 years								
Case No.	Init.	Age	Sex	Heart weight in gm.	Athero-sclerosis	Cause of death	Associated conditions	P.M.No.
N'13	G.N.	40	M	430	(+)	Myeloid leukaemia	-	404/52
N'14	D.M.	60	M	490	++	Medullary reticulosis	-	369/52
N'15	J.H.	54	M	490	-	Head injury	-	287/53
N'16	J.S.	37	M	430	-	Head injury	-	438/53
N'17	J.L.	69	F	400	+	Astrocytoma	-	MHA 5265

Notes on tables 2:2 and 2:3

1. Atherosclerosis grading:-

- (+) Minute flecks only.
- + Slight: No detectable change in lumen or contour, small lesions.
- ++ Moderate: Lesions large enough to cause slight alteration of contour but no important change in lumen calibre.
- +++ Moderately severe: Lesions cause obvious distortion of contour and encroach upon lumen up to about  $\frac{1}{2}$  original diameter.
- ++++ Severe: Lesions cause narrowing to  $\frac{1}{3}$  original diameter. Often associated with complete occlusion.

For the purposes of these tables, the grading refers to the most severe of the lesions present, even if, as was usually the case, the disease was restricted to very short stretches of a single artery.

2. The weighing machine was temporarily unavailable at the time certain cases were examined, and omission to weigh the portions at a later date was an oversight. There was, however, no doubt whatsoever that the hearts were within normal limits of size and weight.

Table 2: 4.

Composition of GROUP III:				HEART DISEASE OTHER THAN CORONARY ARTERY DISEASE							Average Age	37.6 years		
Case No.	Initials	Age	Sex	Heart weight in gm.	Athero-sclerosis grade	Cause of death	Cardiac Disease	Ventricular enlargement R. L.		Ischaemic myocardial damage	Ischaemic symptoms	Atrial Rhythm	Associated conditions : Comments	P.M.No.
D 1	R.M.	42	M	670	+	C.C.F.	Syphilitic Aortic incompetence	+	+++	?+	+		Aortitis. L.Bundle Branch Block	246/52
D 2	M.B.	50	F	450	(+)	Aortic embolism	Mitral Stenosis	+	+	+	?	A.F.	Earlier embolism of sup.mesenteric, renal, splenic and ?L.coronary arteries	282/52
D 3	R.R.	49	M	820	+ single plaque	Sudden cardiac	Aortic Stenosis	-	+++	+	+ 1934		Angina 18 yrs. before death. Old fibrotic ant. infarct, probably embolic. Capsular fibrosis liver and spleen.	302/52
D 4	H.S.	27	M	750	-	Coma. Stokes-Adams attack	Mitral Stenosis Aortic Stenosis	+++	+++	?+	-		Pulmonary vascular changes +++. Complete heart block.	338/52
D 5	A.F.	17	F	690	-	C.C.F.	Mitral incompetence.	++	++	-	-	A.F.	-	453/52
D 6	J.M.	38	F	870	-	C.C.F. sudden cardiac	Mitral incompetence.	+++	+++	-	-	A.F.	Old, treated bacterial endocarditis. Old embolic infarcts spleen and kidney	538/52
D 7	A.S.	16	F	450	-	During anaesthesia. R.V.F.	Primary pulmonary hypertension	+++	-	?	+		Pulmonary vascular changes +++ L.atrium size of bantum's egg.	540/52
D.8	T.T.	34	M	850	-	C.C.F.	Aortic incompetence and stenosis. Mitral Stenosis.	+++	+++	-	-			551/52
D 9	E.L.	24	F	490	-	C.C.F.	Mitral Stenosis	+++	-	-	-	A.F.	Pulmonary vascular changes +++ Multiple infarcts of lungs, with pyrexia. Old infarct of kidney.	573/52
D 10	G.W.	40	F	520	-	Carotid embolism	Mitral incompetence and stenosis	+	+++	-	-	A.F.	Mitral surgery 3 wks. before death. B.P. 150/100. Bilateral renal infarcts.	626/52
D 11	K.M.	22	F	380	-	C.C.F.	Mitral stenosis	+++	-	?	+		Pulmonary vascular changes +++ Multiple pulmonary infarcts, with pyrexia	690/52
D 12	M.C.	53	F	620	+	C.C.F. coma	Mitral Stenosis Tricuspid incompetence. Aortic Stenosis.	+++	++	?+	-	A.F.	Cardiac cirrhosis of liver pulmonary infarcts. Old atrial thrombus.	26/53

Table 2:4 (ctd.)

Case No.	Init-ials	Age	Sex	Heart weight in gms.	Athero-sclerosis grade	Cause of death	Cardiac Disease	Ventricular enlargement		Ischaemic myocardial damage	Ischaemic symptoms	Atrial Rhythm	Associated conditions: Comments	P.M.No.
								R	L					
D 13	J.B.	66	M	590	++	?	Hypertension. Pulmonary Heart Disease. Pericarditis	+	+++	-	?		Emphysema. Unilateral nephrosclerosis. Terminal acute serous pericardial effusion. Exact cause of death uncertain.	125/53
D 14	M.D.	52	F	315	-	Abdominal abscess	Mitral Stenosis (1.8 cm. diam.) Bacterial endocarditis.	(+)	-	-	-		Duodenal ulcer: partial gastrectomy. Post-operative abscess. Infarcts kidney and spleen. Pleurisy.	399/53
D 15	R.B.	37	M	620	-	Cerebral: ? Anoxia	Mitral incompetence with stenosis. Aortic stenosis (slight)	++	+++	-	?+	A.F.	Pericardial sling valvoplasty. Consciousness not regained after operation. 2 old, 1 fresh, minor cerebral infarcts	MHA 5090
D 16	A.T.	34	M	460	-	Cardiac arrest	Mitral stenosis. Aortic stenosis (slight)	++	-	-	-		Pulmonary vascular changes ++. Mitral valvotomy. C. arrest, ?from thrombus obstructing mitral orifice.	MHA 5115
D 17	O.H.	35	F	530	-	C.C.F.	Mitral stenosis and incompetence	+	++	-	-	A.F.	Mitral valvotomy and pericardial sling valvoplasty, 1951. Old cerebral and renal embolic infarcts.	MHA 5246

Notes 2:4

C.C.F. = Congestive cardiac failure.  
A.F. = Atrial fibrillation. If not so indicated the atrial rhythm was regular.

Atherosclerosis grade : see notes 2:2,3.

Ischaemic myocardial damage:

+ = definite infarct.  
?+ = Fibrosis, probably ischaemic replacement fibrosis, but not certain.  
? = Fairly coarse fibrosis but probably not ischaemic in origin.

Ischaemic symptoms :

+ = Anginal symptoms definite.  
?+ = Chest pain, probably anginal.  
? = Chest pain of indeterminate character, could have ischaemic origin.

Table 2:5

Composition of Group IV				SEVERE CORONARY ARTERY DISEASE, with occlusion					Average Age 61.7 years					
No.	Init.	Age	Sex	Heart Weight in gm.	Cardiac enlargement	B.P. in mm.Hg.	Immediate cause of death	Other conditions (in addition)	*Atherosclerosis grade	Anginal history in years	Recent coronary occlusion	Comments	Anti-coag. Ther.	P.M. No.
1.	H.H.	33	M	580	+	120/80	Cerebral Thrombosis	?Polycythaemia Pulmonary infarction Portal vein thrombosis	-	7	-	Obliteration of L. Coronary artery. Entire coronary blood supply from R.C. 7 yrs. No underlying atherosclerosis.	-	216/52
2.	M.R.	58	F	450	+	220/120	Cerebral haemorrhage	-	++++	1	+	Presented with hemiplegia, + E.C.G. of ant. myocardial infarction. Anginal symptoms indefinite.		224/52
3.	J.M.	45	M	400	-	130/85	Myocardial infarction	-	++	7/52	+	Sudden death during recovery phase of 1st ischaemic illness.	+	241/52
4.	S.R.	69	M	450	+	180/120	Aortic embolism	Prostatism Cystostomy	++++	7	-	Good recovery from C.C.F. (+) due to myocardial infarction, 7 yrs. before death. Extensive myocardial damage and obliterative coronary artery disease.		274/52
5.	A.S.	59	M	470	+	(104/60)	Myocardial infarction	-	++++	1	+	Two major occlusive episodes, 1 year apart	(+)	300/52
6.	A.M.	67	F	530	+	138/84	Mediastinitis	Carcinoma of thyroid Thyroidectomy	++++	13	-	Long history of progressive - angina. Widespread advanced obliterative coronary artery disease.		315/52
7.	R.A.	59	M	350	-	120/88	Myocardial infarction	-	++++	7/12	+	Two major occlusive episodes, 8 months apart.	+	384/52
8.	J.E.	65	M	380	-	200/100	Acute coronary insufficiency	Rheumatoid arthritis	++++	12	-	Long history of progressive - angina. Widespread obliterative coronary artery disease.	-	393/52
9.	J.D.	59	M	410	-	170/100	Myocardial infarction +laparotomy	Peptic ulceration	++++	3/12	+	Posterior infarction, involving right ventricle and causing rupture of L. ventricular wall.	+	443/52
10.	M.C.	75	F	450	+	(106/66)	Acute coronary insufficiency	Diabetic ketosis	++++	6/12	-	Widespread advanced obliterative coronary artery disease of old standing.	(+)	580/52
11.	H.L.	80	M	570	+	170/100	Pulmonary infarction +myocardial infarction	-	++++	8/12	+	Two major episodes 7 months apart with multiple thrombotic occlusions.	+	586/52

Table 2:5 (ctd.)

No.	Init.	Age	Sex	Heart Weight in gm.	Cardiac Enlargement	B.P. in mm. Hg.	Immediate cause of death	Other conditions (in addition)	*Atherosclerosis grade	Anginal history in years	Recent coronary occlusion	Comments	Anti-coag. Ther.	P.M. No.
12	C.M.	55	M	450	+	120/80	Myocardial infarction	-	++++	19/12	+	Two major episodes 19 months apart. Multiple thrombotic occlusions terminally.	-	630/52
13.	T.W.	70	M	470	+	(112/80)	Myocardial infarction	Mitral stenosis Anthracosilicosis	++	11 days	+	Death in acute phase of first ischaemic episode.	-	676/52
14.	E.W.	64	F	570	+	(100/80)	Myocardial infarction	Diabetes mellitus. Nephrosclerosis.	++++	3/52	+	Brief history on background of long-standing obliterative coronary artery disease and fresh occlusion.	-	740/52
15.	M.L.	56	F	420	+	140/86	Mesenteric embolism	Rheumatoid arthritis (Pneumonia)	+	1/12	+	Brief history with old-standing severe coronary artery disease + fresh occlusion.	+	741/52
16.	M.A.	72	F	420	+	126/86	Myocardial infarction	Embolism of renal, brachial and vertebral arteries.	++	?(3/12)	+	8 wks. No pain despite severe myocardial infarction.	+	73/53
17.	B.M.	73	F	355	-	155/75	Acute coronary insufficiency	Carcinoma of stomach. Cerebro-vascular disease.	++++	10/365	-	Long history of angina. Widespread old severe coronary artery disease. Inner zonal infarction of L.V. without fresh coronary occlusion.	+	84/53
18.	W.G.	71	M	530	+	"Known hypertensive"	Myocardial infarction	Hypertension. Diabetes mellitus.	+++	?(1/365)	-	Old standing occlusion. No pain recorded except on day of death.	-	M.H.A. 5099
19.	J.S.	73	F	610	+	180/140	Acute coronary insufficiency	Hypertension	++++	10	-	Long history of angina. Widespread old severe coronary artery disease. Inner zonal infarction of L.V. without fresh occlusion.	(+)	126/53
20.	J.C.	73	F	435	+	(120/70)	Myocardial infarction	Gall-stones	++	?(1)	+	Anginal symptoms may have been masked by biliary colic. Rupture of I.V.S.	(+)	198/53

Table 2:5

Composition of Group IV							SEVERE CORONARY ARTERY DISEASE WITH OCCLUSION				Average Age 61-7 years			
No.	Init.	Age	Sex	Heart Weight in gm.	Cardiac enlarge-ment	B.P. in mm.Hg.	Immediate cause of death	Other conditions (in addition)	*Athero-sclerosis grade	Anginal history in years	Recent coronary occlusion	Comments	Anti-coag. Ther.	P.M. No.
21	J.M.	50	M	410	-	(102/86)	Myocardial infarction	-	++	2	+	Death due to a lesion less than 2 mm. in extent, in L.C. main stem. Terminally entire coronary circulation from R.C.	(+)	246/53
22	T.B.	66	M	590	+	(88/72)	Myocardial infarction	-	++++	2	+	Two major occlusive episodes 2 years apart. Unusual occlusion R.C.	(+)	273/53
23	H.E.	62	F	440	+	129/80	Post-operative complications	Carcinoma of stomach. Gastrectomy	++	?	-	Gall bladder dyspepsia at 27 yrs. No anginal history. Myocardial infarction incidental at P.M.	-	367/53
24	S.Q.	38	M	495	+	160/96	Myocardial infarction	-	++++	6/12	+	Two major occlusive episodes, 6 months apart. Oestrogen therapy.	+	420/53
25	W.V.	50	M	465	+	(175/108)	Subarachnoid haemorrhage	Bronchitis	++++	?	-	Coronary occlusions and myocardial infarction incidental at P.M.	-	436/53

Notes table 2:5

- "Cardiac enlargement": weights in excess of Smith's criteria for upper limit of normal (412 gm. for a man and 371 gm. for a woman, Smith, 1928).
- "B.P." = Highest recorded B.P. taken under conditions where this seemed to reflect the true B.P. Readings in brackets were taken during the acute phase after myocardial infarction and may well be low. They are however the only records available. In case 25 there had been recent intracranial haemorrhage.
- \*"Atherosclerosis Grade" : The grade recorded refers to the state of the arteries before and apart from the lesion which is the site of the most recent occlusion, no matter whether this is of long standing or fresh.
- "Anginal History" ? = No history of ischaemic pain or tightness obtained. It is possible that symptoms had been experienced and forgotten.
- "Recent coronary occlusion" = 6 weeks or less except where indicated.
- "Anticoagulant therapy" : nearly always heparin and phenindione. Brackets indicate therapy of less than 48 hours' duration.

DIAGRAMS OF THE CORONARY CIRCULATIONNotes on their preparation and interpretation

The arterial diagrams which follow have been prepared from stereo-artereograms, in conjunction with all other available data.

Care has been taken throughout that the drawings should form a faithful record of the configuration and dimensions of the injected lumen of the major coronary arteries; and of the anatomical detail of arterial branches and anastomoses. The original drawings were largely based on tracings of the arteriograms. Photographic reproduction of them has been made exactly to half-scale. Measurements of lumen diameters made from these diagrams would accordingly be valid.

The upper portion of each arterial diagram was a tracing of the arteriogram of the "Basal Block" of the heart (see Chapter 1)\*. The lower or apical portion was a composite drawing based upon the stereogram of the intact heart and of the trans-ventricular sections. In this portion, some of the arterial branches have been extended lengthwise in order to allow continuity in a two dimensional drawing. Further, it will be recognised that considerable simplification of the detail of smaller branches has been necessary in these drawings. Again, here and there, some slight spatial adjustment of branches has been practised so that a confusion of overlapping structures be avoided.

A drawing of a healthy coronary "tree" appears at the end of this group of illustrations, after case 25. This case was in Group II. It was chosen in preference to one of strictly normal size for two reasons:

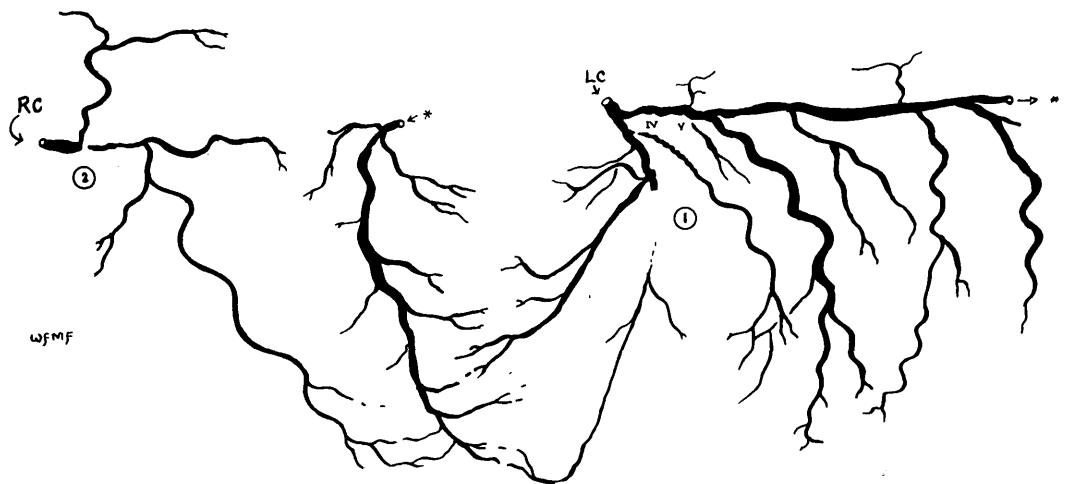
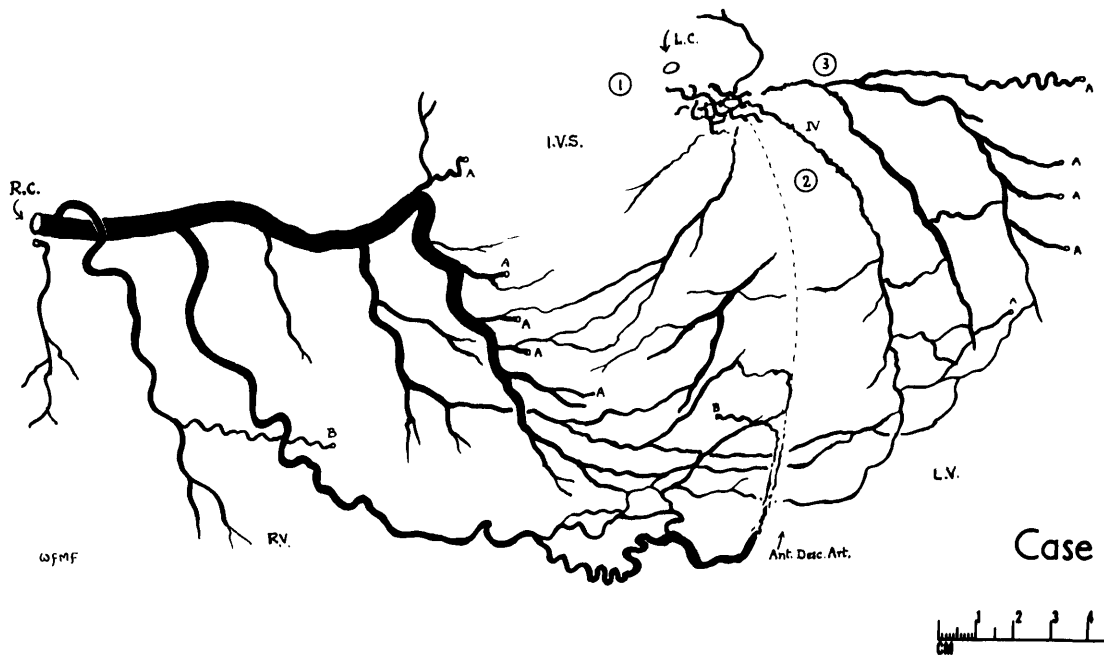
1. Most of the hearts in the coronary disease group were enlarged.
2. It was the most "normal" coronary tree in the control series in respect of the anatomical distribution of the major arteries.

---

\* The arterial diagrams of cases 1-5 have been prepared from the stereo-arteriograms of the intact heart together with notes on the findings made available at dissection. Arteriograms of the "Basal Block" were not available for these cases.

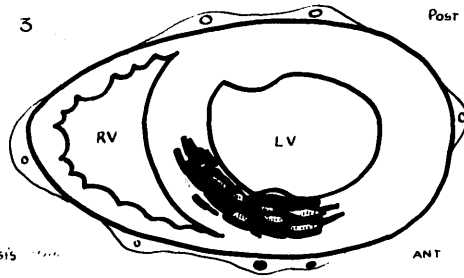
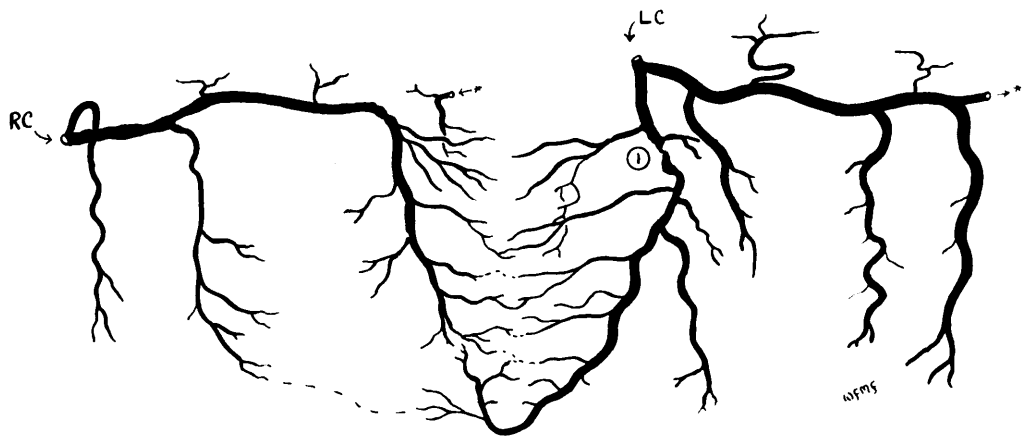


# DIAGRAMS of the CORONARY CIRCULATION : 25 CASES



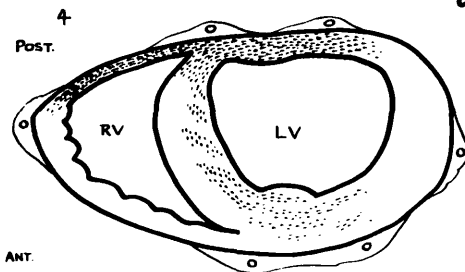
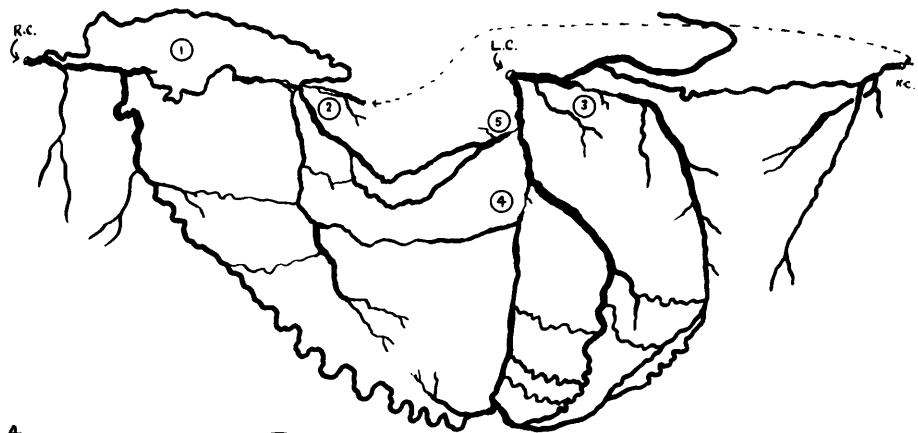
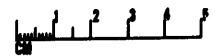
Case 2.

~ For interpretation of the arterial diagrams, see notes on previous page and detail of individual cases in the case records. An example of a healthy coronary "tree" has been placed at the end of this group of illustrations, and follows case 25. ~  
 ~ All diagrams have been drawn strictly to scale. ~ ~ ~ ~



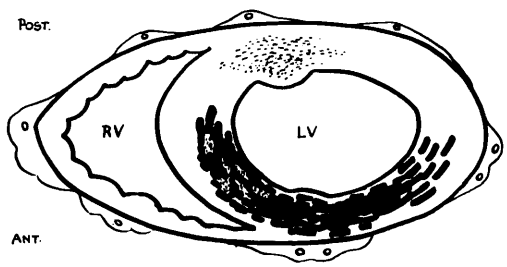
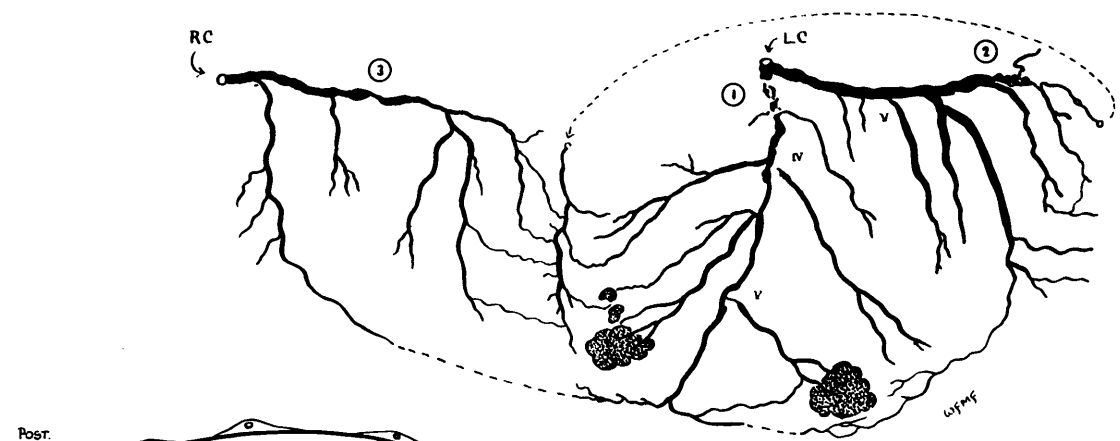
Focal Fibrosis  
Myo. Infarction, 10 weeks

Case 3.



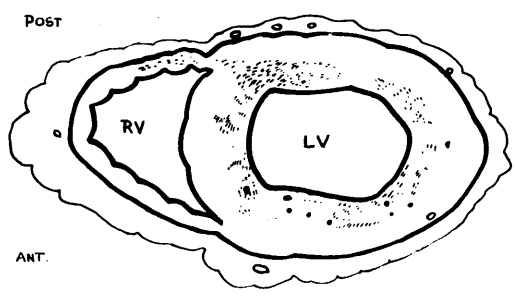
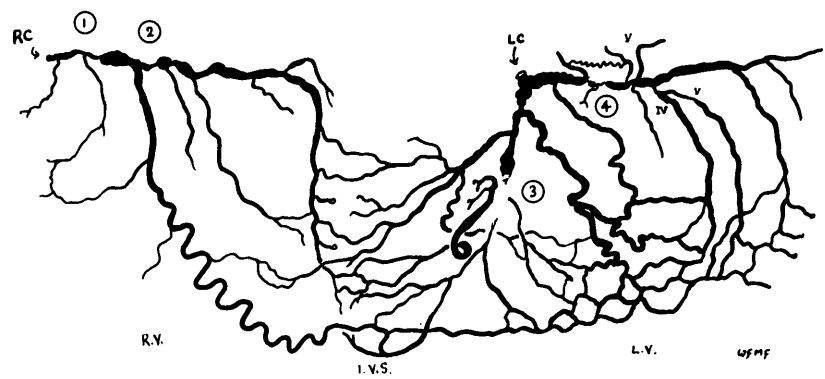
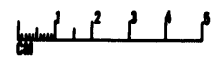
Old fibrotic infarct, 7 yrs

Case 4.



Post.  
ANT.  
Fibrosis 1 year+   
Recent necrosis 2 days

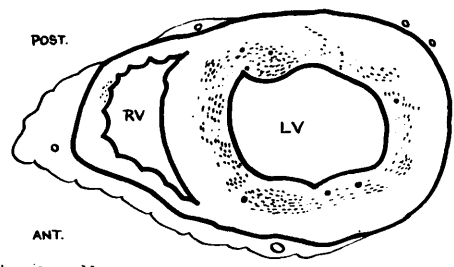
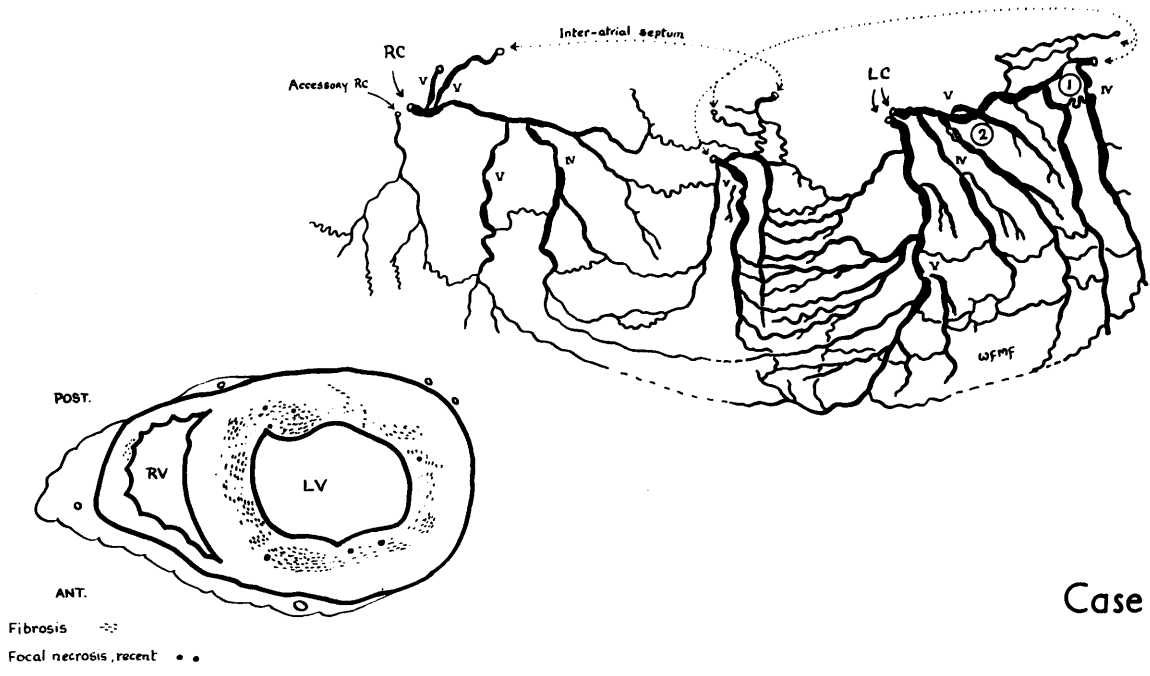
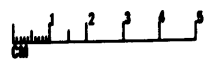
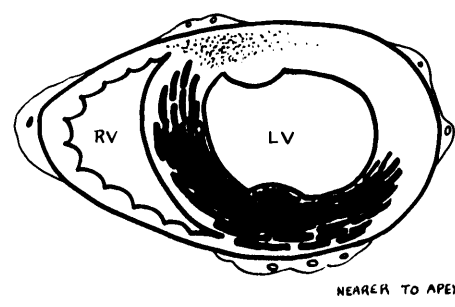
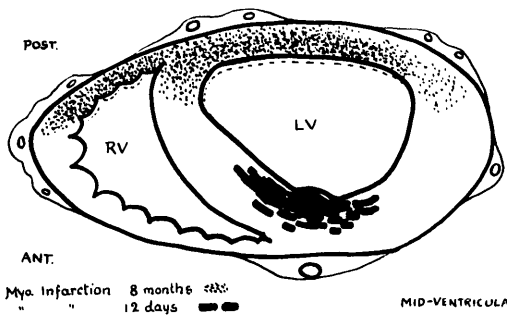
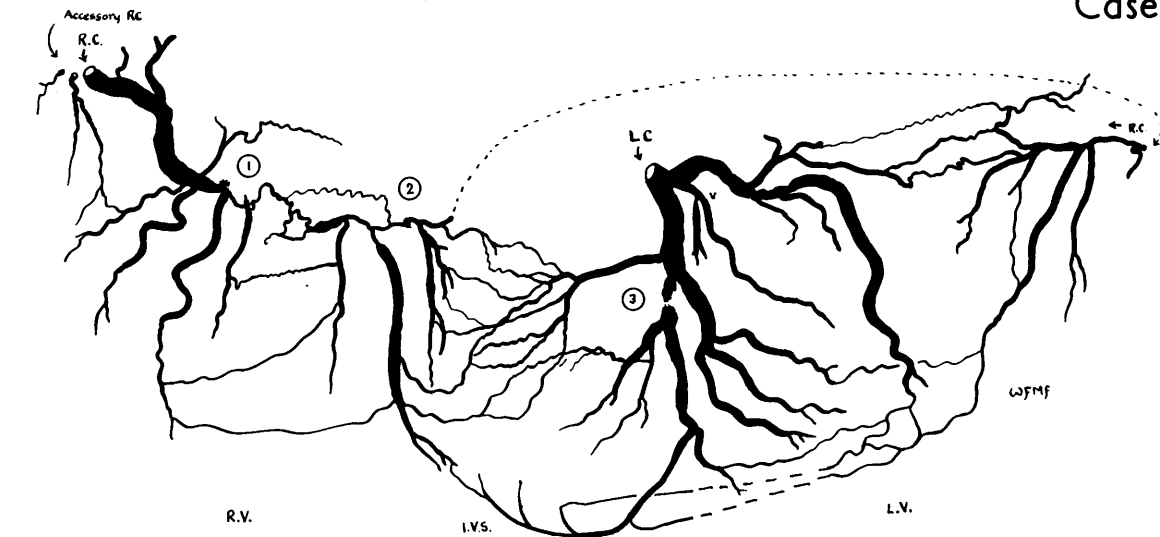
Case 5.



Post  
ANT.  
Old Fibrosis (→ 13 yrs)  
Focal Necrosis

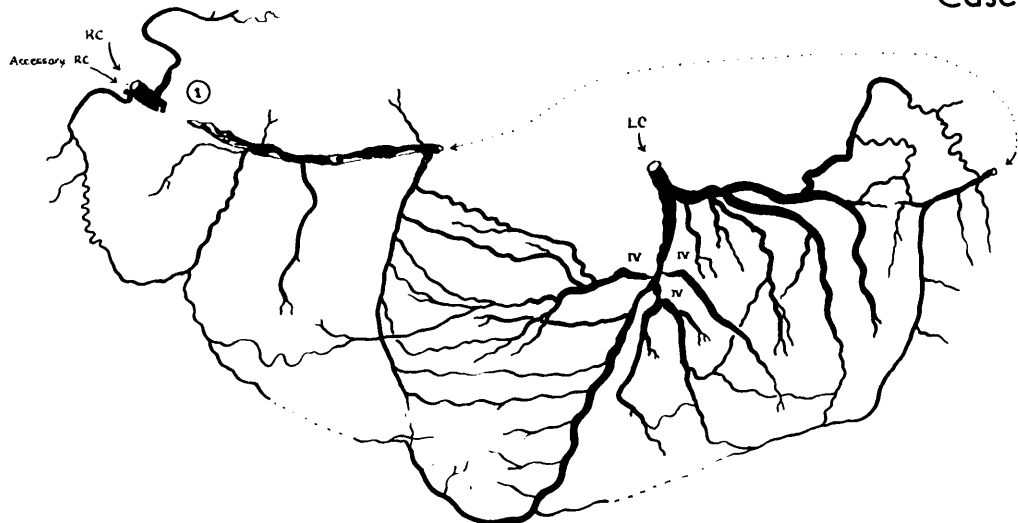
Case 6.




# Case 7

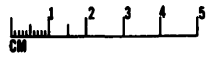
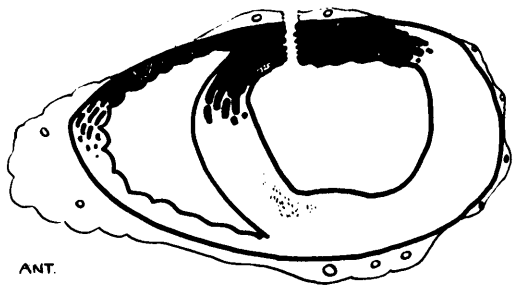


# Case 8

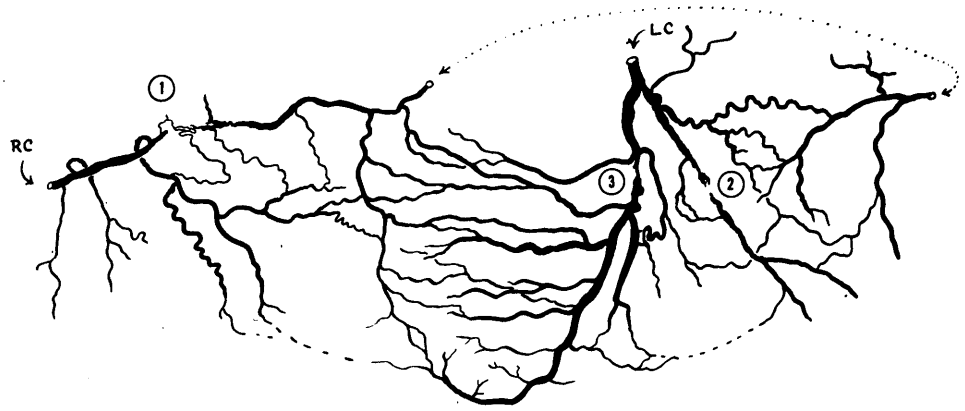
### Case 9.






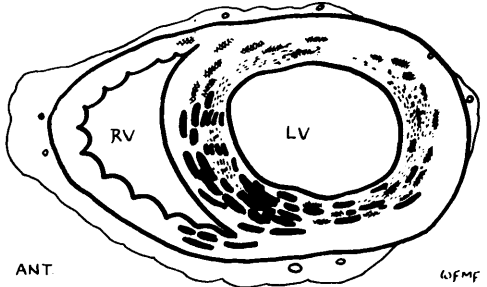
Old fibrosis   
 Myo. infarction, 1-3 months.   
 " " " " , 12 days.   
 wmf.



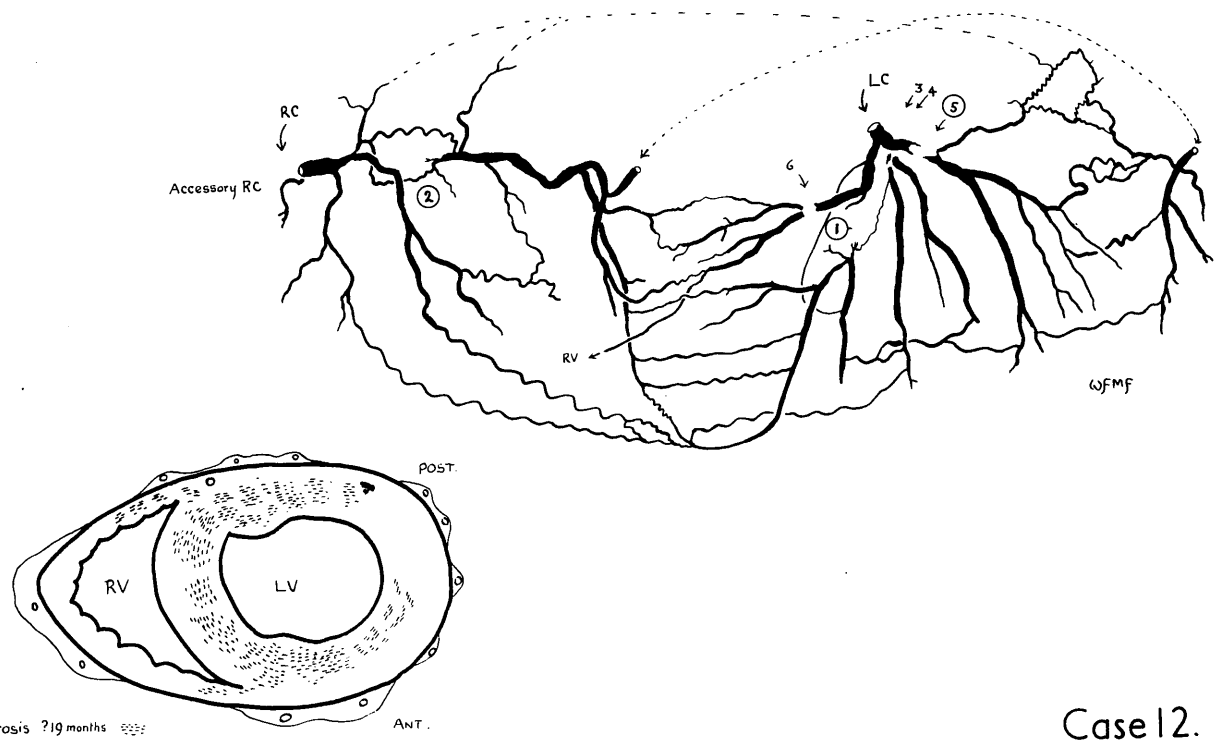
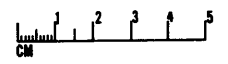
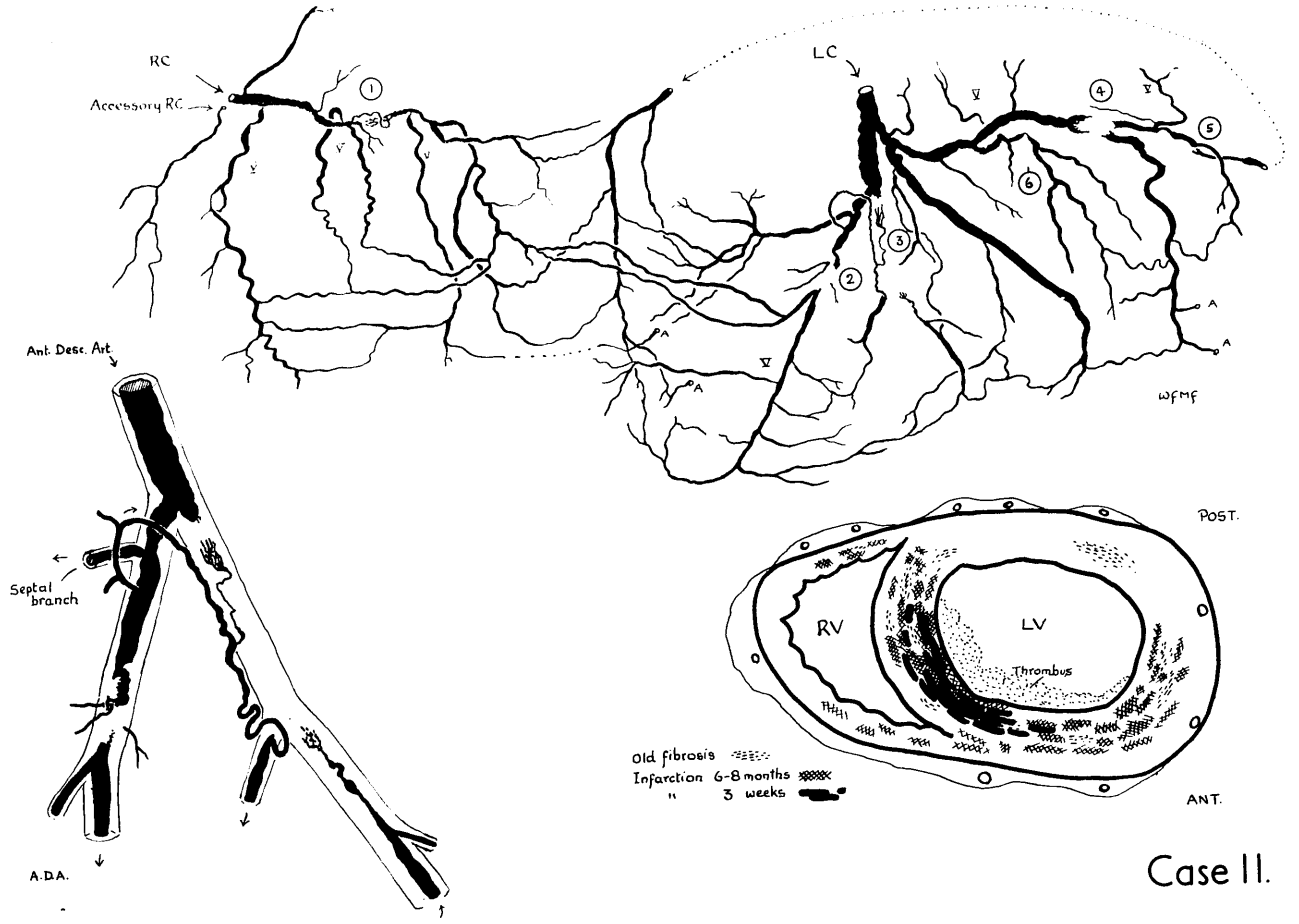
### Case 10.

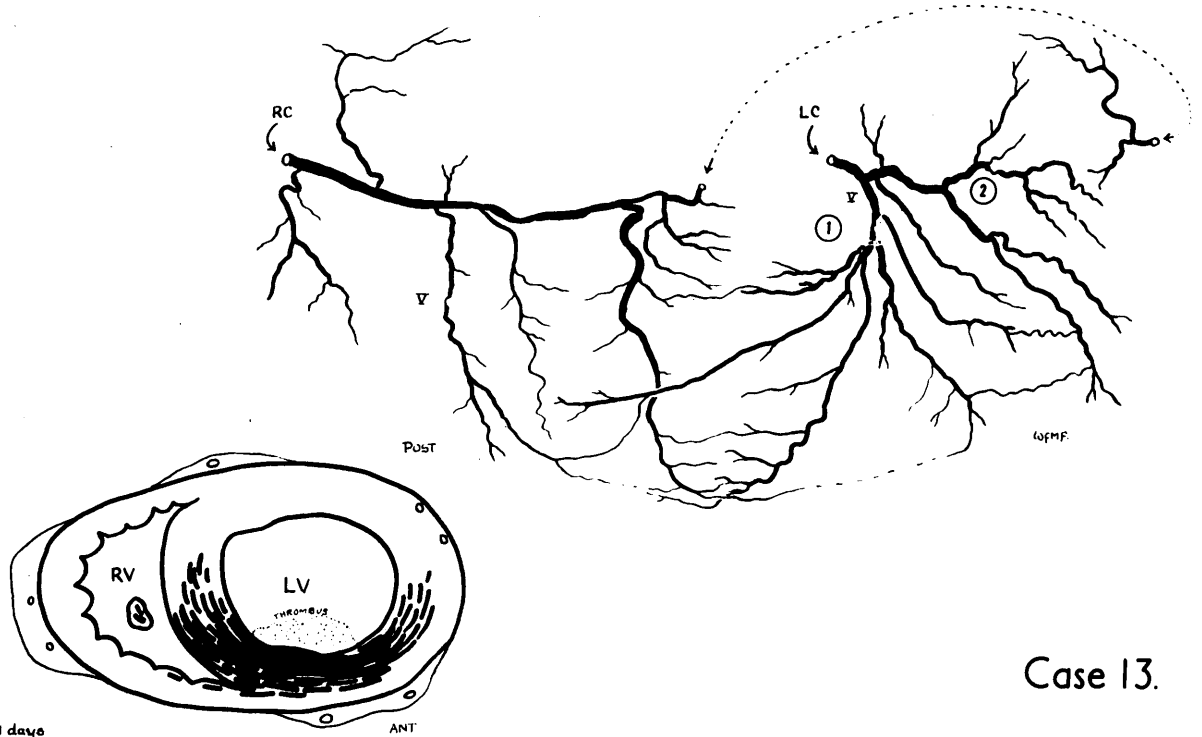


Fibrosis   
 Necrosis, healing, 6 months   
 Recent Necrosis, 2-3 days 



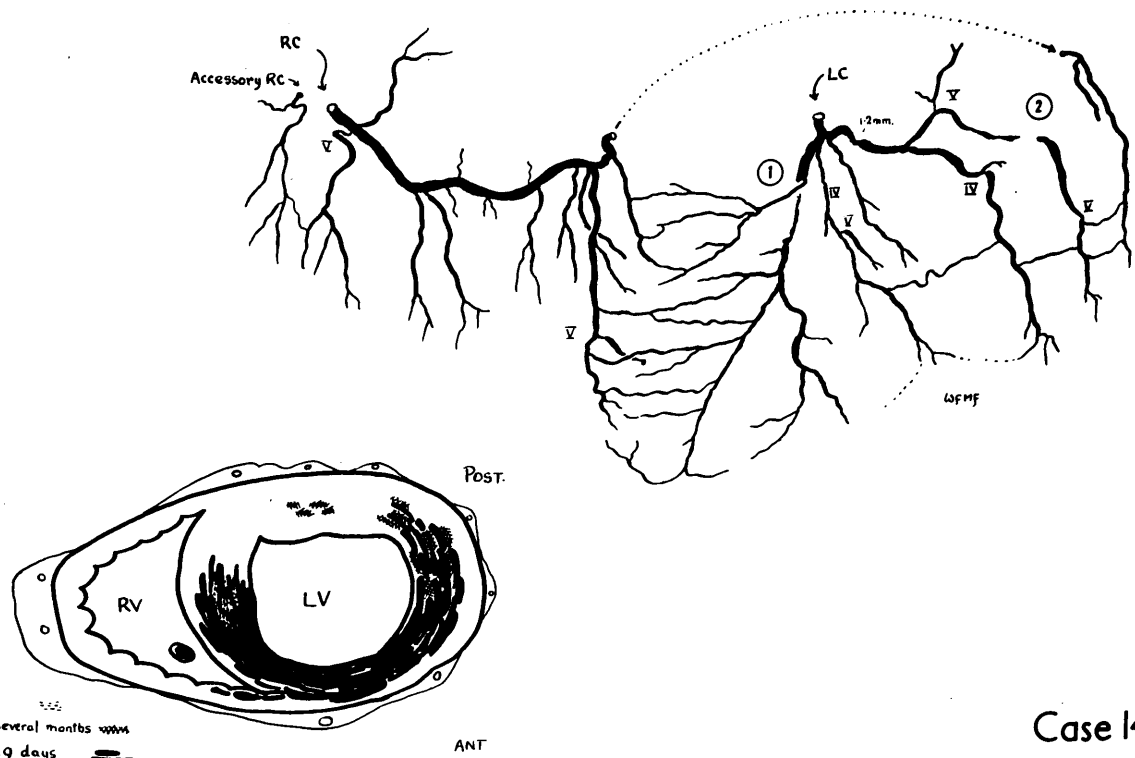
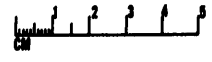
wmf





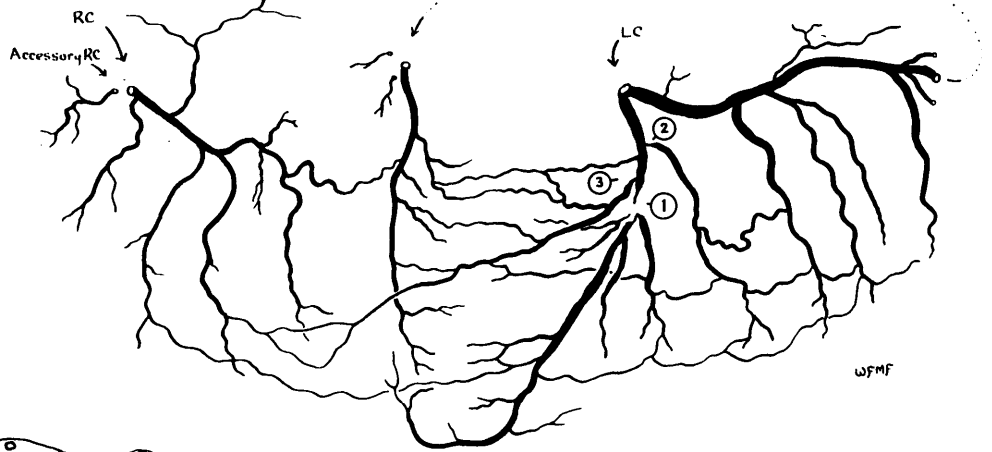
Case 13.

Myo. Infarct, 11 days

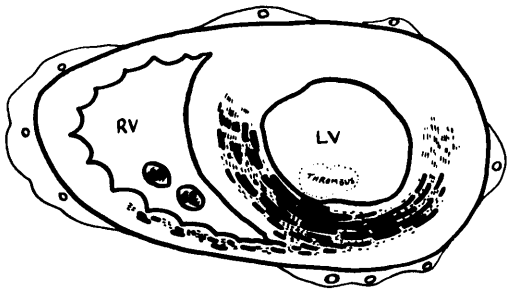




Case 14.

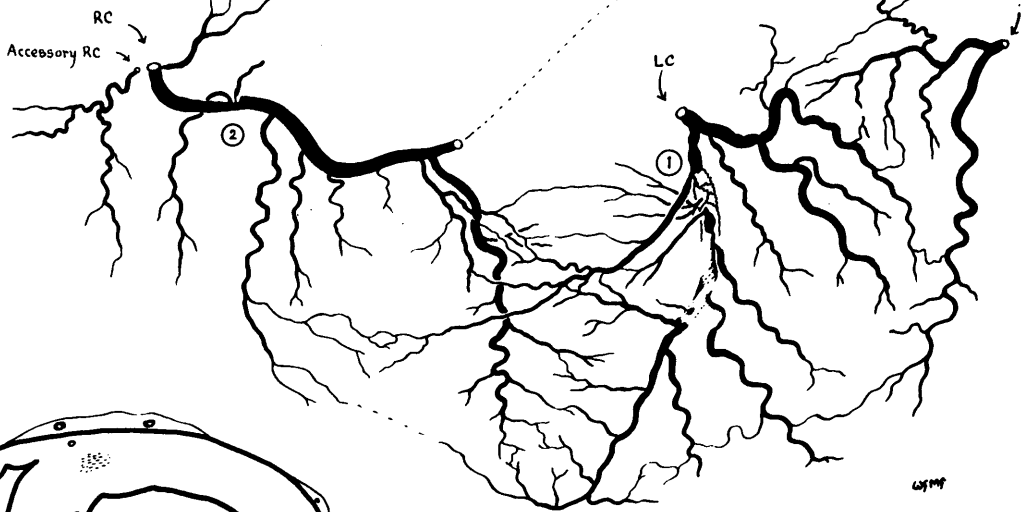
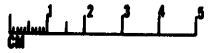
Fibrosis ? age  
 Myo. Infarct : several months  
 Myo. Infarct 19 days



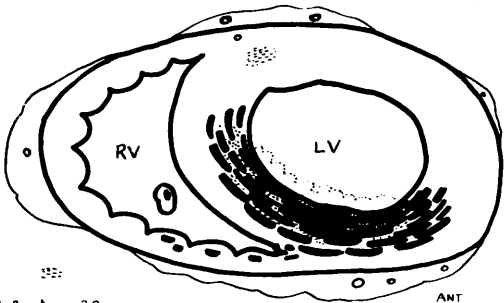
Case 15.





Fibrosis   
 Necrosis 4 1/2 weeks 



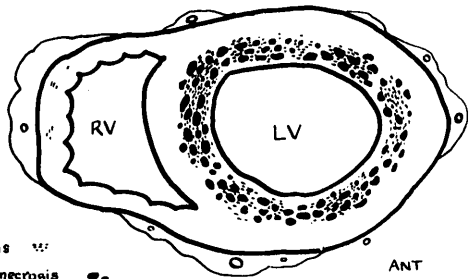
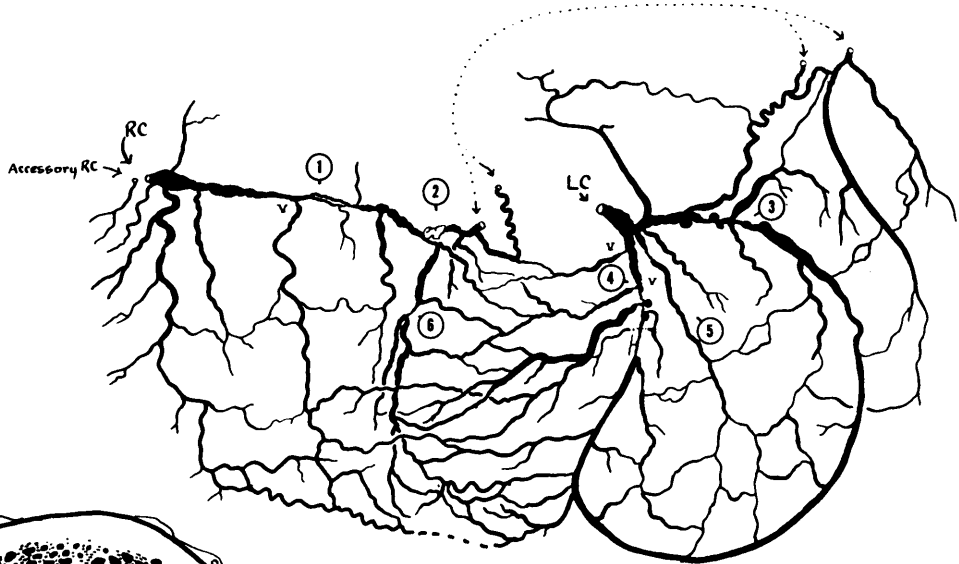
Case 16.



Fibrosis   
 Recent Infarction ? 2 months 

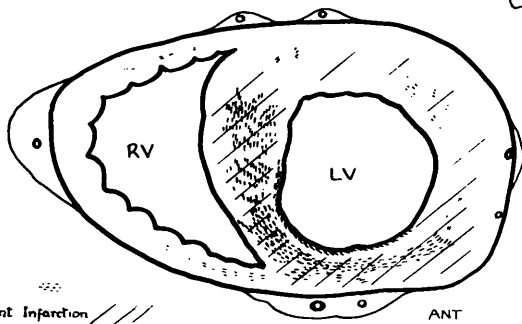
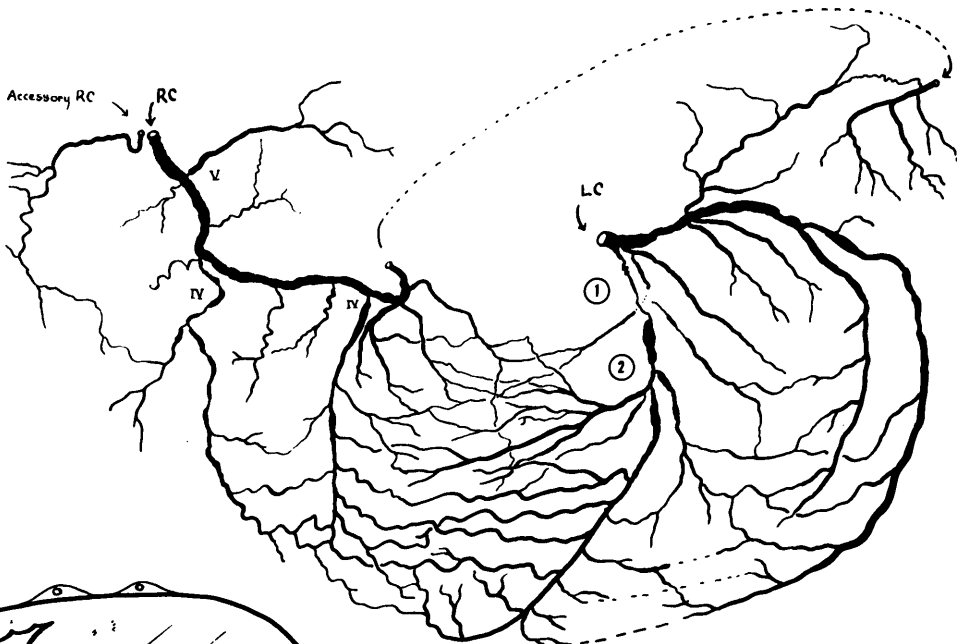
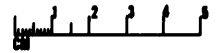
ANT





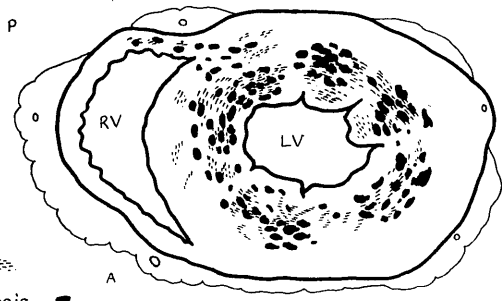
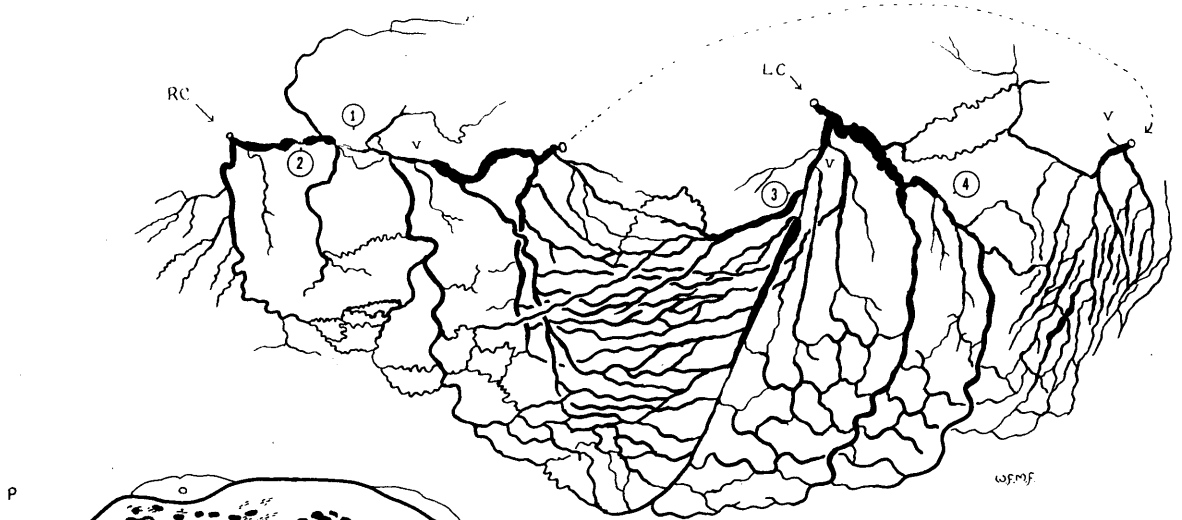
Fibrosis   
 Focal necrosis (1 month and also more recent)



Case 17.



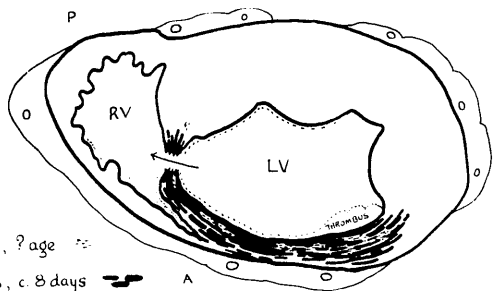
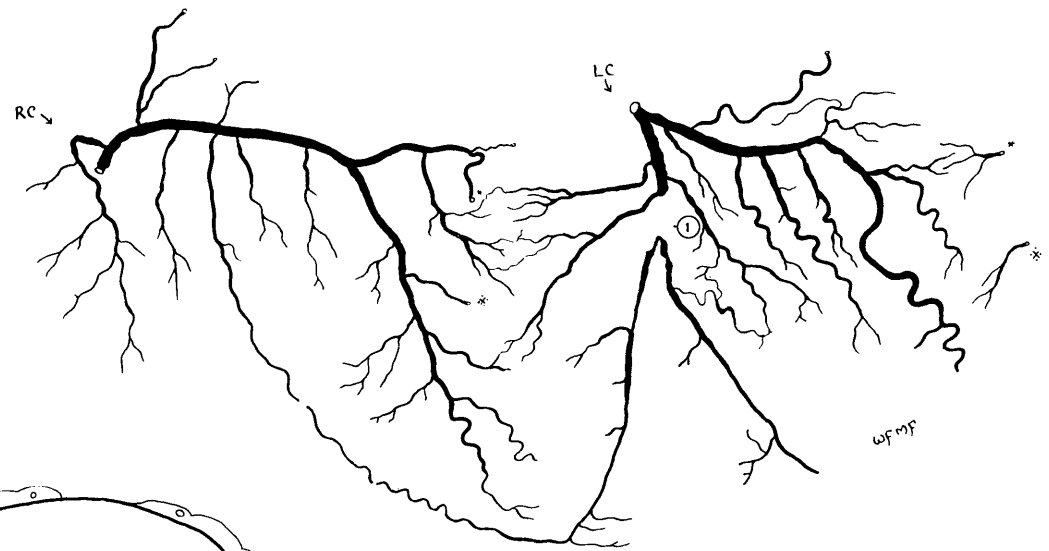
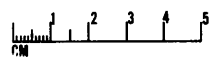
Fibrosis   
 ? Very Recent Infarction



Case 18.



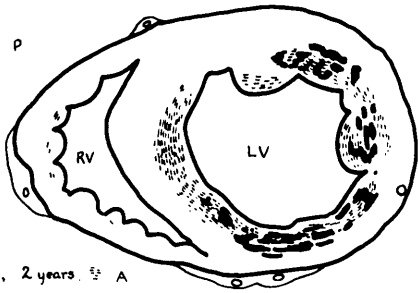
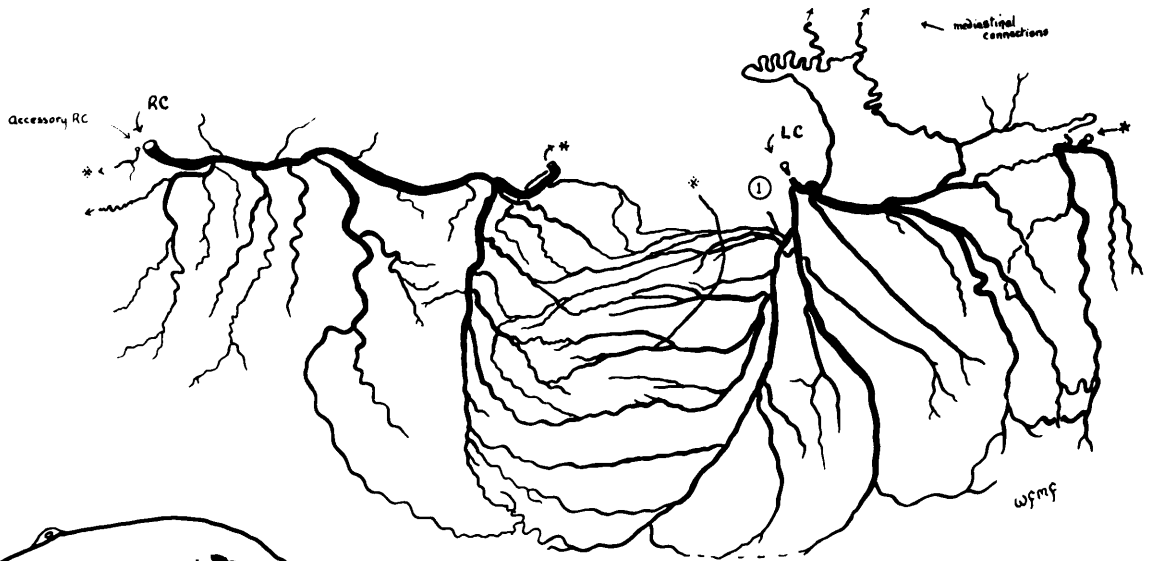
Fibrosis   
 Focal necrosis 1 day 

Case 19.



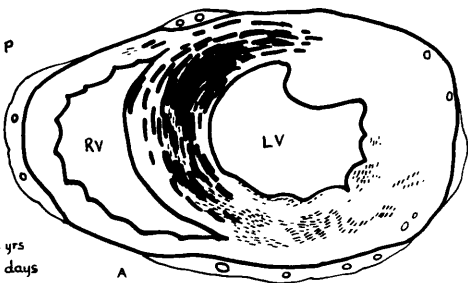
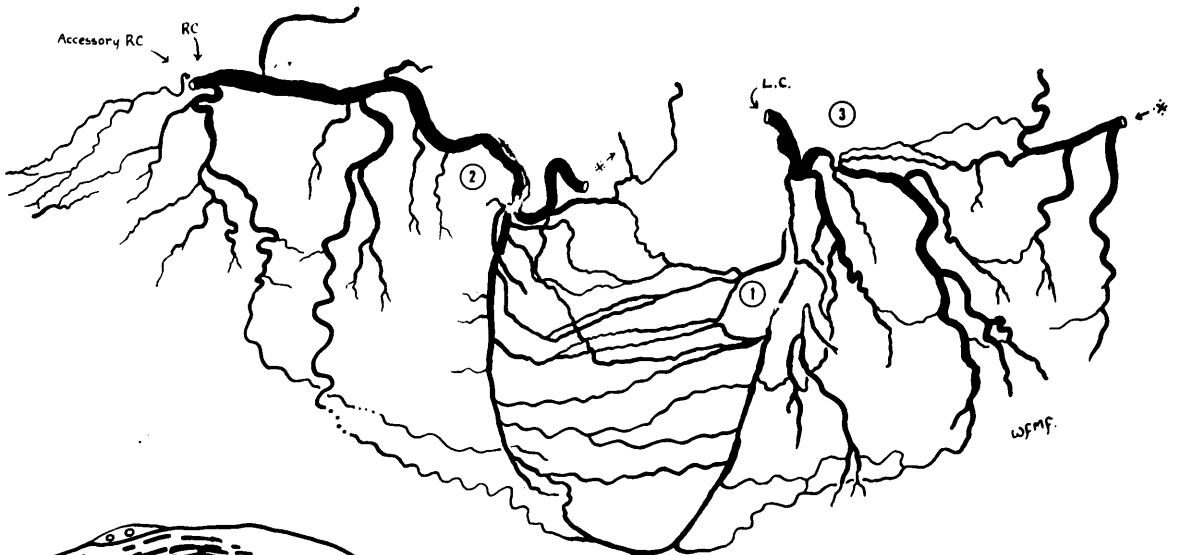
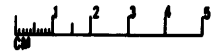
Fibrosis, ? age   
 Necrosis, c. 8 days 

Case 20.



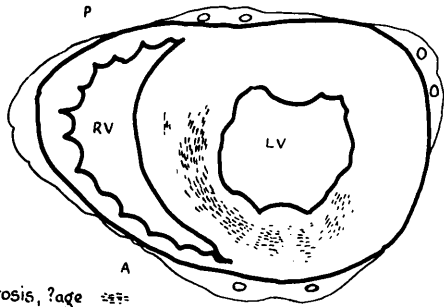
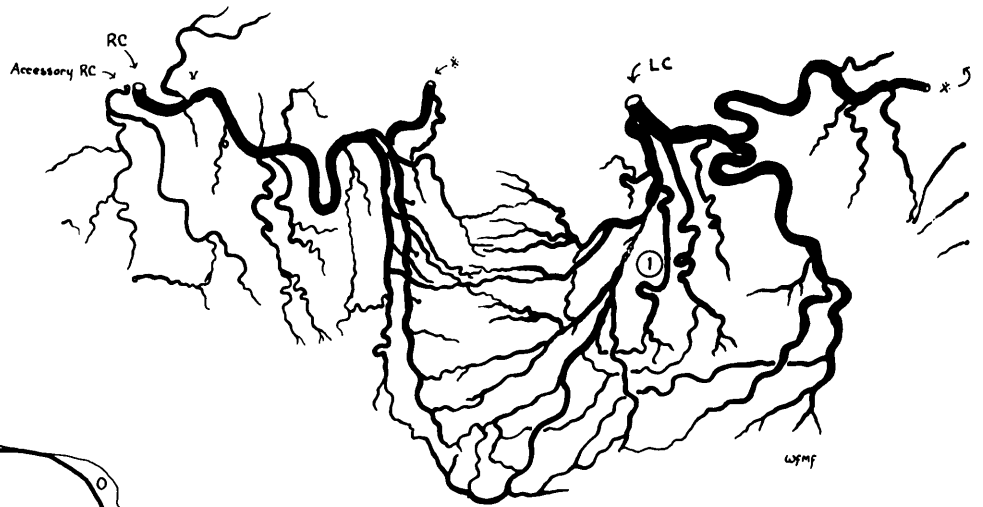Fibrosis, 2 years. A  
 Necrosis, 2-4 days.

Case 21.



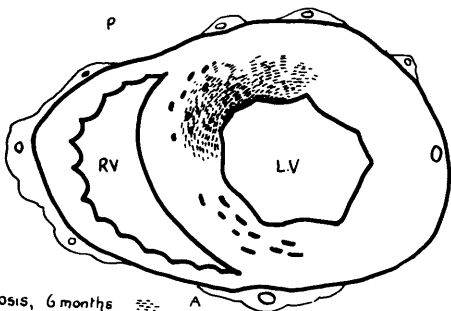
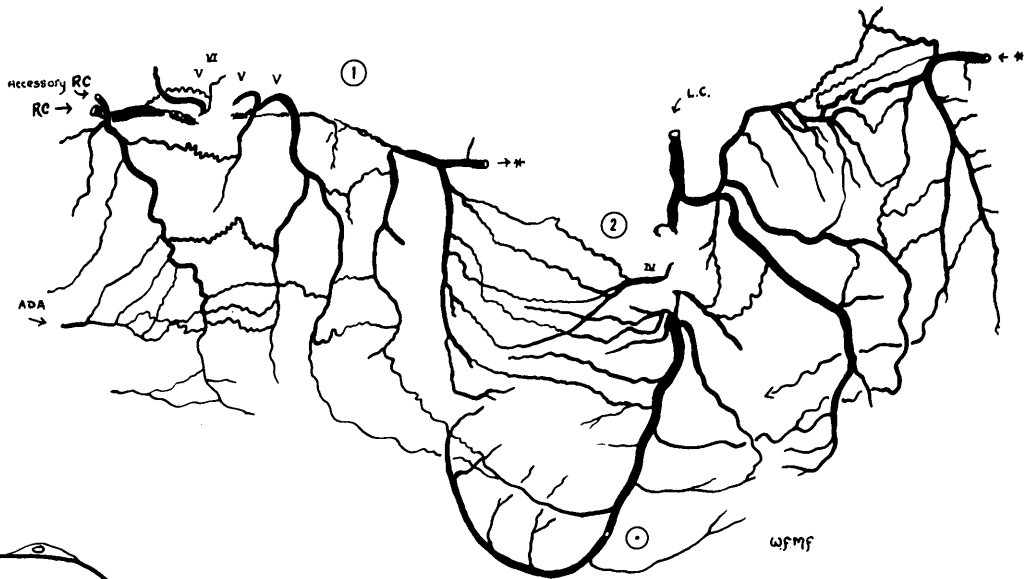
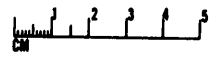
Fibrosis, 2 yrs   
 Necrosis, 2 days

Case 22.

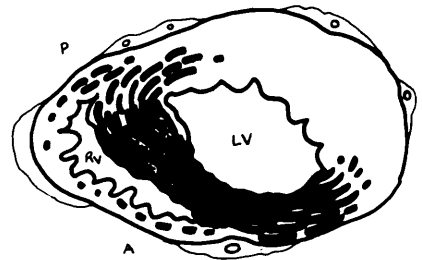


Fibrosis, ?age

Case 23.

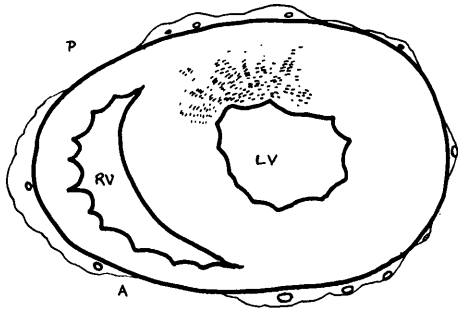
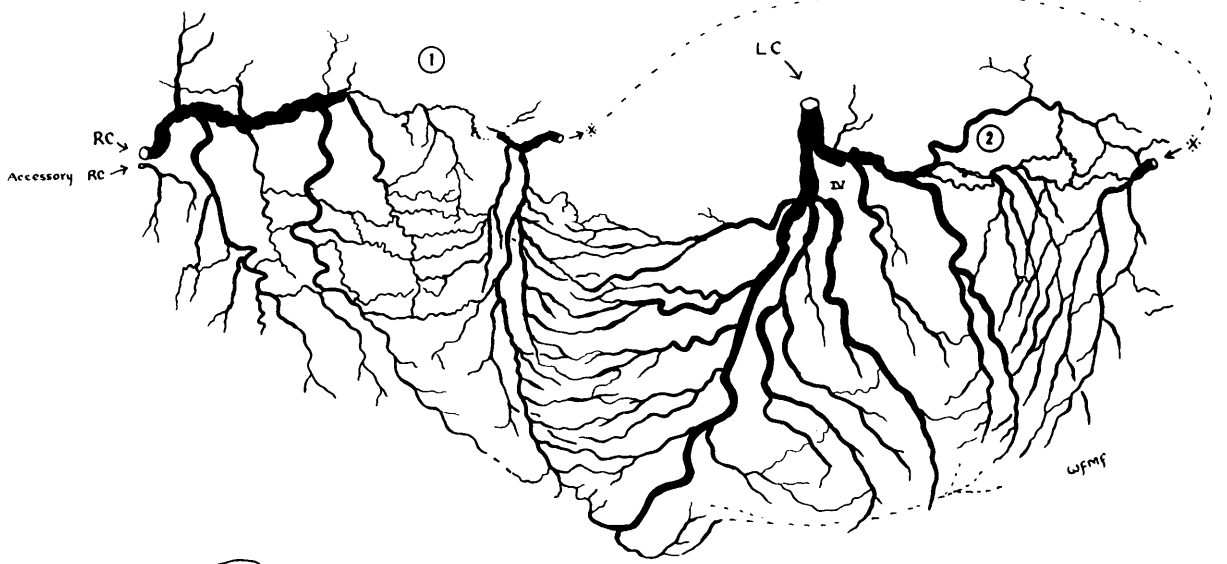


Fibrosis, 6 months  
Necrosis, 9 days  
3-4 cm from AV groove



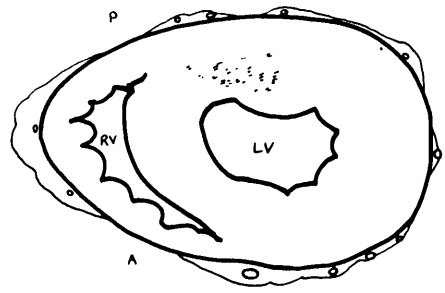
Fibrosis ?age  
3 cm from apex

Case 24.



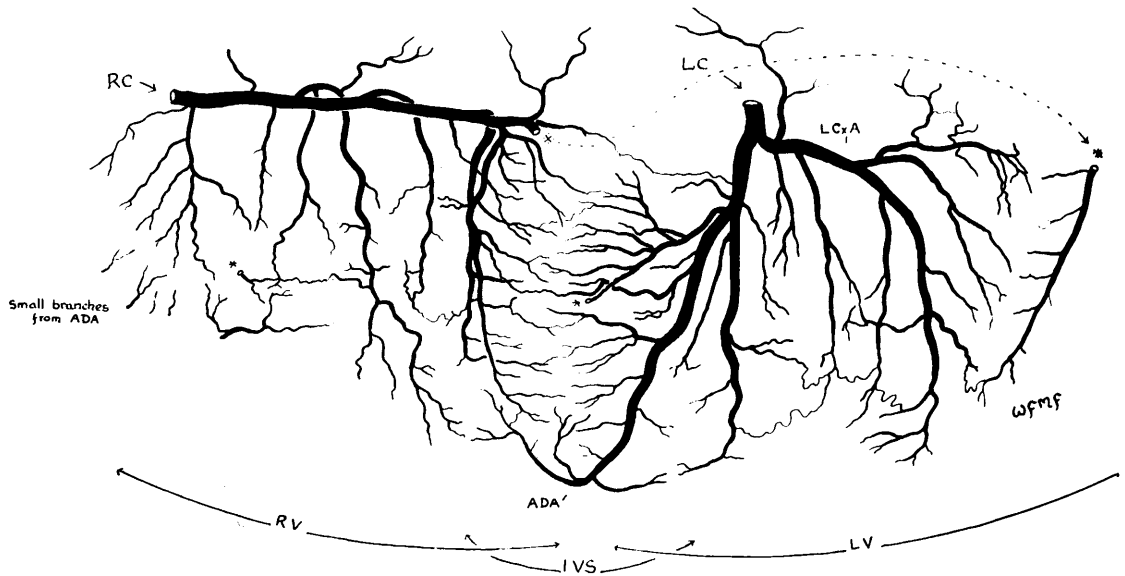
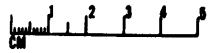
Fibrosis ? age

mid-ventricular section.



through upper 1/3 of ventricles

Case 25.



An EXAMPLE of a HEALTHY CORONARY "TREE" : Case No. N' 16.

# CASE RECORDS

## CORONARY ARTERY DISEASE GROUP

CASE 1

H.H., 33 yrs . Fisherman.

P.M.No. 216/52

This was a most unusual case. It is regrettable that demonstration of the findings is incomplete, on account of the early phase of the investigation at which it was examined.

Clinical features : At 26 years of age this man began to suffer from anginal pain on effort. The onset is not clearly recorded. It is however certain that one year later he had electrocardiographic signs of anterior myocardial damage. Thereafter progress in regard to ischaemic heart disease was one of improvement. There were no clinical incidents to suggest further myocardial infarction, and only minor changes took place in the E.C.G. pattern. There were however two episodes of haemoptysis based on pulmonary infarction. Latterly he was able to return to his work as a fisherman.

The terminal illness started with abdominal pain. 2 weeks later he was admitted to hospital in coma, with right sided hemiplegia. He died 3 days later.

Pathological findings : At autopsy there was evidence of vascular occlusions at several sites. Recent thrombus blocked the middle cerebral artery. It was thought that this occlusion was thrombotic. There was however blood clot in the left ventricle. There was complete occlusion of the portal vein from recent thrombosis - to which the abdominal symptoms were presumably attributable. There was also thrombosis of the deep calf veins.

In no instance was there gross or histological evidence of underlying vascular disease which might have been a cause of thrombosis. The systemic and pulmonary arteries were free from disease, except where occluded by thrombus. The possibility was entertained that polycythaemia may have been the basis for intravascular clotting. (Hb. 136 % Sahli, clotting time 5 mins. - detail of method not recorded - and bleeding time  $2\frac{1}{2}$  mins. , during the final illness.)

The coronary arteries presented a remarkable picture, and the arteriogram of the unopened heart is included in the illustrations. The left coronary artery, including the main stem<sup>①</sup>, anterior descending<sup>②</sup> and left circumflex arteries<sup>③</sup>, was almost completely obliterated. No injection medium whatsoever entered by the left coronary cannula. The entire circulation in life had evidently been supported by the right coronary artery. This vessel had undergone very considerable increase in calibre, presumably in response to the increase volume of blood flow it had carried over a long period of time. The right coronary artery was free from atherosclerosis. It communicated with the left coronary territory through wide-bore anastomoses, especially at the apex, in the posterior left ventricular wall and through the interventricular septum. The distribution of blood to the left ventricle had evidently been largely dependent on enlarged vessels of the subendocardial plexus.

The area of muscle damage was remarkably limited, in view of the extensive nature of the arterial occlusion. Coarse patchy fibrosis, representing old-standing myocardial infarction, was

found high in the antero-lateral wall of the left ventricle, i.e. in the region most remote from the source of collateral blood supply from the right coronary artery.

Comment : Obliteration of almost the entire length of a coronary artery was not seen elsewhere in this series. In each instance in the other cases thrombosis had taken place on a basis of atherosclerotic disease, and the occlusions were always more restricted in extent. Unfortunately at the stage at which this case was examined, I had not introduced the practice of excision of the arteries for further radiography nor the mounting of serial 2 mm. thick sections. In this way the opportunity of demonstrating most striking appearances was lost. Careful dissection showed that the anterior descending artery had been obliterated, and was represented by a fibrous structure in which numerous small vessels followed a tortuous course of great complexity. Undoubtedly these vessels were the product of canalisation of thrombotic occlusion. There was no evidence whatsoever of underlying atheroma. Micro-sections suggested that prior to thrombosis there had been no intimal thickening. An example is included in the microsections mounted between Chapters 7 and 8. Although this finding appeared to be general on dissection, in the absence of a complete series of mounted arterial sections I make the point with reservations. The findings on dissection together with the microsections from several points were in keeping with obliteration of the affected arteries at much the same time, 6-7 years before death.

If indeed the arteries were of normal lumen before obliteration by thrombosis, it is remarkable that the myocardial damage was not more extensive. If protection was provided by collateral blood supply - which seems the most likely explanation - the mystery remains, what could have been the stimulus for "preparatory" enlargement of anastomoses in anticipation of an event to come?



CASE 2

Mrs. M.R.

58 yrs Hsf.

No. 224/52

Clinical Features: The onset of anginal symptoms, as recorded, was indefinite. It was, however, at least one and perhaps two or three years before death. 10 weeks before death a tight sensation in the chest persisted for  $1\frac{1}{2}$  days. Left sided hemiparesis developed 3 weeks before death and occasioned admission to hospital 5 days later.

The blood pressure was 220/120 mm.Hg. The electrocardiographic picture was anterior myocardial infarction (old) with aneurysm formation. Anticoagulant therapy was given. Death was sudden.

Pathological findings: At autopsy extensive myocardial infarction involved the anterior left ventricular wall, including the apex. Microscopically this appeared to have taken place in two stages, which were not clearly defined. For the most part the damage was in keeping with a duration of 10 weeks. Some areas showed denser fibrous tissue which probably represented damage of longer standing, perhaps one year.

Occlusion of the anterior descending artery<sup>①</sup> corresponded to the territory of muscle damage. Occlusion had likewise taken place in at least two stages. The arterial lumen was occupied by recent thrombus which was in communication with haemorrhage in the underlying intima. The latter was largely formed of a crescent of atherosclerotic tissue which contained iron deposits, a feature which suggested that this portion of tissue had itself been formed from thrombus, (See Chapter 8); and its age could have been 1 or more years.

The coronary circulation was left preponderant. Complete occlusion of a diminutive right coronary artery<sup>②</sup>, of old standing, had not caused myocardial damage in its territory, which was restricted to the right ventricle. (This is one of the rare instances in this series in which there has been complete absence of myocardial damage in the territory of an occluded artery) Right ventricular damage had occurred anteriorly in the territory of the occluded anterior descending artery.

The immediate cause of death was cerebral haemorrhage which was so extensive that its source was not determined. There was marked atherosclerosis of the cerebral arteries and no adherent thrombus was present in the heart.

CASE 3

J.M. 45 yrs. Commercial traveller. P.M. No.241/52

This man was apparently fit until the development of sternal pain 10 weeks before death. Pain was provoked by slight exertion and occurred sometimes at rest. Duration of attacks 5-30 minutes. 3 weeks after a particularly severe attack he was confined to bed. 3 weeks later he was admitted to hospital where he continued to have attacks of pain at rest, lasting 10 - 30 minutes, until he died suddenly during an attack of pain, some 4 weeks later. He received anticoagulant therapy while in hospital, until 6 days before death. The electrocardiograms showed healing anterior myocardial infarction. B.P. 130/85 mm.Hg.

Pathological findings : The heart was of normal size. The coronary arteries showed moderate atheroma in the three main stems, but only at one point was there important encroachment on the lumen. This was 3 cm. from the left coronary ostium in the anterior descending artery<sup>①</sup>. For a distance of about 1 cm. the artery was the seat of severe atherosclerotic disease, into which there was evidence of recent haemorrhage. The characters of this portion of atherosclerotic intimal tissue suggested its formation from thrombus. It contained deposits of iron.

At this point the lumen was nearly occluded by thrombus. It is likely that occlusion had been complete in the beginning and that separation of the clot from the arterial wall had allowed a narrow track to form along side it. A micro-section through this lesion is included in the illustrations placed between chapters 7 and 8.

Myocardial infarction involved the inner 2/3 of the anterior left ventricular wall in a patchy fashion and occupied not more than 1/3 of the territory of the anterior descending artery distal to the occlusion. It was noticed that the distal part of this artery filled in retrograde direction from below, through anastomoses mainly in the interventricular septum. Microscopically the appearances of the infarct were in keeping with an age of about 2 months, and it is possible that more than one recent episode was represented. There was also scanty focal fibrosis in the same area.

It is uncertain whether the occlusion and the infarct occurred at the onset of symptoms or three weeks later. The thrombus showed two layers which may have represented two episodes, separated in time by a few weeks. Had the method of serial sectioning introduced later in the investigation been used in this case, this point could have been analysed with more assurance.

This case is a good example of a fatal coronary occlusion which involved a very short stretch of artery, in a coronary tree which was elsewhere unobstructed, although here and there atherosclerotic disease of moderate severity was present.

CASE 4.

S.R. M. 69 yrs. Pithead worker. P.M. No. 274/52.

Clinical features : 7 years before death there was a profound illness as the result of extensive posterior myocardial infarction for which he was admitted to hospital. Before this event there had been sternal tightness on exertion for about one month. Myocardial infarction was accompanied by circulatory collapse, complete heart block and congestive cardiac failure. A-V conduction was restored in 2 weeks and congestive cardiac failure responded to digitalis and mersalyl over a period of about 2 months.

His recovery from congestive cardiac failure was considered "astonishing". Perhaps still more so was his return to work as a watchman and his survival for 7 years. Moreover death was not directly attributable to myocardial causes. He was admitted to hospital with acute urinary retention due to prostatic enlargement and died 3 days after cystostomy, as the result of aortic embolism.

During the intervening 7 years he had been under clinical and electrocardiographic observation at intervals. Minor changes in the electrocardiograms occurred during the first 3 years. Right bundle branch block persisted. No records were taken thereafter until admission to hospital in the terminal illness when signs of anterior myocardial infarction were found in addition to the signs of old posterior myocardial infarction. He had been subject to anginal pain on effort in attacks lasting from a few minutes to as long as 1 hour. The blood pressure was 180/120 mm.Hg.

Pathological findings : The heart was enlarged (450 gm.). The pericardium was densely adherent to the heart at all points and, although not thickened, appeared to have afforded a measure of support to the greatly thinned posterior ventricular wall. Myocardial damage was very extensive. The posterior wall of the right and left ventricles was represented by a thin layer of fibrous tissue in which only a few islands of muscle tissue had survived. The posterior damage lay mainly in the territory of the right coronary artery, and to a lesser extent in that of the left circumflex artery. Patchy fibrosis representing old-standing myocardial infarction spread through the interventricular septum onto the anterior wall of the left ventricle, in this way involving also the territory of the anterior descending artery. There was no evidence of recent myocardial infarction. Old-standing thrombus was attached to the posterior wall of the left ventricle. Detachment of thrombus from this mass presumably formed the source of embolism of the aorta.

The coronary arteries were the seat of very advanced obliterative disease of all main stems. The arteriograms of the whole heart presented a remarkable picture, and is illustrated.

Right coronary artery was completely occluded 3.5 cm. from its orifice<sup>①</sup> and was canalised in a complex fashion in its distal portion. <sup>②</sup>

Left Circumflex artery had been occluded and canalised 2 cm. from its origin. (3)

Anterior descending artery (4) was occluded and recanalised by a narrow track, at a point just after a large branch had been given off. It seemed that survival had depended to a large measure on this branch which linked up with the distal branches of the other arteries through greatly enlarged anastomoses. It is possible that occlusion of the anterior descending artery at this point occurred several years after occlusion of right coronary and left circumflex arteries. On the other hand there was almost complete occlusion of the main septal branch (5) higher up the artery, which had presumably been responsible for the development of complete heart block in the original illness.

A tremendous degree of enlargement of superficial anastomoses was a feature of this heart. These were found particularly at the apex, in the A-V groove and also in the interatrial septum. Indeed many of these vessels were larger than the remaining lumen of the main vessels which supplied them.

The pericardium was adherent to the heart surface in a manner such as might follow a Beck operation. The connecting tissue was highly vascular and traces of injection medium had penetrated into some of the vessels which composed it. In view of the nearly capillary dimensions of the communications so revealed, it is doubtful if any useful additional blood supply to the myocardium could have entered by this route.

CASE 5

A.S. M. 59 yrs. Dispatch clerk. P.M. No. 300/52

Clinical features : This man was admitted to hospital with intense sternal pain of a few hours duration. He died suddenly the following day. Electrocardiograms showed acute anterior myocardial infarction. B.P. 104/60 mm.Hg.

12 months earlier he had an attack of enduring sternal pain of similar severity, but had not sought medical advice and went to his work the next day. Thereafter he continued to suffer from sternal pain on effort. There were no previous ischaemic symptoms. He was said to have had a "heart attack" some 22 years earlier, in which there was no pain.

Pathological findings : The heart was enlarged (470 gm.) There were two clearly defined areas of myocardial damage.

(1) An anterior myocardial infarct occupied most of the territory of the anterior descending artery distal to an occlusion 5 mm. from its origin.<sup>①</sup> The main septal artery arose below the level of occlusion and interference with upper septal blood supply may have contributed to bundle branch block. The infarct was recent, the appearances being consistent with a duration of 1-2 days. It involved nearly the full thickness of the anterior left ventricular wall, the apex and the anterior 2/3 of the interventricular septum. There was also a small area of fibrosis which could have been related to one of the points of narrowing of the anterior descending artery.

The acute occlusion was a compound of fresh thrombus in the lumen and massive haemorrhage into the intima. The haematoma so formed had caused some encroachment on the lumen. Injection medium had entered the haematoma.

Injection medium had also burst beyond the walls of some vessels in the depths of the necrotic muscle to form pools. (This artifact appearance was found elsewhere only on a much smaller scale, in one or two other instances where it was also related to acute necrosis. )

(2) An old-standing and much smaller infarct lay in the post. left ventricular wall and posterior part of the interventricular septum. The damaged area lay in the terminal territory of the left circumflex artery. This artery was the seat of old-standing thrombotic occlusion with a bizarre formation of channels, resulting from canalisation.<sup>②</sup> (See arteriograms and microsections in the illustrations between chapters 7 and 8)

The right coronary artery was small and was narrowed at one point to 1 mm. in diameter.<sup>③</sup> It is doubtful if this obstruction had functional importance, in view of the small size of the artery and the restriction of its territory to the right ventricle.

Anastomoses of small calibre had linked the right coronary artery with the terminal branches of the posterior and anterior descending arteries, both of which arose from the left coronary artery. Anastomoses between these two vessels were unable to influence the severity of infarction when both were occluded.

CASE 6

Miss A.McD. 67 yrs. Civil Servant. P.M. No. 315/52.

A striking feature of this case was the slight degree of myocardial damage despite severe ischemic symptoms over a long period of time, on a basis of advanced obliterative coronary artery disease.

Clinical features. This woman of middle height and moderate obesity had suffered from progressively more frequent and severe effort angina for a period of 13½ years. Although at times there were temporary episodes of increased severity, the general course was unremitting. Detail of the onset was not noted. It would seem definite however that the only severe attack of more than a few minutes duration occurred 4 years after the onset. On this occasion pain lasted half an hour. Despite numerous severe attacks, there was no instance in which myocardial infarction could be diagnosed with certainty.

Five years before death, cervical sympathectomy was performed with temporary reduction in the severity of the pain but no alleviation of the disability. There was an episode of "collapse" in the post-operative period. During the last few years, blood pressure records were within normal limits.

Electrocardiograms taken over the last few years are said to have shown no evidence of myocardial infarction. A series taken 6 months before death showed a pattern of left ventricular hypertrophy but no evidence of myocardial damage.

During the last year of her life angina was again increasing in severity and frequency, occurring regularly about fourteen times a day.

Death itself was due to mediastinitis which followed operation for carcinoma of the thyroid and was not primarily due to ischemic heart disease.

Pathological findings: The heart was enlarged from left ventricular hypertrophy and gross increase in the epicardial fat. (Heart weight 530 gm.) The only myocardial damage obvious on inspection was patchy fibrosis in the entire inner zone of the left ventricle. Fibrosis was of greater density in the posterior wall of the left ventricle in the territory of the right coronary artery, and was also discernible in the adjacent right ventricular wall. On microscopical examination a few small areas of recent focal damage were found as shown in the diagrams.

The coronary arteries showed severe chronic obliterative atherosclerotic disease of all main branches. Further, the right coronary ostium was only 1 mm. in diameter. The left was 2 mm. in diam. The distribution of the obstructive lesions is indicated in the diagram of the arterial tree. Arteriograms of the whole heart and mid-ventricular section appear in chapter 6,

A small, loose portion of thrombus was found in the anterior descending artery above the occlusion. It may have been merely agonal and in any case could have exerted no effect on blood flow.

No other acute change whatsoever was found in the coronary arteries.

The right coronary artery was narrowed at its origin<sup>(1)</sup> and again 2 cm. further down.<sup>(2)</sup> The abrupt narrowing of the second obstruction suggested canalisation of thrombotic occlusion, which may at one time have been complete, or nearly so, in view of the emphasis of myocardial damage in its terminal territory.

Obstruction of the anterior descending artery<sup>(3)</sup> was still complete at death, although its distal portion showed canalisation.<sup>(4)</sup> This lesion involved an important septal branch and a moderately large mural branch.

The left circumflex artery showed thrombotic occlusion of long standing, with typical appearances of canalisation by several channels.<sup>(4)</sup>

Anastomotic development in this case was remarkable. In the arteriogram of the intact heart it can be seen that the central area of the left ventricle is occupied by a multitude of dilated channels. In cross-sections through the heart these can be seen to occupy the inner  $1/3$  or so of the left ventricle and to belong to the subendocardial plexus. The widely dilated, intercommunicating channels formed a network, linking all parts of the inner zone of the left ventricle. The main supply of blood to this network must have entered by one of three routes: (1) the first main branch of the anterior descending artery, to the left ventricular wall. (2) The first septal branch of the same artery. (3) The large tortuous right marginal artery, from the right coronary artery.

It would seem that the network derived from the subendocardial arterial plexus was able to provide channels through which a severely restricted total blood supply to the heart was equitably distributed.

This case is one of a series of four which show essentially similar features and which are made the subject of special description and discussion in chapter 6. (see also 8, 17 and 18).

Ø Ammendment to Fulton, 1956, Brit. Heart J., 28, 341. : Complete occlusion in this case has been omitted from table 2.

CASE 7

R.A. 59 yrs M. Publi can.

P.M. No. 384/52

Clinical features : The first definite episode of anginal pain occurred 7-8 months before death. Enduring central chest pain woke him from sleep and persisted all day ,until relieved by an injection. After 5 weeks rest in bed he was able to continue his work, but was more breathless than formerly. Electrocardiograms taken at this time showed posterior myocardial infarction at the healing stage.

12 days before death moderately severe sternal pain developed while playing bowls. It disappears on resting but pain returned two days later with great severity and accompanied by sweating and nausea. Electrocardiograms taken on admission 4 days before death showed recent "through and through" antero-septal myocardial infarction. Death was preceded by advancing cardiac failure with terminal severe angina. B.P. 120/88 mm.Hg.

Before the onset of angina there had been some shortness of breath for about 2 years and he had been gaining weight. Apart from a "smoker's cough" he had been well otherwise.

Pathological findings: The heart was considerably enlarged in respect of all chambers. The mitral orifice admitted 5 fingers, apparently as the result of stretching of the valve ring following extensive posterior myocardial infarction. It is probable that there was some incompetence of this valve which may have contributed to cardiac enlargement. The valve leaflets themselves were normal.

There were two clearly demarcated infarcts of the heart:-  
(1). Old-standing infarction involved the posterior walls of the left and right ventricles. It corresponded in extent closely to the anatomical distribution of the right coronary artery.

This artery was completely blocked by old-standing thrombus for about 3 cm. The appearances were in keeping with a duration of several months. 2 cm. distally the artery was narrowed irregularly to 1 mm. in diam., thought to be due to canalisation of thrombotic occlusion. At one point this interpretation was placed beyond doubt by the multiple channels which had been formed. (see photomicrograph between chapters 7 and 8 )

(The posterior infarct appeared to have taken place in two stages, but because of its age and structure this was not certain. There was massive, established fibrotic replacement of muscle in both ventricles with considerable stretching of the left ventricle. Interspersed in the old fibrosis were patchy areas in which the fibrous tissue was less dense and more cellular. Again, the right coronary artery may have been occluded in 2 stages, in time. Discrepancy in the apparent ages of the two arterial occlusions could however be due simply to the continued completeness of occlusion in the proximal portion and the early development of canalisation in the distal portion. Like wise two apparent stages in regard to time in the area of infarction may be related merely to the greater or lesser bulk of the patches of necrosis, and all be about 7 months in duration).



(2). The anterior infarct involved the greater part of the anatomical territory of the anterior descending artery below the point of obstruction. In places it reached nearly through the entire thickness of the wall. The damage was consistent with a duration of 10 days and there was no definite indication that it had taken place in more than one stage. There were however a few areas in which concentration of polymorph leukocytes might have been in keeping with further fresh damage in the terminal phase. There was no clear evidence of ischaemic fibrosis, although there was some increase in the perivascular fibrous tissue.

The occlusion of the anterior descending artery<sup>3</sup> is an interesting one. Previously there had been narrowing of the lumen to approximately 1 mm. in diameter, for a distance of 2-3 mm., forming a sort of hour-glass stricture. The thickened intima at this point was composed of yellow-brown atherosclerotic tissue which contained considerable iron deposit. Most probably it had been derived from thrombus. In view of the lack of muscle damage of corresponding age in its territory, it is likely that obstruction was never complete.

In the recent episode thrombus had formed just proximal to the hour-glass stricture of the lumen, at a point where blood - later followed by injection medium - had ruptured into the intima. The time relationship of this intimal lesion to thrombosis is of course not determinable. It would however be in keeping with the clinical sequence of events if the building up of thrombus had paused for a couple of days before causing final, complete occlusion at the narrow "waist". A more speculative possibility is that haemorrhage into the wall had caused temporary obstruction, perhaps through spasm, and that thrombus had developed at the point of damage two days later.

The thrombus itself was of mixed red and fibrin composition. Channels were seen to separate thrombus from underlying intima. This may be seen in the photograph of the thick cross section mounted after page 8:18, and represents an early stage in vessels formation. In the corresponding micro-sections mounted between chapters 7 and 8, no evidence of endothelial lining to these channels can be discerned at this stage.

Anastomoses between the anterior descending artery and the occluded right coronary artery were well developed, in the atrio-ventricular groove enlarged vessels linked the left circumflex artery with the right coronary artery. Those connecting with the right coronary artery (which was blocked) could of course provide no succour to the territory of the anterior descending artery when that artery in turn was occluded. The resultant infarct was extensive.

Stereo-arteriograms of the occluded areas of Right coronary and anterior descending arteries are included (between Ch. 7, 8). Also microsections of Right coronary artery. Before sectioning a dissection of this artery was made and photographed; and is mounted in conjunction with the arteriogram.

CASE 8

J.E. 65 yrs M. Excess luggage clerk. F.M. No. 393/52

Clinical features : This man suffered from effort angina for 12½ years without intermission. The general picture was one of relentless progress in the severity of symptoms, which were provoked by moderate or slight exertion and lasted 2 - 3 minutes as a rule. During the last 3 years pain had occurred also at rest. In the last 6 months attacks were occurring about 14-19 times per day.

Although ischaemic symptoms were progressive over many years, it is of interest - in correlation with the pathological findings - that the onset of symptoms was marked by severe sternal pain which lasted 1 hour and was accompanied by sweating and vomiting. His doctor kept him in bed for 6 weeks. There was a further episode of severe, enduring pain 5 years before death. It is likely that coronary artery occlusion with some myocardial damage occurred in these 2 attacks.

Electrocardiograms were taken on several occasions in the last 8 months and were essentially within normal limits at rest. In retrospect slight signs of posterior myocardial ischaemia can be traced.

He was admitted to hospital in status anginosus. Electrocardiograms taken during a bout of pain showed the pattern of "acute coronary insufficiency". Despite the continuance of ischaemic pain over the next few days, electrocardiograms showed some improvement and the definite emergence of antero-septal ischaemic changes, which had been doubtful on previous tracings.

6 days after admission circulatory collapse developed suddenly and he died 2 days later.

He had also suffered from rheumatoid arthritis 20 years previously. The blood pressure was 200/100 mm.Hg. in recent years.

Pathological findings : The heart was not enlarged and showed no outwards signs of damage. Indeed, on section of the ventricles there was no gross evidence of recent myocardial change - in spite of the electrocardiographic signs. There was however scanty fibrosis in the inner zone of the left ventricle. This was somewhat denser in the posterior wall and in the antero-septal area. It is possible that these two areas of more localised damage may have been related to clinical episodes, at the onset of symptoms and 7 years later.

There were also a few areas of very recent necrosis, mainly in the antero-septal region which may have occurred in the last one or two days.

The coronary arteries showed extensive atherosclerotic disease. (Indeed calcification of the left coronary artery was detected on the radiograph of the chest. Stereo-radiographs of the uninjected excised heart are included in the illustrations\*.

The right coronary ostium was severely stenosed (1 mm. in diameter) from involvement in aortic atherosclerosis. The left circumflex and anterior descending arteries arose separately from the aorta ; the ostia each measured 2mm. in diam.

No acute changes were found in any artery. At one time, however, there had evidently been thrombotic occlusion of the left circumflex artery and a major branch of the same artery. There was also complete occlusion of a smaller branch (3rd. Division)\* of the anterior descending artery and severe narrowing of 3 other major branches (2nd Division)\*, probably the result of thrombosis at one time. Moderate narrowing of the anterior descending artery itself to 1.5 mm. in diam., immediately above the origin of the main-septal artery and similar narrowing of the posterior inter-ventricular artery were also probably thrombotic in origin, though now converted into atherosclerotic thickening of the artery wall. Severe narrowing of 5 other branches of lesser importance were also demonstrated.

All the changes noted above were of old-standing. Canalisation had re-opened all but one of the major branch occlusions.

Anastomoses between branches of the coronary arteries were extensively enlarged, especially in the interventricular septum and the subendocardial plexus of the left ventricle. In this way all arterial territories in this ventricle were linked by a common network of intercommunicating vessels. This feature probably reduced the severity of ischaemic damage which might otherwise have resulted from individual occlusions ; and by equitable distribution of available blood supply conditioned the manner in which changes were generalised in distribution in the deep zone of the left ventricle.

An unusual feature is the size of a communication which crossed the interatrial septum, from a branch of the right coronary artery .

(This case is one of a group of four selected for discussion in chapter 6. Arteriograms are to be found in chapters 4 and 6)

\* See definitions in Chapter 5.

CASE 9

J.D. M. 59 yrs. Printer's storeman. P.M. No. 443/52

A case of extensive posterior myocardial infarction with massive involvement of the right ventricle.

Clinical features : For about 3 months before death, this man had suffered from lower sternal pain provoked by exertion and lasting for a few minutes at a time. There is no detailed record of the onset of symptoms of this nature. He had however been subject to gastric and duodenal ulceration for many years and it is possible that acute ischaemic episodes may have been masked by the pain of ulcer dyspepsia.

Admission to hospital took place a few hours after the onset of intense epigastric pain, accompanied by sweating, nausea and breathlessness. (4 days previously there had been a similar attack which lasted 2 hours during the night but he went to his work the following day.) Circulatory collapse followed laparotomy, at which no acute abdominal findings were made, and led to the diagnosis of myocardial infarction. Electrocardiograms showed extensive recent posterior myocardial infarction. Death occurred 1 week later from rupture of the left ventricle.

Pathological findings : The heart weighed 410 gm. The coronary circulation showed marked right coronary preponderance, which partly explained the great extent of the posterior myocardial infarct. This lesion occupied the entire left ventricular territory of the right coronary artery and about half the right ventricle. It had resulted from occlusion of the right coronary artery about 1 cm. from its ostium. Rupture had taken place close to the interventricular septum, at which point the entire thickness of the wall was affected.

Near the borders of the infarct the damage was patchy. On that account it was difficult to determine the number of episodes of muscle damage of different age that might be present. The recent massive muscle necrosis was more consistent with 12 days than with 7. It is also possible that there was further massive necrosis in the central area about the time of operation, for the damage in this region was confluent.

There were also a few patches in the same distribution in which the density of collagen deposition and the characters of the cell types present suggest an age of 1-3 months. In addition a small area of fibrosis almost certainly of greater age was found in the subendocardial zone of the left ventricle near the septum.

The occlusion of the right coronary artery<sup>Q</sup> was due to recent thrombosis and was clearly causally related to the massive, acute myocardial infarct. Before final occlusion, there had been narrowing of this artery to 1 x 2 mm., as the result of thrombus which had undergone change and had been incorporated into the vessels wall. (A photomicrograph of this lesion appears in chapter 8, opp. p. 8:13)

## CASE 9(continued)

Whether this previous thrombotic obstruction had been more severe or even complete at an earlier date is not determinable. It corresponded in age - in so far as this can be assessed - to the patchy areas of posterior myocardial infarction, and may have been 2 or 3 months old. Indeed it is likely that the onset of ischaemic symptoms was heralded by this arterial obstruction.

There was also narrowing of almost the same degree in the early part of the right coronary artery which was of older standing and correspondingly less certain origin. Had it also been thrombotic, it too might at its inception have been the cause of focal fibrosis in its territory.

Atherosclerotic disease also involved the anterior descending artery which was severely affected in the portion where the main septal artery and two other large branches were given off. Narrowing was just over 1 mm. in diameter in the main stem and less than 0.5 mm. in the septal artery at its origin. It was not satisfactorily determined whether or not these lesions had resulted from thrombosis. The only myocardial damage in the territory of these arteries was deep seated, patchy fibrosis in the anterior extremity of the interventricular septum.

Anastomoses of considerable dimensions linked the left coronary circumflex artery (which was free from obstruction) to the right coronary artery through the atrial circulation in the neighbourhood of the atrio-ventricular groove; and also indirectly through the sub-endocardial plexus. Anastomoses also connected the anterior descending artery via septal arteries with the posterior interventricular branch of the right coronary artery. As all septal arteries took their origin below the level of chronic narrowing of the main stem, it is speculative whether blood flow was from left to right or in the other direction prior to final occlusion of the right coronary artery. What is evident however is that withdrawal of blood supply from the right coronary artery revealed an insufficient degree of collateral circulation to prevent nearly total regional muscle damage.

The anterior wall of the right ventricle was free from damage. It was supplied by an accessory right coronary artery and from branches of the anterior descending artery.

Propagation of loose thrombus extended for 5 cm. in the right coronary artery distal to the occlusion. It is doubtful that it caused any additional obstruction to blood flow.

CASE 10

Mrs. M.C. F. 75 yrs. Para 6. Housewife. P.M.No 580/52

Clinical features : It would appear that there had been breathlessness on exertion for some 8 years. It is known that she exerted herself little during the last 2 years, at any rate. No other cause for breathlessness was found than ischaemic heart disease.

The onset of anginal symptoms is not clearly noted. There was however mild "tightness" in the chest on exertion with discomfort in the left arm, during the last 6 months.

She was admitted to hospital following a severe attack of chest pain and she died 2 days later. During the preceding 3 weeks there had been increasing tiredness, thirst and dyspnoea. On admission she was discovered to be in a state of diabetic ketosis. Blood sugar 470 mg % and B.P. 106/66 mm.Hg. With rehydration, congestive cardiac failure became manifest. Pain recurred while in hospital. Electrocardiograms showed a pattern of acute coronary insufficiency, with extensive sub-endocardial ischaemia. Q waves in V1 and 2 were the only signs of antero-septal infarction.

Pathological findings: It would have been possible to correlate the pathological features with ischaemic episodes 2 days, 6 months and several years before death.

Both the coronary ostia were narrowed (1.5 mm.) and there was widespread severe chronic disease of all main branches of the coronary arteries.

There was complete obstruction to the right coronary artery ① and to the main branch of the left circumflex artery ②. In each instance occlusion was from old-standing thrombosis, which by death had been converted into greyish, translucent, atherosclerotic tissue. Incomplete canalisation was also revealed.

The anterior descending artery ③ was severely narrowed. On section it appeared that encroachment on the lumen had resulted from a crescentic cushion of tissue which had reduced the channel from 2 mm. to less than 1 mm. in diameter. The characters of this crescent of tissue suggested that it was the product of conversion of thrombus into atherosclerotic tissue and were in keeping with a duration of about 6 months. (see Chapter 8).

Intimal haemorrhages of small size were found in relation to these old-standing occlusions. None had evidently caused encroachment on the lumen and there was no related fresh thrombus.

Myocardial damage was in at least 3 stages: (1) Extensive necrosis of 2-3 days duration involved the antero-septal region. Patches of similar damage extended anteriorly to the obtuse border, and involved the territory of the main branch of the left circumflex artery. The main bulk of this infarct lay in the territory of the anterior descending artery, and had occurred without any recent change in the lumen of either artery. The anterior wall of the right ventricle was also affected

(2). Patchy areas of healing infarction in the territories of all 3 arteries. The microscopical characters were in keeping with a duration of several months, possibly six.

(3). Old-standing massive fibrotic replacement of infarcted muscle in all 3 territories, affecting the territory of the left circumflex artery (main branch) with greatest severity.

All episodes of muscle damage involved the inner 3/5 of the left ventricle and at no point reached the epicardial surface. The distribution of damage resembled that found in the four cases described under the title of chronic generalised myocardial ischaemia, (cases 6, 8, 17, 19, Chapter 6). It differed in the occurrence of more clearly regional distribution of separate episodes of damage as well as in their severity. The difference was probably related to the more rapid evolution of changes in this case, and to the less equitable distribution of obliterative changes in the coronary arteries.

As is often the case in histories taken from severely ill persons, there are points about which more precise information would have been desirable. Nevertheless the following retrospective interpretation of the sequence of events may be put forward :-

Right coronary artery occlusion was probably the first to occur, and the associated damage in its territory was slight. Later, occlusion of the large branch of the left circumflex artery (in the presence of disease of the anterior descending artery and occlusion of the right coronary artery) was followed by extensive damage in its own territory, and probably also in the two neighbouring territories.

These events may have occurred many years before death. They had provoked considerable enlargement of anastomoses, particularly in the subendocardial plexus of the left ventricle. The blood supply to the heart came to be carried, therefore, mainly by the narrowed anterior descending artery, and by anastomotic communications between it and the branches of the right and left circumflex arteries; by anastomoses which by-passed the right coronary obstruction; and by a terminal branch of the diminutive left circumflex artery.

Within recent date (? 6 months) occlusion took place in the anterior descending artery. This caused widespread, patchy, deep-seated myocardial damage throughout the inner zone of the left ventricle. The posterior wall, which lay in the territory of the left circumflex artery, was the least severely affected. The anterior descending artery occlusion was thrombotic in origin and may well have been more complete initially than was found later, shrinkage of the clot having increased the lumen to a degree sufficient for the normal needs of the myocardium.

With the development of diabetic ketosis, conditions became acutely abnormal: metabolic changes, fall in blood pressure, increased blood viscosity (Hb 125%), and tachycardia (120/min). These factors precipitated a profound attack of acute coronary insufficiency on a background of advanced obliterative coronary artery disease - without recent change in the lumen of the coronary arteries.

CASE 11

H.L. M. 80 yrs. Indian Forestry Service (rtd). P.M.No.586/52

This is a complex case in which there is none the less general agreement between the severity of coronary artery disease, myocardial damage and, to a lesser extent, clinical findings.

Clinical features : Anginal symptoms were experienced for the first time while walking, 8 months before death. It is likely that coronary artery occlusion and myocardial infarction had occurred about this time. Sternal pain continued to be provoked by exertion, and might persist for as long as 2 hours, if he went on walking. (!) After 5 months he was admitted to hospital with widespread severe chest pain and haemoptysis. Haemoptysis was due to pulmonary infarction. Electrocardiograms at this time showed anterior myocardial infarction in the healing stage. The blood pressure was 170/100 mm.Hg.

2 months later he was readmitted to hospital with severe pain, breathlessness of 2 days duration, haemoptysis and cardiac failure. The electrocardiographic signs were now those of acute anterior myocardial infarction. He died 3 weeks later in cardiac failure without further acute ischaemic episodes.

Anticoagulant therapy was administered during the hospital admissions.

Pathological findings : The heart was enlarged, mainly in respect of the left ventricle, weight 570 gm..

There was recent coagulative necrosis of the antero-septal region of the left ventricle in the distribution of the anterior descending artery, main stem. It was consistent with 3 weeks.

More widespread healed patchy infarction extended from the posterior part of the interventricular septum to the anterior wall of the left ventricle and round to the obtuse border. The damage lay for the most part in the inner and middle thirds of the left ventricle and also involved the right ventricle, anteriorly and posteriorly. Its age could not be placed with certainty and more than one episode may have been represented. For the most part the histological appearances were in keeping with approximately 6 months.

In the same lobe as there were small patches of fibrosis, whose greater density and lack of cellularity suggested an age greater than 6 months.

There was also old-standing thrombus in the left ventricle and right atrium, undergoing incorporation into the walls of these chambers.

In the left ventricle, only the posterior quadrant seemed to have escaped damage.



The coronary arteries were extensively diseased. The coronary circulation was mainly supplied by the left coronary artery, and at death all main stems had been occluded, apart from one large branch of the left circumflex artery. The oblique course of this vessel brought the posterior wall of the left ventricle into its anatomical territory. Moreover this artery was connected, through anastomotic communications of considerable size, directly or indirectly to branches of all other coronary arteries. There seems little doubt that in this way the extent of myocardial damage was limited and life prolonged.

Detail of the nature and distribution of occlusions is shown on the semi-diagrammatic drawing. The following is a summary of the situation.

- ① Right coronary artery : Old-standing complete occlusion, canalised by many channels. These were secondarily occluded by recent thrombus. \*

Anterior descending artery:

- ② Main stem : thrombotic narrowing of old-standing, 1 mm. in diameter. Recent thrombotic occlusion in two stages. ( this lesion is illustrated between Chaps. 7-8. )
- ③ Large branch (second division). Complete occlusion by old-standing thrombus, partially canalised. The appearances could be in keeping with 6 months, or more. \*

Left circumflex artery :

- ④ Main stem : Old thrombotic narrowing to 1 x 1.5 mm. Recent complete occlusion by thrombosis, in two stages. \*
- ⑤ Terminal portion: Old-standing thrombotic narrowing, possibly occlusion with canalisation.
- ⑥ Large branch (second division) Old-standing, canalised thrombotic occlusion . Recent thrombus formation, but patent at death.

There were also 6 occlusions of smaller arteries which were involved in the intimal disease of the parent stems. (3rd division arteries)

Comments: The part played by each episode of occlusion is speculative. The tissue forming the old-standing obstructive lesions contained altered blood and iron deposit. It is likely that these occlusions were thrombotic in origin. Whether they were at one time complete can only be inferred, and their ages remain in doubt.

It is however clear that the extensive patchy infarction of 6-8 months duration lay in the territories served anatomically by the right coronary artery, by the anterior descending artery and its main branch, and by the terminal part of the left circumflex artery (which supplied the posterior part of the interventricular septum). (A patchy area of old damage appeared to lie in the territory of the occluded branch of the left circumflex artery). It may have been that the occlusions in some or all of these vessels occurred about the time of onset of clinical symptoms. It would seem almost certain that at least the severe narrowing of the anterior descending artery took place at this time.

In the terminal phase, thrombotic occlusion of the already narrowed anterior descending artery (main stem) was the obvious cause of the recent antero-septal infarction.

Whether fresh thrombosis of the right and left circumflex coronary arteries occurred at the same time is not clear. No acute myocardial damage, which would serve as a guide to their ages, was found in the territories distal to these occlusions. This may simply reflect the adequacy of collateral supply. Gross and histological features suggested little difference in age between the thromboses of the anterior descending and left circumflex arteries. Thrombus in the right coronary artery may have been more recent.

The occurrence of thrombus occluding 2 arteries at much the same time raises the possibility of embolism. In this case there was abundant source of detachable thrombus in the left ventricle. Detail of the lesions in each instance however suggested a sequence of thrombus formation close to the eventual site of occlusion, with build-up and propagation.

Propagation of recent blood clot seemed to have completed the closure started at a lower level, in the anterior descending artery. In the left circumflex artery it may have been that thrombus formation about 1 cm. proximal to the old narrowing led to close-range - indeed point-blank - embolic plugging of the narrowed stretch. In both instances there was haemorrhage in the underlying intima and cellular infiltration.

Thrombosis was a prominent feature of this case. In addition to those already mentioned in the coronary arteries there was thrombus in the left ventricle and right atrium (the latter being the only discovered source of pulmonary embolism) and the abdominal aorta was almost completely occluded in its lower part by a large thrombotic mass of old-standing.

\* \* Photographs of arterial sections appear in the group between chapters 7 and 8. Also stereoartereogram of ADA and LCxA. Stereo-photographs of thick sections appear in chapter 7.

CASE 12

C.M. M. 55 yrs. Salesman.

P.M. No. 630/52

A usual story with several unusual pathological features.

Clinical features : 19 months before death anginal pain was experienced for the first time, and occurred while walking up a hill. Pain returned 3 hours later and lasted 1 hour. On admission to hospital 11 days later there was electro-cardiographic evidence of recent posterior myocardial infarction and also antero septal damage of less certain age.

During the next 18 months the electrocardiographic evidence of posterior damage receded and the record became one of old, healed antero-septal infarction. During this period he had been making progressive improvement and suffered from effort angina only on rare occasions. He was receiving long-term anti-coagulant therapy.

He collapsed suddenly at the end of his day's work and was brought immediately to hospital, which was nearby; and died before admission.

Pathological findings : The myocardium showed widespread old-standing ischaemic damage involving the anterior and posterior walls of the left ventricle and the interventricular septum. There was also very much less extensive damage of the right ventricle. These areas lay in the territories of the anterior descending and right coronary arteries.

There was no damage of old-standing in the territory of the left circumflex artery, which had apparently been comparatively healthy until the terminal episode. Indeed very considerable enlargement of anastomoses had taken place, connecting this artery to its neighbours. It is probable that a great part of the blood flow to the left ventricle was supported by the left circumflex artery and collateral channels. Enlargement of the subendocardial anastomotic plexus was well marked.

The anterior descending artery (1) and the right coronary artery (2) were both completely occluded. Both lesions were old-standing and were similar in character and of approximately the same age. The myocardial damage was likewise similar in character in the territories of these arteries.

It was not possible to determine with certainty the time sequence of these changes but it is tempting to suppose that both arteries were occluded near the time of onset of symptoms, 19 months before death. Doubtless, as with twins, one would be the elder. Two unrelated arterial occlusions occurring at the same time must be unusual, and no explanation in this instance is readily found.

Both occlusions showed incomplete canalisation by infiltrating arterial processes, at either end. The tissue in which the new vessels lay was greyish and translucent, merging into the underlying atherosclerotic thickening of the vessel walls. The

central (i.e. deeply placed ) stretches of the occlusions by contrast were of a brownish or orange colour, due undoubtedly to altered blood pigment, and they contained abundant crystalline cholesterol.

The ghost of a former intimal lining of the former lumen was seen in the 2 mm. thick section of the anterior descending artery occlusion. It gave the impression that it had been deformed and compressed by the surrounding material. The appearances were confirmed histologically<sup>1</sup> and were thought to represent occlusion by intimal haematoma.

The disruption of the old intima in the depths of the right coronary artery occlusion<sup>2</sup> prevented a similar interpretation of the changes in this artery being made with assurance. The appearances were however not out of keeping with occlusion by haematoma also in this artery. The gross appearances were confirmed histologically. Iron deposition was considerable.

The four recent occlusions had also involved more than one artery simultaneously - or nearly so - but a possible connection could be traced between them. Fresh thrombus blocked separately the left circumflex artery, two large branches of this artery, and the main septal branch of the anterior descending artery. There is little doubt that one or more of these several thrombi were the immediate cause of death. Indeed they had blocked off almost the entire remaining arterial supply to the heart.

Death occurred too soon after the onset of the fatal attack for myocardial damage to have developed. Only one small focal area in the territory of the left circumflex artery was found, in which polymorphonuclear cell infiltration indicated recent damage, the exact cause for which was not clear. All but one of the recent lesions showed mixed red and grey thrombus plugging arteries whose walls showed no acute changes, with the endothelium intact.

The fourth lesion involved the first large branch (3) of the left circumflex artery and had been a canalised occlusion of some standing. The intima was thickened and at one point was infiltrated by leucocytes. The fibrous structure of the canalised tissue in this lesion merged with the more recently deposited thrombus, as though the latter had been there for some time.

One reconstructive interpretation of events could be as follows:- Thrombus had recently built up on the damaged area in the first branch of the left circumflex artery and had caused its occlusion. A saddle of thrombus connected with the occlusion of the nearby second branch (4). Portions of thrombus had also become detached. One portion passed further down the left circumflex artery to impact at a narrowing and bifurcation (5). Blood flow thereupon ceased in this artery and a further detached portion of thrombus was carried proximally into the anterior descending artery. This portion impacted at a bifurcation of the main septal artery (6).

It would seem therefore that recent thrombus built up on an area of previous thrombosis of old-standing, blocked a neighbouring artery by propagation and caused occlusion of 2 others by short-range embolism.

1. 12 ADA 2:5 micro. (between Chap. 7;8) 2. 12 RC 2:1b Colour transparency, Chapter 8.

CASE 13

T.W. M. 70 yrs. Rubber worker: despatch clerk. P.M. No.676/52

Coronary artery disease, with mitral stenosis and anthracosilicosis.

Clinical features : Severe sternal pain was experienced for the first time 11 days before death. It occurred at rest after retiral to bed, was accompanied by vomiting and dyspnoea, and lasted well into the next day. Severe breathlessness returned 3 days later. He was severely orthopnoeic on admission to hospital and died the following day. Basal crepitations; B.P. 112/80 mm.Hg.; Atrial fibrillation. E.C.G. : Recent antero-septal infarctions.

3 years before death there was an acute attack of breathlessness which seems to have been based on left sided, spontaneous pneumothorax. Thereafter he was subject to exertional dyspnoea on slight to moderate effort. Breathlessness was probably based on emphysema and pulmonary congestion from mitral stenosis. there were no features specially in keeping with left ventricular failure or myocardial ischaemia.

Pathological findings : The heart was enlarged, (500 gm.) partly the result of increased epicardial fat. The left atrium was considerably, and the right ventricle moderately enlarged. The mitral valve was the seat of chronic rheumatic deformity, with stenosis admitting the finger tip only. Adherent blood clot was present in left atrium and left ventricle.

Recent myocardial infarction involved the anterior 2/3 of the interventricular septum and the anterior wall of the left ventricle. The appearances were for the most part in keeping with damage of 11 days duration. At the margins of the infarct the damage was patchy and appeared to be somewhat earlier, but was probably none the less of the same age. The right ventricle was involved in its deeper portions. All areas of damage lay in the territory of the anterior descending artery and its main mural branch. The right ventricular damage lay in the territory of its septal branch.

The coronary arteries were the seat of widespread severe atherosclerotic disease. In addition to occlusion of the anterior descending artery (1), there was important narrowing only at one other point. That was in the left coronary circumflex artery (2).

(1) The anterior descending artery had been narrowed to approximately 1 x 1.5 mm. in the region where two important branches arose. The intimal tissue which had caused this narrowing contained iron deposits and in configuration and colour had evidently had its origins in thrombus. There was no recorded clinical episode corresponding to the lesion at this stage. The main stem and the main mural branch were occluded by recent thrombus (consistent with 11 days) which rode the bifurcation in saddle fashion. This thrombus was detached at places by an early stage of canalisation, so that neither obstruction was still complete at death, although nearly so.

A thin band of thrombus extended up the artery to a small (3rd division) branch which was completely occluded by it.

This small occlusion was also undergoing canalisation by fine tracks. It seemed likely that thrombosis had originated at this point and had later propagated - or been displaced - distally, impacting at the point of narrowing and bifurcation. No local cause for thrombosis found.

In view of the atrial and ventricular thrombus the possibility of embolism was also entertained. There was no evidence of embolism outwith the coronary circulation. The left ventricular thrombus overlay the area of infarction and was probably secondary to it. The atrial clot was of long standing.

② The narrowing of left circumflex artery was very localised and was probably originally thrombotic in origin. It was however of old standing. There had been no evident myocardial damage related to it, which might suggest that occlusion had never been complete. At death the lumen measured 0.7 mm. in diam.

The lungs showed emphysema and nodules of anthraco-silicosis. As already noted there was mitral stenosis. These lesions had caused some right ventricular hypertrophy and with it some increase in the calibre of coronary artery branches supplying it. This change was slight in degree. Atrial enlargement was likewise accompanied by increase in the injected vasculature. Otherwise the picture of ischaemic heart disease was little if at all modified by the presence of the other lesions. That is to say, the relationship of coronary artery occlusion to the extent of myocardial damage was not out of keeping with that found in comparable cases of pure coronary artery disease.

CASE 14

Mrs. E.W. F. 64 yrs Housewife. P.M. No.740/52

Clinical features:  
~~This woman~~ <sup>she</sup> was a diabetic and had been under treatment with insulin for 3 years. There was gross obesity. Her activities had been increasingly limited by failing sight, and during the last year she was almost totally blind.

19 days before death/<sup>she</sup>rose during the night and developed severe left mammary pain which persisted for 9 hours until relieved by an injection. There were no other symptoms.

On admission to hospital later that day the diabetic state was moderately out of control. B.P. 100/80 . Blood sugar 400 mg.% Her condition deteriorated during the day, and continued to deteriorate after diabetic control was satisfactory. She died in coma. There were no further ischaemic episodes.

There was no complaint of chest pain prior to the terminal illness.

pathological findings : In addition to the findings in the heart , there was widespread atherosclerosis, diabetic nephrosclerosis and a recent cerebral infarct in the left middle frontal gyrus.

The heart was enlarged (570 gm.) mainly as the result of left ventricular enlargement and greatly increased epicardial fat.

An extensive area of infarction involved the anterior 2/3 of the interventricular septum , the anterior and lateral walls of the left ventricle and the anterior wall and adjacent columnae carnae of the right ventricle. The appearances were in keeping with a duration of 19 days . The damage lay in the territories of the anterior descending artery and the left circumflex artery.

In the territory of the former there was also some patchy fibrosis of uncertain age. In the territory of the latter there was evidence of more extensive patchy infarction of a few months duration , in the same area as was involved in acute necrosis.

There was also a small patch of necrosis of a few months duration in the terminal territory of the right coronary artery.

Atherosclerotic disease of the coronary arteries was widespread and severe. It involved several small vessels ( 3rd division) as well as the main stems. There was however severe narrowing of the main branches only at 2 points.

① Anterior descending artery occlusion : Severe disease commenced just after the main septal artery had been given off. below this level the lumen of the artery had been narrowed to 1 x 1.5 mm. in diameter, in several stages. The most recent of these undoubtedly had been due to thrombosis. It is likely that the resulting occlusion had been nearly complete and that the patch of fibrosis in the interventricular septum was related to it. This episode had probably taken place several months before death.

In the terminal episode the remaining track had been

completely occluded by thrombus. By the time of death a new track had formed between the clot and the vessel wall in the distal part of the occlusion. Only a distance of about 2 mm. remained completely blocked. (This lesion is illustrated in detail between chapters 7 and 8, and is the subject of discussion in chapter 7).

② Left circumflex artery. There was established, complete occlusion 8-9 cm. from the ostium, of at least several months, if not longer, in duration. It had evidently resulted from thrombosis. Similar intimal appearances extended some 3 cm. proximally, suggesting that at one time thrombotic occlusion of considerable length had been canalised all but for a few mm. near its distal end. (This lesion is also illustrated between chapters 7 and 8, and among other features shows a good example of small intimal vessels arising from the lumen.)

In addition there was :-

a. Narrowing of the proximal part of this artery, about 2 cm. from the ostium, to 1.2 mm. in diameter for a very short stretch.

b. severe narrowing of the terminal branch of this artery.

c. Severe narrowing of the main branch of this artery (2nd division)

d. Severe narrowing of a large first branch of the anterior descending artery (2nd division)

e. Numerous narrowings of small arteries, especially at their origins from the parent stems, as they passed through the thickened intima. 5 of these are noted.

**Reconstruction :** The occlusion in the distal part of left circumflex artery appeared somewhat older than the earlier episode of myocardial damage in its territory. The most obvious relationship would be that myocardial damage had followed this occlusion. It is also possible that occlusion had taken place without damage at the time and that damage had followed withdrawal of blood supply from the anterior descending artery when it became severely compromised for the first time, several months before death. This may seem speculative, yet it is certain that following the final occlusion of the anterior descending artery, damage occurred also in the territory of the left circumflex artery, without further change in that artery (which was occluded).

The small area of damage in the territory of the right coronary artery is not easily explained, for that artery itself was not obstructed. A small branch, corresponding to the infarcted territory, was however severely narrowed as if from former occlusion and it may be that damage occurred either at the time of its occlusion, or later on withdrawal of collateral blood supply following the anterior descending artery occlusion.

Anastomotic development was slight to moderate in extent, linking all three main vessels to each other.



CASE 15

Mrs M.L. F 56 yrs. Housewife. P.M.No. 741/52

Clinical features : 7 years before death this woman was admitted to hospital with rheumatoid arthritis and pneumonia. As a result of the former her physical activities were limited, and the latter may have made contribution to breathlessness.

During the last 3 years there was increasing breathlessness on exertion but no anginal pain was noticed.

4½ weeks before death slight lower sternal pain was experienced. Pain returned 17 hours later with great severity and lasted for several hours. It was accompanied by sweating, dyspnoea and, after admission to hospital, by vomiting. On admission she was in early congestive cardiac failure. B.P. 140/86. The electrocardiograms showed recent anterior myocardial infarction.

The cardiac state remained poor, but anginal pain recurred only once, 3 weeks after admission. Anticoagulant therapy was employed for 4 weeks. 3 days after its discontinuance, abdominal pain developed as the result of mesenteric embolism, and she died 2 days later.

Pathological findings : The heart was moderately enlarged (420 gm.) in respect of the left ventricle and increased epicardial fat.

A mid-zonal infarct occupied the anterior part of the interventricular septum and anterior left ventricular wall. Through and through infarction was localised near the apex and there was adherent thrombus in the ventricular cavity. Myocardial damage was in at least 2 stages:-

a. recent necrosis consistent with 4½ weeks in the territory of the anterior descending artery (distal to occlusion). The central parts showed confluent coagulative necrosis, some of which could have been of more recent date but was consistent with 4½ weeks). The peripheral portions were patchy and showed early stages of healing.

b. fibrosis was found in the same area and also more laterally where it lay outwith the territory of the anterior descending artery distal to the occlusion of the main stem but was in the territory of the first main mural branch of this artery.

The right coronary artery was small and took no part in the circulation to the left ventricle. Atherosclerotic disease affected a stretch of about 3 cms. in the anterior descending artery but was elsewhere slight. The coronary arteries in general showed concentric intimal thickening but no important reduction in the lumen.

① The anterior descending artery was the seat of thrombotic obstruction in at least 2 stages. The older of these was of uncertain age, for there was no corresponding clinical episode, but was probably several months. It is likely that severe obstruction to blood flow had occurred at its inception, and that it was the cause of the patchy fibrosis in its territory. Before final occlusion however the remaining channel was 1.5 mm.

in diam. at the narrowest point. Terminally, this track had been obliterated by thrombus ( $4\frac{1}{2}$  wks. before death). Sections through this lesion are illustrated between chapters 7 and 8 and following page 8:12. It would seem that the penultimate episode of thrombosis had been associated with haemorrhage into the underlying atherosclerotic plaque. In its deeper portion thrombus was seen to be undergoing assimilation into the underlying intimal tissue.

(2) At a higher level the first large mural branch (2nd. division artery) had been severely narrowed at its origin from the main stem. It may have been completely occluded at one time and continuity of lumen subsequently restored. An area of old-standing fibrosis was found in its territory, out-with the territory of the main stem below this level.

(3) The largest septal branch also showed old-standing severe narrowing of its origin, and it may be that some of the septal fibrosis was related to this lesion. This is however less certain than with (2). It is however of interest that this branch made a major contribution to the blood supply to the deeper portions of the right ventricular myocardium, and that these portions were also the seat of fibrosis. Moreover considerable anastomotic development had taken place between its branches and branches of the right coronary artery.

Myocardial damage in the right ventricle lay in the territory of the anterior descending artery and its main septal branch and had taken place in at least 2 stages - recent necrosis ( $4\frac{1}{2}$  wks) and old fibrosis.

Embolism was demonstrated to the superior mesenteric artery, the source of which was presumably blood clot in the left ventricle.

There was extensive pleural adhesion on the right side with attachment of the diaphragm to the chest wall at the level of the 3rd interspace.

CASE 16

Mrs.M.A. F. 72 yrs

Housewife.

P.M.No.73/53

Clinical features : Unfortunately in this case ,in which there are interesting pathological findings,there is no history of ischaemic symptoms.

Previously a healthy woman who had borne 14 children began to experience impaired health some 3 months before death. Symptoms included loss of appetite and weight .Giddy turns were a feature at the beginning. Decline in health was progressive and she was admitted to hospital 10 days before death for investigation, an alimentary tract neoplasm being suspected.

On admission auricular fibrillation was present,apex rate 120 / min.,B.P. 126/86. , cardiac enlargement and crepitations in the lung bases. Electrocardiograms gave evidence of extensive anterior myocardial infarction. Anginal symptoms were sought and denied,and she did not admit to breathlessness. Anticoagulant therapy was employed. She died in her sleep 10 days after admission,without complaint of pain or duspnoea.

3 days after admission the left hand was colder than the right and the radial pulse was weaker on the right side; there was no pain.

Pathological findings : The heart was enlarged,(420 gm.). There was evidence of at least 2,possibly 3 or 4 episodes of myocardial damage.

a.Old-standing fibrosis was present (1) in patchy fashion in the interventricular septum and anterior left and right ventricular walls. These areas lay in the territory of the anterior descending artery, and (2) in a localised area in the posterior wall of the left ventricle in an area supplied by terminal branches of the right coronary artery. It is likely that these epsiodes occurred at different times.

b.Recent myocardial infarction involved the greater part of the territory of the anterior descending artery below the level of occlusion. The damage was patchy at its peripheral parts and confluent in the central portion. The anterior wall and some muscular columns in the right ventricle were also involved, and lay in the territory of the anterior descending artery. The histological characters of the lesion were in keeping with a duration of 1-3 months. (For purposes of analysis this lesion has been taken as 2 months in duration)

Here and there in the same area were localised infiltrations with polymorphonuclear cells and lymphocytes,and it may be that these represented extension of damage of more recent date.

The coronary arteries ,apart from the anterior descending artery, were unobstructed and were affected by atherosclerosis only to a slight degree. The right coronary artery was large.

① The anterior descending artery was completely occluded 2 cm. from the ostium for a distance of 4.5 cm..

a. There was evidence of old-standing narrowing of thrombotic origin,leaving a lumen 1.5 mm.in diam. at its narrowest point. Patchy fibrosis in the interventricular septum and anterior ventricular walls was probably related to this lesion. It is

likely that an important septal branch was involved in this lesion and that its obstruction accounted for fibrosis high in the interventricular septum.

b. Within recent date the remaining lumen had been blocked by thrombosis. Thrombus formation had taken place in layers, and was for the most part fibrin thrombus. Occlusion was probably gradual but the period of time the process occupied is unknown. This occlusion corresponded to the recent myocardial damage, which was thought to be 1-3 months in duration.

Histologically the interface between thrombus and previous intima was ill-defined. Fibrin and collagen merged as the thrombus was assimilated into the intimal thickening. The upper and lower extremities of the thrombus showed early stages of canalisation. The injection medium penetrated as into a spongework and in many instances the channels appeared to be the beginnings of new blood vessels.

This lesion is illustrated in detail, with stereo-arteriogram and selected and orientated sections, between chapters 7 and 8. Of particular remark is the basketwork appearance of enlarged vasa-vasorum which surrounds the upper part of the lesion.

② Right coronary artery The cause of the localised area of fibrosis in the territory of this artery is speculative. The artery was unobstructed at death, and was the seat of atherosclerosis at one part only - about 2.5 cm. from the ostium for a distance of about 1 cm. At this point a plaque occupied about 1/3 of the lumen. The presence of staining by old blood pigment, "fibrinoid", minute intimal vessels, and severe encroachment of the origin of a small branch arising at that point, were features in keeping with a thrombotic origin for this lesion. It is tempting to postulate that at its inception thrombotic narrowing of this vessel was sufficiently great to cause myocardial damage in its territory; or that a portion of thrombus became detached and formed an embolus which lodged in the terminal branches to cause localised damage.

Other findings : 1. small infarct of the left kidney, at the stage of yellow coagulative necrosis. Also early nephrosclerosis. 2. Left brachial artery occlusion by embolus. 3. Left vertebral artery occlusion by embolus, recent. No associated cerebral infarction (but this embolus could have been too recent for damage to have been manifest).

Thrombus in the left ventricle was the only demonstrated source of embolism.

The absence of pain despite extensive muscle damage was striking; and it is also of interest that embolic obstruction of the brachial and renal arteries was likewise unattended by pain.

Anastomotic communications were only slightly enlarged beyond normal.

CASE 17

Mrs B.M. F. 73 yrs

Housewife

P.M.No. 84/53

A thin, elderly woman of small stature, with kyphosis and pigeon-chest deformity.

For 10 years she had been subject to upper sternal pain on effort. Pain was invariably relieved by resting for a few minutes and was helped by trinitrin. The exact onset is not noted. There were no attacks of severe enduring pain until terminally. There was gradual progression in the severity of symptoms and during the last 2 years anginal pain also occurred at rest. Attacks occurred daily.

4 weeks before admission severe sternal pain lasted throughout the night. She was not unduly breathless and there were no other symptoms. Pain again became severe about 2 weeks later, culminating in a severe enduring attack in which there was also sweating and nausea. She was still in pain when admitted to hospital. She was pale, looked shocked but B.P. was 150/70 mm.Hg. Sinus tachycardia 104 / min. Electrocardiograms showed recent anteroseptal myocardial infarction.

She received anticoagulant therapy and digitalis. Progress in hospital was largely one of deterioration. The terminal phase was complicated by chest infection and complete heart block.

Pathological findings : The heart was not enlarged ( 355 gm.) but there was great increase of epicardial fat. The coronary ostia were narrowed, (R : 1.0 mm. L : 2 mm. in diam.)

The coronary arteries were the seat of widespread severe atherosclerosis, without evidence of recent change. Enlargement of anastomoses had taken place to a remarkable degree.

Right coronary artery was large, supplying the posterior wall of the left ventricle. It was occluded in 2 places:

① Between 3 and 5 cm. from the ostium there was old-standing thrombotic occlusion which had been canalised by two tracks less than 1 mm. in diameter each.

② At the point where the posterior descending artery (inter-ventricular) was given off there was old-standing complete thrombotic occlusion which was canalised by a hair-line track. This track could have no functional value for blood flow.

At other points along the length of the artery there was severe atherosclerosis with features suggesting an origin in thrombosis.

③ Left circumflex artery showed severe atherosclerotic disease with small aneurysm formations. The area from which these arose had been the seat of thrombotic narrowing or occlusion. The remaining channel was distorted and narrowed, at one point to 1 mm. in diameter.

④ Anterior descending artery was also severely distorted by old-standing thrombotic episodes. This lesion probably had been complete and recanalised. The origin of the main septal artery was involved. Aneurysm formation was also seen in this lesion.

⑤ Large mural branch of left circumflex artery (2nd division)

## CASE 17 (continued)

was severely narrowed at its origin.

⑥ the Posterior Descending (interventricular) artery arose from the right coronary artery and was severely narrowed 2 cm. from its origin. The arteriographic appearances were in keeping with thrombotic occlusion and canalisation.

In addition, there was severe narrowing at the origins of 1 small (3rd division) artery from the right coronary and 2 small arteries from the anterior descending artery.

Only lesions 1,2,3 and 4 were examined histologically. In each there was evidence of old thrombotic incidents on at least 2 occasions.

Small mural thrombi were found in 3 places in the right and 1 in the anterior descending artery. Neither by virtue of site or size could these small clots have exerted significant effect on blood flow. A small intimal haemorrhage was found in the right coronary artery, unattended by encroachment on the lumen or thrombosis. There were no other acute changes.

Myocardial damage had taken place in at least 3, and possibly many, episodes. In the left ventricle it was restricted to the inner 3/5 and was almost uniformly distributed.

a. Patchy fibrosis - one or several episodes.

b. Speckled infarction, composed of numerous areas of focal necrosis, showing a stage of healing 2-4 weeks in duration, probably 4.

c. A few scattered areas of focal necrosis of more recent date.

Muscle damage (b) formed a ring of infarction in the inner zone of the left ventricle. The areas of necrosis were discrete and measured 1-3 mm. in diameter. The immediately subendocardial zone was spared. There was no involvement of the epicardium or outer layers. It is likely that this episode of muscle damage occurred at the time of the first severe attack of pain, 1 month before death and that damage (c) occurred with the subsequent attacks. Fine patchy fibrosis was also found in the right ventricle

Anastomotic enlargement was highly developed. A very large superficial communication joined the anterior descending artery at the apex with a major branch of the left circumflex artery at the obtuse border. There were many other superficial anastomoses of considerable size, one of special note being found in the left atrial circulation.

The vessels composing the subendocardial plexus showed great enlargement, forming a network of large-bore intercommunicating channels. It appeared likely that these channels provided an even distribution of blood to the deeper layers of the left ventricle so that regional massive myocardial infarction had not occurred. When eventually the blood supply to the myocardium fell below the metabolic requirements, during attacks of acute coronary insufficiency, necrosis took place in small focal areas almost uniformly distributed throughout the deeper layers of the left ventricle.

This case, together with 6,8 and 19, is discussed and illustrated in chapter 6.(and 4)

Carcinoma of the stomach and cerebro-vascular disease were incidental autopsy findings. There were no metastases

CASE 18

W.G. 71 yrs. Fishmonger (Rtd.) P.M. No. MHA 5099

This man was known to have hypertension and diabetes mellitus. Evidently he did not complain of ischaemic pain until the day of his death. While walking he developed severe pain below the left nipple, accompanied by breathlessness. The pain lasted about 15 minutes. Breathlessness persisted until death a few hours later, shortly after admission to hospital. He had recently been keeping well. Five months previously there had been a minor cerebro-vascular incident.

Pathological findings : The heart was enlarged (530 gm.) mainly as the result of left ventricular hypertrophy. Arteriograms of the coronary circulation showed widespread atherosclerotic disease but only one main stem was obstructed.

① There was almost complete occlusion of the anterior descending artery, shortly after its commencement. A narrow track could be followed through the occluded area and was almost certainly the product of canalisation of old-standing occlusion. The material composing the occlusion was atheromatous, containing much doubly refractile lipoid. It also contained much brownish material, the product of blood pigment breakdown. In such areas there was abundant iron deposit.

The single track which had restored continuity of lumen was one of several, the others being very small and not filled by injection medium. Haemorrhage into the atheromatous thickening had taken place at several points in this artery but it is unlikely that encroachment on the lumen had resulted.

Occlusion had evidently taken place in two stages. The first episode narrowed the artery lumen to about 1/3 of its original diameter. The second had evidently brought about complete occlusion. Stereo-arteriograms and histological sections of this lesion appear in Chapters 7-8.

② 1-2 cm. further down the artery the same process seemed to have been repeated - occlusion in two stages with canalisation. The channel resulting from canalisation is much wider in this lesion, probably related to its shorter length. In this lesion too there was brownish discolouration, iron deposition and haemorrhage into the intima.

Between these lesions the artery was not importantly narrowed. There was however a recent mural thrombus which coated about 1/3 of the inner circumference.

The myocardial damage which had resulted from occlusion of the anterior descending artery was extensive, and involved the entire related territory of that artery as reckoned circumferentially. For the most part this damage was fibrotic, the result of widespread myocardial infarction of old-standing. In a few places the increased proportion of fibroblasts and the presence of pigment laden macrophages suggested that some of the damage had taken place within the last 1-2 years. The appearances did not make it unlikely that the old-standing damage had taken place in more than one stage, in keeping with successive episodes of coronary artery thrombosis.

There were also a number of areas in which polymorph infiltration suggested very early response to tissue death. To judge from the mottled appearance of the fresh tissue, there had been quite extensive muscle damage.

There was also focal damage of old-standing in the territories of the right coronary and left circumflex arteries. As indicated below, there was no evidence of complete occlusion of either of these arteries but the presence of myocardial damage may perhaps indicate that a more severe degree of narrowing than was found at death may have been present at one time.

The right coronary and left circumflex arteries were the seat of severe atherosclerotic disease. At no point however was there severe narrowing of the lumen. Considerable stretches of both arteries showed brownish discoloration of the intima, in which there were also deposits of iron. These features suggested a thrombotic origin for the intimal tissue, but alternatively they could have arisen from previous intimal haemorrhages. Numerous intimal vessels could be seen in the micro-sections and at places the point of entry of the injection medium could be traced to the lumen. The right coronary artery also showed widespread dissection of the intima by injection medium, accompanied by blood and cellular infiltration. There seemed little doubt that the areas into which injection medium had penetrated had been in life the seat of breakdown with intimal haemorrhage and cellular reaction; and that the dissection was not a simple artefact.

There was severe narrowing at various points in smaller branches:

- Post-Interventricular branch of RC. (IV)
- Right marginal branch of RC. (IV)
- Main atrial artery, arising from RC. (V).

Anastomotic communications of large scale were found in the interventricular septum in the region of the infarct, and to a lesser extent at a distance, linking the right coronary artery with the anterior descending artery.

A small cystic area was found in the brain, in relation to R. basal ganglia, representing old infarction.



CASE 19

Mrs. J.S. 70 yrs. Housewife Para. 7 + 1 P.M. No. 126/53.

Clinical features : For about 10 years this elderly woman had been subject to anginal pain on slight effort. By keeping within her limits distressing pain was avoided and episodes never lasted longer than 10 minutes. At no time was there clinical evidence of myocardial infarction except terminally. In latter months the condition was more severe, and she also suffered from giddy turns. She was known to have suffered from hypertension for at least 2 years, with a blood pressure of 200/140 mm. Hg.

Nineteen hours before death she developed severe enduring sternal pain, requiring morphine for its relief, and she was admitted to hospital in a state of shock. Mephentermine and digoxin were administered without benefit. The electrocardiograms were thought to be in keeping with old anteroseptal infarction and very recent posterior damage. There were no Q waves in aVF.

Pathological findings : The heart was enlarged (610 gm.), mainly as the result of left ventricular hypertrophy and epicardial fat.

The coronary circulation showed right preponderance. Atherosclerotic disease was widespread throughout all main branches and the coronary ostia were also stenosed.

Right coronary artery:

① Old-standing occlusion, as from thrombosis, almost completely obliterated the lumen 3 cm. from the ostium. Anatomical continuity resulted from canalisation by narrow tracks.

② Proximal to the above occlusion there was severe narrowing.

Anterior Descending artery:

③ Just distal to the point of origin of the main septal branch, the main stem was obstructed by an occlusion which had characters in keeping with canalisation of previous complete occlusion by thrombosis. The lesion was of old-standing. The lower 1/3 of this artery was also much narrowed.

Left Circumflex artery:

④ Old-standing severe narrowing was present 3.5 cm. from the ostium.

Each of these occlusions appeared to have been formed from at least two episodes of thrombosis, so far as could be judged. All the lesions were of old-standing. Lesions (1) and (3) are illustrated in Chap. 8.

Intimal haemorrhage was noted at 7 sites. There was no evident encroachment on the lumen as a result, and no associated thrombosis.

Several smaller branches were the seat of severe narrowing of old-standing:

2 branches of RC (V) and 1 branch of ADA (V).

Anastomotic communication was highly developed, linking the three main arteries at all possible sites. Enlargement of anastomotic vessels was particularly marked in the sub-endocardial zone of the left ventricle and as a consequence the coronary

circulation was converted into a network of wide-bore inter-communicating vessels . A highly developed net-work was also seen in the walls of the right ventricle.

Myocardial damage :

a. The deeper layers of the left ventricle showed widespread patchy fibrosis

b. Likewise in the inner zone of the left ventricle there was widespread patchy infarction of very recent characters. The area of infarction was composed of multiple focal areas of necrosis, with microscopical appearances in keeping with a duration of less than 24 hours.

Although the entire inner zone of the left ventricle was involved in these recent and old-standing changes, the heaviest incidence of damage had involved the posterior wall of the left ventricle and adjacent part of interventricular septum. There was similar fresh and old damage in the posterior wall of the right ventricle.

Comment: The old focal fibrosis probably resulted from episodes of focal necrosis. There may have been many such episodes, in keeping with the many episodes of obliterative coronary artery changes. There was however no acute change in the coronary arteries which could account for the terminal acute infarction.

This case is one of four selected for special description under the heading of chronic generalised myocardial ischaemia. (Brit. Heart J. 1956, 28, 341 )

CASE 20

Mrs J.C. 73 yrs. Housewife. Para. 4 + 0 P.M.No. 198/53

Clinical features : Eight days before death, severe mid-line upper abdominal pain developed suddenly, and was accompanied by left shoulder pain. By the time of admission to hospital 6 days later she was too weak to give a clear or reliable history. Most of the details were supplied by her son. Pain was initially accompanied by vomiting.

Pain had evidently lasted for 24 hours and was unrelieved by morphine and atropine. 2 days later slight jaundice was noted. The urine was dark in colour but the stools remained normal. Initially on admission she was thought to have a stone in the common bile duct; but the absence of abdominal tenderness, her collapsed condition with low blood pressure, (90/ ? mm.Hg, for which she received mephentermine) and a loud systolic murmur suggested severe cardiac damage. Widespread recent anterior myocardial infarction was confirmed electrocardiographically.

Apart from a similar attack of pain and vomiting during the course of the previous year, she had been in good health and had no chronic symptoms. There is no knowledge of typical anginal attacks.

Pathological findings:

The coronary arteries were unobstructed and the seat of only slight atherosclerotic change, except for the anterior descending artery. The right coronary ostium however was narrowed (2 mm.) The heart (435 gm.) was enlarged from left ventricular enlargement and adiposity.

① The anterior descending artery was completely occluded 2 cm. from the ostium and immediately after giving rise to the main septal artery. Occlusion had evidently taken place in 2 stages.

a. A plaque of atherosclerotic tissue with features suggesting its origin in thrombosis had reduced the lumen to 1 mm. in diam. The age of this lesion cannot be stated with certainty, but it was probably not less than 1 year. Nor can it be determined whether the lumen had been obstructed at one time to a greater degree.

b. The remaining lumen was completely obstructed by recent thrombus, with characters in keeping with 8 days, or thereabouts. There was no evidence of a local precipitating cause for thrombosis (This lesion is illustrated in detail in Chapters 7-8).

Recent massive myocardial infarction involved the anterior wall of the left ventricle and the interventricular septum. In the lower part of the septum rupture had taken place (accounting for the systolic murmur, right ventricular embarrassment and circulatory collapse). The infarct had characters in keeping with a duration of about 8 days. It involved about 3/4 of the territory of the anterior descending artery below the level of occlusion, and included both surfaces in its central portions.

In the deeper layers in the same territory there were a number of small areas of replacement fibrosis, with appearances suggesting a duration of 6 months to 1 year.

Elsewhere the myocardium was healthy. Anastomotic communication between the coronary arteries was slight apart from a single

communication of moderate size between the right marginal branch of the right coronary artery and the anterior descending artery at the apex.

The liver showed well marked "nut-meg" change. The Gall-bladder contained mixed pigment stones. There was no evidence of traumatic or inflammatory change in the bile ducts or ampulla, and no stones were found in the bile ducts. A careful search of the intestinal contents failed to discover gall-stone material.

Comment : Reconstruction of this case is made the more speculative through the lack of a clear, positive history of ischaemic heart disease. The following seems the most likely interpretation of the pathological findings in the heart.

As the result of thrombosis, possibly about 1 year before death, the anterior descending artery was narrowed to 1 mm. or less in diameter. This episode was followed by focal damage in the deeper layers of the left ventricular wall and septum. Thrombotic occlusion of the remaining channel caused severe massive myocardial infarction. Death was doubtless hastened by rupture of the interventricular septum. /by

The part played by cholelithiasis is not clear. There was no pathological evidence that a gall-stone had actually been passed by the common bile duct. There was adequate grounds for pain in the cardiac damage and for jaundice in the hepatic changes of circulatory origin. Were the two attacks of clinical illness caused by coronary occlusions, then the time relations of the pathological changes could be inferred. So long as the possibility remains that pain and vomiting were due to the passage of gall-stones, this point must remain in doubt.

CASE 21

J.M.            M. 50 yrs.            Storeman.            P.M. No. 246/53.

This case was remarkable for the very localised nature of the lethal obstructive lesion, which was contained in the first few millimeters of the left coronary artery.

Clinical features : This man was fit and had no ischaemic symptoms until 48 years of age. During the last 2 years of his life he suffered from almost daily attacks of gripping sternal pain on effort, but was able to continue at his work. (It is not recorded whether the onset of symptoms was sudden or severe, such as would suggest that coronary artery occlusion had occurred at that time, but reference to duration in exact terms may indicate that the first symptoms were distinctive).

Four days before death severe enduring sternal pain occurred at rest. He went to his work as usual. After two days the pain returned with greater severity. He was admitted to hospital in a state of "shock" and died suddenly 2 days later. Electrocardiograms were in keeping with antero-septal myocardial infarct of recent origin.

Pathological findings: There were no important findings outwith the heart. The heart weighed 410 gm.

The coronary arteries were the seat of slight to moderate atherosclerotic disease and were unobstructed except at one point. The left coronary artery, main stem, was completely occluded just beyond the ostium. On injection the entire filling took place from the right coronary artery.

① Occlusion of the left coronary artery had evidently taken place in two stages. The lesion presented features of much interest and is illustrated in detail (Chapters 7, 3). Situated close to the ostium and of very limited extent, the occlusion might easily escape notice in a first glance at the arteriogram of the unopened heart. The lethal lesion was entirely contained within a block 2 mm, in thickness. (In order to avoid disturbance of this lesion close to the ostium, the polyethylene cannula used for injection was sectioned along with the artery) Examination disclosed that there was a shelf or diaphragm of atherosclerotic tissue which had narrowed the lumen to less than 1 mm. in diameter. In the long axis this obstruction was approximately 1 mm. in extent. The aperture was close to the arterial wall at one side. On histological examination it could be seen that the atherosclerotic tissue of the lesion contained masses of "fibrinoid" material, as might well represent a stage in the conversion of fibrin into fibrous tissue (see Chapter 8) . The appearances were not out of keeping with changes in a thrombotic occlusion of 2 years duration.

The tiny hole left in this shelf of tissue was neatly and completely plugged by a recent dark thrombus, of dimensions little greater than a pin's head.

Myocardial damage was likewise in two stages, and detail of distribution is indicated on the cross section just below the mid-point between A-V groove and apex. The old-standing damage consisted of extensive replacement fibrosis which was restricted to the inner half of the left ventricular wall. It occupied nearly the entire territory of the left coronary artery. Only part of the posterior wall of the left ventricle and the posterior part of the interventricular septum were spared. These areas were supplied by the right coronary artery. The damage was consistent with a duration of 2 years.

The recent damage was less extensive circumferentially and was also restricted to the inner half of the ventricle wall. It consisted of confluent blotchy areas which, on histological examination were consistent with 2-4 days duration. The interventricular septum was involved only to a slight extent.

Extensive anastomotic communication had developed between the right and left coronary arteries. As already mentioned the entire heart was injected via the right coronary artery. Anastomotic enlargement was particularly marked in the interventricular septum, and the sweep of these vessels across the septum can be appreciated even on the 2 dimensional arteriogram of the intact heart. Doubtless collateral blood supply through these channels was responsible for the sparing of considerable areas of myocardium in the territory of the left coronary artery following its final occlusion.

Anastomoses of considerable size connected the atrial circulation with mediastinal arteries.

Comment : On reconstruction of this case it would seem that occlusion from thrombosis had occurred in the left coronary artery some 2 years before death. The extensive nature of the myocardial damage suggests that this occlusion was complete or nearly so and it is likely that the small aperture left in the shelf of atherosclerotic tissue was the product of canalisation. The old obstruction itself appeared to be the product of thrombosis which had undergone change to atherosclerotic material. No cause for recent thrombosis was found.

The survival of considerable areas of myocardium in the territory of the left coronary artery after the final occlusion may be taken as a measure of the contribution made by collateral blood supply from the right coronary artery. Likewise a measure of the circulatory contribution made by the small aperture left in the old left coronary occlusion is provided by the disastrous consequences of its obliteration.

It was tempting to speculate upon the ease with which an instrument passed into the left coronary artery could have dislodged the thrombus and have broken down the shelf which supported it.

CASE 22

T.B. M. 66 yrs. Dairy farmer. P.M. No. 273/53

Clinical features: There were no symptoms of cardiac ischaemia until 64 years of age. Sudden severe sternal tightness developed while milking and lasted for 1 hour. He rested until the pain passed off and was able to continue working for the rest of the day.

Thereafter he was subject to sternal tightness on heavy exertion, lasting for 2 to 3 minutes, but was never off work.

Two years after the initial attack, at the end of a long day in the city, he developed severe sternal pain. This had lasted for 6 hours by the time of admission to hospital.

On admission he was cyanosed and "shocked", B.P. 88/72 mm. Hg.. There was engorgement of neck veins and crepitations were present in both lung bases. Circulatory failure became progressively more severe. Death occurred the following day, after temporary recovery from a Stokes-Adams attack.

Electrocardiograms showed evidence of recent posterior and old anterior myocardial infarction on admission. Shortly before death complete heart block was recorded.

Pathological Findings: The heart was enlarged, (590 gm.), mainly as the result of left ventricular hypertrophy. (The kidneys showed only minor arteriosclerotic changes. No records of previous blood pressure were available).

The coronary arteries showed right coronary preponderance, and were the seat of slight to moderate atherosclerosis, except at three sites where disease was severe.

①. The anterior descending artery was completely occluded by thrombus of old standing which was largely converted to atherosclerotic tissue. The lesion is illustrated in detail in chapters 7, 8, by means of stereo-arteriograms with representative cross sections. It would seem that occlusion extended from the origin of the anterior descending artery and that canalisation had taken place from proximal and distal ends. The proximal channel carried the point of complete occlusion to 4.5 cm. from the ostium. The occlusive process involved the first main septal artery at its origin and spread also into a main branch of the main stem. (The detail of this lesion merits close inspection). The age of this lesion was taken to be 2 years.

②. The right coronary artery was occluded by fresh thrombotic material at the point where it gave rise to the posterior interventricular artery. The thrombotic material contained cholesterol crystals. On detailed examination of the lesion, which is also illustrated in Chapters 7, 8, it appeared that intimal dissection had taken place. The portion of intima involved appeared to have had its origin in old-standing thrombus. There was a track which entered at one point and emerged further down the artery, and it seems that the contents of an atheromatous "abscess" had been extruded into the lumen. Together with blood clot of recent date, this material had impacted at the first bifurcation in its course. This is one of few examples of "short-range embolism" which were found in this series, and the only instance in which the contents of atheroma were involved.

(3) The Left circumflex artery was severely narrowed about 1.5 cm. from its origin and 3.5 cm from the ostium. The intimal tissue composing this lesion had characters in keeping with its origin in thrombus, of old-standing. From the absence of myocardial damage in the territory of this artery it was inferred that occlusion had never been complete.

There was also severe narrowing of an atrial artery at its origin. (V, RC)

Myocardial damage had taken place in at least 2 stages.

a. Old fibrotic infarction involved the anterior wall of the left ventricle in patchy fashion, and with lesser severity extended into the interventricular septum. The area of damage lay in the territory of the anterior descending artery.

b. Recent infarction involved the posterior walls of the left and right ventricles and extended throughout the interventricular septum. The posterior portion lay in the territory of the right coronary artery but the greater part of the septal involvement was in the anatomical territory of the anterior descending branch of the left coronary artery. Indeed, the fresh damage in the septal portion of this territory, which had resulted from right coronary artery occlusion, was more severe than the earlier damage which followed occlusion of its own artery of supply. The appearances were in keeping with a duration of 2 days.

c. There was slight patchy fibrosis in the posterior territory of the right coronary artery.

No damage was found in the territory of the left circumflex artery.

Anastomotic enlargement was clearly seen in the atrio-ventricular groove linking the right and left circumflex arteries, across the interventricular septum and in the region of the apex linking the right and anterior descending arteries. A mediastinal communication is seen in the arteriogram of the intact heart,

Reconstruction :

a. Old-standing partial occlusion of right coronary artery with trivial related myocardial damage.

Old-standing partial occlusion of left circumflex artery without myocardial damage.

b. Enlargement of interarterial anastomoses.

c. Thrombotic occlusion of anterior descending artery 2 years before death, with patchy myocardial infarction.

d. 2 years effort angina, during which further anastomotic enlargement maintained supply to the left ventricle largely from the right coronary artery.

e. Occlusion of Right coronary artery with massive infarction of the left ventricle.

(a. and b. are speculative, there being no related symptoms)

Further comments: (1) Heart block : there was withdrawal of blood supply to the upper part of the interventricular septum from posterior and anterior sources.

(2) A few focal areas of recent damage were found in the left atrial wall. It is evident that the atrio-mediastinal communication was unable to prevent this damage following RC occlusion. There is no means of knowing in which direction blood was flowing during life through this vessel.



CASE No. 23

Mrs H.E. F. 62 yrs. Housewife.

P.M. No.367/53.

Myocardial infarction as an incidental finding.

Clinical features : There were no symptoms which could be related to coronary artery disease.

The gall-bladder had been removed at 27 years of age, following dyspeptic symptoms of 2 years duration. For many years she was subject to heartburn and flatulence, but it was clearly recorded that these symptoms bore no relationship to exertion, and there was no breathlessness until the terminal illness.

During the last 6-7 weeks she was tired, weak and breathless on exertion. There was however no ankle swelling, no nocturnal dyspnoea and no precordial pain. Admission to hospital was occasioned by haematemesis. Total gastrectomy with oesophago-jejunosomy was performed on account of gastric carcinoma. The post-operative course was complicated by jaundice, oedema, chest infection, peritonitis and portal vein thrombosis. She died 7 days after operation.

It was noted that the pulse was regular, 76/ min., B.P. 129/80 mm.Hg. on admission. A systolic murmur was present at all areas. Hb. 72%. Electrocardiograms were not taken.

Pathological findings : The clinical findings noted above were confirmed post mortem. It was thought that infarction of the liver had followed portal vein thrombosis. Peritonitis had resulted from leakage at the oesophago-jejunal anastomosis.

The heart was slightly enlarged ( 440 gm.) from left ventricular enlargement and adiposity.

The coronary arteries showed left preponderance, the main supply to the left ventricle being through a large left circumflex artery, the anterior descending artery being proportionately smaller. For the most part the coronary arteries were healthy and unobstructed. Atherosclerotic disease was present in the early part of the right and left circumflex arteries and the anterior descending artery was occluded.

① Occlusion of the anterior descending artery was of long standing and occupied a very short section of the artery, about 4 cm. from the ostium. The lesion is illustrated in detail between chapters 7 and 8. It appeared that the lumen had been narrowed by atherosclerotic tissue to about 2 mm. in diameter. The track so formed had later been occluded by thrombus. From either end digitate processes had penetrated the occluding thrombus and at one or two points continuity had been established by minute channels. Clearly the lesion remained completely occluded functionally.

Myocardial damage was restricted to the territory of the anterior descending artery distal to occlusion. It took the form of patchy old-standing fibrosis, representing old, healed sub-total infarction. It is likely that a considerable degree of anastomotic development had taken place before complete occlusion to account for the relatively restricted area of infarction.

Anastomotic communication between the anterior descending artery and the right and left circumflex arteries was well marked by the time of death, particularly across the interventricular septum.

Points of interest: Despite complete occlusion of the anterior descending artery, the stresses of the terminal illness did not produce any fresh myocardial damage. This may be related to the degree of collateral circulation available at the time.

The complete absence of ischaemic symptoms is striking. The possibility exists that slight symptoms of cardiac origin may have been overshadowed by pains due to other causes, and not distinguished from them.

An atrial branch of the right coronary artery was severely stenosed at its origin, where it was involved in the atherosclerotic disease at this point in the main stem. (V)

Curiously, the obstructive lesion in the anterior descending artery occupied the only stretch of the vessel which was bridged over by myocardium. Usually the reverse is the case.

*[Faint, mostly illegible text, possibly describing anatomical findings or pathology.]*

Pathological findings:

- a. The heart was enlarged (450 g) with the left ventricle enlarged by hypertrophy.
- b. The coronary arteries were normal, with no atherosclerosis. There was aortic disease at the aortic arch, also aortic aneurysm at the base of the aorta.
- c. The anterior descending artery was occluded 7 cm from the base of the heart, the lesion was atheromatous. It is illustrated in detail in figures 7, 8. It had a typical wedge shape in cross section (see figure 7).
- d. The left circumflex artery was completely occluded 10 cm from the base of the heart. Its diameter at the point of occlusion was 2 mm. It is illustrated in detail in figures 9, 10. It had a typical wedge shape in cross section (see figure 9).
- e. The right coronary artery was severely stenosed at its origin.
- f. Thrombotic occlusion of the left ventricle was present which had undergone complete organization. The process of organization was complete and the wall of the left ventricle was normal.

*[Faint, mostly illegible text, possibly a conclusion or summary.]*

CASE 24

S.Q. M. 38 yrs. Miner P.M. No. 420/53.  
Engine driver.

A brief story of ischaemic heart disease in a relatively young man. 2 episodes of myocardial infarction within 6 months.

Clinical features:

One year before death there was an attack of chest pain lasting about half an hour, to which little attention was paid.

6 months later, while lifting a heavy weight, severe sternal pain was experienced, with radiation down both arms, sweating and breathlessness. Pain lasted for 6 hours. After bed-rest at home for 4 weeks, he was seen as an out-patient, when electrocardiographic signs of posterior myocardial infarction in the healing stage were demonstrated. The serum cholesterol level was elevated (285 mg %).

He continued to suffer from effort pain but was able to return to light work.

The terminal illness was heralded by sternal pain which wakened him from sleep and lasted for 10 minutes. Pain returned the following day in enduring form and he was admitted to hospital. He was not "shocked" on admission. Progress however was one of increasing right and left heart failure for a few days and then improvement set in. 9 days after the onset of the final illness death came suddenly, following a brief episode of pain and extreme dyspnoea.

Electrocardiograms were typical of recent extensive anterior myocardial infarction.

Pathological findings :

The heart was enlarged (465 gm.) mainly due to left ventricular hypertrophy.

The coronary circulation was balanced, with slight right preponderance. There was severe disease at two places. Elsewhere atherosclerosis was slight to moderate.

① Right coronary artery was occluded from 2 to 9-10 cm. from its origin. The lesion was an interesting one and is illustrated in detail in chapters 7, 8. It had evidently taken place in at least two stages :

a. Intimal thickening apparently of thrombotic origin had narrowed the lumen to about 2 mm. in diameter. The origins of 3 3rd division (V) and 1 4th division (VI) arteries were caught in this process and as a result were severely stenosed or occluded.

b. Thrombotic occlusion, believed to be 6 months duration, which had undergone complex changes in the process of canalisation. The proximal part of this process formed a network of small vessels between the clot and intimal wall; the distal portion formed a narrow eccentric track. The detail is best appreciated in the stereo-arteriograms referred to above.

② Anterior descending artery was likewise occluded in two stages, at least.

a. An old standing atherosclerotic lesion had narrowed

the distal portion of the occlusion to less than 1 mm. diameter, of lumen. This portion of the lesion was of uncertain age, and was evidently compounded of several episodes. The narrow channel was still patent at death. Proximally the intimal thickening was also apparently of thrombotic origin and had reduced the lumen less severely. It had however involved the origin of the main septal artery ( 2nd division artery , grade IV occlusion) which was all but completely occluded, at death.

b. The proximal portion of the lesion was completely occluded by recent blood clot , presumably of 9 days duration.

This lesion is also illustrated in detail between chapters 7 and 8.

② - there was also a short occlusion in the anterior descending artery close to the apex which had been opened up by 2 channels. (This lesion had gross appearances of atherosclerosis but was not examined histologically. )

#### Myocardial damage:

(1) Massive fibrotic infarction involved the upper posterior wall of the left ventricle and posterior part of interventricular septum. It was deeply placed and occupied part, but not all, of the terminal territory of the right coronary artery. The appearances were in keeping with 6 months duration. There were also a few focal areas of recent necrosis.

(2) Extensive recent myocardial infarction involved the lower half of the left ventricle anteriorly, in the interventricular septum and the apex . The lower part of the right ventricle was also involved. The appearances were in keeping with 9 days duration. There were also a few scattered areas of focal fibrosis in the left ventricular infarct.

Anastomotic enlargement was well developed and the detail may be seen in the diagram. Of interest is the manner in which the unobstructed accessory right coronary artery communicates with neighbouring vessels.

#### Reconstruction :

- a. Partial occlusion of R.C.  
Partial occlusion of A.D.A. with focal myocardial damage.  
The time at which these events took place is speculative, but one or both may have occurred 1 year before death when chest pain was first experienced.
- b. Thrombotic occlusion of R.C. with posterior myocardial infarction, 6 months before death.
- c. Angina for 6 months during which anastomotic enlargement was increasing.
- d. Thrombotic occlusion of A.D.A. with extensive antero-septal infarction and focal necrosis in territory of R.C. 9 days before death.
- e. Sudden death .

Comments: Anastomotic enlargement between RC and ADA could not, of course, avert disaster when both were finally occluded.

Sudden death without structural explanation is common enough in coronary artery disease. In this instance there was leakage during injection from a subendocardial vessel in the infarcted area. Though improbable, it is not inconceivable that sudden death could have been so caused, where the ruptured vessel was in communication with a widely dilated subendocardial network, and ischaemia already at a critical level.

CASE 25

W.V. M. 50 yrs. Motor transport driver. P.M. No.436/53

Clinical features : This man was subject to winter bronchitis and to increasing shortness of breath over the preceding 5 years. He was otherwise fit and there was no history of angina.

He was admitted to hospital following the sudden development of severe headache. There was no loss of consciousness. He had been actively working immediately beforehand. On admission there was nuchal rigidity but no localising neurological sign. Blood was found in the cerebro-spinal fluid. B.P. 175/108 mm.Hg..

36 hours after the onset of headache he suddenly lost consciousness. There was deep cyanosis, the pulse was rapid and weak, and he died within 15 minutes.

There were no electrocardiograms.

Pathological findings :

Massive subarachnoid haemorrhage was confirmed. Bleeding was traced to a ruptured aneurysm of the left middle cerebral artery. The lungs were emphysematous.

The heart was enlarged (465 gm.), mainly from enlargement of the left ventricle but there was also some right ventricular enlargement. An obliquely patent foramen ovale and thinning of the interatrial septum were also found.

The coronary circulation was balanced, with a degree of R. coronary preponderance. The arteries were the seat of widespread atherosclerotic disease of moderate and severe degree. The terminal portions of the right and left circumflex arteries were occluded.

① Right coronary artery was 4 cm. in length. The appearances were consistent with old thrombotic occlusion, at least in the distal portion. In the proximal portion the possibility of extensive intimal haematoma formation could also be entertained. A narrow track traversed the centre of the occlusion for the first 3 cm. . Canalisation had also penetrated for a few millimetres at the distal end, but the occlusion remained complete. The appearances were in keeping with one, two or more years in duration, but there is no knowledge of the exact time for lack of clinically recognised episodes of occlusion.

This lesion is illustrated between chapters 7 and 8 and sections also appear in chapter 8.

② Left circumflex artery Old -standing thrombotic occlusion had involved the distal portion of this artery and was traversed by a complex narrow track. This lesion is also illustrated between chapters 7 and 8.

3. Severe narrowing affected the origin of a large branch of the anterior descending artery (2nd division artery, Grade IV occlusion). The contour of this lesion suggested thrombotic origin.

There were no recent changes in the coronary arteries.

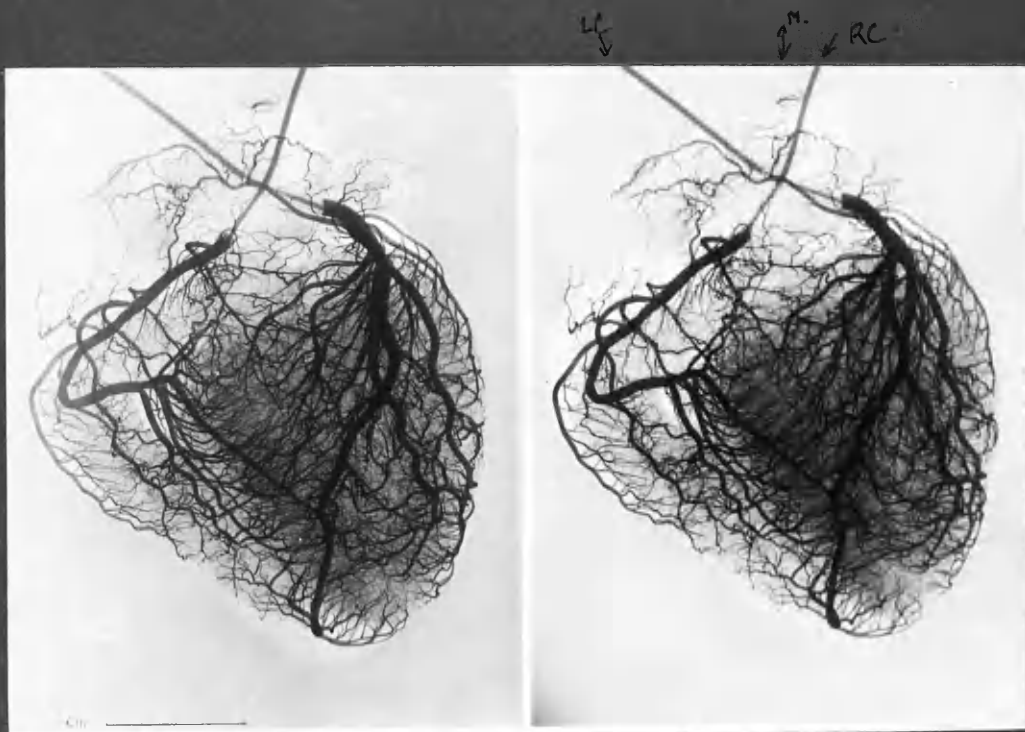
Myocardial damage : There was old-standing infarction in the territory which lay between the two occluded arteries, i.e. the upper posterior left ventricular wall and posterior portion of the interventricular septum. The damaged area was composed of multiple small fibrotic areas with surviving

muscle tissue. Fibrosis lay mainly in the inner half of the ventricle wall . Elsewhere the myocardium showed moderate hypertrophy but no fibrosis ,and there were no areas of recent necrosis.

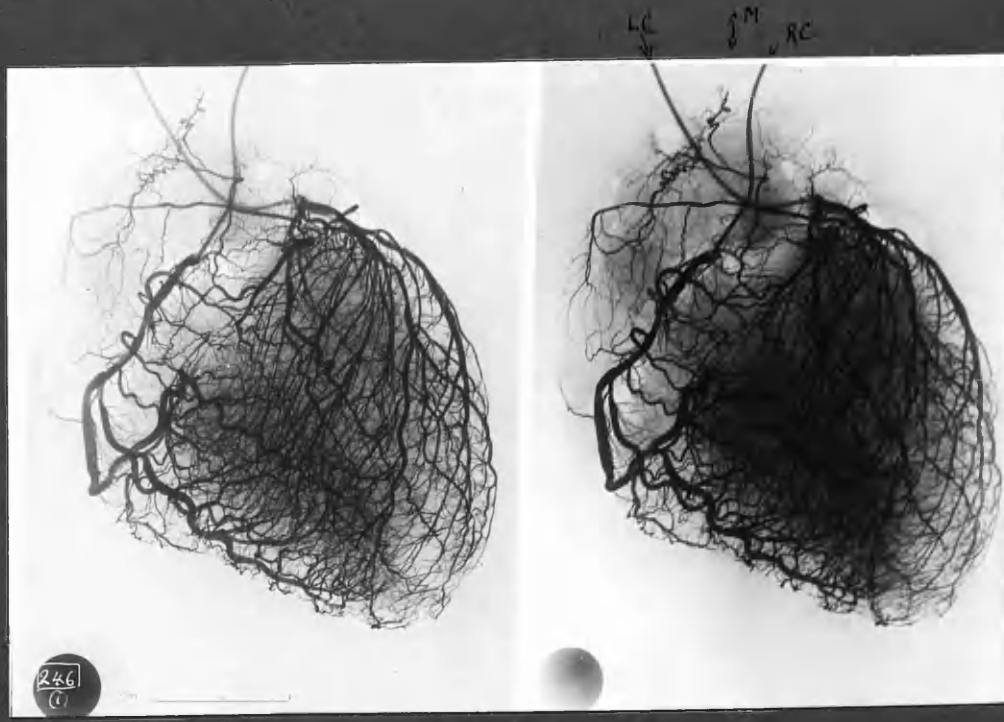
Anastomoses were well developed, linking the anterior descending artery and proximal branches of left circumflex artery with the branches distal to the occlusions. Enlargement of the subendocardial plexus was particularly noticeable not only in the walls of the left ventricle but on the left side of the interventricular septum. This can be seen in the diagram. The widenings of the interarterial communications might be mistaken for errors of penmanship, but in fact represent the dilatation which these vessels exhibit in the immediately subendocardial zone . This may be seen in a stereo-arteriogram included in the illustrations in chapter 4.

Reconstruction: In the complete absence of symptoms of coronary artery disease no detailed reconstruction is possible. There is no knowledge whether the occlusions occurred at the same time or separately. It is evident however that there was only slight narrowing of the lumen before occlusion in both instances; and, despite this, occlusion was followed by only slight to moderate myocardial damage in an incident which escaped clinical notice.

All the appearances were of old-standing. It is likely that death was directly due to aggravation of subarachnoid haemorrhage.



Case N'16.  
NORMAL CORONARY CIRCULATION



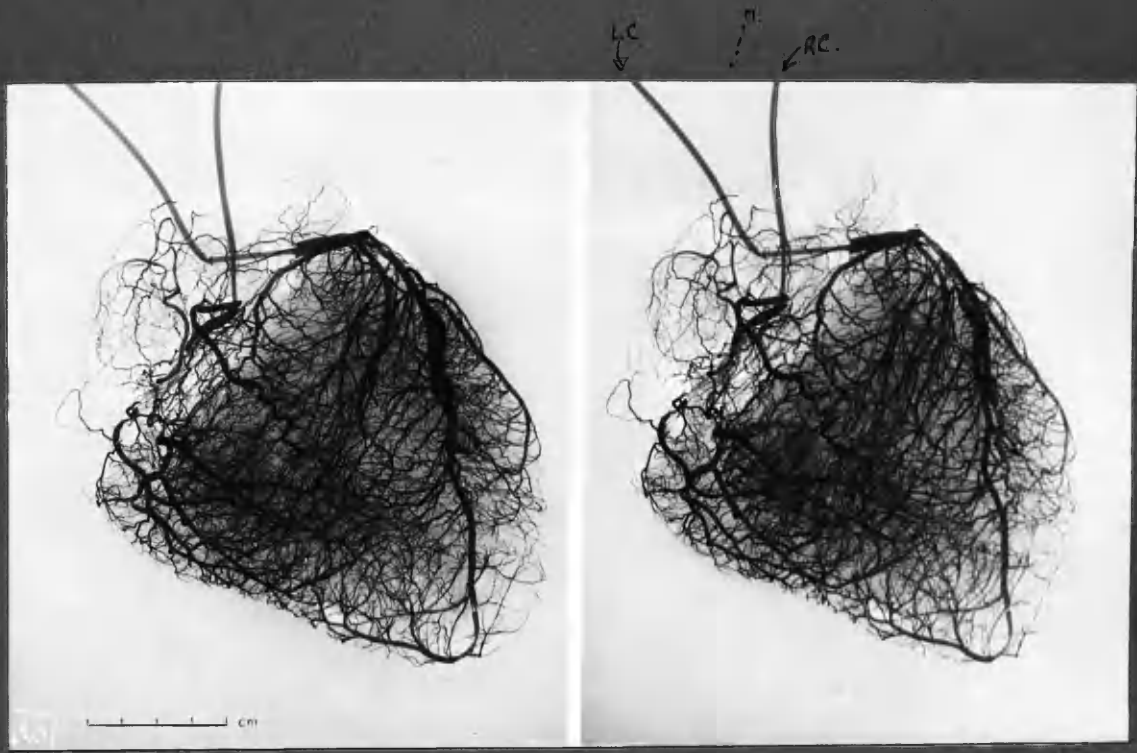
Case 21

Complete occlusion of LC occurred in two stages, the lesion being of remarkably limited extent, within a few mm. of the ostium. Detail of this obstructive lesion appears at the end of this group of illustrations.

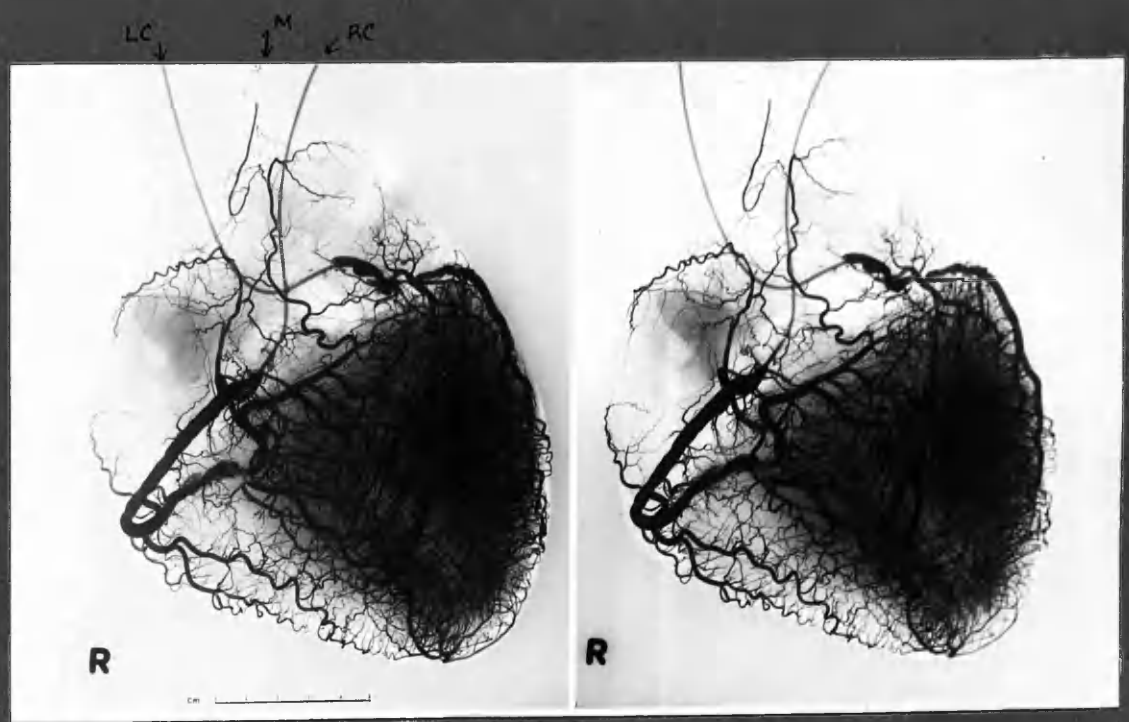
Injection took place entirely from RC, the territories of ADA & LCxA being filled through a rich network of anastomoses. Some communications may be traced across IVS in this stereo arteriogram.

LC = Left coronary, main stem.  
ADA = Anterior descending artery.  
LCxA = Left circumflex artery.

RC = Right coronary artery.  
IVS = Interventricular septum.  
M = Mediastinal communications.



Case 24

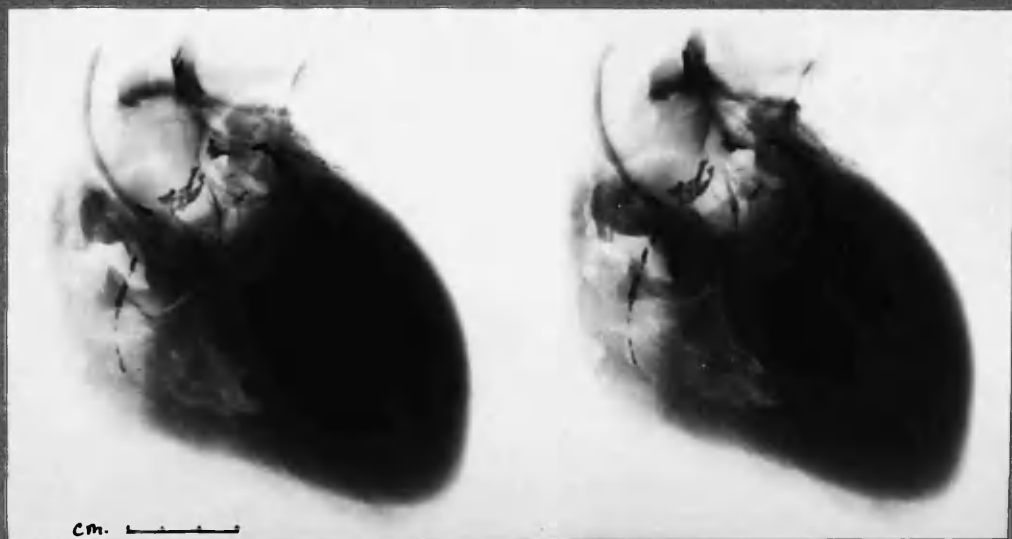


Case 22.

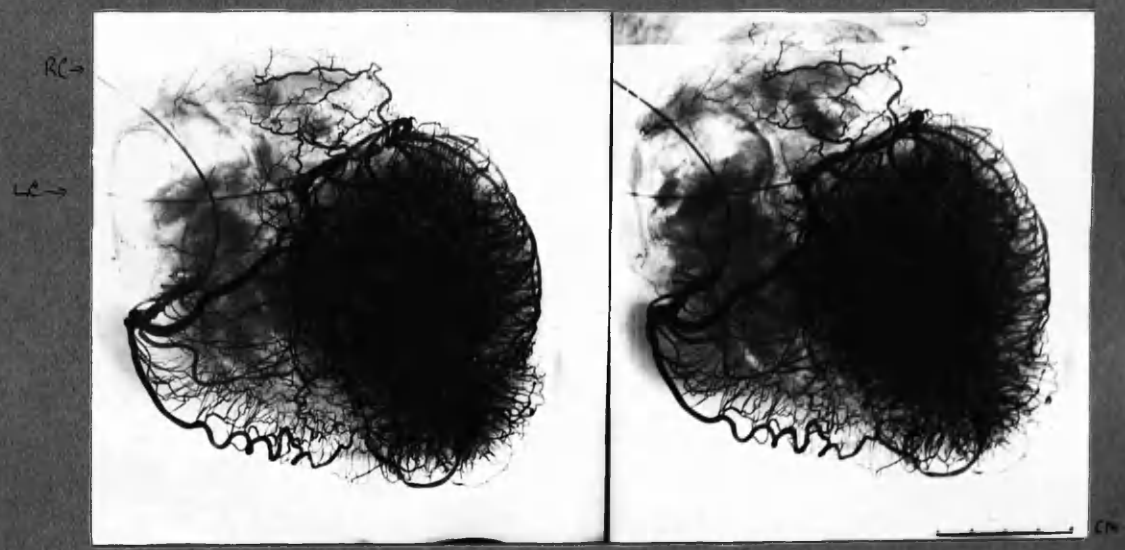
Case 24 1. Complete occlusion by thrombosis, 6 months. 2. Fatal complete thrombotic occlusion, 9 days. Detail of both these lesions to be found between chapters 7 and 8.

Case 22. 1. Complete occlusion ADA, 2 years, detail between chapters 7 & 8. 2. Fatal acute occlusion of unusual type, distal portion RC - detail p. 791. Also narrowing LCxA. N.B. Communications between RC and ADA of little service after both were occluded. Note extensive territory of RC in post. wall of L. ventricle.





Case 8 Calcified coronary arteries.

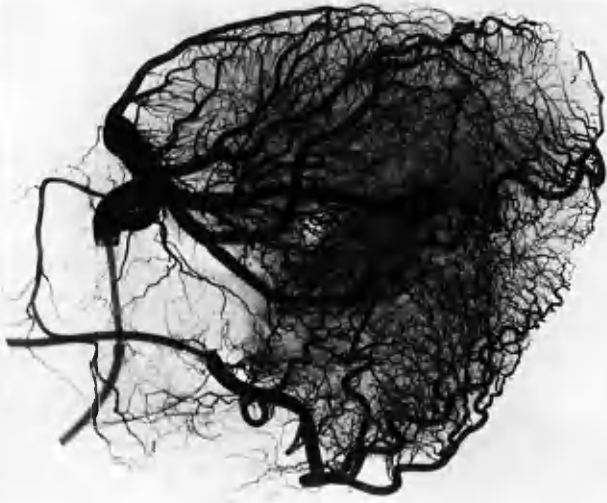


Case 6 Chronic generalised ischaemia.

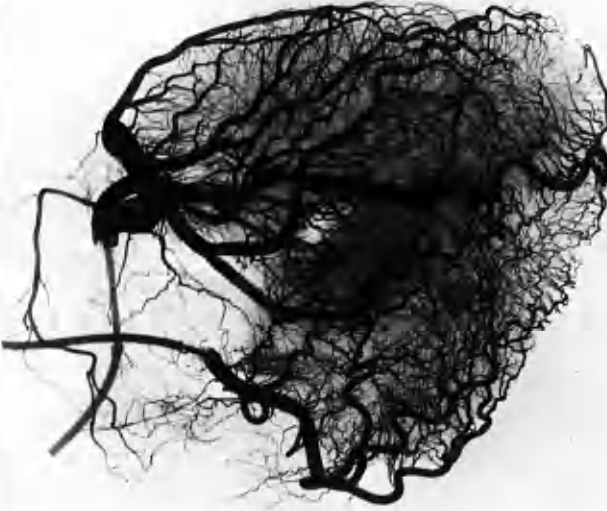
Case 8 : Stereogram of heart before injection. Coronary artery main stems are outlined by calcification. Indeed ADA calcification was visible in clinical radiographs of chest. (This case had the clinical symptoms and the "ossification" of coronary arteries as described in John Hunter.)

Case 6 : Advanced obliterative disease of ADA, LCA and proximal RC. Wide bore superficial communication between marginal branch RC and ADA at apex. Extensive enlargement of deep anastomotic network throughout inner shell of L. Ventricle (Sub-endocardial plexus)

Technical Note: In those two instances radiography was conventional e.f. preceding examples in which radiography using immersion method was employed. Accordingly the heavy shadow cast by tissues was not eliminated and in the lower figure is superimposed on the arteriogram — greatly to the impairment of its photographic reproduction (Indeed the interference by tissue shadow would have been greater but for an ingenious masking method (used in these two instances only) by P.S. Waldie.

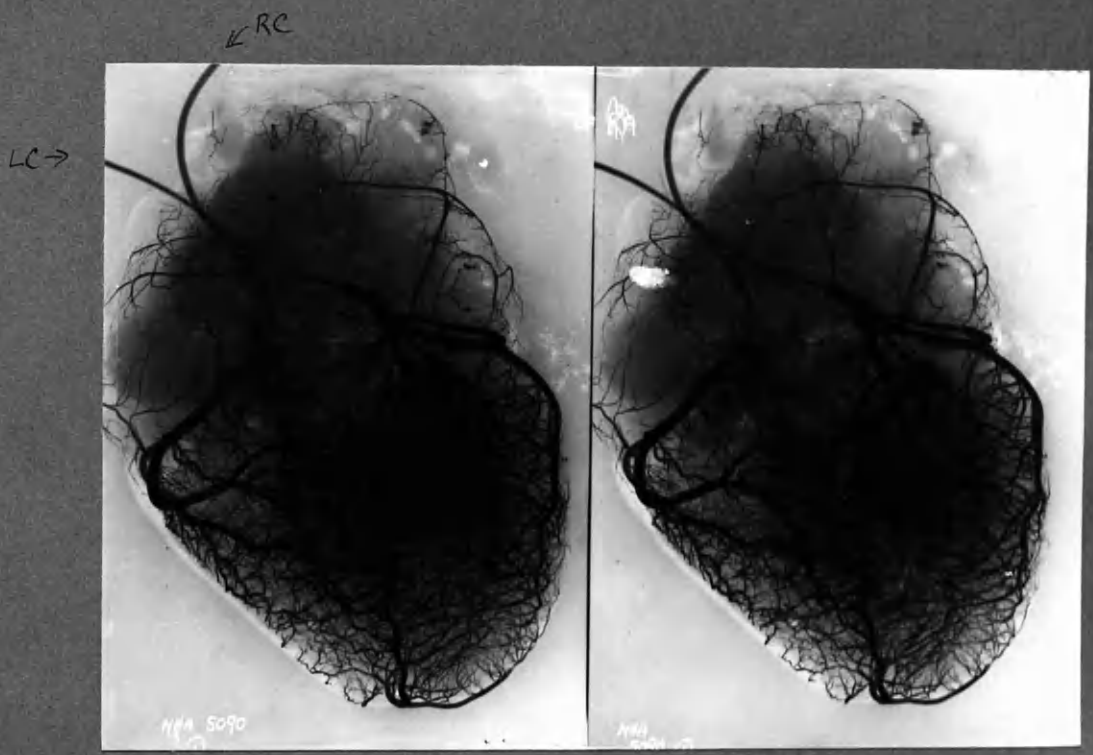


POSTERIOR ASPECT. - MIRROR IMAGE



ANTERIOR ASPECT -

Case N 8 L coronary predominance. It is difficult to examine the posterior wall through the thickness of the heart and a superficial view is obtained by reversing the arteriograms. Look first at L hand pair and then at R hand pair.



Case Dis.

Mitral valvular disease - stenosis + incompetence. + Aortic stenosis (slight)

Note: calcification of mitral valve.

Right ventricular enlargement ++.

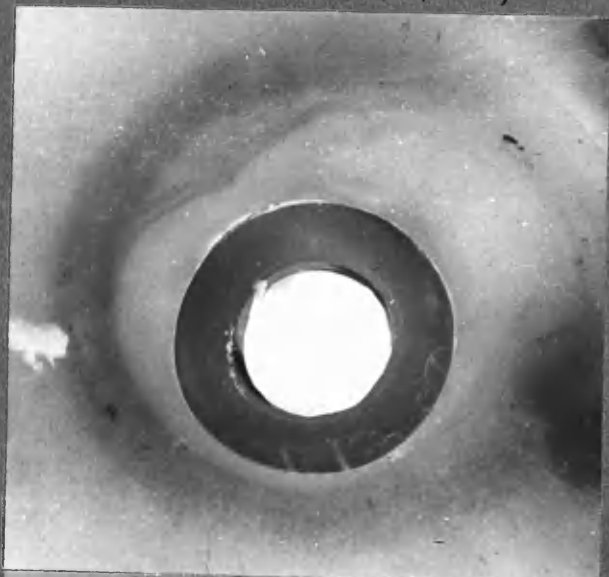
Left " " +

Left atrial " ++

Healthy coronary arteries - calibre somewhat narrow in relation to heart size. It is of interest that a pericardial flap was inserted through ant. and post. walls of L. Vent. the day before death and yet leakage during injection was negligible.

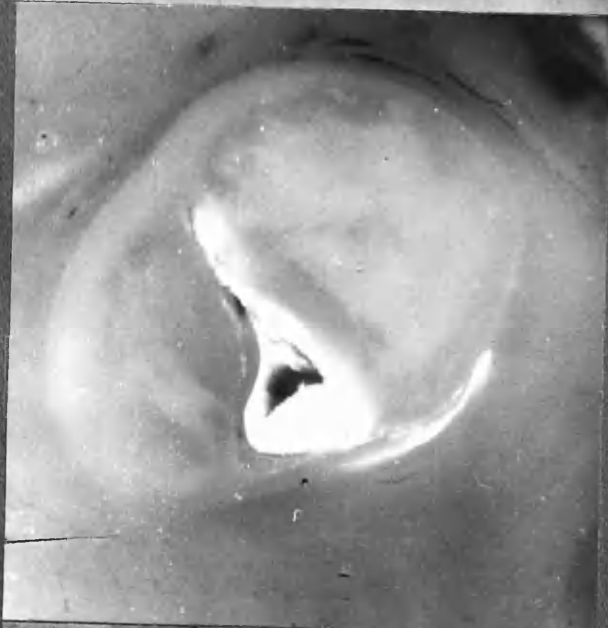21 LC-ADA

Photographs of serially mounted 2 mm. thick sections of isolated coronary arteries.



"Polythene" cannula sectioned in situ.

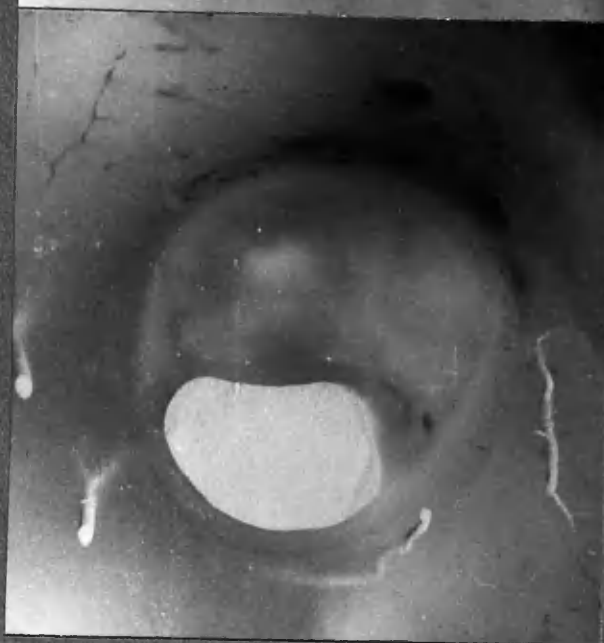1:3b.



Lumen reduced to a narrow slit - old lesion. Upper limit of clot embedded in injection mass - which is white, from LC cannula.

1:4 b.

← 1:5b - micro.



Injection mass Red (grey in photograph) from RC cannula.


1:6 b.

X 15

NOTE: In distinction to sections mounted opposite arteriograms between chapters 7 & 8, which are correctly orientated according to a formal plan, sections 1:4b and 1:6b would require anti clockwise rotation through 90°.

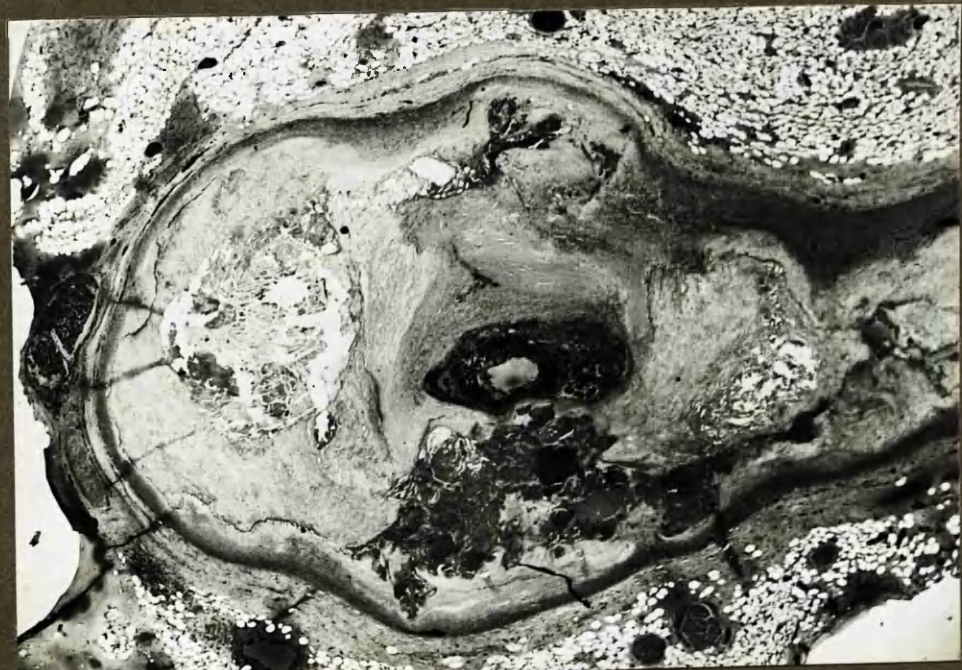

LC - white injection mass.



x 3 3/4

Enlarged Stereocarteriogram of isolated, decalcified LC-upper ADA, Case 21. Cannula in LC almost in contact with complete occlusion of LC: previous narrowing had reduced the lumen to <1mm. in diameter. Terminally (2-4 days before death) the narrow lumen was blocked by a short plug of thrombus. See 2mm. thick sections (opposite) and photomicrograph through block 1:5. (below).



LCxA

21 LC-ADA 1:5 micro. H+E.

x 18

Section through distal portion of thrombotic occlusion; at this level the previous lumen measured 1.4 x 0.5 mm. in diam. To the left side of the section is an atheromatous abscess and in the lower part is massive "fibrinoid".





# CHAPTER 3

NOTES ON

ANATOMY

NOTES

on the

ANATOMY OF THE CORONARY ARTERIES

Page 3 :

INTRODUCTION	1
ANATOMICAL DISTRIBUTION	
MAIN STEMS	2
CORONARY ARTERY BRANCHES	6
EXTERNAL DIAMETERS AND LUMEN DIAMETERS of injected coronary arteries.	9
ANATOMICAL FEATURES IN THE LOCALIZATION OF ATHEROSCLEROTIC LESIONS.	
(1) EPICARDIAL OR INTRAMURAL SITE	14
(2) ANCHORING TO THE HEART WALL	19
(3) INFLUENCE OF BRANCHING	21
Influence of diminished calibre resulting from branching.	21
CHANGES IN THE VASCULARITY OF THE RIGHT VENTRICLE WITH AGE	24
NOTE ON HEART VALVES	26
TABLES 3:2 - 3:9	27
SUMMARY	32

-----

Illustrations not placed with the text are to be found in a group at the end of the chapter.



## CHAPTER 3

NOTES ON THE ANATOMY OF THE CORONARY ARTERIES

From the material made available in this investigation one would be enabled to write yet another original description of the anatomy of the coronary arteries of man. I do not propose to do so. My own observations of anatomical nature broadly confirm the accounts given in standard textbooks of anatomy, and the classical descriptions of Spalteholz, Gross, Crainicuanu, Mönckeberg and Campbell.

In this chapter I offer merely a few comments on anatomical aspects of the coronary arteries which seem to have, or have been thought by others to have, some practical relevance in ischaemic heart disease.

This chapter is the last to have been written. A number of topics which might appropriately have been placed under the heading of anatomical aspects have already found themselves a lodging in other chapters of this thesis. In particular, the anatomy of arterial anastomoses in the heart is dealt with in Chapter 4.

In writing this chapter I have also felt the need for brevity in view of the dimensions of the other chapters. Accordingly the topics mentioned have been treated almost in summary fashion.

ANATOMICAL DISTRIBUTION OF THE CORONARY ARTERIES

(1) MAIN STEMS

In some respects, accounts of the coronary arteries in textbooks of anatomy are misleading. The standardised description usually given of their distribution implies, by default, a conformity of pattern which does not exist.

The lesson which needs to be stressed is the great diversity of configuration in the normal anatomy of the coronary "tree". This point was made by Gross in 1921, emphasised by Campbell in 1929 and has received comment from several authors.

I have regarded the blood supply to the heart through 3 main vessels: Right Coronary artery, Anterior Descending artery and Left Circumflex artery (abbr. RC, ADA and LCxA ). Occasionally the two latter arteries arose separately from the aorta. Usually they arose from a short left coronary artery (main stem). I found the dimensions and course of the anterior descending artery the most constant of the three. The course of the right coronary artery was also fairly constant as far as the posterior inter-ventricular groove, but its subsequent course and its dimensions were highly variable. The left circumflex artery and the main branches of the other two arteries showed a wide range of course and calibre.\*

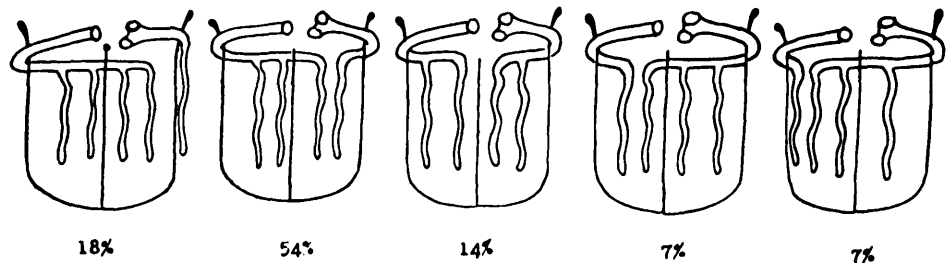
The division of the coronary arteries into right and left suggests an equality which is false. The anterior descending artery alone supplies about

---

\* see DIAGRAMS OF THE CORONARY CIRCULATION, Chapter 2, and arteriograms of the intact heart, in this chapter and elsewhere (e.g. Fig.3:1-5. Fig. 6:1 shows a coronary tree which conforms closely to the standard textbook description.)

half the muscle bulk of the left ventricle. It must be rare therefore for a coronary circulation to be other than left predominant in this sense.\* The proportionate supply of the remainder of the left ventricle by the left circumflex and right coronary arteries has however received rather more attention, because of the interesting variations of coronary artery distribution to the posterior walls of the heart.

Thus, Campbell (1929) analysed his series of 100 injected hearts with the following variants of distribution:




---

Campbell, 1929

My own findings in regard to the distribution of the main stems to the posterior surface of the heart appears in Table 3:1.

---

\* Moreover occlusion of the anterior descending artery was the most lethal of the obliterative lesions encountered in this series (see Chapter 5).

Table 3:1

THE SO-CALLED "BALANCE" OF CORONARY ARTERY DISTRIBUTION				
GROUP	Number of Cases			Whole Group
	R+	R=L	L+	
I. Normal	7	1	4	12
II. Nearly Normal	2	2	1	5
I + II	9	3	5	17
III Non-coronary heart disease.	9	5	3	17
IV Coronary artery disease.	11(13)	9(7)	5	25
TOTAL	29	17	13	59
APPROX. PERCENTAGE	50%	30%	20%	
Campbell, 1929	72%	14%	14%	100
Schlesinger, 1940	48%	34%	18%	225

Note:

- (1) These figures refer solely to the balance of distribution of right and left circumflex arteries to the posterior walls of the heart, and do not take into account the relative importance of the anterior descending artery, and therefore of the left coronary artery distribution as a whole.

R + : Right coronary artery takes significant part in the blood supply to the posterior left ventricular wall.  
R=L : Right coronary artery supplies the posterior part of the interventricular septum and the interventricular groove.  
L + : Left circumflex coronary artery supplies the posterior part of the interventricular septum, the interventricular groove and sometimes posterior wall of the right ventricle.

- (2) Two cases in which the right coronary artery made slight contribution to the posterior left ventricular wall have been classed as "R=L", hence figures in brackets.

My own findings as tabulated merely reinforce the need for recognition of the variability of distribution of the coronary arteries. I do not however attach much importance to the collective data on this topic. It is sufficient to recognise that the variation is so great that detail of distribution has importance only in the context of the individual case.

Further, while there is no doubt that in certain circumstances a particular variant of distribution may have far reaching significance for the outcome in obliterative coronary artery disease, position of the obstructive lesions in relation to it is of first importance.

Thus, occlusion of a large right coronary artery was nearly fatal in Case 4 and was fatal, with rupture of the posterior left ventricular wall, in Case 9. By contrast, occlusion of an anatomically small right coronary artery, which took no part in the blood supply of the left ventricle, caused no detectable myocardial damage (Case 2).

On the other hand, right coronary artery occlusion was survived in Cases 7,10,11,12 and caused only slight to moderate myocardial damage notwithstanding the coronary circulation in these cases was "Right Coronary predominant".

The outcome of coronary occlusion does not depend simply on the anatomical size of the artery in question but, more importantly, on the patency or obliteration of the other major branches and the degree of communication between them.

It has been suggested that the case with left coronary artery predominance is at greater risk of death from coronary occlusion than one with a more balanced circulation. This depends entirely on the site of occlusion. Clearly, occlusion of the left coronary main stem itself could be disastrous in these circumstances but this was a relatively uncommon event in my series.

Of the 5 cases with left coronary predominance in my series of coronary artery disease, the condition was possibly a disadvantage in 3 (5,8,11); in case 15 it was of no account; and in case 2 it was a pronounced advantage at the time of first occlusion.

(Reference may be made to the diagrams of the coronary circulation in Chapter 2, and to arteriograms of the intact hearts.)

(2) CORONARY ARTERY BRANCHES.

My own observations confirm the detailed descriptions of Spalteholz, Gross and Campbell. In particular I confirmed the course taken by vessels through the walls of the right and left ventricles supplying the interventricular septum, and the anatomy of the subendocardial plexus of the left ventricle, (see Chapter 4). I did not note distribution of small vessels in the left ventricle in a fashion which would suggest conformity with the distribution of muscle bundles. (Lowe, 1939, Robb and Robb, 1942, and Wartman and Souders, 1950).

As with the major coronary arteries, I consider there is little to be gained by standardised description of the branches. A glance at the 26 diagrams of the coronary circulation in Chapter 2 will serve to convince that the variation is tremendous. I was surprised that in an otherwise critical paper, Saphir et al. (1935) should have been content to relate their findings to a standardised modification of Spalteholz's diagram of the coronary circulation, a specimen of which is placed on page 3:8 I doubt that they could have done so had arteriography been included in their investigation.

A deep branch to the right ventricle

I confirmed Campbell's observation that a branch of considerable dimensions not infrequently arose from the anterior descending artery and traversed the interventricular septum to join the deep arterial plexus of the right ventricle (e.g. Case 16, stereo, Fig. 6:2. It is also illustrated in the diagrams of the coronary circulation, Chapter 2, in 10 instances.) Sometimes this vessel was in fact the continuation of the first main septal

branch. The relationship of ischaemic myocardial damage in the trabeculae carneae and interventricular wall of the right ventricle to occlusion of the anterior descending artery is discussed in Chapter 5 (page 5:52 and Table 5:2). It may be correlated with the distribution of the septal branches.

#### Accessory right coronary artery

I confirmed Schelsinger's finding that one or more small arteries supplying the anterior wall of the right ventricle frequently had separate origin from the right sinus of Valsalva (accessory right coronary arteries), (conus artery, Schlesinger 1938, 1949). It was not necessary to cannulate these vessels separately, for of course they filled well in retrograde fashion; sometimes however giving rise to troublesome leakage (see Table 3:2).

#### Posterior arterial supply to the right ventricle

I did not confirm Schlesinger's observation that : "Even in normal hearts there is a consistent absence of large vessels over a small area in the posterior walls of the right ventricle near its base". For want of a better explanation I am inclined to regard this finding as a defect of filling. Nor did I find infarcts to be "very rare in this region", (Schlesinger, 1938).

Various points in the distribution and intercommunication of the small branches of the coronary arteries are dealt with in much greater detail in Chapters 4 and 5.

---

(See Diagrams of coronary circulation, Chapter 2, Cases 6,9,11,12, 13,15,16,17,19, N<sup>1</sup>16)

Spalteholz (1924) and Campbell (1929) made a special study of the distribution of atrial vessels, and Campbell described the arterial supply to the region of the conducting system in detail.

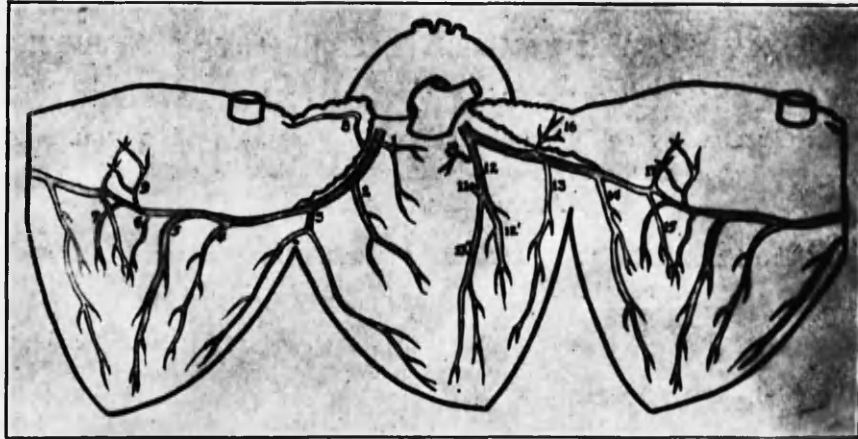


Fig. 1.—The distribution of the coronary arteries as found in 80 per cent of adult human hearts (over thirty years of age). (Adapted from Spalteholz.)

Branches of the Right Coronary Artery:

1. Arteria adiposa dextra.
2. Ramus ventriculi dextri anterior.
3. Ramus marginis acuti.
4. Ramus ventriculi dextri posterior.
5. Ramus sulci longitudinalis posterioris.
6. Ramus ventriculi sinistri posterior.
7. Ramus ventriculi sinistri posterior accessorius.
8. Ramus atrialis dexter anterior.
9. Ramus atrialis sinister posterior.

Branches of the Left Coronary Artery:

10. Arteria adiposa sinistra.
11. Arteria septi ventriculorum.
12. Ramus collateralis descendens anterior.
- 12'. Ramus primus. 12''. Ramus secundus.
13. Ramus ventriculi sinistri anterior.
14. Ramus marginis obtusi.
15. Ramus ventriculi sinistri posterior.
16. Ramus atrialis sinister anterior.
17. Ramus atrialis sinister posterior.

Saphir et al., 1935



## STEREOSCOPIC RADIOGRAPHY OF THE CORONARY SYSTEM

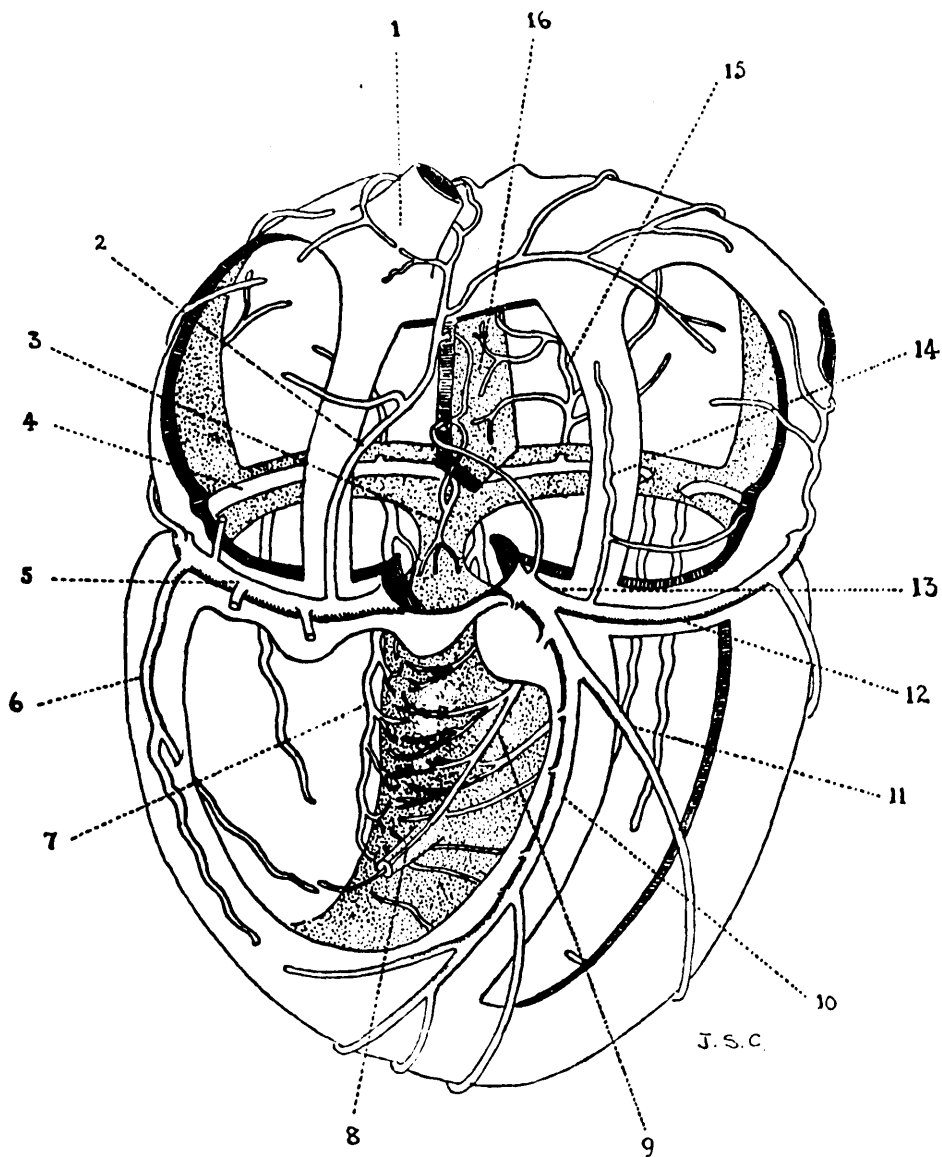


FIG. 2. 1, superior vena cava; 2, ramus ostii cauae superioris; 3, ramus septi fibrosi; 4, circumflex branch, right coronary; 5, right coronary artery; 6, ramus lateralis; 7, ramus descendens posterior; 8, artery in moderator band; 9, anterior septal vessel; 10, ramus descendens anterior; 11, ramus marginalis; 12, circumflex branch, left coronary; 13, left coronary artery; 14, ramus atri sinistri anterior; 15, ramus atri sinistri posterior; 16, interatrial septum.

Campbell, 1929.

EXTERNAL DIAMETERS AND LUMEN DIAMETERS  
OF INJECTED CORONARY ARTERIES

It is scarcely necessary to point out that arteriography indicates only the calibre of the lumen; and that in the presence of coronary artery disease the dimensions of the injected lumen bear little relationship to the external diameter of the artery. The right coronary artery in Case 7 was dissected after injection with demonstration of this point in mind (Fig: 3:7). Further detail of this relationship may be appreciated in the transparent over-drawings mounted with the enlarged stereoarteriograms, which are to be found between Chapters 7 and 8.

It occurred to me that the calibre of the coronary arteries might show enlargement - or diminution - under certain circumstances, for instance in relation to heart size. Accordingly I measured the maximum dimensions of the injected lumen of anterior descending artery in the control series (choosing that artery because it showed the least variation of the three). Detail appears in the tables placed for reference at the end of the chapter.

It was evident that while the largest calibres were to be found in the largest hearts, the variation in calibre was so great that overall there was only a slight increase in lumen diameter with increasing heart size. The difference between the arterial lumen diameters in normal and grossly enlarged hearts was far less than the differences which were found within each group (Table 3:3).

There was rather more correlation between dimensions of the anterior

GENERAL PRINCIPLES OF ANATOMY  
OF THE HEART

The heart is a muscular organ that pumps blood throughout the body. It is located in the chest, between the lungs, and is surrounded by a protective sac called the pericardium. The heart is divided into four chambers: the right and left atria and ventricles. The right atrium receives blood from the body, and the right ventricle pumps it to the lungs. The left atrium receives blood from the lungs, and the left ventricle pumps it to the rest of the body. The heart is a complex organ with many intricate details, and its function is essential for life.

It is important to understand the structure and function of the heart in order to diagnose and treat heart disease. The heart is a complex organ with many intricate details, and its function is essential for life. The heart is a complex organ with many intricate details, and its function is essential for life. The heart is a complex organ with many intricate details, and its function is essential for life.

It was noted that the heart is a complex organ with many intricate details, and its function is essential for life.

" ..throughout life there is a constant increase in the total diameter of the coronaries as well as in the diameter of their lumina."

Ehrich et al., 1931 (cited Gould, 1953)

descending branch of the left coronary artery and the distribution of the other arteries. Thus the average lumen diameter of this artery in 18 right coronary predominant cases was 3.85 mm. while in 8 cases with left predominance it was 4.15 mm. (Table 3:4).

However the position was not so simple. In a given heart the diameter of each coronary artery bore a fairly close relationship to the relative size of its territory, and presumably to the relative volume of blood it was accustomed to carry. But there was a marked disparity in the actual lumen diameters of arteries with similar myocardial territories, in different hearts.

In the control series (normal and abnormal) I did not have the opportunity of examining the relationship which hypertension might bear to arterial calibre. Moreover my numbers were too small to allow statistical analysis. A study of the measurements of the anterior descending artery lumen however did not indicate any constant relationship between its calibre and the sex or age of the subjects.

It may have been significant that the lumen dimensions of the three main coronary arteries were all somewhat small in Case D3, in which great cardiac enlargement was the result of severe aortic stenosis.

The outstanding feature was the great individual variation in calibre of the coronary arteries in general, but whether this was related to an inherited factor, to the amount of physical exertion customarily undertaken or to some other factor, I had no means of knowing.

Aneurysm of the coronary arteries is rare. Scott, 1948, recorded 47 cases reported in the literature to that date, of which 6 were due to atherosclerosis. (Prentice and Penfold, 1952)

---

Harrison and Wood, 1949, found that the cross-sectional area of the coronary arteries increases in hypertrophied hearts.

Unfortunately I did not measure the thickness of the arterial intima in control cases. The arteries in these cases were slit open longitudinally and inspected for the presence of atheromatous lesions. Some degree of generalized intimal thickening without lipid deposit may well have been overlooked, and may have contributed to some of the discrepancies in calibre observed.

In the cases of coronary artery disease the restriction of the arterial lumen was of course largely the result of atherosclerotic intimal thickening. Accordingly I measured the diameter of the previous "lumen" from media to media in the serially mounted 2 mm. thick cross sections. In the 19 cases in which such sections were available the mean "lumen" diameter was 5 mm. When allowance had been made for some degree of generalized intimal thickening in the control cases, this probably represented a slight relative increase in the dimensions of coronary arteries in the presence of coronary artery disease. The increase is however unimpressive. It can scarcely be taken to indicate ectasia of the artery wall in this disease. This negative finding may be correlated with the view, which I express in Chapter 8, that the intimal changes are primary and that such stretching of the medial coat, as may sometimes be found, is secondary to massive intimal lesions.

Exceptionally, however, small dilatations of aneurysmal type were to be found in a few cases. (Examples are shown in Fig.3:8,9.) I am confident that these appearances were not artefact, from stretching by the injection mass.

There was some degree of correlation between media-to-media diameter (of the anterior descending artery) and heart weight, in

coronary artery disease, (Table 3:5). Correlation was more striking where cardiac enlargement had evidently resulted from hypertension, (Table 3:6). The latter finding is probably significant. It seemed likely that the coronary arteries shared in the general dilatation of arteries which occurs in hypertension; and that the finding of coronary artery dilatation and atherosclerosis in the same individual did not indicate that they were causally related, but that both features were related to hypertension. Harrison and Wood (1949) noted that most cases of hypertensive heart disease have dilated coronary arteries. It may be noted however that in my series exceptions existed in both directions. The case with the highest known level of blood pressure in the hypertensive coronary disease group showed the smallest media-to-media diameter of the anterior descending artery (Case 19).

It may also be noted in passing that post-stenotic dilatation of the coronary arteries was not observed.

It has been suggested that the narrowing of a coronary artery which may sometimes be observed distal to occlusion indicates an inherent hypoplasia of the artery in question. This appearance was notable in some arteriograms (e.g. Cases 6,11,18,19,20). On this point I made the following observations:

- a. This appearance was never seen in control cases.
- b. In some instances the appearance was due to extensive infarction which had impaired retrograde filling beyond the occlusion (e.g. Case 2).

- c. In 7 instances the narrowing of the lumen was due to atherosclerotic intimal thickening, and this was probably the explanation in 4 others.
- d. In 2 there was narrowing of the lumen without atherosclerosis. (cases 17,20) at the point in question. These examples could be interpreted as instances of inherent hypoplasia. Or could it not be that the arteries had dwindled in size distal to occlusion through disuse?



ANATOMICAL FACTORS IN THE LOCALISATION OF  
ATHEROSCLEROTIC LESIONS

1. EPICARDIAL OR INTRAMURAL SITE.

It is obvious that the main branches of the coronary arteries lie on the surface of the heart. It would seem however that preoccupation with detail of the anatomical distribution of these arteries, and with the sites of occlusion in them, has overshadowed the significance of their epicardial as opposed to intramural course. And yet my own observations leave me with little doubt that this accident of anatomical position is the factor above all else which determines the presence or absence of atherosclerotic disease of the coronary arteries.

It required no analysis of findings but only observation case by case to reach the conclusion that atherosclerotic disease was almost restricted to the coronary arteries which lay on the surface of the heart. As soon as the course of an artery carried it deeply into the myocardium it acquired as it were an immunity from this disease. Exceptions to this rule were few, and were always explicable on the grounds of extension of the process on the surface for a short distance (a few mm.) into the intramyocardial portion of the artery. (Such extension was in keeping with a thrombotic origin of the lesions.)

In some instances it was observed that the artery in its epicardial course merely dipped under a bridge of myocardium and later regained the surface.

Examples were to be found in Cases 11 (LCxA main collateral), 23(LCxA), 24 (LCxA) as well as those indicated in Table 3.7. It was sometimes apparent on the arteriograms that stretches of an artery which were bridged by a layer of myocardium were less tortuous and of more even contour than was the case proximal and distal to this point. Such stretches indeed commonly showed normal appearances because they were free from atheroma. This was however not invariably so.

For instance complete occlusion, which had been preceded by atherosclerotic narrowing, of the anterior descending artery in Case 23 actually lay under a bridge of myocardium for the greater part of its length. The myocardial shelf was about 0.5 mm. in thickness (see illustrations between Chapters 7 and 8). It could of course be argued that a thrombotic process starting in the upper portion of the artery might have been propagated distally and so account for atherosclerosis under the bridge of myocardium.

In Case 17 the bridge under which atherosclerosis of the anterior descending artery was found covered only about 1 cm. of the artery. This emphasises the importance of the third dimension in assessing the significance of the findings (see Fig. 3:11). By contrast, the bridge over the same artery in Case 25 was 3-4 cm. in length and no atherosclerosis was found in the stretch of artery covered by it (Fig. 3;10).

The relatively few observations I was able to make suggested that complete investment of the coronary arteries with a definite myocardial layer appeared to confer a striking immunity from atherosclerosis, but

the linear extent and depth of the covering layer were important. Where the course taken by an artery carried it more than one or two millimeters below the surface the immunity was absolute. In only one instance however, in the case of bridging of short stretches of the arteries, was the covering layer more than 0.5 mm. in thickness. It seemed that the protection afforded by such thin layers was less secure and atherosclerosis sometimes was found under their cover.

Geiringer (1951) records that this phenomenon was noted by Spalteholz (1924) and by Crainicianu (1922), but its possible significance in the pathogenesis of atherosclerosis was not pursued. He included under "mural" coronary arteries those which were only partially covered by a bridge of myocardium. He found a much lower incidence of atherosclerosis in the upper  $\frac{1}{3}$  of mural than in epicardial anterior descending arteries; and also that the intima was thicker in the epicardial than in the mural arteries, apart from atherosclerosis.

While my own findings broadly confirmed those of Geiringer I would emphasize the point that protection appeared to be conferred only by complete investment by a layer of muscle tissue of considerable thickness. In no instance did a curtain of myocardium partially drawn across the artery appear to have conferred immunity from atherosclerotic changes. Geiringer's observations were made on unselected micro-sections from the upper  $\frac{1}{3}$  of the anterior descending artery in 100 consecutive autopsies. I had the advantage of being able to follow all the changes above, at the level of, and below the myocardial bridges in the last 16 cases of coronary artery disease. But on the other hand

I did not otherwise make my observations on this point systematically, and in the case of control cases may well have failed to observe thin shelves of muscle tissue. Accordingly I have no contribution to make to the incidence of this condition, which was present in 23 of Geiringer's 100 cases. (In 16 cases I found bridging of the anterior descending artery in 6.)

I found the intimal wall in mural stretches of coronary arteries to be, as a rule, very thin, and comparable to normal intima, even in the presence of widespread atherosclerosis elsewhere in the coronary arteries. Geiringer found that the intima of mural coronary arteries was substantially thinner than in the epicardial arteries, and stresses this point in relation to the tendency for atherosclerotic development to occur in the latter. He regarded 0.35 mm. as a critical depth for coronary arteries in this context. My own findings on this point are recorded and discussed in Chapter 8 (page 8:61). It should be appreciated that the thickness of the intima which has been stretched by injection medium is considerably less than in the unsupported artery, so that the findings in the two series are not comparable.

While the influence of the intramural position in preventing atherosclerosis is undoubtedly profound, the mechanism by which this factor operates is arguable. I incline to the view that it may be related to the lesser gradient of pressure during systole between the lumen and outer coats resulting from the coincident compression of the surrounding muscle layers. Whether this is a matter of protection from distension or reduction in filtration pressures, or both, is also

uncertain. It may also be related to lesser shearing strains during systole where the artery is splinted in its mural position: whereas, lying unsupported on the epicardial surface, some degree of kinking and buckling accompanies each pulsation and cardiac contraction. In this connection it may be noted that the internal mammary artery never showed atherosclerotic change in the subjects which I have examined.

Geiringer concludes with the following paragraph:

"It is a melancholy reflection that a shift of a few millimeters in the anatomical course of the main coronary branches would have resulted in practical immunity from the most common form of coronary vascular accident, that is, atherogenic thrombosis. This reflection gains a certain piquancy through the investigations of Chase and Garis who found that while the gorilla and gibbon have an epicardial network of main coronary arteries, the coronary arteries of the chimpanzee and, to a lesser extent, of the orangutan tend to run a mural course. Using an outmoded form of expression, it would seem that, in this respect at any rate, we are descended from the wrong type of ape."

In regard to intimal thickening, passing reference may be made to the finding of a thicker intima in the coronary arteries of male infants by Fangman and Hellwig (1947), confirming observations by Dock (1946).

## 2. ANCHORING TO THE HEART WALL

No matter what may be the true aetiology of atherosclerosis it is evident that anatomical or dynamic factors must play a part in determining the localization of the lesions in the heart. For the distribution of coronary atherosclerosis, though widespread and variable, is not entirely haphazard. This is also true for thrombotic occlusions in the coronary tree. In Chapter 5, I indicate the manner in which these lesions were widely distributed along the right and left circumflex coronary arteries, whose course lies in the atrio-ventricular groove; whereas the lesions in the anterior descending artery, running at right angles to the other two, showed a greater tendency to localization.

Commenting on the site of severe atherosclerotic lesions, Saphir et al. (1935) "found the involvement confined mostly to an area approximately 1 cm. in length beginning about 2 cm. from the point of origin of the descending branch." These authors support their own findings by similar observations by Mönckeberg (1924), Kirch (1927) and Levine and Brown (1929). I found that thrombotic occlusion was to be found most commonly in this artery 2-4 cm. from the left coronary ostium, which corresponds closely to the findings of others. Why there should be this localization seemed to demand enquiry.

Roberts (1945) tried to explain this localization on grounds of mechanical stresses, anatomically determined by the length of the coronary "neck". He contended that the maximum stress fell upon the anterior descending artery just before it became anchored to the

myocardial surface by the first main septal artery. This portion of the artery he referred to as the "pathological neck", and found a greater degree of coronary artery disease at this point in cases where the pathological neck was short. (He further suggested that short and long "necks" might be hereditary factors.)

I felt there might be some significance in these observations. Accordingly I examined my own material from the point of view of (1) anatomical variation in the lengths of the left coronary artery, main stem ("anatomical neck") and of the anterior descending artery from the bifurcation to origin of the main septal artery ("pathological neck"); (2) the relationship of the most proximal evidence of severe atherosclerosis to the point of origin of the main septal artery.

My findings appear in Tables 3:8,9.

From Table 3:9 it may be seen that in 13 out of 20 instances, severe atherosclerosis may have developed in relation to the site of origin of the first main septal branch of the anterior descending artery. Scrutiny of individual examples supported this point of view. It seemed that the anatomical site of origin of the first main septal artery was the main factor determining the distances from the left coronary orifice and bifurcation at which severe atherosclerosis is encountered most frequently. At the same time it was noted that similar lesions in many instances occurred proximal and distal to the immediate neighbourhood of the main septal artery. The localization of the latter lesions must have been otherwise determined. The question is further discussed in Chapter 5.

"Wolkoff ... maintained that the point of division of the smaller branches and, more commonly, those portions of the walls of vessels which are directly attached to the myocardium are the sites of predilection".

(Saphir et al. 1935)

### 3. INFLUENCE OF BRANCHING

I confirmed that thrombotic occlusion tended to commence near a point of bifurcation or origin of a branch and to extend to a point where another branch of considerable size was given off, or bifurcation took place (Winternitz, 1938). A glance at the diagrams of the coronary circulation, Chapter 2, will support this statement, which is substantiated in greater detail in Chapter 7. There were not infrequent exceptions.

To some extent the distribution of atherosclerosis conformed to this pattern, which is not surprising if the lesions in questions were thrombotically determined (see Chapter 8). There were however a great many atherosclerotic lesions whose site could not be related to the origin of branches.

Influence of diminished calibre resulting from branching: Severe atherosclerosis was largely a disease of the main coronary arteries and their major epicardial branches (1st and 2nd division arteries). The major branches were by comparison infrequently involved, but this difference was not so striking as the comparative freedom of the smaller branches from atherosclerosis, save where their origins were



involved in the intimal disease of the parent stems (see Chapter 5).

It may be noted that stenosis of the origin of a small branch in its course within the wall of a large coronary artery may entirely escape notice in the arteriograms. This happens even with magnified stereo-arteriograms where the first part of the branch is directed towards or away from the viewer and the stenosed segment is thereby overlain by the branch itself and by the main artery. Accordingly, were I to re-examine coronary arteries arteriographically with the establishment of the exact incidence of stenosis of small branches in mind, I should take two sets of stereo-pairs for each artery, at right angles to each other. My own statement of findings on this topic, however, combines the findings of stereo-arteriography with the examination of the serially mounted 2 mm. thick sections of the coronary artery main stems (Chapters 2 and 5). Being in the transverse plane, these sections afforded optimum opportunity for the observation and measurement of the origins of small branches.

Examples of various degrees of stenosis of small branch origins may be seen in various sections mounted between Chapters 7 and 8 (e.g. 24 RC.2:8a and 4:16) and in Fig. 3:12.

A slight constriction of the lumen was also observed at the origin of small branches even in normal arteries.

-----

In passing, I may note also that I did not observe any definite preference on the part of atherosclerotic lesions for the side of the artery adjacent to the myocardium, or indeed for any particular point on circumference of the sections, although in some instances there was certainly heavy involvement of the side next to the heart wall.

... ventricles were expanded and a peculiarly ... with the exception that ... in ...

I agree with Martin et al. that the difference in shape ... tissue shadow of the ... as ... vascular density. This matter was of course ... in my preparations. I did not however have sufficient cases in a group to reach ... I would repeat ...

- (1) I did not observe any absolute evidence of diminished vascularity of the right ventricle with age. Nor do I consider that the illustrations by Gross and Kugel (1933) adequately support their conclusions.
- (2) The obliquity of transection of the right ventricle ...

CHANGES IN THE VASCULARITY  
OF THE RIGHT VENTRICLE WITH AGE

In 1921 Gross stated that there appeared to be a decreased vascularity of the right ventricle with increasing years. His observations were made on arteriograms of the whole heart, and were mainly a comparison between the relative vascularity of the right and left ventricles. The issue was not the degree of obstruction which might be found in the right coronary artery itself.

His contentions were challenged by Ehrich et al. (1931) and by Whitten (1930a). The original position was again defended by Gross and Kugel (1934). In the latter investigation cross-sections of the ventricles were employed with appearances very similar to my own - with the exception that the radiography was carried out in air, not with immersion.

I agree with Ehrich et al. that the difficulty in allowing for the tissue shadow of the ventricles invalidates an impression of altered vascular density. This matter was of course overcome in my own preparations. I did not however have sufficient cases in each age group to reach firm conclusions. I would merely make three points:-

- (1) I did not remark any absolute evidence of diminished vascularity of the right ventricle with age. Nor do I consider that the illustrations by Gross and Kugel (1934) adequately support their conclusions.
- (2) The obliquity of transection of the right ventricle invalidated any comparison which may be made in regard to vascular density in 2 dimensional radiographs.

(3) Gross implies that in old age the right ventricle suffers from ischaemia, and that failure of that chamber in the elderly is so conditioned. It will be evident from examination of the transventricular sections with which Chapters 4 and 6 are illustrated that cardiac ischaemia induced by stenosis or occlusion of the main stems is reflected in a great increase in the vascular density of small vessels of the myocardium, the converse of what Gross would suggest; although it must be allowed that this change is much more prominent in the left ventricle.

I regard the point as unproved either way, and the controversy somewhat nonsensical.

I include an enlarged transventricular section from the heart of a woman of 80 years, the oldest in my series (Fig. 3:13).

It was however evident that increase in thickness of the wall of the right ventricle, in the presence of mitral valve lesions in Group III cases, was accompanied by increase in the arterial tree supplying it, as might be expected (see, for instance, Fig. 4:49). As indicated in Chapter 4, the increase in arterial vascularity involved also increased prominence of the subendocardial plexus of the right ventricle.

### HEART VALVES

Not uncommonly injection medium outlined a network of arterial vessels in the upper portion of the aortic cusp of the mitral valve, where that valve was the seat of post-rheumatic endocardial damage. An example is shown in Figure 4:34. Uncommonly traces of injection medium were found in the upper portion of this valve, in the absence of obvious pathological change. In Case D 13 quite marked injection was found (Fig. 4:35). I did not succeed in injecting vessels in any valve cusp other than the aortic cusp of the mitral valve.

The vasculature of heart valves was investigated by Ritter, Gross and Kugel (1928). These workers found injectable vessels in valves in 123 of 700 hearts, and in 14 instances the valves appeared normal.

"... this is not a mere academic question. If they are non-inflammatory in origin, they may have something to do with lesions which occur in the valves. If they follow inflammatory disease of the valves, they are largely of interest pathologically, and have no practical importance."  
Gross, 1928

See also Wearn, 1936, Am. Heart J. 11:22.  
Kulitsky, 1946. Am. J. Path. 22:351

Table 3:2

ACCESSORY RIGHT CORONARY ARTERY:		INCIDENCE	
		<u>No.</u>	<u>Approx. %</u>
GROUP I,II	(17 cases)	11	65%
" III	(17 " )	12	70%
" IV	(25 " )	15	60%
<b>Total:</b>	<b>(59 cases)</b>	<b>38</b>	<b>64%</b>

Table 3:3

ANTERIOR DESCENDING ARTERY DIAMETER IN RELATION TO HEART WEIGHT (34 control cases)							
Heart weight in gm.	-200	200- 290	300- 340	350- 410	420 -490	500 -790	800+
Mean lumen diameter in mm.	3	3.8	4.1	3.9	3.6	4.1	4.2
No. in each column	1	5	5	4	8	8	3

Table 3:4

DIAMETER OF ANTERIOR DESCENDING BRANCH OF LEFT CORONARY ARTERY IN LEFT AND RIGHT CORONARY PREDOMINANCE (34 control cases)			
Balance of coronary artery distribution	R+	R=L	L+
Mean lumen diameter in mm.	3.85	4.24	4.17
No. in each column	18	8	8

Note 3:4 : The figure for R=L group was increased by one case with unusually wide coronary arteries (case N'13, lumen diameter of 5.5 mm). The mean for the other 7 cases was 4.06 mm. lumen diameter.

Table 3:5

MEDIA-TO-MEDIA DIAMETER IN RELATION TO HEART WEIGHT Anterior descending artery only. Coronary artery disease, 19 cases				
No. in sub-group	3	10	6	Total group
Heart weight in gm.	350- 410	420- 470	595- 610	350- 610
Mean diameter in mm.	4.0	5.1	5.3	5.0

Table 3:6

MEDIA-TO-MEDIA DIAMETER IN RELATION TO HYPERTENSION Anterior descending artery only. Coronary artery disease, 19 cases			
No. in sub-group	12	7	Total group
	No evidence of hypertension other than heart weight.	Evidence of hypertension in addition to heart weight.	
Mean diameter in mm.	4.7	5.43	5.0

Table 3:7

MYOCARDIAL BRIDGES OVER PROXIMAL HALF OF ANTERIOR DESCENDING ARTERIES: with relation to ATHEROSCLEROSIS. 16 cases of coronary artery disease			
Bridge of myocardium.	Case No.	Thickness of bridge in mm.	Atherosclerosis under bridge
COMPLETE	17(1)	0.5	+
	(2)	0.3	-
	19	2	-
	23	0.5	+
	25	0.5	-
PARTIAL	11	-	+
	11 c	-	+
	20	-	+

Note:

- a. There was no myocardial bridge in 10 of the 16 cases.
- b. In case 17 there were two bridges across ADA.
- c. In case 11 both ADA and its main collateral (11c) were partially covered by myocardial bridging.



Table 3:8

MEASUREMENT OF "ANATOMICAL AND PATHOLOGICAL NECK" OF ANTERIOR DESCENDING ARTERIES				
length in cm.	0-0.9	1 +	2 +	3 - 4
<b>A. OSTIUM TO BIFURCATION OF L.C.</b>				
Group I and II (17 cases)	15	2		
" III (17 " )	15	2		
I,II,III (34 " )	30	4		
IV (24 " )	17	5	2	
I,II,III approx. %	88	12		
IV " %	71	21	8	
<b>B. OSTIUM TO 1st MAIN SEPTAL ARTERY.</b>				
Group I + II (17 cases)		5	7	5
III (17 " )	1	1	8	7
I + II + III (34 cases)	1	6	15	12
IV (24 " )		4	12	8
I,II,III approx. %	3	17	44	36
IV " %		16	48	32
<b>C. BIFURCATION OF L.C. TO 1st MAIN SEPTAL ARTERY</b>				
Group I + II (17 cases)	2	8	6	1
III (17 cases)	1	6	7	3
I + II + III (34 cases)	3	14	13	4
IV (24 cases)		12	9	3
I,II,III approx. %	9	41	38	12
IV " %		50	38-	12

Table 3:9

DISTRIBUTION OF ATHEROSCLEROSIS IN ANTERIOR DESCENDING ARTERY IN RELATION TO ITS 1st MAIN SEPTAL BRANCH. 24 cases	
Site of most proximal evidence of severe atherosclerosis	No. of cases
a. At the level, or within 2 mm., of 1st septal artery	13
b. Proximal to 1st septal artery	7
c. Distal " " " "	4

Note:

In case 1 there was complete obliteration of left coronary artery and branches by thrombosis, so that the relevant measurements could not be made on the arteriograms. Moreover there was no evidence of underlying atherosclerosis before thrombosis. Accordingly this case is omitted from the series for the purposes of Tables 3:8 and 3:9.

Distribution of atherosclerosis in the anterior descending artery.

Great variation in the extent of atherosclerosis in the anterior descending artery was observed. In some cases the disease was limited to the proximal part of the artery, in others to the distal part, and in still others to the middle part.

External and internal diameters of the anterior descending artery  
examined in relation to coronary artery disease, heart size and other factors. It was seen that the relative calibres of the main divisions of the coronary arteries were in proportion to the relative dimensions of the territories supplied by them.

### SUMMARY

In this chapter a few anatomical features arising from the present investigation have been presented and discussed.

In general, the findings have been confirmatory of the classical descriptions of the arteries of the heart by Spalteholz, Gross, Crainicianu, Mönckeberg and Campbell; and, for the most part, have been in accord with standard textbook accounts.

Distribution of main stems: Recognition of the range of normal variation in distribution of major divisions of the coronary arteries was regarded as of greater importance than any supposed conformity with a hypothetical "normal" pattern. The relative constancy of course and dimensions of the anterior descending branch of the left coronary artery contrasted with the highly variable distribution of the right and left circumflex arteries. The fallacy inherent in dividing coronary circulations into "balanced", and right or left "predominant", on a basis of the distribution of the circumflex arteries alone, has been stressed.

Great variation was likewise found in the detailed distribution of lesser branches.

External and lumen diameters of the anterior descending artery were examined in relation to coronary artery disease, heart size and other factors. It was seen that the relative calibres of the main divisions of the coronary arteries were in proportion to the relative dimensions of the territories which they supplied. There was little evidence that stretching of the

artery wall was a constant or important feature in atherosclerotic disease; whereas there was considerable correlation between artery diameter and cardiac size, particularly where cardiac enlargement had resulted from hypertension.

Conversely, there was no evidence that diseased coronary arteries were hypoplastic. Narrowing of the lumen in the arteriograms was almost invariably demonstrated to be the result of atherosclerotic disease.

Some factors in the localisation of atherosclerosis in the coronary "tree" were examined.

(1) Atherosclerosis was almost restricted to the epicardial arteries. The branches within the myocardium were practically free from intimal thickening or disease. Intermediate features were presented by those portions of epicardial vessels which were covered for short stretches by bridges of myocardium. It was seen that "immunity" from atherosclerotic change was only conferred on these arteries which were covered by a layer of substantial thickness (about 1 mm. or more); and that the protective effects of muscle layers of lesser thickness were inconstant. No protection was observed as the result of incomplete investment. The situation is discussed.

(2) The effects of branching of the arteries on the localization is briefly discussed. It was noted that there was a tendency for atherosclerotic disease, and for occlusion, to affect the anterior descending artery at the level of the origin of its first main septal branch. At this point the main stem was anchored to the myocardial wall. The


significance of this finding is discussed.

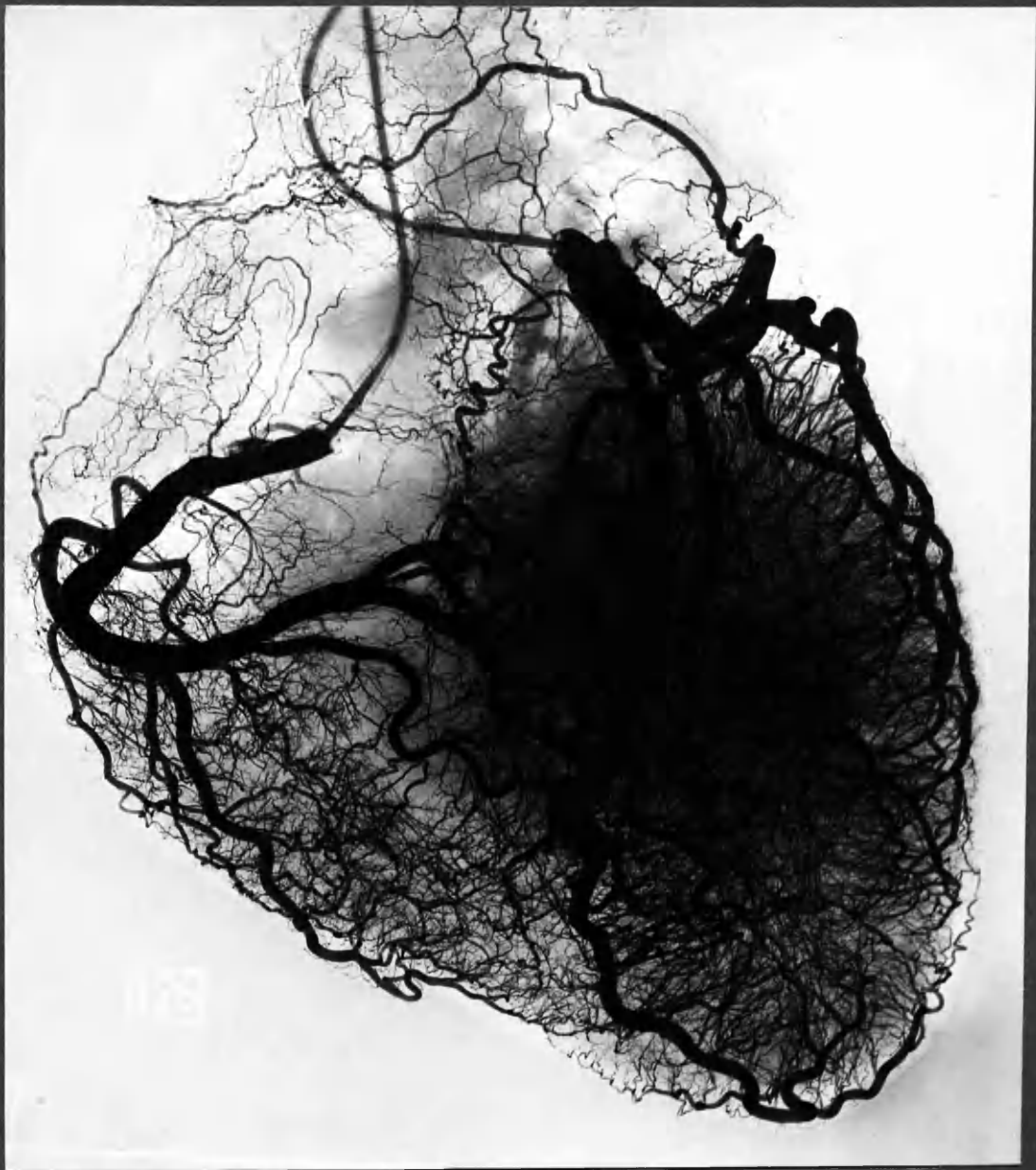
Notes are also included on the vascularity of the right ventricle, in the light of some assertions on this subject in the literature; and on arterial structures in the heart valves.

Anatomical details of small vessels and anastomotic communications between them are described and discussed in detail in Chapter 4.

ILLUSTRATIONS

Chapter 3





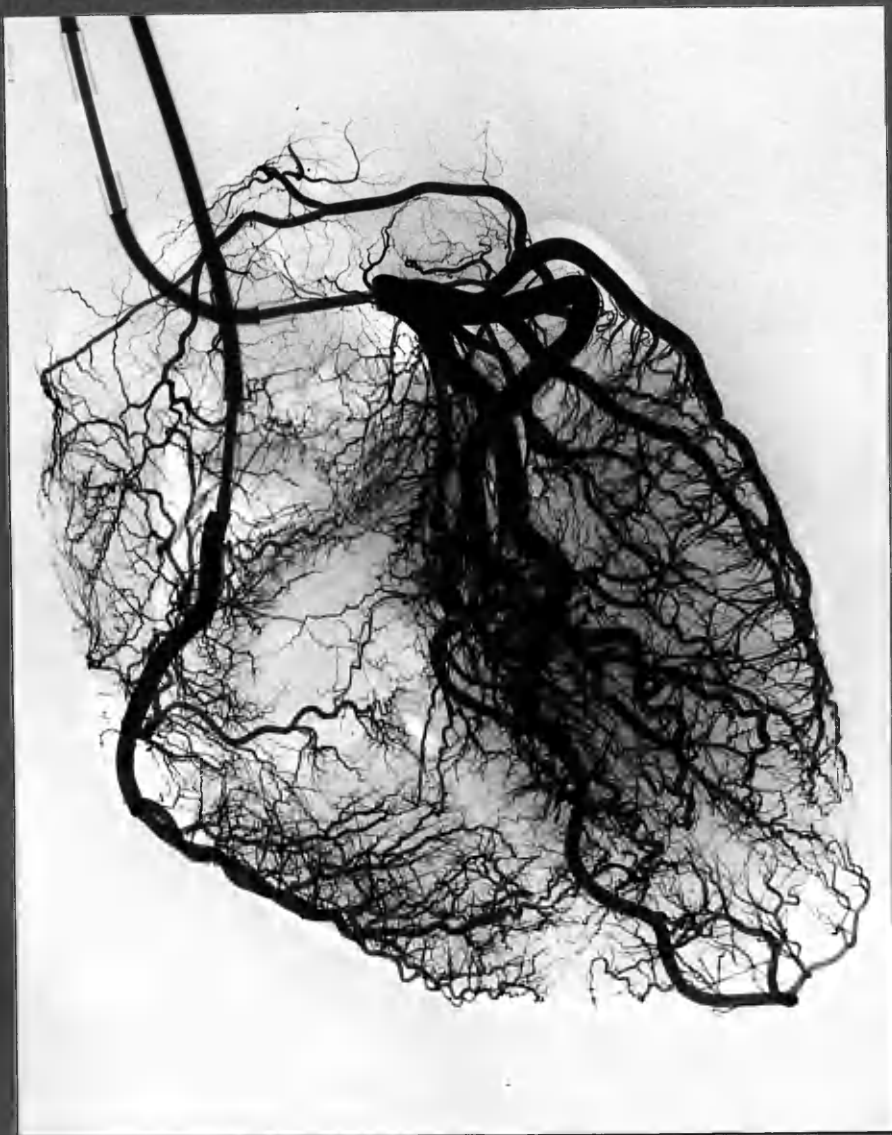
Case D13.

Left ventricular hypertrophy.

"Balanced" coronary circulation. , R=L.

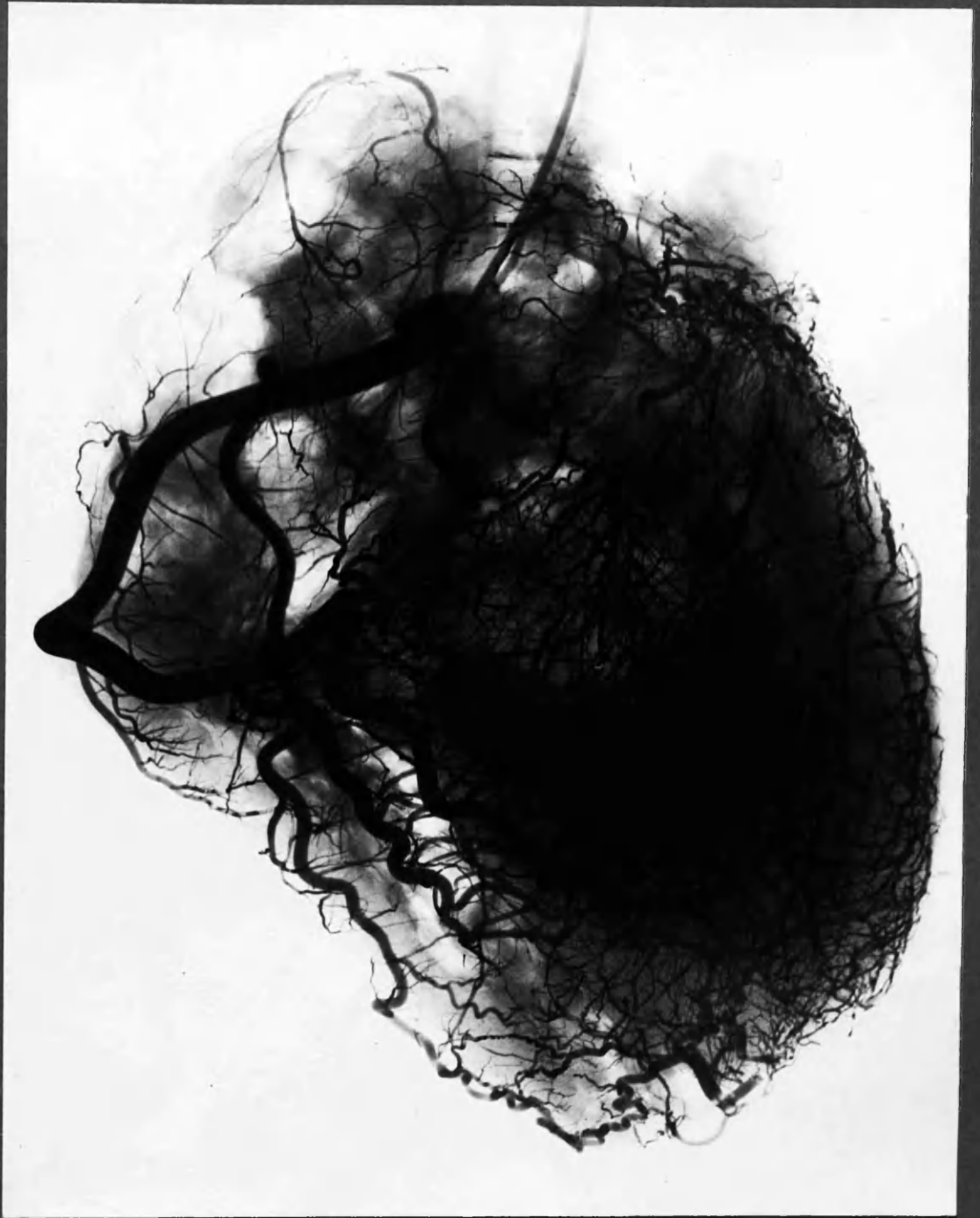Fig 3:2.

Normal Heart. Left coronary predominance , L+  
R. coronary artery supply restricted to Right Ventricle.



Case No. 2





Case 1.

Anatomically "balanced" coronary circulation. Subsequent to obliteration of left coronary artery by thrombosis 7 yrs before death, the entire blood supply to the heart came from the Right coronary artery. With increased blood flow the right coronary artery has increased in calibre.

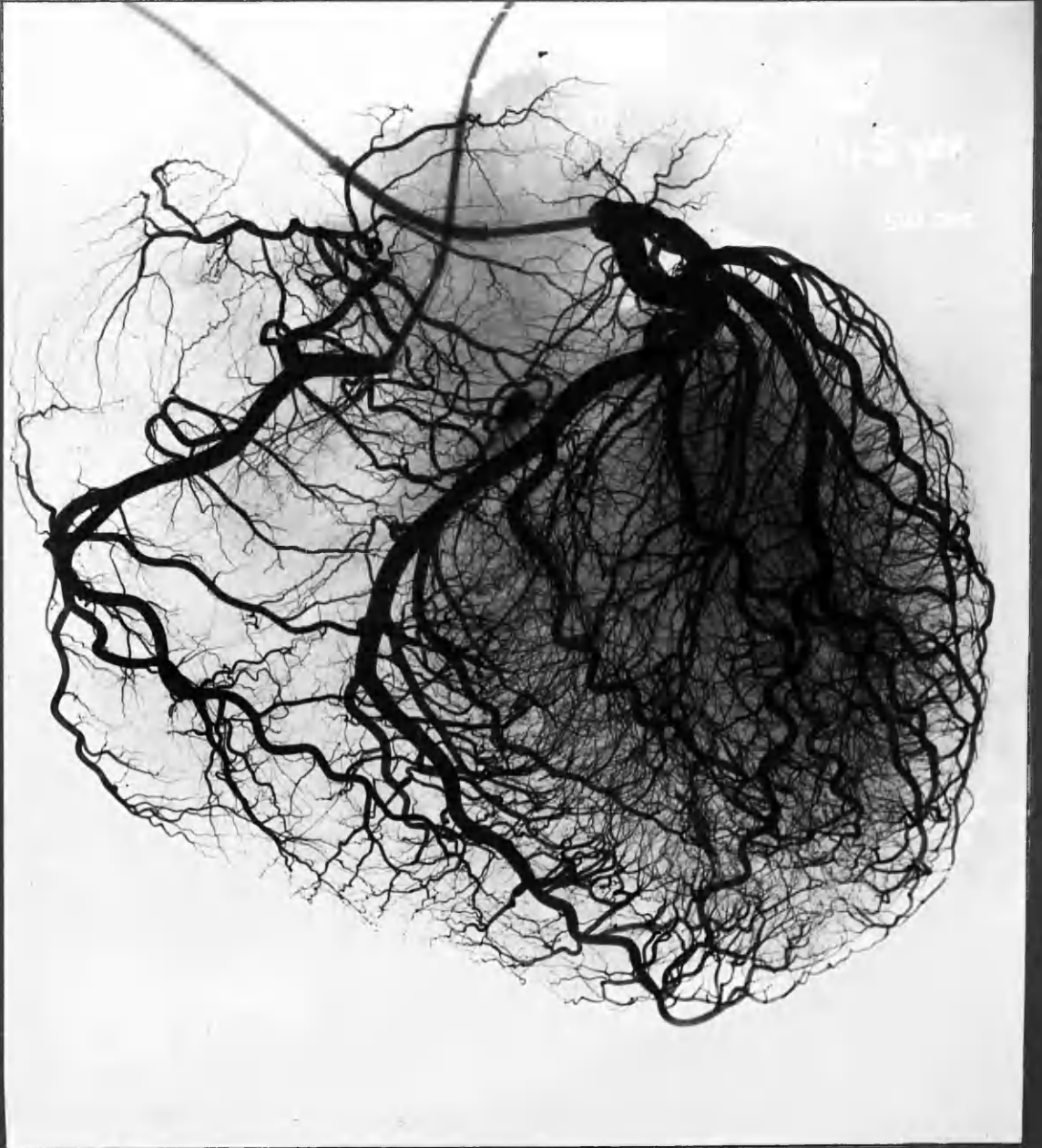
Fig. 3-4



Case D7.

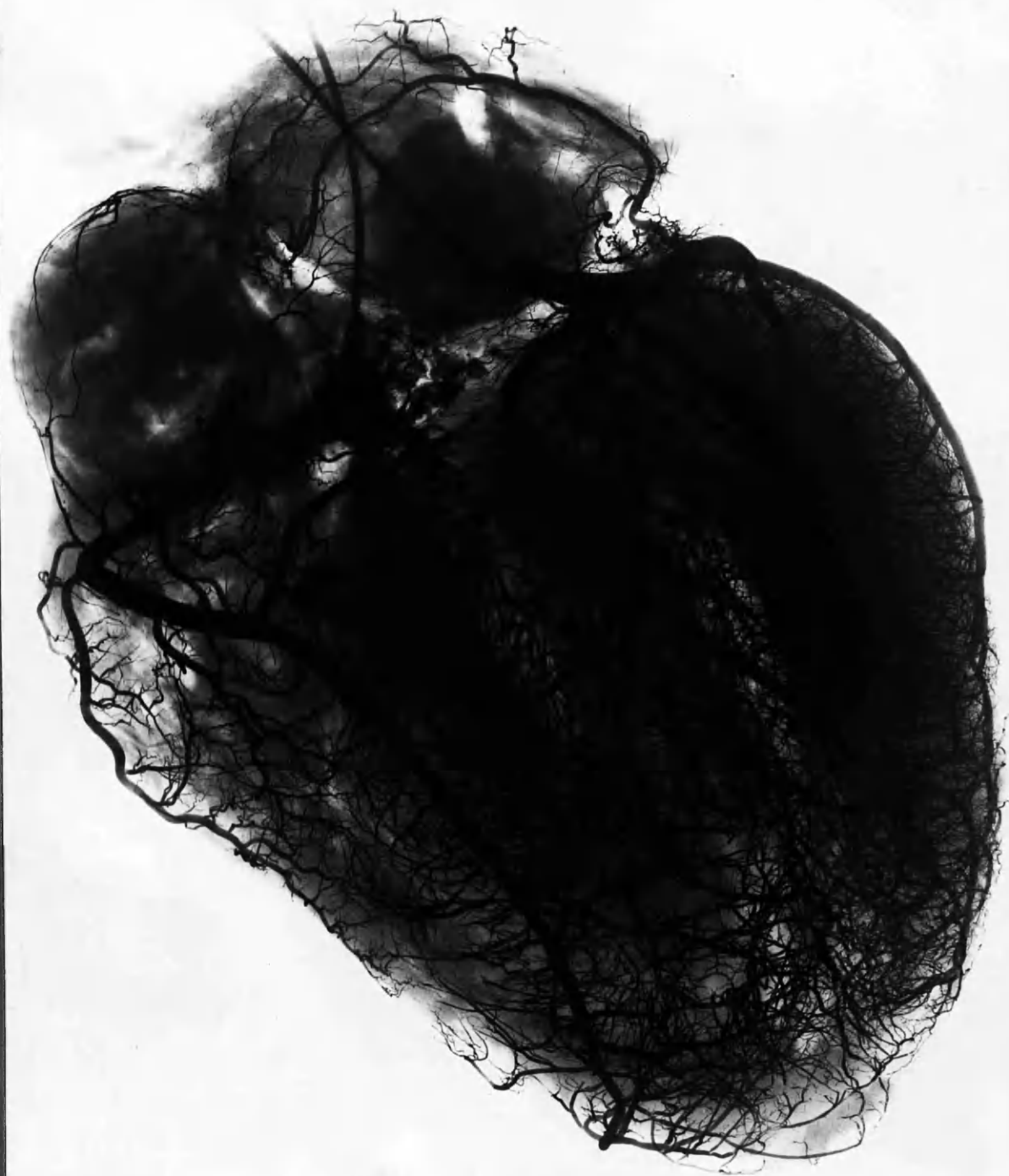Primary pulmonary hypertension, R. vent. enlargement.

R. coronary dominance + increase calibre, with R. vent.  
hypertrophy.



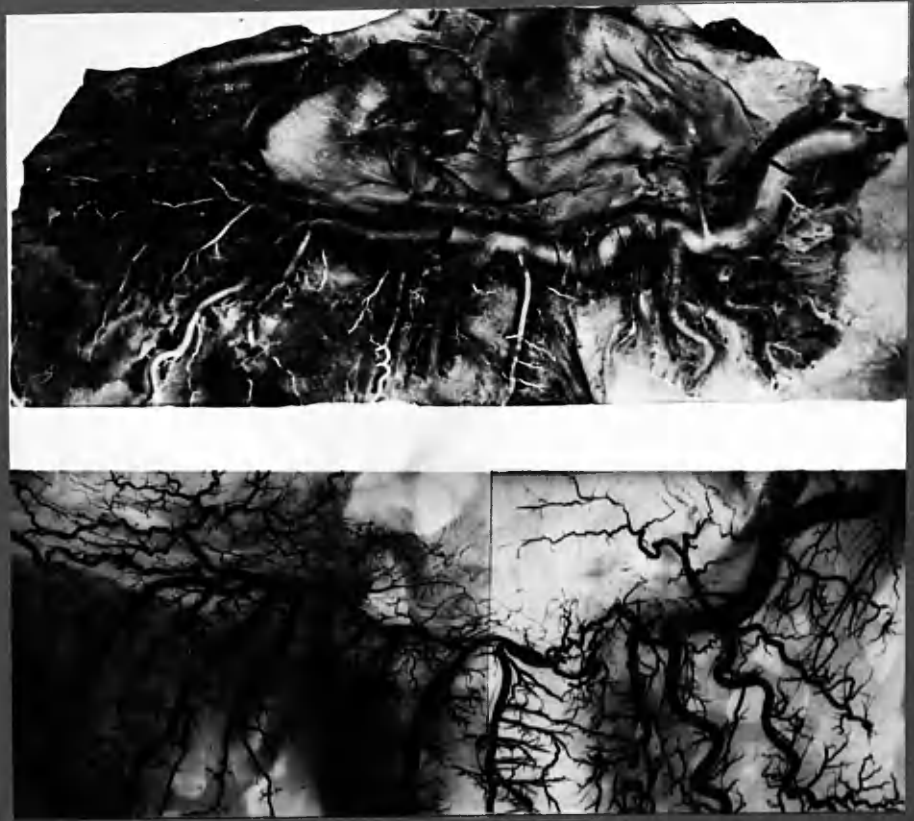
Case N'15

Enlarged heart, normal coronary circulation, with left coronary predominance. Left circumflex artery unusually large and anterior descending artery unusually small. Note apex almost entirely supplied by posterior intervent. branch of left circumflex.



Case D3

Aortic Stenosis (note calcification). Left ventricular hypertrophy +++. Main stem coronary arteries nevertheless of normal calibre.

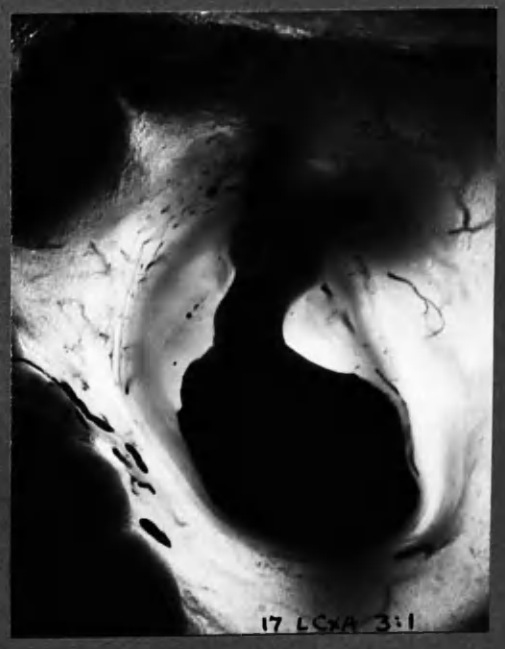

Case 7. Dissection and arteriogram. R. Coronary artery

:8



:9



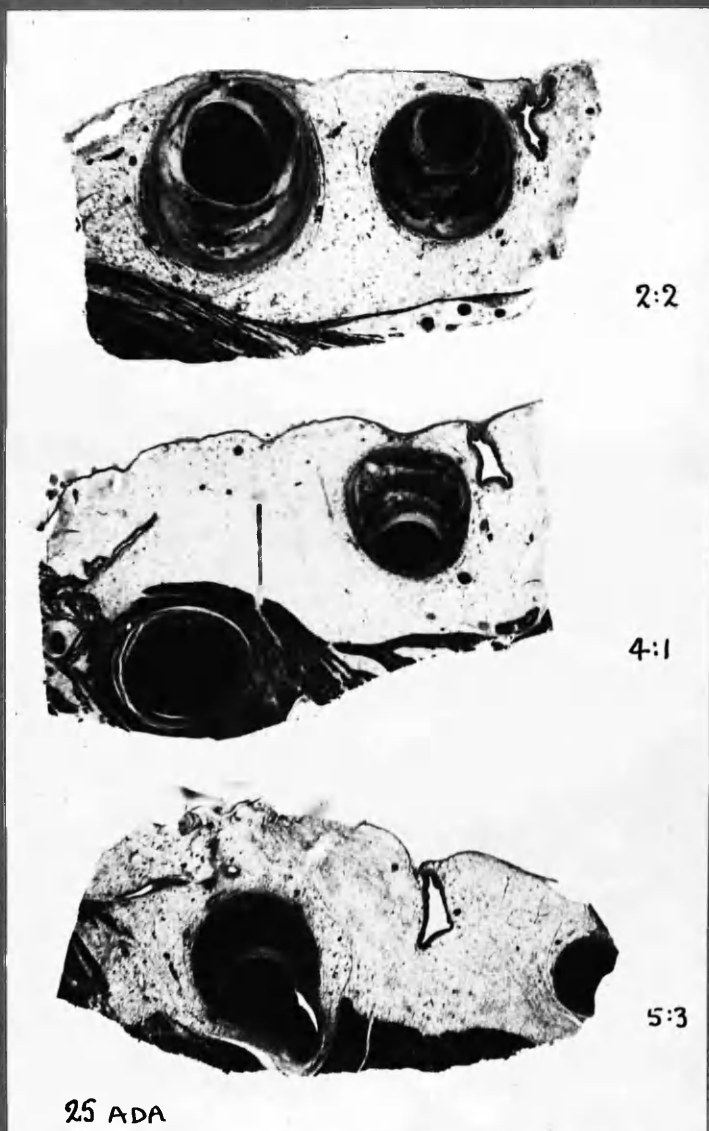
Two examples of localized aneurysmal dilatation of coronary arteries. N.B. Not an injection artefact.



Fig 3:11



Atherosclerotic changes in coronary arteries despite investment by a bridge of myocardium. This bridge however covered only a short stretch of the arteries.




3 representative sections taken along the course of a coronary artery, which illustrate:-

- A. Severe atherosclerosis of artery when epicardial
- B. Freedom from atherosclerosis during course under a bridge of myocardium.
- C. Involvement again by atherosclerosis as soon as the artery "surfaces" to regain epicardial position.

Fig. 3:12

STENOSIS OF BRANCH ORIGIN, within intima of parent artery.



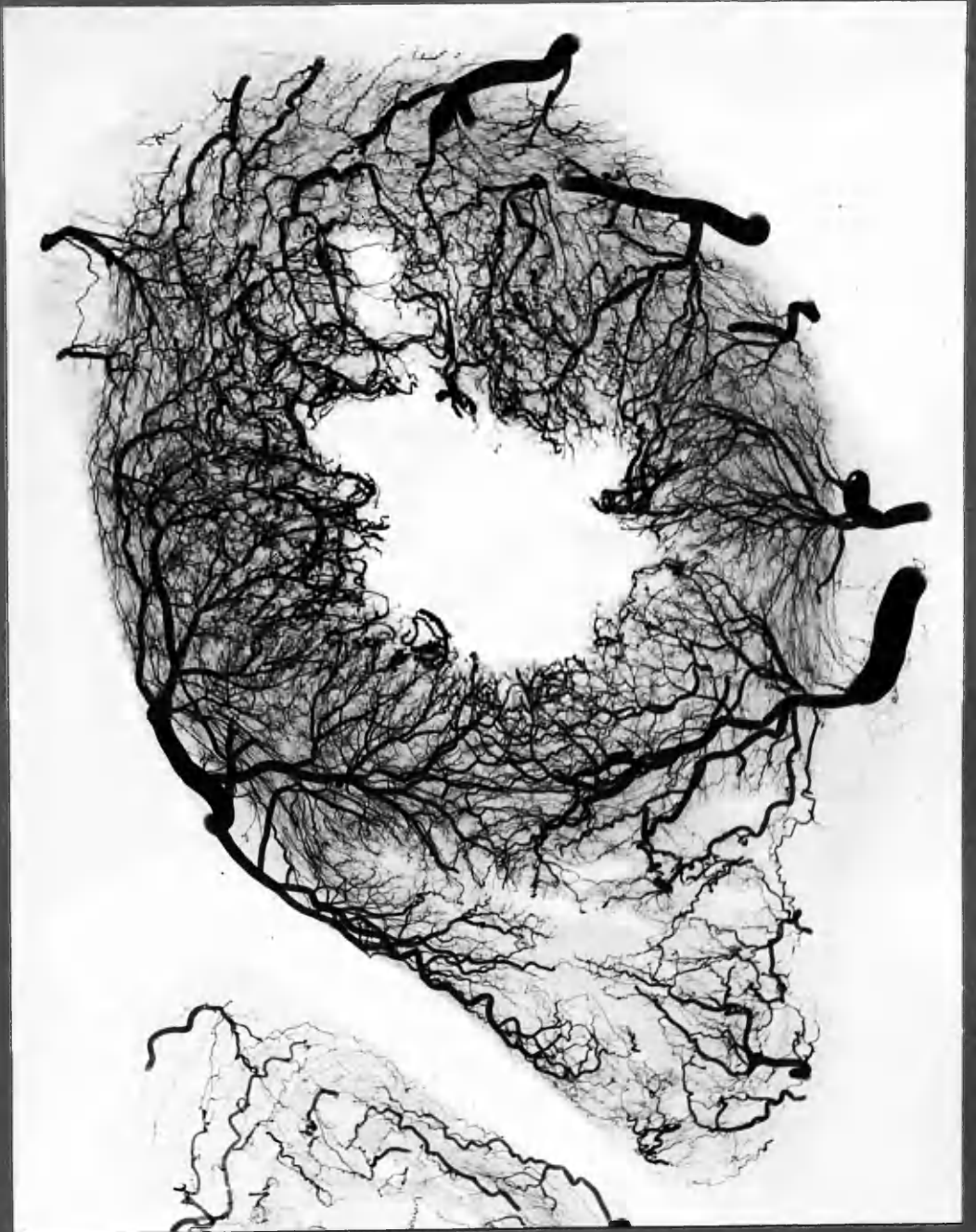
x9

Case 14: — LCxA 2:8 STEREOGRAM of 2mm. thick section.

Commonly an otherwise normal smaller branch of a coronary artery is severely narrowed for a short distance at its origin. The stenosed stretch in fact lies within the parent artery and is restricted to that portion of the branch origin which is passing through the thickness of the atherosclerotic intima. Stereoscopy shows clearly that the appearances are not artefact, resulting from the plane of section.

Such obstructions are readily missed, even in stereoarteriograms, if the axis of the branch at its origin is nearly at right angles to the radiograph, or if there is overlapping by the lumen of the parent artery. (In this instance the stenosed branch origin is clearly shown in the arteriogram, mounted in the group between Chapter 7 & 8.)





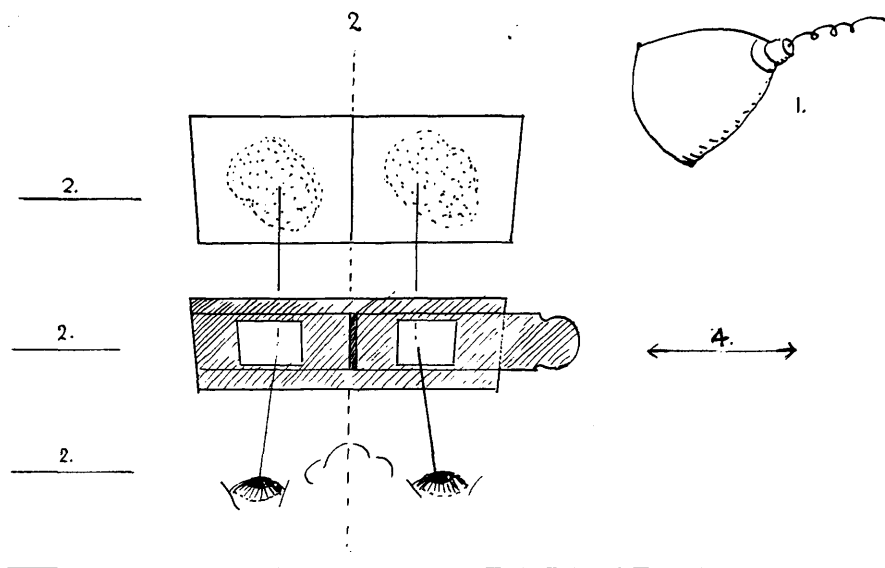

x 2.

Case N'17 , age 80 yrs.

Transventricular section shows rich vasculature in both Right and Left ventricles , including deep anastomoses.

# STEREOSCOPE

1. Lighting should be shaded from the eyes; cast no reflections or shadows.
2. Stereograms, eyes and stereoscope should be centred, and in the same "horizontal" plane.
3. Commence viewing with stereoscope close to eyes, at a distance of about 8 inches from the page.
4. Lateral movement of one of the lenses allows adjustment to the optimal separation for comfortable viewing. This varies with the distance between the observer's eyes and the separation of the stereo-pairs.



The stereoscope provided is of relatively low power, in order that viewing may be undertaken at a comfortable distance from stereograms mounted in a bound volume. The stereograms of this thesis may be viewed to greater advantage through more powerful lenses. Supplementary paired lenses of low power (e.g. 4 dioptries) may be placed over the lenses of this stereoscope, attached by adhesive tape.

VOLUME II

OBSERVATIONS ON THE CORONARY ARTERIES

VOLUME II

Thesis Presented to the University of Glasgow  
for the Degree of Doctor of Medicine

by

William F. M. Fulton  
B.Sc., M.B.Ch.B., M.R.C.P.

---

# CHAPTER 4

## ARTERIAL

## ANASTOMOSES

IN THE CORONARY CIRCULATION

c -

C H A P T E R    4

ARTERIAL ANASTOMOSES IN THE CORONARY CIRCULATION

page No. 4 :

INTRODUCTION	1
THE HISTORICAL BACKGROUND	2
ANATOMICAL FEATURES OF CORONARY ARTERIAL ANASTOMOSES: as demonstrated in the present investigation	8
CRITERIA, METHODS AND MATERIAL	9
ARTERIAL ANASTOMOSES IN THE NORMAL HEART:	
Incidence: general statement	13
ATRIAL ANASTOMOSES	15
VENTRICULAR ANASTOMOSES:	
1. Superficial:	
a. Right ventricle	16
b. Left ventricle	17
c. Superficial anastomoses at the apex	17
d. Superficial right to left communications	18
2. Deep:	
a. Interventricular septum	18
b. Subendocardial plexus of the left ventricle	19
c. Subendocardial plexus of the right ventricle	22
d. Blood supply of the papillary muscles	23
e. Intramural communications other than above	23
ANASTOMOSES AT OTHER SITES:	
1. Heart valves	23
2. Arteriae telae adiposae	23
EXTRA-CARDIAC COMMUNICATIONS:	
1. Mediastinal connections	24
2. Pericardial communications	26

ctd. over..

ARTERIAL ANASTOMOSES IN THE CORONARY CIRCULATION (ctd.)

page No. 4 :

MEASUREMENT OF CORONARY ANASTOMOSES AND SOME CALCULATIONS	28
CHARACTER OF ANASTOMOSES	34
SOME CONCLUSIONS	38
COMMENTS ON THE ARTERIOGRAPHIC DEMONSTRATION OF CORONARY ANASTOMOSES OF SMALL CALIBRE: with critical reference to the Schlesinger technique	40
DISCUSSION OF THE SIGNIFICANCE OF ANASTOMOSES IN THE NORMAL HEART	54
CORONARY ARTERIAL ANASTOMOSES UNDER PATHOLOGICAL CONDITIONS: Discussions of the influences under which coronary anastomoses enlarge	66
A. Ischaemia as a passive influence	66
B (1) Dynamic effects of coronary artery occlusion	68
B (2) Anastomoses in relation to ventricular hypertrophy	82
TIME FACTOR IN THE ENLARGEMENT OF ANASTOMOSES	86
COMMENT	94
SUMMARY	96

\_\_\_\_\_

\_\_\_\_\_

\_\_\_\_\_

\_\_\_\_\_

- 2 -  
ILLUSTRATIONS

DIAGRAMS

	<u>Page</u>
4:1 Subendocardial plexus of the left ventricle	4:20a
:2 Phasic conditions of blood flow in deep vessels of the left ventricle.	4:20a
:3 Anastomosis count in a normal heart.	4:28a
:4 Anastomosis count in advanced coronary artery disease.	4:28a
:5 Distribution of anastomoses in normal hearts.	4:28b
:6 Numerical distribution of anastomoses in normal controls and total coronary group.	4:28b
:7 Numerical distribution of anastomoses in coronary artery disease, graded A,B & C, according to duration of anginal histories.	4:90a
:8 Aggregate cross-sectional areas of anastomoses in normal hearts and in coronary artery disease.	4:31
:9 Numerical distribution of anastomoses in normal	4:83a
:10 and nearly normal hearts, and hearts with ventricular enlargement, mainly due to valvular disease.	
:11 Comparison of the potential capacities for blood flow through anastomoses in normal hearts and in coronary artery disease, graded A, B & C, according to duration of anginal histories.	4:90a

ARTERIOGRAMS

Figures 4:1 - 4:50

4:97a  
et seq.

Arteriograms of intact hearts.	Fig. 4:1-4
Atrial anastomoses.	4:6-13
Anastomoses of interventricular septum.	4:14-20
Superficial anastomoses: anterior wall of right ventricle.	4:21-22
Subendocardial plexus of left ventricle.	4:23-31
Subendocardial plexus of right ventricle.	4:32
Anastomoses in right ventricle in coronary artery disease.	4:33
Anastomoses in mitral valve.	4:34,35
Communications at the apex.	4:36,37
Changes in small vessels of the heart wall as seen in transventricular sections:	
coronary artery disease	4:38-46
ventricular hypertrophy	4:47-49
Sinusoidal dilatation of the capillary bed (stereo:enlarged)	4:50



The first part of the report deals with the general situation of the country and the position of the various groups. It is a very interesting and well-written account of the situation in the country.

The second part of the report deals with the political situation and the position of the various groups. It is a very interesting and well-written account of the situation in the country.

The third part of the report deals with the economic situation and the position of the various groups. It is a very interesting and well-written account of the situation in the country.

The fourth part of the report deals with the social situation and the position of the various groups. It is a very interesting and well-written account of the situation in the country.

### THE HISTORICAL BACKGROUND

The subject of inter-arterial anastomoses in the heart has been exhaustively reviewed by Gross (1921) and Spalteholz (1924). Although the early workers, who included Thebesius, Haller, Morgagni and Senac, had come to the conclusion by dint of careful dissection that anastomoses existed between the coronary arteries, the controversy did not really develop until their existence was denied by Hyrtl (1855). His observations were based on an injection method and were confirmed by Henle (1866), (Gross, 1921).

On the basis of ligation experiments on dogs, Cohnheim and von Schulthess-Rechberg (1881) concluded that the coronary arteries were end-arteries in the true sense of the word; and that if communication existed it was at a capillary level only. The findings and opinions of these workers were confirmed by others but the body of opposition grew.

Ligation experiments were repeatedly performed with results differing from those of Cohnheim, while pathological and clinical observation on coronary occlusion and myocardial infarction led many, whose number included Aschoff, Osler and Herrick, to conclude that interarterial anastomoses must exist, at least in the abnormal heart.

#### The period of detailed classical investigations

At the beginning of the 20th century injection methods, that were more highly developed than had previously been employed, were used for the investigation of the coronary arteries. In 1907 Jamin and Merkel were able to demonstrate anastomoses by the aid of stereo-arteriography. (It is evident from examination of their "Stereoskopischen Röntgenbildern" that they accomplished/

accomplished this with certainty only in hypertrophied hearts. These, however, showed no coronary artery disease). In the same year, using a much more penetrating injection method, followed by clearing of the heart, Spalteholz (1907) was able to give an account of coronary anastomoses in detail. He came to the following conclusions at that time, which he confirmed and elaborated in his monograph in 1924:-

1. The coronary arteries are not end-arteries in the sense used by Cohnheim.
2. They anastomose abundantly with one another near the surface of the heart at all areas, and also with the vasa vasorum on the great vessels.
3. The arrangement of this superficial anastomotic network bears remarkable resemblance to that of the flat muscles of the trunk.
4. At those parts where the myocardium is thick, branches can be seen leaving the superficial network approximately at right angles to pass into the depths of the muscle, within which they enter into numerous anastomoses, especially beneath the endocardium. Each papillary muscle is supplied by several vessels which anastomose with one another.
5. In their finer distribution the coronary arteries are very similar in the dog and man.
6. The position of the superficial network appears to alter with growth in a characteristic fashion.  
(Spalteholz, 1907, trans.W.F.M.F.)

Gross himself arrived at similar findings and illustrated his points by radiographs and by photographs of cleared specimens. He resorted to the latter for the demonstration of finer communications.

Summarising the position of knowledge in 1921, Gross says:

"Thus it cannot any longer be doubted that anastomoses exist between the branches of an individual coronary artery as well as between/  
between/

between branches from both sides. The dissections of Thebesius, Haller, Morgagni, de Senac, and Caldani, the experimental work by McWilliam, Fenoglio and Droguell, Bickell, K<sup>o</sup>lster, Samuelson, Tigerstedt, von Frey, Porter, Miller and Matthews, and Smith; the clinical and anatomical observations made by Samuelson, Huber, Aschoff and Tawara, Huchard, West, Chiari, Pagenstecher, Engelhardt, Thorel, Dock, Galli, Merkel, Osler, Krehl and Herrick, as well as the work of Jamin and Merkel, Spalteholz and Nüssbaum have placed this conclusion beyond dispute.

There is still, however, no accurate knowledge of the exact nature as well as architectural arrangement of these anastomoses."

In an investigation in which he combined the approach by stereo-arteriography with the clearing method of Spalteholz, Gross was able to give further description and illustration of interarterial anastomoses. His observations are based on 100 "normal" hearts, at all ages. His summarised conclusions are as follows:-

- "a. Anastomoses exist between the right and left coronary arteries both in their capillary as well as pre-capillary distribution.
- b. Anastomoses exist between the branches of each coronary artery.
- c. Anastomoses exist between the coronary arteries and vessels from the adjacent and attached organs.
- d. Anastomoses in the heart are universal and abundant."  
(Gross, 1921)

These points have been quoted at some length in order to emphasise the state of knowledge existing nearly 40 years ago.

#### Confirmation of the work of Gross and Spalteholz

In 1922 Crainiciana using red lead in oily suspension and radiography, came to essentially the same conclusions and demonstrated the same points as did/

did Spalteholz and Gross. Using a barium suspension, Campbell (1929) gave further confirmation of this work.

The several methods employed by these investigators had in common painstaking attention to the detail of finer arterial branches. As a result they were able to demonstrate numerous, small-scale arterial communications in all parts of the human heart. The methods employed were naturally tedious and time-consuming.

A few other approaches were made. For instance, Whitten (1930) employed injection followed by corrosion. By this method he was able to add little to the findings of earlier workers. Nevertheless he has been credited with the discovery of certain features in the distribution of small vessels in the ventricles (Wiggers, 1949; Ernstene, 1948) which were given full and detailed description by Spalteholz.

#### Schlesinger and later workers

Interest in the use of injection methods in the investigation of coronary artery disease was revived by the introduction by Schlesinger (1938) of a new and relatively simple method of examination. The technique, some details of which are discussed elsewhere, involved a standardised procedure of injection (of a lead-agar mass), radiography (after the heart had been opened), and dissection. The method has been extensively and usefully employed in the investigation of coronary artery disease. There is little doubt however that its simplicity and rapidity have favoured its popularity. The suitability of a technique for the demonstration of finer detail must be judged on other grounds.

It/

It comes as a surprise, following the statements of Gross, Spalteholz and others, to read that "the coronary arteries in normal hearts, even senile hearts, are true Cohnheim end-arteries, without anastomotic connections." (Schlesinger, 1938). Fourteen years later, after they had investigated over 1000 hearts, the group of workers in Boston, Mass., with whom Schlesinger was associated, maintained essentially the same point of view, for the majority of normal hearts. At any rate it was not revised by them, although we read that "in the normal heart the coronary arteries do present anatomic anastomoses on the capillary level." (Zoll et al., 1952). In this large series, 224 hearts were regarded as grossly normal. Only 23% of these normal hearts showed interarterial anastomoses, according to the method used. This figure, and also the incidence of intercoronary arterial anastomoses found by these workers in diseased hearts, are widely quoted (e.g. Beck, 1957).

The Schlesinger technique has been employed unmodified by Holyoke (1945) and by Ravin and Geever (1946) with conclusions essentially similar to those of the Boston group. In general it may be stated that no more than 1 out of every 4 normal hearts yields evidence of interarterial anastomosis to the Schlesinger method.

It is essential that the limitations of this method be understood when its results are interpreted, and this has been frankly acknowledged by Blumgart (1948).

On the question of fine calibre anastomoses, the conclusions reached through its use are at variance with the results obtained by Spalteholz, Gross, Crainicianu, and Campbell, and with the results of the present

investigation.

Since the observations made in the large and small series of normal and abnormal hearts investigated by Schlesinger's method are numerically overwhelming, this discrepancy demands closer examination. Accordingly space will be devoted to a critical examination of the conclusions based on the Schlesinger technique (on the question of coronary arterial anastomoses). In this section will be found discussion of certain detailed points of technique which have direct bearing on the demonstration of communicating vessels of fine calibre. The discussion will therefore have relevance to the technique used in this investigation and the results obtained by it. It is preferable however to deal firstly with the results themselves.

ANATOMICAL FEATURES OF CORONARY ARTERIAL ANASTOMOSES  
AS DEMONSTRATED IN THE PRESENT INVESTIGATION

Introductory Remarks

In regard to arterial communications in the normal heart, it may be broadly stated that the findings of the present investigation are in accord with those of Gross, Spalteholz, Crainicianu, and Campbell; and, particularly in regard to incidence, are at variance with the findings of Zoll, Schlesinger, Wessler, Blumgart and Freedman, Ravin and Greever, and Holyoke. After an adequate technique of injection and radiography had been developed, anastomoses of various sizes were found, without exception, in all hearts examined.

It was possible not only to prove that coronary arterial anastomoses existed in normal as well as in abnormal hearts, but also to provide demonstration of their structure, size, number and situation. Description of these features is accordingly given in detail in this chapter.

It was further decided to analyse some of the information made available on these points, and the method adopted and the conclusions reached are described later (page 4:29 et seq.).



## CRITERIA, METHODS and MATERIAL

1. CRITERIA

The following criteria for the recognition of arterial anastomoses were adopted:-

1. The presence in the left coronary artery of pigment injected into the right coronary artery.
2. The stereo-arteriographic demonstration of unequivocal communication between arterial branches.

A few comments relevant to these criteria may be made. The recognition of interarterial communication was made with confidence when the stereo-arteriograms were examined at magnification x 5. It is hoped that the photographic reproductions of paired arteriograms with which this chapter is partly illustrated may be found convincing, when likewise viewed stereoscopically. (A proportion of individuals do not normally employ binocular vision for the perception of depth, and will accordingly have difficulty in appreciating the three-dimensional picture).

Confirmation of interarterial communications by gross dissection, aided sometimes by rendering the tissues translucent and by the use of the dissecting microscope, was undertaken in a number of instances in order to satisfy myself that the radiographic method was reliable. Clearing methods could occasionally reveal small anastomoses that were poorly filled by the injection medium and on that account poorly represented on the radiograph; but the reverse was never the case. Fig. 4:8B is a photograph of atrial vessels visualised by a clearing method, and may be compared to the radiograph of the same case (Fig. 4:8A).

The appearance in one artery of a material injected into the other has been accepted by all workers as reliable evidence of interarterial communication. It is a finding which is simple and convincing; much as the arrival in Edinburgh of a man from Glasgow proves the existence of communication between the two cities! But it is a limited observation. It gives no indication of the route taken nor of the communications that may exist in other parts. The stereo-radiographic picture on the other hand may be compared to a map prepared from aerial photographs. In this investigation the information so provided would alone have been sufficient to convince the observer of the existence of arterial communication.

## 2. METHODS

Details of the technique employed have already been given (Chapter 1). For convenience a few points are summarised which have direct relevance to the demonstration of anastomoses.

Features of the technique included:-

- (1) A reliably high degree of penetration of the injection medium, together with the radiographic demonstration of vessels as small as 20-30 microns in diameter.
- (2) Routine use of stereo-arteriography of the whole heart and of all portions of the heart; and the viewing of stereo-pairs at a magnification of x 5 approximately.
- (3) The use of fine-grain X-ray film.
- (4) A special method of radiography which practically eliminated tissue shadow (and thereby rendered the results readily reproducible on photographic paper).
- (5) Measurements quoted for maximum penetration were derived from projection micrometry of thick frozen sections, prepared from tissues fixed in 5% formol-saline.

Measurements of anastomoses were made by direct comparison with a standard radiograph, calibrated by projection micrometry, as described on page 1:45.

By the method employed it was possible to follow the course of anastomotic channels of 20-30 microns diameter and upwards. The injection medium became impacted in the immediately pre-capillary arterioles, and reliable filling was commonly achieved down to 20 microns diameter. A small amount of diluted medium had sometimes found its way into the capillaries, and even into veins, but such traces of opaque substance were insufficient to cast a shadow on the radiograph. With the exception of the unusual condition described on page 4:36 all vessels seen in the X-ray pictures were on the arterial side of the capillary bed and could be traced from their parent arterial stem.

### 3. MATERIAL

A statement of the material has already been given in Chapter 2, together with the criteria of normality which were adopted. Further selection of cases for detailed analysis of anastomoses was based on the standard of arterial injection, or on the adequacy of the available evidence preserved in the radiographs. The cases which have been discarded as unsuitable for this particular purpose were all examined early in the investigation. After the establishment of the more refined technique the cases so selected were consecutive; and are referred to as Group Ia, IIa, IIIa and IVa. (In Group IVa there is the exception that cases 2, 3 and 5 were discarded while 1 and 4 were retained).

8 out of the 9 normal cases that will be analysed in regard to the incidence of anastomoses had weights of 350 gm. or less.

Table 4:1

The MATERIAL: selection for study of anastomoses		
Group	Total	Suitable for analysis of anastomoses
I NORMAL	12	9
II NEARLY NORMAL	5	4
III HEART DISEASE OTHER THAN CORONARY ARTERY DISEASE	17	15
IV CORONARY ARTERY DISEASE	25	22
Total :	59	50

Further subdivision of the 15 cases in Group IIIa and the results of their analysis appear on pages 4: 83.

Subdivision of the coronary artery disease group (Group IVa) is likewise made for analysis of anastomotic changes and is described on pages 4: 89,90.

It will be appreciated that the main purpose of the present investigation was a detailed examination of the coronary arteries in advanced coronary heart disease. It was not primarily an enquiry into the anatomy of the normal coronary circulation. Accordingly the numbers of normal controls examined were relatively few. Nevertheless the detailed nature of the investigation and the absoluteness of some of the findings allow some conclusions to be drawn from comparatively few normal cases - notwithstanding that some of these conclusions be at variance with the findings of numerically much larger published series.

## ARTERIAL ANASTOMOSES IN THE NORMAL HEART

## 1. INCIDENCE: General Statement.

In each of the nine consecutive normal cases in Group Ia some degree of interarterial communication was demonstrated during the course of injection. This was sufficient to allow the red-pigmented medium introduced into the right coronary artery to appear in the left coronary cannula in 1 to 3 minutes, at a pressure gradient of 150/50 mm.Hg.

In superficially placed vessels near the junctional zone between territories of the right and left coronary arteries, invasion by pigmented medium could often be detected in a shorter time. On the other hand, in a few instances, only a very slight degree of superficial communication could be seen in this way; yet the pigment appeared in the left coronary cannula as usual. In these cases anastomoses were later found connecting the two arteries through their septal branches or through the sub-endocardial plexus. Evidence will be presented which demonstrates the relatively greater frequency and calibre of these more deeply placed anastomoses.

In regard to anatomical detail my findings confirmed that anastomoses in the heart were "universal and abundant" (Gross, 1921). They were found in the atrial walls and interatrial septum; in the right ventricle; in all layers of the interventricular septum (where however they tended to be more numerous and of larger calibre as the left ventricular cavity was approached); on the surface of the left ventricle beneath the epicardium, and at all levels in the walls of that chamber, especially in the deepest layers, extracardiac arterial communication was frequently noted at the roots of the great vessels and at the venous orifices; and between atrial arteries and arteries of the mediastinum.

The description of coronary anastomoses that follows is derived entirely from original observation of the cases that formed the material of the present investigation. It agrees almost exactly with the descriptions given by Spalteholz (1924), Gross (1921) and Crainicianu (1922). However, none of these workers recorded measurement of anastomoses in the normal heart, nor estimated their numbers. All were evidently defeated by technical difficulties in providing radiographic illustration of these fine calibre vessels. Gross and Spalteholz resorted to photographs of cleared specimens for their illustrations of anastomoses. (The limitations of the cleared specimen have already received comment).

The findings of the present investigation on the other hand have been freely illustrated by selected radiographs, sometimes in stereo-pairs. It is hoped that the support thereby given is not only of sufficient merit to justify a further detailed description of coronary anastomoses, but that it will also serve to confirm the findings of earlier workers, and to refute some of the conclusions based on more recent but less critical observations.

The distribution of anastomoses which I found in the normal heart is presented in Diag. 4:5. This diagram is derived from the combined group of normal hearts (Group Ia); the data from which it is constructed are described on page 4:29 et seq. Although most of the information contained in this diagram merely gave support to impressions formed from observations made in less systematic fashion, three points stood out:

1. The emphasis that could be placed on arterial anastomoses in the deeper layers of the left ventricle, and to a lesser extent of the right.
2. The scarcity and small calibre of communications within the substance of the left ventricular wall, when septal and sub-endocardial anastomoses were excepted.

3. The rarity of communications on the epicardial surface of the left ventricle, except in the immediate vicinity of the apex.

The detailed description will deal with arterial anastomoses in the normal heart under the following headings:

1. Atrial
2. Ventricular:
  - (a) Superficial
  - (b) Deep
3. Anastomoses at other sites
4. Extra-cardiac communications

For convenience a few comments and illustrations referring to anastomoses in coronary disease will be interpolated in this description. Care has been taken to avoid confusion between normal and abnormal findings.

#### ATRIAL ANASTOMOSES

The finer vessels of the left atrial wall and the auricular appendage formed an arterial network which was readily demonstrable. Intercommunication of arteries was found with less constancy in the right atrium. For the most part communication took place through vessels of very narrow calibre (20 to 100 microns in diameter) (Fig. 4:6,7). Figure 4:8 shows a more definite network in a heart that was slightly overweight but otherwise normal.

A similar network in the hypertrophied left atrium is also shown (Fig.4:9). In coronary artery disease atrial communications were frequently enlarged to considerable size (see Figs. 4:11,12,13 ) and appeared to form substantial communication between an obstructed and a more adequately supplied

artery. These anastomoses had perhaps special functional significance in that they were usually inter-coronary (i.e. L-R). Atrial anastomoses were moreover so situated anatomically that linkage could take place through them between many points in the course of the right and left circumflex arteries.

Moreover, mediastinal communications when present almost invariably linked up with the main coronary supply through the atrial circulation (see Figs. 4:1 1:4 and arteriograms of intact hearts of cases 21, 22, 19, N<sup>1</sup>/<sub>6</sub>).  
 etc  
 Whether such communications had any functional value is another matter. Arterial anastomoses were also found in the interatrial septum.

#### VENTRICULAR ANASTOMOSES

##### 1. Superficial (Epicardial) Ventricular Anastomoses

a. Right ventricle: The anterior wall of the right ventricle was found to be a constant site for numerous small scale communications between the right coronary and the anterior descending artery (Fig. 4:21). On injection satisfactory retrograde filling was usually obtained of the accessory right coronary artery (conus artery, Schlesinger, 1949) when present. Filling of these arteries could take place from the left or right coronary artery or from both.

On the posterior wall of the right ventricle similar anastomoses were often found, but less constantly at this site on account of the great variation in distribution of the major branches..(As already indicated the junctional zone between the two circumflex arteries could lie in the posterior right ventricular wall, the interventricular groove, or even quite far round the posterior wall



of the left ventricle.) No confirmation was found of Schlesinger's view that a relatively avascular area exists at this site (Schlesinger, 1938).

In addition anastomoses were found on the epicardial surface of the right ventricle near the apex. At sites other than these, superficial right ventricular anastomoses were infrequent, in the normal heart.

Anastomoses were often found between the arterial branches supplying the conus of the right ventricle and the network formed by the vasa vasorum of the pulmonary artery (Fig. 4:21). (The vasa vasorum of the aorta were also frequently injected through communications with the coronary arteries.)

b. Left ventricle: Except at the apex, superficial anastomoses were found only rarely on the epicardial surface of the left ventricle. Such communicating vessels as did occur were usually in the fat accompanying the major vessels and were of very fine calibre.

c. Superficial anastomoses at the apex: At the apex there was usually a confluence of at least three arteries: the anterior descending artery (which usually rounded the apex), the posterior interventricular artery (which usually arose from the right coronary artery) and the marginal branch of the right coronary artery. It was usual to find some degree of anastomoses at this site in normal hearts. Commonly one, two or more communications of 50-300 microns diameter were found linking the terminal branches of these arteries.

(Fig. 4:36,31 )                      Deeper communications also linked the superficial arteries with the subendocardial plexuses of the right and left ventricles at the apex (Fig. 4:31,32).

d. Superficial right to left communications: This is not a separate group but is included in a., b. and c. above. Communication between the right and left arteries took place on the surface of the heart at many sites depending on individual variations in the distribution of the arteries. Thus posterior communications on the surface of the right ventricle were more common in the presence of left coronary preponderance, and on the surface of the left ventricle in right coronary preponderance, as might be expected. As already mentioned, however, communication between the branches of the right coronary and anterior descending arteries was fairly constantly found in the anterior wall of the right ventricle, in keeping with the relatively constant course of the main trunks of these arteries.

In disease one or more of these superficial anastomoses was commonly enlarged to considerable size (Fig. 4:37 and arteriograms of intact hearts, cases 1,4,6, 17<sup>\*</sup>). Similarly, in ventricular hypertrophy as well as in coronary artery disease, the territory between the right and left coronary arteries posteriorly was often bridged by a communication of dissectable size. An arterial communication of this order, lying in the atrio-ventricular groove, is illustrated in Cunningham's Textbook of Anatomy (Edition VIII, p.1188). A similar communicating vessel was found only once (N 3) in the present series of normal hearts. Commonly only vessels of much smaller size were found at this site in health.

## 2. Deep Ventricular Anastomoses

a. Interventricular septum: The territory between the anterior and posterior groups of arteries supplying the interventricular septum was a constant site for numerous anastomoses. For the most part the communicating arteries followed

\* Fig. 3:3, 4:4, 6:6 and 4:3, respectively.

the general direction of the septal branches of the anterior descending artery, which swept backwards and slightly downwards as they traversed the septum. Those placed just under the endocardium of the left ventricle tended to run at right angles to this direction. They formed part of the sub-endocardial plexus.

The site of anastomotic communication in the interventricular septum depended upon the distribution of coronary arteries supplying it. This showed considerable variation about a general plan. In accord with the observations of others, the anterior  $2/3$  of the septum was found to be most commonly supplied by branches of the anterior descending artery and the upper posterior  $1/3$  by the posterior interventricular artery. Within an inch of the apex, the main supply of the interventricular septum was derived in the majority of cases from the anterior descending artery alone. (See Fig. 4:15,14.) Septal anastomoses were numerous and measured commonly 100 to 300 microns in diameter.

Because of their favourable position and their occurrence in large numbers, interventricular septal anastomoses were regarded as communicating channels of great potential importance. In ischaemic states the enlargement of these anastomoses could reach tremendous dimensions, as illustrated in Figs. 4:18,19,20. Further, as the posterior interventricular artery was commonly a branch of the right coronary artery, these interventricular septal anastomoses were mostly "intercoronary" in the full meaning of the word.

b. The sub-endocardial plexus of the left ventricle: A network of intercommunicating arterial channels in the deeper zone of the left ventricle was a constant feature. It was usual for the larger vessels composing this network

to measure about 100-200 microns in diameter. For the most part the larger vessels were found to run in the substance of the columnae carneaee and intercommunication took place at points where the muscular columns linked with each other or joined the main wall of the ventricle. To some extent the distinctness of the plexus was related to individual variation in prominence of the columnae carneaee (see Fig. 4:23).

The internal network was supplied in the main by vessels of similar calibre (c.200 microns) which arose from the epicardial branches and ran directly through the ventricular wall at right angles to the surface (Figs. 4:27, 29, 30, 31B and Diag. 4:1). These vessels usually gave off relatively few side branches en route and, in this way, underwent little diminution in calibre before reaching the deep plexus. Conversely communications also existed between the sub-endocardial plexus and the terminal arborisations of the other vessels which supplied mainly the outer and middle layers of the ventricular wall. At the apex one or more terminal branches of a major coronary artery, usually the anterior descending artery, could be seen to turn inwards to link with the plexus. In ischaemic disease, vessels feeding the sub-endocardial plexus at this site were often large. Thinness of the ventricular wall at the apex may have favoured communication. Similarly at the base, where the ventricular wall is also thin, vessels were sometimes found to arise directly from the major divisions of the left coronary and to pass deeply just below the atrioventricular junction to join the subendocardial plexus. In several cases, one of which is illustrated in Fig. 4:23, a long communication of this sort followed a

SUB-ENDOCARDIAL PLEXUS of the  
LEFT VENTRICLE

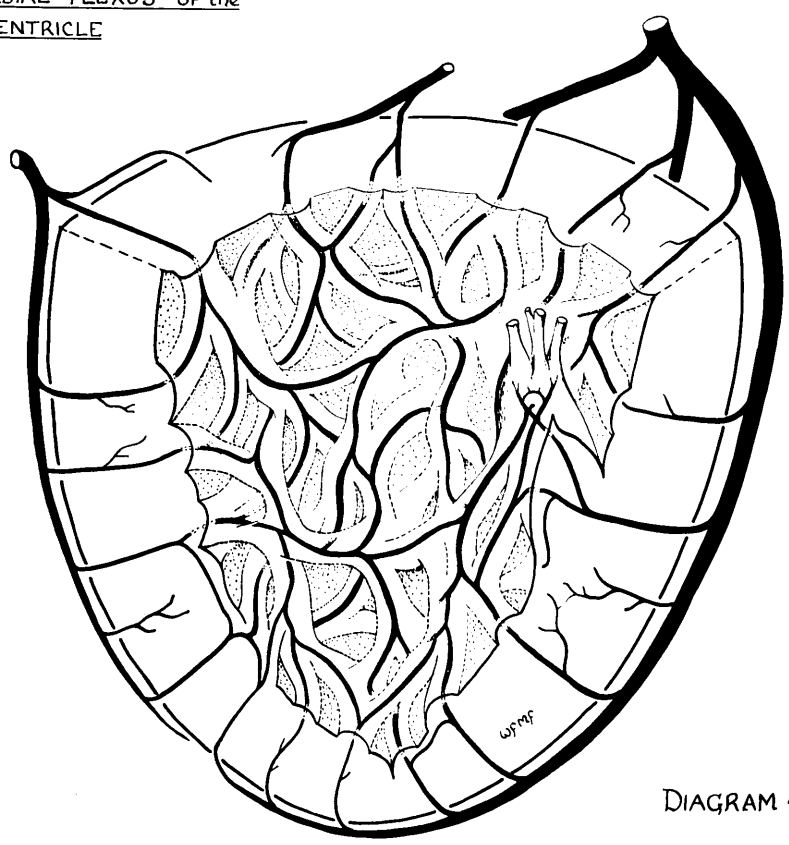
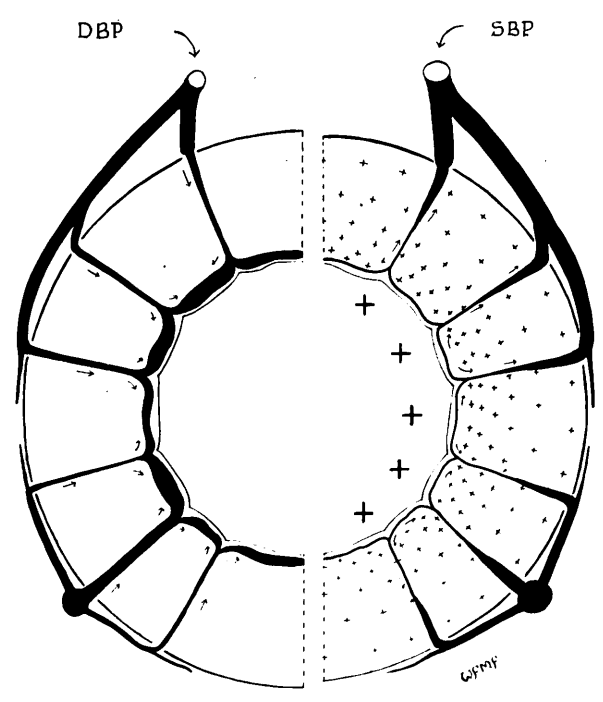


DIAGRAM 4:1



DIASTOLE

EARLY SYSTOLE

PHASIC CONDITIONS OF BLOOD FLOW  
IN DEEP VESSELS OF THE LEFT VENTRICLE

DIAGRAM 4:2

distinct course from the early part of the left coronary artery through the sub-endocardial layers most of the way to the apex.

On the left surface of the interventricular septum vessels took part in the subendocardial plexus, as elsewhere in the left ventricle. They communicated with the arteries more deeply placed in the septum, but for the most part differed from them in the direction of their course. It has already been noted that the trans-septal vessels followed a course more or less parallel to the plane of the atrio-ventricular groove, whereas the sub-endocardial vessels on the left side of the interventricular septum most frequently ran in a vertical direction, nearly at right angles to the trans-septal arteries. This may be clearly seen in Fig. 4:14 and was previously noted by Spalteholz (1924).

Effort has been made through the use of stereoscopic views and by detailed description to focus attention on the sub-endocardial plexus (see Fig. 4:23-31 and 4:38-49). For although its normal characters received detailed anatomical description by Spalteholz(1907,1924) its importance in pathology has largely been ignored. In a later part of this presentation its pathological significance is considered in more detail. At this point it is merely stated that in ischaemic heart disease dilatation of the sub-endocardial vessels was usual, and in some circumstances was extreme, with conversion of the arterial supply to the deeper layers of the left ventricle into a network of wide-bore intercommunicating channels.

c. The sub-endocardial plexus of the right ventricle; In the normal heart the sub-endocardial arterial plexus of the right ventricle was a less prominent feature than that of the left. As might be expected, moreover, in view of the thinness of its walls, the distinction between superficial and deep arterial divisions was made less readily in the right than in the left ventricle.

In right ventricular hypertrophy on the other hand the vessels composing the sub-endocardial plexus had increased in size and were separated more clearly from the superficial vessels by the greater thickness of muscle wall. In this way they presented a pattern of intercommunication basically similar to that of the left ventricle.

In addition to supply from the mural branches, derived in the main from the right coronary artery, an important contribution to the sub-endocardial plexus of the right ventricle was also made by septal branches stemming from the anterior descending artery. I confirmed that one of these was usually larger than the others and crossed the moderator band, as illustrated by Campbell (1929). It appeared that this source of blood supply to the right ventricle had importance for the distribution of ischaemic damage in that chamber (see Chap. 5).

In coronary artery disease a complex pattern of anastomosis was sometimes found in the wall of the right ventricle with confusion of the anatomical arrangement.

The sub-endocardial plexus of the right ventricle is illustrated in Fig. 4:32.

d. The blood supply of the papillary muscles: The papillary muscles were supplied for the most part in the same manner as the columnae carneae (Fig. 4:28,47 and Diag. 4:1). The vessels supplying them took part in the sub-endocardial plexus and communications of considerable diameter (200-300 microns) were frequently found in the bases of the papillary muscles. Finer communications intrinsic to these muscles were also found.

e. Intramural communications of the left ventricle other than septal vessels and vessels taking part in the sub-endocardial plexus: In view of the statements of others, intramural arterial anastomoses were found to be surprisingly scanty in normal hearts and never of large calibre. Usually they were less than 100 microns in diameter. Sometimes none were found. Accordingly, the mid-zone of the outer walls of the left ventricle seems sometimes to be an exception to the general statement of Gross that "anastomoses in the heart are universal and abundant" (Gross, 1921).

#### ANASTOMOSES AT OTHER SITES

##### 1. The Heart Valves

Fig. 4:34 illustrates injection of the valve leaflets of the mitral valve and indicates that an anastomotic pattern may be found here as well as in other parts of the heart. This looping arrangement is regarded by Gross as characteristic.

##### 2. Arteriae telae adiposae

Very fine looping vessels were seen to supply the sub-endocardial fat and illustration of these is shown in Figs. 4:36, . In some



circumstances these may enlarge to provide some degree of intercommunication between arteries. The importance of arteriae telae adiposae, however, in protecting the ageing heart from the effects of arterial occlusion has not been so impressive in the present series, as the role attributed to them by Gross (1921) who first drew attention to their potentialities. Of course, with increasing adiposity, normal superficial arteries become displaced from the surface of the myocardium by fat. But in this investigation there was little to suggest that "new" vessels of sufficient size and so anatomically placed as to be of service to the nutrition of the heart muscle had developed from the minute arteriae telae adiposae.

#### EXTRA-CARDIAC COMMUNICATIONS.

##### 1. Mediastinal connections

In the majority of hearts leakage of medium took place during injection from the cut surface of the mediastinal tissues lying above the atria and in relation to the great vessels. For the most part it amounted only to an oozing through presumably very small vessels and it ceased spontaneously. In approximately half the cases it required the ligation of a small artery. In a few cases leakage was brisk and could be traced to vessels of considerable size.

Mediastinal communication was demonstrated in 6 out of 9 normal cases, 2 out of 4 nearly normal cases, 8 out of 15 cases in Group IIIa, and 18 out of 22 cases of coronary artery disease (Group IVa).

For the most part mediastinal communications of larger calibre were found in the cases of coronary artery disease, but were not restricted to these cases. In one normal case (N 8), in which "splenic anaemia" had existed for several

years before death at the age of 14 years, a vessel connecting the atrial circulation with the mediastinum measured 800 microns in diameter (at its narrowest point). In the coronary group, similar vessels of 300 to 700 microns in diameter were not uncommon. Clearly vessels of this order could make appreciable contribution to the total blood supply of the heart; but as the information arising from this investigation about the further connections of these vessels is very incomplete, I will not labour the point. In any case, blood may well have flowed in life through this and similar communications not to, but away from, the heart. On this point too there is no certainty.

Mention of the lung roots is made because leakage through small vessels occasionally took place alongside the pulmonary veins even when these had been severed well clear of the left atrium. No information in regard to their communications in the lung root was derived from this investigation. A satisfactory enquiry into the extent of the extra-cardiac communications would require the injection and radiography of the heart, whilst it was still attached to a large block of tissue containing the superior mediastinum and lungs or lung roots. This would entail much inconvenience in the management of the other technical procedures but could readily be undertaken as a matter of separate enquiry.

After injection and before radiography, it was the usual practice to trim away most of the tissues attached to the heart. In this way opportunities for convincing radiographic demonstration of mediastinal communications were often lost. In only a few instances is the evidence preserved sufficiently for two-dimensional illustration, but it may be possible to recognise vessels passing upwards from the atrial circulation towards the superior mediastinum

in Figs. 1:4, 4:1 and whole heart arteriograms from cases 21,20,

## 2. Pericardial Communications

In the process of adherence of the pericardium to the epicardial surface of the heart, the pericardial and coronary circulations are brought into intimate contact and a certain amount of communication appears to take place. In the hope of establishing new blood supply to the heart in this way, operations have been devised (Mautz and Beck, 1937, and others).

From this investigation little positive information has been gained on this topic. The impression was formed however that such communication as existed must be mainly at a capillary, or near-capillary, level. Two cases of widespread old-standing, adherent pericardium were examined, one secondary to myocardial infarction and the other to rheumatic heart disease. In each of these cases traces of injection medium entered the tissue binding the pericardium to the myocardial surface. The medium was contained in short vessels which were not measured but which were probably not larger than 100 microns in diameter, and were few in number. A vastly greater number of vessels in the same areas were outlined by the blood within them which had not been fully displaced by the preliminary saline perfusion and had not received the injection medium. The vessels which contained injection mass were for the most part poorly filled, a feature which suggested that the mass had reached them only through vessels of still finer calibre. Radiographic demonstration of these vessels was not obtained.

One case was also examined which had undergone mitral valvotomy one year before death. Extensive granulation tissue bound the pericardium and adjacent

structures to the surface of the heart, especially in the region of the site of operation. Again, this tissue was entered by injection medium from the coronary circulation, mainly as partial injection of very fine vessels. Radiographic demonstration however was obtained of one vessel of approximately 150 microns in diameter.

---

I do not think that a satisfactory enquiry into the question of acquired blood supply to the heart from pericardial vessels could be obtained using only the technique of this investigation without modification. Its investigation, in my opinion, would require also the use of a medium of greater penetration so that the capillary bed would be injected. This would render the method unsuited to an investigation of the coronary circulation as a whole.

MEASUREMENT OF CORONARY ANASTOMOSES AND SOME CALCULATIONS

It is not difficult to come to the conclusion that anastomoses are much more in evidence, and of much wider calibre, in advanced coronary artery disease than in the normal heart, or in other forms of heart disease. It is a very different matter to find some way of recording the findings of each individual case in a numerical fashion so that grouped results can be subjected to analysis. Yet only with such an analysis can comparison on a quantitative basis be made, other than the expression of opinion and the recording of numerous examples. Several investigators have sought such a measurement. No published method is without obvious shortcoming or fallacy - e.g. "Anastomotic Index", Crainicianu (1922); Kerosene perfusion, Dock (1941); Graduated glass spheres, Prinzmetal (1947).

I have come to the conclusion that no estimate of a numerical or quantitative nature can substitute for the detailed study of the arterial anatomy of each case in a series under analysis. With repeated examination of the evidence and comparison between cases and groups of cases, conclusions may be reached from such a study and representative examples selected. This I have done. I have also tried to take the matter further and have examined the stereo-arteriograms of the entire series systematically, recording the findings in a fashion that permitted certain calculations to be made.

The results of these calculations agreed with the opinions which I had formed from the direct scrutiny of individual vascular patterns. In recording the results graphically and in drawing conclusions from them, I wish it to be understood that the diagrams were not the only source of these conclusions, but were support for, and illustration of, conclusions already reached on a

An Example of Anastomosis Count in a  
NORMAL HEART.

CASE No. : 402/53		Lumen diam. in microns.					
		10-40	40-100	100-200	200-500	500-800	800+
ATRIAL	Mural		++		1		
	Septal						
EPICARDIAL	R.V.	+	+				
	L.V.	+					
	R.V.-L.V.			+			
ENDOCARDIAL	R.V.	++	+	+			
	L.V.		++	+++	+		
I-V. SEPTAL			+	++			
INTRAMURAL L.V. (other than Septal)			-	-			
APICAL (2.5cm.)	R.C.-ADA.		+				
	Other-ADA. Connecting with Sub-endocardial Plexus	+			+		
PAPILLARY MUSCLES.	Supply						
	Intrinsic			+	+		
"ANASTOMOTIC INDEX"		+	++	+++	+		
" " expressed numerically -		1	2	3	1	0	0

KEY : + = 1-3    ++ = 3-10    +++ = 10-25    ++++ = 25+

DIAGRAM 4:3

An Example of Anastomosis Count in a case of  
ADVANCED CORONARY ARTERY DISEASE.

CASE No. : 84/53		Lumen diam. in microns					
		10-40	40-100	100-200	200-500	500-800	800+
ATRIAL	Mural		+	+	+	+	+
	Septal			+			
EPICARDIAL	R.V.		+	+	++		
	L.V.		+	+			+
	R.V.-L.V.			+	++		
ENDOCARDIAL	R.V.			+	+		
	L.V.				+++	++	
I-V. SEPTAL			++	++	+		
INTRAMURAL L.V. (other than septal)		(+)(+) (+)(+)	(+)(+) (+)(+)	+	+		
APICAL (2.5cm.)	R.C.-ADA.		++	++	+++		
	Other-ADA. Connecting with Sub-Endocardial Plexus	(+)(+)	(+)(+)		+++	+	+
PAPILLARY MUSCLES	Supply				+		
	Intrinsic				+		
"ANASTOMOTIC INDEX"		(+++)	(+++)	+++	+++	++	+
" " expressed numerically -		1	1	3	3	2	1

[The brackets (+) indicate vessels composing a fine network restricted to areas of severe old-standing myocardial damage, which appear to have arisen from greatly dilated capillaries and which differ in character from true arterial anastomosis. Accordingly, they have not been taken into account when calculating the anastomotic index.]

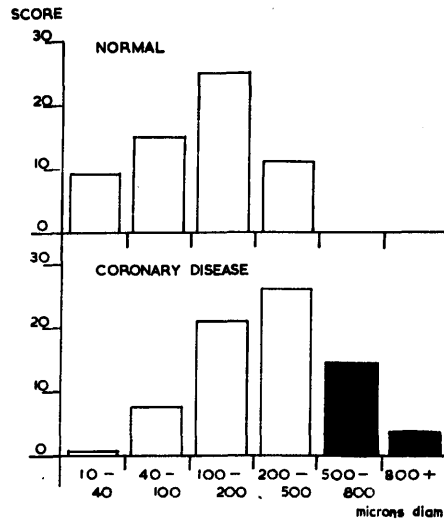
DIAGRAM 4:4

THE DISTRIBUTION OF ANASTOMOSES IN NINE NORMAL HEARTS

DETAILING NUMBERS and CALIBRES at DIFFERENT SITES.

		microns diameter				
		10-40	40-100	100-200	200-500	500-800
ATRIAL		oooo	o o o o o o o o	o o o o o o o o	o o	
EPICARDIAL	R.V.	o o o o	o o o o	o o		
	L.V.	o o o o	o o o o	o o	o	
	RV.-LV.	o	o o o	o o o o	o o	
ENDOCARDIAL	R.V.	o o o	o o o o	o o o o	o o o	
	L.V.		o o o o o o o o	o o o o o o o o o o o o	o o o o	o
I-V. SEPTAL		o	o o o	o o o o o o o o	o o o	
INTRAMURAL L.V. (other than septal)			o o o	o o o		
TOTAL SUPERFICIAL VENTRICULAR		□	□	□	□	
TOTAL DEEP VENTRICULAR		■	■	■	■	■

DIAGRAM 4:5



COMPARISON OF NUMERICAL DISTRIBUTION OF ANASTOMOSES IN NORMAL CONTROLS AND TOTAL CORONARY GROUP.

DIAGRAM 4:6

basis of direct observation. The anatomical study and the quantitative calculations were complementary.

The method employed required tedious and meticulous examination of the radiographic evidence. A proforma was constructed on which was recorded the approximate numbers of anastomoses at different sites in the heart, in such a way that the entire coronary circulation was included. The anastomoses were graded according to calibre. Examples of such records are given for a normal heart (Diag. 4:3) and for a heart with severe coronary artery disease (Diag. 4:4). The measurements were carried out by direct comparison with a transparent calibrated scale held in contact with the radiograph while it was viewed stereoscopically at x5 magnification. For the preparation of this scale see page 1:45. The record so obtained is referred to as an "Anastomosis Count".

Anastomosis counts have been used for two types of calculation:

- (1) The first calculation is expressed in Diag. 4:5 in which the anastomosis counts of a group have been aggregated. This has only been undertaken for normal hearts. It demonstrated the average distribution of arterial anastomoses in the normal heart and thereby presents the anatomical basis upon which the changes of disease may develop. One important feature is the relatively greater size and number of anastomoses in the deeper than in the superficial layers of the heart.
- (2) The second calculation was the derivation of the "Anastomotic Index", which has been entered on the last line of the proforma.



- (2) This index was largely derived from the numerical records of each column. An assessment of the anatomical details of the case were also taken into account. It represented a rough indication of the numbers of anastomoses, grouped according to calibre, present in the heart. It is expressed in arbitrary units. Thus in the example of a normal heart the anastomotic index was 123100. By contrast the example of a heart in coronary artery disease had an index of 113221.

When the hearts of a particular group were considered together, the "Anastomotic Score" could be calculated. This was simply the sum of the anastomotic indices corrected for the number in the group.

$$\text{Anastomotic score} = \frac{\text{Sum of anastomotic indices} \times 10}{\text{Number in the group}}$$

The "score" was used to compare different groups in regard to their anastomotic development - with quite striking results, as can be seen in Diag. 4:6. In this diagram, comparison was made between the scores in Group I (Normal hearts) and Group IV (Hearts with advanced coronary artery disease). The term "score" was used in preference to "mean", to which it roughly corresponds, because it was thought undesirable to express in terms of mathematical accuracy calculations based on findings which in turn were necessarily based partly on judgement.

When considering the evidence in Diag. 4:6 and 4:7 (and also in Diag. 4:9 and 4:10) which feature anastomotic scores in different groups and sub-groups, it should be appreciated that the functional significance of an

anastomotic channel is not to be related in linear fashion to its diameter, but in proportion to the diameter<sup>4</sup> (in so far as Poiseuille's Law is applicable in calculation of resistance to blood flow offered by these channels). In Diag. 4:8 some indication of the relative importance of wide bore channels compared to narrow ones is given by expressing the results in terms of the aggregate cross-sectional area, calculated from the mean cross-section x "Score".

COMPARISON OF THE AGGREGATE CROSS-SECTIONAL AREAS PRESENTED BY ANASTOMOSES IN NORMAL HEARTS AND IN CORONARY ARTERY DISEASE, GRADES A, B & C.

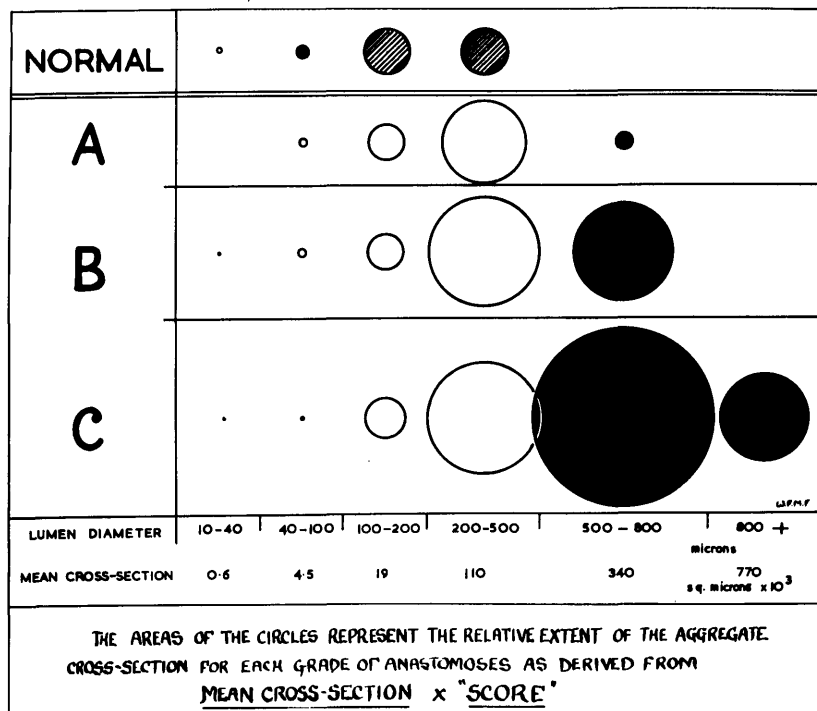


DIAGRAM 4:8

In order to take the matter further and to express the findings in terms of blood flow, the values represented by the circles in Diag. 4:11 were derived from the calculation:-

Resistance to flow varies inversely with (mean diameter)<sup>4</sup> x "Score".

This value, for the range of values involved, roughly corresponds to:-

$$\text{Capacity for flow} \propto \text{Mean cross-section}^2 \times \text{"Score"}$$

The significance of the findings contained in these graphs will be discussed later (page 4: 89 et seq ).

There are a number of other considerations which arise in the critical interpretation of the graphs. For the most part these are unimportant but are included for completeness:

(1) The nature of the calculation has in all respects avoided exaggerating the picture. Thus an index of 123100 might have been expressed 2 7 18 2 0 0 if the average of each value had been taken for +, ++ and +++ instead simply of the number.

(2) Between the four groups there is moreover a slight qualitative difference which may be kept in mind when comparing the information contained in Diag. 4:6-11. In the majority of hearts in all groups the filling of the arterial tree with injection medium was up to standard, as described in Chapter 1. That is to say, filling was regular down to vessels of 40 microns lumen diameter, and the great majority of arterioles were filled to 20 microns diameter, and less. Only two cases in Group Ia and none in Group IIa failed to conform to this standard. On the other hand 6 out of 15 cases in Group IIIa and 6 out of 22 cases in Group IVa showed occasional instances of arrest of filling at arterial diameters of 50 microns diameter and over. It is therefore probable that the relatively smaller numbers of anastomoses recorded in the first 3 columns of the anastomoses counts of Groups III and IV is partly accounted for by inclusion in these groups of a higher proportion of cases in which the injection had been slightly below standard. It is unlikely that these considerations have had any influence on the recorded incidence of anastomoses of calibre greater than 200 microns in diameter.

(3) Quite apart from the standard of injection technique in other respects, it would seem that the demonstration of interarterial anastomoses of fine calibre is less readily achieved where similarly placed communications of larger bore are present in the same area. This is understandable on the grounds that the resistance offered by a vessel of narrow bore is disproportionately higher than that offered by a wide-bore channel (v. Poiseuille's Law, ) so that flow of blood during life, and of opaque medium during injection, will tend to follow the channels which offer the least resistance. As in the French story, the kitten does not necessarily enter by the small hole under the door when one big enough for the cat is available.

These points have been raised in order to forestall deductions beyond the scope of the evidence. It might be concluded from examination of the graphs alone that anastomoses of very fine calibre (less than 100 microns in diameter) were less frequent in the presence of cardiac disease than in normal hearts. It cannot be denied that this may be so and indeed would be not only interesting but also susceptible to explanation were it the case. The point must however be left in uncertainty.

The converse position is of greater importance and rests on more secure ground. It is of interest to note from Diag. 4:6, 7, 9, 10 that the anastomotic patterns of the several groups show a difference not so much of number as of calibre. There has, so to speak, been a "shift to the right" with increased severity of cardiac and coronary artery disease.

The important conclusion may be reached that sufficient numbers of small scale arterial anastomoses are already demonstrable in the healthy normal coronary circulation to account for the numbers of large scale anastomoses found in disease. Whether these large scale anastomoses do in fact arise from enlargement of pre-existing arterial communicating channels is another matter and will be considered later.

CHARACTER OF ANASTOMOSES

## (a) NORMAL

The appearance of anastomoses in the normal heart varied somewhat with their size and site. Those situated on the epicardial surface were often tortuous, with a corkscrew or "spirochaetal" appearance, but many were straight. Occurring in the deeper layers of the heart muscle they were usually fairly straight and showed little change in calibre throughout their length. Nussbaum (1912) commented on their straight ~~course~~ and lack of branches. I have confirmed that this is true in the case of anastomoses of very narrow bore. But in others finely penetrating injections have revealed that a number of very fine arterioles of short length may be seen to arise from them at right angles, when viewed at magnification (Fig. 4:8B). These arterioles of 15 microns diameter and less may not be clearly recorded on the radiograph but can be seen with certainty in the cleared specimen examined by the dissecting microscope.

## (b) ABNORMAL

In advanced coronary artery disease greatly enlarged anastomoses were found. When on the epicardial or endocardial surfaces or in the thin-walled atria, they tended to be exceedingly tortuous, presenting an appearance which was characteristic. The eye soon learnt to recognise them on the radiograph before their truly anastomotic character had been traced. In the depths of the ventricular myocardium (e.g. in the interventricular septum) the degree of tortuosity was very much less, and was little more than could be straightened out by stretching the muscle to its normal anatomical limit before taking the

radiograph. The tortuous superficial anastomoses could not readily be straightened out in this way.

In the histological section, the walls of vessels which were believed to be anastomoses were exceedingly thin, being composed of little more than an endothelial lining, supported on a thin fibrous tunic, in which elastic tissue was scanty and only occasional isolated muscle cells were found. Even when such channels were expanded under the influence of disease to a diameter of 500 microns and more, the wall remained a thin structure as described. "Collaterals do not develop an arterial coat but are similar to greatly dilated arterioles." (Gregg, 1950, based on Mautz & Beck, 1937.)

The structure of anastomoses of large size is consistent with their development from pre-existing smaller arterial anastomoses. Although more is to be said on this matter later, I hold this to be the usual origin of the large anastomoses found in disease. The question of the formation of "new" anastomotic channels from capillaries is less clear and is conveniently dealt with at this point.

#### The origin of arterial anastomoses from capillaries

On theoretical grounds alone it cannot be denied that anastomotic channels of arterial type may arise from dilatation of capillaries. After all, such is a common process in embryonic life. If some of the findings of the Boston workers who have employed the Schlesinger technique are to be accepted without qualification, then we must conclude that this process also accounts for the development of interarterial anastomoses in adult life. I doubt however that this is the usual process if it indeed occurs:-

1. As already indicated, it is not necessary to invoke the capillaries, because the interarterial anastomoses of the normal heart are numerically sufficient.
2. All gradations from small calibre interarterial communications to those of large dimensions can be traced.
3. Communications which seem to have developed through dilatation of capillaries are of different character.

In regard to the last point, widespread dilatation of capillaries was observed in the presence of myocardial ischaemia, under certain conditions. When this happened the picture presented was distinct from the usual pattern presented by arterial anastomoses. An example is shown in the cross section of case 19, Fig. 4:50, in which the pattern of the grossly dilated arterial vessels composing the subendocardial network can be distinguished from the background of dilated capillaries, or "sinusoids", as they have now become. This appearance has been found in a few cases only in this investigation, and has not been described in any of the published works referred to. It is only demonstrated by an injection technique of fine penetration, for the sinusoids are of narrow calibre, about 10-30 microns diameter. They communicate with one another in the step-ladder fashion of normal capillaries, from which they are with little doubt derived. The numbers of occasions on which this appearance was well marked (2) is too small for its significance to be assessed. But on these two occasions the dilatation of capillaries of this order was confined to areas which had evidently suffered damage in the form of multiple small foci of necrosis with subsequent fibrotic replacement. In such areas the fibrosis was extensive but not confluent. In the meshes of the fibrous tissue, surviving muscle tissue or granulation tissue supported the capillary network. A similar appearance in much less extensive form was seen at the margins of larger healed infarcts in a few instances; but it was not seen in recent

massive infarction where necrosis of the capillary bed had accompanied the destruction of muscle elements (cf. Snow et al. 1955).

Dilatation of the capillary bed as described was only found within an area of severe ischaemia. It was never found in the neighbouring territories that were well provided with arterial supply. By contrast, enlargement of the normal arterial anastomotic pattern was often prominently developed in these areas.

---

\* "The potential mechanisms for collateral reactions are the opening of pre-existing, but non-functioning collaterals by an increased differential pressure, metabolites and nerve action, or the formation of new collaterals..... whether the subsequent further increase in retrograde flow is through the same collaterals or through newly formed channels, or whether the latter ever develop, has never been determined."

Gregg, 1950.



### SOME CONCLUSIONS

In summary, the stereo-arteriograms of this investigation were prepared from injected specimens, using a mass which had reliable properties of penetration, and a method that allowed visualisation of vessels down to 20-30 microns in diameter. Detail of the finer arterioles was inspected stereoscopically at a magnification of x5. The results obtained depend upon these points.

Examined by this technique, it was seen that some intercommunication of vessels at a pre-capillary level was the rule, not the exception, in the normal coronary circulation of man. Arterial anastomoses of 20-200 microns in diameter were abundant. Anastomoses of the order of 200-300 microns in diameter were commonly found in smaller numbers and in the sites that have been described in detail.

Conversely, on the basis of the demonstration afforded by this investigation, it may be stated that true anatomical end-arteries are the exception in the coronary circulation, both under normal and abnormal conditions; and that fine arterial communications at a pre-capillary level exist in all parts of the human heart. The observations on coronary anastomoses of Spalteholz, Gross and others have been confirmed. The failure of some other workers to demonstrate anastomoses in the normal heart is thought to have arisen from inadequacies of technique.

The evidence so far presented further suggests that the large-scale arterial anastomoses, which provide means of alternative blood supply in established ischaemic heart disease, are for the most part -

if not exclusively - formed from the enlargement of pre-existing, normal, interarterial communications. Diagrams 4:6, 7, 9 and 10 show that the fine pre-capillary anastomoses found in the normal human heart are numerically sufficient to account for the larger channels found in disease. The main difference in the anastomotic pattern found in groups of normal and abnormal hearts was one of calibre rather than of number.

COMMENTS ON THE ARTERIOGRAPHIC DEMONSTRATION OF  
CORONARY ANASTOMOSES OF SMALL CALIBRE:  
with critical reference to the  
Schlesinger technique

"It is definitely pertinent to our discussion to mention that the data obtained on this question by the employment of a given technique can never be more accurate than the method itself."

Gross and Kugel, 1934.

A marked discrepancy has already been noted in the reports by various authors on the occurrence of anastomoses in the normal human heart. To a large extent the discrepancy lies between observations based on the Schlesinger technique, or some modification of it, and observations based on some other method, including that used in the present investigation.

In view of the numerically large series in which the Schlesinger technique has been employed, it is of no small consequence that the negative conclusions to which it has given rise be critically assessed. Accordingly space is devoted in this section to a discussion of the reliability of the Schlesinger technique for the demonstration of coronary artery anastomoses of small calibre. Opportunity will also be taken to introduce some points of detail which arose during the course of my own investigation.

The Schlesinger Technique

a. Technical details: The coronary arteries are injected under controlled conditions with a radio-opaque medium composed of lead phosphate in agar. A method of partial dissection is then employed by which the heart is "unrolled" into a slab a single wall in thickness.

This has the advantage that on the subsequent radiograph the major arteries are presented in a single plane. In the process of "unrolling" the heart the interventricular septum is excised. A single radiograph of the injected heart is taken and the two dimensional arteriogram so obtained is used as a guide to the dissection of the coronary arteries. Dissection is made with fine pointed scissors and is aided by the presence of injection medium in the arteries. Red and blue dyes are incorporated in the injection medium introduced into the right and left coronary arteries respectively and, in the presence of communication between the coronary arteries, mixture of these colours may occur.

Three types of proof were accepted as evidence of arterial anastomosis (Schlesinger, 1938, Zoll et al., 1951).

- "1. Demonstration of a continuous, stained, epithelial-lined, connecting channel filled with mass between two coronary arteries.
2. The presence of injection mass of any colour distal to a complete occlusion.
3. Visualisation of a mixture of colour in the injection mass."

The conclusions in regard to anastomoses in the normal heart, based on the evidence provided by the Schlesinger method of examination, have already been indicated and are again briefly stated. In the original series (Schlesinger, 1938) no communication was found to exist between the coronary arteries in normal hearts. The situation has been modified by the examination of greater numbers and 23% of 224 grossly normal hearts showed the presence of anastomoses (Zoll et al. 1952).

b. Critical discussion of the inferences based on the Schlesinger technique: Provided that one or more of the criteria already quoted for the recognition of anastomoses has been satisfied, the evidence supporting the presence of interarterial anastomosis in a given heart is indisputable. Interpretation of the absence of such evidence is however a very different matter. Before the absence of demonstration can be taken to mean the absence of structure, the limits of the technique employed must be very carefully assessed. In the succeeding pages the limits of the Schlesinger technique and the validity of the evidence upon which certain conclusions have been based are subjected to detailed critical analysis.

It has been generally accepted (Zoll, Wessler, Schlesinger, Freedberg, and Blumgart, 1952, and by many others) that some form of communication normally exists between the two coronary arteries. The question presently at issue is at what level or levels, and to what extent, does communication take place in the normal coronary circulation. According to the authors quoted above, communication is at a capillary level only, in the majority of normal hearts, although in some (23%) arterial communication also exists. The steps in the argument by which their conclusions were reached are of interest.

The medium employed did not penetrate capillaries. Mixing of the two differential colours therefore gave sound evidence of communication at an arterial level between the coronary arteries. The radiological technique did not provide demonstration of injected vessels less than 200 microns in diameter. It was found further that admixture of colours could take place, notwithstanding the failure of radiology (and dissection) to provide evidence of anastomosis. Accordingly it

was inferred that the size of the communicating vessels must lie between 200 microns in diameter and capillary level. So far this seems to follow logically from the evidence made available by the technique employed.

But the argument has been taken further. It has been asserted that the absence of colour mixture implied the absence of communications greater than 40 microns in diameter. This conclusion was evidently based on two assumptions:-

1. the filling of the smaller arterial vessels with injection mass was uniform.
2. the filling of arterial anastomoses was as uniform and regular as that of other vessels.

I shall first examine the evidence upon which these assumptions were based.

In regard to the penetration of the injection medium, we read that:-

"The lead agar mass used in this investigation was regularly found in vessels as small as 50 microns in diameter, irregularly penetrated as far as vessels from 40 to 10 microns in diameter but was not found in vessels under 10 microns in diameter. These measurements were made on stained microsections prepared from tissue fixed in formalin and embedded in paraffin; they are therefore subject to a correction of about 50 to 100% for shrinkage from the unfixed state. Vessels down to 200 microns were visualised on the radiograph." (Zoll et al., 1951).

This is essentially the same description as appears in Schlesinger's original article (Schlesinger, 1938).

The operative word in this statement, upon which much depends, is regularly. One might wish to know on what grounds penetration of the injection medium has been assumed to be "regular", when the vessels

under consideration were too small to be visualised radiographically; and accordingly no picture of the arterial "tree" was obtained at this level. The validity of this, and certain other, assumptions is perhaps best judged in the light of personal experience with injection methods. Accordingly I shall approach the criticism of certain features in the Schlesinger technique from the standpoint of observations made in the course of my own investigation.

Some technical points which arose in the present investigation

The technique which I employed has already been described in detail in Chapter 1. In the early phase of the investigation however experiment was made with a variety of materials and methods - with a variety of grades of unsatisfactory result. This period of experiment had the advantage of providing familiarity with the artefacts of filling which may be encountered in arterial injection.

In the earlier cases it was usual to find, for example, that the terminal arterial twigs, as seen on the radiograph, appeared to end abruptly, as if they had been pruned. It may be noted that even the more satisfactory published coronary arteriograms present this appearance. In some instances the defect has been exaggerated by the poor resolution of detail obtainable on half-tone block reproduction. In others it is evident that the standard of injection itself has been responsible for the truncated appearance of the arterial tree. Where my injection was sub-standard, only occasional communications were clearly demonstrated in the "no-man's land" between adjacent arterial territories, and others were recognisable in the stereograms though imperfectly filled. An example is shown in Fig. 4:15 of an injection

of the minimum standard acceptable in this series as a whole, but insufficient for inclusion in Group Ia. It may be compared with an arteriogram of optimum quality, also from the septum of a normal heart (Fig. 4:14).

In some cases the overall picture suggested regular penetration down to the finest vessels - when viewed in two dimensions. Close scrutiny under the stereoscope often showed that the level at which filling was arrested varied widely in the same specimen. Viewed in this manner at magnification, a sometimes surprisingly large number of vessels showed abrupt arrest of filling at 40 to 200 microns diameter. Indeed only where the great majority of arterioles had been filled to 15 microns and less, was there no evidence on the radiograph of arrest of filling at a level greater than 40 microns. It was concluded that if an injection mass of the type employed is to achieve reliable filling of all vessels of a given diameter (40 microns for the purposes of this argument) it must also fill the majority of their branches down to a considerably finer level. This requirement was fulfilled by the medium used in the greater part of this investigation.

Estimation of the regularity of filling of the smaller vessels from inspection of histological sections was considered to be far less reliable than was estimation based on the magnified stereo-radiographic picture. In the examination of histological sections no element of accuracy was felt in judging the potential lumen diameters of contracted small vessels into which injection medium had not entered; nor indeed in determining their arterial or venous nature. It is however on microscopic sections that Schlesinger and his co-workers make their



estimate of the "regularity" of filling.

While these remarks throw doubt on the reliance that may be placed on statements based solely upon histological evidence in regard to the penetration of an injection medium into small arterial vessels in general there is another consideration of great importance in the filling of anastomoses in particular. In my experience anastomoses of fine calibre are more difficult to fill completely than are vessels of similar diameter which branch dichotomously from the parent stem. In a given specimen it may be found that the majority of arterioles, leading directly and in tapering fashion from small arterial branches, are filled down to 20 microns diameter; while the long, cylindrical and often tortuous, communicating channels of 50-100 microns diameter are incompletely and inconsistently filled. Explanation can be offered for this. It would seem that more than one factor is involved.

During the injection of the unobstructed coronary arterial circulation, the pressure at the two ends of an anastomotic channel must be approximately equal, where that channel connects branches of the same artery. Accordingly the gradient of pressure favouring flow along such an anastomotic channel must be very low. It is of course possible to create a gradient of pressure between the right and left coronary arteries, so that those anastomoses which connect branches of the two arteries will be filled from one of them. This is well established practice in injection technique; but it must be emphasised that this manoeuvre cannot influence the filling of anastomoses within the territory of either artery, i.e. anastomoses running between the

branches of the same artery. The filling of these anastomoses depends upon penetration of a very fine order, aided perhaps by gentle massage during injection.

Of course, the creation of an artificial obstruction, as by ligation of a given major arterial branch before injection, can favour flow of the medium into the distal portions of that artery through anastomoses which communicate with the arteries of neighbouring territories: just as blood flow through such anastomoses is promoted by the same mechanism during life, where the arterial occlusions are due to disease. A procedure of this sort is not practicable in the injection of the heart as a whole, nor is it necessary. It was however carried out in a few instances as a matter of interest and also in response to the challenge offered by the following statement:-

"We have repeatedly found that in the normal heart, the ligation of a single vessel just previous to injection never results in anastomotic injection beyond the ligature."  
Schlesinger (1938).

This ligation experiment was performed during the present investigation on three hearts, two of which were normal, aged 8 and 43 years, and one which was outwardly normal but was found to have a minor degree of mitral valve disease. In two the anterior descending artery was ligated with double ligatures and in the other an unusually large left marginal branch was chosen. In each case filling of the distal portion of the occluded artery was visible in the periphery of its territory within 5 seconds and retrograde spread of medium reached the site of ligature in 10 to 20 seconds. The injection pressure used at this stage of the procedure was 80-100 mm.Hg. (see Figs. 1:4,4b). Subsequent radiography showed filling beyond the occlusion indistinguishable from

that of other vessels (apart from dilution in the few mm. distal to the ligature). It may be noted that these findings were made with a medium that (a) does not pass through the normal capillary bed and (b) has properties of penetration into small vessels which are only slightly greater than are the properties recorded for the lead agar mass used in the Schlesinger technique.

This minor variant of injection technique is not in itself important but it is recorded here because its employment serves to illustrate, more dramatically than does a more detailed critical evaluation of the quoted measurements, that a considerable qualitative difference exists between the Schlesinger technique and the technique employed in this investigation.

#### Concentration of injection mass and silting

There are further technical details which bear upon the difficulty in obtaining satisfactory filling of narrow anastomotic channels. Although the larger anastomoses often show fine branches leaving them nearly at right angles, communicating channels of the finest order usually appear to be unbranching (see page 4 : 34 ). It can accordingly be understood that the columns of injection medium entering the opposite ends of a long narrow anastomotic vessel simultaneously and at the same pressure may make only slow progress along its length. As the injection proceeds, the solid portion of the medium becomes more concentrated, as the result of loss of the fluid portion through the thin walls of the finer vessels. Eventually the viscosity of the medium increases to such an extent that the ends of the narrow

anastomoses become choked up and no available gradient of pressure is sufficient to force the injection medium along them; although it could readily have flowed through them during an earlier phase of the injection, at a time when its viscosity was still low. This point has been supported by sectioning fine vessels on the surface of the heart at the conclusion of injection and observing the absence of leakage from them. Section of similar vessels early in the course of injection can give rise to troublesome leakage.

Thus, if reversal of flow in the course of injection is overlong delayed, and concentration of the medium at the ends of the finer intercoronary anastomotic channels causes even them to become silted up, it can be understood that this happens still more readily in the less favourably placed anastomoses which connect the branches of the same artery.

The radiographic recognition of anastomoses:  
three-dimensional v. two-dimensional arteriography

In regard to the recognition of anastomoses we read that:-

"Indisputable demonstration of grossly dissectible pathways in this way (i.e. by dissection) was possible in only about one-fifth of the hearts in which anastomoses were accepted as present." "It was found that roentgenograms alone could not be relied upon to prove the existance of such communications." "Smaller anastomoses 60-70 microns in diameter could be traced along their entire course by laborious study under the dissecting microscope in tissue cleared by Spalteholz's technique or by reconstruction of a complete series of microscope sections.\* Vessels of this calibre were not visible on the roentgenogram." (Zoll et al., 1951).

---

\* (There is nothing to suggest that either of these procedures were actually undertaken by this group of workers.)

It may be recalled that a single, two dimensional arteriogram is employed in the Schlesinger technique, and accordingly it is not surprising that little reliance has been placed upon it for the recognition of anastomoses.

When high-quality, stereo-radiographs are viewed at sufficient magnification, I am satisfied that reliance can be placed on their interpretation in regard to the recognition of arterial communications. This is in direct contrast to the opinion quoted above, which echoes the statement of Schlesinger (1938) that "no final decision as to the patency or occlusion of any vessel can be made from the roentgenogram alone". Explanation of the discrepancy between these observations and my own partly lies in the superiority of three-dimensional representation over the single, two-dimensional roentgenogram.

A certain reflection on the quality of arteriography is contained in the following statement by Zoll et al. (1951): "Anastomoses could be clearly demonstrated on careful dissection that were not visible on the arteriogram". This is a surprising comment. In my experience the demonstration of small scale anastomoses by dissection is less reliable than by stereo-radiography. Even with the dissecting microscope, after rendering the tissues semi-transparent in glycerine, the tracing of vessels of diameter less than 200 microns is difficult and tedious in the extreme, except where they lie close to the surface. In any event this is a method which is necessarily incomplete. It carries the further disadvantage that during dissection damage is only too easily inflicted on delicate vessels; so that the evidence often cannot be preserved. The dissection of numerous long, often tortuous and overlapping communications of the order of 100 or even 200 microns in

diameter is clearly outwith the scope of any reasonable examination. As has been seen, the great majority of anastomoses which I found in normal hearts were of this order.

#### "Incidence" of anastomoses

A final point about the Schlesinger technique. It will be noted that the authors who have employed this technique are unable to give detail of anastomoses in the normal heart and record only incidence of anastomoses, i.e. the presence or absence of anastomoses, as an absolute finding. In view of the virtual impossibility of tracing innumerable fine branches through the substance of the myocardium by dissection, and in view of the absence of radiographic visualisation of vessels less than 200 microns in diameter, some vagueness about the actual size, site and numbers of anastomoses in the normal heart is understandable. It is only surprising that any dogmatic statement has been hazarded at all.

#### Conclusions

From the foregoing remarks it will be appreciated that:-

1. Filling of tapering vessels down to 20 or 30 microns lumen diameter is not inconsistent with failure to fill long anastomotic channels of considerably larger calibre.
2. The published arteriograms of the heart that have been examined and also those obtained in the preliminary stages of this investigation can be misleading in this respect, that the majority of normal coronary arteries are demonstrated as "true Cohnheim end-arteries".

3. Judging from the published results it is evident that the Schlesinger technique is inadequate for the demonstration of anastomoses less than 200 microns in diameter; and the negative conclusions, which have been based upon it in regard to the incidence of anastomoses in the healthy coronary circulation, should be interpreted accordingly.

Addendum: It may seem that in this section an undue amount of ammunition has been expended on a single target. Simply to state, however, on the strength of my small series, that I differ on this fundamental point from those already quoted, whose opinions have been based on a great many observations, would be to invite unfavourable assessment of my own findings, on grounds of numbers alone. Thus I have felt it necessary, in the face of numerically much larger series, not only to indicate the grounds for my own opinions, but also to explore point by point the weaknesses in the structure upon which differing opinions have been supported.

In doing so I wish to stress again that the limitations of the Schlesinger technique in the demonstration of anastomoses of fine calibre do not upset the validity of observations made by its employment on some other aspects of coronary artery disease; nor the value of the contributions based on them. These contributions have been considerable, and some have been referred to in other parts of this thesis.

---

Further notes: 1. After the preparation of this manuscript,

Laurie and Woods (1958) reported on a series of hearts perfused by one artery using a method otherwise related to the Schlesinger technique. They come to the conclusion that "of 150 Bantu patients functionally significant anastomoses were present in 75% of normal hearts from patients over 4 years of age but in only 23% of hearts from patients with chronic ischaemic heart disease". (!)

The underlining and exclamation mark are mine.

2. Using wax spheres, Pitt, 1959, found anastomoses in only 1 out of 15 normal hearts.

#### Experimental observations

In the experimental field the problem has been approached in several ways. Firstly there is the observation that ligation of a major coronary artery in the dog can be sustained and that the resultant area of myocardial infarction may be considerably less in extent than territory of the occluded artery (Linton, 1957, and others). This has been taken as evidence that in the normal dog heart there is sufficient interarterial communication to permit survival of myocardium entering an area with normal blood supply when the supply through the normal channels has been cut off. If the artery distal to the closure be cut, a measurable retrograde flow may be observed and is arterial in character (Gregg, 1954).

Prinzmetal (1948) injected radio-active erythrocytes into the blood stream of the living dog after ligation of a major coronary artery and



DISCUSSION OF THE SIGNIFICANCE OF ANASTOMOSES  
OF THE NORMAL HEART

Evidence has been presented which bears on the anatomical nature position and frequency of interarterial anastomoses in normal and abnormal hearts. The conclusion has been expressed with conviction that the coronary arteries are not end-arteries in an anatomical sense. Conclusions in regard to their functional importance on the other hand cannot be reached with the same degree of assurance. Particularly would this seem to be the case where the observations have been anatomical and not experimental. The experimental approach nevertheless has its own important shortcomings.

Experimental approaches

In the experimental field the problem has been approached in several ways. Firstly there is the observation that ligation of a major coronary artery in the dog may be survived and that the resulting area of myocardial infarction may be considerably less in extent than the territory of the occluded artery (Hirsch, 1907, and others). This has been taken as evidence that in the normal dog heart there is sufficient interarterial communication to permit survival of myocardium (bordering an area with normal blood supply) after its supply through the normal channels has been cut off. If the artery distal to the ligature be cut, a measurable retrograde flow may be observed and is arterial in character (Gregg, 1950).

Prinzmetal (1948) injected radio-active erythrocytes into the blood stream of the living dog after ligation of a major coronary artery and showed that they were centripetally distributed throughout the territory

of the ligated artery in a matter of seconds.

In the living heart therefore it has been shown that collateral blood supply exists; but detail of the channels through which the abnormal flow of blood has taken place cannot be revealed by such experiments.

#### Post-mortem perfusion experiments

Attempts at quantitative measurement of intercoronary flow have been made in the heart perfused after death. It has been well known for a long time that fluids of the viscosity of blood, or less, can be made to pass from one coronary artery to the other, both in normal and in abnormal hearts.\* Crainicianu (1922) using serum as the perfusion fluid, developed the concept of the "coronary coefficient". Other workers have used kerosene (Dock, 1941, Prinzmetal, 1942), and radio-opaque gelatine (Dock, 1941). In order to discover the maximum diameters of such vessels in the normal heart, Prinzmetal (1947) perfused with a medium in which were suspended graduated glass spheres. His estimate of 70-180 microns lumen diameter for interarterial communications by this method is roughly - and somewhat remarkably - on accord with my own findings.

These methods reveal only the degree of anastomosis that exists between the two main coronary arteries. They can give no information about anastomoses which connect branches within the distribution of either artery. This is a serious limitation; for it may be just such anastomoses which have the greatest importance in individual cases of coronary disease.

---

\* Lower (1728) perfused fluid from one coronary artery to the other.

None of the methods directed to the measurement of flow, experimental or using post-mortem perfusion, can indicate the numbers, sizes or sites of the communicating channels.

#### Function inferred from structure

On the other hand the present anatomical demonstration of inter-arterial anastomoses does provide a picture of the dimensions, number and sites of these vessels; but can in its turn give no direct measure of blood flow. Indeed, only a conjectural conception of their functions during life can be derived from study of the anatomical features of channels examined after death. That is not to say that opinions so derived are not valid, but that they cannot be held without reservation.

A great deal is already known about the coronary circulation and its responses under a variety of circumstances, so far as total volume flow is concerned, or the conditions of flow in a major coronary artery on the surface of the heart. There is little knowledge about the detailed condition of blood flow in the smaller vessels in the depths of the myocardium. Yet it is here, in the deeper layers, that the majority of arterial communications occur; and here is a field the experimenter cannot enter with impunity. Accordingly we must still depend upon indirect evidence from which to derive a detailed concept of blood flow in the depths of the myocardium, and of the functional status of anastomoses in the normal heart. Intramural coronary blood flow cannot be measured directly but "can only be inferred from judicious consideration of differential pressures in the central and peripheral ends of a coronary artery" (Wiggers, 1949). The underlining is mine.

For I submit that indirect evidence is also provided by the study of the detailed structure of the deep vessels of the heart as revealed in this examination.

Accordingly I shall attempt to reach some conclusions about the conditions of blood flow in the smaller arteries of the beating heart, from a study of anatomical structure and later of pathological structural change. In doing so I acknowledge the need for caution in accepting conclusions so derived. But I would also submit the opinion that arguments based upon a functional interpretation of structure studied in comprehensive detail are in no greater degree fallacious than are arguments based on direct observations in life that have necessarily been of a fragmentary nature.

If injection medium is introduced into one coronary artery at a higher pressure than into the other, as in this investigation, or if an artery is ligated in the beating heart while blood flow into the rest of the coronary circulation is unimpeded, abnormal gradients of pressure are set up between neighbouring arterial territories. Some hold the view that the passage of injection medium or, as the case may be, of blood containing radio-active erythrocytes, from one territory to another reveals only the presence of communicating channels and does not prove that blood flowed through them during life.

"The fact that an artery can be injected post mortem from another artery is no evidence that the living blood follows the course of the post-mortem injection", wrote Pratt in 1898. Again, in a destructively critical article on the functional status of coronary collaterals, Wiggers (1950) cites the following excerpt, with which he is apparently in agreement:

"The passage of a fine injection mass from one vascular area to another proves nothing concerning the possibility of one area receiving its blood supply from the other. Such a supply is impossible if the resistance in the communicating vessels is greater than the blood pressure in the smaller branches of the artery through which the blood supply must come. It is a fact that this high resistance is due to the small size of communicating branches which makes the artery terminal."  
(Porter, 1901)

To my mind these statements are unwarrantably absolute. Indeed, not only do I think it likely that some measure of blood flow may readily pass through normal collateral channels (such as I have observed) under the influence of abnormal gradients of pressure, but also I contend that the very existence of such channels is tantamount to proof that blood did actually flow through them during life, under normal circumstances. I acknowledge that the volume of flow may well have been very small; but had the flow ceased completely, obliteration would surely have been their fate.

I propose to start from an hypothesis that the calibre of a healthy arterial channel bears a close relationship to the flow volume of blood it has been accustomed to carry during life; and to test this hypothesis against the detailed findings that I have made in the coronary circulation. As will be examined later in this chapter, correlation between blood flow and vessel calibre in coronary disease is not always simple. But I would suggest that a search for correlation between structure and function is more likely to lead in the direction of biological truth than is an argument founded on denial of their association.

(1) Is it reasonable to suppose that blood does pass through anastomotic channels under normal circumstances?

In order that blood shall flow through an anastomotic channel, a gradient of pressure must exist between its ends. Can such a gradient be expected, where the blood enters both coronary arteries from the aorta at the same moment and at the same pressure? The following points have bearing on this question:

a. During ventricular systole a gradient of pressure must exist between the deeper and more superficial layers of the ventricular wall. This has been demonstrated experimentally by Johnson and di Palma (1939) in the left ventricle of the cat.

b. During ventricular contraction there must likewise exist a difference in intramural pressures between the left and right ventricles, consonant with the pressures within their chambers.

c. The route taken in terms of distance, angulation and calibre of vessels traversed must rarely be identical when the same portion of myocardium is approached from two different directions.

It would be surprising, in the face of these factors, if there were no pressure gradient at all between the ends of anastomotic vessels at any phase of the cardiac cycle. Indeed, is it likely that chance alone shall dictate that numerous interarterial anastomoses are to be found characteristically at certain sites (as, for instance, in the anterior wall of the right ventricle, close to the interventricular septum and left ventricle, and in the region of the apex)? At these sites the arterial territories supplied by the right coronary artery and the anterior descending branch of the left coronary artery meet. The blood

enters these two arteries at the same pressure; but there is without doubt greater resistance to blood flow offered during systole by the high intramural pressure of the left ventricle than is present in the right. It is probable that during systole a gradient of pressure from left to right favours flow through channels which link the territories of these two arteries. This would explain the prominence of anastomoses at these sites on a sound functional basis.

Conversely, the existence - or persistence - of such channels at these sites is strongly suggestive that blood did course through them during life. At other parts of the right ventricle, where one would not expect such differences of intramural pressure to exist, anastomoses are less in evidence, or even absent.

Under abnormal circumstances the same principle is more dramatically illustrated. In coronary artery disease it may be observed that the establishment of an abnormal gradient of pressure, favouring flow from a well-supplied to an ischaemic area, is accompanied by the development of greatly enlarged arterial anastomotic channels. This phenomenon receives closer examination later.

In the depths of the left ventricle are found numerous anastomoses. Explanation of their existence in terms of the relationship between vessel calibre and blood flow is not so readily reached as in the instance first cited. Indeed the explanation that will be set forward later is somewhat complex. The principles involved are more suitably considered after the situation found in advanced coronary artery disease has been described. Accordingly discussion of the conditions of blood flow in the normal deep arterial plexus will be deferred until it can be included with the abnormal (page 4:74 et seq.)

It sometimes happens that the search for understanding of the changes in disease may in turn lead to new interpretation of the normal situation, or at least to an increased awareness of the latent significance of normal structures. Such was my experience in seeking an explanation for the paradox of grossly dilated subendocardial anastomoses in the presence of greatly impoverished blood supply. (See page 4: 72 et seq.)

(2) What is the significance of arterial anastomoses in the normal heart? Are they not too small to make important contribution to the heart's blood supply? Do they indeed serve any useful purpose at all? And if not, why then should they exist?

Without doubt arterial anastomoses can be regarded as a beneficent provision of nature. Latent in them resides a potential source of collateral blood flow, to meet the exigencies of obliterative coronary artery disease. A teleological explanation for their existence along these lines is however scientifically unacceptable. Again, natural selection is unlikely to take part in the development of a protective mechanism which can only uncommonly have importance for the survival of the species. Coronary anastomoses have been demonstrated moreover in lower animals, in which coronary occlusion does not occur in the ordinary course of events. Explanation must lie in other directions.

In the embryological development of arteries in general, as for instance in the limbs, a retiform stage is found (Woolard, 1922). The retiform arrangement is preserved in the capillary bed, but in course of time it becomes less obvious in the arteries themselves. Indeed in some it would seem to be lost altogether. (Such could truly be termed end-arteries in an anatomical sense.) Spalteholz (1907) compared the arterial network in the coronary circulation to that which he had already demonstrated in the skeletal muscle of the trunk.



In the kidney, by contrast, the preglomerular interlobular arteries do not seem to communicate. (This is a limited personal observation based on post-mortem injection, which tallies with the clear-cut delimitation of embolic renal infarcts.\*) The internal immobility of the kidney contrasts with the active contractile movements of the myocardium and of skeletal muscle. Perhaps therein lies a factor the presence of which favours the preservation of pre-capillary network, while its absence allows atrophy of intercommunicating channels.

I contend, therefore, that the patency of intercommunicating channels is maintained by differential blood flow. The necessary interarterial pressure gradients can be provided by muscular contractions. Arterial anastomoses exist in the normal heart because the intrinsic circulatory conditions created by cardiac contraction prevent the atrophy and disappearance - which would otherwise be their natural lot.

Their usefulness under pathological conditions has nothing to do with it.

In contending that blood does in fact course through arterial anastomoses in the normal heart under normal circumstances, the point made is an academic one. Nevertheless it is also fundamental. It seems unlikely that these channels take an important part in the distribution of arterial blood to the myocardium, so long as normal conditions of coronary blood flow are maintained. Their usefulness in disease is another matter. The practical importance of normally occurring anastomotic blood flow to my mind lies in the preservation of patency of the channels which carry it.

---

\* In detailed injection studies of the kidney, Gross, 1917, and Loomis, 1936, do not appear to have demonstrated pre-capillary arterial communications in the healthy kidney. Lockhart et al., 1959 state "..... no anastomoses exist between the interlobar arteries and consequent branches till the capillary stage".

Collateral blood flow tested by naturally  
occurring coronary artery obstruction

Obstruction to a coronary artery tests the potential capacity of arterial anastomoses for augmented collateral blood flow. Where obstruction is complete, the difference between the limits of the territory of the occluded artery and the extent of muscle death might be taken as a measure of the effectiveness of arterial anastomoses in providing means of alternative blood supply. At first sight the matter would seem readily susceptible to pathological investigation; and to allow close correlation of the detailed picture of anastomoses provided by injection studies and their potential functional capacity in terms of muscle survival. But it is not so, particularly in the case of normal anastomoses.

The pathological process does not oblige the investigator by simulating the experimental ligation of a healthy artery in a normal coronary circulation. In the first place occlusion of a previously healthy coronary artery is probably a rare event in human pathology. It occurs from embolism for instance. Nearly always in the thrombotic lesions which I have examined there had been partial obstruction of the lumen before occlusion was finally made absolute. Atherosclerotic narrowing had often been present for a long time beforehand, and the abnormal gradients of pressure created by it in the arterial tree may well have caused changes in the anastomotic pattern. Again, where death was delayed following occlusion, further and more intense changes in the anastomotic pattern could result. Further, where death is immediate, the extent of muscle damage cannot be estimated. Finally, there are a host of factors other than arterial anastomoses which have bearing on the outcome

in coronary artery insufficiency.

In this series there was no instance of death following soon after complete coronary occlusion in the absence of previous coronary artery disease. There were however several cases (e.g. Case 16; see also Chapter 5 ) in which death had occurred within a few weeks of occlusion, and the previous atherosclerotic narrowing had been only moderate in degree. Myocardial infarction was extensive in these cases and the anastomotic pattern only slightly exaggerated beyond the normal. At this point the general statement may be made that a degree of anastomotic development which has departed only slightly from the normal seems usually insufficient to provide an immediately available and adequate alternative route for blood supply.

This opinion is in accord with the findings of many workers in the field of pathology. It must be remembered however that these observations have necessarily been on cases that have died. We have no knowledge of the exact situation at the time of occlusion in cases that have survived the incident, as do many. It is not as a rule possible to make more than a tentative retrospective reconstruction of a case from the pathological findings; and then only when the findings have been made in great detail. There was however one unusual case in this series which perhaps serves to illustrate the point and to suggest that a greater potential for collateral blood flow may reside in normal arterial anastomoses than is generally thought to be the case.

The case in question (No.1) is illustrated and described in the case records, Chapter 2. Sudden occlusion occurred at the age of 26 years from extensive primary thrombosis of the left coronary artery. To judge from gross

and histological features the entire coronary circulation had been free from atherosclerosis at the time of this event. One might have expected extensive infarction of the left ventricle on grounds of poorly developed collateral blood flow, but in fact there was a relatively small area of patchy fibrosis in that part of the territory of the left coronary artery most remote from alternative blood supply. At death seven years later from an intercurrent complication (cerebral thrombosis) the entire coronary circulation was seen to have been supported by the right coronary artery through large anastomotic channels. It is likely that most of the enlargement of anastomoses had taken place after, and as a result of, occlusion of the left coronary artery. There is no reason to suppose that the anastomotic pattern beforehand was other than normal, but of course there can be no certainty on these points so long after the event.

#### A. HYPERTENSION AS A FAMILY INCUBATOR

It has been repeatedly shown that anoxia has a powerful effect upon the coronary circulation. Augmentation of total coronary inflow resulting from anoxia may be two or threefold, and may be observed when heart rate and aortic blood pressure have altered. It is believed therefore that the changes in blood flow are due to vasodilatation. It is not clear whether the effects of anoxia are direct, or are mediated through neuro-humoral

CORONARY ARTERIAL ANASTOMOSES UNDER PATHOLOGICAL CONDITIONS:  
Discussion of the influences under which coronary  
anastomoses enlarge

Evidence has already been presented which shows that the enlarged anastomotic channels found in ischaemic heart disease may in fact be derived from pre-existing, pre-capillary communications.

In the section which follows, various factors are discussed which may promote increase in the size of anastomotic channels. For the most part, these factors may be considered under the headings of:

- A. Ischaemia as a passive factor, causing vasodilatation.
- B. Dynamic influence of altered conditions of blood flow consequent on (1) coronary artery obstruction and (2) other conditions, including valvular disease and ventricular hypertrophy.

I shall deal briefly with the first of these topics for it is largely outwith the scope of my own observations. The main burden of this section will concern the changes which were found in the smaller vessels of the coronary circulation apparently mainly as the result of altered conditions of blood flow.

A. ISCHAEMIA AS A PASSIVE INFLUENCE.

It has been repeatedly shown that anoxia has a powerful effect upon the coronary circulation. Augmentation of total coronary inflow resulting from anoxia may be two or threefold, and may be observed before heart rate and aortic blood pressure have altered. It is believed therefore that the changes in blood flow are due to vaso-dilatation. It is not known whether the effects of anoxia are direct, or are mediated through more subtle biochemical changes resulting from anoxia. (Gregg, 1950). The effects of

anoxia on coronary blood flow are similar, no matter whether it results from reduced oxygen saturation in the blood or temporary ligation of a coronary artery (Eckenhoff et al., 1947, Green and Wegria, 1942, Gregg and Green, 1940, cited Gregg, 1950). These observations are based on acute experiments over periods of minutes. According to Zoll et al. (1951b) an increased proportion of normal human hearts showed interarterial anastomoses in the presence of anaemia (i.e. anastomoses of a size sufficient for demonstration by the Schlesinger technique).

When the retrograde blood flow from the peripheral portion of a ligated coronary artery is measured, it is said to remain relatively constant for a few hours and thereafter to increase (x2 in 48 hours, x3-4 in 1 week), (Gregg, 1950). This slow augmentation of collateral blood flow would seem to require a mechanism other than simple dilatation for its explanation.

It is clear on anatomical grounds that great augmentation of collateral blood flow requires enlargement of collateral channels far beyond the limits of vasodilatation. It may call for an increase in diameter of 5, 10, or sometimes 20 times that found normally in anastomoses at similar sites. The process requires time, and the relationship between time and dimensions of anastomoses is traced in the next section. Here we are concerned with the influences at work (over a period of time) which lead to enlargement of these structures.

One of these influences may be ischaemia in the sense of anoxia. That anoxia may provide a potent vaso-dilating stimulus in the first few minutes is clearly shown by the experimental findings I have noted. There is little certain evidence, on the other hand, that anoxia plays an important part in

the vascular changes thereafter. Indeed, the findings quoted above do not provide clear indication that it plays much part, if any, in augmenting collateral blood flow even in the period immediately following coronary occlusion. Moreover, the influence of anoxia must be restricted to the area of ischaemia itself, and cannot account for the changes in neighbouring vessels.

The dynamic influence of blood flow has appealed more strongly to me as an explanation for the phenomena observed. Here too, however, there were findings which at first sight seemed paradoxical, and were difficult to reconcile with this theory.

B. (1) DYNAMIC EFFECTS OF CORONARY ARTERY OCCLUSION ON ARTERIAL ANASTOMOSES.

"...when the lumen of some artery has been too long obstructed or ligated, the blood busies itself in opening a wider channel for its passage in this vessel, must drive and buffet all the more into the next ones, until it has considerably dilated them to give itself room".

Richard Lower, 1669 (cited Blumgart et al., 1950)

When a coronary artery is ligated experimentally, there is an immediate fall in the pressure distal to the obstruction. In course of time this pressure rises nearly to the level obtaining in the unobstructed artery. The rise in pressure however lags behind the augmentation of retrograde collateral blood flow (Gregg, 1950). One may safely assume that a fall in pressure likewise takes place distal to acute occlusion of a coronary artery in man. There is moreover no reason for supposing that the situation differs in any fundamental way where the obstruction is incomplete, although the changes will of course be lesser in degree.

Distal to coronary artery occlusion, therefore, one may expect a fall in the resistance which normally opposes anastomotic flow from neighbouring territories. The abnormal pressure gradient so created will favour blood flow through collateral channels towards the ischaemic area. At first its volume must be small.

Where conditions favouring collateral blood flow have been operating for a considerable period of time, I have found varying degrees of enlargement of those vessels which had been carrying the abnormal blood flow. (This has also been noted by many workers, including Mautz and Beck, 1937, in the experimental field.) A point that I would stress however is that enlargement of anastomoses was prominent not only within areas of impoverished blood supply distal to occlusions, but also in the neighbouring non-ischaemic areas (e.g. Fig. 4:11,13,21 and whole heart arteriograms, Cases 1,20,21). Clearly only dynamic influences related to augmented blood flow could be operative in these areas.

Where a single artery had been occluded, enlargement of anastomoses was to be seen linking the territory of the obstructed artery with the neighbouring territories. Enlargement involved not only the communicating vessels themselves but also nearby stretches of the arterial branches feeding them. In extreme cases, such as Case 1, it was evident that even the main stem itself had shared in the increase in lumen dimensions. It seemed likely that these changes were sequels to augmented blood flow. Small vessels, including anastomoses, which were anatomically remotely placed from the territory of an obstructed artery commonly did not take part in the enlargement.

The probable course taken by the blood in life through abnormal



routes could be reconstructed from examination of the stereo-arteriograms. Close examination of the changes which had taken place in the coronary circulation, in conjunction with a study of the time relations of occlusions, gave support to the concept that blood flow itself provided a dynamic stimulus to the enlargement of anastomoses.

Table 4 : 2

INCIDENCE OF ENLARGEMENT OF BRANCHES OF UNOBSTRUCTED CORONARY ARTERIES, in response to augmented collateral blood flow carried by them to neighbouring areas of ischaemia.	
<u>Small branches</u> (4th Division and less)	23 cases
Small branches + <u>3rd and 2nd Division arteries</u>	14 "
Small and larger branches + <u>Main Stems</u>	4 "

Note 4 : 2

"Enlargement" records an impression, not a measurement. Experience in following the gradual tapering of normal coronary arteries down to the finest twigs makes it possible to recognise lumen dimensions which are outwith the normal for that site. Moreover similar vessels not involved in collateral blood flow may also be available for comparison in the same heart.

When we turn to the ischaemic area itself, an essentially similar pattern of vascular change may be found. In my specimens, widespread enlargement of available intercommunicating channels was prominent, especially where regional ischaemia was of long standing. In this way

the relief blood supply through anastomoses at the margins of the ischaemic area was distributed to all parts.

For the most part superficial anastomoses contributed to the collateral supply only at the margins of the ischaemic area. Deeply placed anastomoses on the other hand were responsible not only for bringing new supply but also to a large extent for its distribution within the ischaemic area. The part played by the subendocardial plexus was brought into prominence in this investigation. Its recognition was favoured by the use of transverse sections of the ventricles and the preparation of arteriograms from them. Some of the changes in the small vessels of the heart, occurring in relation to ischaemia distal to occlusion, are best demonstrated in transventricular sections. Some of these accompany the following brief description of the changes in the subendocardial plexus in disease. The anatomical features of the subendocardial plexus of the left ventricle have already been described, with illustrations, earlier in this chapter.

Some examples of changes in the deep vessels  
in coronary artery disease

In the section from Case 23 (Fig. 4 : 41) characteristic changes in the deep vessels may be seen. In this instance there was old-standing sub-total infarction of the territory of the anterior descending artery. It is immediately apparent that there is an increase in the vascular density of the ischaemic area. If attention be directed to the vessels in the innermost layers of the left ventricle, it may be seen that these are widely dilated in the ischaemic sector. When examined stereoscopically intercommunication of many of these vessels could be

traced (in the fashion shown in Fig. 4:38 (stereo.), from Case 25). The vessels of the subendocardial plexus outwith the affected area showed a moderate increase in size.

Similar but more widespread appearances may be seen in the section from Case 18 in which there was old anterior descending artery occlusion with only trivial old-standing myocardial damage (Fig. 4:42).

In both these cases the other arteries were unobstructed and many of the enlarged deep vessels lay in their territories.

Sometimes occlusion of a coronary artery was followed by massive infarction of such severity that the arteries as well as the muscle tissue were destroyed. The section from Case 9 (Fig. 4:43) is an example, in which the territory of the right coronary artery distal to occlusion shows little or no retrograde filling. In this instance there is little change in the deep plexus in the healthy portions; and clearly the immediately available collateral blood supply had been insufficient to prevent massive necrosis. Another example may be seen in the stereo-pairs from Case 20, in which the apex is viewed from below. The muscle damage in Case 13 on the other hand, though extensive, was not sufficiently confluent for obliteration of the vascular tree. Indeed, it would be difficult to tell from this section (Fig. 4:44) that there had been recent coronary artery occlusion and myocardial infarction. Again there is only slight departure from normal in the subendocardial plexus, and severe myocardial damage was not prevented.

The most extreme changes in the deep plexus of the left ventricle were found in cases of widespread obliterative coronary artery disease of long standing. In four cases with anginal histories of 10 years

and more, the changes in the subendocardial plexus were so striking, and the influence of these changes on the distribution of myocardial damage so significant, that they were selected for special description, which was published in the British Heart Journal, 1956. They will also be referred to in greater detail in Chapter 6.

In these four cases, the vascular density in the inner core of the left ventricle could be appreciated in the 3-dimensional arteriograms of the intact heart. The distribution was more clearly demonstrated in 2 dimensions in the cross-sections. (Two of these are included at this point (Fig. 4:39 (stereo) and 4:45,46). Others are in Chapter 6.) It could be seen that the inner zone of the left ventricle was occupied by a network of wide-bore intercommunicating channels. Without doubt these were derived from great enlargement of the subendocardial plexus. Blood entering this plexus at any point could readily be distributed throughout the vascular bed of the left ventricle.

The total inflow to the heart in these cases must necessarily have been greatly impaired on account of partial or complete obliteration of the main coronary arteries (see details of case records 6,8, 17 and 19). The persistence and progressive increase in the severity of anginal symptoms in these cases gave further indication that the total inflow had been greatly reduced; for despite the vascular changes in the depths of the left ventricle, myocardial ischaemia was not relieved.

Within an ischaemic area, therefore, enlargement of arterial vessels was sometimes observed of such degree and extent that any useful level of compensatory change seemed to have been exceeded.

Interpretation of these changes

Important issues were raised by these findings, which in this context were at first sight paradoxical. How was it, that the most widely enlarged and abundant deep anastomoses were found in those cases in which the total blood flow must have been severely restricted? What part had time to play in this? How was it that enlargement of these vessels did not regress as further obliteration of the main arteries reduced the total inflow? I have tried to find an answer to these questions in terms of the dynamic effects of blood flow on vessel calibre.

In the argument which follows, the evidence provided by the experiments on intramural pressures during cardiac contraction by Johnson and di Palma (1939) and on arterial pulsation distal to occlusion by Wiggers (1950) have been correlated with the detailed picture of the deep myocardial vessels that has been provided by this investigation. The conclusions must however remain speculative.

The intimate haemodynamics of the deep vessels of the heart is not understood - and by virtue of their inaccessible situation is likely to remain obscure. In these circumstances one can but attempt to deduce from their anatomical structure and situation, in conjunction with our knowledge of other features of the heart's action, some idea of their probable function during the different phases of the cardiac cycle. This I shall attempt to do. The argument will be the more readily followed if the vessels composing the sub-endocardial plexus are assumed to be grossly dilated as in severe coronary artery disease (e.g. Cases 17,25) although what is to be said would apply equally to

the deeper vessels in their normal condition, on a much smaller scale. It may be helpful to refer to the schematic drawing of the subendocardial plexus and its connections with the epicardial arteries, which appears in Diag. 4:1

With each cardiac cycle, the pressure conditions which surround the deep vessels of the heart must fluctuate through a wide range. It is obvious that there is likewise a wide variation in the conditions of blood flow in them.

During diastole intramural pressure is low and we may suppose that the deep myocardial arteries are charged with blood, under the influence of the diastolic pressure in the main coronary arteries. The commencement of systole presumably finds these deep vessels turgid with blood. To some extent myocardial contraction may assist in pulsing the blood in its forward course from capillaries to veins; but in the larger vessels composing the subendocardial network, and in other deeply placed arterial branches, the situation may well be very different.

In order to explain more clearly what I believe may take place, I propose to regard the relatively wide-bore vessels of the subendocardial plexus, when taken together, as forming a sort of complex reservoir, which is in direct communication with the epicardial vessels through a number of straight channels, as indicated in Diag. 4:2.

When the myocardium contracts, the turgid subendocardial vessels must inevitably be compressed, either between groups of muscle fibres or between the muscle and the contents of the ventricular cavity. It would seem reasonable to suppose that with the onset of systole the blood contained in the subendocardial "reservoir" will seek such natural exit as may be available. One likely route of escape is towards the

superficial arteries beneath the epicardium. This will of course involve reversal of flow.

I have confirmed that anatomical channels through which the sub-endocardial "reservoir" may empty itself do in fact exist (e.g. Fig. 4:29,44 ). Their capacity to perform this function, however, could be annulled by two theoretical circumstances: (1) contraction of the myocardium in such a fashion that the more superficial portions of the myocardial arteries were compressed with greater force than the deeper portions, so opposing outward flow during systole from the sub-endocardial plexus: (2) a higher pressure of blood in the superficial arteries than in the deep vessels could resist or reverse the tendency to outward flow.

In regard to the first of these, the evidence of electrocardiography shows that the wave of contraction travels from the deeper layers of the myocardium to the surface. Accordingly, those portions of a myocardial vessel that are deeply situated will be compressed before its more superficially placed portions. Admittedly the time interval is very brief but is not necessarily negligible.

More important, however, is the convincing work of Johnson and di Palma (1939) who demonstrated a gradient of pressure within the myocardium of the left ventricle of the cat. They found that the inner layers of the left ventricle developed a pressure at the height of systole that was in excess of the aortic pressure and therefore of the coronary systolic pressure; whereas the pressure in the superficial layers was much lower and usually less than the aortic pressure. A moment's reflection serves to convince not only that a gradient of

pressure from within-outwards is to be expected in the left ventricular wall during systole but also that any other state of affairs would be physically impossible. A gradient of pressure from the surface inwards is no more likely to exist in the contracting ventricle than is a higher pressure to be found near the surface than at the bottom of the sea.

Johnson and di Palma's observations, taken together with electrocardiographic evidence, provide the physiological background on which to support the concept that in the early phase of ventricular systole the myocardial vessels are exposed to a wave of compression not unlike a wave of peristalsis: both its direction and its pressure gradient favour blood flow from the deeper layers towards the surface of the heart.

The arrival from the aorta of the systolic pulse wave in the coronary arteries is the only available force that can resist this outward flow from the deeper vessels. There will, of course, be a short interval of time during and immediately after the isometric phase of ventricular contraction when the outward flow of blood will be unopposed. This interval ends with the arrival of the systolic pulse. Nevertheless, since the intra-myocardial pressure at the height of systole is higher in the deeper layers of the myocardium than in the coronary arteries, it is likely that outward flow from the subendocardial "reservoir" continues until it is emptied of blood.

On the other hand, experimental evidence suggests that blood enters the vessels of the superficial layers of the left ventricle during the course of ventricular systole. Accordingly it may be supposed that



outward flow may be halted or reversed at this level.

With the onset of diastole the deep vessels again fill and become turgid, ready for compression to reverse the flow during the next systolic contraction.

Now, in the presence of obstruction to a coronary artery, the arrival of the systolic pulse in the epicardial vessels distal to the obstruction will be delayed for a longer time than in regions with a healthy arterial supply; and the pressure will be lower. This circumstance is probably of paramount importance in the production of the anastomotic patterns seen in the depths of the myocardium in coronary artery disease. For such conditions will favour a larger and more complete emptying flow from the subendocardial plexus in the region of ischaemia. Moreover, since the subendocardial vessels are intercommunicating, blood from all parts of the "reservoir" may seek exit into the relatively low-pressure area distal to the arterial occlusion. If this is in fact the case, the relatively extensive nature of the changes found in the deeper vessels in the presence of localised ischaemia is explained.

The situation in generalised myocardial ischaemia with universal involvement of the deep plexus has probably essentially similar origins. Initially it is likely that differential pressure gradients exist between different sectors of the deep plexus, and promote its enlargement. By the time severe obliterative disease has overtaken most of the major coronary branches on the surface of the heart, the pressure gradients in the deep vessels may well have undergone several changes of direction. Evidence will be presented in Chapter 6 that

myocardial ischaemia in these cases was evenly distributed in the deeper layers of the left ventricle. This does not mean that the conditions of blood flow in the deep plexus was likewise equitable. On the contrary, an even distribution of blood throughout the deep network, which may be fed mainly at one or two points, would call for intrinsic conditions of blood flow far from sluggish.

Moreover, it is likely that the differential pressure between the left ventricular cavity and epicardial coronary arteries distal to occlusions, where most or all major vessels have been compromised by disease, is greater than in the normal state; and that this differential pressure will favour augmentation of ebb-and-flow conditions in the deep plexus. In this context it is of interest that in cases with aortic stenosis (in which there is a great disparity between intraventricular and aortic pressures) the deep plexus was likewise exaggerated (e.g. Case D3), a point which receives comment in Chapter 6.

The foregoing description has envisaged ebb-and-flow of blood with each cardiac cycle, in the subendocardial and other deeply situated myocardial arteries. As already discussed, dynamic factors evidently influence the calibre of the vessels through which blood is flowing. To judge from the coronary circulation, this stimulus would seem to be likewise effective when the flow is reversed.

Now it may be held that in the normal heart the ebb-and-flow of blood is small; but at the same time it may be noted that the calibre of the vessels composing the normal subendocardial plexus is rather larger than that of the myocardial vessels which supply it. (See Fig. 4:25,30, 31.) It is tempting to correlate the slight increase in lumen diameter of these vessels with increased movement of blood. In the abnormal

heart the position is on more secure ground, and it is more readily understandable that increased movement of blood in the deep plexus should contribute to dilatation locally of the vessels which compose it (see Fig. 4:38-47).

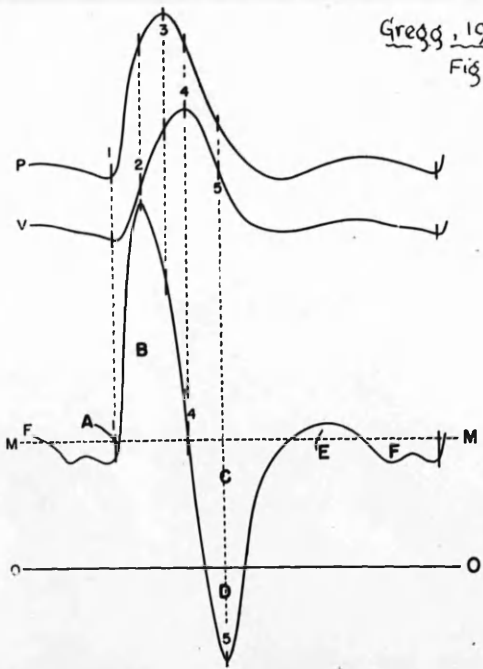
In this concept may lie the explanation of the paradox of dilated arteries in an area of ischaemia. As the movement of blood is largely of a to-and-fro character, the occurrence of increased movement of blood is compatible with diminished effective flow; and diminished flow compatible with dilated vessels.

The greater the ebb-flow the greater the stimulus to further vascular enlargement. Conversely the greater the vascular dilatation the greater the subendocardial "reservoir" and the greater the volume of ebb and flow possible. In this way a cycle may be set up.

Despite the provision of what appears to have been an abundant collateral supply to an area of earlier ischaemic damage, the persistence in that area of dilated subendocardial vessels may maintain a network as rich as may be found in an area still subject to severe ischaemia (e.g. Case 25, Fig.4:24, 38). I have insufficient numbers of observations on this last point for the evidence to be conclusive. It seems likely, however, that once wide dilatation of the vessels composing the subendocardial network has developed, the haemodynamic factors that I have postulated tend to prevent regression of that dilatation even after ischaemia has been relieved.

#### Correlation with experimental evidence

The interpretation of phasic coronary arterial flow within the



Gregg, 1950.  
Fig 37.

Fig. 37.—Upper curve, P, reproduction of femoral arterial pressure pulse. Middle curve, V, derived intravascular volume curve. Lowest curve, F, reconstructed flow pattern rectified to linear scale from original optical recording. Areas B, E, volume-elastic increments. Areas A, D, F, volume-elastic decrements. C, area of back flow. Interrupted line, MM, mean flow level. Line OO, zero flow level. Synchronous vertical intercepts for each curve, reading consecutively, are: 1) Onset of flow and pressure rise. 2) Maximal rates of forward flow and volume increase. 3) Peak of applied pressure. 4) Point of maximal intravascular volume. 5) Maximal rates of back flow and volume decrease. (Shipley, Gregg and Schroeder.<sup>41</sup>)

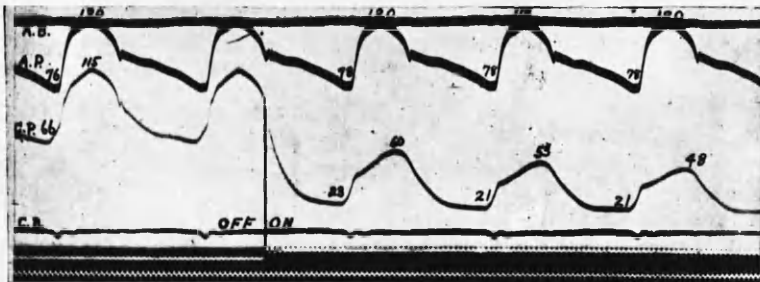


Fig. 2. Records showing aortic and coronary pressures before and after occlusion of the anterior descending branch of the left coronary artery. Following compression at "on", coronary pressures recorded from a side branch peripheral to a clamp fall abruptly and stabilize at 48/21 mm. Hg.

Wiggers, 1950

heart the position in on way  
standards that increased moven  
contribute to dilatation local  
4:38-47)  
In this concept may lie th  
arteries in an area of lachan  
to-and-fro character, the occur  
compatible with distended eff  
with dilated vessels.

The greater the sbb-flow  
enlargement. Conversely the B  
subendocardial "reservoir" and  
In this way a cycle may be est

Despite the grow  
supply to an area of  
of dilated subendoc  
found in an area all  
(3). I have found  
evidence to be compa  
ion of the vessels  
hemodynamic factors

that dilatation even after ischemia has been relieved.

Coronary flow with experimental evidence

The interpretation of basic coronary arterial flow with the

myocardium, which I have outlined, could be, and was in fact, reached through seeking correlation between structure and function, when contemplating the significance of the detailed changes in the deep vessels of the heart.

The conditions of phasic blood flow in these deep vessels may also be inferred from experimental observations on blood flow in the major coronary arteries on the surface of the beating heart. My own deductions are in accord with the experimental findings of a number of workers, whose observations on coronary blood flow are summarised by Wiggers (1949), Blumgart et al., (1950) and by Gregg (1950) (Chapter 5). In Gregg's Fig. 37 may be seen illustration of the abrupt reduction in and, finally, reversal of left coronary flow rate which occurs during and shortly after the isometric phase of ventricular contraction. The close relationship which this curve bears to cardiac contraction is entirely in keeping with regurgitant flow from the myocardial into the epicardial vessels. By the same token, it is unlikely that back flow in the coronary arteries is simply a rebound phenomenon.

Further, it is highly significant that the curves obtained of right coronary phasic flow are of much smaller amplitude and do not show reversal of flow. This is in keeping with the much lower intramural pressure in the right ventricle during systole than obtains in the right coronary artery at any phase of the cardiac cycle. Observations on coronary artery pressure tracings distal to experimentally created occlusion are also in keeping with the concept I have developed (see Wiggers, 1950, Fig. 2).

From the available experimental evidence Gregg (1950) writes:

"During isometric contraction and early injection, the blood in the deeper lying and more strongly compressed coronary vessels is forced backward into the larger proximal channels and, by thus contributing to the supply of blood available for the less strongly compressed and more superficial vessels, reduces the inflow from the aorta."

My own observations add little to this concept of normal conditions of coronary blood flow, save confirmation from a structural standpoint. I have however tried to correlate pathological changes of calibre in the deep vessels with abnormal conditions of blood flow in the walls of the left ventricle and to find an explanation in terms of causal relationship between altered function and structure. In doing so, I have found more intimate understanding of the conditions of deep blood flow likely to exist also in the normal heart.

## B 2. CORONARY ANASTOMOSES IN RELATION TO VENTRICULAR HYPERTROPHY.

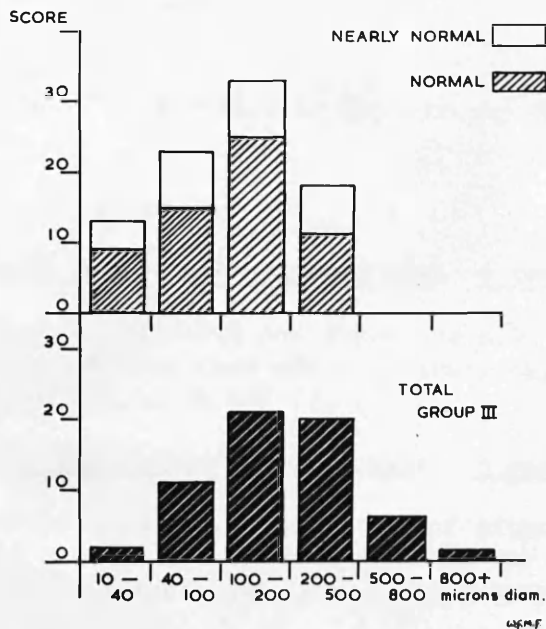
It has been held that in myocardial hypertrophy a condition of "relative ischaemia" exists (Fishberg, 1940, Harrison et al., 1932). This term is based on the concept that hypertrophied muscle fibres are at a disadvantage in regard to metabolic exchanges when compared to fibres of normal diameter. Moreover, the numerical ratio of capillaries to muscle fibres remains unchanged (Wearn, 1941, Smith, 1957) while the oxygen requirements of the over-taxed myocardium are increased. It is likely, therefore, that the demands of the hypertrophied myocardium can only be satisfied by a greater augmentation of coronary blood supply than merely in linear proportion to the increased bulk of muscle.

Earlier experiments (Dock, 1941) in which the heart was perfused after death with kerosine, suggested that the increased coronary flow consequent on hypertrophy was, volume-for-weight, actually less than in the normal heart. Using a method of catheterising the coronary sinus together with radioscopic estimation of heart size - a method open to obvious and acknowledged inaccuracy - Bing et al. (1949) have computed that in hypertrophy the beating human heart shows an absolute increase in coronary blood flow corresponding to the increase in the size of the heart; but not a relative increase, which would be desirable.

There is rather less known about the relationship of cardiac hypertrophy to anastomotic development. Zoll et al. (1951b) have observed an increased incidence of intercoronary anastomoses in hypertrophied hearts as compared to normal controls.

In the present investigation it was noticed that an increase in the calibre of anastomoses accompanied enlargement of the chambers of the heart. The information obtained from anastomosis counts (see page 4 : 29) of Group III was analysed. It will be recalled that the hearts of this group were the seat of cardiac disease other than coronary artery disease. The analysis firstly shows that the main difference between the anastomotic pictures of normal and hypertrophied hearts was in calibre rather than in number of communicating channels (Diag. 4 : 9). Comment has already been passed on the "shift to the right" in the presence of coronary artery disease (Diag. 4:6).

Group IIIa cases were further subdivided into three sub-groups according to the presence of predominantly right, predominantly left, or combined right and left ventricular hypertrophy. One case was omitted from this analysis



COMPARISON OF THE NUMERICAL DISTRIBUTION OF ANASTOMOSES IN NORMAL & NEARLY NORMAL HEARTS AND HEARTS WITH VENTRICULAR ENLARGEMENT, MAINLY DUE TO VALVULAR DISEASE (GROUP III).

DIAGRAM 4:9

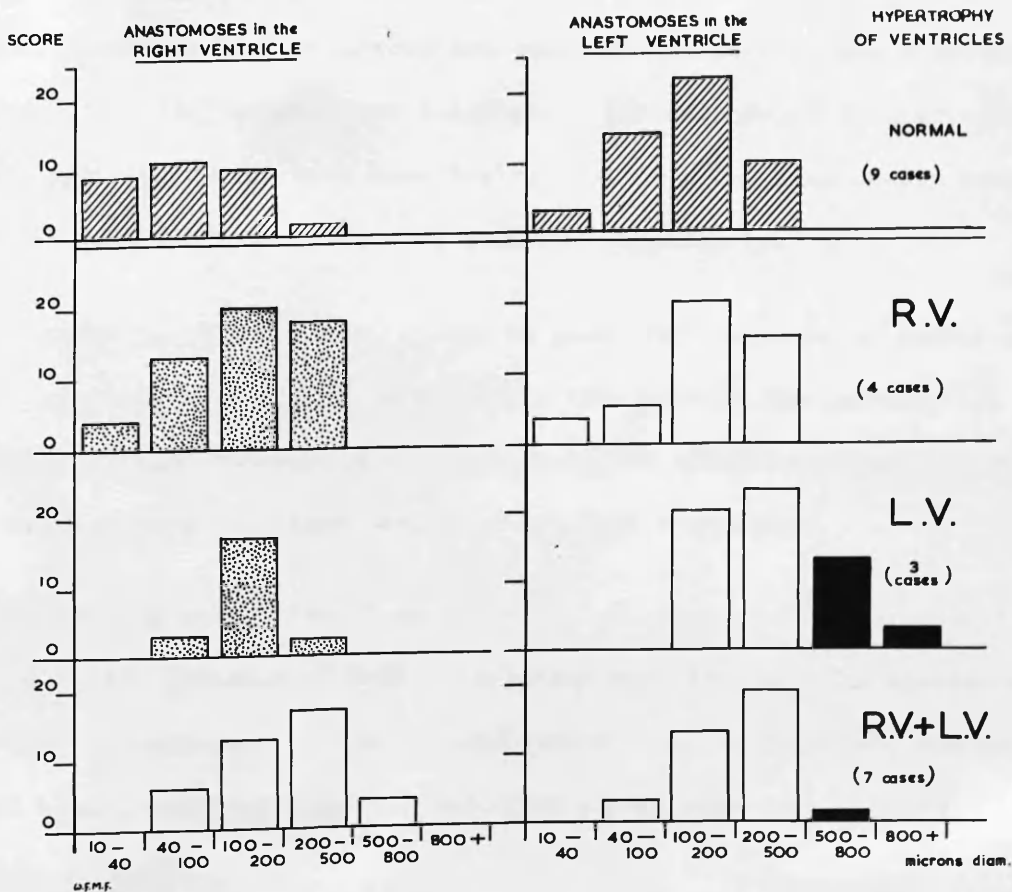


DIAGRAM 4:10



because it showed no definite ventricular hypertrophy despite moderate mitral stenosis.

Sub-group 1: Right ventricular hypertrophy: 4 cases

3 cases were of mitral stenosis and there was also left atrial hypertrophy. The remaining case was of primary pulmonary hypertension. (No. D9,11,16 and 7).

Sub-group 2: Left ventricular hypertrophy: 3 cases

1 case was of aortic stenosis. 1 case was of mitral incompetence with little R.V. hypertrophy. In the remaining case L.V. hypertrophy was probably due to hypertension (D13) (No. D3,10,13).

Sub-group 3: Right and left ventricular hypertrophy: 7 cases

2 cases: combined mitral and aortic stenosis. 2 cases: mitral incompetence. 3 cases: mitral stenosis with incompetence. In this group there was also left atrial enlargement. (No. D4,8,5,6,12,15,17)

The numbers in each sub-group are too small to permit firm conclusions. Nevertheless it was thought that analysis of the data would be instructive. In Diag. 4:10 the scores have been derived not from the anastomosis counts of the hearts as a whole but from each ventricle separately.

Presented in this fashion, it can be seen that increase in number and size of anastomoses was found in the right ventricle in the presence of hypertrophy of that chamber, when compared to the situation in normal hearts or in cases showing only hypertrophy of the left ventricle.

Similarly, a marked "shift to the right" is seen in the scores of the left ventricle in the presence of left ventricular hypertrophy. The anastomoses in the last two columns, i.e. those over 500 microns in diameter, emphasised in solid black, occurred only in cases with aortic stenosis.

In constructing these diagrams it has been assumed that the altered anastomotic patterns were related - though not necessarily causally - to ventricular hypertrophy. However, the great majority of cases showed hypertrophy only as the result of valvular disease. It may well have been the case that alterations in intraventricular systolic pressure as a consequence of valvular disease conditioned both the enlargement of deeply placed anastomoses and the hypertrophy of muscle.

The small number of cases in these sub-groups does not permit further elaboration of the points which could arise from these data. I merely observe that the relationship between ventricular hypertrophy and increased calibre of anastomoses was qualitatively consistent; and in some situations may be additional evidence in support of dynamic factors in the enlargement of these vessels.

It may be noted in passing that there was also increase in the dimensions of main stems and branches of all orders, apparently in close relation to the bulk of the ventricles which they supplied. To some extent the increased calibre of anastomoses merely reflected the increased calibre of the coronary tree as a whole.

enlargement of anastomoses at least to this degree, and that such degree was common.

While the evidence of my own investigation has tended to suggest

THE TIME FACTOR IN THE ENLARGEMENT OF ANASTOMOSES

Enlargement of small calibre communicating arterial channels, to a size sufficient to carry a useful measure of collateral blood flow, cannot result from simple relaxation of the muscular coat. The process involves the stretching and growth of the tissues of the vessel walls. It was evident in my specimens that a long period of time was required - even when high degrees of ischaemic stimulus had been operating.

When the dimensions of anastomotic channels in coronary artery disease were compared with those found at similar sites in normal hearts, it was apparent that a 5-10 fold increase in lumen diameter was not uncommon. When, for example, anastomoses of 500 microns in diameter were found in the inter-ventricular septum, where 50-200 microns in diameter would commonly be found in the normal, it seemed reasonable to postulate an increase of about x5 in lumen diameter. This implies an increase in the circumference of about x 15, and in the cross-sectional area x 25. The distension which can take place therefore is no small adjustment in the dimensions of these vessels. Mautz and Beck (1937) likewise recorded a ten-fold increase in the diameter of coronary anastomoses in the dog, following ligation of a coronary artery.

Examination of individual specimens, in which coronary artery occlusion had been followed by varying degrees of myocardial infarction, led to the impression that an effective volume of collateral blood flow demanded enlargement of anastomoses at least to this degree; and that such development was common.

While the evidence of my own investigation has tended to emphasise the long period of time, under conditions of human pathology, required for the

development of major degrees of anastomotic enlargement, it must be remembered that the process has its beginnings. In this connection there have been many pertinent observations in the experimental field.\* In general these have indicated that demonstrable increase in collateral blood flow following partial or complete ligation of a coronary artery may be manifest in the course of a few days; and, where occlusion had initially been partial, that a significant measure of protection against the effects of complete occlusion can develop in the course of a few weeks.

I do not propose to discuss the experimental evidence itself. I would only make the point that caution must be exercised in applying the findings to man, particularly in regard to the time required for the development of collateral blood flow sufficient to afford protection to the myocardium. The species difference itself may be important, on general grounds. Likewise those experiments conducted on young, actively growing animals (e.g. Blumgart et al., 1950) may reveal a rate of vascular adaptation far higher than can be assumed for man in middle life and old age.

Again, most of the experiments have been carried out on animal hearts, substantially smaller than the adult human heart. The actual bulk of tissue

---

\* The experimental evidence has been reviewed by Gregg (chap.8), 1950, and by Blumgart et al., 1950. Of particular relevance are observations by:-

Mautz, F. R. and Beck, C.S., 1937. J. Thorac. Surg. 7.113

Mautz, F. R. and Gregg, D.E., 1937. Proc. Soc. Exp. Biol. & Med. 1937, 36. 797 (cited Gregg, 1950).

Eckstein, R.W., Gregg, D.E. and Pritchard, W.H., 1941. Am. J. Physiol. 132. 351.

Gregg, D.E., Thornton, J.J. and Mautz, F.R., 1939. Am. J. Physiol. 127. 161.

Zoll, P. M. and Norman L.R., 1952. Circulation 6.832.

involved and distances in relation to new blood supply may be the factors of greatest importance, when the protective effects of a given degree of collateral circulation are being assessed, and the time estimated for its development. My own impressions of the time required for the enlargement of anastomoses to provide equivalent degrees of protection in man and in experimental subjects would be less divergent were the increase in time in not less than geometrical proportion to the heart size. The long period of time required for this development in man has been alluded to by many authors on this subject; although, so far as I have found, none have attempted to define the period required.

I had hoped to find in the examination of my material an answer to two questions:

1. What degree of anastomotic enlargement is required in order to provide a given degree of protection from myocardial infarction following coronary artery occlusion?
2. How long does it take for such degrees of enlargement to develop from normal structures?

I have come to the conclusion that no simple or exact answer to these questions can be expected from the examination of the human heart. From my own series an answer can be given only in broad terms: namely, that very extensive departure from the normal anastomotic pattern is required for a high degree of protection from the consequences of occlusion of a major coronary artery, supplying the left ventricle; and that this process apparently requires many months and probably years.

Only the relationship between duration of time and dimensions of enlarged anastomoses will be dealt with at this point. The relationship between anastomotic development and myocardial damage is examined in

## Chapter 6.

The impression was readily gained from direct inspection of individual specimens that anastomoses of the largest calibre were to be found in the cases of long duration. Moreover fatal cases with short histories tended to show extensive massive infarction of the affected territory and a pattern of anastomotic development not far removed from normal. It was decided to take the matter further and to analyse the data contained in the anastomosis counts (see page 4:29) of cases with advanced coronary artery disease (Group IVa).

The cases of advanced coronary artery disease were divided into 4 sub-groups according to the duration of ischaemic symptoms, dating from the first symptom of angina pectoris (see Table 4:3). Where anginal pain was a definite feature, the duration of the history appeared to correspond fairly closely to the duration of occlusive coronary artery disease, as judged from pathological evidence (sub-groups A, B and C). In the fourth sub-group (D) were placed cases in which there was no clear history of ischaemic pain (except terminally, in case 18, in which there was clear evidence of old-standing occlusion and myocardial damage). Since sub-group D contained cases of widely differing grades of severity of obliterative coronary artery disease and adaptive vascular change, without indication from the history of the probably duration of ischaemic heart disease, it was decided to exclude this group from the diagrams used in this analysis.

---

(Had these cases been combined with sub-group A however the only significant difference would have been in column 5. The score of sub-group A would then have read 1,7,19,21,7,0 instead of 0.7.20.20.3.0. This would have reduced the difference between sub-groups A and B in all diagrams, but the general trend would have been the same.)

Table 4:3

SUB-DIVISION of CASES of SEVERE CORONARY ARTERY DISEASE (Group IVa) according to DURATION of ISCHAEMIC SYMPTOMS			
Sub-group	Duration of History of Anginal Symptoms.	No. of cases	Case No.
A	Less than 6 months (5 days to 3 months)	4	9,13,14,15
B	6 months to 2 years (6 months to 2 years)	7	7,10,11,12, 21,22,24.
C	Longer than 5 years (7 to 14 years)	6	1,4,6,8,17, 19.
D	No anginal history.	5	16,18,20,23, 25.
Total		22	

Note: There were no cases with histories longer than 2 and shorter than 7 years. In a larger series, which included such cases, would probably make a further group 2 to 5 years advisable.

In Diag. 4:7 the "anastomotic scores" of sub-groups A, B and C are compared with each other and with the score of the normal group\*. It may be seen that with increasing duration of anginal history there was a progressive

---


$$* \text{ Anastomotic score} = \frac{\text{Sum of anastomotic indices}}{\text{Number in the group}} \times 10$$

See page 4:30

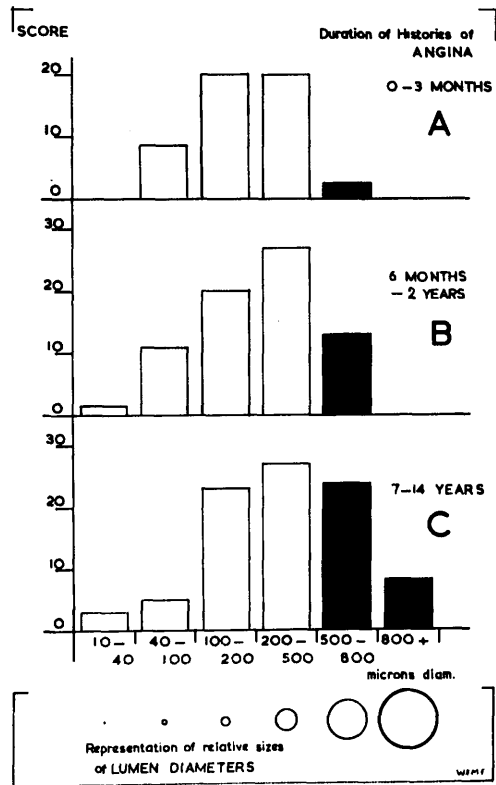


DIAGRAM 4:7

COMPARISON OF THE POTENTIAL CAPACITIES FOR BLOOD FLOW THROUGH ANASTOMOSES IN NORMAL HEARTS AND IN CORONARY ARTERY DISEASE, GRADES A, B & C.

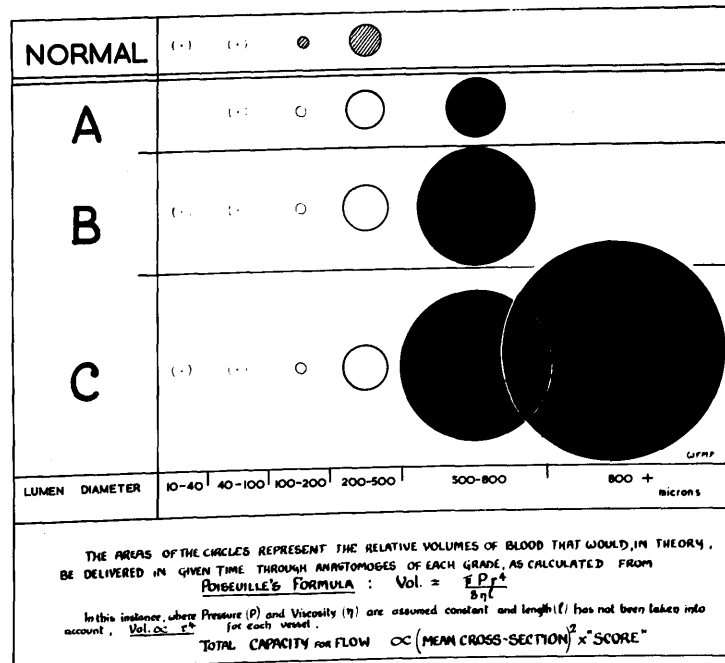


DIAGRAM 4:11



increase in the numbers of large scale anastomoses. In order to emphasise this point, solid black has been used in the last 2 columns.

The scores of sub-group A show a pattern not far removed from the normal. It is of interest that the radiographs of these cases showed few anastomoses of large calibre; and thrombotic occlusion of a major coronary artery was followed by extensive infarction of the territory of that artery. In each case death was attributable to this lesion.

By contrast, in sub-group C large scale anastomoses were numerous. Four of these cases are dealt with under the heading of "chronic generalized myocardial ischaemia" in the next section. The remaining two cases had survived episodes of coronary artery occlusion and did not die as the direct result of coronary artery disease.

In Diagram 4:7 relative numbers of anastomoses have been presented graphically, graded according to calibre. The point of practical importance, of course, is the significance of these data in terms of potential capacity for collateral blood flow. When numbers are translated into the calculated capacity for blood flow for each column the balance of the picture becomes very different, as may be seen in Diagram 4:11.

In this diagram the areas of the circles represent the relative capacity for blood flow, i.e. the relative volumes of blood that would pass through the aggregate channels of each grade at a given pressure, where variation in length is disregarded. The overwhelming advantage for potential collateral blood flow held by few channels of large size over large numbers of small channels is so striking that further comment is superfluous.

(The calculations were made by the application of Poiseuille's law to the data contained in the anastomotic scores of each column and sub-group. For this purpose the mean diameter of each grade was used, the mean diameter for grade 800 + microns lumen diameter being taken as 1000 microns.

From the mean lumen diameters the values for radius<sup>4</sup> were calculated, which are theoretically in proportion to capacity for blood flow. The areas of the circles in Diag. 4:11 are proportionate to these values x anastomotic scores (i.e. area = r<sup>4</sup> x score).

Had the mean cross sectional areas been used for this calculation (area = (mean cross section)<sup>2</sup> x score) there would have been no appreciable difference in the proportions of the diagram.)

There are however two points, relevant to the interpretation of these diagrams, which require to be borne in mind:

(1) The calculations are based entirely on the calibre and number of anastomotic channels. It does not necessarily follow that they bear close relation to the total blood flow to the myocardium nor indeed to the total forward flow passing through them. Presumably the total flow to the myocardium is mainly influenced by the degree of obstruction to major coronary arteries on the surface of the heart, when this is severe: whereas movement of blood may be largely ebb and flow in character in the deep anastomotic channels, as discussed in the previous section.

(2) It is also essential to appreciate that these measurements refer to the state of affairs existing at the time of death. Where, for instance, coronary artery occlusion has been survived for a number of years, it is obvious that the degree of anastomotic enlargement found at death is unlikely to reflect the degree obtaining at the time of the occlusion. It is impossible to determine with precision how much of the collateral circulation has subsequently developed as the result of occlusion, although a guess may sometimes be hazarded. The longer the interval of time the greater is likely to be the departure from the

conditions before occlusion. Where death has occurred shortly after occlusion, it may be assumed that the subsequent change in the collateral circulation has not been great. In these circumstances correlation of arterial occlusion, myocardial damage and available collateral blood supply may be made with more assurance - though still with reservations.

Further there is no means of comparing the anastomotic development in these fatal cases with that existing in similar clinical cases which have survived the incident of coronary occlusion.

COMMENT

Observations on the enlargement of anastomoses in the ischaemic cases of this series are in keeping with the following sequence of events.

Resulting from coronary artery occlusion or severe narrowing, anoxia of the territory distal to the lesion initially provokes dilatation of arterial channels, including pre-existing anastomoses. The influence of anoxia doubtless continues, but further changes are dominated by the dynamic effects of increased blood flow.

The reduced pressure distal to occlusion of a coronary artery sets up a pressure gradient which favours collateral blood flow from the neighbouring territory. The increased movement of blood so promoted stimulates the active enlargement of vessels carrying it. This in turn facilitates augmented blood flow, and in this way a cycle is entrained which in time may lead to enlargement of vessels many times the maximum calibre attainable by simple relaxation of the medial coat.

As the process continues, some channels dilate to a greater extent than others. Eventually the relief blood supply to the ischaemic area is mainly carried by relatively few collateral channels of wide bore. In certain circumstances it is also possible that some channels in the neighbouring territories may regress as ischaemia is relieved, as the pressure gradient falls, and as they are by-passed by more favourably placed vessels. In the ischaemic area itself, however, the deeper communications at least appear to remain enlarged indefinitely.

There are doubtless other factors which condition the readiness with

which the mechanism of anastomotic adaptation is brought into play. Nitrites and anaemia have shown to be beneficial in this respect in experiments conducted on the pig (Zoll and Norman, 1952) but little is known about other influences. It is quite possible that hormonal or neurogenic influences may have adverse or favourable effects. Obviously knowledge of such factors could have practical bearing on the clinical management of coronary artery disease.

Occlusion of a given coronary artery apparently may have differing degrees of effect in different individuals despite an essentially similar anastomotic development and anatomical distribution of arteries. The discrepancies become the more understandable if it be borne in mind that, where coronary artery occlusion has been survived for even a short period of time, it is not possible to distinguish with precision the degree of anastomosis present at the time of occlusion from the development that has taken place subsequently; that the functional value of dilated collateral channels may be limited by obstruction in the neighbouring artery delivering the relief blood flow; and that a great many factors influence the balance between the requirements of the myocardium and the quality and volume of its blood supply.

Some aspects of these topics are examined in Chapters 5 and 6. Restitution of blood flow by canalisation of the occlusion itself is another matter, and receives attention in Chapter 7.

### SUMMARY

The historical background to modern opinion on the question of arterial anastomoses in the normal heart is presented and discussed.

The findings in this connection made by workers who have employed the Schlesinger method of examination are found to be at variance with the results obtained by earlier workers and by the present investigation. Accordingly, the position is reviewed in detail. The importance and reliability of magnified three-dimensional viewing of arteriograms are stressed.

The results of the present investigation in regard to coronary anastomoses are stated. In general they confirm the observations of Spalteholz and Gross.

A method of recording numbers of anastomoses of different calibres at various sites in the heart is described. Calculations are made from the data so obtained. The extent and distribution of anastomoses under normal and abnormal conditions is compared.

Conclusions based on the numerical data in conjunction with detailed examination of structure include:-


1. Anatomically the coronary arteries of man are not "end-arteries".
2. Numerous arterial anastomoses of fine calibre are to be found at nearly all areas of the normal heart, and are larger and more abundant in the deeper layers of the ventricular walls, especially in the interventricular septum and the sub-endocardial plexus of the left ventricle.
3. The subendocardial plexus of the left ventricle affords an important potential source of collateral blood supply under conditions of disease. In this respect it competes with the anastomoses of the interventricular septum. The importance of the subendocardial plexus in pathology appears to have been largely overlooked.
4. Except at a few sites, such as the apex, superficial communications are usually few and of very small scale in the normal heart.

5. Apart from the interventricular septum and subendocardial plexus, intramural communications in the left ventricle are scanty.
6. Mediastinal communications are frequently found and join the coronary circulation through the atrial vessels.
7. The coronary anastomoses of large calibre found in disease have almost certainly been derived from enlargement of pre-existing arterial communications. These communications are present in normal hearts in sufficient abundance to account for the numbers of channels of wider bore found in disease. The difference is not one of number but of calibre.
8. Correlation may be made between the degree of anastomotic development and the duration of severe coronary artery disease. Relatively little departure from the normal pattern was found in cases dying as the result of coronary artery occlusion where the history was of short duration. Whereas, long-standing cases of coronary artery disease were found to have developed numerous greatly dilated anastomotic channels which formed the anatomical basis for potentially greatly augmented collateral blood flow.

The significance of anastomoses in the normal heart and the factors which may influence their enlargement are discussed. It is concluded that haemodynamic influences must play an important role in the enlargement of collateral channels, not only in the neighbouring territories, but also in the ischaemic areas themselves.

Explanation has been sought for the paradoxical occurrence of anastomoses of large calibre within areas of ischaemia, where, at first sight, it might be expected that the conditions of blood flow would be sluggish. The interpretation put forward reconciles anatomical structural change with altered conditions of blood flow.

Anatomical description is supported by illustrations prepared from arteriograms of anastomoses in most parts of the normal heart, and also in conditions of disease. Special emphasis has been laid on the demonstration by stereo-arteriography of the subendocardial arterial plexuses of the ventricles.

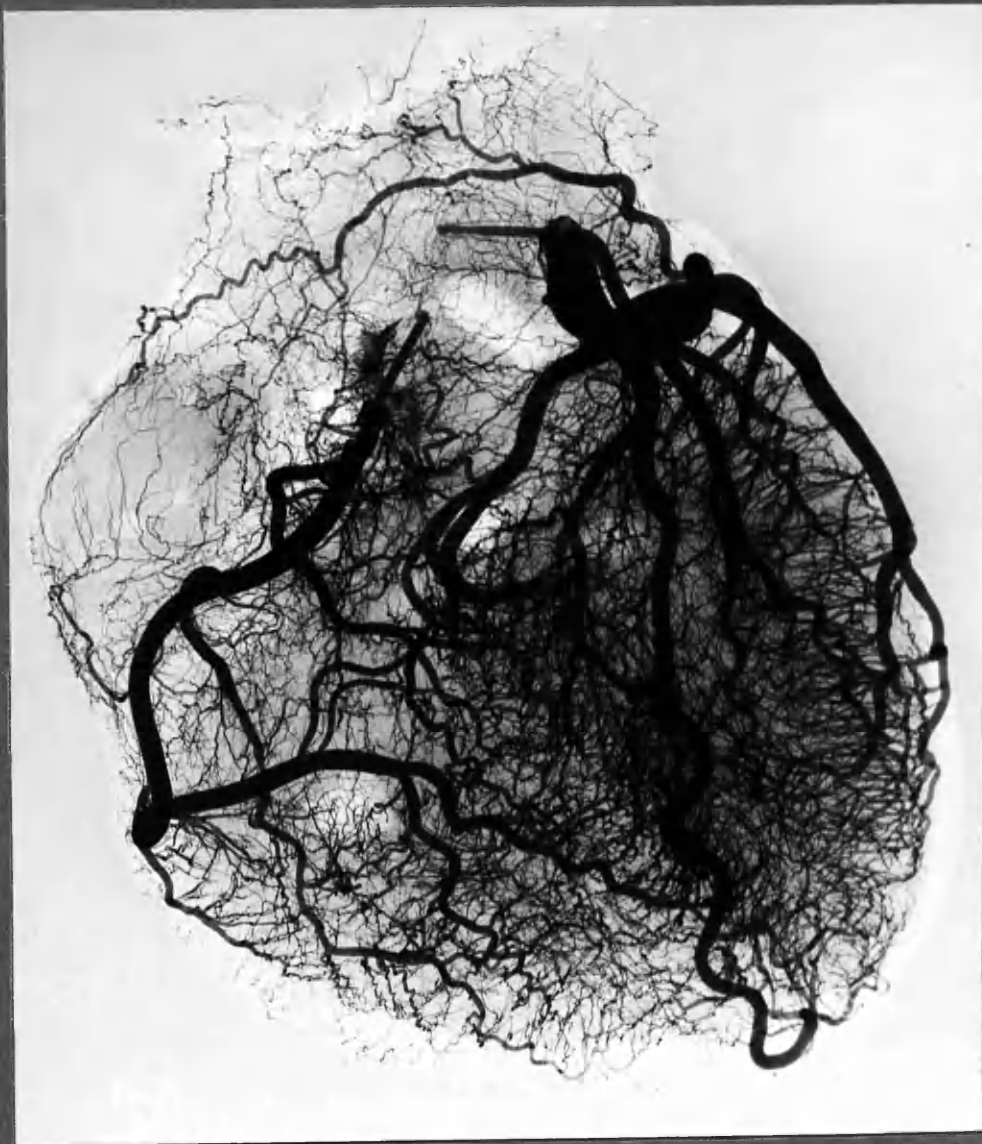




FIGURES

Chapter 4

↓ mediastinal communication

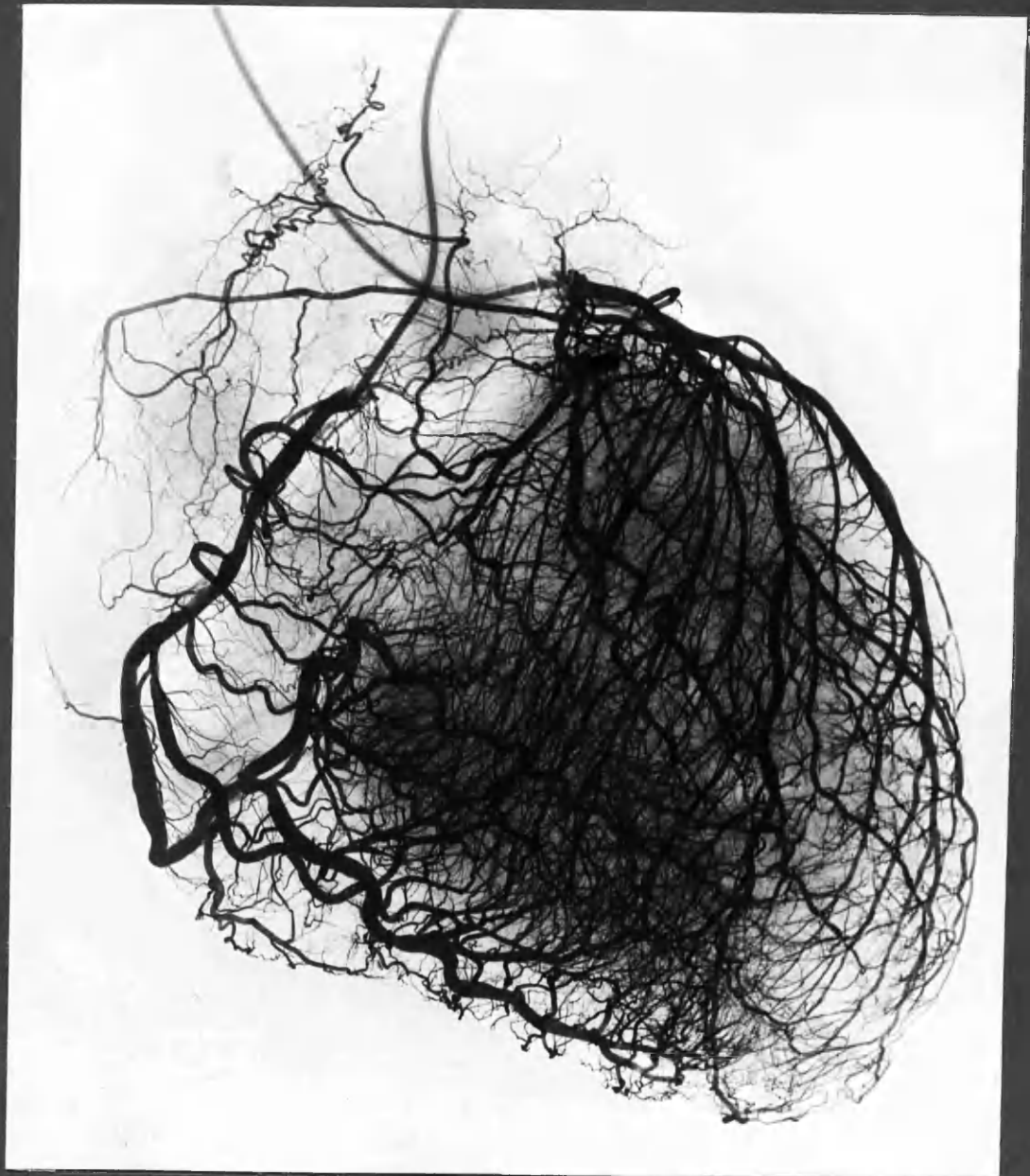


<1

N11

Contact print of a NORMAL HEART arteriogram. Numerous anastomotic communications were present but cannot be appreciated in the 2-dimensional arteriogram, on account of their small size and the overlapping of structures.

Note minute arteries supplying the epicardial fat at the right border of the heart, and other small vessels of the mediastinum communicating with the atrial circulation.

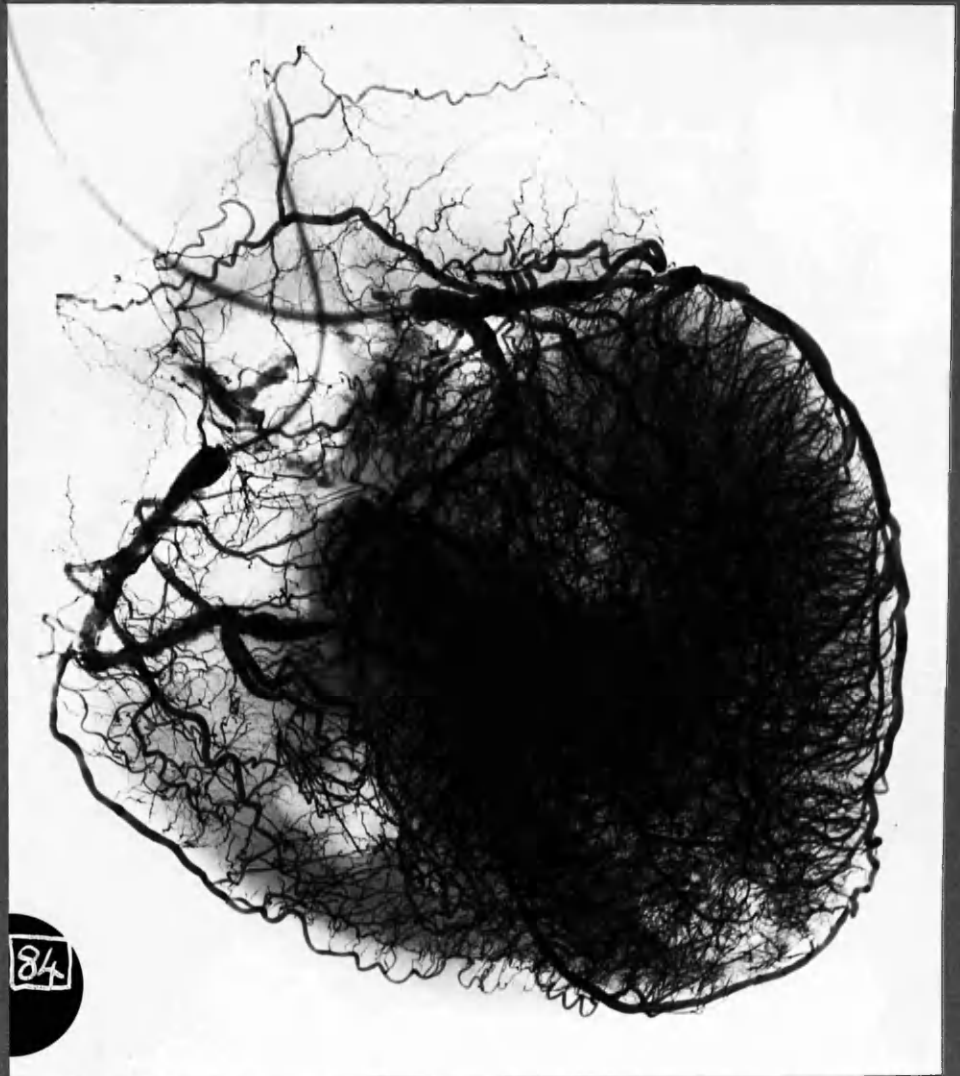

x1

Case 21

Complete occlusion of the left coronary artery, main stem, was present within a few mm. of its origin. The entire filling of this coronary "tree" with radio-opaque medium took place through the right coronary artery. Anastomoses can be seen sweeping across the interventricular septum from the posterior interventricular branch of the right coronary artery to link with branches of the anterior descending branch of the left coronary artery. This can be better appreciated in fig. 4:20.

Note also enlarged atric-mediastinal arterial communication.



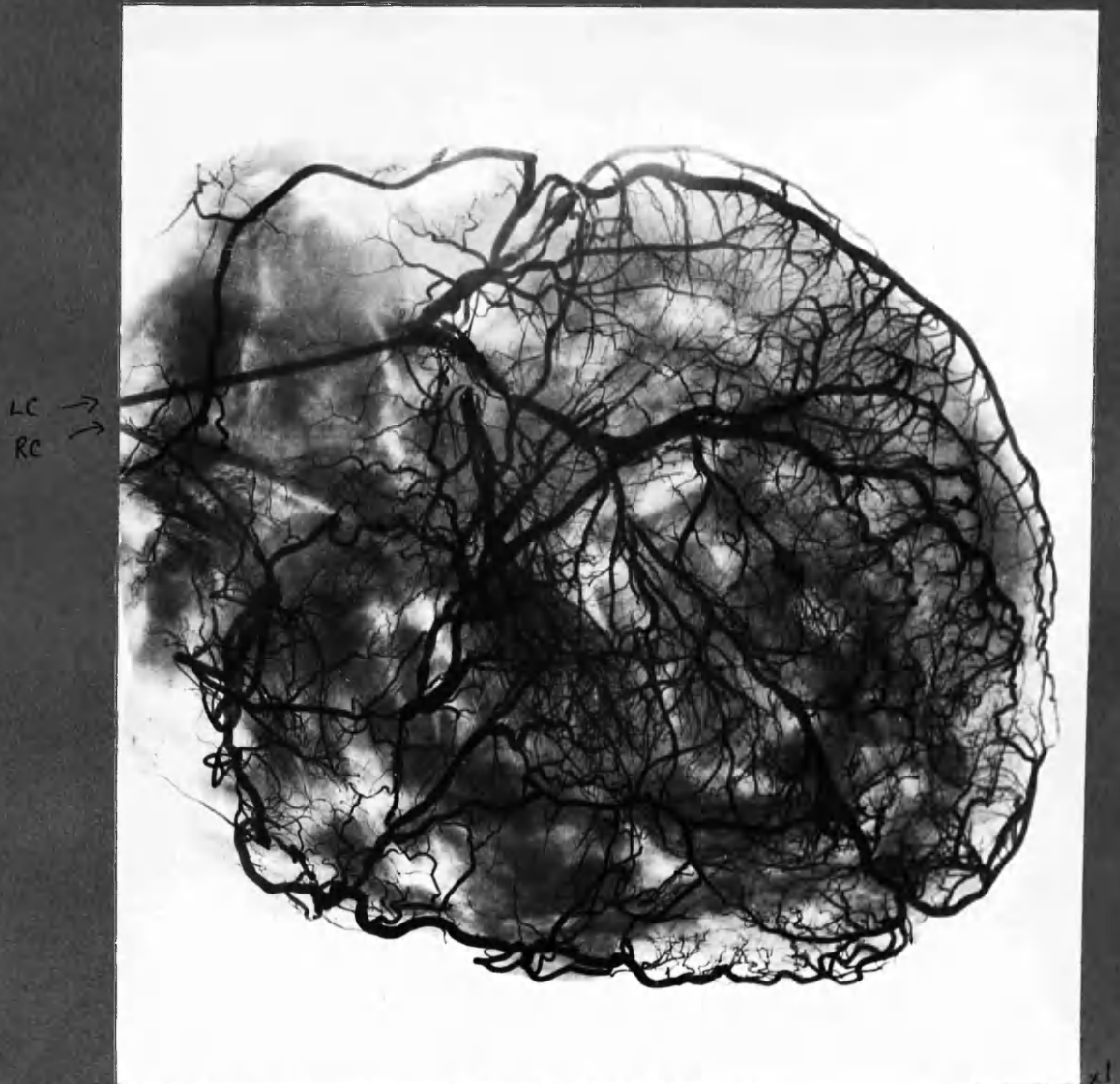
x 1

### Case 17

Widespread obliterative coronary artery disease with generalised cardiac ischaemia. Most of the central density is attributable to widely dilated, intercommunicating channels in the inner shell of the left ventricle. These channels have arisen from the subendocardial plexus. The location of these vessels is better recognised in transventricular section. (Fig. 4:39)

Note also a wide bore communication between the left marginal branch of the left circumflex artery and the anterior descending artery - which is occluded proximally.





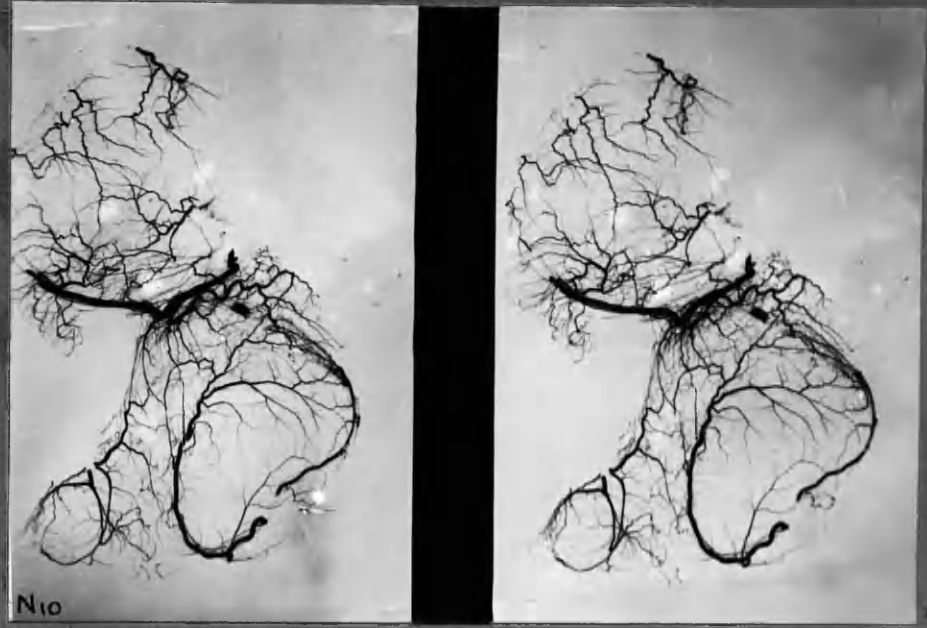
#### Case 4

The posterior walls of the ventricles were replaced by thinned-out scar tissue, as the result of massive cardiac infarction of 7 years duration. The posterior wall of the left ventricle was stretched and almost devoid of smaller arterial branches. Accordingly the arteriogram is remarkable for the lack of overlapping structures. Widespread severe obliterative coronary artery disease has made it difficult to identify even the main stems in this arteriogram; and wide-bore anastomoses have converted the arterial tree into a network. Deep vessel injection was not good in this case, and most of the communicating channels seen were superficial, e.g. in the region of the apex.

[The mottled shadows are partly due to saline-soaked cotton wool swabs with which the heart was stuffed before radiography. Radiography was performed without the saline immersion method.]

ATRIAL ANASTOMOSES

Fig 4.6  
:7

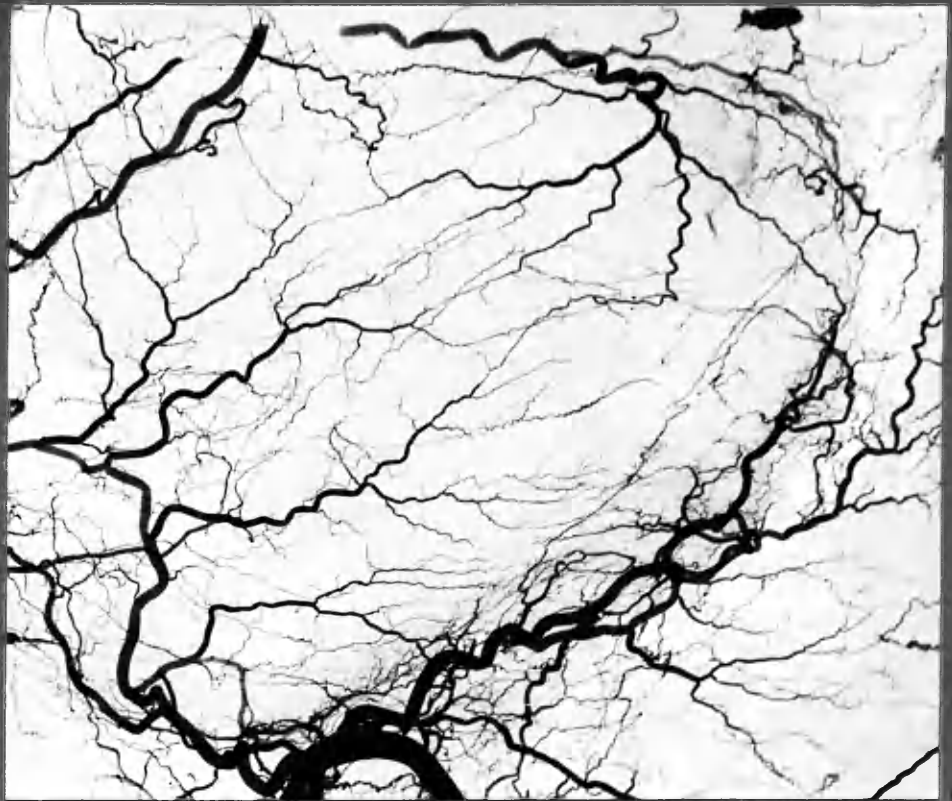


N10

:6

x7

N10 "ATRIAL CAP" IN NORMAL HEART OF A CHILD, 8 yrs.



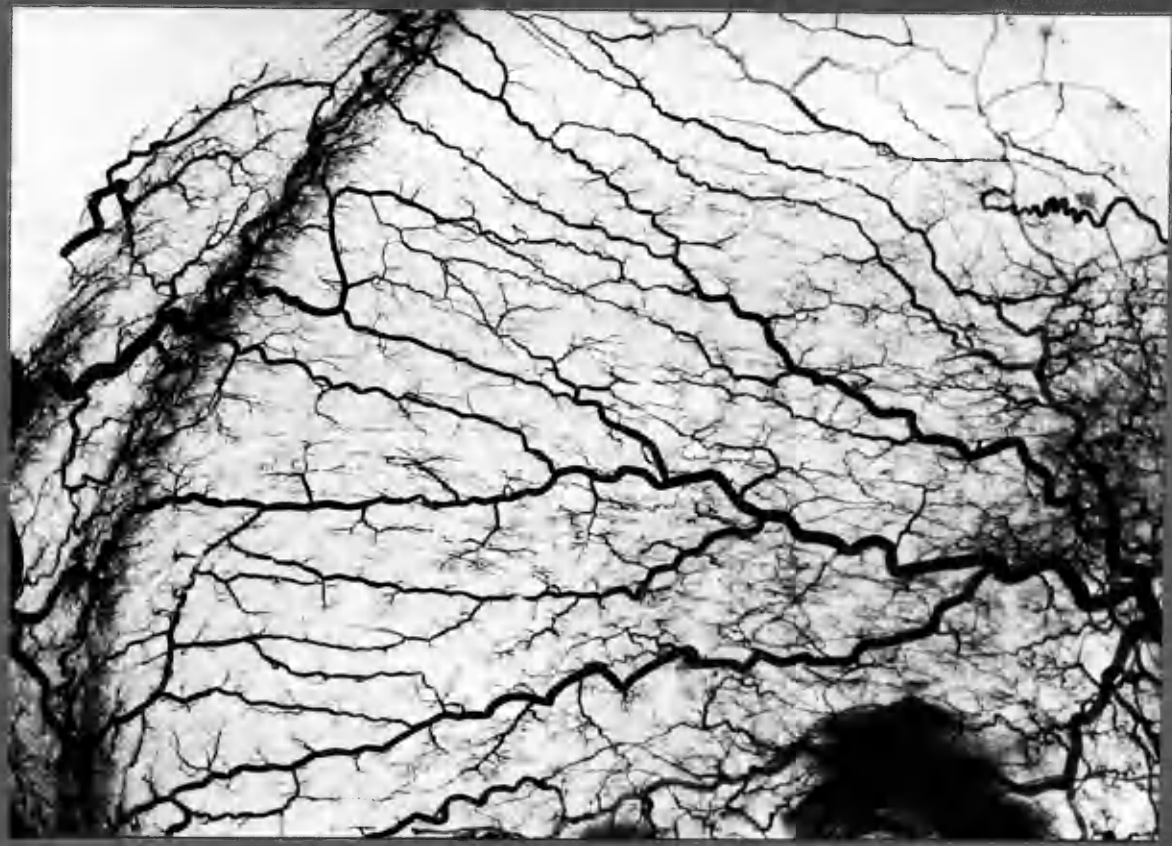
:7

:8

TYPICAL FINE CALIBRE ANASTOMOSES IN A NORMAL LEFT ATRIUM.

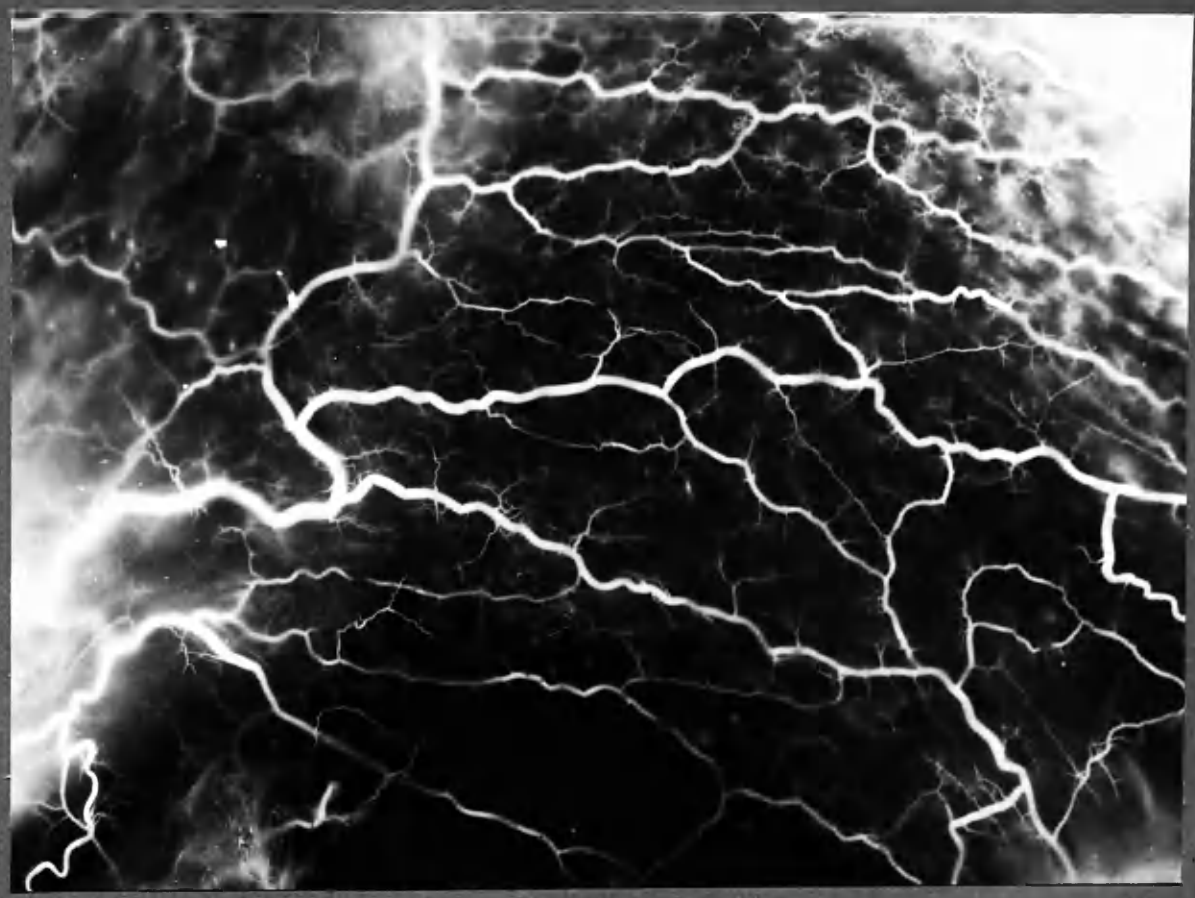N9

x3



A

x4

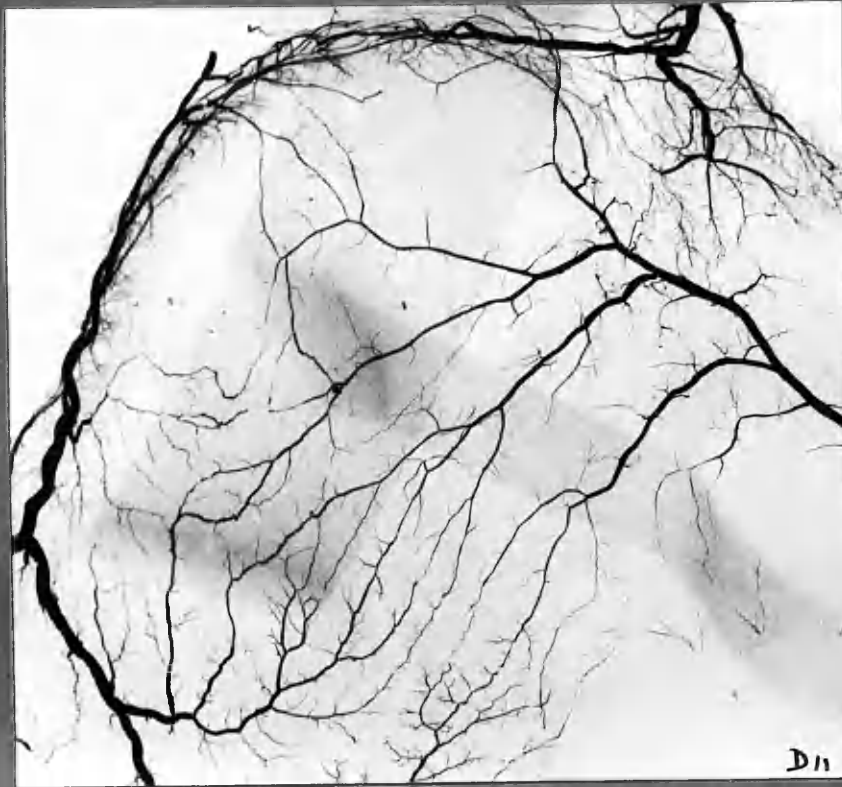


B

x6

N17. L. ATRIUM. A. Radiograph (routine). B. Photograph of cleared specimen. area in 'B' lay on left hand side of 'A', but in a different plane so that corresponding detail cannot be compared in the two pictures.

Fig 4:9  
:10



:9 L. ATRIAL HYPERTROPHY



:10 ATRIAL INTERCORONARY ANASTOMOSIS





Fig 4:11, Case 12

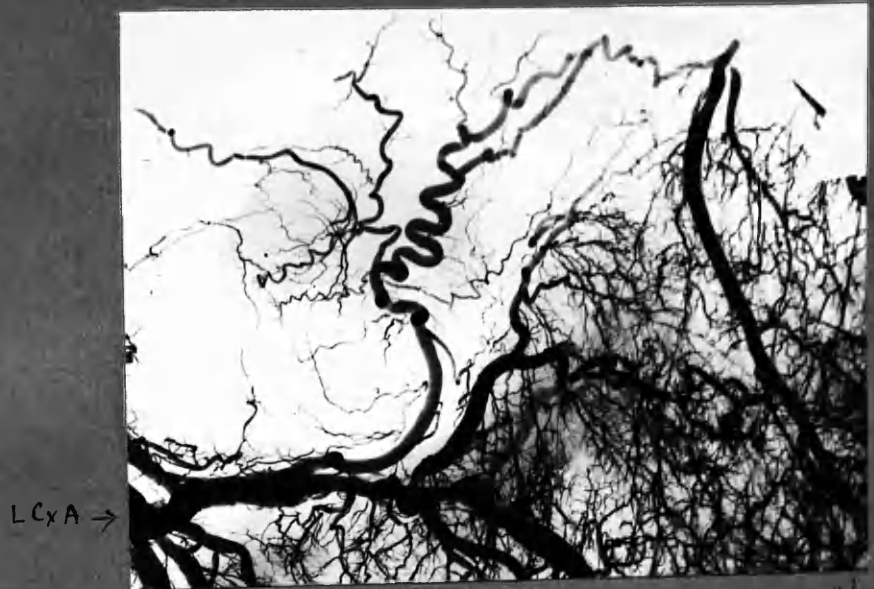
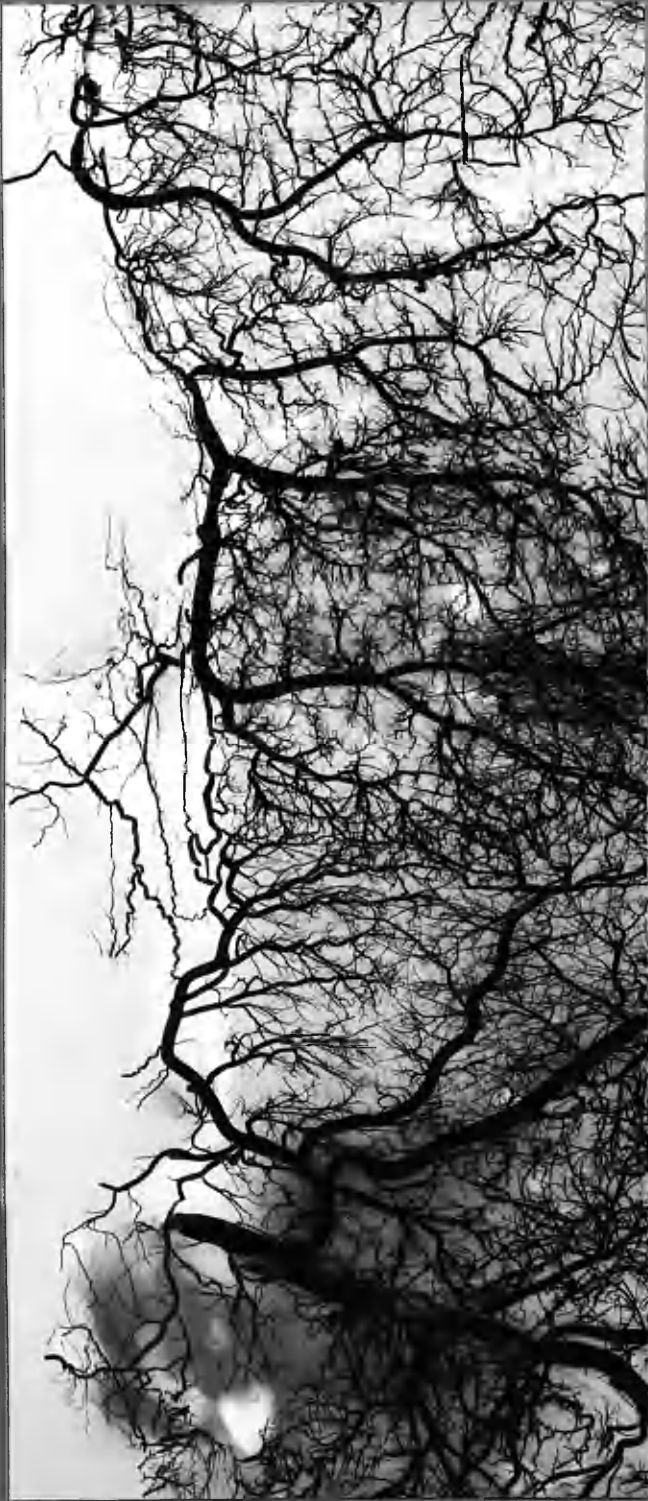
Fig 4:12, Case 17

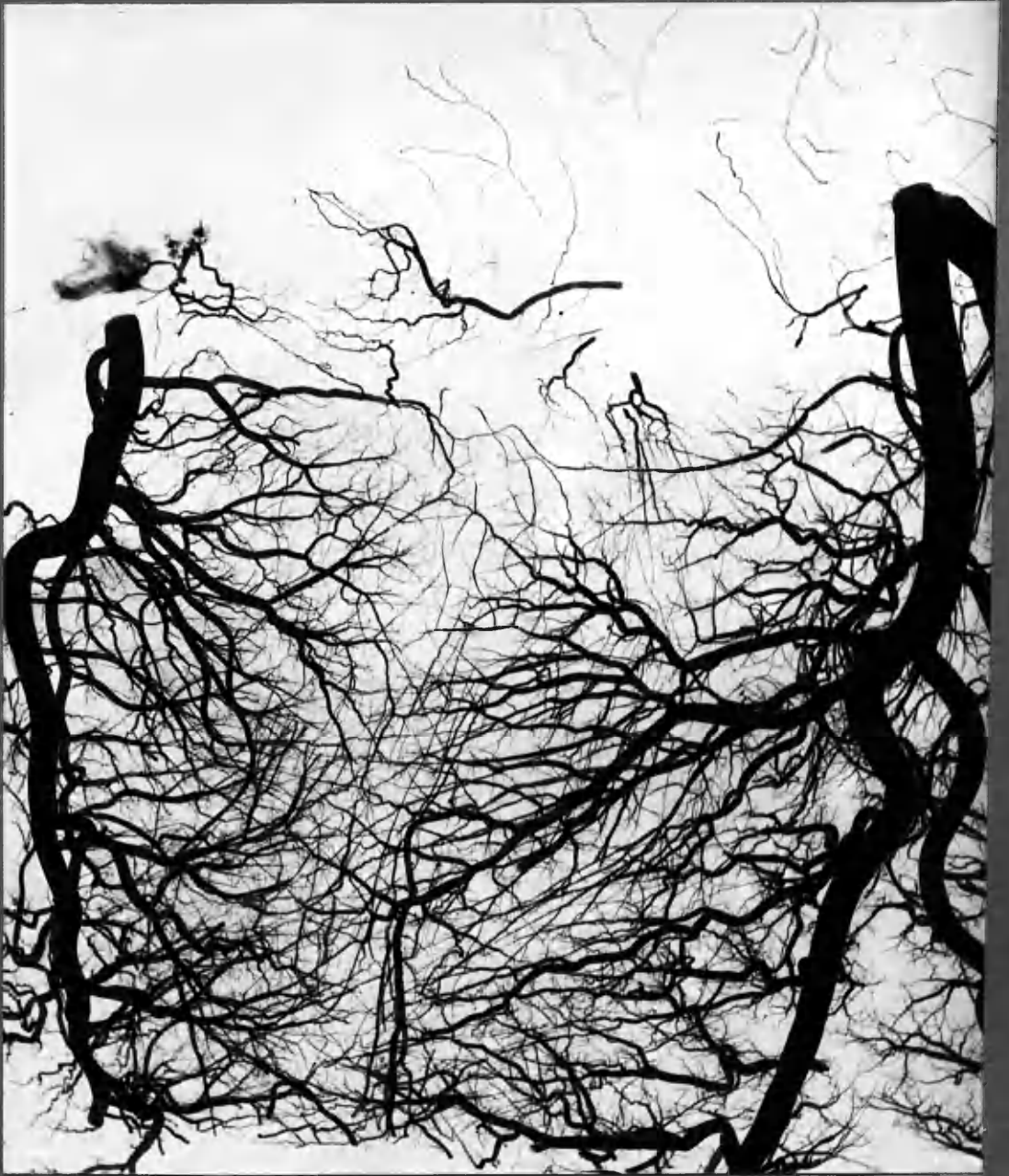Fig 4:13  
L RC



Case 24 : Atrial intercoronary anastomoses

ANASTOMOSES OF THE INTERVENTRICULAR SEPTUM.

Fig. 4:14.



W9

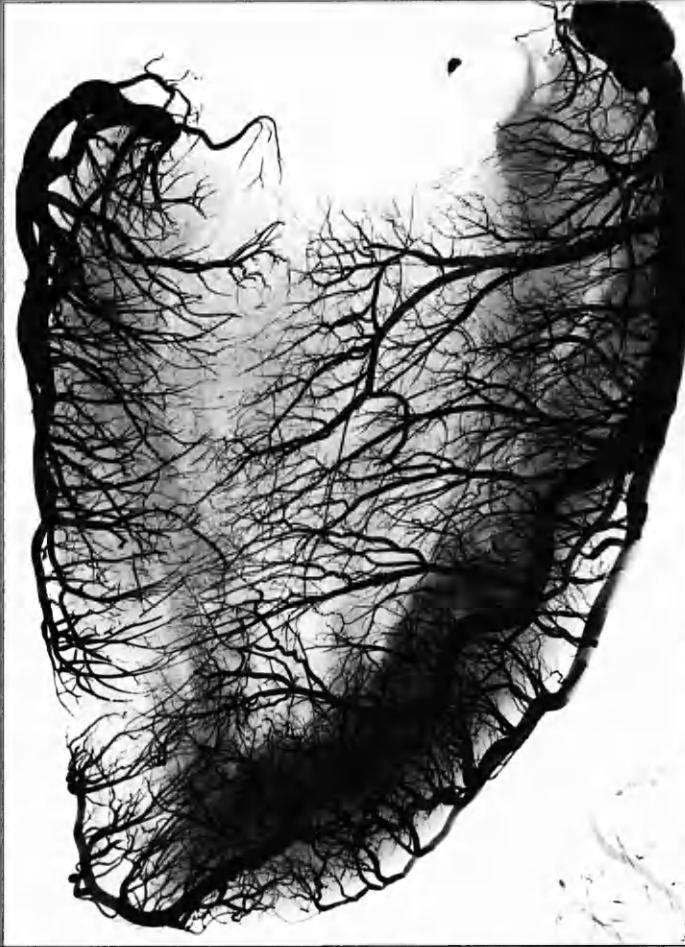x 2

Upper portion of interventricular septum : NORMAL HEART.

Fig. 4:15

Post. interventricular  
artery

ADA



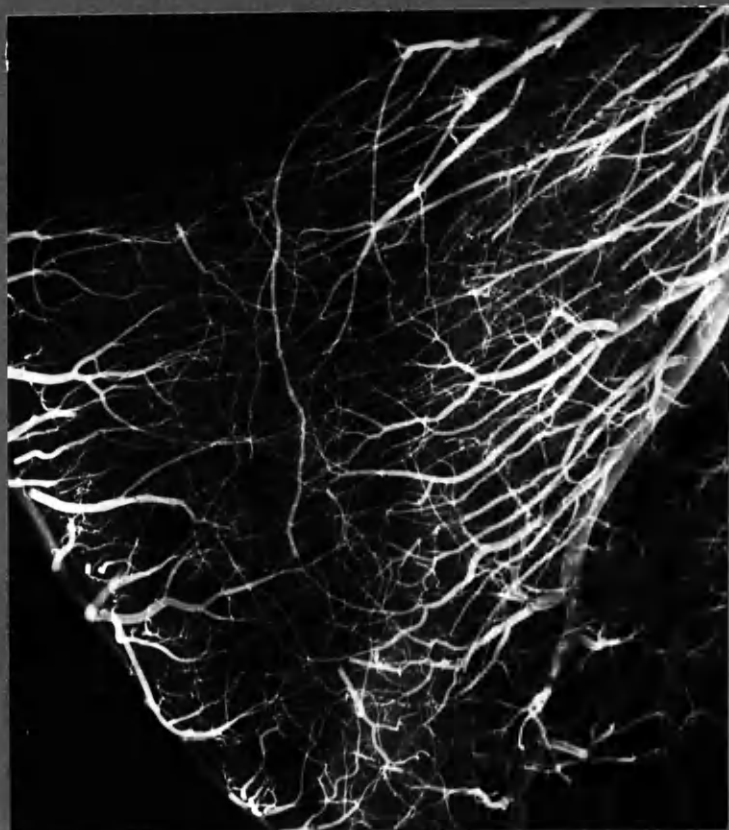
N<sub>2</sub>

x 1 1/2

Interventricular septum : NORMAL.

Comparatively crude injection. cf Fig 4:14.



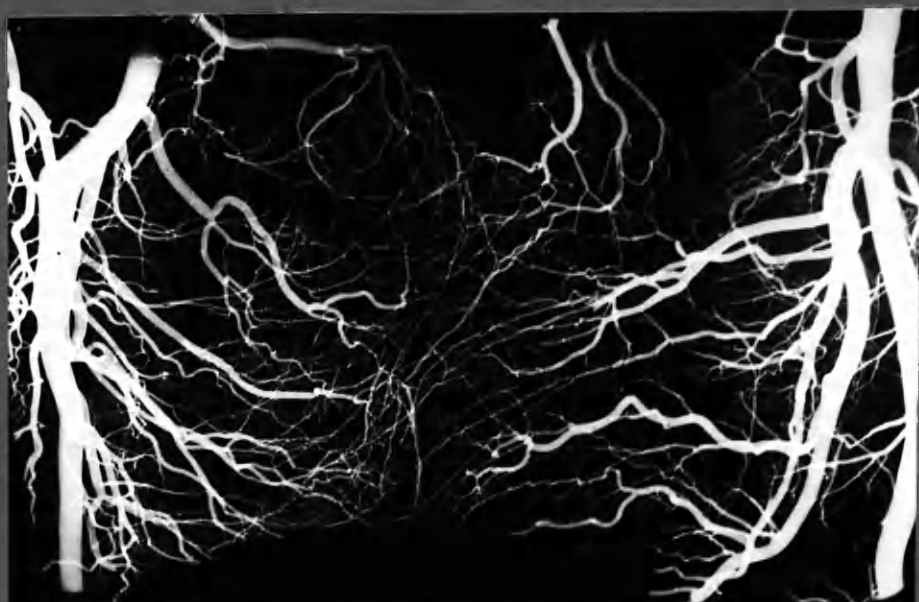

:16

N3

IVS

x 1 1/2



:17

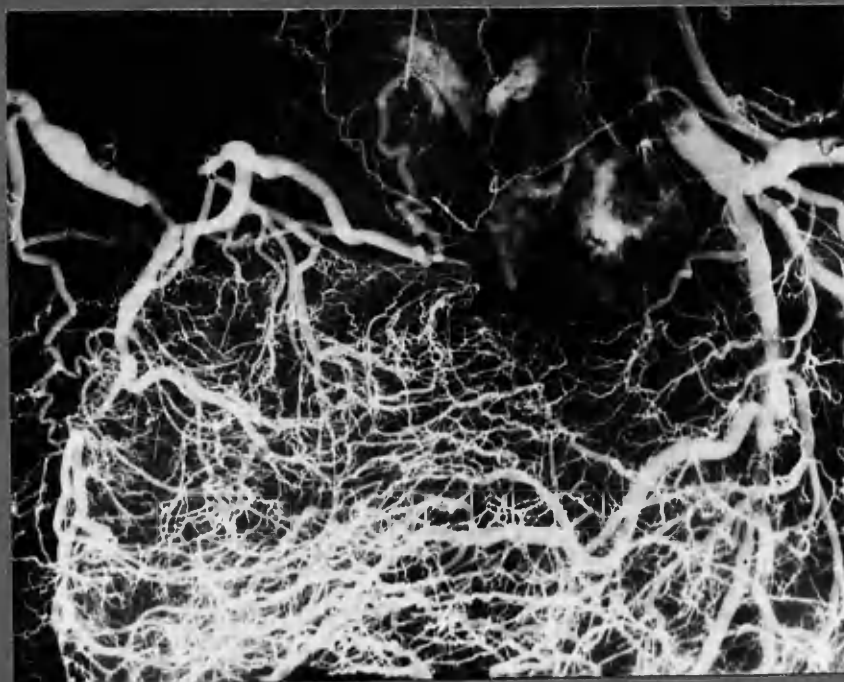
N'15

IVS, upper portion, enlarged heart,

x 1 1/2

INTERVENTRICULAR SEPTUM IN ADVANCED CORONARY ARTERY DISEASE .

Fig 4:18  
:19



Case 17

x 1 1/2



Case 19

x 1 1/2

Fig 4:20



Case 21

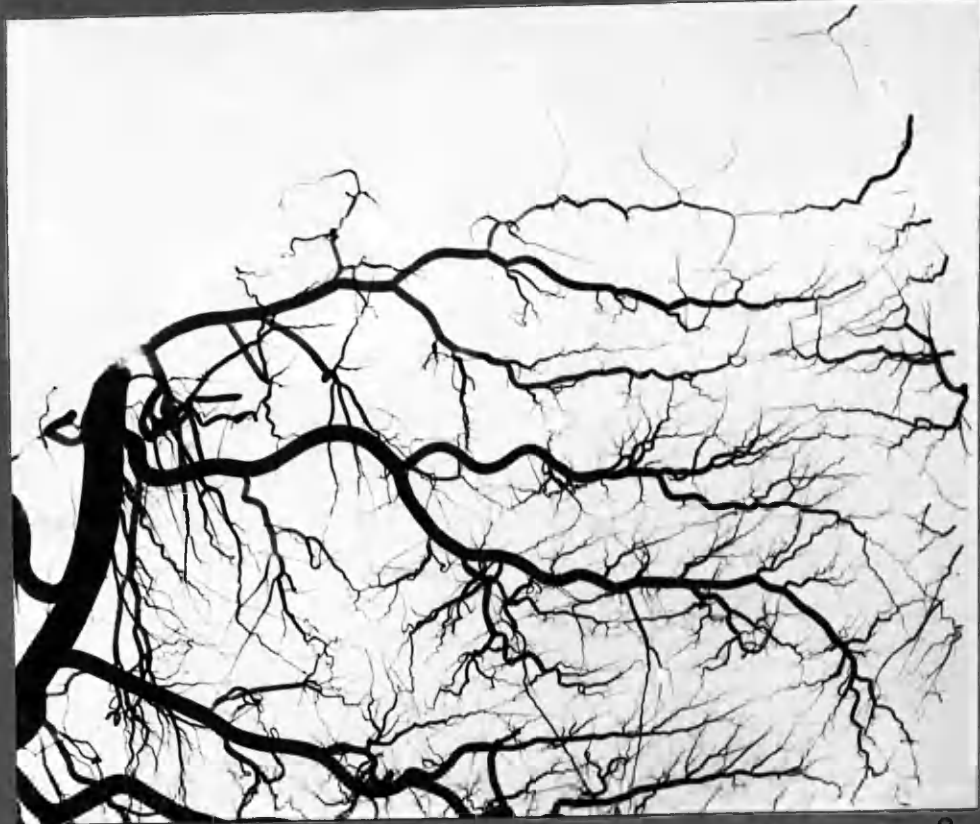(cf. fig 4:14 .)

$\times 1\frac{3}{4}$

SUPERFICIAL ANASTOMOSES: ANTERIOR WALL OF RIGHT VENTRICLE

Fig 4:21  
:22

Pulmonary Artery

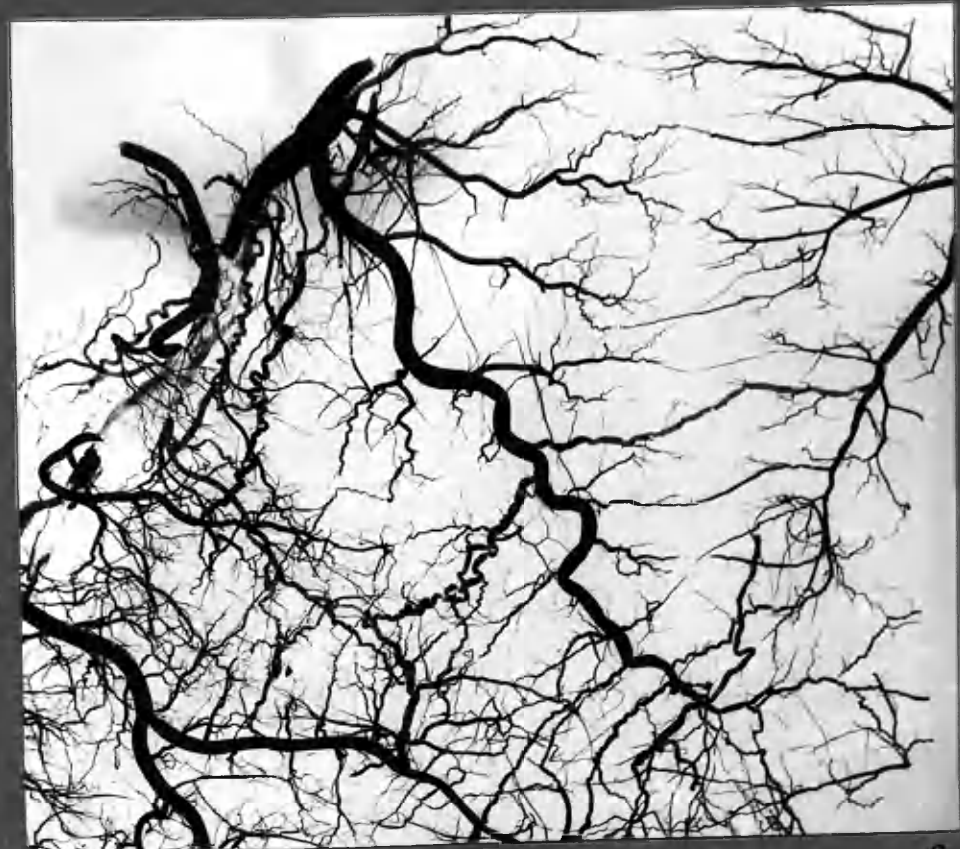


RC

Branches of ADA

21

No. intercoronary communications between ant. desc. artery and left Coronary artery + accessory R.C., in ant. wall of R. ventricle. Reform. vessels in wall of pulmonary artery. Retrograde filling of accessory R.C. x2.



RC

Branches of ADA

22

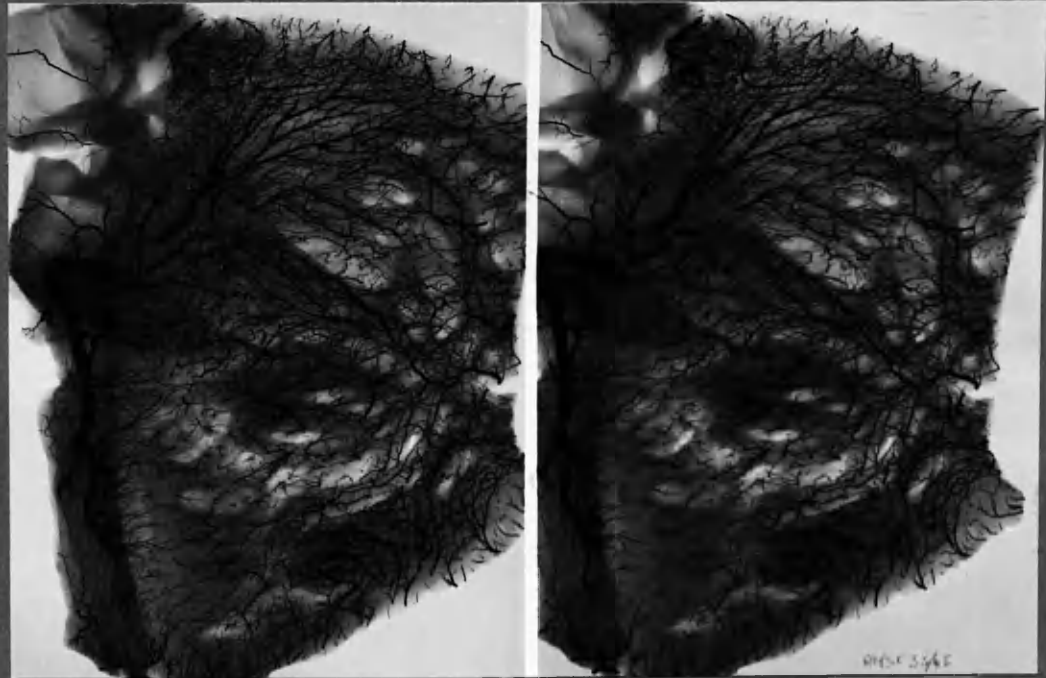
Case 24 Enlargement of intercoronary communications. x2.



4310

Fig. 23  
:24

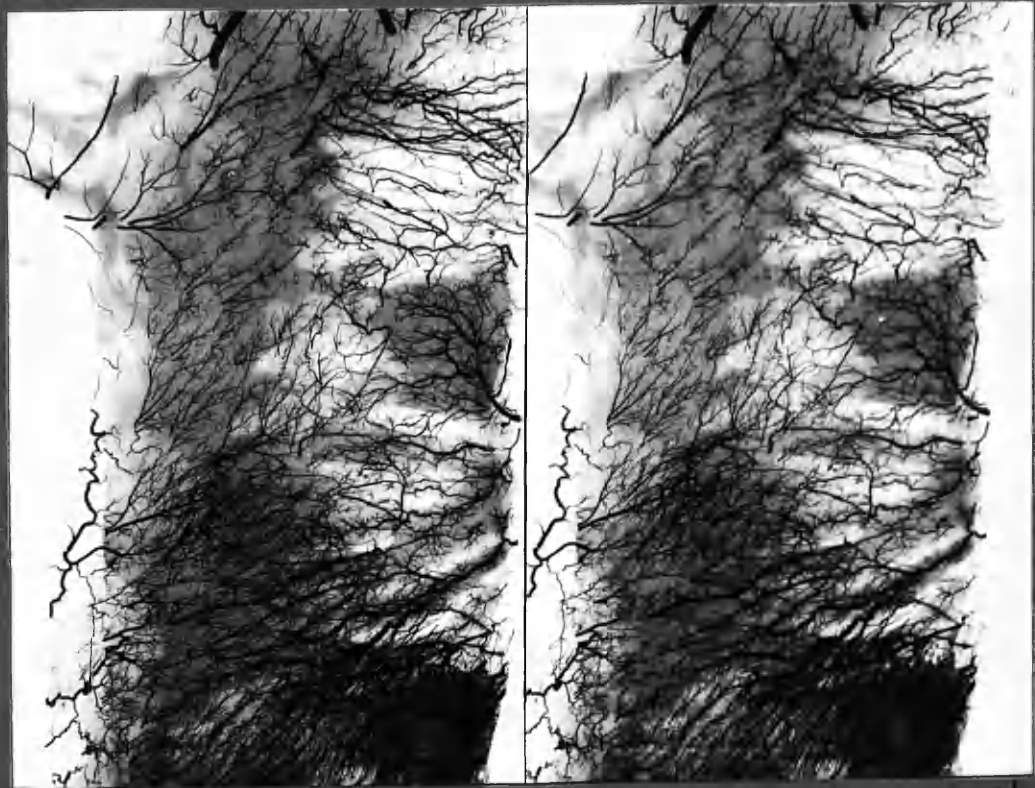
SUBENDOCARDIAL PLEXUS of the LEFT VENTRICLE



N10 NORMAL HEART, child, 8 yrs.

X1

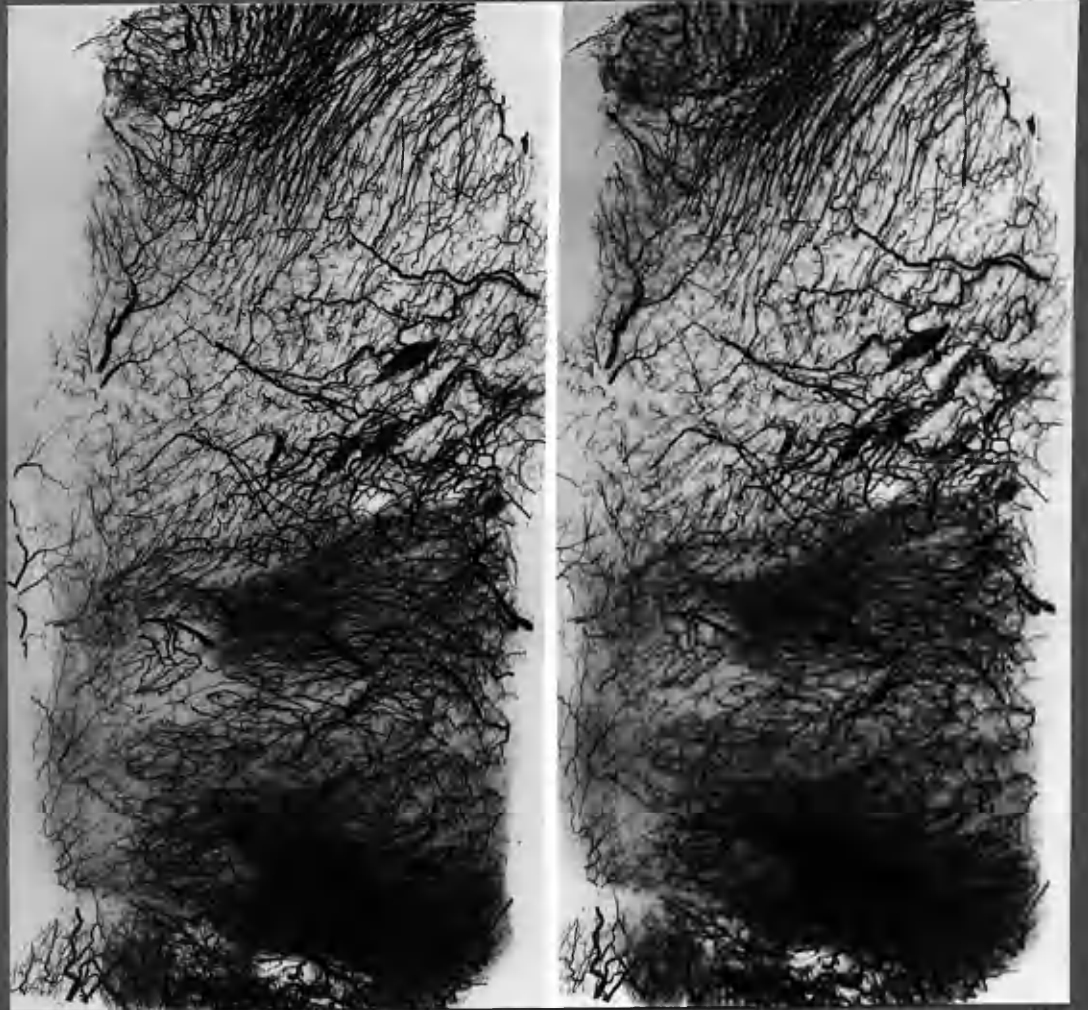
:23



Case 25. Coronary Artery Disease. Localized enlargement of deep vessels in post. LV. wall.

24

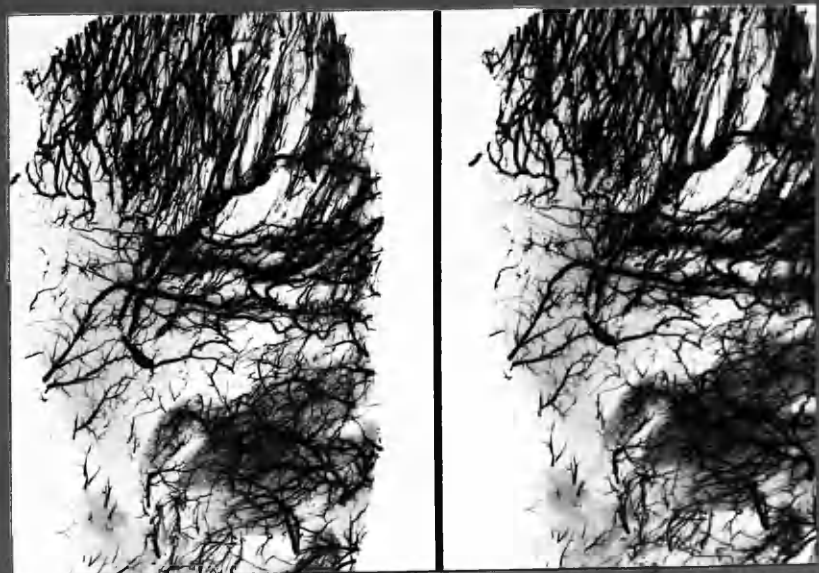
These specimens, and also those in Fig. 4-25, 26, were prepared by slicing the basal slab (formed by the opened L. ventricle) into 2 portions: The stereo pairs are arteriograms of the inner portions only, in this way avoiding the confusion created by overlapping superficial vessels and rendering the features of the subendocardial plexus more readily appreciated.



25

N<sup>o</sup> 17, aged 80 yrs. Subendocardial plexus of L. Ventricle.  
 Unusually rich anastomoses. The heart was slightly large but was not  
 the seat of evident disease.  
 The specimen was prepared for arteriography as in fig. 123, 124.

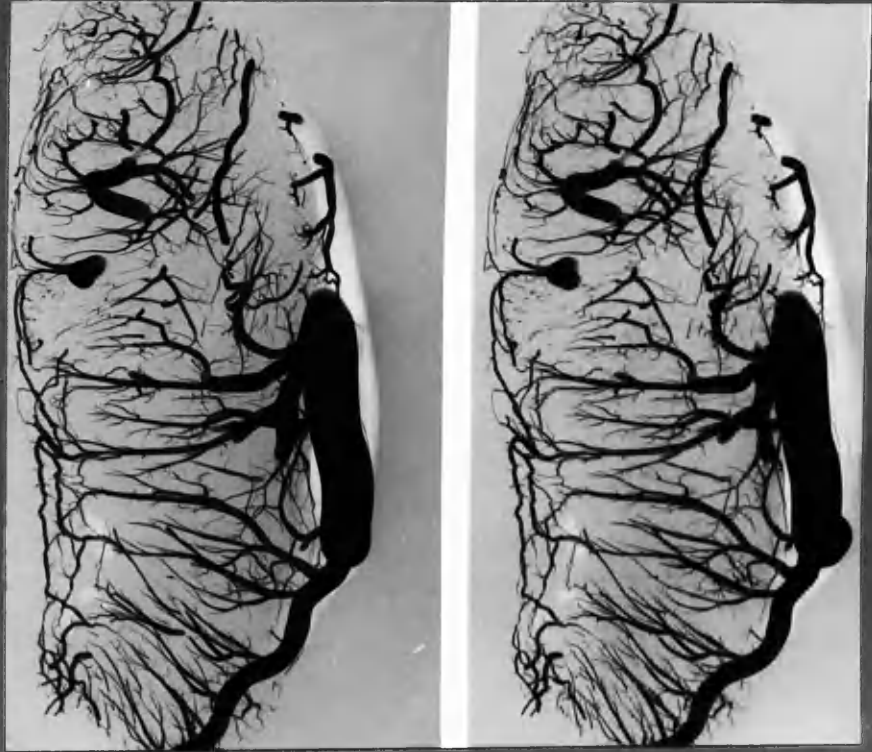
x1



26

Case 19. Enlarged vessels of subendocardial plexus in long-standing  
 coronary artery disease.  
 The specimen was prepared for arteriography as in fig. 123, 124.

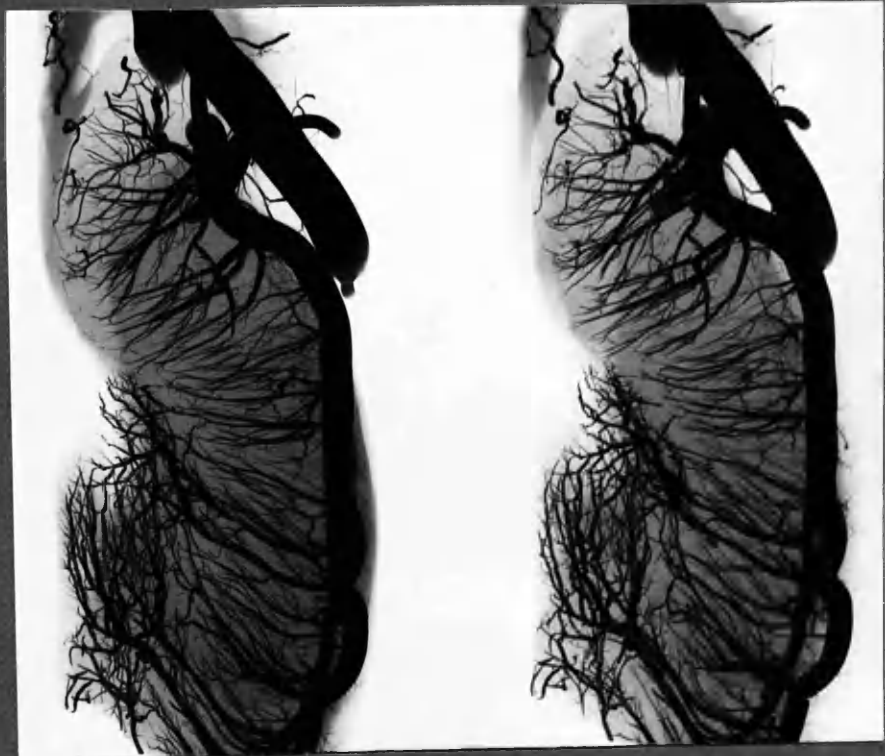
x1



:27

N7

x2



:28

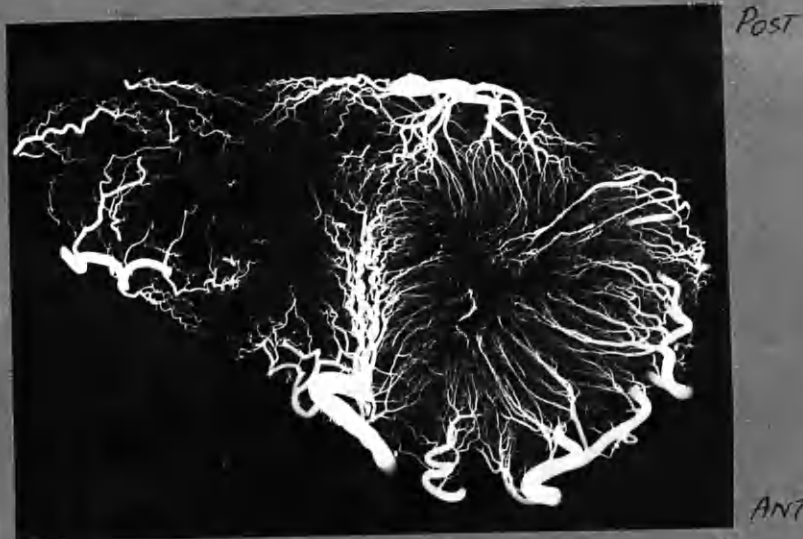
N7

x2

Two selected "vertical" sections of Left ventricle from a NORMAL heart: Epicardial artery on right and Ventricular cavity on left, showing communications between surface and deep vessels, and between vessels of the subendocardial plexus. The lower figure features the blood supply to a papillary muscle.

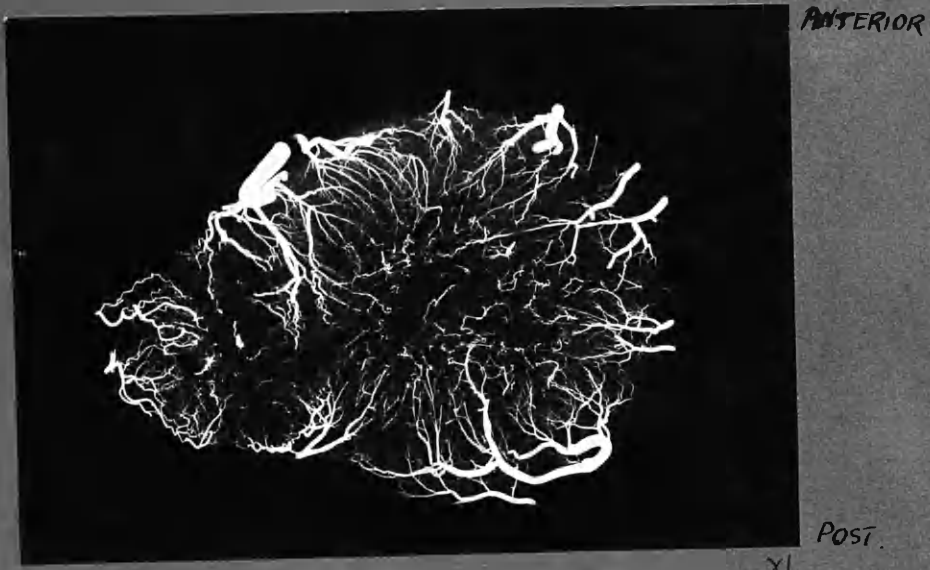
Fig. 4:29  
=30

:29



N<sub>6</sub> mid ventricular T. Section , as seen from above.  
NORMAL.

:30

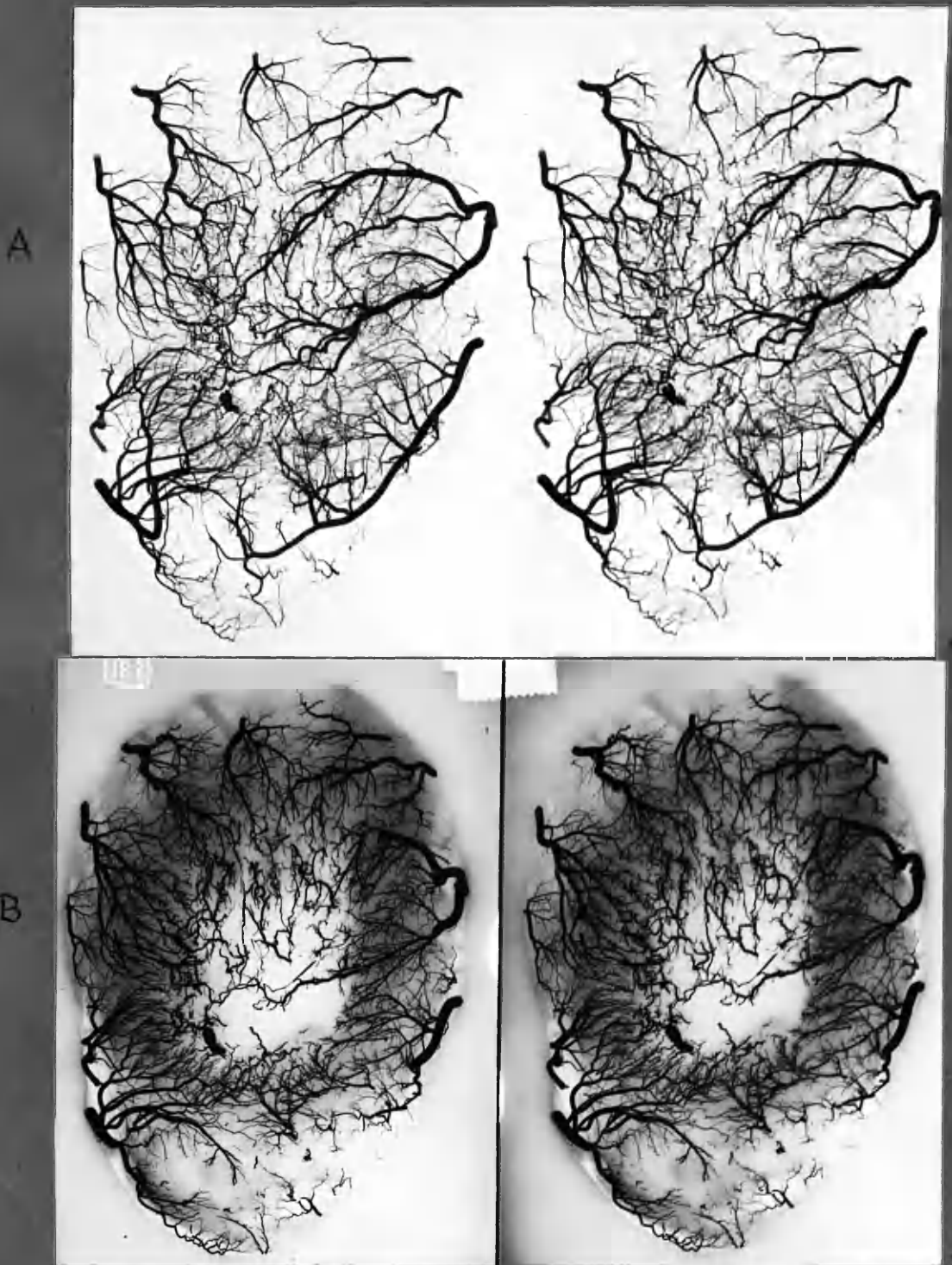


N<sub>8</sub> T.S. NORMAL ventricles , viewed from below  
This specimen was "stobbed" before sectioning , as in  
fig. 4:31 opposite , in order to demonstrate connections  
of subendocardial plexus .



4-113  
 SUBENDOCARDIAL PLEXUS OF LEFT  
 VENTRICLE AND COMMUNICATIONS AT THE APEX.

Fig- 4:31



N<sup>o</sup> 15

A: apex, viewed from above

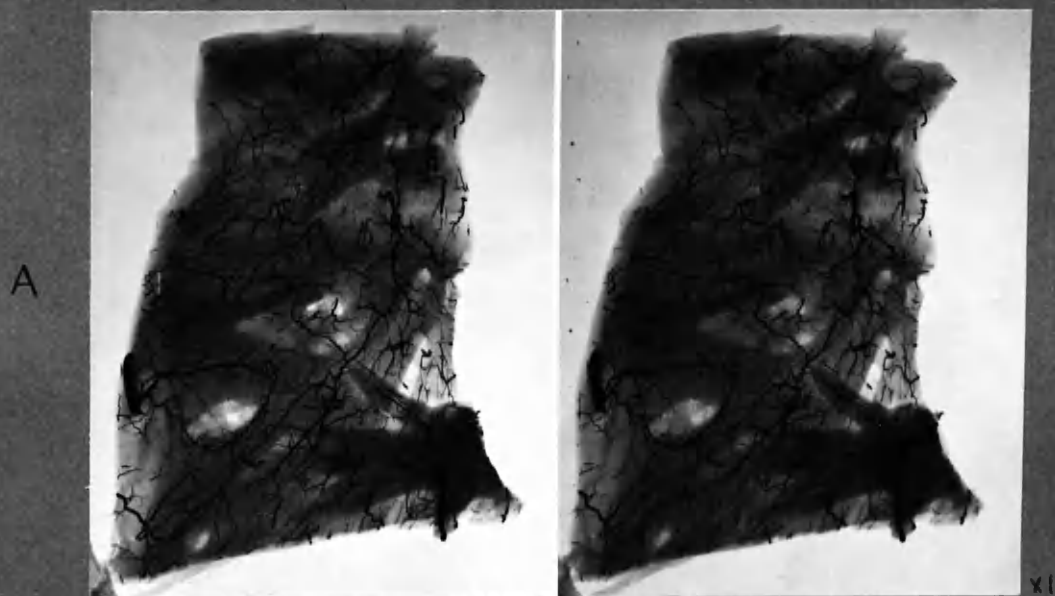
B: transventricular section.

In the preparation of these sections, the apex was "stuffed" against a board so that the knife left part of the "floor" of the left ventricular cavity in the section above the apex (B). In this way the connections with epicardial vessels can be traced. Also the manner in which the lower part of the subendocardial plexus is fed by vessels at the apex can be traced in "A". A superficial communication between branches of L. and R. coronary arteries can also be seen in this section.

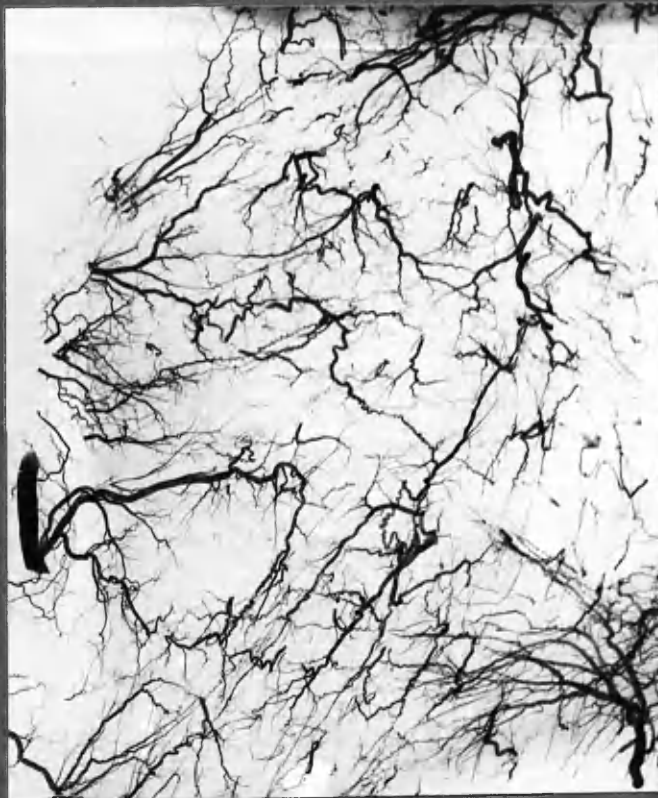Slightly enlarged heart, otherwise no abnormality was found.

## SUBENDOCARDIAL PLEXUS of the RIGHT VENTRICLE.

Fig 4:32

N<sub>11</sub>

B

N<sub>11</sub>

x2

- A: Radiograph of uncovered specimen showing tissue shadows  
 B: Radiograph of same specimen by immersion method. Tissue shadows eliminated.

The specimen was prepared in similar fashion to :23, :24, :25, :26, so that subendocardial plexus was portrayed without overlapping superficial vessels.

N.B. In this otherwise normal heart there was a minimal degree of R. ventricular hypertrophy, and this was the most prominent R. ventricular subendocardial plexus in the normal group. Death had resulted from carcinoma of bronchus.

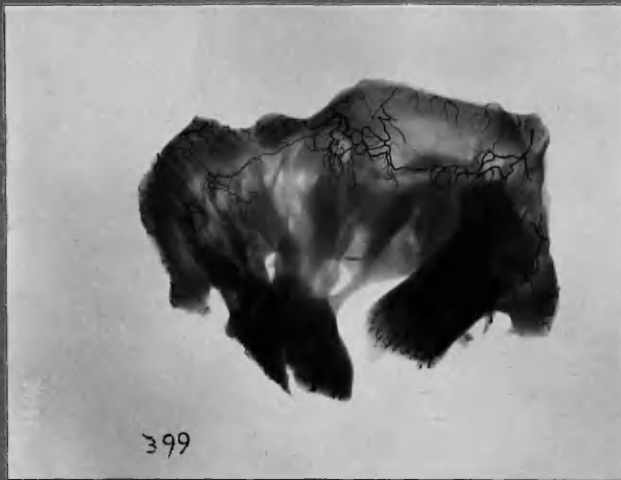Fig. 4: 33  
: 34  
: 35

:33



Case 19 x 2  
Dissection of anastomoses in R. ventricle in coronary artery disease. Most of these dilated, tortuous, intercommunicating vessels were superficial.

:34



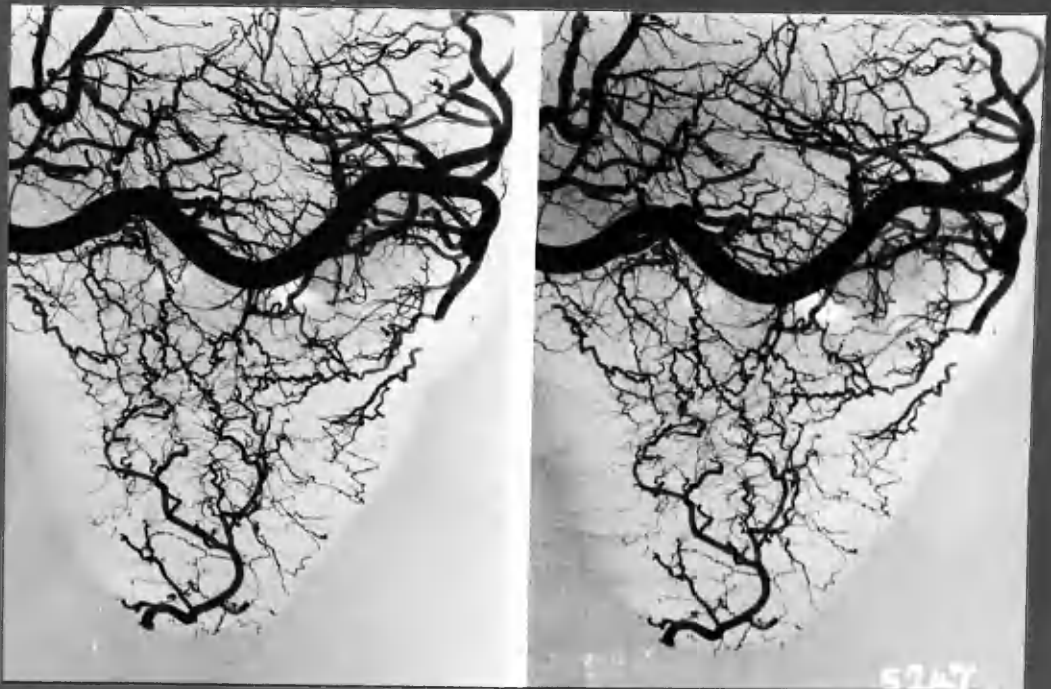
D14 Mitral stenosis. x1

ANASTOMOSES IN MITRAL VALVE

:35



D13 . No obvious valve disease.

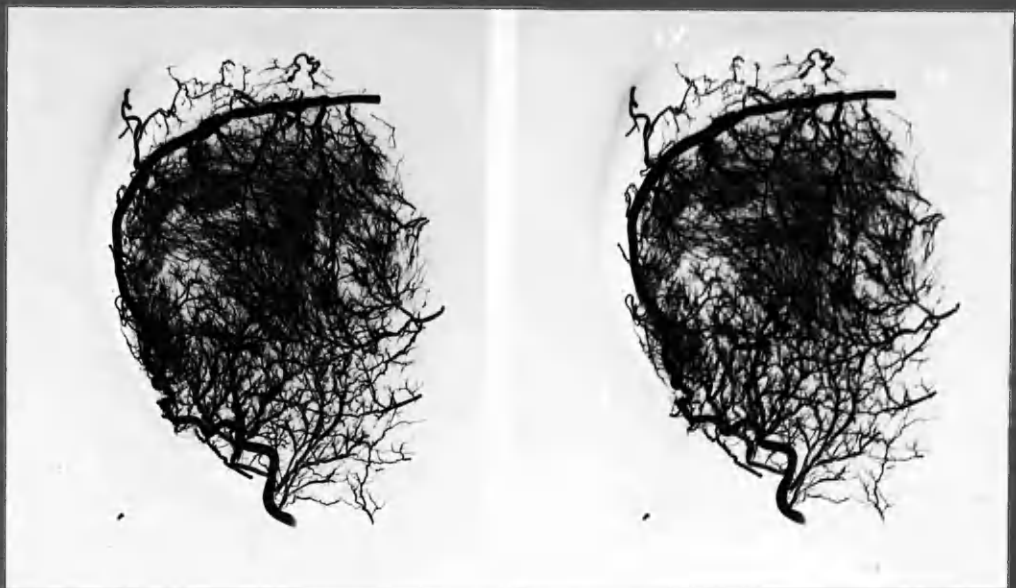

:36

N11

x 2.

NORMAL HEART. Most of the anastomoses are in the subendocardial layers of the R. ventricle. Often superficial anastomoses are found in this area - eg. N15 (Fig. 4:31) and case 17, below. Note also arteriae telae adiposae.



:37

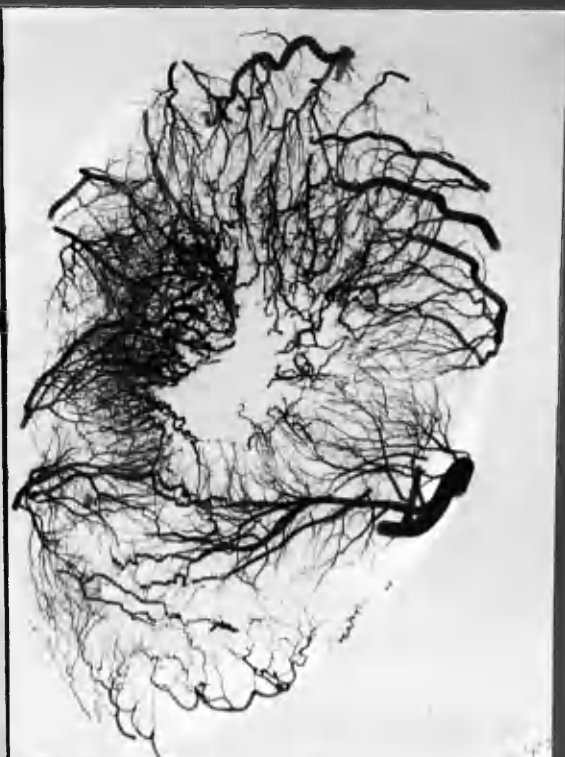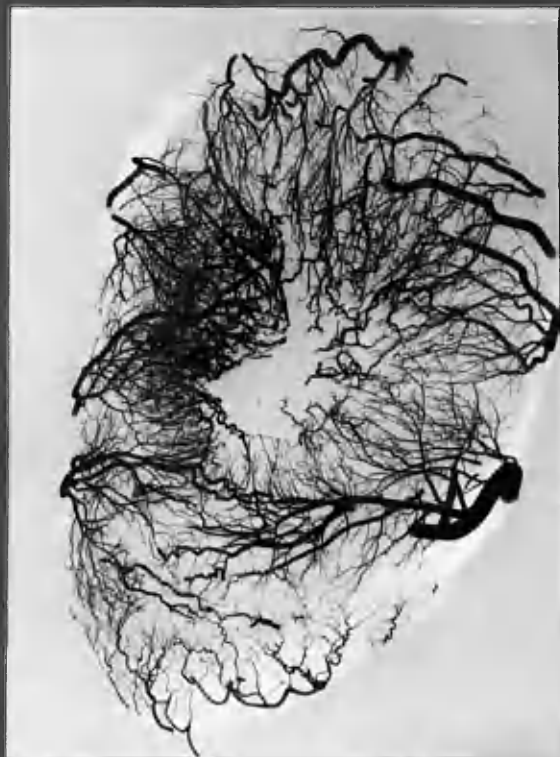
x1

Case 17.

CORONARY ARTERY DISEASE of long-standing. Large bore superficial communication between ADA and marginal branch of LCXA. Also communications with subendocardial plexus of left ventricle.



RV  
wall



38

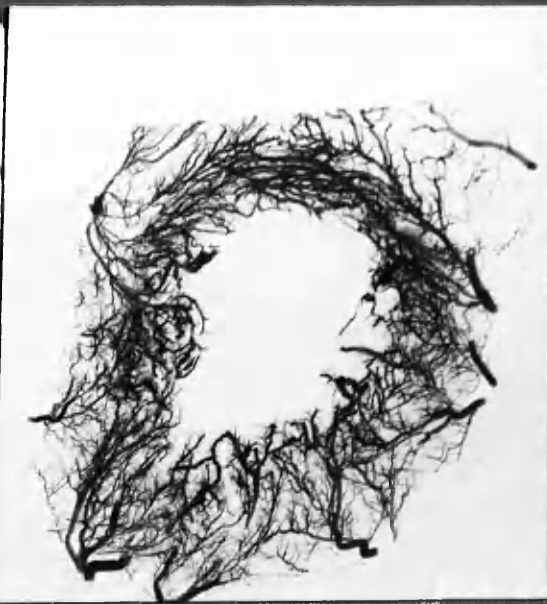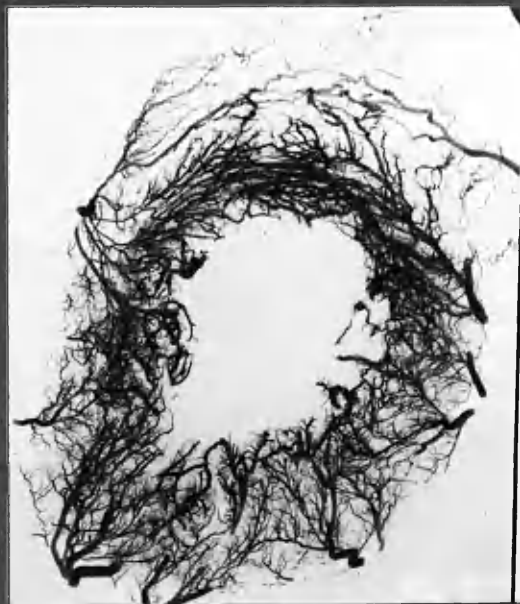FADA

RV

Case 25

Enlargement of subendocardial plexus of LV mainly in post. wall, cf  
generalized enlargement in Case 17, below.

RV



39

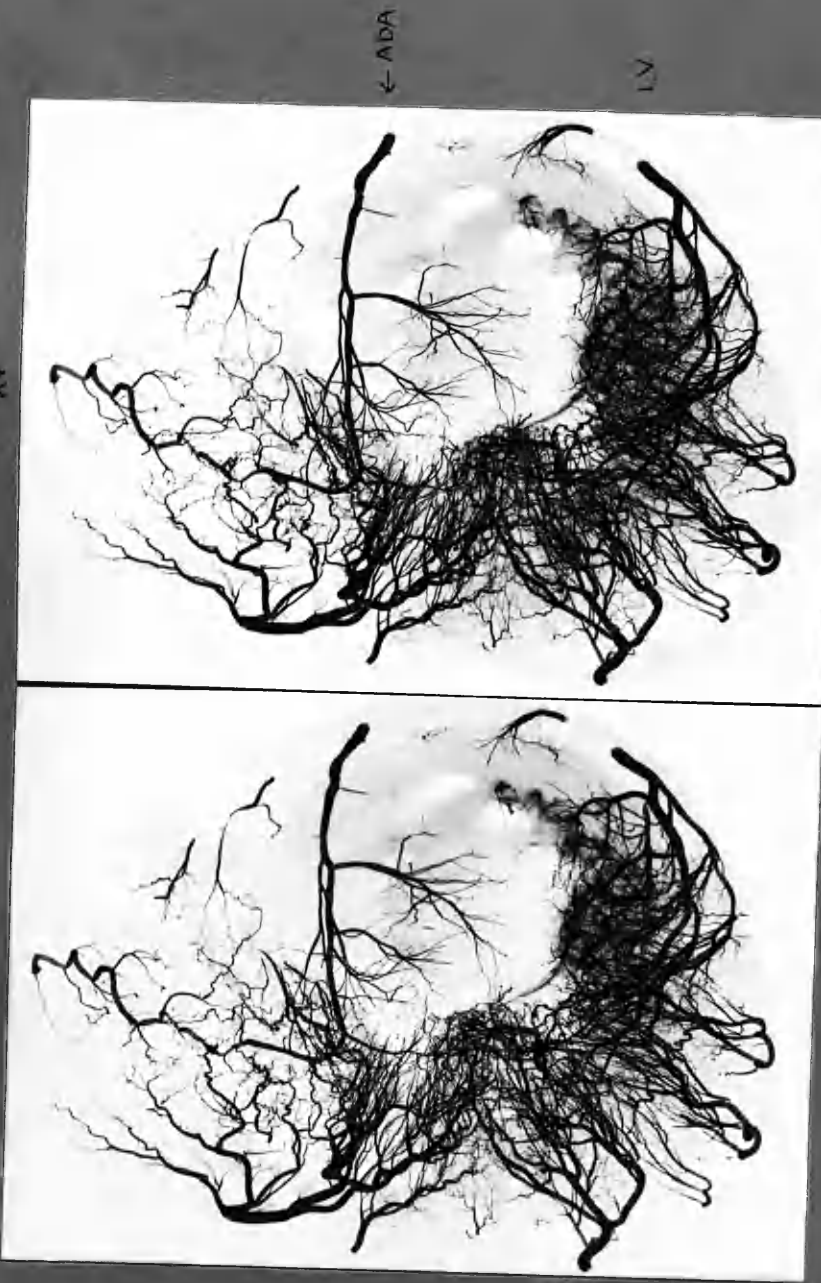
FADA

Case 17

cf. Fig 4:29, 611a.  
(Normal)

X1

Fig 4:40



Case 20 Apex viewed from below:  
Large area of "through and through" infarction in which there is little or no small vessel injection.  
Superficial and deep communications are of small scale.

Post.  
↓  
Ant.

Case 23

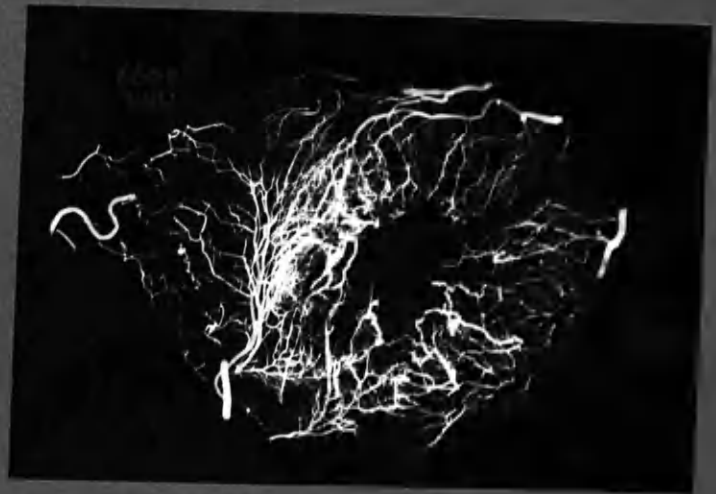Old occlusion of ADA. Antero-septal ischaemic changes.



41

Case 18

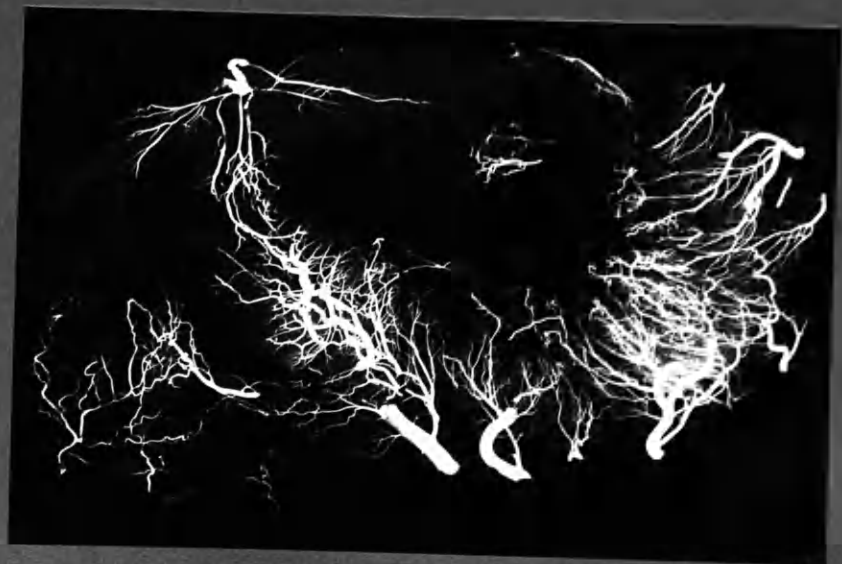Old occlusion of ADA. Antero-septal ischaemic changes.



42

Case 9

Recent occlusion RC. Necrosis of post. walls of RV and LV. Little antecedent enlargement of anastomoses.

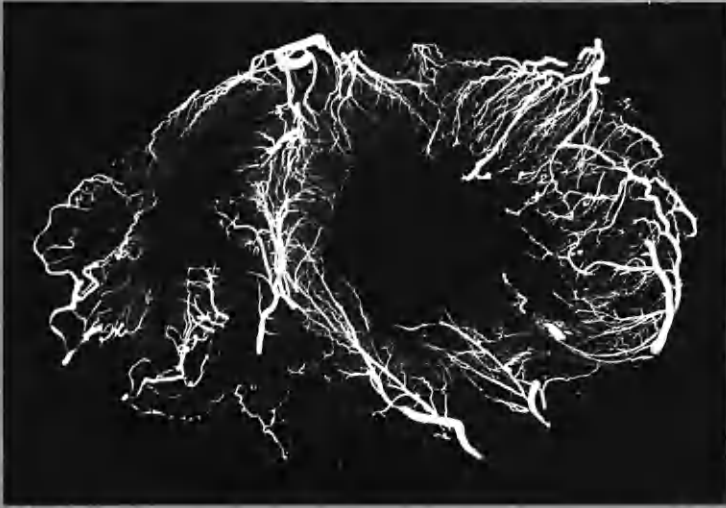


43

x1

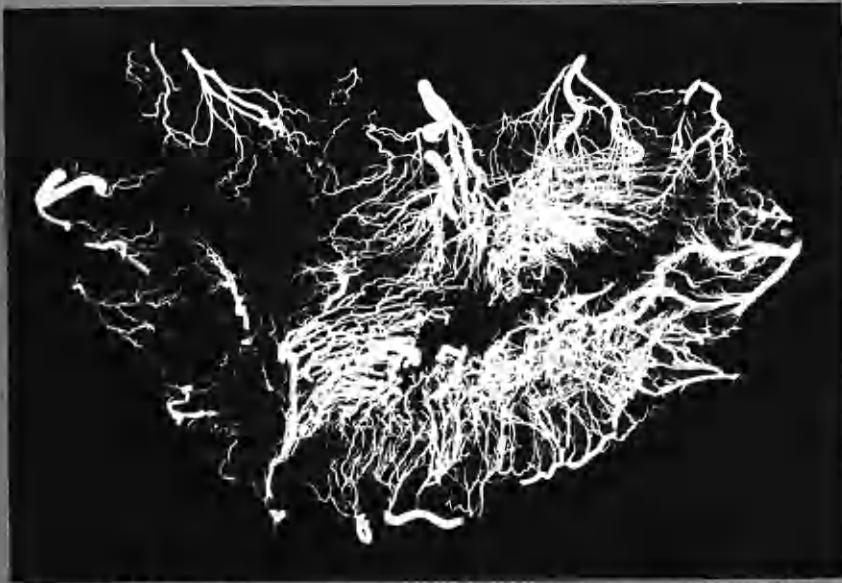
Fig. 4:44  
:45  
:46

Post  
|  
ANT.

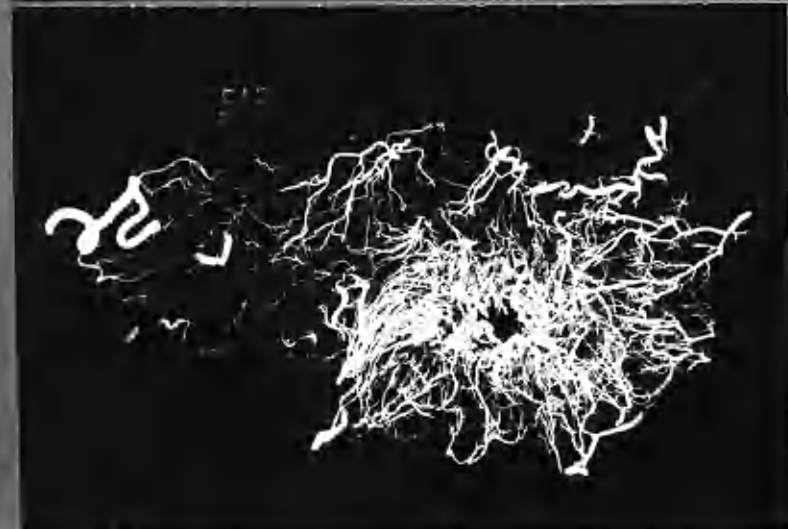

Case 13

x1



midventricular  
section.



near cardiac  
apex

Case 6

x1

Chronic generalized cardiac ischaemia  
Widespread enlargement of channels in inner zone of LV.



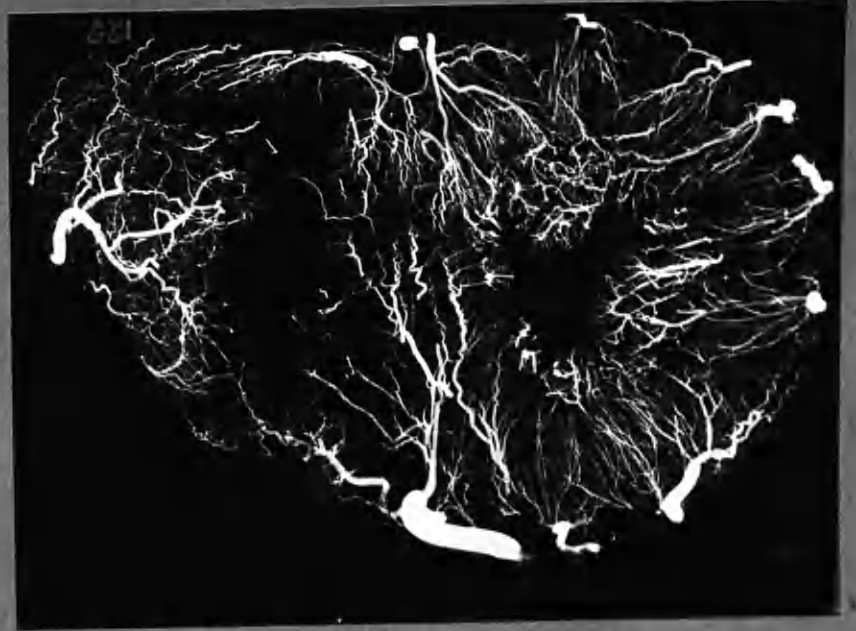CHANGES IN THE SMALL VESSELS OF THE HEART WALL IN HYPERTROPHY

Fig 4:47  
:48  
:49

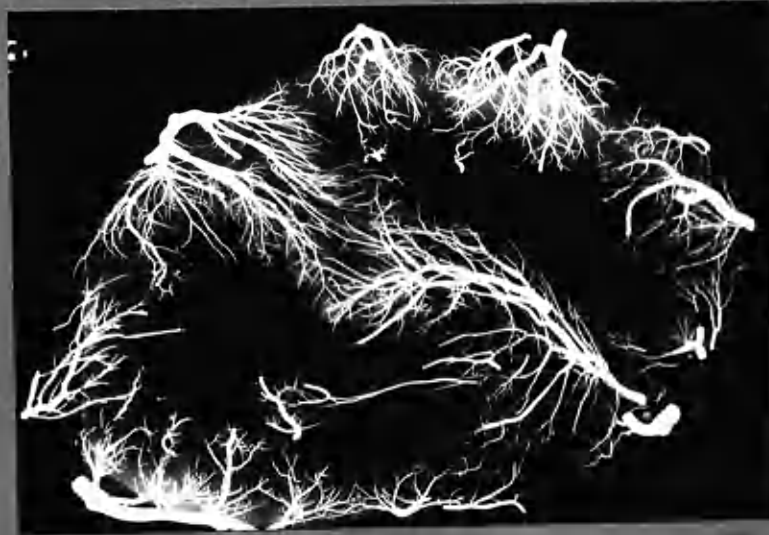D13  
Left ventricular hypertrophy  
(non-valvular)

Slight increase in prominence of subendocardial vessels.

POST.  
↑  
↓  
ANT

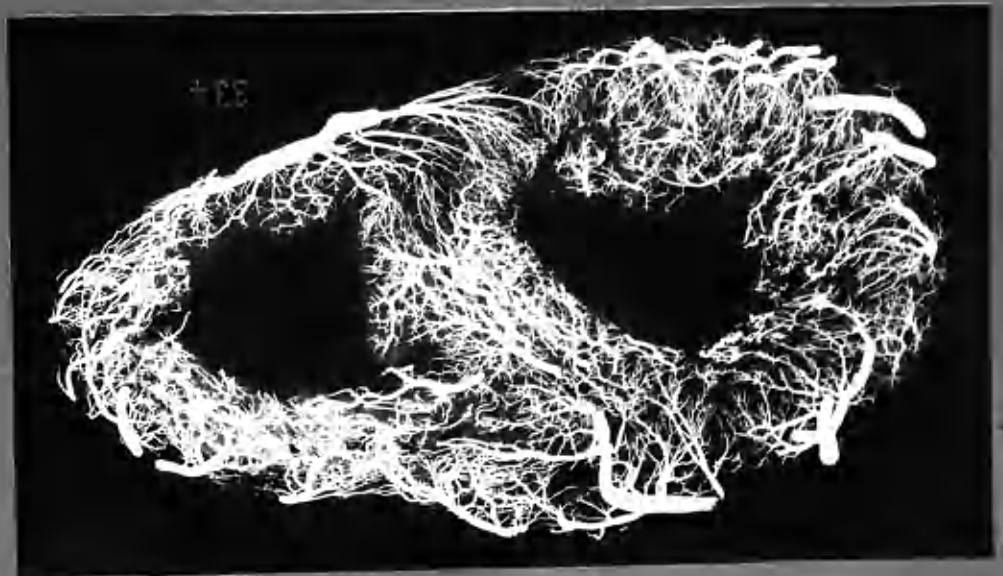


:47



D7.  
Right vent. hypertrophy.  
(Essential pulmonary hypertension).

:48



:49

D4. Right and left ventricular hypertrophy.  
Aortic and Mitral valvular disease.



Case 19

x2½

Stereo pair enlarged to show sinusoidal dilatation of the capillary bed. The appearance of these structures contrasts with that presented by dilated arterial anastomoses, as illustrated in many of the foregoing figures. Some widely dilated vessels of the subendocardial plexus are also seen.

Other examples of coronary artery anastomoses are to be found among the illustrations in Chapter 6.



CHAPTER 5

THE RELATIONSHIP OF

CORONARY OCCLUSIONS

TO

MYOCARDIAL DAMAGE



**SECTION 101.101 - Purpose**

It is the purpose of this Act to provide for the...  
of the...  
of the...  
of the...  
of the...

**SECTION 101.102 - Definitions**

As used in this Act, the following definitions apply:

(a) "Person" means any individual, partnership, firm, corporation, or other legal entity.

**SECTION 101.103 - Short Title**

This Act may be cited as the...

- (1) To establish a...
- (2) To provide for the...
- (3) To ensure that...
- (4) To encourage...
- (5) To provide for the...
- (6) To ensure that...
- (7) To provide for the...

**SECTION 101.104 - Construction**

This Act shall be construed to effect its purpose...

**SECTION 101.105 - Severability**

If any provision of this Act is held to be invalid...

**SECTION 101.106 - Effective Date**

This Act shall take effect on...

Chapter 5: THE RELATIONSHIP OF CORONARY OCCLUSIONS TO MYOCARDIAL DAMAGE.

	<u>Page</u>
<u>INTRODUCTION.</u>	5:1
<u>DEFINITIONS AND CRITERIA</u>	
Coronary artery occlusion Grades I, II, III.	4
Subdivision of coronary arteries.	7
Abbreviations.	8
Myocardial damage.	9
Age-grouping of arterial occlusions and myocardial damage.	10
Other terms used.	10
<u>NOTE ON THE PRESENTATION OF OBSERVATIONS IN THIS CHAPTER.</u>	11
<u>GENERAL OBSERVATIONS ON CORONARY ARTERY OCCLUSIONS AND RELATED MYOCARDIAL DAMAGE.</u>	12
<u>EPISODES OF CORONARY ARTERY OCCLUSION AND MYOCARDIAL DAMAGE.</u>	15
Data derived from the last 15 cases.	17
<u>DEGREE OF NARROWING WHICH PRECEDED OCCLUSION.</u>	19
<u>FURTHER DETAILS IN THE RELATIONSHIP OF CORONARY OCCLUSION AND MYOCARDIAL DAMAGE.</u>	
(1) The distribution of coronary artery occlusions in relation to myocardial infarction.	27
(2) Coronary artery occlusion without myocardial infarction.	30
(3) Extent of old-standing v. recent myocardial damage.	33
(4) Ischaemic myocardial damage in the absence of coronary artery occlusion.	35
(5) The proximate cause of regional myocardial damage, including "infarction at a distance".	36
(6) Extension of infarction.	38
<u>ANTERIOR DESCENDING ARTERY, the "artery of death".</u>	44
<u>INFARCTION OF THE RIGHT VENTRICLE and related coronary artery occlusion.</u>	51
Congestive cardiac failure.	57
<u>CORONARY OSTIAL STENOSIS.</u>	61
<u>NOTES ON BRANCH OCCLUSIONS.</u>	65
<u>SUMMARY AND CONCLUSIONS.</u>	68



6

OBSERVATIONS ON THE RELATIONSHIP OF CORONARY ARTERY  
OCCLUSIONS TO MYOCARDIAL DAMAGE

Recognition of the relationship borne by complete occlusion of a coronary artery to massive myocardial infarction in its anatomical territory presents little difficulty in an apparently straightforward instance. In many cases, however, neither is the background to final occlusion of an artery simple nor does the distribution and extent of myocardial damage bear a simple relationship to it. It was found that an occlusion had sometimes developed in several episodes and its condition at death in terms of completeness or incompleteness did not always reflect the state of affairs believed to have existed at the time of muscle damage. Likewise, several episodes of myocardial damage could be found in the territory of a single artery.

When individual cases were examined in detail in this investigation it was often possible to trace in retrospect the likely sequence of events. In doing so, each episode of arterial occlusion in each coronary artery and each episode of myocardial damage in each territory could sometimes be satisfactorily correlated. Correlation of these features would not have been valid without the demonstration by an injection method of the anatomical distribution of the coronary arteries and the background of anastomotic enlargement. Table 5:1 indicates the degree of general correlation in this series between the pathological changes in the myocardium and in the coronary arteries when individual cases were analysed from this point of view. This high degree of correlation of findings in individual cases may usefully be kept in mind when considering the aggregate data which form the burden of this chapter.

Table 5:1

GENERAL CORRELATION OF PATHOLOGICAL CHANGES IN THE CORONARY ARTERIES AND MYOCARDIUM IN INDIVIDUAL CASES. 25 Cases.			
	Case Nos.		
	1-5	6-10	11-25
I Very close correlation	(1)	-	6
II Close correlation, minor discrepancy or uncertainty	(3)	5	7
III Important discrepancy or uncertainty	-	-	2
0 No satisfactory correlation	(1)	-	-

Note 5:1. ( ) Entries for cases 1-5 are enclosed in brackets. Owing to insufficiency of findings in these cases, as opposed to cases 6-25, the assessment of correlation was made with a lesser degree of certainty.

The detailed examination of a relatively small number of cases has provided a picture of the manifold variety of changes which may be found in the more severe phases of coronary artery disease. There was an individuality about the pathological features of each heart and indeed of each lesion - which made each case in its own right a subject of instruction - and sometimes, of surprise. At the same time this very individuality introduced great difficulty in the abstraction of data of a numerical order suitable for analysis of the series as a whole. Doubtless the recognition and demonstration of what can happen in this complex disease has more importance than how often certain contingencies arise, especially where the series under consideration is a small one. At the same time an analysis of the collective data of this series has brought out a number of points of interest and is complementary to the detailed examination of the individual case. Thus, the collective data presented in this chapter have helped to preserve perspective. Conversely, constant reference to individual instances has helped to prevent fallacious deductions being drawn from comparisons of numerical data.

In this chapter the collective data which bear upon the subject of coronary artery occlusion and ischaemic myocardial damage are presented and discussed. It is emphasised at the outset that material of this order could readily be handled in a fashion that would have very little usefulness in the study of coronary artery disease - and which indeed could be frankly misleading. Thus the absolute incidence of a particular feature may be compared with the corresponding findings in other series. In making such comparisons, it will be recognised that the absolute incidence of, for instance, coronary artery occlusions in a given series may variously reflect the selection of cases, the criteria adopted, the method used and the diligence with which the observations were pursued. Further fallacy would be introduced were a series correlation to be attempted between the incidences of any two features expressed as simple numerical values, as for instance the incidences of myocardial damage and coronary artery occlusion.

Categorisation of findings necessary for the abstraction of suitable data can introduce into a complicated subject a simplification which is artificial. Again, the degree of correlation between two findings will depend to a large extent on the selection of data. Conclusions drawn from the comparison of aggregate findings therefore have always been made with reservation and tested in the light of individual examples. Thus it was recognised that comparison of the incidence of arterial occlusion at particular sites in the coronary tree with the anatomical sites of myocardial damage could be valueless, unless detail of distribution of the arteries involved in each case was also known - and expressed.

One of the difficulties encountered in this analysis has been the selection of criteria for the definition of the terms used and some of these will be indicated before the presentation of findings. Other terms will be defined or explained as occasion arises.

Despite the shortcomings and fallacies inherent in the type of data handled in this chapter, it is hoped that their abstraction has served some purpose and that some useful concepts may have emerged.

## DEFINITIONS AND CRITERIA

### Coronary Artery Occlusion

"Occlusion" of a coronary artery is used in three senses, in regard to its severity or completeness.

#### A. Main stem occlusions.

##### 1. Grade I occlusion: "Complete occlusion".

By this is meant complete obliteration of the arterial lumen as found at the time of death, no matter for how short a distance, nor that there be evidence of canalisation at one or both ends.

##### 2. Grade II occlusion: "Canalised occlusion" or "canalised-once-complete occlusion".

Such occlusions were incomplete at death; but features were still present which were highly suggestive that occlusion was at one time complete and that continuity of the lumen had been restored by the process of canalisation. The detail of these features is described in Chapter 7. Classification of an occlusion as "canalised" was made after examination of the arteriograms, histological sections and, where available, of the serially mounted free-hand sections of the arteries. Occlusions were placed in this category no matter how narrow the channels might be through which continuity of lumen had been restored. On the other hand an arbitrary criterion of 1 mm. lumen diameter at the narrowest point was adopted as the maximum allowable in a lesion to be classed as a canalised occlusion. As will be seen in the text, there was little evidence that occlusion had ever been complete where the arterial lumen, as found at death, was greater than 1 mm. in diameter. Whereas lesions which were

more severely stenosed than 1 mm. lumen diameter typically showed evidence suggestive that the artery had been completely occluded at an earlier date.

In practice there was little difficulty in the majority of lesions in deciding whether or not they were the product of complete occlusions, followed by canalisation. In case of doubt, the lesion was placed in grade III.

A complete occlusion that had been by-passed by enlarged adventitial vessels or other near-by channels was not classed as a canalised occlusion but was placed in grade I.

3. Grade III occlusion: "Severe narrowing".

This term has been applied to lesions of main-stem arteries in which the lumen diameter was 1 mm. or less at the point of maximum narrowing, and which lacked conclusive evidence that the lumen had at any time beforehand been completely obliterated.

B. Branch occlusions. (2nd Division<sup>¶</sup> arteries only)

In the case of branches of the main stem arteries the criterion adopted for the upper limit of lumen diameter (for classification as occlusion, II or III) was 1/3 of the original lumen diameter. In most instances, branch lesions with stenosis of the lumen to this extent were thought to be instances of canalisation of complete occlusion.

Branch occlusions moreover are only recorded along with main stem occlusions in the case of second division arteries, and then only where the occlusion commenced within one centimeter of the parent stem, unless the branch was a particularly large one (as was sometimes the case with the posterior interventricular artery) when an element of judgement might be introduced. Branch occlusions that were merely part of an extensive main stem occlusion are not recorded separately, i.e., branch occlusions are ignored unless separated



from the nearest point of occlusion by 1 cm. or more.

Occasionally a very large branch of the left circumflex artery in particular exceeded the dimensions of the anatomical continuation of the main stem. Occlusions in two such branches have been classified as main stem occlusions.

C. Occlusions of 3rd Division<sup>2</sup> arteries, and smaller, are not recorded along with those in larger arteries and in the abstracted data no distinction is made between grades I, II and III. Narrowing had to be to 1/3 original lumen diameter or less to qualify as "occlusion" of these arteries.

D. Arterial occlusions at more than one point.

Many occlusions were of compound appearance, having been formed in several episodes. Where these episodes were represented by several layers at the same point in the artery a single occlusion is described. (This could be the site of several "episodes" of thrombosis or occlusion, as the case may be, in other context). Difficulty arose where occlusion had apparently occurred in more than one incident along the length of the artery. Especially was this so when two such lesions were in contact or overlapped. The decision then as to whether one or more occlusions was to be recorded depended upon the application of the criteria that were adopted. In this chapter two apparent incidents of occlusion have been allowed as separate occlusions only where the two lesions were separated by not less than 1 cm. of lumen of overage calibre, for the artery in question.

Note on 1 mm. lumen diameter. The original lumen diameter of the main stem coronary arteries lay usually between 3 and 5 mm., 4 mm. was adopted as the average normal lumen. 1 mm. lumen diameter therefore corresponds to "marked narrowing", as used by one group of workers in America (Zoll et al., 1951) who define this term as a 75% reduction in lumen diameter. It is uncertain how closely "marked narrowing" corresponds to these measurements when used by other writers.

\* vide infra

"Narrowing" is used in the specific sense already described as "severe narrowing". "Slight narrowing" implies a lumen diameter greater than 2 mm. lumen diameter or half the original lumen diameter, while "moderate narrowing" lies between 1 and 2 mm. lumen diameter. These terms will not however be used as a rule, for the diameter as measured will usually be stated for moderate narrowings. Above 2 mm. lumen diameter the artery is described as "unobstructed", for reasons that will appear in the text.

Measurements of lumen diameter were taken from the arteriograms, mounted 2 mm. thick arterial sections and, where pertinent, from frozen section. Shrinkage at these stages in the processing of the tissues was not more than 10% and sometimes was unappreciable. The majority of lumina were nearly circular. Where this was not so the figure quoted is the estimated diameter of the cross-sectional area had it been circular.

#### Subdivision of Coronary Arteries

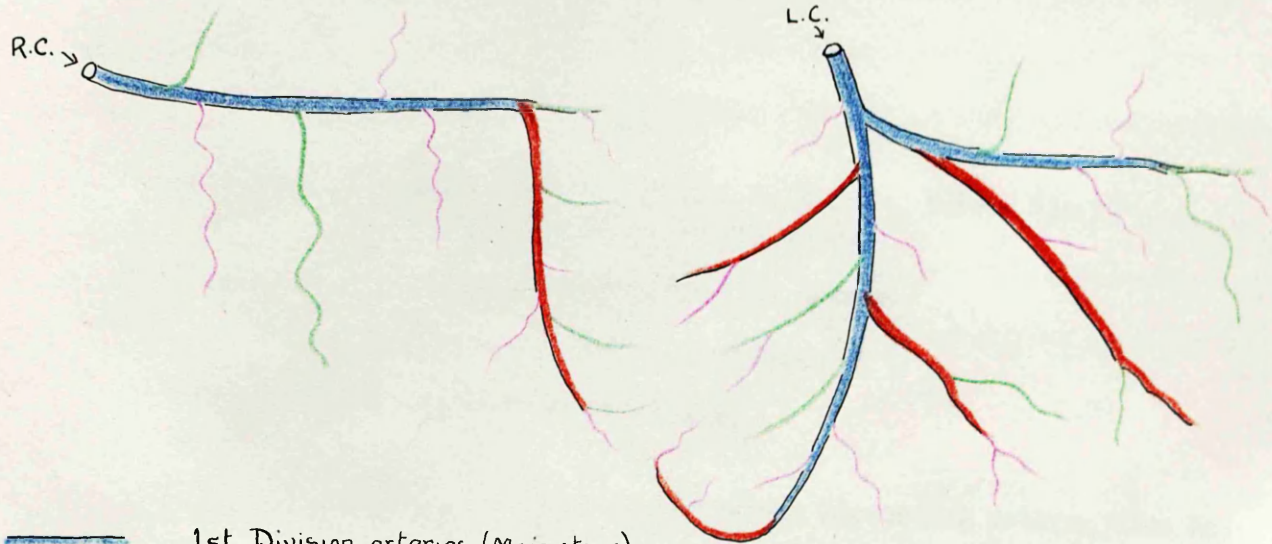
Some anatomical considerations have been discussed in Chapter 3.





For most purposes the coronary circulation has been regarded as having three main arterial stems (Right, Left Circumflex and Anterior Descending arteries). Where occlusion of the Left Coronary main stem itself existed, it has been regarded as equivalent to occlusion of the Anterior Descending and Left Circumflex arteries together. Thus Left Coronary main stem occlusion is entered as occlusion of two arteries.

For certain purposes the Left Coronary artery main stem has been considered separately from its main divisions, the Left Circumflex and Anterior Descending arteries. These together with the Right Coronary artery comprise 4 arteries, and occlusion of each may be separately recorded.

In either event the convention adopted will be clearly indicated.

LIFT UP



-  1st Division arteries (Main stems)
-  2nd " " (Major branches)
-  3rd " "
-  4th " "

SUBDIVISION OF THE  
CORONARY ARTERIES.

1st Division arteries: Anterior descending artery, left circumflex artery and right coronary artery. These are usually referred to as "main stems".

2nd Division arteries: These are main branches of the parent stems and include the posterior interventricular (posterior descending) artery, the right and left marginal arteries and the main septal artery arising from the anterior descending artery, and also other branches with an original calibre of 2 mm. or more and which supplied a considerable territory of myocardium.

3rd Division arteries: These are branches of lesser importance, arising directly from the main stems or from large branches of them, which have calibres  $1/3$  or less than the parent artery.

Because of the great variation in distribution of the coronary arteries the minimum use is made of nomenclature of former days which was based upon an orderly conception of the anatomy of the coronary circulation, shown to be applicable only to a proportion of cases.

#### Abbreviations

LC	=	Left Coronary artery, main stem, before its division into ADA and LCxA.
LCxA	=	Left Coronary Circumflex artery.
ADA	=	Anterior Descending artery.
RC	=	Right Coronary artery.

21 ADA, for example, refers to the Anterior Descending artery, Case 21.

### Myocardial Damage

Except where otherwise specified, "myocardial damage" is used to describe all forms of ischaemic myocardial damage, in which there appears to have been replacement of muscle tissue by fibrous tissue or necrosis. The fine, diffuse, peri-vascular fibrosis that is found in ischaemic hearts as well as in others is not included. Unless otherwise stated, "myocardial damage" in the context of this chapter refers to ischaemic myocardial damage.

Distinction has been drawn between focal damage in which the individual lesions were of the order of 5 mm. or less in diameter (no matter how many such lesions may have existed separately) and massive damage in which the lesions were larger. Infarcts which involved a large area are described as "extensive".

Caution has been found necessary in the use of the term "infarction". Some authors appear to have included under this heading all forms of myocardial damage attributable to ischaemia, while others have implied a distinction between focal lesions and myocardial infarction. In this chapter the term has therefore been qualified by "focal" or "massive" where there could otherwise be dubiety in the meaning, and importance in making the distinction.

Where "episodes of infarction" of different ages involving the same territory were found, it is so expressed in preference to "two infarcts", for example, unless these two infarcts belong to arterial territories supplied by two distinct branches and were not confluent.

In each case myocardial damage could be acute, semi-recent or old.(see below)

Acute and semi-recent focal damage	= "focal necrosis"
Old focal damage	= "focal fibrosis"
Old massive damage	= "massive fibrosis" or "massive fibrotic replacement"

Age grouping of arterial occlusions and myocardial damage

- "Acute" = less than 28 days before death.  
 "Semi-recent" = 1 to 6 months duration.  
 "Old" or "Old-standing" = greater than 6 months duration.

"Recent" is sometimes used, for brevity, to describe lesions of less than 6 months duration, where there is no need to distinguish between acute and semi-recent lesions.

Other terms used

The terms "ipse-regional" and "para-regional" have been coined for the sake of brevity and precision.

"Ipse-regional": The myocardial region or territory anatomically supplied by a particular artery, and the coronary artery anatomically distributed to a particular myocardial region, are mutually referred to as ipse-regional. Thus occlusion of the anterior descending artery, for example, would commonly be followed by infarction of the ipse-regional territory, in this case the antero-septal region of the left ventricle. Depending on the nature of the disturbance of the anatomy of the coronary circulation in disease, damage may also occur in the territories of other arteries. It is then described as "para-regional" infarction. Conversely, myocardial damage in a particular myocardial region may be referred to as resulting from a para-regional arterial occlusion.

NOTE ON THE PRESENTATION OF OBSERVATIONS IN THIS  
CHAPTER

---

The presentation of the collective data which bear upon coronary artery occlusion and ischaemic myocardial damage may be approached from many different standpoints. Where possible, corresponding data referring to arterial and myocardial changes have been grouped together.

For the most part aggregate figures refer to the entire series of 25 hearts. For certain purposes only the last 15 cases have been used for analysis. In the last 15 cases all the relevant data were preserved in the mounted arterial specimens whereas in cases 6 - 10 there were some deficiencies in this respect and in cases 1 - 5 serial mounting of arterial sections had not been introduced.

In order to reduce cumbersomeness of description it was decided, for the most part, to consider main-stem occlusions only. At the end of the chapter a separate section is devoted to 2nd Division branch occlusions and to occlusion of smaller arteries. Two occlusions of arterial branches which were larger of calibre, and supplied a greater area of myocardium, than the continuation of the main-stem, were classed as main-stem occlusions (see Table 5:3).

GENERAL OBSERVATIONS ON CORONARY ARTERY OCCLUSIONS  
AND RELATED MYOCARDIAL DAMAGE

Table 5:2

SITE OF ARTERIAL OCCLUSIONS IN 25 HEARTS (Main stems only)		
	A (I,II)	B (I, II, III)
RC alone	1	1
LCxA "	1	1
ADA "	7	6
RC + ADA	6	3
RC + LCxA	1	1
ADA + LCxA	5	4
RC + ADA + LCxA	$\frac{4}{25}$	$\frac{9}{25}$

- Notes 5:2. (1) Column A records the situation where complete and canalised (once complete) occlusions only are considered (Grades I and II). In column B severe narrowings (Grade III) are also included as occlusions.
- (2) In one case (No.21) the left coronary main stem alone was occluded and is represented in this table as occlusion of ADA and LCxA. LC occlusion in case 1, in addition to occlusions of ADA and LCxA, is not included.

---

It is evident from Table 5:2 that isolated ADA occlusions were not uncommon, nor was severe disease of all three main stems. Further comment on these data would serve little purpose at this juncture.





Table 5:3

INCIDENCE OF ARTERIES (main stem only) INVOLVED IN OCCLUSIONS AND THE INCIDENCE OF IPSE-REGIONAL MYOCARDIAL DAMAGE.			25 Cases
	Occlusions		Arterial territories affected
	A I, II	B I, II, III	
RC	12	14	15
LC (main stem)	2	2	-
LCxA	10	14	14
ADA	<u>21+2</u>	<u>21+2</u>	<u>21</u>
	45+2	51+2	53

Notes 5:3.

- (1) 2 instances of LC (main stem) occlusion are recorded. In one of these (Case 1) there was also occlusion of ADA and LCxA, and entry is made under each heading. In the other (Case 21), ADA and LCxA were unobstructed and entry has accordingly been confined to LC. (It so happens that the totals of 45 and 51 would have been the same had LC been treated as equivalent to ADA and LCxA in each instance). In each case myocardial damage is entered under the territories of ADA and LCxA, there being no arterial territory served by LC on its own.
- (2) 2 instances of muscle damage in the territory of ADA were related to occlusions of major branches of ADA where the main stem itself was unobstructed proximally. These appear as "+2" in the appropriate columns. (Cases 8 and 11)
- (3) No sure explanation was found for focal damage in the territory of RC in 2 cases (16 and 18) and in one (Case 2) no damage at all was found in the territory of an occluded RC artery.

Superficially, these figures would suggest that myocardial damage accompanied coronary artery occlusion in every instance. Such a conclusion however would be unjustifiable on this evidence alone. In order to test this point it would be necessary to compare each instance of occlusion with the presence or absence of ipse-regional myocardial damage of corresponding age, and to record the incidence of correlation. This is a matter which can be pursued with a fair degree of accuracy in the case of recent lesions, but which becomes much more elusive in cases of older standing, in which the situation may be exceedingly complex. Nevertheless attempt was made in this investigation to establish the degree of correlation between arterial and

myocardial changes of all ages, and the data so derived are dealt with in some detail later in this chapter. The general statement of correlation is contained in Table 5:1. Exceptions are indicated in Table 5:3, Note 3 above.

Table 5:4.

INCIDENCE OF CORONARY ARTERY OCCLUSIONS. 25 Cases			
	Main stem (1st Division Arteries)	Major branch (2nd Division Arteries)	Total
Complete at death. (I)	30	6	36
Canalised at death once complete. (II)	17	9	26
Severe narrowings. (III)	9	-	9
	<u>56</u>	<u>15</u>	<u>71</u>

Notes 5:4.

- (1) LC = LCxA + ADA and is therefore recorded as two occlusions Case 21, and not recorded Case 1 (see Note 5:3 (1) ).
- (2) 2 occlusions occurring in the one artery are recorded as 2 occlusions where they were separated by not less than 1 cm. of average lumen for the artery. This accounts for the higher incidence of main stem occlusions here recorded (56) than of arteries involved in occlusion (51, Table 5:3). 2 separate occlusions in the same artery occurred in 5 instances ( Cases 6, 7, 17, 18, 19). 3 of these were Grade III occlusions.

---

For reasons indicated above, it would serve no purpose to relate the findings in Table 5:4 to the incidence of myocardial damage, for the relationship is a much more complicated one. It is however possible to compare these figures with those of other series. In this connection Zoll et al. (1951b) noted 749 occlusions in 275 hearts, or 2.86 occlusions per heart. In my own series 71 occlusions in 25 hearts represents 2.84 occlusions per heart (main stem and major branch). Where only main stem occlusions are considered, 2.24 occlusions per heart were found.

EPISODES OF CORONARY ARTERY OCCLUSION AND  
MYOCARDIAL DAMAGE

To judge from the evidence contained in the arteriogram in the 2 mm. thick mounted sections and in the histological sections, occlusion of a coronary artery was frequently the final outcome of several distinct stages of encroachment on the lumen. The grounds for believing these stages to have been thrombotic in nature are presented in Chapters 7 and 8. Where the penultimate stage of narrowing (before complete occlusion) had reduced the lumen of the artery to 1 mm. or less in diameter, as found at death, this stage also qualifies as an occlusion, according to the criteria I have adopted. In the tables that follow, penultimate narrowing to this degree is therefore referred to as an "episode of occlusion". It is possible that some such narrowings which have been later occluded had themselves been the product of canalisation of an earlier complete occlusion. Such arteries may therefore have been completely occluded twice, but there was no means of knowing this with certainty.

Likewise in myocardial lesions, gross and histological features often suggested damage. The occurrence of massive infarction corresponding to the earlier episode of arterial occlusion might be held to indicate occlusion of very severe degree, probably complete; whereas, in general, the lack of damage other than focal fibrosis could be regarded as in keeping with incomplete occlusion. Retrospective assessment of the completeness or otherwise of arterial occlusions based on such indirect evidence must be made with great reservation, and would not be permissible at all except in conjunction with an assessment of the degree of collateral blood supply available through anastomoses. It was felt that massive myocardial damage provided valid evidence of a positive nature, which probably reflected the relative completeness of the arterial occlusion at the time. Trivial myocardial damage by contrast could not be taken as a reliable index of the relative incompleteness of the arterial occlusion. Thus, in several instances, complete occlusion was

accompanied by focal damage only. Accordingly there was no certain means of determining on grounds of related myocardial damage alone whether an arterial narrowing had been completely occluded at one time, and its lumen again opened up.

When examined in cross-section, episodes of intimal change preceding the final episode of thrombosis were preserved in the artery wall and were distinguished one from another spatially in a manner analogous to the record borne in the rings of a tree. Episodes of myocardial damage were also on occasion clearly defined, but by no means always so. For instance, old-standing fibrotic replacement, especially when focal, could have represented single or multiple episodes of ischaemic damage, for all one could tell in retrospect. For the lesions in the myocardium were intermingled and not spatially distinguishable, as in the artery wall. Conversely, in recent infarcts, diverse appearances could be presented in different portions, depending on the size and patchiness of the lesion, without necessarily implicating damage of different ages.

I have perhaps overstressed the difficulties and pitfalls. In spite of them, a close correlation was found between episodes of coronary artery occlusion and episodes of myocardial infarction in each of the last 15 cases of this series. The collective data on this topic derived from these cases will shortly be introduced. Before doing so, the aggregate incidence of episodes of arterial occlusion and the aggregate incidence of episodes of myocardial damage in the whole series are presented.

Table 5:5

EPISODES OF ARTERIAL OCCLUSION AND EPISODES OF MYOCARDIAL DAMAGE.			
Episodes of occlusion in each artery		Episodes of muscle damage in each arterial territory	
Main stem	66	Massive	53
Major branch	<u>15</u>	Focal	<u>37</u>
	81		<u>90</u>

It has not been intended to suggest from the manner in which these data have been presented that there was any relationship between branch occlusions and focal damage, or between main stem occlusions and massive damage. Branch occlusions showed no evidence of more than one episode of occlusion as a rule, but this point is made with less certainty than is the incidence of previous occlusion in the main stems. It is possible that the size of the arteries was an important conditioning factor.

The excess of episodes of muscle damage (90) over episodes of arterial occlusion (81) is partly the result of episodes of focal damage which occurred without further arterial change at the time (acute coronary insufficiency) and partly the result of damage which followed occlusion of the artery of a different region ("infarction-at-a-distance"). The figure of 90 is the sum of all recognised episodes of myocardial damage in each of the three arterial territories. Their relationship to episodes of occlusion would have been very different had episodes of myocardial damage occurring simultaneously - so far as could be judged - in two or three territories been counted as single episodes. When this was done the figure fell from 90 to 55.

Data derived from the last 15 cases

In Tables 5:6, 5:7 and 5:8 data from the last 15 cases of the series are presented in greater detail. The information so provided has little interest in itself, but is to be taken in conjunction with Table 5:9 and Diagram 5:1 which contain matter of greater importance.

Table 5:6.

INCIDENCE OF OCCLUSIONS FOUND AT DEATH IN 29 CORONARY ARTERIES.				15 Cases
Occlusions:	Main-stem (1st Division arteries)	Branch (2nd Division arteries)	Total	
Grade I	18	3	21	
II	8	3	11	
III	6 <sup>#</sup>	0	6	
	<u>32</u>	<u>6</u>	<u>38</u>	

Note 5:6. # 3 of these severe narrowings were in arteries also the seat of Grade II occlusions.

Table 5:7

EPISODES OF OCCLUSION AND EPISODES OF MYOCARDIAL DAMAGE.								
15 Cases.								
	Episodes of coronary artery occlusion					Myocardial damage		
	Main-stem I and II		III	Branch I,II,III	Total	Episodes of corresponding age in each arterial territory		
						Massive	Focal	Total
Acute	11	-	11	3	14	13	7	20
Semi-recent	4	-	4	2	6	8	3	11
Old	13	10	23+2	1	24	13	12	25
	28	10	38+2	6	44	34	22	56

Notes 5:7.

- (1) In 2 instances a second episode of occlusion was thought to have involved the portion of artery adjacent to established complete occlusion. As it is certain that these second episodes had no important effect upon blood flow, and were in other respects of uncertain identity and importance, they are omitted from the totals in this Table, and also from Table 5:8 and Diagram 5:1.
- (2) There were 6 episodes of incomplete occlusion before final occlusion. 4 of these were classed as Grade III (6+4=10) and 2 as Grade II (26+2=28).

Again, in this Table, the total episodes of myocardial damage (56) over episodes of occlusion (44) may be observed, where each episode in each arterial territory has been recorded. On the other hand, where episodes in regard to time alone were considered the figure for myocardial damage was smaller (Table 5:8).

Table 5:8

EPISODES OF MYOCARDIAL DAMAGE IN REGARD TO TIME ALONE	
15 Cases	
Episodes of muscle damage	33
Episodes of arterial occlusion, I and II only	
Main stem	28
Branch	6
	<u>34</u>

Note 5:8

See Note 5:7 (1).

THE DEGREE OF NARROWING WHICH PRECEDED OCCLUSION

In the foregoing Tables it was seen that in 32 coronary artery main stem occlusions there were 38 episodes of occlusion. That is to say, prior to the terminal event there had already been narrowing of the affected segment of artery to 1 mm. or less lumen diameter in 6 instances. This suggested that it might be a matter of interest to approach the problem from the standpoint of the degree of narrowing which had preceded the final episode of thrombosis in the other occlusive lesions in the series. For this purpose certain data in the last 15 cases of the series have been analysed in detail and are set out below in Table 5:9 and in Diagram 5:1.

Table 5:9

DEGREE OF NARROWING BEFORE OCCLUSION				
15 Cases.	32 main stem occlusions and 6 branch occlusions			
			<u>Main</u>	<u>Branch</u>
1	Narrowing of the original lumen	4-2 mm. ( $1-\frac{1}{2}$ diam.)	14	4
2	" " " " " "	2-1 mm. ( $\frac{1}{2}$ - $1/3$ " )	12	2
3	" " " " " "	1 mm. or less ( $1/3$ or less)	6	-
			<u>32</u>	<u>6</u>

Note 5:9 The measurements in mm. are used for main stems where the original lumen diameter was of the order of 3 to 4 mm. or more. Where the lumen diameter was originally less than 3 mm. then the fraction is employed.

Estimation of the maximum narrowing prior to occlusion by thrombosis is not an easy matter. An arteriogram of an injected artery may clearly indicate the degree of narrowing proximal and distal to an area of occlusion but can give no information about the segment which is blocked by thrombus, except under certain circumstances. The information is only obtainable on serial sectioning of the affected segment. As already described (see Technique, page 1:38) the excised artery was sectioned at approximately 2 mm. intervals and the sections were mounted serially. Examined by direct and transmitted light the channel blocked by thrombus could be closely inspected, and measurements made of its diameter at various levels throughout its length.



Prior to sectioning and mounting, the tissue was fixed in 5% formal saline and so far as could be judged from comparison of the injected portions of the arterial lumen in the sections and on the radiographs (taken before fixation), the degree of shrinkage was so slight as to be negligible. (This is in contrast to the very considerable shrinkage encountered in paraffin sections of arteries). If it may be allowed that there was likewise no important shrinkage of the tissues in the area blocked by thrombus then the method permitted an estimate to be made of the maximum degree to which the lumen was narrowed before final occlusion. This estimate was probably reliable in the case of recent occlusions. In old occlusions the borderline between previous thrombus and underlying intimal tissue was less clearly defined. Examined in this way it was found that the point of maximum narrowing was variably placed in the length of the occlusion and might extend for a distance of only 1 or 2 mm. in some cases. It was accordingly evident that random sections through an occluded segment of artery, which might be several centimeters in extent, might well fail to reveal the point of maximum narrowing. Illustrations of arteriograms and corresponding sections of selected instances of coronary occlusions appear in Chapter 7. In this context particular reference is made to 20 ADA.

It may have come as a surprise that in as many - or as few according to one's pre-conceived notions - as 6 occlusions out of 32 there had been previous narrowing of the arterial lumen to 1 mm. or less in diameter. The question is immediately raised, what was the functional significance of narrowing of this order, and for that matter of narrowing of lesser or greater degree? At what point did encroachment on the arterial lumen appear to have reduced its capacity for blood flow to a level at which myocardial damage occurred? The evidence presented in Tables 5:9 and 5:10 and Diagram 5:1 bear upon these problems.

With each of 29<sup>±</sup> occlusions the maximum degree of antecedent narrowing and the muscle damage corresponding to it were recorded. The age and nature of the most recent episode of occlusion was also noted, together with the myocardial damage which in turn had resulted from it. It will be appreciated that the information was the more precise where the changes under examination were recent, and also that an estimate of the degree of antecedent narrowing, based on these post-mortem observations, could not be safely assumed to represent the state of affairs at its inception. In many cases, narrowings (of greater severity, at any rate) were apparently the end-product of episodes of thrombosis and it is likely that in some a greater degree of encroachment on the lumen existed at one time than was found at death. Indeed complete occlusion may have occurred with subsequent restoration of continuity of the lumen (see Canalisation, Chapter 7). It will further be appreciated that integrity of the myocardium implied adequacy of its blood supply during life but did not necessarily indicate the measure of blood flow that was carried by the artery in question. (For collateral supply may have made very considerable contribution). By contrast, the development of ischaemic damage following the withdrawal of blood supply occasioned by occlusion of a narrowed artery could, with more justification, be taken not only as an index that the myocardium had depended upon that artery for its blood supply but also as some measure of that dependence.

The evidence presented in Diagram 5:1 will be considered in regard firstly to the adequacy or inadequacy for blood supply to the myocardium of the three categories of coronary artery narrowing, and secondly to the effects of obliteration of these channels.

- ± 3 arteries showed occlusion at two separate points. Only the occlusions of greater severity in each instance have been considered for this purpose (32 - 3 = 29).

TABLE 5:10

DEGREE OF NARROWING PRECEDING THE FINAL EPISODE OF OCCLUSION ; AND RELATED MUSCLE DAMAGE.

15 CASES, 32 OCCLUSIONS (Main stems only)

DEGREE OF NARROWING BEFORE FINAL OCCLUSION.	OCCLUSIONS			MUSCLE DAMAGE related to previous narrowing				FURTHER MUSCLE DAMAGE caused by final occlusion.			
	I and II		III	NONE or not known	FOCAL only	MASSIVE		NONE or not known	FOCAL only	MASSIVE	
	<1 month	1-6 months				OLD	<1/3			>1/3	<1/3
2 mm. diam. and greater ( > 1/2 )			25R		25R					25R	
			25L	22L	22L				22L	25L	
			23A	19R	19R				19R	23A	
			22A	19L	19L				19L		22A
			19A	17R	17R				17R		
			17L		19A				19A		
			12R	17L	17L				17L		12R
			12A	13L	12R						12A
			12A		13L			13L			
		14L		12A	12A					14L	
2-1 mm. diam. ( 1/2 - 1/3 )			24R		24R						24R
	22A					22A					22R
			19R		19R				19R		
		16A	18A		18A		16A				18A
			18A		18A					18A	
			17R		17R				17R		
	13A	15A	17A		13A		15A				13A
			17A		17A				17A		15A
				12L						12L	
	11L					11L			11L		
1 mm. diam. and less ( < 1/3 )	24A				24A						24A
	21LC					21LC					21LC
	20A				20A						20A
	14A				14A						14A
	11R					11R		11R			
	11A					11A				11A	

A = ADA L = LCxA R = RC LC = LC main stem.

32 occlusions involving 29 arteries. The lesser occlusion in each of the 3 instances, where two occlusions occurred in the same artery, is enclosed  $\square$ . These are omitted in Diag 5:1

N.B. ① Absence of myocardial damage following complete occlusion of 11 LCxA probably reflected the adequacy of anastomotic enlargement. 11 RC on the other hand was anatomically a small artery and the original occlusion was canalised by narrow channels. Their terminal obliteration by thrombus was unattended by further damage to the myocardium. In the case of 22 LCxA and 13 LCxA the occlusions were of Grade III, and may never have been complete.

② Death occurred within 1 hr of occlusion of 12 LCxA. The extent of infarction was assumed to be great, for this artery had been carrying a major part of the blood supply to the heart following previous ADA and RC occlusion.

**DIAG. 5:1** MYOCARDIAL DAMAGE RELATED TO FINAL EPISODE OF CORONARY ARTERY OCCLUSION AND TO PREVIOUS NARROWING.  
 29 occlusions, main stems only. 15 cases

DEGREE of NARROWING of C. Art. before final occlusion	A MUSCLE DAMAGE related to PREVIOUS NARROWING.				B ADDITIONAL MUSCLE DAMAGE related to FINAL EPISODE.			
	NONE or not known	FOCAL only	MASSIVE <math>< \frac{1}{3}</math> <math>> \frac{1}{3}</math>		NONE or not known	FOCAL only	MASSIVE <math>< \frac{1}{3}</math> <math>> \frac{1}{3}</math>	
2 mm. diam. or more (> 1/2)	■ ● ● ● ● ● ● ○ ○ ○ ○				○ ○	● ○ ○	■ ● ● ●	● ● ●
2-1 mm. diam. (1/2 - 1/3)	◆ ◆ ● ● ● ● ●	◆ ◆ ■ ■			◇	● ● ●		◇ ◆ ◆ ◆ ■ ■ ●
1 mm. diam. or less (< 1/3)		◆ ◆ ◆	◆ ◆ ◆		◆			◆ ◆ ◆ ◆ ◆

Reference to the age of the final episode of occlusion

- ◆ = Acute (Death within 28 days)
- = Semi-recent (1-6 months)
- = old (older than 6 months)
- = narrowing (Grade III occlusion)

◇ one case (No 12) in which massive infarction was presumed, but in which death occurred within 1 hour of onset of terminal episode.

The size of massive infarction (> 1/3, < 1/3) refers to an estimate of the fraction of the mass of muscle in the anatomical distribution of the occluded artery in question.

3 Grade III occlusions have been omitted because there was also old-standing Grade II occlusion of the same artery. This diagram therefore features 29 not 32 occlusions.

(1) In 12 instances occlusion took place in an artery that was previously narrowed only to a modest degree (i.e., not less than 2 mm. in diameter). In not a single instance was there evidence that narrowing to this degree had caused myocardial damage. From this evidence the important conclusion was reached that main stem coronary arteries in which the lumen diameter was at no point less than 2 mm. could be regarded as "unobstructed". This assumption has been adopted when considering other data in this chapter. Indeed 2 mm. diameter is probably a generous allowance for this purpose. The concept is given further support from the absence of myocardial damage in the territories of arteries still unobstructed at death.

In the second horizontal column in Figure 5:1 it can be seen that the degree of antecedent narrowing in 11 instances of occlusion lay between 1 and 2 mm. lumen diameter. Of these 7 were unassociated with myocardial damage, 3 were the presumptive cause of focal damage and only one of massive myocardial infarction. When in the next column the group of 6 instances of antecedent narrowing to 1 mm. or less lumen diameter, we find that myocardial damage had occurred on each occasion, equally divided between focal damage and massive infarction.

From these findings it may be cautiously inferred that the adequacy of coronary arteries in terms of blood flow became critical at a lumen diameter of 1 mm. approximately. Below this level myocardial damage was usual, above 2 mm. lumen diameter blood flow was sufficient and myocardial damage absent. Further evidence on this point was afforded by the incidence of muscle damage related to Grade III occlusions (severe narrowings) in column 3, Diagram 5:1.

It is scarcely necessary to point out that the lumen diameter at the point of maximum obstruction in a coronary artery is only one factor in determining the degree of impairment or adequacy of blood flow, albeit an important one. The length of the occlusion, its site in the artery, the size of the myocardial territory supplied distal to the point of occlusion, the volume of collateral

blood flow through anastomoses, as well as factors more intimately concerned with the metabolic requirements of the myocardium, have all a bearing upon this problem. The absence of muscle damage in relation to particular degrees of narrowing is evidence of a negative nature. The degree of muscle damage which followed obliteration of a narrowed lumen by fresh thrombosis, on the other hand, provided positive evidence which will now be considered.

(2) Of the 12 occlusions in which the arterial lumen had been 2 mm. or more before the most recent episode of narrowing, 4 were classed as severe narrowings. Focal myocardial damage was found in the territories of 2 of these and no damage in the remaining 2. The absence of massive infarction would seem to confirm the correctness of the classification of these lesions. Whereas the complete occlusion of the remaining 8 arteries which had been previously "unobstructed" was attended by massive myocardial infarction in 7 and focal damage in 1. Likewise myocardial damage followed 9 out of 11 instances of complete occlusion where antecedent narrowing had reduced the lumen to 1-2 mm. diameter. Of the other 2, 1 would almost certainly have caused recognisable massive myocardial infarction had death not occurred within about 1 hour of the onset of the fatal attack; in the other, focal damage had already occurred with the former episode and anastomotic enlargement was considerable, linking the occluded main stem (LCxA, Case 11) with a branch which was of main stem proportions.

When we turn to the last group, where antecedent narrowing had reduced the lumen to 1 mm. or less before terminal occlusion, we find that complete obliteration of this narrow lumen was followed in 5 out of 6 cases by massive myocardial infarction. In the sixth case no damage was found in relation to second occlusion of an anatomically small right coronary artery, in which earlier thrombotic occlusion had been canalised by a few narrow and tortuous tracks. Lack of further myocardial damage in these circumstances calls for



little remark. A matter of far greater surprise to me was the extensive nature of the damage which followed the withdrawal of that measure of blood supply which had been carried by the narrow tracks present in the other 5 cases. Indeed in one case infarction occupied nearly the entire muscle territory of the affected artery and death resulted from cardiac rupture. Before making these observations, I had not imagined that the moiety of flow volume which could pass through an obstruction of this order would have had such importance. It is evident that this concept was wrong.

These last findings have major significance; and they introduce a topic which will be dealt with further when discussing the importance of collateral blood supply (see Chapter 6, page 6 et seq. and Chapter 7). At this juncture the point is made that the occurrence of massive myocardial damage following withdrawal of blood supply through these narrow channels did not necessarily mean that all or even the major blood supply to the affected region was latterly carried by them. Theoretically it may only have meant that withdrawal of the contribution made by them reduced the total supply to the affected territory below a level critical for the survival of the myocardial tissue. The contribution made by collateral channels may indeed have been the greater.

The marginal requirements of the myocardium for its survival appear to be met by a surprisingly small volume of blood flow. In the dog heart doing no cardiac work, Gregg holds that about 5 ml./min. is probably sufficient to maintain viability indefinitely for a 51 gm. heart. In so far as this opinion is applicable to a muscle mass of say 100 gm. of human left ventricle, 10 ml./min. would be required to pass through - or by-pass - the obstruction, i.e., about  $1/6$  or  $1/8$  of the normal rate of inflow. E.C.G. changes are reported in the beating heart when the coronary blood flow is reduced by approximately 70% of normal (Wegria et al., 1949). According to experiments by Shipley and Gregg (1944) percentage decrease in flow of this order in the



carotid artery of the dog is achieved by reduction in lumen area of that artery of about 90% or more. There does not seem to be reliable data of this order for the coronary arteries. It would seem however that reduction of the lumen diameter of a major coronary artery to 1 mm. or less (approximately 90%-95% reduction in lumen area) may well reduce coronary inflow in the region of these experimental findings.

Before leaving the subject of narrowings of 1 mm. lumen diameter it may be of interest to summarise the relationship of these lesions to myocardial damage in the corresponding territories, and this is done in Table 5:11, which refers again to the full series of 25 cases. Only the maximum degree of occlusion for each artery is noted in Tables 5:11, 5:12a and 5:12b below. (i.e., one entry for each obstructed artery, not for each occlusion). Only ipse-regional myocardial damage features in these Tables.

Table 5:11

IPSE-REGIONAL MYOCARDIAL DAMAGE RELATED TO MAIN STEM SEVERE NARROWINGS (Grade III) ONLY.		25 Cases.
Massive myocardial damage		0
Focal myocardial damage		4
No myocardial damage		2
		6

Note 5:11 In addition, 3 Grade III occlusions occurred in arteries more severely obstructed by other lesions. From this Table it can be seen that in 6 instances of main stem narrowing of severe degree but without evidence, at the site of the lesion or elsewhere, of complete occlusion at any time, 2 had caused no myocardial damage and the other 4 had caused focal damage only. These findings are in contrast to the damage found in association with canalised occlusions (once complete) and occlusions still complete at death (Tables 5:12a and b).

Table 5:12a

MYOCARDIAL DAMAGE RELATED TO MAIN STEM CANALISED OCCLUSIONS (II).		25 Cases.
Massive myocardial damage		10
Focal myocardial damage only		5
No myocardial damage		<u>0</u>
		15

Table 5:12b

MYOCARDIAL DAMAGE RELATED TO MAIN STEM COMPLETE OCCLUSIONS (I).		25 Cases.
Massive myocardial damage		26 + 1 <sup>⊗</sup>
Focal myocardial damage only		2
No myocardial damage		<u>1<sup>⊘</sup></u>
		29 + 1

Notes 5:12b

- (1) <sup>⊗</sup> In one case death occurred within 1 hour of the onset of the fatal attack in which recent coronary artery thrombosis had occurred. Massive myocardial damage seemed inevitable but death occurred before changes were manifest (Case 12).
- (2) <sup>⊘</sup> Occlusion of anatomically small RC artery, which supplied only part of R.V. (Case 2).
-

Table 5:13  
(over)

The table content is illegible due to the low contrast and high noise of the scan. Only some faint text is visible in the bottom-left corner of the table area, which appears to be a header or a note.

TABLE 13. DISTRIBUTION OF ARTERIAL LESIONS (main stems only) and RELATED MYOCARDIAL DAMAGE (25 Cases)

	ARTERIAL SITUATION FOUND AT DEATH. 25 Cases.	MYOCARDIAL DAMAGE in territory of occluded artery(s)			ARTERIAL SITUATIONS which were probably present earlier and which caused myo-cardial damage.
		NONE	FOCAL only	1 - 2 3 - 3 Nearly TOTAL	
A	1 ARTERY OCCLUDED. Others strictly normal				
B	1 ARTERY OCCLUDED Others "unobstructed."	3, 4, 5, 16, 20	3	15, 14, 14	
C	1 ARTERY OCCLUDED 1 other narrowed 2-1 mm.	9, 18, 23	23	18, 9	6, 7, 14, 11, 22, 24
D	1 ARTERY OCCLUDED. 1 other also occluded.	2, 7, 13, 14, 23, 24, 25	25	13, 23, 24, 21, 7, 14	
E	1 ARTERY OCCLUDED. 2 others occluded	4, 5, 11, 12	12	4, 5, 11	19, 17, 17?
F	2 ARTERIES OCCLUDED "SIMULTANEOUSLY."	1, 21	1	21	11, 12
G	OLD OCCLUSION OF 2 OR 3 ARTERIES. Time relations uncertain. No recent arterial change.	6, 8, 10, 17, 19	6, 7, 8, 9	10	
H	NO ARTERIAL OBSTRUCTION	—			

◇ acute lesions (< 28 days)    □ semi-recent lesions (1-6 months)    ○ old-standing lesions (> 6 months)  
 Numbers enclosed refer to case numbers. Myocardial damage refers to the mass of muscle in the territory distal to the occlusion in question - not to the total ventricle or territory - and does not take into consideration damage in other arterial territories (NB. Case 1. Occlusion of LC, ADA, LCA. Case 21. occlusion of LC = ADA + LCA.)

FURTHER DETAILS IN THE RELATIONSHIP OF CORONARY  
ARTERY OCCLUSION AND ISCHAEMIC MYOCARDIAL DAMAGE

- (1) The distribution of coronary artery occlusions in relation to myocardial infarction.

Experimental observations have indicated beyond doubt that regional myocardial damage can follow the ligation of a major artery in a coronary circulation which was previously normal. Similar conditions can be operative in human disease in the case of embolism of a coronary artery; but this is an infrequent cause of myocardial infarction in contrast to thrombosis on a basis of atherosclerotic coronary disease. In atherosclerosis of the coronary arteries it is common for the disease process to be widespread and for more than one artery to be severely involved. In different cases the obstructive lesions may vary greatly in their anatomical distribution, number, completeness, speed of development and in their time relationship to one another. In this way the pattern of coronary artery disease which underlies myocardial damage may present a variety of configurations. If we regard the three main stem coronary arteries as being variously unobstructed, narrowed or obliterated, we can, in theory, draw up a list of many possible combinations of circumstances which might be found in the coronary tree at the time of death. It would then be of interest to know under which of these, and with what frequency, myocardial damage actually occurs.

For this purpose the 25 cases which composed the present series, in which these details were available, were divided into 8 arbitrarily selected categories according to the distribution of obstructive lesions of the coronary arteries. In Table 5:13 is indicated the occurrence and severity of myocardial damage found in each category. In regard to the severity of myocardial infarction, an approximate estimate was made of the proportion of damaged muscle to the total mass of heart muscle anatomically supplied by the artery in question, distal to the point of occlusion. Where more than one area of myocardial infarction existed only the area of greatest or most recent massive infarction was considered.

The distribution of obstructive lesions of the coronary arteries records the state of affairs existing at the time of death. In the case of acute and semi-recent arterial lesions, this probably reflected closely the situation at the time of myocardial damage. In the case of old-standing lesions, on the other hand, the relationship of myocardial infarction to coronary artery occlusion, and the relationship in time and importance of several occlusions to one another, are matters which became increasingly speculative with the age of the pathological changes.

For example, in a given case it could be determined with assurance that an acute or semi-recent arterial occlusion had taken place in the presence of obviously longer-standing occlusion of another artery. By contrast, where two occlusions were each of old-standing their time relationship to one another had to remain in doubt. In the latter circumstances it was not always possible to state with certainty whether myocardial infarction had followed occlusion of the ipse-regional artery at a time when the other arteries were unobstructed, or at a time when there was already occlusion of another; or indeed whether the proximate cause of myocardial infarction in the territory of an occluded artery was the withdrawal of collateral blood supply, following occlusion of a para-regional artery ("infarction-at-a-distance").

When we consider the incidence of isolated occlusion of a single coronary artery, it is evident therefore that in the case of acute and semi-recent lesions the statement of incidence has been based on reliable evidence. It is, moreover, a minimum figure for the series; for there can be little doubt that episodes of myocardial damage on a basis of isolated occlusion of a single coronary artery had been of common occurrence earlier in the course of the disease in cases which presented a much more complex picture by the time of death. On reconstruction of 18 cases in which 2 or 3 coronary arteries were occluded by the time of death, it seemed likely from the evidence available that myocardial damage had resulted from occlusion of a single artery, earlier in the course of the disease, at a time when narrowing of one other artery to between 1 and 2 mm.

lumen diameter had been the only other obstructive lesion in the coronary tree. This appeared to have been the case in 5 out of 18 cases. Again this is presumably a minimum figure.

The occurrence of myocardial infarction as the result of isolated occlusion of a single coronary artery is a matter of some interest in human disease. Accordingly the information in the present series is summarised in Table 5:14, which is partly abstracted from the information embodied in Table 5:13.

Table 5:14

MYOCARDIAL INFARCTION AND ISOLATED OCCLUSION OF A SINGLE CORONARY ARTERY.	
25 Cases.	
	Cases showing related myocardial infarction
A. One artery occluded, others "unobstructed" (lumen diameter 2 mm. or more) at death	4
B. One artery obstructed, one other narrowed 1-2 mm. lumen diameter at death	3
C. Probable occurrence of 'B' at an earlier stage	5

The interest occasioned by myocardial infarction resulting from occlusion of single coronary artery is somewhat surprising; for it is an occurrence that one would have thought, on a priori grounds, to be not uncommon. Saphir, however, is widely quoted for the concept that for myocardial infarction to occur there must be obstruction of at least 2 branches of the coronary arteries (Saphir, 1935)\*. His actual words were:

"One of the most striking findings in this series of hearts was the fact that whenever a myocardial infarct was encountered, at least two branches of the coronary arteries supplying the infarcted area were involved. In this consecutive series of cases no instance was found in which myocardial infarction occurred with only one main artery involved. The involved branches were either completely occluded by calcified plaques or thrombi, or extremely narrowed by calcified plaques. Where extreme narrowing only was present, at least three main branches were involved."

\* Saphir et al., 1935.

It is clear that this point of view has not been substantiated by the evidence derived from the present series. The question may of course be raised, to what extent were the other arteries in the 4 out of 25 cases properly described as "unobstructed"? The evidence has already been presented upon which the opinion that 2 mm. lumen diameter of a coronary artery main stem provides a measure of blood flow sufficient to maintain the integrity of the myocardium (see page 5:23 ). In any case, in 2 out of the 4 cases, the arteriograms of the injected arteries were practically normal apart from the affected arteries, and atherosclerotic changes were minimal and obviously of no great importance for blood flow (see Cases 3, 15, 16 and 20). Schlesinger (1938) states that "infarction may occur in a heart with very little atherosclerosis and with only one major vessel occluded". He was reporting one such case in a series of 56 injected hearts which included cases of coronary artery disease, and 6 showed myocardial infarction.

(2) Coronary artery occlusion without myocardial infarction.

There is often a pronounced disparity between the degree of obliterative coronary artery disease and the extent of myocardial damage related to it - a point which is widely accepted by workers in this field.

It is also sometimes stated that coronary occlusion may on the one hand take place without corresponding myocardial damage, and on the other that myocardial infarction can occur without coronary artery occlusion. These are matters about which there is less general agreement and I should now like to consider them in the light of the evidence of the present series.



Table 5:15

THE SEVERITY OF MYOCARDIAL DAMAGE OF CORRESPONDING AGE IN RELATION TO THE AGE OF ARTERIAL OCCLUSIONS AS FOUND AT DEATH. (IPSE-REGIONAL TERRITORIES AND MAIN STEMS ONLY)				
25 Cases				
Arteries the seat of occlusions		Myocardial damage		
		None	Focal only	Massive
I and II				
Acute	15	1 <sup>7</sup>	1 <sup>8</sup>	13
Semi-recent	6	0	0	6
Old	24	1 <sup>9</sup>	7	16
III	6	2	4	0
	51	4	12	36

## Notes 5:15

- (1) Where an artery was the seat of occlusion at more than one place, only the more severe of the two lesions is recorded in this Table. There is thus one entry for each occluded main stem artery, of which there were 51.  
cf. total main stem occlusions 56 (Table 5:4).
- (2) <sup>8</sup> Focal damage was all that was found in the territory of this artery (LCxA, Case 12). Death occurred within 1 hour of the onset of the fatal attack and it is likely that a greater degree of myocardial damage would have become manifest had death been delayed.
- (3) <sup>9</sup> Occlusion of an anatomically small RC which supplied the right ventricle only (Case 2).
- (4) <sup>7</sup> Acute occlusion without acute ipse-regional myocardial damage of corresponding age in an artery which was not previously occluded according to the criteria adopted. (i.e., previous narrowing was greater than 1 mm. in diameter (1 x 1.5 mm.) as measured at death. On the other hand, there was old ipse-regional focal ischaemic damage and it is likely that narrowing had at one time been more severe (Case 11). The main branch of this artery was rather larger than the continuation of the main stem. It was unobstructed and collateral circulation through enlarged anastomoses was extensive.
- (5) RC in one case had been occluded and re-canalised by very narrow tracks. In the terminal illness there was again complete occlusion by thrombus. The first occlusion was accompanied by massive infarction and this lesion is classed as "old", and the terminal thrombosis which was unattended by further damage has been ignored (Case 11).

Several points arise from Table 5:15. Firstly, from the practical point of view, every instance of complete occlusion of a main stem coronary artery with 3 exceptions, was accompanied by ischaemic myocardial damage. This was the case no matter whether the occlusion was still complete or had been canalised

by the time of death. The exceptions were as follows:

- (1) 12 LCA. Occlusion had occurred so soon after death that there had been insufficient time for the development of reliable evidence of massive myocardial damage. Otherwise in the circumstances massive infarction seemed inevitable.  
5:15, Note 2.
- (2) 2 RC. Old-standing occlusion of an anatomically small artery which was responsible only for the supply of part of the right ventricle - which is generally acknowledged to be less vulnerable than the left ventricle to the effects of ischaemia. It took no part in the supply of the left ventricle.  
5:15, Note 3.
- (3) 11 LCA. Acute occlusion in the presence of old-standing, widespread, obliterative coronary artery disease with previous and present episodes of para-regional massive infarction and ipse-regional focal damage.  
5:15, Note 4.

The first of these exceptions may be discounted in this context. In regard to the second, it may be noted that the more important left ventricle was outwith the territory which could have been involved. In regard to the third, which concerned the left ventricle, there had previously been ipse-regional damage, but none of duration corresponding to the acute occlusion. These last two instances are thus the only absolute support given in this series to the contention (Blumgart et al., 1941; Zoll et al., 1952) that complete coronary occlusion may exist without myocardial infarction.

In 7 instances of old-standing occlusion, in my series, ischaemic myocardial damage was focal only. It is not clear whether focal damage was included under "myocardial infarction" in the paper by Blumgart et al. (1941); but in Zoll et al. (1952) it is stated that "abnormal anastomoses ..... can reduce or even prevent entirely ..... the pathologic evidence of myocardial necrosis after coronary artery occlusion." The underlining is mine.

The position in regard to related myocardial damage was different when arteries which were the seat of severe narrowing only (1 mm. or less in diameter at death and where there was no evidence to show that occlusion had ever been complete) were considered. In 2 out of 6 instances of arterial obstruction of

this nature there was no evident myocardial damage in the corresponding territories and the damage was focal only in the remaining 4.

Very careful assessment of each lesion was required in the derivation of data of the kind included in Table 5:15. Fallacies could have arisen from terminology or from observations less meticulous or complete. Thus in Case 11, a right coronary artery was occluded by recent thrombus and there was no corresponding acute damage in the territory distal to it. But this thrombus was seen to be but a terminal secondary formation which had blocked the narrow tortuous tracks formed in the process of canalisation of a previous complete thrombotic occlusion. The earlier occlusion had caused myocardial infarction. Accordingly, in Table 5:15 this occlusion is recorded as canalised, once complete (Grade II) associated with massive myocardial damage (see Table 5:15, Note 5). In 2 other cases there was thrombosis as a secondary event at some time after complete occlusion of old-standing in a nearby stretch of artery. The earlier complete occlusions had caused myocardial infarction. The obliteration of a further stretch of the lumen by thrombus in an artery still completely occluded had not caused further myocardial damage. This can hardly be held to be surprising. In these instances, the recent thrombosis without recent myocardial damage was ignored for the purposes of Table 5:15 and the arteries were graded as "old complete occlusions" with massive myocardial damage. Random sections happening to pass only through the recent thrombus could have given a false impression of the age of the occlusions.

(3) The extent of old v. recent myocardial damage.

There was an interesting discrepancy between the degrees of damage which followed acute and old occlusions. If Case 12 is excluded, for reasons already given, with but one exception (LCx main stem, Case 11) massive myocardial damage was found in the territories of main stem arteries blocked by acute occlusion. Whereas, in the territories of arteries the seat of old-standing, complete, or canalised-previously-complete, occlusions, 7 out of 25 cases showed focal fibrosis

only in relation to the occlusions. In a small series this difference might be partly due to chance, but I think it may well have other explanation.

In the case of acute occlusions, in every instance the related myocardial injury had been sufficiently severe to form the direct or contributory cause of death. It is therefore not surprising that the myocardial lesions themselves should have been of greater rather than of lesser dimensions. By contrast, old-standing myocardial damage and the occlusions which caused it were lesions which had been survived. In some cases survival may have depended largely upon the measure of immediately available collateral blood supply, which had greatly limited the extent of myocardial damage. It may, however, be pointed out that this cannot have been the only factor; for old-standing myocardial damage was, in the majority of instances, quite extensive.

It will be recalled that non-fatal infarction was classed as "old" if death had been delayed for more than 6 months. In these cases death was due to further ischaemic injury in most instances but in some to intercurrent causes. In the case of the 6 semi-recent lesions, death had occurred between 1 and 6 months (Table 5:15). Death was due to the ischaemic lesion in question in 3, to a further episode of occlusion involving another artery in 2, and to acute coronary insufficiency in 1.

It may be postulated that where the evolution of coronary artery disease is slow, with partial occlusion of arteries for a long period of time before eventual obliteration of the lumen, the development of increased collateral blood flow will be encouraged and the heart the better prepared to withstand the insult of sudden complete withdrawal of blood flow through one artery; and that thereafter the continued slow progress of the disease will allow further time for adjustments to be made before the heart is called on to withstand second and subsequent coronary artery occlusions. In these circumstances there will be a tendency for some instances of myocardial injury to be focal only in extent, and there will be an enhanced tendency to survive coronary artery occlusion.

In the case of acute occlusions, in every instance the relative  
injury had been sufficiently severe to form the direct or contributory  
cause of death. It is therefore not surprising that the myocardial lesion  
should have been of lesser dimensions. The fact that the occlusions  
did not cause infarction is due to the fact that the occlusions were  
of a temporary nature and were not of sufficient duration to cause  
myocardial necrosis. In some cases survival may have been due to  
myocardial collateral circulation which supplied the area which  
was occluded. It may, however, be noted that the extent of myocardial  
injury for old-standing myocardial infarction has been found to be  
in the majority of instances, associated with extensive

It will be noted that the infarction was not of the  
type which is usually seen in these cases but that it was  
of a type which is usually seen in cases of infarction but in some  
of the instances of infarction of the type which is usually seen  
in the majority of instances of infarction. (This is not a  
conclusion.)

Bean, 1938

300 myocardial infarcts,  
20% associated with arterial narrowing  
but no thrombus.  
No significant damage in the coronary  
arteries in 4 hearts.

Yater et al. 1948

114 hearts with gross myocardial infarcts:  
8 showed no complete occlusion of any  
artery.

Karsner, 1949.

Myocardial infarction without organic  
occlusion of the coronary arteries, not  
encountered.

(cited Gould, 1953)

The majority of focal lesions directly related to coronary artery occlusions will accordingly be of old-standing. I imagine that in a larger series, cases would be found in which recent occlusion had caused focal damage only; and I should expect this to occur only in a background of long-standing coronary artery disease. Apart from 12 LCxA (Table 5:15, Note 2) in this series isolated acute focal myocardial damage was found in only two circumstances:-

(1) in acute coronary insufficiency in the presence of widespread, advanced, chronic obliterative disease of the coronary arteries where there had been no recent thrombosis; and (2) in the territory of a previously obstructed artery, when it was provoked by the occlusion of para-regional coronary artery, presumably through the withdrawal of collateral blood supply.

(4) Ischaemic myocardial damage in the absence of coronary artery occlusion.

The occurrence of ischaemic myocardial damage in the absence of coronary artery occlusion is easily stated for the 25 cases of coronary artery disease - there was no instance. There were however a few instances of old-standing focal fibrosis, presumably ischaemic in origin, in the territories of arteries which were not themselves occluded according to the definitions used in this presentation. This occurred in at least 3 cases, in each of which there was occlusion of at least one other artery. In one case (Case 14) the minimum lumen diameter of the main stem supplying the territory in question was 2.5 mm. and the area in which the focal fibrosis lay seemed to correspond to occlusion of a tertiary branch. In another (Case 16) a mural atherosclerotic lesion had caused only trivial encroachment on the lumen. Its origins however appeared to have been from thrombus and it is possible that at the time of its formation a portion had become detached and led to embolism of a small branch. This explanation is speculative. In the third case (Case 18) atherosclerosis of RC and LCxA was severe and, at least in part, had evidently had its origin in thrombus. Ischaemic damage could have occurred through greater encroachment on the lumen at an earlier stage, or from the detachment of thrombus. At death, narrowing 1 x 2 mm.

was present in LCxA and there was also severe narrowing of the posterior branch of RC. Indeed, at the time of its inception, it may have been this latter lesion which caused the focal damage in the RC territory.

It has already been remarked that in 4 cases with advanced, obliterative, coronary artery disease, acute focal myocardial damage occurred as the result of acute coronary insufficiency without any acute change in the lumen of the arteries; but that is another matter. In a somewhat similar case, widespread extension of previous myocardial damage developed during diabetic ketosis on a basis of widespread severe obliterative coronary artery disease (see Cases 6, 8, 17, 19 and 11).

On the other hand myocardial infarction was found in 2 cases of rheumatic valvular disease in which there was no obvious lesion of the coronary arteries. Myocardial infarction in these cases was thought to have been due to embolism, with subsequent almost complete restoration of the arterial lumen. For details of the evidence upon which this opinion is based see Cases D2 and 3.

(5) The proximate cause of regional myocardial damage, including "infarction-at-a-distance".

The immediate cause of regional myocardial infarction is commonly recognised to be acute occlusion of the artery which had formed the normal blood supply to the affected territory. Sometimes, however, the damage that followed acute occlusion involved more than the one arterial territory. And further, acute myocardial damage was sometimes found without acute changes in the coronary arteries. It was therefore a matter of interest to discover the incidence of these three circumstances in the present series.

Clearly the information could only be reliable in the case of semi-recent and acute lesions. Myocardial damage was classed as massive or focal and the evidence in regard to its proximate cause appears in Table 5:16.

Table 5:16

THE PROXIMATE CAUSE OF ACUTE AND SEMI-RECENT MYOCARDIAL DAMAGE in 16 cases with acute and semi-recent arterial occlusions and 6 cases without corresponding recent arterial changes. <span style="float: right;">25 Cases.</span>			
	Corresponding occlusion of ipse-regional artery	Corresponding occlusion only of para-regional artery	No corresponding artery change
<u>Cases</u> showing:			
a. Massive damage	17	3	2 (4)
b. Focal damage	1 <sup>Ⓜ</sup>	2	4 (2)
<u>Arterial territories</u> showing:			
a. Massive damage	17	3	3 (9)
b. Focal damage	1 <sup>Ⓜ</sup>	2	10 (4)

Notes 5:16

- (1) <sup>Ⓜ</sup> One case in which complete occlusion was probably of too short a duration to have caused recognisable myocardial damage and should probably be excluded from this Table (Case 12).
- (2) Column 3: In 2 cases acute focal damage was so extensive that in aggregate it constituted massive damage of each of the three territories in their inner zones (Cases 17 and 19), hence the figures in brackets. Also, naked eye examination of the myocardium in 1 case suggested that myocardial infarction was massive where the only acute damage found microscopically was focal (Case 18). Death occurred less than one day after the onset of the fatal attack. This case is recorded as an instance of massive myocardial damage.

---

The occurrence of massive myocardial damage as the result of occlusion of the ipse-regional artery calls for no special comment. The interest of this Table lies mainly in the second column, in which it may be seen that 5 instances of myocardial infarction occurred in this series as the result of occlusion of corresponding age in a para-regional artery. Four cases were involved, with massive damage in 2, focal only in 1, massive and focal in 1, and in each case the damage was acute. On retrospective reconstruction of these cases, in each it appeared that survival of muscle tissue in the territory of one artery had depended after its occlusion on collateral blood supply from one or both of the other coronary arteries. When in turn at a later date one of these other arteries was occluded, this event was accompanied not only by myocardial



infarction in its own region but also in the territory of the artery first obstructed. In no instance was the territory infarcted in this indirect fashion previously undamaged, but was the seat of previous myocardial infarction or widespread focal fibrosis. This phenomenon has also been observed by Saphir et al. (1935), by Bean (1937) who called it "ectopic infarction" and by Blumgart et al. (1941) who used the term "infarction at a distance".

(6) Extension of infarction.

The concept is widely held that myocardial infarction may take place in several stages. The clinical picture often seems to lend itself to this interpretation both in symptomatology and in electrocardiographic changes. Indeed it would be reasonable to suppose that the sudden withdrawal of blood supply on occlusion of a major coronary artery makes necrosis inevitable in a portion only of the myocardium in its territory; while at the periphery of the ischaemic area, or between patches of necrosis, the issue of tissue survival or necrosis is not immediately decided. At a critical level of ischaemia the balance between available coronary supply and the needs of the myocardium may be disturbed favourably or unfavourably by many factors. One factor which may favourably stabilise the situation is the arrival of a sufficient measure of relief collateral blood flow through enlarged anastomoses. Extension of the infarct to involve the threatened areas of myocardium on the other hand may be brought about by any of the precipitating factors which have been found operative in acute coronary insufficiency, e.g., effort, alteration in blood pressure, or change in cardiac rhythm, as well as by further obliteration of the affected coronary artery - or indeed of another coronary artery.

The objective recognition post mortem of several stages in a given area of ischaemic myocardial damage presents little difficulty where the incidents have been separated by long intervals of time. Where the intervals of time have been short however the recognition of separate episodes of muscle damage is a matter of much greater difficulty.

In this investigation the criteria laid down by Mallory et al. (1939) were employed for the "aging" of myocardial infarcts. Broadly speaking, the histological features described by Mallory et al. were found to correspond to the age of the infarcts, where this was clearly indicated by the clinical events. It was observed, however, that small areas of infarction often showed cytological features in advance of those which formed part of more massive infarction - as indeed might be expected; and that in this way a false impression of two ages of muscle damage might be produced. In so far as the peripheral portions of the infarcted area would show changes of apparently greater age than the more central portions, it might be thought that confusion with extension of infarction would not arise; for in extension of the infarct the converse would be the case. But the distribution of myocardial damage in an area of infarction was in many cases of a nature so compound that this was not so. And, moreover, it could happen that the first incident of infarction was of a patchy or focal nature and it was the second incident that caused massive confluent necrosis.

The histological features of myocardial damage in this series were reviewed not less than three times in each case in addition to the initial examination. As a result, only minor adjustments were made in the "aging" of the infarcts as a whole, and in the great majority of instances the histological and clinical evidence could be reconciled. On the other hand, repeated review of the histological features served to reduce the degree of assurance with which two or more episodes of myocardial damage were distinguished, where the interval between the episodes would have been reckoned in days or weeks. I find myself unable to claim that "in practice this differentiation presents little difficulty" (Snow et al., 1955).

Where it may be decided that two episodes of myocardial infarction have occurred in the same territory at an interval of days or weeks, it would be a matter of considerable interest also to determine whether the second episode had been provoked by a corresponding episode of thrombosis, extension of the thrombus

into other branches, occlusion of another artery, or by some other agency. Close attention was paid to these possibilities and some of the information is abstracted in Tables 5:17 and 5:18. For this purpose only acute and recent infarcts have been selected.

Table 5:17

INCIDENCE OF EARLIER MYOCARDIAL DAMAGE IN AREAS INVOLVED IN ACUTE AND SEMI-RECENT MYOCARDIAL INFARCTION. 22 Cases, 38 Territories (23 the seat of massive myocardial damage and 15 of focal necrosis).			25 Cases.	
Recent myocardial damage related to:-		Previous myocardial damage found in:-		
		Cases	Arterial Territories	
1.	Further occlusion of ipse-regional coronary artery.	11 + 1 <sup>Ⓜ</sup>	12 + 1 <sup>Ⓜ</sup>	
2.	Recent occlusion only of para-regional coronary artery.	4	5	
3.	No further change in the coronary arteries.	6	13	
		<u>21 + 1<sup>Ⓜ</sup></u>	<u>30 + 1<sup>Ⓜ</sup></u>	

Note 5:17    Ⓜ Case 12: too recent for certainty.

Table 5:18

EXTENSION OF INFARCTION WITHIN 3 MONTHS, as recognised by myocardial damage of 2, or more, ages. 25 Cases					
Case No.	Ages of infarcts		Corresponding 2nd. episode of coronary artery thrombosis		Other contributory causes of 2nd. episode of infarction
	1st	2nd	Same artery	Other artery	
9	? 3 months	12 days (?7 days)	+ (-)	- (-)	- (operation)
7	10 days	1 day	-	-	-
14	?3 months	19 days	-	+	-
16	?8 weeks	a few days	-	-	? arrhythmia

Note 5:18    "?" in relation to ages of 1st infarcts indicates that the "aging" depended on pathological findings alone, there being no clearly recognisable corresponding clinical episode.

Table 5:17, in which the information is self explanatory, needs little comment beyond that already given elsewhere in this chapter. The main interest lies in Table 5:18.

The expression "extension of infarction" as used by others is not clearly defined. I think that it is used most commonly in the context of relatively recent infarction, and in keeping with the concept expressed in the first paragraph under this heading - as distinct from further episodes of infarction involving an area already the seat of old-standing damage. Accordingly the instances of acute and recent infarction which showed myocardial damage in more than one stage have been divided into two groups: (1) those in which the antecedent damage was 6 months or more in duration at the time of the latest episode of infarction; (2) those in which two or more episodes of myocardial damage have occurred within a shorter period of time. In the second group it so happened that the longest interval was 3 months approximately.

It can be seen from Table 5:18 that in only 4 cases was there reliable evidence of extension of infarction within a period of 3 months. In Case 9 patchy infarction of about 3 months duration was related to right coronary artery obstruction by thrombosis which was represented at death by narrowing 1-2 mm. in diameter. Subsequent complete occlusion by thrombosis some 12 days before death caused massive, confluent myocardial damage, which led to cardiac rupture. It was uncertain whether yet a further episode of myocardial damage had been related to an emergency operation 5 days after the second incident of occlusion. In Case 14 the second episode of myocardial damage was likewise separated from the first by a considerable interval- about  $2\frac{1}{2}$  months. It was also caused by a second incident of thrombosis but in this case it was the artery of another region that was involved. The other 2 cases by contrast showed a few areas of fresh focal damage - or so it was thought - as a terminal event in the last day or two. In one of these there was atrial fibrillation and it is possible that a change in cardiac rhythm was a factor in aggravating ischaemia. There was no further fresh thrombosis.

These 4 cases are the only instances in this series in which I would commit myself to objectively recognised evidence of extension of infarction. It may be noted that neither the terminal events, nor incidents so widely separated as by 10 weeks, correspond to the picture which the clinician usually has in mind when speaking of extension of infarction. Of course, were the clinical features in other cases to be taken first and the attempt made to reconcile the pathological features to them, it might be possible to agree that the histological changes were not inconsistent with an interpretation in several episodes. But this is not the same as the histological recognition of such episodes. In this series there were several cases in which the terminal illness could have lent itself to an interpretation of infarction in several stages at intervals of days, but there was no reliable histological evidence to the effect that corresponding episodes of myocardial damage had indeed accompanied these incidents. The converse however cannot be stated.

I have been somewhat surprised at the scantiness in this series of reliable objective evidence of extension of infarction during the course of the acuter phases of the terminal illness. In their series, also of 25 cases, Snow et al. (1955) report a higher incidence of extension of infarction, which they found in 10 cases: "In 9 cases the interval between the first and subsequent infarcts (due to a single occlusion) was known; in no case did this interval exceed 8 weeks and in 7 cases it was less than 3 weeks". In no case did they find further occlusion of the corresponding regional artery as a cause of extension of infarction.

The question of several episodes of thrombosis at the site of coronary artery occlusions is more fully dealt with in Chapters 7 and 8. A few points are however relevant to the present issue. In the majority of instances of acute and recent thrombotic occlusion more than one episode of thrombosis could be traced. Indeed, as already indicated, where infarction had occurred in the same arterial territory on more than one occasion it was not unusual to find corresponding

stages in the development of occlusion. Sometimes the record of these episodes was well preserved in the texture of the intimal tissue and overlying thrombus; and several incidents were more clearly distinguished in the arterial changes than in the myocardial damage which they had caused. Again there was greater difficulty in making this distinction where the incidents were close together and I did not find it possible, as a rule, to distinguish between very recent thrombus formation in two incidents and two portions of thrombus of different composition which might have been formed almost at the same time. In contrast to the ease with which incidents of thrombosis in the artery, as seen on section, could be recognised, the "aging" of thrombotic occlusions was a matter of far lesser precision than that of myocardial damage. And on this point I have found little guidance from the literature (see Chapter 7).

Clearly the question of extension of infarction is one of practical importance for the interpretation and management of the clinical illness. Were it of common occurrence and were further thrombosis found to underlie even a small proportion of incidents of extension, then the implications in regard to anticoagulant therapy would be obvious. There is however little reliable evidence that second episodes of thrombosis are common or important in this connection. It is a field that merits further survey. In the 2 cases here reported with thrombosis as the cause (direct in one and indirect in the other) of extension of infarction, no anticoagulant therapy had been administered beforehand. No conclusions would be permissible from isolated instances and the point is not further elaborated here.

THE ANTERIOR DESCENDING ARTERY, THE "ARTERY OF DEATH"

"It must be admitted, also, that the reputation of the descending branch of the left coronary as the artery of sudden death is not undeserved."

Herrick (1912)

It is evident from the findings summarised in Table 5:2, and in other published series, that the incidence of arterial occlusion falls most heavily upon the anterior descending artery. It is a matter of interest, so far only of academic importance, to determine the part played by lesions of this artery in the causation of death from coronary artery disease. Accordingly, the proximate causes of death in the 25 cases of this series were examined in relation to the background of coronary artery obstruction. In Table 5:19 are seen three main subdivisions of cases: (1) 2 cases in which death was from unrelated causes, (2) 7 cases in which there was severe widespread chronic coronary artery disease and death was due either to acute coronary insufficiency or indirectly to an additional complication, and (3) 16 cases in which death could be mainly attributed to the occlusion of one artery in particular. Of this last group, one case (No.18) showed no recent change in the lumen of coronary arteries and one artery only was the seat of chronic occlusion. In the other 15 cases death followed directly upon recent occlusion of one artery, in the course of days or weeks. Detail of these 16 cases in regard to arterial occlusions is further set out in Table 5:20. For purposes of argument, the artery last to be occluded was held to be the "artery of death". Should it be contended that this expression is acceptable only in the sense of a "last straw on the camels back", I would hold that the evidence of this series was at least suggestive that some straws are heavier than others!

Table 5:19

THE CAUSE OF DEATH IN RELATION TO THE BACKGROUND OF ARTERIAL OCCLUSIONS. 25 CASES.		
	Cases	Case Nos.
1. Intercurrent causes in the presence of sub-clinical ischaemic heart disease.	2	23, 25
2. Severe, widespread coronary artery disease without acute changes in the coronary arteries:		
(a) Directly due to coronary disease, death in acute coronary insufficiency with myocardial damage.	4	8,10,17,19
(b) Due to intercurrent complications without further myocardial damage.	3	1,2,6
3. Directly related to occlusion of a particular coronary artery:		
(a) Old standing, one artery only.	1	18
(b) During the acute illness following occlusion.	15	3,4,5,7,9,11,12,13,14,15,16,20,21,22,24
	<u>25</u>	

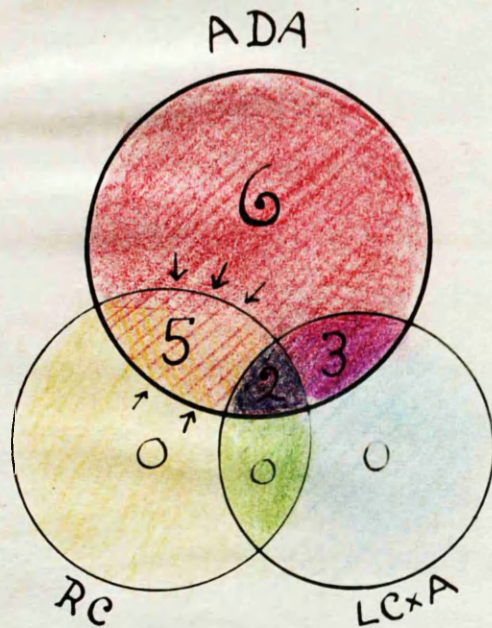
Table 5:20

16 CASES IN WHICH DEATH WAS CLOSELY RELATED TO OCCLUSION OF A PARTICULAR CORONARY ARTERY. (Occlusions Grade I and II only)		
Terminal occlusion direct cause of death	Occlusions of other arteries beforehand	Cases
ADA	-	6
ADA	RC	3
ADA	LCxA	3 <sup>≡</sup>
ADA	RC + LCxA	2 <sup>∅</sup>
RC	-	-
RC	LCxA	-
RC	ADA(S)	1
RC	ADA + LCxA	1
LCxA	-	-
LCxA	RC	-
LCxA	ADA	(1) <sup>≡</sup>
LCxA	ADA + RC	(1) <sup>∅</sup>

Note 5:20 Explanation of (1)<sup>≡</sup> and (1)<sup>∅</sup> appears in the text.



DIAG. 5:2 THE ARTERY OF DEATH.



Schematic presentation of the part played by each of the three coronary arteries in 16 cases in which death could be attributed to particular occlusions, as detailed in table 5:20

From the findings included in Table 5:20 it can be seen that anterior descending artery occlusion was the proximate cause of death on its own account in 6 cases out of 16, and on a background of previous occlusion of one or both of the other coronary arteries in a further 8 cases, i.e., in 14 out of 16 cases. In sharp contrast to the behaviour of the anterior descending artery, on no occasion was death due to occlusion of the right coronary or left circumflex arteries alone; and when it did follow right coronary occlusion in 2 cases there was also previous occlusion of at least one other artery or major branch. In each of these cases the anterior descending artery was implicated. Diagram 5:2 has been constructed in order to give graphic emphasis to these findings.

Special mention may be made of 3 cases which slightly offset the emphasis on the anterior descending artery. (1) In Case 12 there was old-standing complete occlusion of the anterior descending artery just distal to the origin of an unusually large septal artery, which appeared to have carried the main blood flow of the anterior descending artery after occlusion of its main stem. Death, which took place within an hour of the onset of pain, was thought to be immediately attributable to occlusion of this septal artery. At the same time there was also fresh occlusion of the left circumflex artery and it could be argued that the cause of death might have been left circumflex occlusion in the presence of anterior descending artery occlusion (and old right coronary artery occlusion). Accordingly, this possibility is indicated in Table 5:20 in brackets. (2) In Case 11 death was clearly due to massive antero-septal myocardial infarction 3 weeks after thrombotic occlusion of the anterior descending artery. There was also thrombosis of similar age in the previously narrowed (1.2 mm. diameter) left circumflex and previously occluded right coronary arteries, without demonstrable myocardial damage of corresponding age. Death in this case was classed as being due to anterior descending artery occlusion in the presence of previous occlusion of the other two arteries, and no other possibility has been entertained in the entries made in Table 5:20. (3) In Case 21, occlusion of LC only took place and has been recorded in Table 5:20 as occlusion of ADA in the presence of LCxA occlusion,

"It may be said in this connection, however, that other investigators, like Bork and very recently Barnes and Ball do not agree that the left coronary is more frequently involved than the right. The latter believe that the designation of the anterior descending branch of the left coronary as the "artery of coronary occlusion" is not justifiable"

Saphir et al., 1935.

"In all instances both coronary arteries were involved, but most frequently the more severe lesions were found in the left coronary artery, especially in its descending branch about 2-3 cm. from its origin...The next most severely affected branch... was the ramus anterior ventriculi sinistri."

32 instances: Saphir et al., 1935

Levine and Brown, 1929. (cited Saphir et al. 1935)

In 39 of 45 autopsy cases, the infarction was found within the distribution of the anterior descending branch of the left coronary artery.

and also as occlusion of LCxA in the presence of ADA occlusion. In the latter case it is enclosed in brackets ( )<sup>■</sup>. The anterior descending artery was without doubt the more important artery in this case.

The lethal potentiality of anterior descending artery occlusion was a most striking feature of this series. At least two questions are immediately raised (1) In how far has this phenomenon been exaggerated by selection of cases? (2) Were there any special features related to anterior descending artery occlusions which contributed to a fatal outcome?

In regard to the first question, the series was a consecutive one, selected in the ordinary sense only in so far as all but two had passed through one medical unit in a large hospital and were known cases of coronary artery disease. There was no selection in regard to any special feature of coronary artery disease. But when considered against the unknown background of coronary artery disease as a whole, the 16 cases of the third group were in another sense "selected" - they were selected by death due to the disease; and death was directly or indirectly due to anterior descending artery occlusion in each of these cases. Obviously in a larger series exceptions would be expected but I think my series is eloquently complementary to Herrick's assessment of the anterior descending artery as the artery of (sudden) death.

Are there then any special features about occlusion of this artery? In regard to the linear extent of the thrombus, to canalisation, or to antecedent narrowing I have not noted any important difference between one artery and another, save that, if anything, the longest stretches of thrombotic obliteration of the lumen were found in the right coronary artery. There are at least two other important considerations: (1) the functional importance of the anterior descending artery based upon its anatomical distribution, and (2) the possibility that the usual site for occlusion in this artery may cause a proportionally greater interruption of blood supply than is commonly found in occlusion of the others.

(1) The anatomical origin of the coronary arteries from two coronary ostia is of course the basis for the terminological division of the coronary circulation into two arteries, right and left. The further division of the left coronary into two "branches" does little to remove the spurious note of equality implicit in the terms right and left coronary arteries. Nor does the convention for classifying the coronary circulation into "right and left preponderant" and "balanced" serve to reduce the risk of misconception. The expanded representation of Spalteholz's diagram of the coronary circulation, such as used by Saphir et al. (1935) in their classic paper, greatly minimises the relative importance of this artery.

The distribution of the anterior descending artery was seen to be the most constant of the three main subdivisions of the coronary circulation. It supplied about half the myocardium of the left ventricle, as seen on mid-ventricular transverse section and also above this level. It should not be overlooked however that below this level it usually took over the supply of an increasing proportion of the ventricle; so that within an inch or so of the apex the entire arterial supply (anatomically) of the left ventricle not only in its anterior and antero-septal portions but in its lateral and posterior portions as well, was provided by the anterior descending artery, in the great majority of cases. Further, it supplied the greater part of the inter-ventricular septum in its upper portion, through which the conducting tissue passes. At a rough estimate, about half the total bulk of the left ventricle depended upon the anterior descending artery.

There was of course great anatomical variation in the distribution of the coronary arteries. But it should be appreciated that the expressions right and left "preponderance" and "balanced" coronary circulation reflect mainly the inter-relationship between the right and left circumflex arteries and give no indication of the importance of the anterior descending artery. (See also Chapter 3).

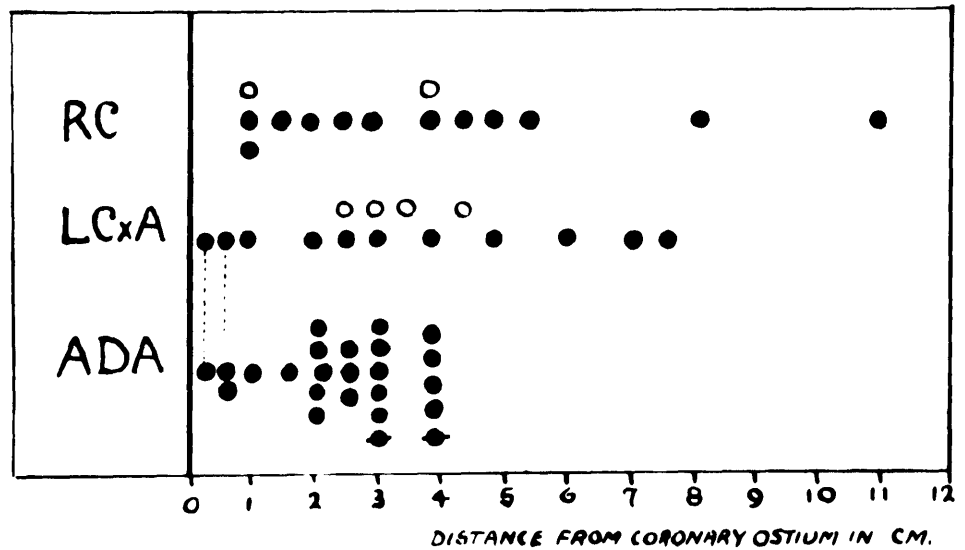
By contrast the right coronary artery normally supplied a relatively small portion of the left ventricle - the posterior 1/3, or so, of the upper 2/3 of the interventricular septum and the adjacent posterior left ventricular wall. It also commonly took part in the supply of the junctional tissues. The greater part of its distribution was to the right ventricle which was evidently less susceptible to ischaemic damage than was the left. Right ventricular infarction does not appear to rank with left ventricular ischaemia as a cause of death.

Although it was on occasion a very large artery, in the majority of cases the left circumflex coronary artery was definitely the smallest of the three. Moreover, the tendency for large branches to arise fairly early in its course further diminished the consequences of its occlusion, as a rule.

(2) Other things being equal - which they never are in coronary artery disease - one would expect the extent of muscle damage caused by coronary occlusion to depend upon the extent of the anatomical territory of the artery distal to the point of occlusion. In a given artery this would in turn depend upon the site of occlusion along the length of its main stem. It is therefore relevant to the present argument to compare the distribution of occlusions in the anterior descending artery with that found in the other arteries. Accordingly the distance from the coronary ostium of the proximal end of the most proximal occlusion in each artery was measured and the information so derived is presented in Diagram 5:3.

In Diagram 5:3 it can be seen that the distribution of occlusive lesions along the length of the arteries which lay in the atrio-ventricular groove was more wide-spread than in the anterior descending artery. In the anterior descending artery all but 4 of 22 main stem occlusions were within 3 cm. of the ostium and the remaining 4 within the next centimeter. As a result, in every case of occlusion of this artery a major portion of its anatomical

DIAG. 5:3 SITE OF COMPLETE (I) and CANALISED, ONCE COMPLETE (II)  
 OCCLUSIONS IN 45 ARTERIES . 25 CASES.  
 SEVERE NARROWINGS (III) IN ARTERIES NOT OTHERWISE OBSTRUCTED  
 ALSO INCLUDED.



- Position of proximal end of occlusion (I and II).
- " " " " severe narrowing (III).
- ⋮ Entry is made under LCxA and ADA for LC main-stem occlusions (Cases 1, 21)
- ◆ Occlusion of large branch where main stem was unobstructed proximally (Cases 8, 11)

distribution lay distal to the point of occlusion. Whereas nearly half the occlusions of the right and left circumflex arteries were beyond 3 cm. from the ostium.

The possibility exists therefore that the tendency for occlusions of the anterior descending artery to be so disposed in the proximal few centimetres of its course may have an important bearing on the extensive nature of many antero-septal infarctions and upon the proportion of such lesions that directly or indirectly lead to death. It would be worth while examining the detail of location of occlusive lesions in this artery in order to discover, if possible, what factors may have conditioned their localisation. In Diagram 5:3 the grouping of anterior descending artery occlusions in the region of 2-3 cm. from its origin would suggest that in this area some anatomical factor may be operative. The more widely scattered lesions in the other arteries would by the same token suggest that search for a corresponding factor in them might well prove fruitless. This matter receives consideration elsewhere. (See Chapter 3).

---

Saphir et al., 1935 record that 2 cm. distal to the bifurcation was noted as the usual site for occlusion in the anterior descending artery by Levine and Brown, 1929 ; as the site of the severest changes in the coronary arteries by Mönckeberg, 1924 ; and was referred to as the "Lieblingstelle" by Kirch, 1927.

"The commonest site of occlusion is the anterior descending branch of the left coronary artery about 2 cm. from its origin.. The circumflex branch of the left coronary and the main stem of the right coronary are each involved much less often, a common site of occlusion of each of these vessels being about 1 cm. from its origin. "

Gould , 1953.



The possibility exists therefore that the tendency for occlusion of the coronary artery is not necessarily related to the position of the artery in the heart. It would be wrong to conclude that the position of the artery is a factor in the development of atherosclerosis. It would be more correct to say that the position of the artery is a factor in the development of atherosclerosis. It would be more correct to say that the position of the artery is a factor in the development of atherosclerosis.

Zaus and Kearns, 1952

"Massive Right Ventricular Infarction is rare", Zaus and Kearns, 1952.

Mallory et al. 1939

54 hearts, infarct located in:

L.V.	53	Apex	24
		Apex and septum	22
		Base	5
		Septum	2
R.V.	1		

Yater et al., 1948

(cited Gould, 1953)  
 153 hearts, 153 myocardial infarcts  
 (130 gross, 23 microscopic)

Site:	L.V.	146
	R.V.	7 - all in post. wall.

Appelbaum and Nicolson, 1935

113 cases : infarction of the right ventricle in 8.

Barnes and Ball, 1932

49 cases. Infarction practically confined to the left ventricle.

INFARCTION OF THE RIGHT VENTRICLE AND RELATED CORONARY  
ARTERY OCCLUSION

There can be no question in the mind of the clinician and the pathologist alike that infarction of the left ventricle is a far more dramatic event than is infarction in the right ventricle. Infarction of the right ventricle receives relatively little attention, and indeed one wonders if it is often disregarded. Perhaps this is because isolated infarction of the right ventricle is a distinctly rare event and when it occurs in company with infarction of the larger left ventricle it is apt to be overshadowed. In a consecutive series of 160 hearts that were the seat of 235 myocardial infarcts, Wartman and Hellerstein (1948) were able to find only 4 instances in which the right ventricle alone had suffered infarction. On the other hand there was involvement of the right ventricle in association with left ventricular infarcts on 18 occasions. Mallory et al. (1939) found ~~one~~ instance of right ventricular infarction in 54 hearts.

The occurrence of ischaemic myocardial damage in the right ventricle was by no means a rare event in the present series. The lesions were usually relatively small, being for the most part of a focal nature. Massive infarction of the posterior wall did however occur in 3 hearts. In every case the right ventricle was carefully inspected for gross evidence of infarction or fibrosis and whether or not such lesions were found the micro blocks were so cut that the anterior and posterior walls of the right ventricle for a distance of 1-2 cms. were included with the blocks of the interventricular septum. The information in regard to ischaemic myocardial damage in the right ventricle is recorded in Table 5:21 together with the background of arterial occlusion and the company of left ventricular infarction in which it occurred. From the data so obtained it would seem that the right ventricle in coronary artery disease is by no means a barren field for the investigator.

As in the left ventricle, the distribution of ischaemic damage in the right ventricle could, as a rule, be traced to occlusion of the artery of supply to the

region. The arterial supply of the right ventricle is not without interest and an understanding of the detail of its distribution is essential for the interpretation of the data which appears in Table 5:21. At approximately mid-ventricular level, the anterior wall of the right ventricle in my preparations received its arterial supply not from the right but from the anterior descending branch of the left coronary artery, for a variable distance from the interventricular groove. Above this level, its supply came from the first branches of the right coronary artery, or from an accessory right coronary artery. The remaining parietal wall of the right ventricle was consistently supplied by the right coronary artery with the exception of the posterior portion near to the interventricular septum where occasionally it was supplied by the left circumflex artery. In the neighbourhood of the apex the anterior descending artery played an inconstant part in the blood supply of the posterior wall. The arterial supply of the septal wall was essentially that of the interventricular septum as a whole, i.e., the anterior portion from the anterior descending artery and the posterior from the posterior interventricular artery (which in hearts with balanced or right preponderant coronary circulations stemmed from the right coronary artery). An artery of considerable interest was the first main septal branch of the anterior descending artery which traversed the septum and continued across one of the columnae carnae of the right ventricle (I think it was probably the moderator band in my cases) to arborise in the subendocardial plexus of the right ventricle.

It was thus found possible to explain on a basis of anatomical arterial supply the occurrence of infarction localised in the anterior wall, in the posterior wall or confined to the septal surface and muscular columns; or conversely to explain the sparing of one or more of these regions in the presence of right ventricular infarction nearby. In conformity with the distribution of arterial supply, right ventricular ischaemic damage has been recorded in Table 5:21 under three headings: anterior, posterior and septal. The muscular columns are regarded as part of the septal territory.

Table 5:21

INFARCTION OF THE RIGHT VENTRICLE AND RELATED CORONARY ARTERY OCCLUSIONS. 25 Cases.								
Case No.	Right ventricular ischaemic myocardial damage			Arteries occluded			Site of left ventricular infarcts	Thrombus in right ventricle
	Anterior wall	Septal wall or muscular columns	Posterior wall					
1	-	-	-	-	LCxA	ADA	A-L	+
2	x	-	-	RC	-	ADA	A-S	-
3	-	-	-	-	-	ADA	A-S	-
4	-	-	old	RC	LCxA	ADA	P	-
5	-	-	-	RC	LCxA	ADA	A	-
6	-	-	-	RC	LCxA	ADA	D-Z	-
7	x	-	old	RC	-	ADA	A-S, P	-
8	-	-	-	(RC) <sup>#</sup>	LCxA	-	D-Z	-
9	-	X	acute	RC	-	S	P	+
10	X	X	X	RC	LCxA	ADA	A-S, A-L, P	* & RA
11	X	X	X	RC	LCxA	ADA	A-S, L, P	-
12	X	X	X	RC	LCxA	ADA	A-S, L, P	-
13	X	X	-	-	LCxA	ADA	A-S	-
14	X	-	-	-	LCxA	ADA	A-S, A-L	-
15	X	-	-	-	-	ADA	A-S	-
16	X	X	-	-	-	ADA	A-S	-
17	-	-	-	RC	LCxA	ADA	D-Z	-
18	-	X	-	-	-	ADA	A-S	-
19	x	-	-	RC	LCxA	ADA	D-Z	-
20	X	acute	-	-	-	ADA	A-S	-
21	-	-	-	-	LCxA	ADA	A-S, L, P	-
22	-	X	-	RC	LCxA	ADA	A-S, P	-
23	-	-	-	-	-	ADA	A-S	-
24	X	X	X	RC	-	ADA	A-S, P	-
25	-	-	-	RC	LCxA	-	P	-
	11 + 1	10	7	14	15	22		

## Notes 5:21

- Extensive massive infarction.      # RC ostium - 1 mm. diam.  
 X Focal damage.                              S = septal branch of ADA.  
 x Small scale focal fibrosis                RA = right auricle.  
 A-S = antero-septal.  
 A-L = antero-lateral.  
 P = posterior (basal)  
 L = lateral.  
 D-Z = deep-zonal.

Assessment of RV infarction as the primary cause of RVF was considered admissable only where signs of LVF were absent or relatively trivial. This of course does not preclude the possibility that RV infarction contributed to RVF.

It can be seen from this Table that inclusion of the anterior right ventricular wall in the immediate vicinity of the interventricular septum was a common event in the presence of antero-septal infarcts, and in no instance occurred without anterior descending artery occlusion. Septal wall infarction was likewise part of antero-septal infarction resulting from anterior descending artery occlusion - with one exception, Case 9. In this instance there was right coronary occlusion as the only occlusion of a main stem artery and the infarcted area was in the posterior part of the interventricular septum. Curiously enough there was severe narrowing of the origin of the first major septal artery and it is tempting to suppose that this may have aggravated the consequences of right coronary occlusion. For in this case posterior right ventricular infarction was extensive and death took place from rupture of the posterior left ventricular portion of the infarct. (Rupture of the interventricular septum occurred in one case in this series (No.20), and in this sense involved the right ventricle, but I had no instance of parietal wall infarction with rupture of the right ventricle.) Posterior right ventricular infarction occurred in 7 cases. In 6 of these cases the damage was part of a more extensive infarct involving the posterior wall of the left ventricle and was the result of right coronary artery occlusion. Putting this the other way round, in 6 out of 7 instances there was no evidence of posterior right ventricular ischaemic damage in the presence of anterior descending or left circumflex coronary artery occlusions alone, but only in the presence of right coronary occlusion as well. In the seventh instance (Case 24) the right coronary was largely obliterated but posterior wall infarction of the right ventricle followed anterior descending artery occlusion. The infarct lay in the terminal posterior territory of this artery which was unusually extensive. The extent of the infarct was probably aggravated by right coronary occlusion.

On the other hand right coronary artery occlusion occurred in 4 cases without causing right ventricular damage. It would be pertinent to enquire where the occlusions were situated in the right coronary artery in these cases; for if

they were only near its distal end might it not be that the right ventricle lay outwith the ischaemic territory? But it was not so. The occlusions in these cases (Nos. 2, 5, 6 and 25) were situated 1, 4, 1 and 4 cms. respectively from the coronary ostium. It is probably not without relevance however to note that the only two instances in this series of occlusion of a right coronary artery by severe narrowing alone belonged to this group of four (Cases 5 and 6); and that the right coronary artery in Case 2 was unusually small. (In addition the right coronary ostium of Case 8 was narrowed to 1 mm. and no infarction of the right ventricle was found.) For reference, some of these points are summarised in Table 5:22.

Table 5:22

THE RELATIONSHIP BETWEEN ISCHAEMIC MYOCARDIAL DAMAGE IN THE RIGHT VENTRICLE AND CORONARY ARTERY (MAIN STEM) OCCLUSIONS. 25 Cases.				
(1) Right ventricular ischaemic damage	Cases	Site of RV "infarct"		
		Ant.	Septal	Post.
A: In presence of occlusion of RC	9	7	5	7
ADA	14	12	9	6
LCxA	8	7	5	4
B: Apparently caused by occlusions of				
RC	6	0	1	6
ADA	13	12	9	1
LCxA	0	0	0	0
Total RV "infarcts"	15 <sup>#</sup>	12	10	7
(2) Occlusions in the absence of RV infarction				
RC	4 (out of 12)			
ADA	8 (out of 21)			
LCxA	7 (out of 10)			

Note 5:22 (1) "infarct" = territory in which myocardial damage of ischaemic type was found. For the most part this was focal replacement fibrosis. (See also Table 5:21).

(2) # Ischaemic damage of RV in 15 cases. For detail see Table 5:21.

It can be seen from Tables 5:21 and 5:22 that, although massive right ventricular infarction was uncommon in this series, occlusion of the arteries of supply to the right ventricle was unaccompanied by myocardial damage in the walls of this chamber in only 12 out of 36 instances. (RC occlusions 14, ADA occlusions 22.) Ischaemic damage of the right ventricle was massive in 3 and focal in 12 out of 25 cases. These findings are scarcely in accord with the rarity of right ventricular infarction that is commonly accepted. It is possible that the high incidence of massive posterior right ventricular infarction (3 cases) is fortuitous in so small a series, but it is a finding which is in striking contrast to the following text-book excerpt.

"Schlesinger (1938) has pointed out the consistent absence of large vessels and of fibrosis in the posterior basal portion of the right ventricle and the rarity of infarction in this location. Despite the frequency of occlusion of the right coronary artery, infarction of the right ventricle is extremely rare. Blumgart and his associates (1940) believe that this is so because the right ventricle, like the atria, is thin walled and may derive considerable nourishment from the blood coming directly from its cavity."

(Gould: Pathology of the Heart, 1953)

Several views have been put forward to explain the relative infrequency of right ventricular infarction. These include the thinness of the wall, nutrition by Thebesian veins, and the relatively low intraventricular (and accordingly intramural) pressures during systole. The last of these will offer a lesser degree of opposition to systolic coronary blood flow than is the case in the left ventricle and this seems to me to be the best found of the above explanations. Thebesian veins have been quoted by many and revealed by few. Schlesinger suggests that investigators might well concentrate on the posterior basal region of the right ventricle in the search for Thebesian veins, because of the consistent absence of large vessels in this "apparently avascular" area (Schlesinger, 1938). In my own series there was little difference to be found between the arterial pattern found in this area and the rest of the right ventricle in normal as well as in diseased hearts; and as already indicated ischaemic changes were found there in 6 out of 25 cases.

Adherent thrombus was found in association with right ventricular infarction on only two occasions (Cases 9 and 10) and there was no evidence of pulmonary embolism in either of these cases. They had received anticoagulant therapy for 4 and 2 days before death respectively. Adherent thrombus was found in the right ventricle in only one other case in this series (Case 1). (Pulmonary infarction however did occur in one case (No.11) in which adherent thrombus was found in the right auricle.)

#### Congestive Cardiac Failure

In the clinical records of this series, failure of one or both ventricles was noted not infrequently, and the incidence of right and left ventricular failure is recorded in Table 5:23 together with the incidence of right ventricular (and left ventricular) infarction. Positive entries in the case of right ventricular failure were based upon jugular venous over-filling, oedema or the expressed opinion that congestive cardiac failure was present. In left ventricular failure paroxysms of acute dyspnoea, basal crepitations, pulmonary congestion on the X-ray, circulatory collapse or "shock", or, again, the opinion that left ventricular failure existed were taken as acceptable evidence. On the other hand, not in every case in which the entry in the Table is negative was there a definite statement to this effect in the clinical records.



Table 5:23

RIGHT VENTRICULAR INFARCTION AND RIGHT VENTRICULAR FAILURE. 25 Cases						
	RV infarct	RV failure	LV infarct	LV failure	Comments	Infarct. of R.V. a cause of R.V.F.?
1	-	F	≡	T	-	-
2	+	-	≡	-	-	-
3	-	-	≡	-	-	-
4	≡	≡	≡	T	Congestive cardiac failure with 1st. infarct 7 yr. before death. Recovered. Terminal L.V.F. only.	?+
5	-	-	≡	T	-	-
6	-	-	+	-	-	-
7	≡	-T	≡	≡	No R.V.F. with R.V. infarct. C.C.F. only after L.V. infarct and L.V.F.	-
8	-	-	+	-	-	-
9	≡	-	≡	T	No C.C.F. despite massive R.V. infarct.	-
10	+	-	≡	T	-	-
11	+	?	≡	?	Signs partly due to pulmonary infarction.	-
12	+	-	≡	-	-	-
13	+	-	≡	T	-	-
14	+	-	≡	?	X-ray only suggestive of L.V.F.	-
15	+	T	≡	T	-	-
16	+	-	≡	T	-	-
17	-	≡	+	≡	-	-
18	+	-	≡	T	-	-
19	-	-	+	T	-	-
20	≡	≡	≡	T	Rupture of I.V.S.	-
21	-	T	≡	T	-	-
22	+	T	≡	T	-	-
23	-	-	≡	-	-	-
24	+	≡	≡	≡	-	-
25	-	-	≡	-	-	-

## Note 5:23

T = Terminally - i.e., in the last day or two.

≡ = (1) Signs of failure present, possibly only in terminal illness but not merely "terminally."

(2) Massive infarction.

+ = Focal infarction only.

R.V.F. = R.V. failure.

C.C.F. = Congestive cardiac failure.

L.V.F. = L.V. failure.

Although the cases were well documented it was not always possible in retrospect to derive a clear picture of the duration and time sequence of right and left ventricular failure. For the most part the signs were noted only in the terminal phases of the terminal illness, in which right ventricular failure primarily due to right ventricular damage could not have been distinguished with certainty from failure secondary to left ventricular failure. Thus in 5 cases signs of right ventricular failure were noted in conjunction with left ventricular failure, in the terminal phase of the last illness.

There were however 4 cases in which right ventricular failure had been observed over a longer period of time. (1) In Case 17, right ventricular failure was evidently secondary to profound left ventricular weakness; there was no post-mortem evidence of right ventricular infarction. (2) By contrast, in Case 7, massive posterior myocardial infarction included the posterior wall of the left ventricle apparently without causing signs of failure of either ventricle at the time; but, at a later date, right ventricular failure accompanied left ventricular failure which followed anteroseptal infarction. The anterior wall of the right ventricle was involved only to a slight degree in the terminal infarct. The remaining two cases have special interest. (3) Case 20 showed increased pulsation and overfilling of the jugular veins, and there was rupture of the interventricular septum. (4) Case 4 suffered widespread massive infarction of the heart involving the posterior wall of the left ventricle, posterior part of interventricular septum and the posterior wall of the right ventricle, some 7 years before death. During this illness he developed severe right heart failure for which he was treated with digitalis. After some months digitalis was discontinued without return of cardiac failure. It would seem likely in this case, where signs of left ventricular failure were less in evidence, that the right ventricular damage played at any rate an important part in the causation of failure of that ventricle. Terminally, typical left ventricular failure developed without failure of the right ventricle. This is the only case in this series in which ischaemic damage of the right ventricle seems to have been an important element in promoting its failure.

On the other hand, in Case 9, right coronary occlusion was followed 9 days before death by posterior myocardial infarction which included massive infarction of a large portion of the right ventricle. Crepitations were noted in the lung bases but there is no record of signs of right ventricular failure.

No definite conclusions on the relationship of right heart failure to right ventricular infarction can be reached from the findings of this series. The findings are however not discordant with the view that "in myocardial infarction with failure the primary strain is on the left ventricle, the right ventricle being only secondarily affected." (Gould, 1953). I wonder, however, whether this is only partly true, and whether the assumption that right ventricular infarction is an uncommon event may have influenced the clinical assessment of congestive failure in the presence of myocardial infarction, to the neglect of the part which may have been played by right ventricular damage. Unless the clinician has the possibility of right ventricular infarction as a cause of right heart failure in mind at the time, only in the most striking instances will the pathologist be enabled to form an opinion of the probable part played in cardiac failure by the right ventricle, when he should find this chamber the seat of ischaemic damage. The assessment would need to be made in prospect, not in retrospect alone.

While right ventricular failure in ischaemic heart disease is commonly regarded as secondary to left ventricular failure, other conditions have been cited. These include other causes of right heart strain, such as pulmonary disease, mechanical effects of the diseased left ventricle on the right, and the effects of perforation of the interventricular septum. It has been suggested that bulging to the right of an infarcted interventricular septum may encroach upon the cavity of the right ventricle (Atlas et al., 1950; Russek and Zohman, 1950) or obstruct its outflow tract (Peel, 1948). As already indicated, right ventricular failure related to interventricular septal perforation occurred in one case of this series. In Case 13 there was mitral stenosis and pulmonary disease (silicosis) but no right ventricular failure and no right ventricular infarction. There was, on the other hand, terminal left heart failure due to left ventricular infarction.

CORONARY OSTIAL STENOSIS

Insertion of cannulae into the coronary ostia before injection was accomplished without difficulty until the sixth case, in which the right coronary ostium was so small that a special cannula had to be made. On measurement it was found to be about 1 mm. in diameter. It then became my practice to measure the ostial diameter by means of graduated probes, inserted just into the ostium. The measurements so derived from the last 20 cases appear in Table 5:24.

Table 5:24

CORONARY OSTIAL DIAMETERS IN 20 CASES									
Diam.	1 mm.	1.5	2	2.5	3	3.5	4	5 mm.	
RC	3	3	3	2	1	3	5	0	20
LC	0	2	4	2*	1	3	7	1	20

Note 5:24 \* Case 8: 2 orifices of 2 mm. diameter each. (= 1 of 2.5 mm.)

Table 5:24 indicates the frequency with which ostial stenosis of varying degree was found in 20 consecutive cases. It can be seen that, in general, greater degrees of narrowing were found of the right coronary ostium than of the left. The converse obtained with the incidence of ostia which were not narrowed. This is in keeping with the average diameter of the ostia derived from these figures: RC - 2.6 mm. LC - 3.1 mm. (Average normal diameter probably 4 mm.).

It was however evident in individual cases of coronary artery disease that the degree of ostial stenosis not only varied greatly but bore only an inconstant relationship to the severity of the disease of the coronary arteries themselves. In general, coronary ostia which were free from atherosclerosis had a diameter which was similar to the anatomical calibre of the arteries which they fed; and this in turn was closely related to the extent of the myocardial territory which they supplied. It has already been indicated that there was great normal variation

in the extent of these territories and in the calibres of the related normal coronary arteries. Ostial diameters in normal hearts varied from 2-4mm. and were sometimes 6-7 mm. in hypertrophied hearts. Accordingly it was obvious that a diameter of, say, 1-2 mm. might represent severe ostial stenosis for one artery and be unimportant or even normal for another. Moreover, ostial stenosis in the presence of narrowing of greater degree, or complete occlusion, of the corresponding coronary artery would obviously have lesser importance than if it were the sole obstructive lesion. The functional significance of ostial stenosis is thus not clearly indicated by collective data which do not take these factors into account.

It would be of interest also to know the relationship of stenosis of the coronary ostia to the severity of the arterial disease in the heart as a whole. The right coronary orifice measured 1 mm. in diameter in 3 cases. Two of these (Cases 6 and 8) had long histories of ischaemic heart disease with widespread severe chronic obliterative coronary artery disease. But in one the ostial stenosis was the only obstructive lesion of that artery. In the third case (No.11) the right coronary artery was anatomically small so that stenosis in this instance had lesser functional significance, and in addition there was a canalised occlusion within 3 centimetres of the orifice. In each of 3 cases where the orifice of the right coronary artery was 1.5 mm. in diameter, the ostial lesion was part of severe chronic generalised obliterative disease of the coronary arteries. Narrowing to the same diameter in the left coronary ostium was part of the picture of generalised obliterative disease in one case and in the other there was severe narrowing of the left coronary circumflex and occlusion of the anterior descending artery. Where the left coronary ostial diameter was 2 mm., occlusion occurred within a few millimetres in one case and was part of generalised obliterative disease in 3 others. Where the right coronary ostium was 2 mm. in diameter, one fed an anatomically small right coronary artery, one a large artery not obstructed elsewhere, and there were no special features related to the third. Above 2 mm. diameter in either artery there was no evident relationship between

ostial diameter and the severity of coronary artery disease. Complete occlusion and widespread atherosclerotic disease occurred in arteries whose orifices were practically normal.

Ostial stenosis in all cases of this series appeared to have been atherosclerotic in nature as part of atherosclerosis of the sinus of Valsalva. Sometimes the orifice was rigid as the result of calcification. In no case was there evidence to suggest a syphilitic origin either in the aorta or elsewhere, and serological tests for syphilis were negative. As might be expected, where one ostium was severely involved the other was, as a rule, also diseased and vice-versa; but exceptions existed where the one was 1 mm. and the other 4 mm. in diameter (Case 11). Although severe stenosis was found in several cases in which the history was relatively brief, in each there was severe chronic coronary artery disease. Conversely, in the presence of long-standing severe generalised disease of the coronary arteries there was in each case narrowing of 1, 1.5 or 2 mm. diameter in both ostia (Cases 6, 8, 10, 17, 19). (No measurements were taken in the other long-term Cases, 1 and 4)

The sum of the two ostial diameters would not provide a suitable expression for comparison of cases, for the same figure could have greatly differing values in terms of resistance to bloodflow. According to Poisseuille's Law resistance to fluid flow varies inversely with the fourth power of the radius (other things being equal). This calculation has accordingly been applied and the results are recorded in Table 5:25.

In this Table the figures express (in nearest round figures) the relative volumes of fluid which would theoretically pass through the coronary orifices, other conditions being the same in all cases. It will be appreciated that the resistance offered to blood flow by narrowing at the ostium is only a small part of the total resistance to blood flow in the coronary circulation. Accordingly it may be assumed that important interference with blood flow would occur only where the ostial stenosis was severe. On the basis of considerations already

discussed in relation to narrowing and occlusion of the coronary arteries themselves, it is probable that an ostial diameter of 2 mm. or more may transmit a sufficient blood flow volume; whereas insufficiency might be expected where the ostial diameter is in the region of 1 mm. The findings in terms of myocardial damage, or its lack, in this series are out of accord with this concept; but as myocardial damage could in every case be related to obstructive lesions of the coronary arteries themselves, no firm conclusions could be reached.

Table 5:25.

OSTIAL STENOSIS AND RELATIVE RESISTANCE TO BLOOD FLOW 20 Cases					
Case	Ostial diameters in mm.		Relative resistance to blood flow (approx. reciprocal)		
	R	L	R	L	R + L <sup>oi</sup>
6	1	2	1	16	17
7	4	4	250	250	500
8	1	2.5	1	40	41
9	4	4	250	250	500
10	1	1.5	5	5	10
11	1	4	1	250	251
12	4	4	250	250	500
13	4	1.5	250	5	255
14	2	3	16	80	96
15	2.5	3.5	40	150	190
16	3.5	3.5	150	150	300
17	1.5	2	5	16	21
18	2.5	2.5	40	40	80
19	1.5	2	5	16	21
20	2	4	16	250	266
21	3	2	80	16	96
22	3.5	3.5	150	150	300
23	2	4	16	250	266
24	3.5	4	150	250	400
25	4	5	250	625	875

I have so far found little reference to the coronary ostia in atherosclerotic disease. It is of course well known that they may be involved in atherosclerosis of the aorta but few authors comment upon the degree of stenosis or give measurements. Indeed I have not found reference to their normal dimensions. In this series it can be stated that, on occasion, stenosis of a coronary orifice had evidently been an obstructive lesion of importance but in no instance was there complete obliteration and in no instance was myocardial damage referable to ostial stenosis alone.

BRANCH OCCLUSIONS

In this section the findings which concern occlusion of branches of the coronary arteries, as distinct from the main stems, are presented. It will be recalled that these branches were classed as 2nd, 3rd and 4th division arteries, according to size, and sometimes to importance (e.g., the main septal artery was classed as a 2nd division artery, even when its dimensions were not great). (See page 5: 8.)

Occlusions of these branches are referred to in this chapter, and in the text and diagrams of Chapter 2, as grade IV, V and VI occlusions respectively. In Table 5: 26 below, grade IV occlusions have been divided into complete, apparently canalised-once-complete, and severe narrowing (as with main-stem occlusions). Those which showed only severe narrowing, and therefore may never have been complete, were not included in the tables that appeared in the earlier part of this chapter (Tables 5:4,6). No attempt has been made to subdivide grade V and VI occlusions in the same fashion.

Table 5: 26

OCCLUSIONS OF BRANCHES OF THE CORONARY ARTERIES. 25 Cases			
Artery Division Occlusion Grade	2nd IV	3rd V	4th VI
Complete at death	6		
Canalised at death, ? once complete.	9		
Severe narrowing, ? never complete.	12		
Unclassified.		38	1
Total:	27	38	1

Detail of the occlusions themselves may be seen in the diagrams of the coronary circulation in Chapter 2. A few points may be made in regard to the selection of branch occlusions. A branch occlusion is discounted where



it arises within 1 cm. of a main stem occlusion or is in fact part of it. There is one exception to this. Where recent thrombosis occluded the lumen at a point where there was good evidence of previous occlusion of a branch, then that branch occlusion is treated as a separate occlusion, and is included in Table 5: 26. This could not have been told from examination of the arteriograms alone. The evidence was to be found in the mounted 2 mm. thick serial sections of the arteries. An example is the main septal artery in case 24.

The relationship between branch occlusions and myocardial damage.

It is popularly assumed that small areas of infarction are likely to result from occlusion of smaller coronary artery branches. My own evidence would suggest that this is a misconception. Out of a total of 66 instances, I have been able to record only 5 examples of ischaemic myocardial damage which seemed to be referable to occlusions of a coronary branch artery. In only 2 of these did the evidence seem certain (cases 4, 15).

I present these figures however with reservations. They refer to gross evidence for the most part, for only occasionally did I select portions of myocardium specially to establish this point. Moreover, the observations were not sufficiently systematically pursued, or recorded, for me to be certain that some small areas may not have been overlooked; or may not have been distinguished from neighbouring damage of greater severity, resulting from main-stem occlusion. I can however assert that such structural damage as may have resulted from these occlusions was sufficiently trivial to have escaped notice in a careful examination, except for the few instances cited.

Presumably the comparative freedom from infarction in the areas supplied by branch vessels was related to the smallness of their bulk, and the short distances which collateral blood flow would have to travel to supply them.



The collective data which bore upon the relationship between coronary artery occlusion and myocardial damage have been examined and analysed in this chapter. Broadly speaking, a close relationship was found between arterial occlusions and myocardial damage in the related territories; and also between the incidence of episodes of arterial occlusion and episodes of myocardial damage. On the other hand, great variation obtained in the relationship borne by the extent of myocardial damage to the severity of coronary artery obstruction. With the detailed information made available in individual cases (in respect of many features which included anatomical distribution of the coronary arteries, the site and extent of each of the occlusive lesions, and their episodic development, the exact distribution of myocardial damage in relation to arterial territories and the pattern of anastomotic enlargement, together with relevant clinical information) a very high degree of correlation was found between arterial changes and their consequences. There remained only a few discrepancies which could not be satisfactorily reconciled.

The degree of coronary artery narrowing before final occlusion has been closely examined, and also its relationship to myocardial damage, both before and after final occlusion. Three grades of narrowing short of complete occlusion were adopted and their functional significance was assessed from the degree of myocardial damage related to them, and from the consequences of their final obliteration. Grounds have been put forward for regarding coronary arteries as "unobstructed" where the lumen diameter was still 2 mm. or more (i.e., had been reduced by not more than half its original dimensions); and for regarding 1 mm. lumen diameter (approx.) as critical for the nutritional integrity of the myocardium. Despite the potent influence which such severe narrowings could have on the enlargement of coronary arterial anastomoses, their final obliteration was nonetheless followed by massive myocardial infarction. This occurred in 5 cases which died as a result, thereby indicating the previous adequacy of, and dependance of the myocardium on, the measure of blood flow passing through these narrow channels.

The background of obliterative coronary artery disease against which recent occlusion and myocardial damage had taken place was closely examined and found to vary greatly. Massive regional myocardial infarction was never encountered except where there had been complete occlusion of the ipse-regional artery. (A proportion of such occlusions were canalised by the time of death.) In 4 of the 16 cases which showed recent myocardial damage related to recent coronary artery occlusion, the ipse-regional artery was the only coronary artery that was obstructed. Further, there was reason to suppose, on reconstruction of the likely sequence of events, in cases of greater complexity, that in 5 others the first infarct had likewise occurred at a time when the other arteries were still free from obstructive lesions. These findings are in keeping with the effects of acute coronary occlusion induced experimentally and disagree with the widely quoted concept that occlusion of at least two major coronary arteries are required for the production of myocardial infarction in man.

It is also stated that coronary artery occlusion can occur without causing ischaemic myocardial damage. It needed no detailed analysis to recognise that the proportion of arterial territory distal to the point of occlusion that became the seat of infarction showed all gradations, in different instances, from massive infarction of the greater part of the affected territory, to relatively scanty focal damage. Focal necrosis or focal fibrosis was not infrequently the only damage which had ensued from complete and canalised-once-complete occlusions of main stem coronary arteries. Complete absence of related ischaemic myocardial damage, however, was encountered only twice in cases which had survived coronary artery occlusion sufficiently long for changes to have become manifest. One of these involved a right coronary artery which took no part in the blood supply to the left ventricle. The other was in a left circumflex artery distal to the major branches to which it had given rise.

Conversely it is also sometimes stated that myocardial infarction may occur in the absence of coronary artery occlusion. In the 25 cases of coronary artery disease under consideration, there were 3 instances of focal fibrosis in

the territories of arteries not themselves occluded at the time of death. Tentative explanation for these instances has been put forward. It may also be noted that in each case there was occlusion of one or more para-regional coronary artery. Attention has also been directed to the occurrence of myocardial infarction in 2 cases of rheumatic valvular disease in which no obstructive lesion in the coronary arteries was found.

Recent myocardial damage on the other hand occurred in 6 cases in the absence of recent change in the coronary arteries. In each instance there was severe chronic obliterative coronary artery disease.

Further, recent myocardial damage occurred on 5 occasions following occlusion of corresponding age in another coronary artery, without recent change in the artery anatomically distributed to the affected territory. In every instance of this phenomenon ("infarction at a distance" or "para-regional infarction") there was also massive myocardial damage in the territory of the recently occluded artery. Moreover, recent para-regional myocardial damage was never found except in the territory of an artery that had been previously occluded.

With one exception (in which death followed within 1 hour), recent coronary artery occlusion had resulted in massive regional myocardial infarction, and had been the cause of death. Generally speaking, myocardial damage of old-standing tended to be of lesser extent than recent myocardial infarction. This was thought mainly to reflect the tendency for lesions of lesser severity to be survived; and that this in turn was at least partly the result of a slower evolution of the arterial disease process, which thereby allowed more time for the development of collateral channels before and after complete occlusion. Exceptions however occurred in both directions. Focal fibrosis was sometimes the only lesion to be found in the territory of a chronically occluded artery.

Although more than one episode of myocardial damage was commonly found in the same arterial territory, the episodes had usually been widely separated in

time. Recognisable extension of infarction within 3 months was distinctly uncommon. It occurred in only 4 cases. In one of these it resulted from a second episode of occlusive thrombosis in the ipse-regional artery. In another, occlusion of a para-regional artery was the cause. The interval of time between the episodes was in the region of 2 months and the second episodes of infarction were survived for 12 and 19 days respectively. The precipitating causes in the other two remain undetermined. The common supposition that further thrombosis and extension of muscle damage are likely complications during the first few weeks following myocardial infarction has therefore received but scanty positive support from the findings of this series.

Assessment of the part played by each of the three main coronary arteries in the causation of death from recent myocardial infarction revealed and emphasised the lethal potentialities of occlusion of the anterior descending artery. Factors which could have been contributory were the size and anatomical distribution of this artery and the tendency for occlusive lesions to be located in its proximal 4 cm., as measured from the left coronary ostium.

Infarction of the posterior wall of the right ventricle was massive in three instances. Myocardial damage of lesser extent was also found here and/or at other sites in 15 cases. The relationship of muscle damage of the right ventricle to occlusions in the arteries of its supply has been described and discussed. It was shown that focal damage in the anterior wall of the right ventricle was a common accompaniment of anterior descending artery occlusion; that damage of the columnae carneae of the right ventricle was usually related to infarction of the interventricular septum; and that posterior wall damage was almost always the result of right coronary artery occlusion. In one instance posterior wall infarction followed anterior descending artery occlusion in the presence of old occlusion of the right coronary artery.

The relationship of right ventricular damage to right ventricular failure was examined. In only one instance did it seem justifiable to conclude that ischaemic damage of the right ventricle was the main cause of right ventricular failure. In other instances, infarction of the left ventricle, with pulmonary congestion consequent upon its failure, was evidently the precipitating cause of congestive cardiac failure. It was not possible to assess the part played by ischaemia of the right ventricle in these circumstances, considerable though it might nevertheless have been on occasion. It was however noted that severe ischaemic damage of the right ventricle could exist without failure of that chamber.

Some details relating to the coronary ostia have been presented and the importance of ostial stenosis is discussed. In no instance was there complete obliteration of the ostium itself. Ostial stenosis was the result of atherosclerosis of the sinus of Valsalva, and its occurrence bore only an inconstant relation to the severity or distribution of obliterative disease of the coronary arteries themselves. There was however a tendency in general for atherosclerotic narrowing of the coronary orifices to occur in cases of coronary artery disease.

In presentation of the data under consideration in this chapter it has been emphasised that they have been derived entirely from cases of severe coronary artery disease, and that the great majority of cases died as the direct or indirect result of coronary artery occlusion. In particular it may be noted that in every instance of recent myocardial infarction, the lesion under consideration was a lethal one. A different quantitative relationship between recent coronary artery occlusion and myocardial damage might well be expected could pathological examination be made in a series of cases recovering from recent myocardial infarction and dying from unrelated causes. Some indication of the degree of difference was inferred however from examination of old-standing lesions which had been survived.

# CHAPTER 6

## MYOCARDIAL DAMAGE

IN RELATION TO

## ANASTOMOTIC

## ENLARGEMENT



- b -

CHAPTER 6

THE EXTENT AND DISTRIBUTION OF MYOCARDIAL DAMAGE  
IN RELATION TO THE PATTERN OF ANASTOMOTIC ENLARGEMENT

Page No. 6:

INTRODUCTION	1
REGIONAL MYOCARDIAL INFARCTION	
GENERAL COMMENTS	5
SELECTED EXAMPLES	6
DEGREE OF PROTECTION AFFORDED BY ANASTOMOSES: processes which promote their enlargement and test their efficacy.	9
An Illustrative Case	12
COMMENT	13
INNER ZONAL INFARCTION	
GENERAL COMMENTS	15
SUMMARY OF FINDINGS IN 4 CASES OF "CHRONIC GENERALIZED MYOCARDIAL ISCHAEMIA".	16
DISTRIBUTION OF MYOCARDIAL LESIONS IN RELATION TO ADAPTIVE CHANGES IN THE CORONARY CIRCULATION.	22
Factors influencing the inner zonal distribution of focal ischaemic damage.	26
Note on pathogenesis of the focal nature of the necrotic lesions.	28
ISCHAEMIA, NOT ITS RELIEF, THE STIMULUS TO ANASTOMOTIC ENLARGEMENT.	30
RIGHT VENTRICLE IN GENERALIZED CARDIAC ISCHAEMIA	31

ctd. over...

- c -

THE EXTENT AND DISTRIBUTION OF MYOCARDIAL DAMAGE  
IN RELATION TO THE PATTERN OF ANASTOMOTIC ENLARGEMENT (ctd.)

Page No.6:

**INCIDENCE AND RECOGNITION OF CHRONIC GENERALIZED  
MYOCARDIAL ISCHAEMIA**

RECOGNITION OF THE INNER ZONAL PATTERN OF VASCULAR AND MYOCARDIAL CHANGES	31
CLINICAL RECOGNITION OF CHRONIC GENERALIZED MYOCARDIAL ISCHAEMIA	33
A COMMENT ON THE TERM "ACUTE CORONARY INSUFFICIENCY".	37
SURGICAL IMPLICATIONS	38
GENERALIZED CARDIAC ISCHAEMIA IN CONDITIONS OTHER THAN ADVANCED CORONARY ARTERY DISEASE	40
A Note on Syphilitic Coronary Ostial Stenosis	43
A Note on a Case of Aortic Stenosis	44
SUMMARY	45

---

NOTE: The arteriogram of the coronary arteries in the  
section shown in ———— is reproduced  
in Fig. 31.

Detail of distribution of the coronary arteries  
shown in the section is reproduced in the diagram

ILLUSTRATIONS

Page

DIAGRAM 6:1. Distribution of ischaemic myocardial damage and related anastomotic patterns.

6:4a

ARTERIOGRAMS, grouped at end of the chapter.  
Arteriograms of intact hearts, together with arteriograms of transventricular sections:

Normal coronary circulation. Fig. 6:1,1a

Examples of coronary artery disease. 6:2,2a  
6:3,3a  
6:4,4a  
6:5,5a  
6:6,6a,6b  
6:7,8  
6:9

Photomicrograph of section of interventricular septum. 6:10

Arteriogram of transventricular section: aortic stenosis. 6:11

---

NOTE: The arteriogram of the intact heart from which the section shown in Fig. 6:9 was taken, is to be found in Fig. 4:3.

Detail of distribution of the ischaemic myocardial damage in each case is to be found in the diagrams mounted with the case records and diagrams of the coronary circulation in Chapter 2.



## CHAPTER 6

THE EXTENT AND DISTRIBUTION OF MYOCARDIAL DAMAGE  
IN RELATION TO THE PATTERN OF ANASTOMOTIC ENLARGEMENT

---

INTRODUCTION

When sudden occlusion of a major coronary artery is accompanied by massive infarction in its territory, it does not stretch the imagination to trace a causal relationship between these events. To most observers - but not to all - it has seemed obvious that muscle death follows arterial occlusion and is caused by it. It has however been observed for a long time that the territorial extent of muscle damage usually falls short of the entire muscle mass anatomically dependent on the artery in question. This has been noted by many in the field of human pathology, and also following experimental coronary artery occlusion in lower animals (e.g. Hirsch and Spalteholz, 1907). It has also been confirmed in the present investigation.

Herrick (1912) cited the observations of several contemporaries who considered that this discrepancy between the extent of the lesion and the arterial territory distal to occlusion was evidence for the existence of collateral circulation in the heart of man.\* Even at that time there was confirmation that this was so. Notable contributions have been made to this topic by later workers, including Schlesinger (1938) and Zoll et al. (1951a.).

---

\*Chiari; Dock, 1896; Galli; Recklinghausen and Fujinami; Hirsch and Spalteholz, 1907.

An early appreciation of "coronary insufficiency".

"It has been long known, that although the heart is always full of blood, yet it cannot appropriate to its wants a single particle of fluid contained within its cavities. On the contrary, like every other part it has its peculiar vessels set apart for its nourishment. In health when we excite the muscular system to more energetic action than usual we increase the circulation in every part, so that to support its increased action the heart and every other part has its power augmented. If however we call into vigorous action a limb round which we have with a moderate degree of tightness tied a ligature we find that the member can only support its action for a very short time ; for now its supply of energy and its expenditure do not balance each other ; consequently, it soon, from a deficiency of nervous influence and arterial blood, fails and sinks into a state of quiescence. A heart, the coronary vessels of which are cartilaginous or ossified, is in nearly a similar condition ; it can like the limb girt with a moderately tight ligature discharge its functions so long as its action is moderate and equal. Increase however the action of the whole body and along with the rest that of the heart and you will soon see the truth of what has been said....."

Allan Burns , 1809.

Lecturer in Anatomy in the  
University of Glasgow.

In my own series I have found considerable correlation between the anatomical distribution of coronary arteries, the anastomotic development found at death, and the distribution of myocardial damage. It has been possible to form some opinion of the degree of protection which may have been afforded by a given degree of anastomotic enlargement. And yet there have been surprising departures from the general pattern. My own findings have impressed on me the complexity of the relationship between occlusion and muscle damage, so that no single factor, such as the degree of anastomotic enlargement, can satisfactorily explain all the variations which may occur. Nevertheless, the available collateral blood supply did seem to be the most potent single factor conditioning the extent of muscle damage which followed coronary artery occlusion.

Before considering the rôle of collateral blood supply in this connection, it may be worth while briefly to list the factors which in general may influence the balance between myocardial demands and coronary blood supply:-

(1) Related to flow volume

Anatomical importance of the occluded artery.

Site of occlusion in that artery.

Completeness of occlusion.

Immediately available collateral channels; their site, course and dimensions.

Patency of other coronary arteries, and proximal branches of the same artery.

Systematic blood pressure at the time of occlusion, and thereafter.

The unknown element of vascular spasm.

Encroachment on diastole by tachycardia.

(2) Quality of the blood

Anaemia.

Hypoxia, from respiratory insufficiency, high altitude,  
carbon monoxide poisoning.

Hypoglycaemia.

(3) Myocardial demand

Increased work as in effort, hypertension, aortic  
valvular disease.

Ventricular hypertrophy.

Tachycardia, as in excitement, exertion, arrhythmias,  
fevers.

Hyperthyroidism.

Against such a potentially complex background it may seem that few conclusions about any one factor could be derived from a relatively small series. And yet this does not in certain respects seem to be so. For, as already indicated, the adaptive changes found in the smaller branches of the coronary tree were outstanding. Attention will now be directed to their importance for the extent and distribution of muscle damage consequent on obliterative coronary artery disease.

If the cross sectional diagrams, which accompany the drawings of the coronary circulation in Chapter 2, are examined, it may be seen that a wide variation in the distribution of myocardial damage was found in the 25 cases of coronary artery disease. Damage in the territory distal to occlusion was sometimes extensive and sometimes slight. Commonly it was massive, but sub-total. Infarction in some instances was confluent and in others patchy.


I have found it helpful to distinguish between two types of myocardial



damage in regard to distribution: regional and zonal. Type examples of regional infarction are illustrated in Diagram 6:1, A and B, while C shows inner zonal necrosis.\* As might be expected, many gradations and combinations of these two forms of myocardial damage were found in the cases of this series. The distinction between them however is not merely descriptive. Evidence will be presented which relates the distribution of myocardial damage to the underlying changes in the coronary circulation.

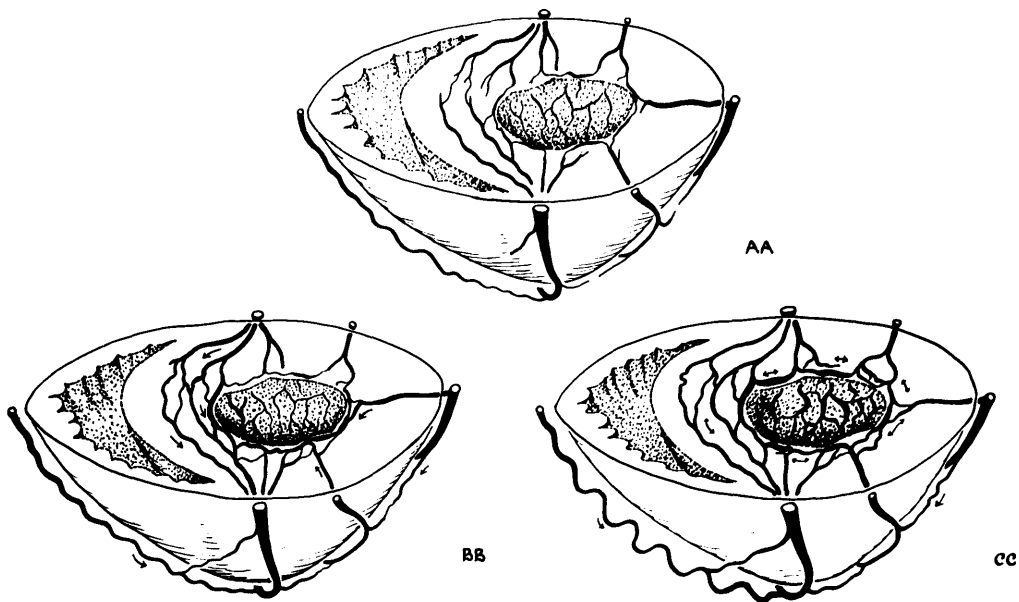
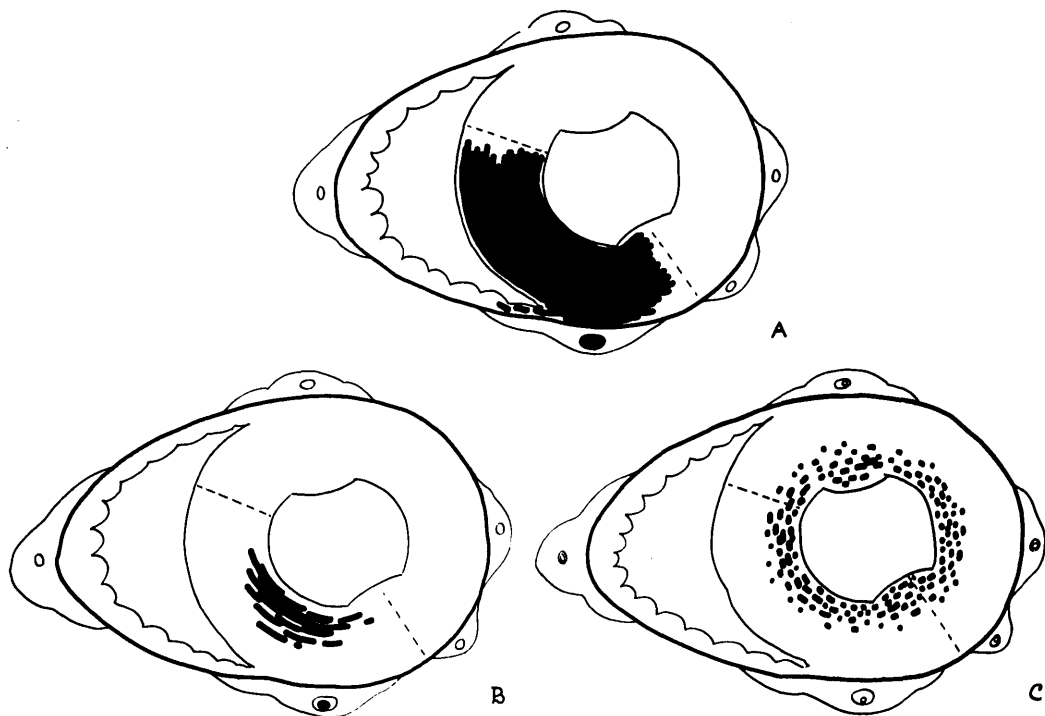
---

\* Neither in the present series, nor in published accounts, have I encountered necrosis in "zonal" distribution in the outer layers of the left ventricle.



DISTRIBUTION OF ISCHAEMIC MYOCARDIAL DAMAGE . (A,B,C) AND RELATED ANASTOMOTIC PATTERNS , (AA,BB,CC)

DIAGRAM 6:1



WPMF

A: Massive regional myocardial infarction, involving most of the territory of the occluded artery . B: Sub-total regional myocardial infarction . C: Inner zonal "ring" infarction of the left ventricle : focal necrosis. ~ ~ ~  
 AA: Anastomotic pattern, little or no departure from normal. BB: Local enlargement of anastomoses provides a measure of collateral blood supply from neighbouring unobstructed arteries. CC: Generalized enlargement of anastomoses promotes equitable distribution of diminished total blood supply to the heart. ~ ~ ~

## REGIONAL MYOCARDIAL INFARCTION

### General Comments

Infarction which is restricted to the territory of an occluded coronary artery I have described as "regional". (For the sake of greater precision, the term "ipse-regional" was introduced in Chapter 5.) Regional infarction is the common and familiar sequel to complete coronary occlusion, as from recent thrombosis or from experimental ligation. In Diagram 6:1 A, I have illustrated extensive regional myocardial damage such as might follow sudden occlusion of a major coronary artery (e.g. the anterior descending artery), where the other arteries were unobstructed. It will be seen that the damage occupies the greater part of the anatomical territory of the occluded artery, and is also restricted to it. Quite such extensive damage is probably uncommon and there was no instance of equal severity in my series.

As indicated in the previous chapter, the extent of infarction, when measured in circumferential fashion in the transventricular sections, sometimes reaches nearly the full width of the anatomical territory distal to occlusion; but usually there was a greater proportion of the muscle mass at risk which was spared. Especially was this the case in the superficial layers; and commonly the immediately subendocardial layer was not infarcted, at any rate extensively. At the margins of the infarct the damage was only occasionally clear-cut. Characteristically it was patchy, as has been recorded in the diagrams.

Examination of arteriograms did not suggest to me that the survival of islands of myocardium at the margins of massive infarcts was to be attributed to "over-lapping terminal vessels", each of which made contribution to normal

blood flow (cf. Wiggers, 1950). Nor am I prepared to attribute the survival of the subendocardial layers to Thebesian veins or arterioluminal communications (cf. Wearn, 1933, Grant and Viko, 1929), for I have not observed these structures. Whereas, I have observed anastomotic vessels at these sites and in sufficient number to provide an alternative explanation for this phenomenon. Generally speaking the smaller the extent of the infarct relative to the territory at risk, and the more patchy its distribution, the greater was the anastomotic development which I found in that region.

#### Selected examples

Fairly extensive recent infarction was found in cases 9, 13 and 16, as well as in several others. Death occurred 12 and 11 days and 2 months (?) respectively after its occurrence. As may be seen in the arteriograms of the transventricular sections (Fig. 4:43, 44 and 6:2a) and of the intact heart (case 16, Fig. 6:2), the anastomotic pattern in these cases showed little departure from normal. It seemed very likely that the extensive myocardial damage, with rupture in one of these instances, and the poor development of collateral circulation were related.

In case 20 (Fig. 6:3, 3a and 4:40) there was antero-septal infarction of 8 days' duration, with rupture of the interventricular septum. Despite a superficial communication of moderate size between the right coronary and anterior descending artery near the apex, and also local enlargement of some of the vessels of the subendocardial plexus in the anterior wall of the left ventricle, it is evident that the collateral blood flow to the distal territory of the anterior descending artery was insufficient to avert massive infarction. It was perhaps noteworthy that communications across the inter-

ventricular septum were poorly developed and that local enlargement of the subendocardial plexus communicated with the epicardial arteries only through vessels of much lesser calibre - and then mainly with a relatively small branch which was narrowed at its origin. There was also deep communication between the main stem and the main collateral branch of the anterior descending artery, which was, of course, of no functional value where the occlusion was proximal to both.

In Fig. 4:41 is seen the pattern of anastomoses in a case which had survived sub-total antero-septal myocardial infarction. Death was due to inter-current illness. It was not possible to determine, long after the event, what had been the anastomotic situation at the time of coronary artery occlusion. But it may be noted that the resultant infarct was patchy and was much lesser in extent than in the previous cases; and, at the time of death, very considerable enlargement of communicating channels could be seen linking the vessels in the affected area with those in the neighbouring territories. Communication had been effected through the anastomoses of the interventricular septum and subendocardial plexus. Much of this enlargement of anastomoses had doubtless occurred subsequent to occlusion - after the horse had bolted - and had therefore exerted no protective effect. The contribution to subsequent health, and even survival, may none the less have been of great importance. A similar situation may be seen in case 18 (Fig. 4:42 and Fig. 6:4) and in case 25 (Fig. 4:38). Sub-total infarction of restricted size, characteristically situated in the deeper layers of the left ventricle, is represented graphically in Diagram 6:1 B.

It is tantalising, and almost inescapable, that so much must depend on

indirect evidence when trying to form a general picture of the relationship between anastomotic development and the extent of myocardial infarction. It is clear that cases dying with acute massive cardiac infarction in my series have shown but little increase in the calibre of communicating vessels beyond the normal pattern. But it must be relatively uncommon to have the opportunity of comparing the anastomotic pattern with fresh myocardial infarction which, but for some unrelated intercurrent event, would have been survived. I did not have this opportunity. In all recent cases in my series death was attributable to myocardial infarction.

The anastomotic pattern obtaining at the time of infarction in lesions which had been survived must therefore remain a matter for conjecture. As indicated, commonly these infarcts were substantially smaller or more patchy than the fatal infarcts. There is however no means of knowing whether the collateral vessels were of normal or greater than normal calibre, when occlusion took place. It would however be in keeping with other findings had there already been enhancement of collateral circulation in these cases before complete coronary occlusion, and that the limitation of the extent of infarction be explained on this basis.

In this connection it may be noted that final occlusion in all cases (save case 1) had been preceded by some degree of antecedent narrowing of the artery, so that at the least the stage was set for enlargement of anastomotic channels, as discussed in Chapter 4. In my own series, wherever there was severe narrowing of old-standing there was also enlargement of anastomoses beyond the normal degree. Blumgart et al. (1950) demonstrated enlargement of anastomoses in the pig following experimental narrowing of a

coronary artery. Subsequent ligation of the artery after an interval was survived, and in some instances there was no evidence of myocardial infarction. Acute ligation of a coronary artery, where the circulation had not been prepared by its previous narrowing, resulted in myocardial infarction and death. From their series of 1200 human hearts, Blumgart et al. (1955) are able to cite but 3 instances of recent occlusion of coronary arteries, where there did not appear to have been antecedent narrowing. Only "slight, incompletely developed anastomoses were present distal to the acute occlusions." (Death occurred 5, 11 and 24 days respectively after the onset, and myocardial damage was massive, with rupture in one instance.)

The degree of protection afforded by anastomoses:  
the processes which promote their enlargement and  
and test their efficacy

From what has been said, it is reasonable to correlate the more extensive infarcts with insufficiently augmented collateral circulation. And it is tempting to relate the survival of a considerable proportion of the myocardium-at-risk to the increased collateral blood flow made possible by the enlarged anastomoses, eventually demonstrated post mortem. This possibility is made probable by the experimental evidence. I have indicated that in man the exact balance between anastomotic enlargement and survival of myocardium must remain uncertain. The longer the time which may elapse between coronary occlusion and death, the greater is the degree of uncertainty, on account of the anastomotic enlargement which takes place after, and as a result of, occlusion.

On the other hand, further evidence of the importance of enlarged anastomoses is sometimes afforded in another way. It is not uncommon for occlusion of a second coronary artery to provoke extension of the area of infarction in the territory of the artery first occluded. This phenomenon of "infarction at a distance" (Bean, 1937, Blumgart et al., 1941) or para-regional infarction (see Chapter 5) is susceptible to explanation in terms of collateral blood flow. Cases 22 and 24 are good examples. Where blood flow into a system of communicating channels is suddenly cut off, by obstruction to the artery which fed them, and this is followed by extension of the area of infarction in the territory of another artery, itself the seat of old-standing occlusion, there seems little doubt that the previous survival of myocardium-at-risk had depended upon collateral blood flow. And that the course of blood flow from the recently occluded artery had followed the enlarged anastomotic channels demonstrated after death. The only point seriously in doubt is the dimensions of those channels at the time of the first occlusion and their relation to the mass of muscle-tissue-at-risk, which had survived.

I have already discussed in some detail the influences under which coronary anastomoses enlarge following occlusion (Chapter 4) and have indicated the sound experimental evidence upon which the interpretation was supported. In naturally occurring coronary disease, however, the experimental situation is not closely mimicked. The anastomotic picture which I found at death was often the end-product of successive episodes of narrowing and occlusion in two or more arteries and the part played by each was a matter for speculation.

It seemed that there were examples of pathological narrowing of a coronary



artery of a degree insufficient to produce myocardial damage, or sufficient to produce only trivial damage, where the obstruction had nonetheless elicited enlargement of collateral channels. In this way the experimental situation in the first stage of partial ligation was simulated. On the other hand, when such narrowings were subsequently obliterated by thrombosis in the cases of my series, infarction was usually massive, even though sub-total. This is in contra-distinction to the experimental findings, already quoted, by Blumgart et al. (1950).

It has been suggested that if coronary artery narrowing should proceed episodically stage by stage, or perhaps gradually if this occurs, and if at each stage increase in collateral blood flow keep pace - though laggingly - with the reduction in flow volume through the normal route, then the final episode of thrombosis leading to obliteration of the remaining channel may cause little or no damage. The outcome of such events will depend upon the speed of their evolution. (The situation will, of course, remain favourable just so long as the other arteries are able to deliver a sufficient volume of blood to the channels of communication.) I imagine that such a train of events is possible. I do not however have in my series an instance of recent isolated occlusion of a single artery in which the final episode of thrombosis has not led to massive infarction, albeit sub-total, despite evidence of antecedent narrowing in one or more stages. But of course had it been otherwise the incident would probably have been survived.

In a number of instances nevertheless I found complete occlusions in much more complex setting where the related myocardial damage was only slight. It may well have been the case that at an earlier date a single artery had

been occluded, stage by stage, as outlined above; but for all one can be sure, the situation could equally have been complex from the outset in these instances (see cases 6, 8, 17, 19). In cases 1,3,18, 25, the extent of myocardial damage was only a small fraction of the territory of occluded arteries.

There was only one clear instance of complete occlusion of a main-stem coronary artery without some degree of ipse-regional myocardial damage. This was in case 2, in which the artery involved was an unusually small right coronary which took no part in the supply to the left ventricle.

An illustrative case: The following account of the sequence of events in case 22 may be not without interest, and it may be that a sequence of this order is more common than one which simulates progressive experimental ligation of a single artery. It would seem that early in the course of the disease there had been thrombotic narrowing of the right coronary artery with only trivial ipse-regional myocardial damage, represented at death by focal fibrosis in the posterior basal portion of the left ventricle. The time of this episode is not known, for it had evidently passed unnoticed clinically. 2 years before death the anterior descending artery was completely occluded by thrombosis. The resultant mass of myocardium which was infarcted represented only about  $1/3$  of the myocardium-at-risk, in the territory of the anterior descending artery distal to occlusion. By what mechanism had the remaining  $2/3$  of myocardium at risk been spared? Presumably the narrowing of the right coronary artery had provoked the enlargement of communications between the anterior descending artery and its own branches distal to occlusion. A supplementary flow of blood would then have flowed from

the anterior descending artery through these communicating channels up to the time, 2 years before death, that it was itself occluded. When this occurred the pressure gradients were reversed and would favour blood flow from the right coronary artery into the branches of the anterior descending artery distal to occlusion. In this way the extent of muscle damage was limited. That protection had indeed been provided by these communicating channels was later put to the proof. For, 2 years later, when the right coronary artery in turn was blocked by fresh thrombus, relief blood supply through anastomoses was withdrawn. Massive extension of infarction in the territory of the anterior descending artery ensued.

Indeed, the anterior, ipse-regional, infarction consequent on occlusion of the anterior descending artery in the first instance, was less widespread than the para-regional extension of infarction which followed right coronary artery occlusion. This is one of several instances in which help extended by an artery to a neighbour in trouble opened up channels of supply which in turn were used to avert disaster in its own time of need. Perhaps in this situation lies one of the few morals which may be pointed by a study of coronary artery disease!

#### Comment

As outlined in Chapter 4, the withdrawal of normal blood supply, as the result of coronary artery occlusion, provided the main stimulus for the enlargement of channels which communicate with other arteries. Accordingly, it need not occasion surprise that anastomotic development should, for the most part, have lagged behind the needs of the heart muscle. The advent

of vascular occlusion has commonly found the coronary circulation to a greater or lesser degree unprepared. Only exceptionally was the potential capacity of the immediately available anastomoses a sufficient substitute for blood supply through the normal channels. It is evident that anastomotic enlargement takes place as a response to, not as protection against, the effects of coronary artery obstruction. Successive episodes of narrowing at sufficiently long intervals of time may indeed allow a high degree of compensatory collateral circulation to develop before final occlusion. But all idea of protective preparation in anticipation of disaster must be abandoned if this aspect of the subject is to be seen in its true light.

particular form of infarction does not appear to be mentioned in this subject.

In this section, the features shared by these two categories respect of disease of the main coronary arteries, disease of smaller vessels of the coronary circulation, and the relation of myocardial damage will first be summarized and discussed. It will then be possible to relate my own findings to those of others and indicate their significance in the general picture of ischaemic heart disease.

INNER ZONAL INFARCTION

In contrast to regional infarction, less commonly ischaemic myocardial damage was widely distributed in the inner zone of the left ventricle, without being restricted to the territory of any one artery (see Diagram 6:1 C). This distribution of infarction has been recognised by a number of observers, and was found in pure form in four cases of this series. The distribution of the ischaemic lesions was itself sufficiently arresting. But the related adaptive changes demonstrated by arteriography in the coronary circulation were so striking that the features presented by these cases have been submitted for publication (Fulton, 1956). The anastomotic enlargement which I found in association with this form of myocardial damage was widespread and of extreme degree, and appeared to have conditioned its distribution. These changes in the coronary tree do not appear to have been described hitherto, and accordingly a satisfactory explanation for this particular form of infarction does not appear in the published work on this subject.

In this section, the features shared by these four cases, in respect of disease of the main coronary arteries, changes in the smaller vessels of the coronary circulation, and distribution of myocardial damage will first be summarised and discussed. I shall then try to relate my own findings to those of others and indicate their significance in the general picture of ischaemic heart disease.

Summary of findings in four cases exhibiting changes related to chronic generalized myocardial ischaemia.

Detail of the four cases appears in the case records in Chapter 2. Some features are summarized for reference in Tables 6:1,2. In these tables it may be seen that there was a close similarity in positive and negative findings, clinical and pathological.

Clinical features; In each case there was a long history of effort pain, and in two pain occurred also at rest. Although angina was severe in three cases, it is felt that the distinctive feature of this group was not so much the severity of the pain as the relentlessly progressive course, of long duration and uninterrupted by remissions. Certainly exacerbations did occur, but clinically recognised episodes of myocardial infarction were absent except as a terminal event. Terminally in three of the cases the clinical picture was that of acute coronary insufficiency, as described by Master et al., 1941. The remaining case died from intercurrent causes.

Pathological features: A characteristic feature was inner zonal ring distribution of ischaemic changes in the left ventricle. This distribution applied alike to myocardial damage and changes in the small vessels. A micro-section through the interventricular septum of case 19 is shown in Figure 6:10, in order to demonstrate the coincidence of vascular and fibrotic changes in the same picture.

Table 6:1

CLINICAL FEATURES OF 4 CASES OF CHRONIC GENERALIZED CARDIAC ISCHAEMIA				
Case No.	6	8	17	19
Age	67	65	73	70
Sex	F	M	F	F
General course:				
Duration of history in years.	13½	12½	10	10
Unremitting progress	+	+	+	+
Duration of usual attack in minutes.	2-3	2-3	"few"	"less than 10"
Frequency of attacks	20/day	19/day	"daily"	"frequent"
Longest attack apart from terminal episode.	30 min.	1 hour	"always short"	10 min.
Episodes of myocardial infarction recognised clinically.	-	-	-	-
Blood pressure (mm.Hg.)	138/84	200/100	155/75	180/140
The terminal illness:				
Its nature *	∅	A.C.I.	A.C.I.	A.C.I.
Precipitating factors established	-	-	?	-

Note 6:1

\* : ∅ - Mediastinitis following thyroidectomy for carcinoma of thyroid.

A.C.I.- "Acute coronary insufficiency".

? : There was post-mortem evidence of gastric carcinoma

Table 6:2

PATHOLOGICAL FEATURES IN 4 CASES OF GENERALIZED CARDIAC ISCHAEMIA				
Case No.	6	8	17	18
Age in years	67	65	73	70
Sex	F	M	F	F
Heart Weight in gm.	530	380	355	610
Left ventricular hypertrophy	+	-	-	+
Subendocardial fat increase	+++	++	++	++
<u>Myocardial damage (L.V.)</u>				
Massive regional infarction	-	-	-	-
Inner zonal focal necrosis	+	+	+++	+++
Inner zonal focal fibrosis	+++	+++	+++	+++
<u>Coronary arteries</u>				
Balance	R=L	L+	R+	R+
Ostial diameter in mm.				
Right	1.5	1	1	1.5
Left	2	2	2	2
Recent occlusions	-	-	-	-
Old Occlusions *				
Main stem:				
Complete (at death)	(I) 1	-	-	-
Canalised	(II) 1	1	2	2
Severe narrowing	(III) 2	1	2	2
Large branch	(IV) 1	3	2	-
Small branch	(V) 2	6	3	3

Note 6:2

\* For criteria, see Chapter 5.



In each case there was advanced coronary artery disease and some degree of stenosis of both coronary orifices. Ostial stenosis was severe in two instances. (It may be noted in this connection that the blood Wassermann reaction was negative in life, and that there was no post-mortem evidence of syphilitic involvement of the aorta or aortic valves.)

Between the four cases there were 14 occlusions of main-stem coronary arteries\*. Only 1 of these was still complete at death (Grade I occlusion). 6 were indisputable examples of canalised occlusions and functionally must still have been virtually complete (Grade II occlusions). 7 were probably examples of canalised occlusions, but it was not certain that they had in fact been previously complete (Grade III occlusions).

In addition, there were 6 instances of occlusion of important branches (2nd division arteries, Grade IV occlusions) and 14 instances of occlusion of small branches (Grade V occlusions).

Apart from the occlusions recorded above, there was widespread atherosclerotic disease which had brought about distortion and narrowing of the arterial lumen at many points probably to a functionally important degree, yet insufficient for classification as occlusions, according to the criteria defined in Chapter 5.

---

\* The criteria for the classification of occlusions have been uniformly applied throughout this thesis and are detailed in Chapter 5. These criteria had not been adopted at the time the article referred to was submitted for publication in the British Heart Journal, 1956. Accordingly, a numerical discrepancy may be noted between the data presented now and at that time.

All occlusions were of old standing. There was no instance of recent occlusion either of large or of small coronary arteries. This point is emphasised, for it contrasts with the occurrence of recent myocardial necrosis.

Recent myocardial infarction could be recognised on gross inspection in 2 cases (17 and 19). In these it took the form of multiple focal areas of necrosis measuring 1-3 mm. in diameter, which in aggregate formed a ring of infarction as seen in cross section throughout the inner shell of the left ventricle. The immediately subendocardial layer was not affected. In the other two cases, isolated areas of focal necrosis in inner zonal distribution were found on histological examination. In all cases there was extensive fibrosis, which was likewise distributed throughout the inner zone of the left ventricle, without respect for the boundaries of arterial territories. In two cases there was indeed a more closely packed texture of fibrosis in the territory of a single occluded artery; but in no case was there evidence of previous massive myocardial infarction (see Diagrams, Chapter 2).

No precipitating factor for the development of acute necrosis was found. Only in case 6 was death directly attributable, so far as is known, to a factor other than coronary disease, although in case 17 cerebro-vascular disease and the debilitating effects of gastric carcinoma doubtless had some influence.

Intimal haemorrhages were found in two cases but had not caused significant narrowing of the lumen. All were of small size and their presence was unaccompanied by thrombosis.

Two small shallow mural thrombi were found in the right coronary artery in case 17, but had not made any material encroachment on the lumen, and could

scarcely have exerted any haemodynamic influence.

In no case was there valvular disease or congenital abnormality.

As might be expected from what has already been said about the pathogenesis of anastomotic enlargement, the presence of long standing severe obliterative coronary artery disease had provoked a great increase in the dimensions of arterial communications in the four hearts. Enlarged anastomoses were to be found at all parts: in the atria, the anterior wall of the right ventricle and in the region of the apex and atrioventricular groove, and, of particular note, in the interventricular septum and inner zone of the left ventricle. The characteristic and outstanding changes in these cases of chronic generalized ischaemia were seen in the deep vessels.

In the arteriograms of the unopened heart, as may be exemplified in Fig.6:5, a great increase in the "vascular density" of the central portion of the left ventricle was seen. This appearance contrasted with arteriograms of the normal coronary circulation (e.g. Fig. 6:1 ). (It should be recalled that the method of radiography almost eliminated tissue shadow, so that the central density is entirely attributable to the increase in vascular structures.) When the paired arteriograms of the unopened hearts were examined stereoscopically it was evident that the dense central area was composed of a network of dilated intercommunicating channels which occupied the entire inner zone of the left ventricle. The position of this network was also clearly demonstrated in the arteriograms of the transventricular sections. (See Fig. 6:5a; 6a,b;8;9, and 4:39,45,46. Compare with normal appearances in Fig. 6:1a and 4:29.) The manner in which this inner zonal network of dilated vessels has arisen from the subendocardial plexus of the left ventricle has already been discussed in Chapter 4.

The distribution of myocardial lesions in relation  
to adaptive changes in the coronary circulation.

In view of narrowing of the coronary ostia together with widespread obliterative disease of the main coronary arteries and branches, it would seem inevitable that cardiac ischaemia must have been generalized in the four cases described. Moreover it may be assumed that severe generalized ischaemia had been reached gradually, through successive episodes of obliterative change in the epicardial arteries, at widely separated intervals. At no time in the course of the disease had the severity of ischaemia in the territory of an obstructed coronary artery been sufficient to cause massive regional ischaemia. It would be in sequence with other findings had adaptive changes in the small vessels lagged only slightly behind the progress of obliterative disease of the main stems, so that stage by stage the effects of arterial occlusion were mitigated by augmented collateral blood flow. Such a process evidently demands a long period of time and it may be noted that in these cases the histories of clinical symptoms were of 10 years or more.

Widespread patchy fibrosis in the entire inner shell of the left ventricle almost certainly represented the late result of several, perhaps many, episodes of focal necrosis at an earlier date. (Aschoff, 1906, Appelbaum and Nicolson, 1935.) Its occurrence also indicated that complete protection against the effects of coronary artery occlusion had not been provided by the volume of collateral blood flow immediately available.

In circumstances where all major branches of the coronary arteries had been affected by disease in the fashion found in these cases, and where widespread enlargement of anastomoses was likewise of advanced degree, it was evident that all semblance to the original coronary "tree" had been lost. The tree had been

replaced by a network. It is submitted that the conversion of the coronary tree into a network provided the anatomical basis upon which structural myocardial damage was largely prevented or delayed: and that it also conditioned the focal character and inner zonal distribution of myocardial necrosis when it occurred. These points will be considered severally in more detail.

With the replacement of the coronary tree by a plexus of widely intercommunicating channels, the original main stems had lost much of their importance for regional blood supply. Occlusion had occurred without massive local infarction. Indeed, it seemed that in these circumstances regional infarction became anatomically impossible. This was attributable to the redistribution of blood within the left ventricle through large calibre anastomoses. The persistence and progressive increase in severity of anginal symptoms bore witness to the fact that adaptive changes within the coronary circulation had failed to alleviate myocardial ischaemia. It is clear that the fault lay not with distribution so much as with total inflow of blood to the heart muscle.

In these circumstances, any factor which might make for reduction in the volume or quality of blood entering the coronary circulation, or for increase in the demands of the myocardium, would bring the heart muscle nearer to the precipice of irreversible ischaemic change. It would be understandable if this condition were reached first by areas in which the demands were greatest or where the circulatory conditions were least favourable. Observation has shown that the areas to suffer first consisted of multiple focal points in the deeper zone of the left ventricle. Not only is this zone remotely placed from the source of blood supply, but also during systole resistance to entry of blood into the walls of the left ventricle must increase as the endocardial surface

is approached.

Inner zonal distribution of focal ischaemic lesions has been noted by a number of observers. The explanations for its occurrence differ widely.

The distribution of focal necrotic or fibrotic lesions in the deeper layers of the left ventricle has been alluded to by a number of authors, who have included Barnes and Ball (1932), Büchner et al. (1935), Opitz (1935) and Holzmann (1937), (cited Büchner, 1939), Friedberg and Horn (1939), Master et al. (1941), Pirani and Schlichter (1946), Freedberg et al. (1948), Horn et al. (1950), Chiche et al. (1953), and others.

"The lesions .. have been restricted for the most part to the inner third of the wall of the left ventricle. Occasionally in the more severely affected hearts, additional scattered foci were found within the middle third of the left ventricular wall, although never to the same degree as that encountered just beneath the endocardium. Involvement of the pericardium or subepicardial muscle was not observed. Similarly a thin strip of subendocardial muscle was spared, unless this could be ascribed to antecedent disease .... The lesions, furthermore, have not necessarily been confined to the area of supply of the most severely narrowed vessel.. That the extent of involvement of the heart is quite variable is indicated by the findings of seven instances of grossly visible necrosis of the major portion of the left ventricular inner shell."  
(Horn et al., 1950).

This description is quoted in detail, because it is representative of the descriptions given by other observers, and is in entire agreement with the findings in the present series. Except for the case reported by Pirani and Schlichter (1946), I have noted no mention of ostial stenosis, in addition to the multiple narrowings and occlusions which underlay the ischaemic changes reported.

Most authors have stressed the relationship between widespread severe

coronary artery disease and the restriction of ischaemic damage to the inner layers of the left ventricle. Thus Barnes and Ball wrote:

"In an occasional instance, chronic infarction is diffuse, tends to exist in the form of subendocardial fibrosis and involves the entire left ventricle more or less completely. It is not usual for acute or healed acute infarction to be present in a left ventricle which is the seat of diffuse fibrosis of the chronic type". (Barnes and Ball, 1932).

The last statement correlates with my own observation that regional infarction becomes anatomically impossible where the coronary circulation has become a network of widely intercommunicating channels.

It was of much interest to read the observations on this topic by the several authors quoted above and to realise that in my own arteriograms was revealed the basis of arterial change which could coordinate and give meaning to their findings. It must be pointed out that arteriography was not part of any of the investigations to which I have referred. Accordingly no correlation of ischaemic changes and vascular pattern could be made. Indeed, I have not found published description of the vascular pattern which I have described.

It is however of interest that my conclusions on this point were anticipated by Chiche et al. (1953), although these authors did not carry out injection studies themselves. Evidently their imagination was caught by reference to enlargement of some vessels of the subendocardial plexus by Whitten (1930) (who employed a corrosion method, thereby destroying the possibility of correlation with the myocardial changes). Chiche and co-authors correlated the possibility of wide arborisations in this plexus with the distribution of ischaemic lesions in the deeper layers of the left ventricle, concluding "les effets d'une obliteration tronculaire seraient compensées par le reseau vasculaire sous-endocardique".

For lack of a satisfactory explanation in terms of vascular changes in the depths of the left ventricle, various explanations for the occurrence of inner zonal infarction have been put forward. Some of these will now be considered.

Factors influencing the inner zonal distribution of focal ischaemic damage: The most obvious factor conditioning the inner zonal distribution of focal necrosis in acute coronary insufficiency is remoteness from blood supply. This was the explanation that first appealed to Friedberg and Horn (1939). Other explanations offered include:-

- a. As the result of in-vivo perfusion studies following ligation of a coronary artery, it was shown that the filling of an ischaemic area from collaterals took place in concentric fashion and the sub-endocardial layer was found to have a poorer collateral circulation than the epicardial. (Prinzmetal et al., 1948, used as explanation by Horn et al., 1950.)
- b. The gradient of pressure diminishes from the inner to the outer layers of the left ventricle during systole (Johnson and Di Palma, 1939) and accordingly the inner layers are more susceptible to oxygen deprivation (Horn et al., 1950).
- c. "The relatively greater degree of work imposed upon the papillary muscles by systolic contraction of the ventricle plus tension exerted upon the mitral valve appears to be an additional reason for increased nutritional demand". (Horn et al., 1948)

The first of these explanations is not acceptable in the present context



on at least three grounds - that the experiments were acute, the subjects were normal, and that they were dogs.

1. Acute observations made on normal hearts obviously cannot be directly applied to those cases of long-standing severe coronary insufficiency, in which the whole circulatory anatomy of the heart has been distorted in fashion reported here, as the result of pathological influences which have been operating for many years.

2. The observations of Spalteholz (1924) suggest that a superficial anastomotic network is characteristically found over the left ventricle of the canine heart. Injection studies by Bobb et al. (1948) likewise indicate that anastomotic connections are mainly in the epicardial region (Gregg, 1950). A similar network on the surface of the left ventricle of man was not found in the present investigation, neither in normal nor in diseased hearts.

In regard to the second explanation, the findings of Johnson and Di Palma (1939) on the subject of intramyocardial pressure have already been discussed (page 4 : 76). Their demonstration of the pressure relations within the myocardium of the left ventricle and in the aorta indicates that a high intramural pressure must oppose entry of blood into the deeper layers during systole, and may well reverse the flow. For a period during (and immediately after) cardiac contraction, therefore, the inner zone of the left ventricle must be at a disadvantage in respect of blood supply, compared to the outer layers. It should be noted that in this important paper, these authors do not speculate about the metabolic requirements of the deeper layers, for such was outwith the scope of their experiment. The speculation is on the part of those who have quoted them. There seem to me no grounds for contending that

the metabolic requirements of the deeper layers of the left ventricle differ in any material respect from those of the superficial layers. From Johnson and Di Palma's data, there is no reason to suppose that the increased pressure found in the deeper layers is other than the simple summation of pressures derived from all layers of the left ventricle. The circulatory problems of satisfying these metabolic requirements is another matter.

In regard to the third point, it may be commented that, of all left ventricular structures, the papillary muscles lie farthest from their epicardial source of blood. The occurrence of ischaemic change in the papillary muscles, therefore, is not out of accord with their relative remoteness from supply. Moreover, lying as it were within the ventricular cavity, the full force of systolic ventricular cavity pressure will compress these structures from all sides, and so offer maximum opposition to coronary blood flow, during that phase of the cardiac cycle.

A note on the pathogenesis of the focal nature of the necrotic lesions:

It is popularly supposed that small areas of myocardial infarction result from occlusion of small branches of the coronary arteries. This is probably a misconception, for which I have found little support in the relevant literature. I attempted to find some correlation between the position of areas of focal necrosis and the anatomy of the small vessels in their neighbourhood. I thought it likely that such areas would lie at points farthest from arterial twigs. No correlation, however, was to be established.

Thick sections (c.4 mm.) of the left ventricle in cases 17 and 19 were cleared in glycerine and viewed under the dissecting microscope, at approximately x 20 magnification. Areas of recent necrosis showed a greyish

appearance distinct from the pale brown of the rest of the myocardium. In some instances an area of focal necrosis was indeed situated in the territory between terminal arterial twigs, as I supposed might be the case. In others, small arteries with their terminal arteriolar branches were seen to pass right through the necrotic lesions.

In no instance was occlusion of a small branch found in association with an area of necrosis. The concept of "twig infarcts" was not supported by the findings in these cases. The conclusion was reached that the focal nature of the lesions was the product of a relationship between myocardial requirements and available blood supply which was more subtle than could be explained solely on a basis of the intimate anatomy of terminal arterial supply. It seemed likely that the degree of ischaemia prevailing in the inner zone of the left ventricle was close to a level critical for the survival of the muscle cells. Under circumstances which temporarily upset the balance between supply and demand unfavourably, some groups of muscle fibres succumbed while others recovered.

In regional infarction following occlusion of a major artery, on the other hand, it would seem that the degree of ischaemia in the central parts of its territory must exceed by far this critical level, so that necrosis overtakes the population of muscle fibres en masse, and not singly or in isolated groups.

"Small myocardial scars are usually to be attributed to occlusion of small branches of the coronary arteries." Gould, 1953.

---

Small infarcts were related to sclerosis of small vessels without occlusion of large coronary arteries, in 7 cases described by Barboni and Tumiotto, 1954. Similar statement was made by Campbell, 1929.

Ischaemia, not its relief, the stimulus to anastomotic enlargement

It is sometimes suggested that the development of increased arterial anastomosis in the coronary circulation is a compensatory change (e.g. Zoll et al., 1951a) - which indeed it is. Conversely, it has been argued (in Chapter 4) that the beneficial effects of anastomotic enlargement are purely fortuitous. A favourable outcome does not in fact prove a causal relationship between it and the processes conditioning that enlargement. This point has been particularly well illustrated by the four cases under consideration. They have provided a clear demonstration that vascular "adaptations" in the form of expanded anastomoses can occur as pathological sequelae of ischaemia, regardless of the ability of neighbouring arteries to bring relief. Indeed, the greatest complexity of collateral development was found in these very hearts in which enlarged anastomoses had failed to relieve ischaemia; where, so to speak, each major coronary artery had been so compromised by disease that it could barely carry sufficient blood for the basic needs of its own territory, and was therefore in no condition to afford charity for its neighbours. In these circumstances, where inflow of blood to the whole organ had been reduced at source, internal rearrangement of channels of supply could at the best achieve only a more equitable distribution of poverty. While complete starvation occurred in no one region, all were hungry all the time. This hunger had its outward expression in angina. In times of added stress, the weakest or the least favourably situated areas succumbed first. These lay farthest from the source of blood supply, in those layers of the left ventricle to which delivery of blood is impeded to the greatest extent by extravascular compression during systole.

The right ventricle in generalised ischaemia

The presence of widespread anastomoses throughout the circulation of the right ventricle and the presence of fibrosis and fatty change provided evidence that the right ventricle had also been subjected to ischaemia. Presumably infarction was less likely to affect the right ventricle than the left in generalised ischaemia, for the same reasons that the right ventricle is usually spared in ischaemic heart disease. However, in cases 3 and 4 of this series isolated patchy areas of necrosis were found in the right ventricle.

INCIDENCE AND RECOGNITION OF CHRONIC GENERALISED  
MYOCARDIAL ISCHAEMIA

Recognition of the inner zonal pattern of vascular  
and myocardial changes

(1) Descriptions of focal ischaemic myocardial damage and its association with "acute coronary insufficiency" are far less prominent in the relevant literature than are accounts of massive myocardial infarction, apparently on a regional basis. Accordingly the occurrence of 4 cases in a series of 25 raises the possibility that the method of examination may have had some influence on their discovery. The use of cross sections of the ventricles, in contrast to the more usual post-mortem technique, certainly makes the distribution of changes more readily recognised.

(2) The vascular pattern of inner zonal anastomotic enlargement likewise has not received the mention elsewhere that might otherwise have been expected were the condition common. Here again there are cogent reasons why it may not have been evident in most of the studies based on

injection techniques. Firstly, stereo-radiography of the intact heart and of sections is not part of the routine of the Schlesinger technique, which has been so widely adopted in recent years for the investigation of the heart in disease. Secondly, the technique of radiography used in this investigation largely eliminated the left ventricular tissue density that has hitherto obscured the vascular pattern in the results obtained by other workers. The true vascular density revealed by my method is more easily recognised and interpreted. Thirdly, the inner zonal distribution cannot be recognised in a single two-dimensional arteriogram of the "unrolled" heart. Even with magnified stereo-viewing, this distribution might have escaped notice had attention not been drawn to it otherwise. Its recognition was favoured by the use of cross sections of the ventricles. Finally, defective filling by injection mass is encountered most readily in the subendocardial anastomoses.

These factors combined make it reasonable to suppose that the vascular pattern is of more common occurrence than the absence of published description would suggest.

The clinical recognition of Chronic Generalized  
Myocardial Ischaemia

On the basis of such a small series it would be incautious to draw any definite conclusions about the recognition of this condition during life. Certain points, however, may be made with a view to their substantiation or rejection with the experience of greater numbers of cases.

The first point to be stressed is the duration of the disease. This can of course be judged clinically only from the onset of symptoms. In a large series of cases which had survived the first month from the first ischaemic symptoms, approximately half died during the first 2 years, irrespective of the occurrence of myocardial infarction (Zoll et al., 1951a).<sup>\*</sup> Death in these cases has probably been the outcome of regional infarction, promoted by occlusion of major coronary arteries in hearts whose anastomotic development had not been advanced. After the first few years the curve of mortality rate flattens out (Zoll et al., 1951a). As the years go by, an increasing proportion of cases, which have never shown evidence of massive regional infarction despite continuance of ischaemic symptoms, will presumably belong to the group of chronic generalized myocardial ischaemia.

The more gradual and progressive the severity and frequency of effort pain, or at any rate of symptoms related to left ventricular ischaemia, the

<sup>\*</sup> A somewhat longer period was recorded by Tulloch (1950). A more favourable outlook for the survivors of the first 2 months from the onset is afforded by the series of Cole et al. (1954) in which 2/3 of the cases survived 5 years.

Block et al. (cited Wood, 1956) quote a mortality rate for angina pectoris of 15% in the first year and 9% per annum thereafter.

Age as a factor in prognosis has been clearly shown by the observations of Peel, 1955 and others.

more closely will cases correspond to the syndrome described. Episodes of regional myocardial infarction, unless of minor extent and occurring early in the clinical course, will make diagnosis of the condition in life the less likely. As each year passes without remission in the severity of angina, the greater will be the likelihood of the anastomotic pattern of myocardial ischaemia reaching its full, generalized development.

It is felt that the progressive, unremitting character of the anginal history has more significance in this context than the actual severity of effort pain. Indeed it is not without possibility that chronic generalized cardiac ischaemia may exist, with the production of the typical pattern of vascular adaptation without pain being experienced at all. After all, a proportion of cases (5 out of 25 in this series) suffer myocardial infarction without the accompaniment of pain; and others whose terminal illness was heralded by pain may have clear pathological evidence of earlier episodes of myocardial damage and coronary occlusion which had passed unnoticed. Clinical manifestation, or at any rate recognition, of ischaemic disease might in such circumstances take the form of a first and fatal episode of acute coronary insufficiency with focal necrosis.

The present series includes a case (No. 10) in which there was a history of breathlessness on exertion for 8 years, mild anginal symptoms for 6 months, and a sudden severe attack of sternal pain. Death occurred 2 days later from extensive inner zonal ring infarction of the left ventricle. There was bilateral ostial stenosis (1.5 mm. in diameter) and a severe degree of widespread atherosclerotic disease of the coronary arteries with occlusions.



Unfortunately during injection extensive leakage into the lumen of the left ventricle took place\* and the resulting arteriograms were somewhat unsatisfactory. The inner zonal pattern of enlarged intercommunicating vessels could be made out visually, although the specimens are not suitable for photographic reproduction. The severity and extent of coronary artery disease was more in keeping with a history of 8 years rather than of a few months. There was no recent change in the coronary arteries. Terminal myocardial damage was due to acute coronary insufficiency precipitated by diabetic ketosis.

Master et al. (1941) have stressed the importance of precipitating factors in the clinical recognition of infarction due to acute coronary insufficiency without recent change in the lumen of the coronary arteries, as distinct from infarction due to acute coronary artery occlusion.

"The diagnosis .... should suggest itself when an episode of severe precordial pain, shock or heart failure is associated with some factor capable of increasing the work of the heart or decreasing the coronary flow. The chief of these precipitating factors are: shock following operation, pulmonary embolism or acute haemorrhage; marked tachycardia or bradycardia; impaired oxygen capacity of the blood, as in acute anaemia; aortic stenosis or insufficiency; and heart failure associated with slowing of the circulation."

Master et al. 1941.

These authors also describe electrocardiographic criteria for the distinction of acute coronary insufficiency from acute coronary occlusion (i.e. of inner zonal from regional myocardial damage). In the present series the four cases under review had electrocardiographic changes in keeping with

---

\* Presumably through rupture of a dilated subendocardial vessel, but the source of leakage was never satisfactorily determined.



A comment on the term "Acute Coronary Insufficiency"

As noted above, ischaemic symptoms in the four cases under consideration corresponded clinically to the description of "acute coronary insufficiency". The question may be raised whether most cases of so-called "acute" coronary insufficiency, resulting primarily from coronary atherosclerosis, would also come into the category of "chronic generalized myocardial ischaemia, with adaptive changes in the deep vessels of the left ventricle as described. Absence of investigation of the vascular pattern in the published instances of myocardial damage due to acute coronary insufficiency to which I have referred prevents an answer being given to this question. (Cases 2, 3 and 4 cited by Zoll et al. (1951 (a) ) were investigated by arteriography but there is no indication of the exact distribution of myocardial and small vessel changes.)

It is clear that acute coronary insufficiency could be a misleading term when applied to such cases; for it would seem likely that of all the manifestations of coronary artery disease, that of "acute" coronary insufficiency has the most chronic pathological basis. It is an acute complication of a chronic condition, and one which can develop without acute arterial changes to precipitate it.

These remarks do not of course apply to acute coronary insufficiency arising from causes other than widespread coronary artery disease, such as pulmonary embolism (Dack et al. 1949), carbon monoxide poisoning (Büchner, 1939), anaemia (Büchner, 1939; Master et al., 1941), low atmospheric pressure (Highman and Altland, 1949), acute blood loss (Master et al., 1941, 1950).

It is quite possible that the majority, if not all, cases of acute coronary



insufficiency, when primarily attributable to advanced coronary artery disease, develop this clinico-pathological syndrome on a basis of the vascular pattern which I have presented. This point seems to demand further observation.

### Surgical Implications

The situation would seem to invite surgical exploitation. With channels for the distribution of blood to all parts of the left ventricle already prepared, all that would seem to be awaited is some means of introducing a new source of blood supply. An attractive feature of this form of anastomotic development is that it would probably matter little at which point relief blood supply entered the network.

The problem of bringing an extracardiac artery into anastomotic communication with the deep vessels of the myocardium has been partially overcome. Vineberg and Miller (1953) reported the preliminary results of implantation of the internal mammary artery into the wall of the canine left ventricle about  $1/3$  of the distance from the endocardial surface. Evidently some of these grafts "took" and communication was established. Unfortunately injection studies seem to have been of poor quality; and there was no proof that the blood flowing in the internal mammary artery was entering and not merely escaping from the heart.\*

One would suppose that prior enlargement of the deep plexus, and the pressure gradients existing in cases of generalized cardiac

---

\* Forward flow in the internal mammary artery implanted into the dog heart is reported by Vineberg et al. 1955 and by Pilcher, 1959.

ischaemia with severe coronary artery disease, would favour blood flow into the heart from an extracardiac source, to a greater extent than would be found in the normal heart of the dog. Detailed information about the communications which might develop in the human heart in disease is still awaited at the time of writing. The results however of a  $2\frac{1}{2}$ -4 year follow-up of 24 survivors of 28 operations in man are clinically encouraging. (Vineberg et al., 1955.)

In the setting of advanced coronary artery disease of long standing, the introduction of new blood supply through the implantation of an artery of fair size directly into the depths of the myocardium appeals to me as a procedure of greater potentiality than the various methods of surface grafting or abrasion (e.g. Beck et al., 1935, O'Shaughnessy, 1936, Torchiana and Weisz, 1956). It is unfortunate that there is no readily available artery for this purpose shorter and of larger calibre than the internal mammary artery. In a larger artery the pressure would be higher, and the arrival of the systolic pulse wave earlier. I imagine that both these factors would be pertinent to the performance of a substitute coronary artery.

See also  $6\frac{1}{2}$ -6 year follow-up of 75 survivors of 88 operations, Vineberg and Walker, 1957.

GENERALIZED CARDIAC ISCHAEMIA IN CONDITIONS OTHER THAN  
ADVANCED CORONARY ARTERY DISEASE.

The occurrence of characteristic changes in the small vessels in cases of generalized ischaemia, due to widespread obliterative coronary artery disease, led me to examine the control series for evidence of similar changes where cardiac ischaemia might have been suspected; and where it could not have been other than generalized. The most likely cases to yield information on this point seemed to be those of aortic stenosis.

In aortic stenosis, overt myocardial ischaemia is not uncommon, provoking severe angina and sometimes deep zonal fibrosis. The occurrence of coronary insufficiency in aortic stenosis is discussed by Contratto and Levine (1937) and coronary blood flow in aortic stenosis and insufficiency by Green (1936).

The haemodynamic disturbance in aortic stenosis might be likened to that of bilateral ostial stenosis in the presence of marked left ventricular hypertrophy. In these circumstances I felt that the vascular pattern in the depths of the left ventricle might be not unlike that found in chronic generalized cardiac ischaemia due to ostial stenosis and disease of the coronary arteries. In fact this was so, although the changes were not quite so extreme. In Fig. 6 : 11 may be seen a transventricular section in a case of severe aortic stenosis. (Details of this case are appended below.)

The occurrence of ischaemia in the left ventricle in aortic stenosis is readily understood, on grounds of the disparity which must

exist between the intraventricular and coronary artery pressures. The mechanism by which the inner zonal anastomoses enlarged to the degree found is not so obvious. As already discussed in Chapter 4 myocardial ischaemia may provoke enlargement of the small vessels through two mechanisms: hypoxia and altered conditions of blood flow. The effects of ventricular contraction on the conditions of blood flow in the deeper layers of the left ventricle were considered at length, with the conclusion that the ebb-and-flow movement of blood in the sub-endocardial network contributed to the enlargement of the vessels which composed it. In aortic stenosis both factors may be operating - passive and dynamic. I can visualise a great exaggeration of normal conditions of coronary blood flow in the wall of the left ventricle in this condition. Powerful systolic contraction must blanch the greater thickness of the ventricular wall, as the arteries within it are compressed with great force, while the opposing coronary artery pressure is feeble by comparison. It would be in keeping with my other findings were dynamic factors of blood flow so engendered to exert a potent influence on the enlargement of the subendocardial plexus in aortic stenosis.

The question also arises, did hypertrophy of the left ventricle itself contribute to the changes in the small vessels? In this connection it was observed that the deep plexus in the left ventricle was exaggerated in all conditions which produced hypertrophy of that chamber. Hypertrophy of the right ventricle was likewise accompanied by increase in the prominence of its subendocardial plexus. Examples of transventricular sections in the presence of ventricular hypertrophy are shown in Figs. 6 : 11 and 4 : 47. Again it was not clear whether



the enlargement of deep anastomoses was the product of relative anoxia, increase in the dynamic stresses accompanying and causing hypertrophy, or simply an increase in size of vessels consonant with the increase in bulk of muscle. Perhaps all factors mentioned made their contribution. The concept of relative ischaemia of hypertrophied myocardium is supported by Harrison et al. (1932), Fishberg (1940) and Wearn (1941), and denied by Harrison and Wood (1949). Smith (1957) confirmed that the numerical ratio between capillaries and muscle fibres remains unchanged in hypertrophy of the dog heart, as described in man by Wearn (1928, 1941).

Returning for the moment to the four cases under consideration earlier in this chapter, the first case (no.6) had left ventricular hypertrophy of unexplained cause (other than ischaemic disease) for all records of blood pressure were normal. Cases 8 and 17 showed no ventricular hypertrophy although in the first of these the blood pressure was elevated (200/100 mm. Hg.). Case 19 had established hypertension and considerable left ventricular hypertrophy. It was felt that in these cases of advanced coronary artery disease left ventricular hypertrophy probably exaggerated the vascular changes in two, but that hypertrophy was not essential to their production.

In regard to anaemia I have little comment to make from the evidence of my own series. Zoll et al. (1951b) and Zoll and Norman (1952) reported increase in the incidence of anastomoses (of a size demonstrable by the Schlesinger technique) in the presence of anaemia, in human and porcine hearts respectively; but inner zonal distribution

of the changes was not noted.

Of the control cases, only the two with aortic stenosis showed an exaggeration of the subendocardial vessels to a degree comparable to that found in coronary artery disease. It is tempting to relate this finding to the feature which aortic stenosis and coronary artery disease have in common and which is not shared by the other conditions listed in Table 2:4 - namely, an upset in the dynamic conditions of blood flow in the wall of the left ventricle, consequent on a disparity between ventricular and coronary artery pressures.

#### A note on Syphilitic Coronary Ostial Stenosis

No cases of syphilitic narrowing of the coronary orifices occurred in this series. The condition was reviewed in a paper by Scharfman et al. (1950) from which it is gathered that myocardial infarction is uncommon in this condition but that when it does occur it takes the form of multiple areas of focal necrosis. No note is made of the distribution of these lesions. Büchner (1939) however recognised the left ventricular inner zonal distribution of the focal lesion in syphilitic ostial stenosis.

which was supplied by the right coronary artery. I was left  
in a search for another opportunity of injecting a heart with  
aortic stenosis.

Note on a case of Aortic Stenosis. (No. D3)

Some details of this case appear in Table 2:4.

Breathlessness, anginal symptoms and congestive cardiac failure were features of the terminal illness, which was progressive over some seven months. Death was sudden. 18 years beforehand there had been an episode of pain which might have been ischaemic and otherwise, until the final illness, there was no angina.

A deep seated, fibrotic infarct was found in the territory of the anterior descending artery. The infarct occupied only a small fraction of the territory of this artery. About 1/3 of the way from the left coronary orifice there was a localised atherosclerotic patch which caused encroachment on the lumen to a degree which was only just discernible. The cause of infarction was therefore obscure. It seemed likely that occlusion had occurred at one time, presumably 18 years before death, and that the plaque of tissue was the remnant of organisation of thrombus.

When the aortic valve was examined closely, the deformity was such that a deep pocket had been formed below the left coronary ostium. This pocket was filled with material which appeared to represent old-standing blood clot. The adjacent aortic wall was thickened and calcified, as might have resulted from the organisation of thrombus. It seemed reasonable to postulate that a portion of clot had become detached from the main mass at the aortic valve and had temporarily occluded the anterior descending artery by embolism. There was no stenosis of coronary ostia.

Turning to the transventricular section (Fig. 6:11) it may be seen that the deep vessels of the left ventricle showed considerable enlargement. The appearances however need some explanation. This case occurred early in my series and was the first and only case to receive a poor quality mass into the right coronary and a highly penetrating medium prepared by precipitation into the left coronary artery. The pattern in the lateral wall of the left ventricle is on this account of a different texture to that in the posterior part, which was supplied by the right coronary artery. I was unsuccessful in a search for another opportunity of injecting a heart with pure aortic stenosis.

## SUMMARY

Distinction is drawn between two types of ischaemic myocardial damage in regard to distribution: Regional and Zonal. The patterns of anastomotic change in the coronary circulation and occlusive disease of the major coronary vessels are examined in relation to these two types of myocardial lesion. The chapter falls mainly under two headings: Regional myocardial infarction and inner zonal infarction of the left ventricle.

Regional myocardial infarction: It was shown that this form of myocardial infarction resulted from acute coronary artery occlusion and ischaemic damage was restricted to the territory of the affected artery.

It was evident that recent coronary artery occlusion was followed by extensive regional infarction where the degree of anastomotic enlargement had not shown much departure from the normal pattern.

The difficulties in assessing the situation obtaining at the time of infarction of older standing (i.e. which had been survived) are stressed. It seemed likely that the main factor conditioning restriction in the extent of ischaemic damage, and thereby favouring survival, was indeed pre-existing anastomotic enlargement. Complete protection against the effects of coronary occlusion was (with one exception) never encountered.

All the evidence pointed to the fact that augmentation of collateral blood supply occurs as a result of coronary artery occlusion and not in anticipation of need. The part played by anastomotic enlargement subsequent to occlusion receives comment.

Discussion is introduced of the experimental evidence on the subject of coronary anastomoses in relation to the severity of myocardial infarction following coronary artery ligation.

Inner zonal infarction: This condition was exemplified by four cases which have been selected for special description. They had in common a long history of unremitting, relentlessly progressive angina; widespread advanced obliterative coronary artery disease; narrowing of both coronary ostia; inner zonal distribution of ischaemic myocardial damage in the entire left ventricle; and a characteristic pattern of vascular adaptation.

Anastomotic development was of advanced degree and affected the subendocardial plexus of the left ventricle with special emphasis.

Terminal myocardial damage took the form of focal necrosis, which was extensive in two cases, and was in no instance precipitated by recent coronary artery occlusion.

Factors conditioning the distribution of focal necrosis are discussed in detail. It is suggested that remoteness from the source of arterial supply, together with the obstruction to coronary inflow to the deeper layers of the left ventricle during systole, which results from extravascular compression, are the most likely factors governing this distribution.

In these cases, the coronary circulation was converted into a network of dilated, intercommunicating channels. In this way the anatomical basis, upon which regional infarction might have occurred, no longer existed. There was evidence that 14 instances of thrombotic occlusion of main stems and 20 of smaller branches had occurred between the four cases during the course of the disease.

All occlusions were of long standing, and none had caused more than moderate local increase in the density of patchy fibrosis in the territory of the affected artery. By the time of death all but one were recanalised.

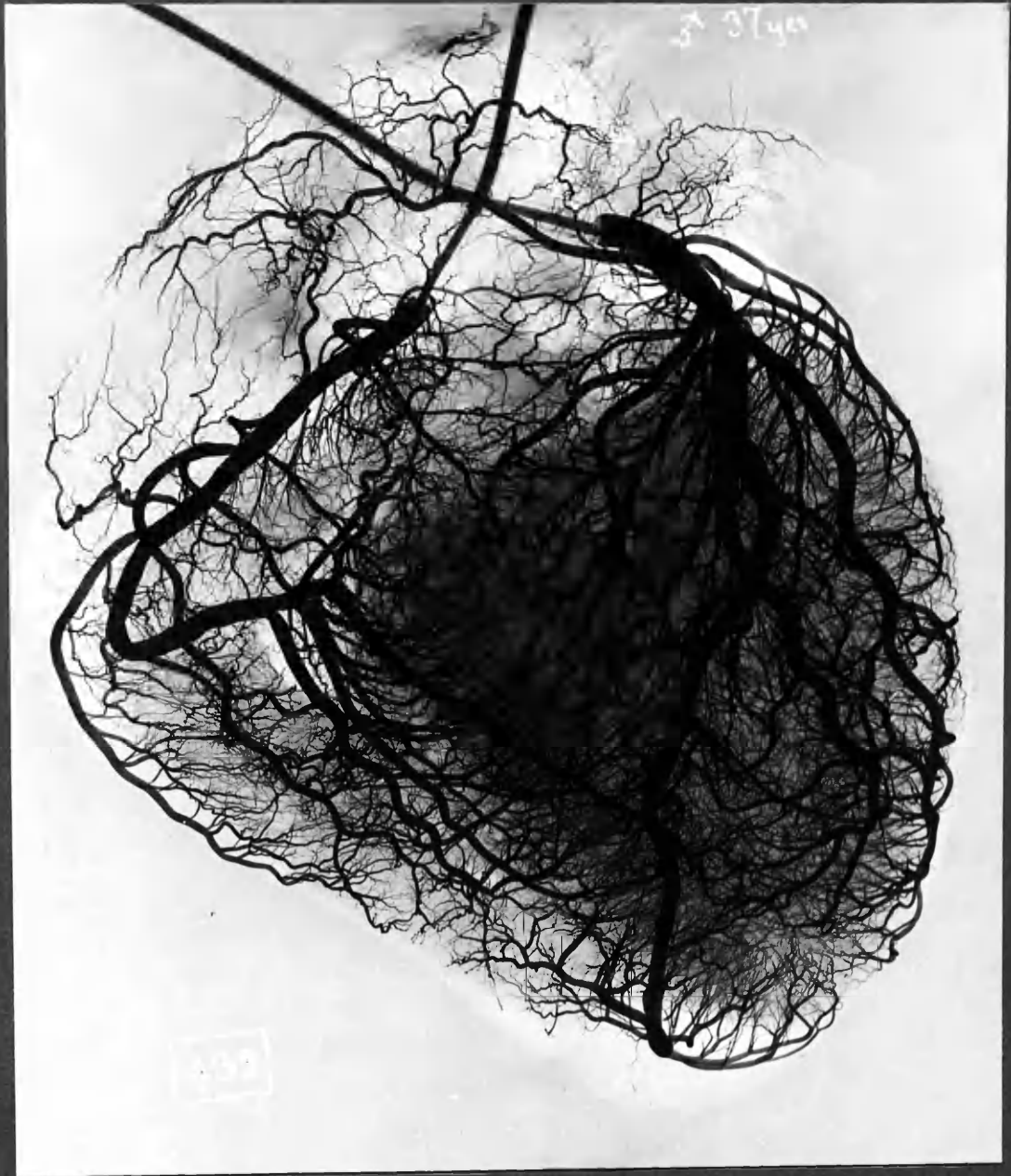Stress is laid on the very chronic nature of the vascular background found in these cases in which acute attacks of coronary insufficiency were primarily due to obliterative coronary artery disease.

Little reference to the importance of the subendocardial plexus in disease has been found, and it is believed that the vascular pattern observed in the four cases has not previously been described. Possible reasons why this should be so are discussed.

Mention is also made of the findings in other conditions in which cardiac ischaemia must have been generalized. Special reference is made to aortic stenosis, and to enlargement of the subendocardial plexus of the left ventricle in that condition.

FIGURES

CHAPTER 6

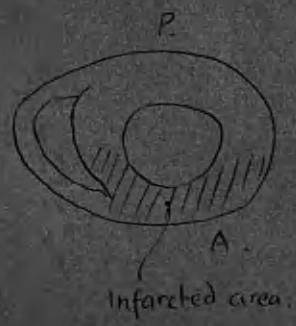
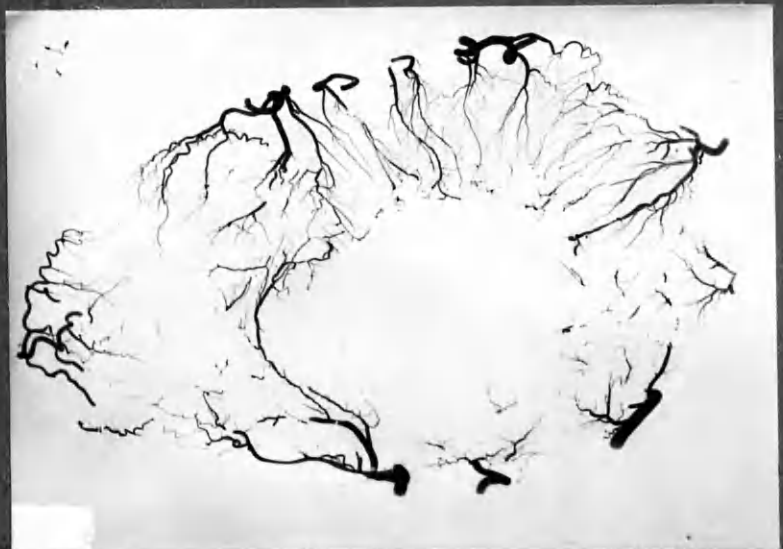

N' 16

NORMAL CORONARY CIRCULATION.

Fig 6:2a

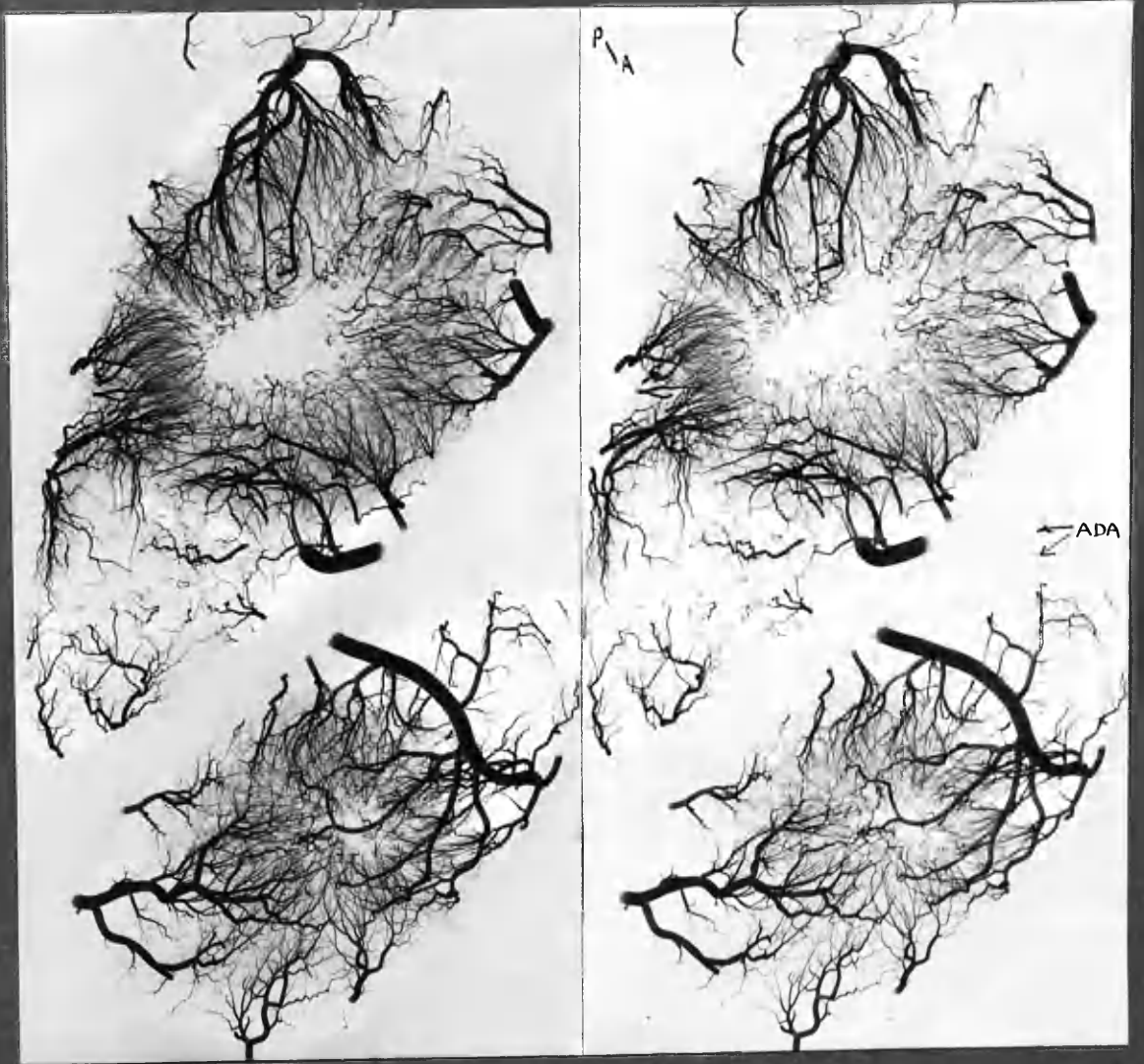
Post. LV wall  
normal vascular filling.



Case 16.

↑ ADA





N'16 Stereo-pair. T.S. ventricles and apex.

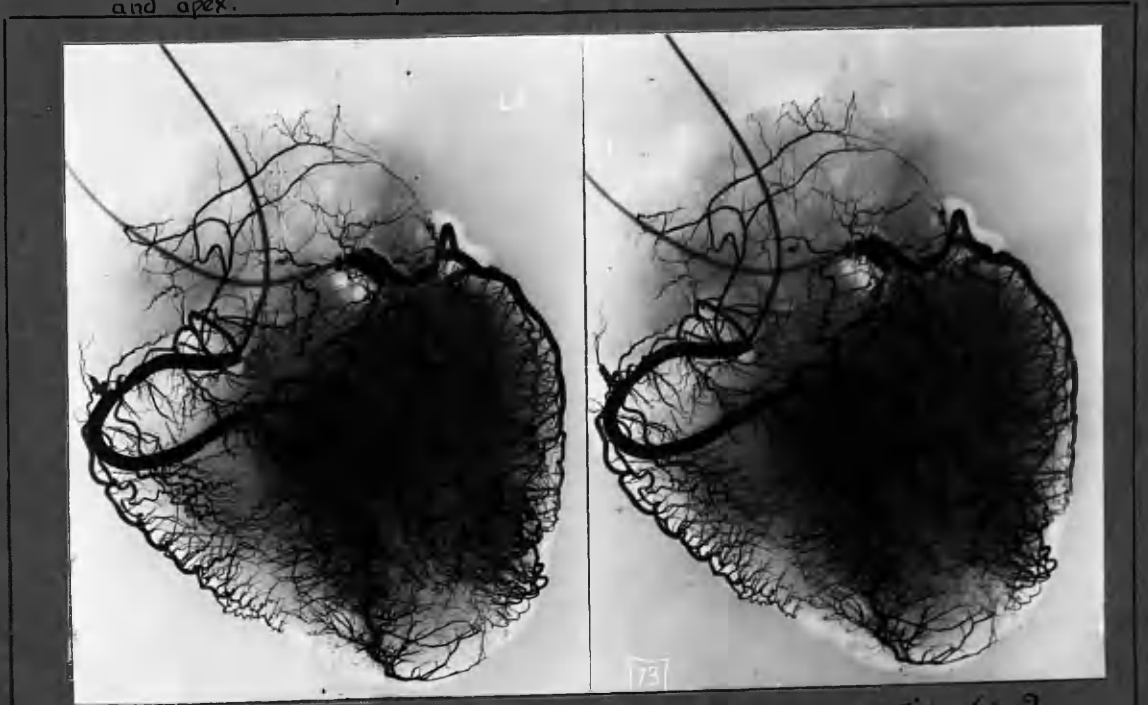
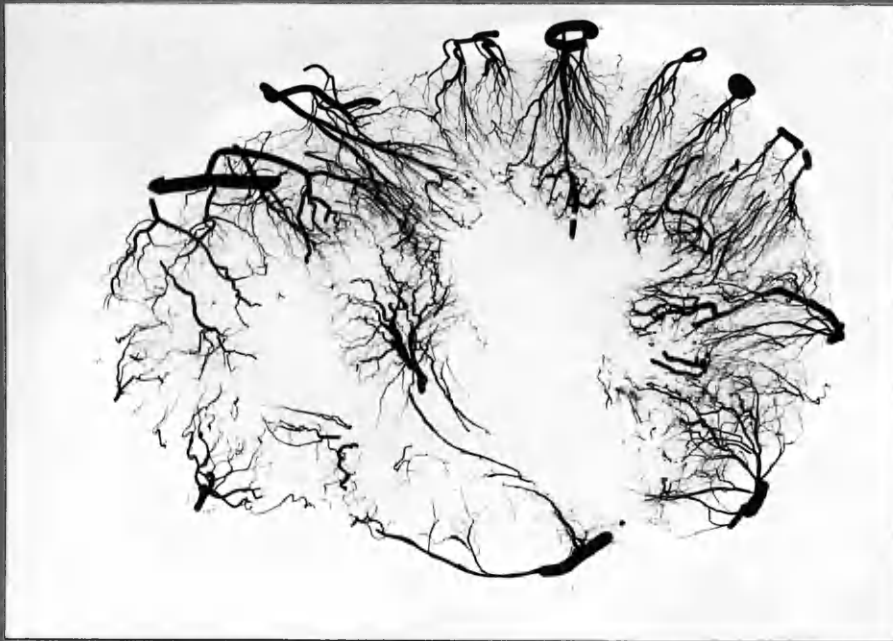


Fig 6: 2

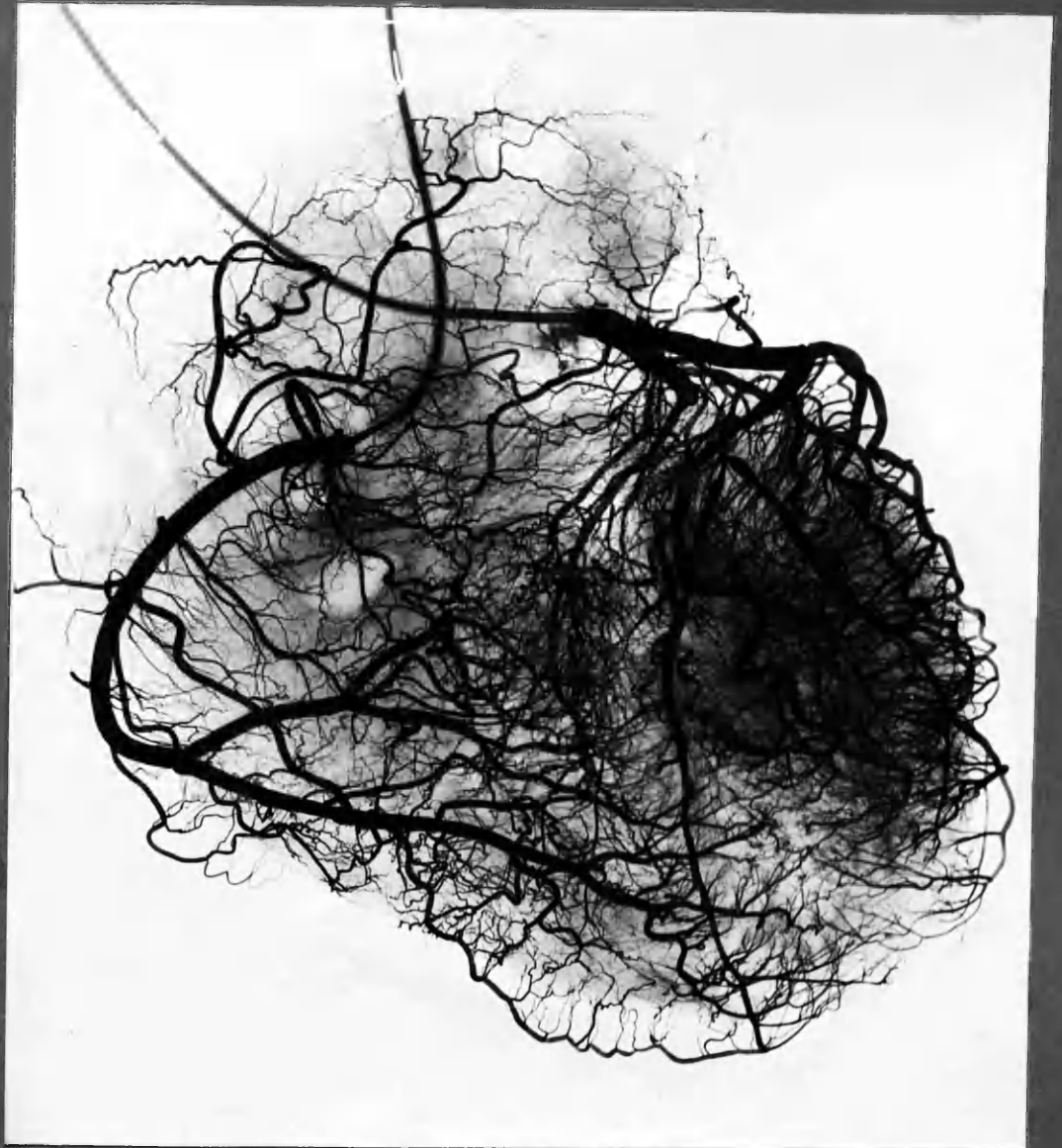Case 16 : stereo.  
occlusion ADA. Anastomotic enlargement slight

Fig 6:3a.



Case 20

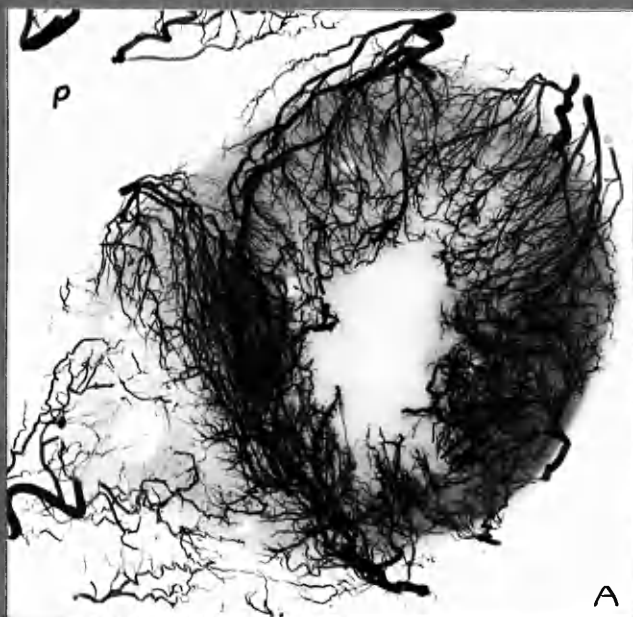
T.S. mid-ventricles.



Case 20

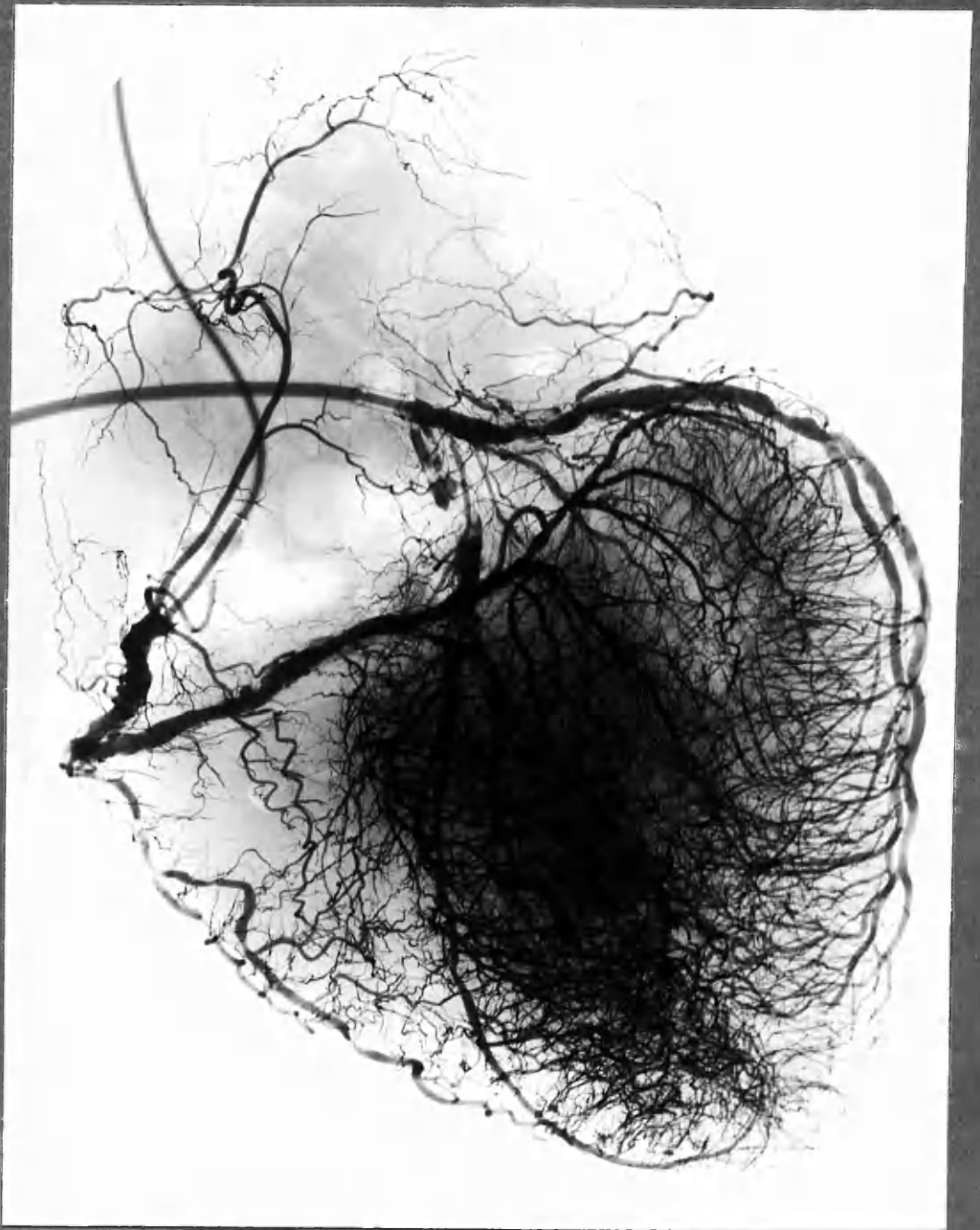
Recent necrosis of ant vent. wall has involved smaller arteries in the infarcted area, which have accordingly not been filled.

Fig. G: 4a.



Case 18 . Trans-ventricular section

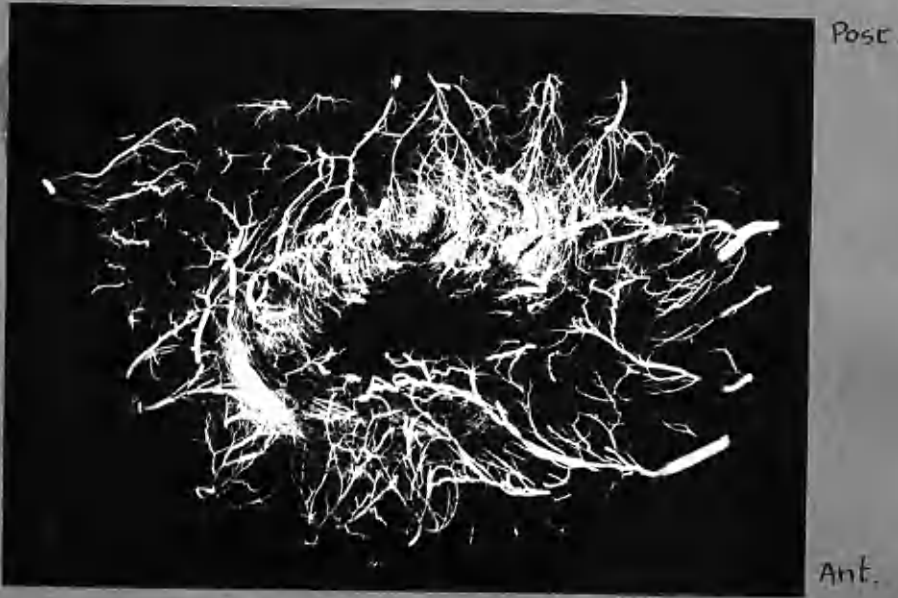



## Case 18

Old occlusion ADA. Enlargement of anastomoses in depths of L.V.  
and across IVS.

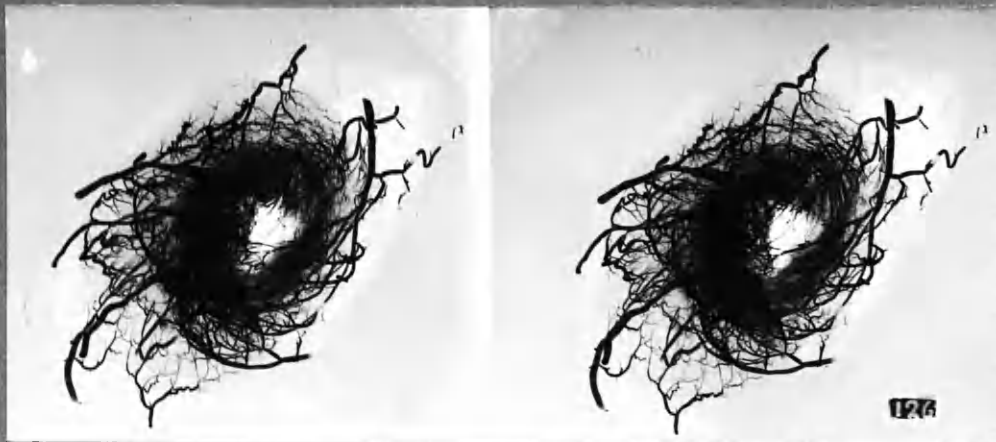
Fig 6:5a




Case 19.

Transventricular section  
(See Fig 6:10)

Fig. 6:5 b



Case 19. Stereo. Apex.

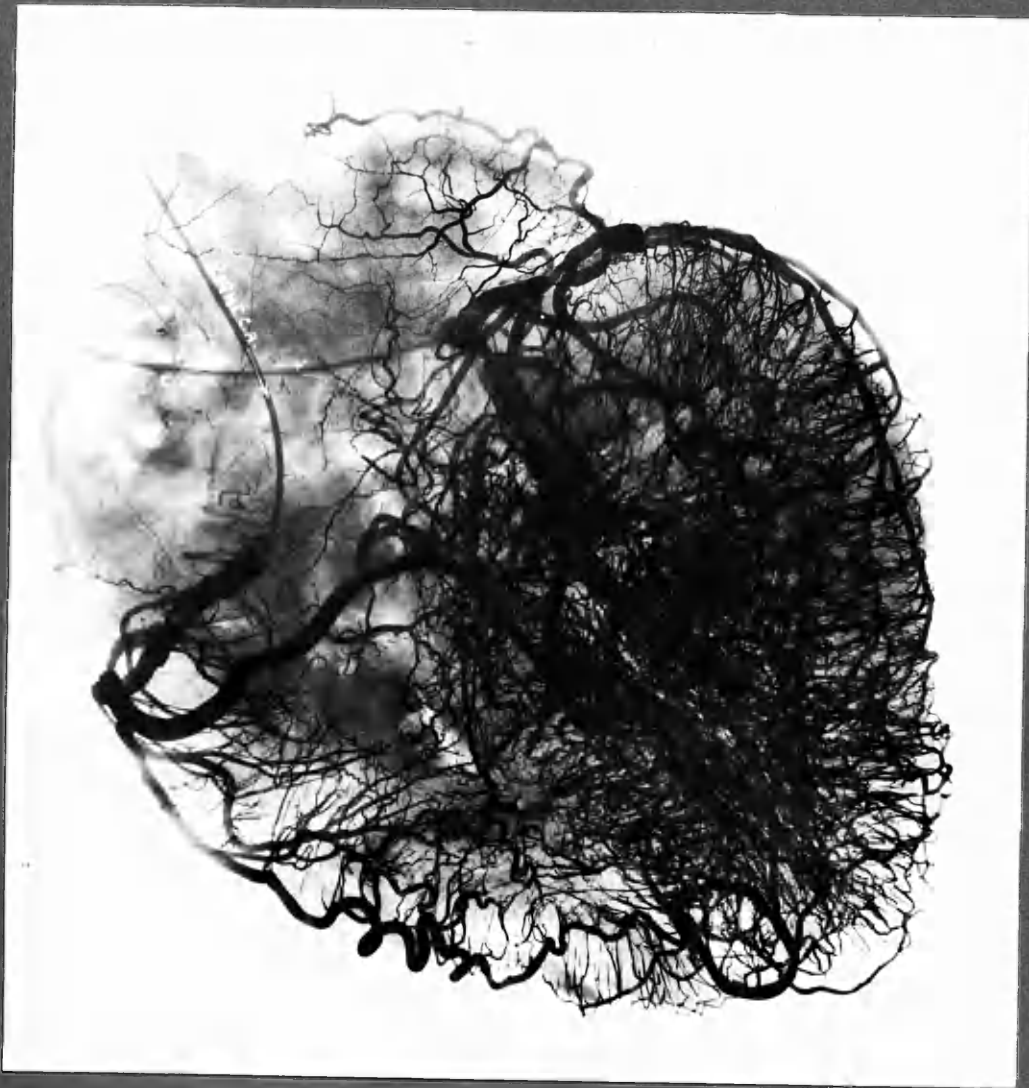

## Case 19.

Widespread severe obliterative coronary artery disease.  
Generalized enlargement of vessels of L.V. subendocardial  
plexus.

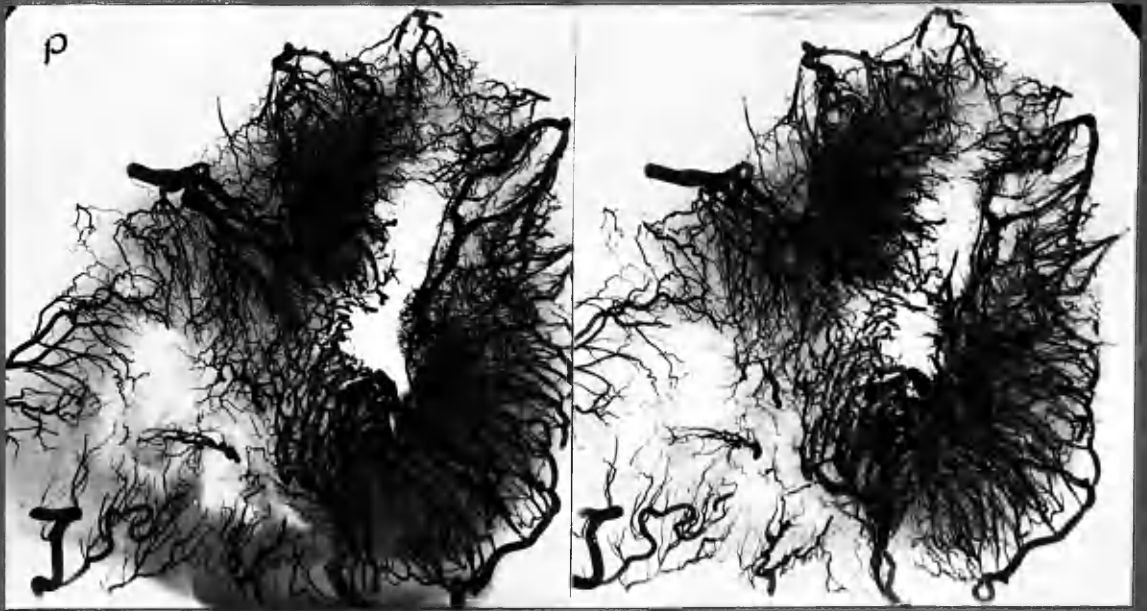
N.B. The central density in L.V. area is due to radio-opaque  
injection mass in arterial channels, and NOT to tissue shadow.

Fig. 6:6

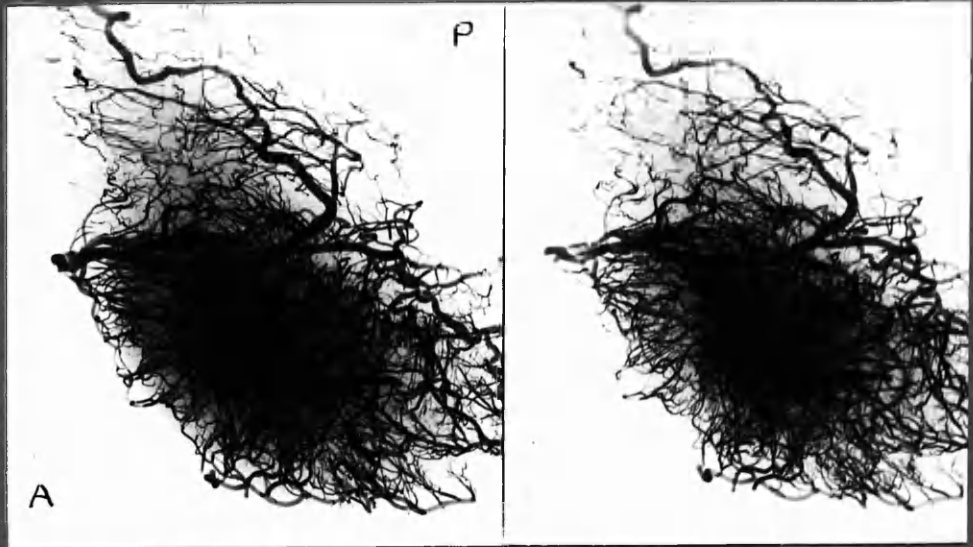


Case 6





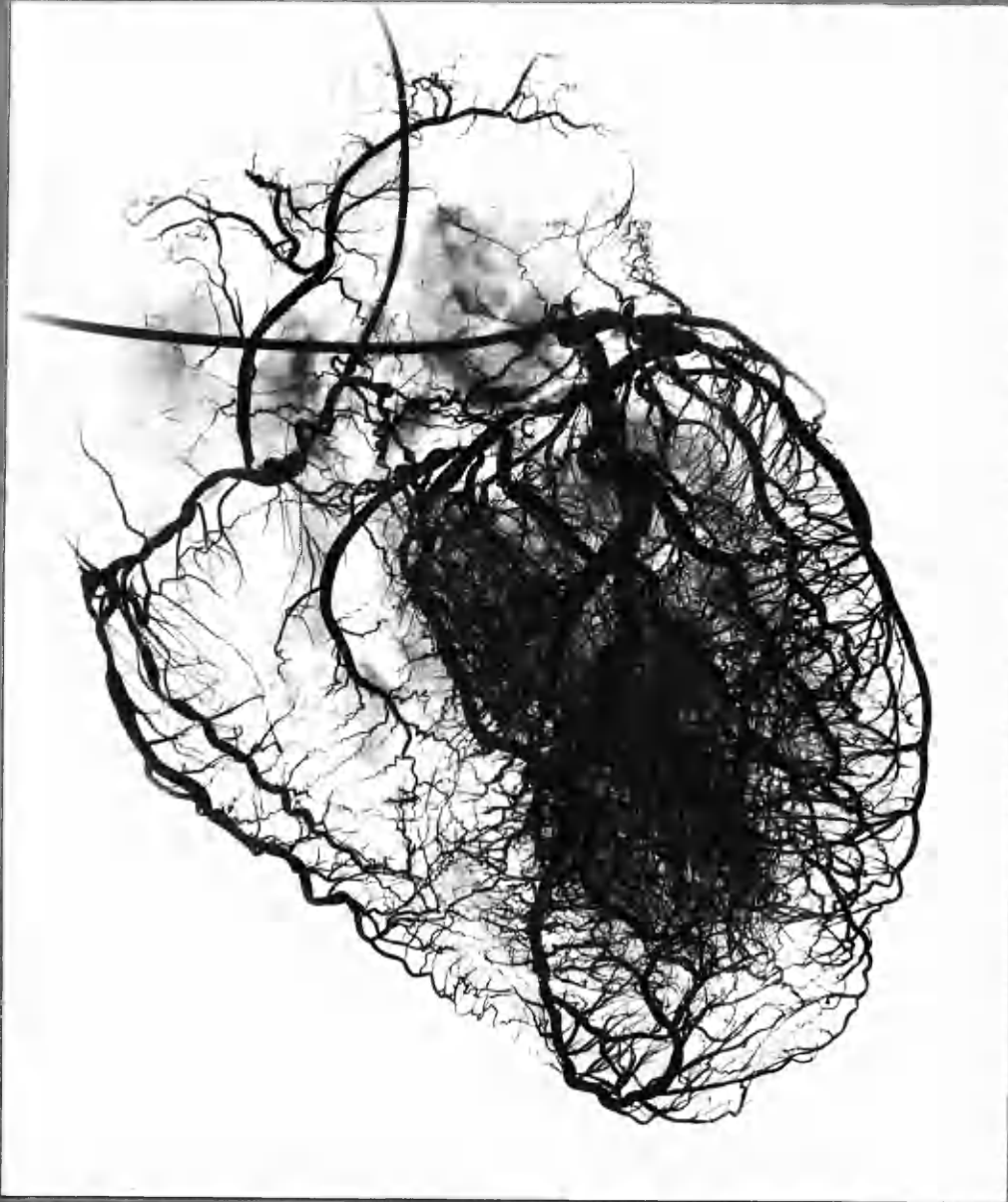
← marginal branch  
RC  
ADA



ADA →

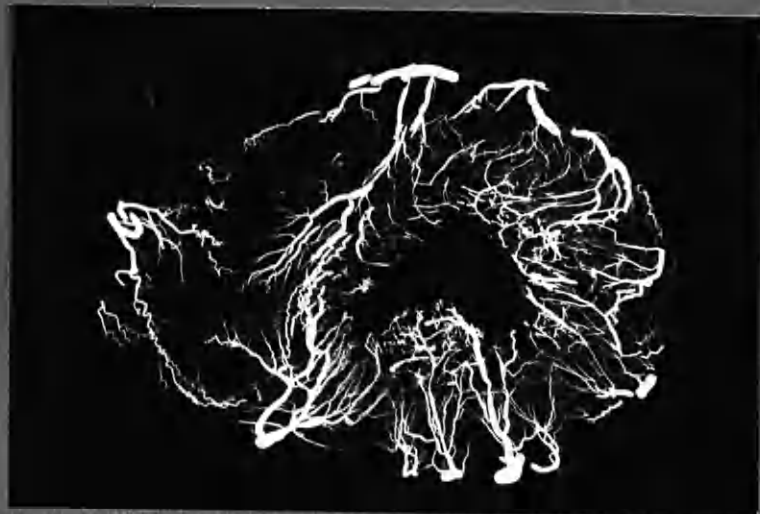Case 6 Stereo-pairs : midventricular section and apex

Fig. 6:7



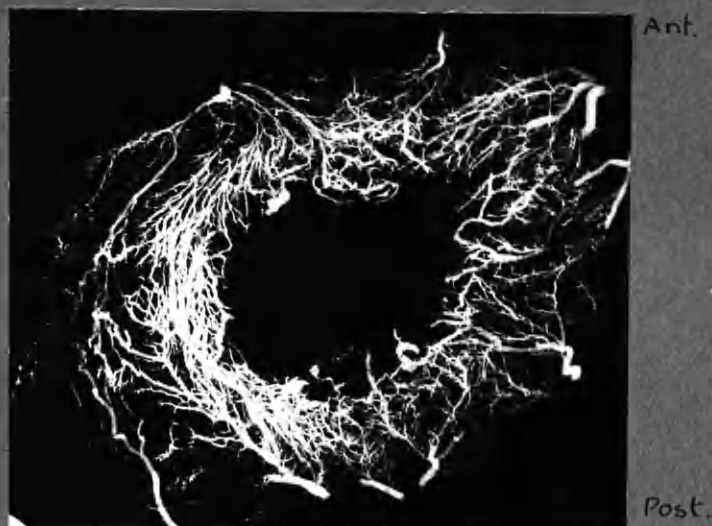Case 8

Fig 6:8



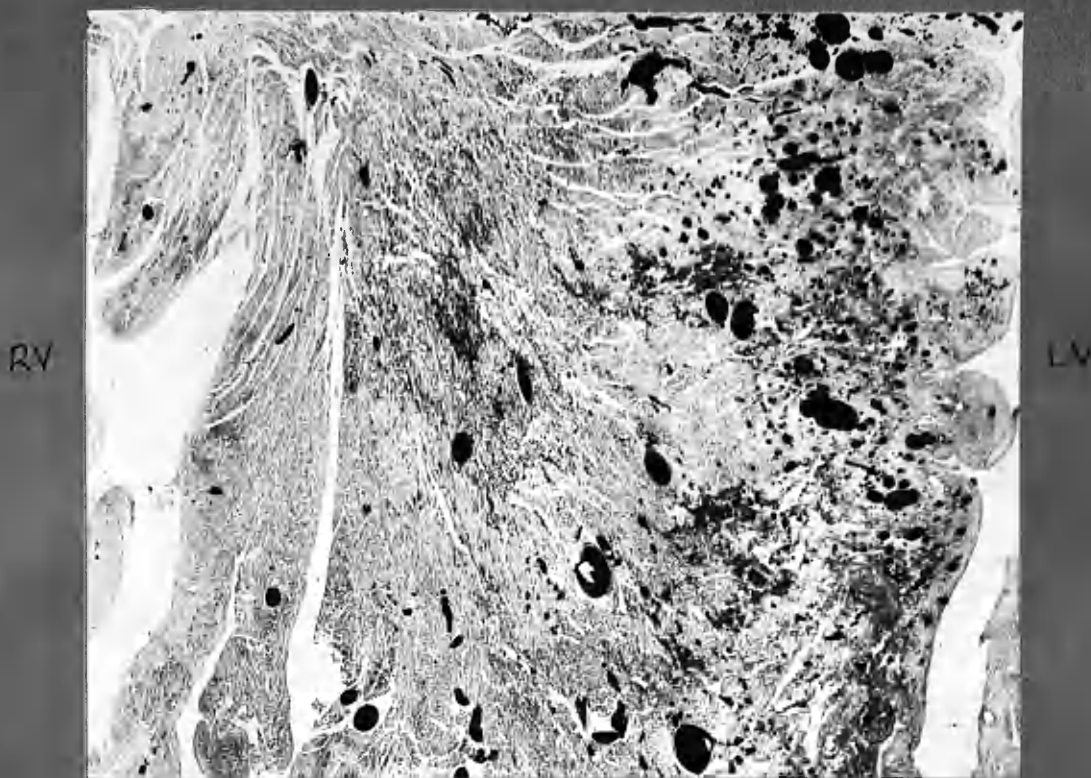
Case 8 Transventricular section.

Fig 6:9



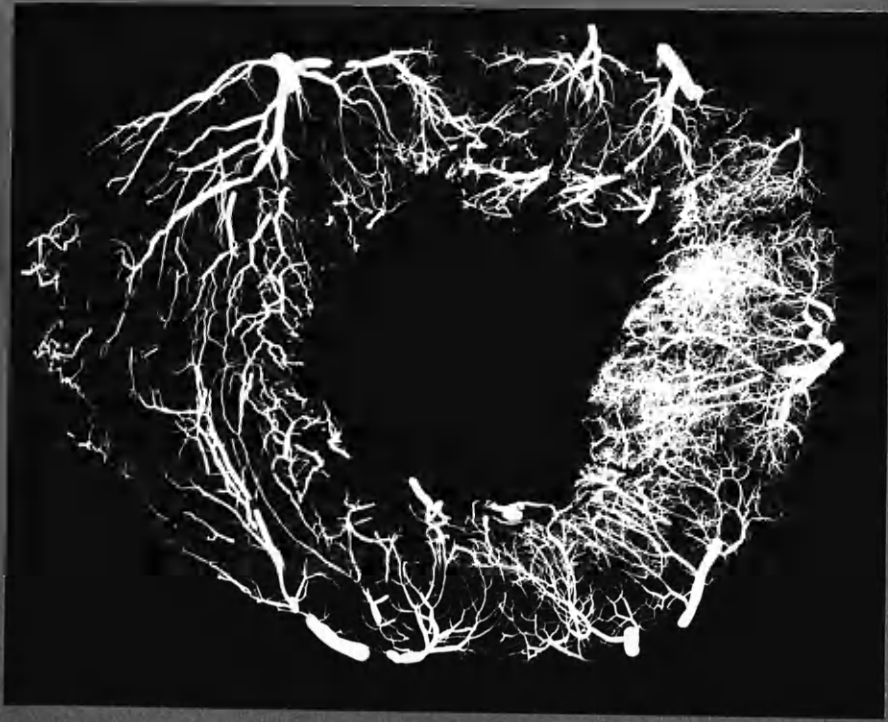
Case 17 T.S. mid ventricles.

Fig 6:10



Case 19 T.S. portion of Inter-ventricular septum. x7  
 Showing fibrosis and vascular density (injected vessels black)  
 in the inner (L.V.) half of the septum.  
 vertoeff and Van Gieson

Fig. 6:11.



Post.

← small vessel density produced by more penetrating medium into L-C. than R.C.

Ant.

Case D3 . midventricular T.S. . Aortic stenosis .





OBSERVATIONS ON THE CORONARY ARTERIES

VOLUME III

Thesis Presented to the University of Glasgow  
for the Degree of Doctor of Medicine

by

William F. M. Fulton  
B.Sc., M.B., Ch.B., M.R.C.P.



# CHAPTER 7

## CANALISATION



Chapter 7: CANALISATION OF THROMBOTIC OCCLUSIONS

	<u>Page</u>
<u>INCIDENCE OF CANALISATION IN THIS SERIES.</u>	7:2
<u>CRITERIA AND TERMINOLOGY.</u>	5
<u>MATERIAL, METHODS AND PRESENTATION.</u>	7
Note on the pictorial method used in this chapter.	8
System of reference to illustrations.	10
<u>THE CHANGES OBSERVED IN THROMBOTIC OCCLUSIONS.</u>	12
"Separation".	14
"Fissuring".	20
"Separation" and "Fissuring" combined.	26
Time -limit in canalisation.	30
1. Sclerosis.	30
2. Necrosis	32
<u>FACTORS WHICH MAY INFLUENCE CANALISATION of thrombotic occlusions.</u>	
Intimal thickening and encroachment on the lumen.	33
Composition of the thrombus.	35
Possible influence of anastomotic enlargement.	37
<u>FUNCTIONAL STATUS AND FATE OF SMALLER BLOOD CHANNELS IN CANALISED THROMBOTIC OCCLUSIONS.</u>	39
<u>"AGING" OF THROMBOTIC OCCLUSIONS OF THE CORONARY ARTERIES.</u>	44
Very recent appearances.	46
Old-standing appearances.	47
Intermediate changes.	49
<u>THE POSITION OF THE NEW LUMEN IN CANALISED OCCLUSIONS.</u>	51
<u>NOTE ON VESSELS ARISING FROM THE ADVENTITIAL COAT in regard to canalisation.</u>	53
<u>COMMENTS ON THE VARIED CONFIGURATION OF CANALISED OCCLUSIONS.</u>	55
<u>THE FUNCTIONAL SIGNIFICANCE OF CANALISATION.</u>	58
<u>SUMMARY.</u>	62

ILLUSTRATIONS (see overleaf).

b

ILLUSTRATIONS

The majority of illustrations are to be found at the end of the chapter. (1) Stereo-artereograms are accompanied by photographs of selected 2 mm. thick cross sections. (2) Other photographs and photomicrographs are placed in a second group.

Illustrations distributed in the text:-

DIAGRAMS

	<u>Page</u>
7: 1 Canalisation of thrombotic occlusion (1)	7:14a
7: 2 .. .. .	14a
7: 3 Canalisation of thrombotic occlusion (2)	14b
7: 4 .. .. .	14b
7: 5 Position of the new lumen	51a

PHOTOGRAPHS of 2 mm. thick sections.

4 Examples of canalisation (stereo-pairs)	24a
(15 ADA 3:6a, 11 ADA branch 4:4 b. and 5:1a, and 11 LGxA branch 1:5a)	
24 RC 3:4b (by incident and transmitted light)	24a'

For notes on illustrations and system of reference,  
see pages 7: 8, 10.

OBSERVATIONS ON CANALISATION OF THROMBOTIC OCCLUSIONS  
OF THE CORONARY ARTERIES

---

It is well recognised that complete occlusion of a coronary artery is not necessarily permanent, and that continuity of the lumen may later be restored. There are however many details of the processes involved which are imperfectly understood, and about which there is no uniform agreement. The integrated combination of stereo-arteriographic, micro-anatomical and histological methods used in this investigation has been of special advantage in the analysis of changes in thrombotic occlusions of the coronary arteries. The opportunity has therefore been taken of examining the nature of the changes which may lead to recanalisation of obstructed coronary arteries; and to enquire of the data obtained what proportion of occlusions are in this way rendered incomplete, how long the process takes and what measure of restitution of arterial lumen - and therefore of blood flow - may result. These points receive attention in this chapter. It is hoped that the illustrations made possible by the technique of examination may prove to be features of special interest.

INCIDENCE OF CANALISATION OF OCCLUSIONS IN THIS SERIES

The incidence of canalisation in 47 main stem occlusions is indicated in Tables 7:1 and 7:2. Severe narrowings, in which it was doubtful that the lumen had ever been completely obliterated, are not included. From these Tables it can be seen that 12 out of 13 occlusions of less than one month's duration were still complete at death. Whereas 12 out of 25 occlusions over one year's duration had been canalised.

The relationship of incidence of canalisation to duration of occlusion was not however as simple as these two groups, from the two ends of the scale, would suggest. Thus when the distribution of canalised and complete occlusions among lesions of longer standing was examined, there was little difference which could be related to the age of occlusions alone. It so happened in this series that 4 out of 5 occlusions of 1-2 years duration were still complete, while 4 out of 9 occlusions of 1-8 months duration were already canalised by the time of death. There was a nearly equal distribution of complete and canalised occlusions in lesions of more than 2 years standing.

Quite obviously, firm conclusions cannot be based upon these figures alone. It was made evident by them however that the passage of time was not the only or even the most important, factor which determined the restoration of continuity of the arterial lumen following its obliteration by thrombosis. Indeed, several occlusions were still complete after 7 years and more had elapsed.

It may also be pointed out that the process of canalisation was often seen to have advanced far along the length of occlusions which were none the less still completely occluded at death for a short distance. Further, in 6 instances of recent occlusion the arteries involved had evidently been occluded and recanalised before the advent of final occlusive thrombosis. The data in this latter respect have already been dealt with in Chapter 5 and do not feature in Tables 7:1 and 7:2.

Table 7:1

RELATIONSHIP OF DURATION TO THE INCIDENCE OF CANALISATION in 47 main-stem coronary artery occlusions. 25 Cases.					
Age of lesions	Occlusions at death				
	Complete			Canalised	
1 - 28 days	5(2)	7(10)	9(12)	13(11)	
	11(22)	11(22)	11(22)		
	12(1)	14(19)	20(?8)		
	21(4) <sup>≠</sup>	22(2)	24(9)		
4 - 12 weeks	2(?10)	16(?8)		3(6)	15(4 $\frac{1}{2}$ )
3 - 8 months	7(7)	14(?)	24(6)	7(7)	10(?6)
8 - 24 months	2(12)	12(18)	12(18)	5(12)	
	22(24)				
2 years and more or "Older" but of unknown age	1(7) <sup>≠</sup>	1(7)	1(7)	4(7)	4(7) 6(?13)
	4(7)	6(?13)	10(?)	8(?12)	17(?10) 17(?10)
	10(?)	19(?10)	25(?)	18(?)	18(?) 19(?10)
				23(?)	25(?)

Notes 7:1

Nos. = Case numbers.

Figures in brackets indicate the age of the occlusion, in days, weeks, etc. according to the horizontal column.

<sup>≠</sup>LC = 1 occlusion (=2 occlusions in Table 5:4).

<sup>≠</sup>LC, ADA and LCxA occluded = 3 occlusions (= 2 occlusions in Table 5:4)

"?" = (a) In main stem occlusions less than 8 months in age, "?" indicates that there has been insufficient indication of its age from the history, and that the age has been estimated from the apparent age of the corresponding muscle damage.

(b) In the old-standing lesions "?" followed by a number in brackets indicates the duration of ischaemic symptoms and that the lesion in question may be of any age between 2 years or so and this number of years. "?" alone in brackets indicates that the lesion and corresponding muscle damage appear to be of old standing, but there was no relevant history of ischaemic symptoms.

Table 7:2

RELATIONSHIP OF DURATION TO THE INCIDENCE OF CANALISATION in 47 main-stem coronary artery occlusions. 25 Cases.				
Age of lesions	Occlusions at death			Total
	Complete	Canalised	Canalised/ Complete	
1 - 28 days	12	1	1/12	13
4 - 12 weeks	2	2	4/5	9
3 - 8 months	3	2		
8 months - 2 years	4	1	12/13	25
2 years and older	9	11		
	30	17	17/30	47

In these Tables only main stem occlusions have been analysed. The position in regard to major branch occlusions (2nd Division arteries) was essentially similar, there being 9 occlusions still complete at death and 8 canalised. The ages of these occlusions were however often in doubt, and no attempt to subdivide them according to age was made.

Similarly, a considerable proportion of smaller branch obstructions (3rd Division arteries) were incomplete at death.

## CRITERIA AND TERMINOLOGY

Classification of occlusions as "complete" or "canalised" was made upon the situation found at death. The criteria adopted in Chapter 5 were again employed. An occlusions that had been previously canalised and then completely occluded for the second time was therefore classed as a complete occlusion. An occlusion was classed as "canalised" where continuity of the lumen had been restored, as judged on examination of the arteriograms and, where relevant and available, of the mounted 2 mm. thick arterial sections. No matter by how narrow a track, where continuity was restored the occlusion was classed as canalised. Conversely no matter how extensive the process of canalisation, an occlusion was classed as complete where continuity of the lumen had not been restored, even should the intervening obstruction be less than 1 mm.

The decision to class an occlusion as canalised (as opposed to a "narrowing", where the obstruction may never have been complete) was made after examination of a number of features. These include: (1) the arteriographic evidence, in which abrupt change in the calibre of the lumen, breaking up of the lumen into several channels, and intimal vessels running in the long axis of the artery were noted; and (2) the nature of the intimal tissue surrounding the channel(s) in question as judged on the evidence held in the 2 mm. thick sections and the micro-sections. Pigmentation from altered blood pigment, iron deposition, and the configuration of the most recently formed portion of the intimal plaque were taken into consideration in determining the origin of the tissue from thrombus. Further details will emerge in the description. The features which suggested a thrombotic origin for intimal tissue are considered in greater detail in Chapter 8. In the majority of occlusions the distinction between primary severe narrowings and channels formed by the canalisation of complete occlusions was made without difficulty. As indicated in Chapter 5 the correctness of the classification received support from the

degree of myocardial damage found in relation to the different grades of obstructive lesion in the arteries.

The grounds for selection of 1 mm. as the upper limit of lumen diameter for lesions classed as "occlusions" are also dealt with in Chapter 5. It was found that there was little doubt in the classification of obstructive lesions below this calibre, but some lesions in which the lumen measured 1.5 mm. in diameter, and even more, were sometimes thought to have been the product of widening of a channel previously much narrowed, or even completely occluded; for, in these instances, there was related focal myocardial damage not otherwise readily explained. Such lesions are not included in the data under consideration in this chapter.

Abbreviations used.

- LC = Left Coronary Artery, main stem.
- ADA = Anterior Descending Artery.
- LCxA = Left Circumflex Artery.
- RC = Right Coronary Artery.



THE MATERIAL AND THE METHODS OF EXAMINATION IN RELATION TO THE  
DEMONSTRATION OF CANALISATION OF THROMBOTIC OCCLUSIONS.

The methods used and the general statement of the material have already been detailed in Chapters 1 and 2. There are however certain points of particular relevance to the demonstration of changes in thrombotic occlusions which will be further elaborated below.

The information available in the last 16 cases was of a more searching order than in the earlier cases. The methods of preservation of the evidence in a form which could later be used for demonstration improved throughout the course of the investigation. Most of the illustrations therefore have been taken from the later cases. For this reason the order has been reversed in which the illustrations are presented. In Cases 10-25 each injected main-stem artery (and some others) was excised in a block, cutting widely, guided by the stereo-arteriograms. Further stereo-arteriograms were taken of the excised arteries of the last 10 cases after decalcification, and these form the best examples for illustration. Although less satisfactory for photographic demonstration, comparable information was obtained from direct examination of the stereo-arteriograms, taken after partial dissection, in Cases 5-15. Cases 1-4 were subjected to careful dissection under low-power magnification, in conjunction with the arteriograms of the unopened heart. Micro-sections were available in all but a few of the lesions - but not always, in retrospect, at the point of major interest. In the last 16 cases, serially mounted 2 mm. thick transverse sections were taken from the full length of the occlusions and were of the greatest value. They provided essential information about the position of the channels within the arteries and the nature of the thrombus or tissue in which they lay.

Indeed /

Indeed these serial 2 mm. sections were essential for the sure interpretation of the radiographic picture. By their aid, points that might otherwise have been in question in the arteriograms could be established beyond doubt. For instance, continuity following occlusion was sometimes restored through nearby enlarged anastomotic vessels lying in, or just outwith, the adventitial coat. Presumably such vessels arose from the network of vasa vasorum. Examples of this phenomenon are to be found in the right coronary artery in Cases 7, 24 and 25 and in the major branch of the anterior descending artery in Case 11. Examination of the sections demonstrated clearly the relation of these structures to the arterial walls. Restoration of blood flow outwith the original arterial lumen is of course not classed as canalisation.

The differential colour used in the injection medium was also of value in certain circumstances (e.g., Cases 22 and 23, anterior descending arteries) and was of course preserved in the 2 mm. thick sections.

#### Note on the Pictorial Presentation Used in this Chapter

In this chapter the arteriograms of the coronary arteries have been enlarged 2-4 fold, where practicable, and are presented in stereo-pairs.<sup>1</sup> In my opinion the stereoscopic view is essential for a proper appreciation of the changes. On the opposite or subsequent pages the arteriograms are accompanied by photographs<sup>2</sup> of selected mounted 2 mm. thick arterial sections. The levels at which these sections were taken are indicated on the transparent sheet. The monochrome photographs compare unfavourably with the direct examination of the actual specimens at x20 magnification, using a binocular dissecting microscope. Some of the monochrome photographs are reproduced in

- 
1. Enlargements made from my arteriograms by Peter Waldie, F.R.P.S., Stobhill General Hospital, Glasgow.
  2. Photographs of 2 mm. thick sections were taken by means of a 35 mm. camera mounted on a microscope stand using a 4.5 cm. lens, no eyepiece, Ilford F.P.3 film, illumination by 300W., 2" projector (W.F.M.F.). The negatives were printed by Miss Sheila Grace, Department of Materia Medica, University of Glasgow.

stereo-pairs (e.g., Case 14). A small number of colour transparencies<sup>2</sup> are included in Chapter 8, which help in the interpretation of the black-and-white photographs; and emphasise the deficiencies of the latter where gradations of tone and shade are so important. Photomicrographs are also introduced where relevant.<sup>1</sup>

In the direct examination, a detailed picture of the micro-anatomy of a number of occluded and canalised arteries was obtained, supplemented at selected levels by histological sections. The attempt has been made, so far as possible, to present the evidence photographically. Coloured over-drawing on the transparent sheets has been introduced as an aid to interpretation of the photographic evidence, which by this device is left untouched. In addition, I have prepared line drawings by way of illustrating the description given in the text.

A number of selected occlusions are first presented in detail, accompanied in some instances by brief description. The processes involved in canalisation, as determined in this examination, will then be described. Thereafter the significance of these features will be discussed together with consideration of the functional importance of canalisation in ischaemic heart disease.

It will also be convenient to introduce later in this chapter some description of intimal vessels apart from those taking part in canalisation, and of changes found in vasa vasorum in relation to arterial occlusion.

- 
1. Microphotographs taken and printed by Mr. Donald McAllister, Department of Physiology, University of Glasgow.
  2. Colour transparencies taken and processed by Mr. George Marshall, Department of Anatomy, University of Glasgow.

System of reference to illustrations.

The arteriograms and photographs of 2 mm. thick transverse sections have been placed so far as possible on opposite pages for ease of reference. A few arteriograms unaccompanied by transverse sections have been placed together at the end of this group. The cases have been assembled in reverse order, from 25 to 1, with the exception that a print from Case 24 begins the series.

The photomicrographs and photographs of 2 mm. thick transverse sections, not mounted with related arteriograms, follow in a second group, again assembled by cases and in reverse order.

These illustrations are in some instances shared by Chapters 7 and 8, and are accordingly placed between them. In addition, in both Chapters, occasional illustrations may be distributed throughout the text. These will be placed opposite to or within a few pages of the textual reference to them, and a note will also be appended to the grouped illustrations of that case.

The system of reference is best indicated by examples:-

22 ADA = Anterior descending artery, Case 22.

22 ADA (art.) = Stereo-arteriogram of .. .. .

22 ADA 2:5a = 2 mm. thick section 5 in 2nd row of the mounted arterial series, viewed from its proximal aspect. This is usually its upper surface in reference to the arteriograms. The position is indicated on the transparent sheet.

22 ADA 2:5b = The same, but viewed from the distal (or lower) aspect.

The sections have been carefully orientated in relation to the stereo-arteriograms. 2:5a would therefore have its anterior aspect facing downwards on the page, and the reverse would hold for section 2:5b. Right and left will be unchanged and in either case will correspond to the arteriograms.

25 RC 3:4 micro. = Microsection taken from the thick section corresponding in position to 4th section in 3rd row of the mounted arterial series of the right coronary artery, Case 25.

As there may be several sections with various stains or magnifications taken from the same 2 mm. thick block, a figure number may also be placed after references such as this; or a page number.

14 ADA 2:4 micro. (4,6,7) = The figures in brackets refer to the 4th, 6th and 7th mounted micro-photographs of sections taken from block 2:4 of ADA, Case 14.

Figure numbers referring to figures in other chapters are prefixed by the number of the chapter, e.g., Diag. 8:2 or Fig. 5:7.

Abbreviations used for microsections:-

Paraffin sections:

- H. and E. : Haematoxylin and eosin.  
W. v G. : Weigert's elastic tissue stain and van Gieson's stain.  
V. v G. : Verhoeff's elastic tissue stain and van Gieson's stain.  
P.B.R. : Prussian blue reaction, for iron.  
Fibrin W. : Fibrin stain, Weigert's.  
Picro-Mall. : Lendrum's acid picro-Mallory stain.

Frozen sections:

- ∅ : Unstained.  
Sch.R. : Scharlach R., for fat.  
Pola : Photographed by aid of polarised light.

(Other abbreviations used have been outlined in Chapter 5)

In the foregoing demonstration of selected examples of coronary artery occlusions it will have been apparent that a great variety of changes were found. Indeed, of the 47 complete and canalised occlusions under consideration in this chapter, no two lesions were identical. In the arteriograms alone each occlusion had an individuality of configuration. The appearances in a relatively recent occlusion largely depended upon the anatomy of the artery in which it lay; the previous state of the artery wall; the extent of the thrombus; and its duration. In the course of time, change took place in the thrombus and in the artery wall. As a result still more complex appearances were produced in older lesions. The processes involved in canalisation of thrombotic occlusions as observed in this investigation form the subject of this section.

In the great majority of instances of coronary artery occlusion, it was evident that thrombosis had taken place in the presence of considerable antecedent arterial disease. In all but two instances in this series, recent occlusion by thrombus had involved arteries which showed considerable intimal thickening, and some were severely narrowed.

One exception was in Case 12 in which the main septal artery was plugged by thrombus of perhaps one day's duration, the result of "short-range embolism" from thrombosis higher up the main stem of the anterior descending artery. The other was in Case 1 in which it seemed, on reconstruction of the case, that complete obliteration of the left coronary artery (main stem, anterior descending artery and left circumflex artery) had taken place in the absence of underlying coronary artery disease at the time. The subject was a young man in whom there was probably an abnormal clotting tendency. On dissection a most remarkable demonstration of canalisation was obtained which greatly excited my interest in this aspect of the subject. (For details see Case Report, Chapter 2). The manner in which the canalising channels occupied the entire luminal area, internal to the internal elastic lamina, in this case forms a striking contrast to the findings in the other arteries of this series. It resembles the situation found in other arteries and in veins in which thrombosis has occurred without previous intimal thickening.

I have thus only a single very recent, and a single long standing, example of thrombotic occlusion in previously normal coronary arteries. The findings which I report in this chapter, therefore, have been based almost entirely on

occlusions by thrombosis of arteries already the seat of severe intimal disease. There is reason to suppose that the changes which followed thrombotic occlusion were influenced by the state of the intimal wall at the time, and also by the dimensions of the arterial lumen.

*ed!*  
A feature which has impressed me greatly was the evident inertness of thrombus in contact with atherosclerotic intimal surfaces. Even after several weeks had elapsed the presence of thrombus seemed to have evoked little response from the underlying intima in the form of cellular activity or the development of vascular tissue. Perhaps this was because thrombus was not chemically foreign in its intravascular site. Or could it have been that without routes of transport the forces of phagocytosis and vascularisation were so surprisingly tardy in mounting their attack? This topic is dealt with in greater detail in the next chapter. At this point it is noted that the early changes observed in occluding thrombus depended little upon responses from the underlying intima; and that the earliest changes observed were mechanical, not cytological.

It will of course be recognised that the intima of a coronary artery often shows cellular infiltration, vascularisation and haemorrhage at the site of thrombosis. In this series it was not always clear whether these features had preceded - and possibly precipitated - the advent of thrombosis, or conversely had resulted from its presence. It was however observed that they were not invariable accompaniments of thrombosis; were well marked in some instances of very recent thrombosis; and were often remotely placed from the luminal surface, and therefore from contact with thrombus. Identical changes were found moreover in atherosclerotic plaques in the absence of recent thrombosis. It was accordingly thought that cellular infiltration and vascular tissue occurring in the depths of an atherosclerotic plaque, which had also been overlain by thrombus, were features to be related to changes taking place in the plaque itself and were not necessarily dependent on the presence of recent thrombus on its luminal surface. In these respects the deep seated changes were to be

distinguished from changes occurring at the interface between intimal surface and thrombus.

Two distinct primary processes were observed in recent thrombotic occlusions and will be referred to as "separation" and "fissuring". In the first instance each appeared to have been mechanical in origin.

"Separation" or Detachment of the Clot from the Artery Wall

Where death had occurred a few days, or weeks, after occlusion of a coronary artery by thrombosis, the injection medium was sometimes seen on the arteriogram to be interposed between artery wall and thrombus. This process is illustrated graphically in Diagram 7:1 (a-c) overleaf. Separation of the thrombus from the arterial intima could take place at one point on the circumference<sup>1</sup> or at several points<sup>2</sup>. Sometimes separation had proceeded only a short distance from one or both ends of the thrombus. In others the process had cleared a primitive channel which ran the greater length of the obstruction<sup>3</sup>. In the arteriogram this channel formed a finger-like fluid wedge, inserted between the thrombus on the one side and the arterial intima on the other. The exact situation may be appreciated by reference to the arterial sections. In the micro-sections it was seen that no more than a thin layer of fibrin coated the clot in the distal channel<sup>4</sup>. On the other hand, an endothelial covering has overgrown the clot at its proximal end<sup>5</sup>.

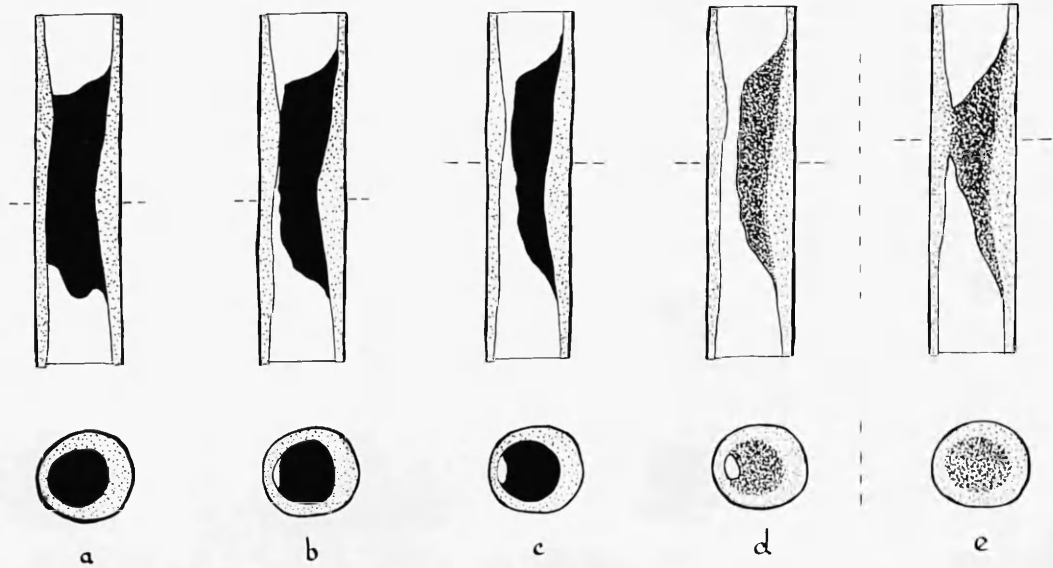
It is tempting to suppose that continuation of this process would have led eventually to union of the proximal and distal channels and so to restoration of continuity of the lumen. It will however become apparent that the arteriographic appearances taken by themselves tend to carry the imagination towards concepts

- 
1. 24 ADA 2:8a, 3:4a, 16 ADA 2:4a.
  2. 16 ADA 4:1b, 15 ADA 3:5b, 3:6a.
  3. 14 ADA art.
  4. 14 ADA 2:4 micro. (6, 8).
  5. 14 ADA 2:1 micro.



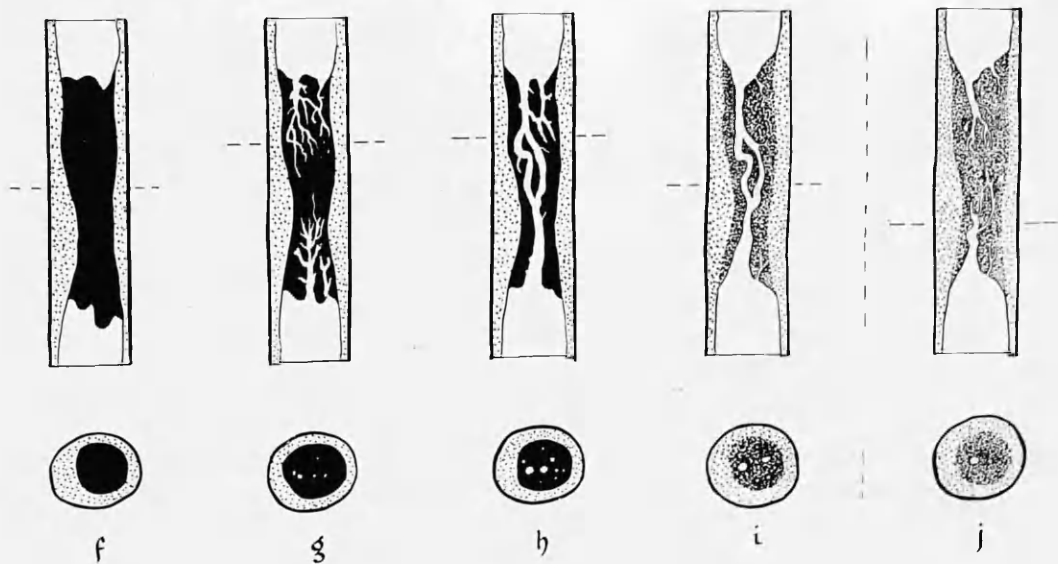
DIAGRAM 7:1

## CANALISATION OF THROMBOTIC OCCLUSION (1).



Separation

DIAGRAM 7:2



Fissuring

WPMR

: a. Recent thrombotic occlusion. b. Partial separation of thrombus. c. New channel formed between thrombus and artery wall. d, e. Organisation of stages b, c. f. Recent thrombotic occlusion. g. Fissuring of the thrombus. h. continuous channel(s) through substance of the thrombus. i, j. Organisation of stages g, h.

DIAGRAM 7:3 CANALISATION OF THROMBOTIC OCCLUSION (2).

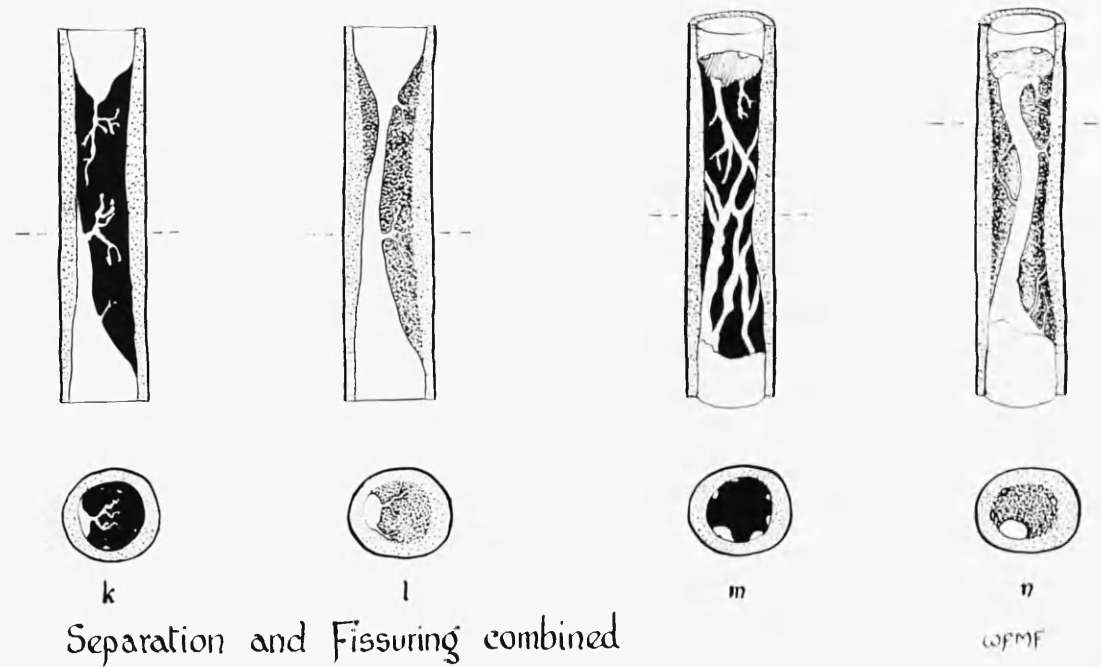
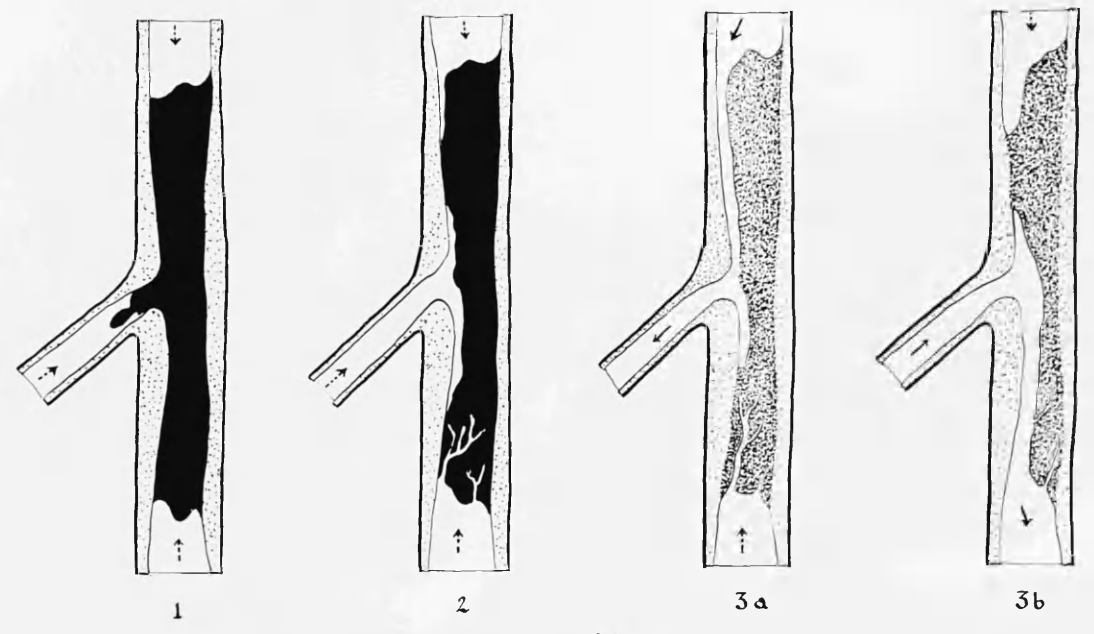


DIAGRAM 7:4



The influence of arterial branching

which may not be supported by other objective evidence. Therefore, before entertaining these possibilities further, it is advisable to examine certain details pertinent to the interpretation of the arteriograms; and also to acknowledge the difficulty in reaching firm conclusions.

Firstly, it was observed that the extremities of an occluding thrombus sometimes extended a short distance up or down the artery in contact with the wall at one side; and indeed a free "tail" to the thrombus was not unusual at its distal end.<sup>1</sup> It may therefore be questioned whether the appearances which have suggested separation had not merely outlined the original formation and position of the thrombus. This possibility cannot be discounted. The detail of configuration of these channels, as seen in the arteriograms and in the sections, suggested to me that they had been formed mainly through separation of the thrombus from the arterial wall, but this must remain but an impression. It was also in keeping with this interpretation that more extensive channels were found in occlusions of several weeks duration than in those only a few days old; and that, in some lesions, the tapering ends of the channels led imperceptibly into narrow clefts between thrombus and intima which were more clearly secondary developments.

Secondly, it may be questioned whether the appearances suggesting separation had in fact been produced post mortem, by forcing injection medium under pressure between thrombus and the toneless tissues of the arterial wall. Again this possibility must be entertained and cannot in every instance be discounted. I do not think however that the appearances were artefact. In 14 ADA fresh blood was present in the cul-de-sac formed by the distal channel, suggesting (with the technique employed) that the channel was present in life; and on micro-section the tissues and thrombus did not appear to have been disturbed by forceful entry of injection medium between them. The appearances have suggested to me that a channel such as this was formed a considerable time before death; but again the point is not more amenable to proof than this.

---

1. 22 RC: The arteriogram shows the shadow of such a tail extending into branches.

Further suggestive evidence that such early channels existed in life was afforded by the striking resemblance which they bore to certain established blood channels found in lesions of old standing. A close similarity of arteriographic appearance may be seen between the primitive channel in 14 ADA and the distal part of the main branch of 22 ADA (art.2); or between 24 ADA and 25 RC, distal ends. The ages of these occlusions were respectively 19 days, 2 years, 9 days and "old standing". In each of the earlier cases the channel lay between the intimal wall and a mass of thrombus. In the older lesions it lay between intimal wall and a mass of atherosclerotic tissue. The atherosclerotic tissue in these older lesions bore evidence of earlier formation from thrombus, and still showed brownish pigmentation derived from altered blood and iron deposition. (For further details see Chapter 8). Close resemblance may also be traced between 14 ADA<sup>1,2</sup> and the old standing changes in 14 LCxA<sup>1,2</sup>, and also in 10 micro.<sup>3,4</sup> when the 2 mm. thick and micro-sections are examined.

After many sections through recent and old occlusions had been compared, the conclusion seemed almost inescapable that the earlier changes represented forerunners of the later. In older lesions it has seemed likely that channels coursing between unthickened intima on one side and plaques of material apparently derived from organisation of thrombus on the other, had originally developed on a basis of primitive clefts between thrombus and artery wall. I contend that the earliest stages in this process are mainly mechanical, and do not initially depend upon cellular agency or tissue growth. At a later date of course the process may be extended by cellular activity.

At least two factors may be at play in the early stages. (1) The clot may shrink and separation take place mainly at one point. Retraction of whole blood clot in vitro is well recognised, and is doubtless also a feature of laminated thrombus formed in the arterial lumen. (2) Spasm of the arterial wall may have

- 
1. 14 ADA 2:5a and b and 14 LCxA 3:6b.
  2. 14 ADA 3:1b and 14 LCxA 3:5b.
  3. 10 LCxA main branch, micro. 2.
  4. 10 RC 1:13 micro. 5.

been present at the time of thrombus deposition, and its subsequent relaxation allowed separation to occur. These possibilities are speculative, and not amenable to proof in human pathology. In some instances extensive calcification will preclude the effects of spasm and relaxation.

As already indicated the primary channels were simple spaces between thrombus and intimal surface. In older lesions the channels were lined by endothelium. It is generally supposed that endothelium spreads over the surface of the clot and so invests it in a continuous layer. In regard to the time required for this process on the other hand most authors are evasive, resorting to terms such as "speedily" (Dible, 1958), or avoiding the issue altogether. In my investigation the age of a high proportion of the lesions was known with a fair degree of certainty and I tried to establish the time relations of the changes. In regard to endothelial growth, however, I was at some disadvantage, caused by the employment of an injection method. Firstly, the close application of the dense injection medium to the lining of a vessel sometimes obscured detail at the interface and made it difficult or impossible to identify endothelial cells. Secondly, shrinkage of the gelatin mass often took place in paraffin sections, separating it from the intima. On occasion the intimal lining might adhere to the gelatin mass and be stripped from the underlying tissue. These defects did not interfere with the findings in every instance, but have prevented firm conclusions being reached from observation of certain lesions, which would otherwise have been critical. While the presence of identified endothelial lining can be stated with certainty, I must necessarily maintain a greater caution about its absence.

For the most part I was unable to detect a continuous endothelial lining in the primitive channels of only a few weeks duration. Isolated cells and groups of cells might nonetheless be found upon their lining; but where the lining was not continuous there was no certainty about the origin or nature of these cells. Investment of the clot at the proximal end of an occlusion was certainly present <sup>1</sup> at 3 weeks and endothelium lined some of the smaller blood

---

1. 14 ADA 2:1 micro.

spaces in another<sup>1</sup> at 8 weeks approximately. A definite endothelial coat always lined the new channels in lesions of 6 months and more in age.

As already remarked, were the process of separation of thrombus from arterial wall to extend the full length of the obstruction, it is evident that continuity of the arterial lumen could be restored. This was observed apparently to have taken place from one end or the other of certain occlusions or through the meeting and linking of channels approaching from either end. It might be expected that separation throughout the length of a thrombus would have taken place with greater readiness in occlusions of shorter length, and indeed I think this may have been so. In my series the only instances of successful canalisation of recent thrombotic occlusions by separation were found in lesions where the clot was less than 1 cm. in length. Thus, (1) thrombotic occlusion of only a few millimetres extent was already incomplete at death, 11 days after it had caused massive myocardial infarction (Case 13), (2) in Case 15, a rather longer occlusion was canalised by the time of death  $4\frac{1}{2}$  weeks later.<sup>2</sup> (Radiographic illustration of these lesions was somewhat obscured by calcification, which was extensive, but the interpretation of the radiographs was placed on a secure footing by the serially mounted 2 mm. sections.), (3) in Case 3 separation of clot from the artery wall also appeared to have been the cause of canalisation by the time of death 6 weeks later.<sup>3</sup>

Turning to the older lesions, it appeared in retrospect that the channels in many canalised occlusions of old-standing had been formed originally by the process of separation. The narrowed portion of artery (X) immediately below the recent occlusion in 24 ADA is probably a case in point. It may be seen in the section of this portion of the artery<sup>4</sup> that the lumen was placed between a large atherosclerotic plaque and the thin arterial wall; and further that the

- 
1. 16 ADA.
  2. 15 ADA (not illustrated).
  3. 3 ADA micro.
  4. 24 ADA 3:6a.

plaque has been formed in several layers. It also showed pigmentation from altered blood products. A similar narrowing is seen in the lower part (Y) of 18 ADA and in the upper part (X), 22 ADA. Many other examples were present in this series.

It has already been noted that a fairly large proportion of occlusions of old standing showed complete canalisation, whereas examples among the very recent occlusions were few. This was perhaps not surprising, but the most obvious interpretation was not necessarily the right one. (1) Thus it may be suggested that the process of separation continued for a long period of time and that therein lay the explanation of the higher incidence of successful canalisation among the older lesions. (2) On the other hand, early restoration of continuity of the arterial lumen may have increased the chances of survival; so that it might, on that account, be expected that a higher incidence of successful canalisation would have been found in lesions which had been survived (beyond the unstable first few months) than in occlusions which had been the immediate cause of death.

I tend to favour the second explanation. I think that there might be a time limit to the process of canalisation by separation of the thrombus from the arterial wall. Also I do not think that it may be safely inferred from the numerical disparity in my series between recent and old-standing canalised lesions that restoration of continuity by separation is an uncommon event within one month of thrombosis. (In this series only 1 case in 13 showed canalisation within 1 month.) It cannot be overstressed that the data of this, and for that matter of all other, pathological series were obtained solely from fatal cases. It is not impossible that separation of clot from intima may take place much more quickly in other instances - with benefit to the heart of such an order that the incident escapes the pathologist's examination. Indeed in some

cases of non-fatal arterial thrombosis it is conceivable that occlusion may have been complete only for a matter of days or hours, or even minutes, but I have no evidence which could bear upon this point directly.

In retrospect, one may only speculate on the exact nature of the early changes in older lesions, which have ipse facto been survived. Nevertheless, the occurrence of abrupt severe narrowing of the arterial lumen, eccentrically placed between an atherosclerotic plaque and the arterial wall, together with myocardial damage in the territory of such an artery not otherwise obstructed, is most readily interpreted on a basis of temporary occlusion and recanalisation. The grounds upon which the origin of atherosclerotic tissue in such lesions may be traced to changes taking place in thrombus are considered in Chapter 8.

#### "Fissuring", or Infiltration of the Clot

The second primary change that was observed was fissuring of the fibrinous clot and is illustrated graphically in Diagram 7:2 f-j. In 16 ADA 2:4a and 2:8a, 14 ADA 2:5a and 2:5b, 24 ADA 2:8a, and others, a common appearance in the injected specimen is seen. The injection medium has infiltrated into the substance of the clot as if into a spongework.

Again it could be held that the appearances indicated not so much a change in the thrombus as an uncovering of its initial structure. In the case of "fissuring" the distinction is not a matter of importance.

Infiltration of injection medium into the substance of the thrombus occurred only in the presence of fairly recent thrombus (up to about 2 months) and the appearances were more characteristically found in grey rather than in dark red thrombi, but not exclusively so. Accordingly, it was typically found at the ends of thrombotic occlusions, where the clot tended to be greyer than in its central portions.



Where there had already been separation of the clot from the artery wall this form of infiltration also arose on occasion from the channel so formed. A good example is seen in 14 ADA 2:3b and 14 ADA 2:4 micro.(1-7). In the micro-section it was seen that ill-defined, groping finger or root-like processes of injection medium were enclosed in the meshes of a fibrin network, which also contained red blood cells. Other meshes contained blood but no injection medium. This clot was about 3 weeks old.

The appearances suggested that the meshes of the fibrin clot had at one time been completely filled by cellular blood elements and that in course of time loose portions had been replaced by fluid blood; and in turn by injection medium. It was not clear, however, whether such loose blood elements (mainly red blood cells) had been washed out of the interstices of the fibrin network by the pulsatile flowing blood, like the sea may wash sand from between rocks; or whether they had been displaced into other interstices and packed more tightly, thereby making room for the invading blood; or whether a certain amount of haemolysis had taken place. Possibly all three processes were operative. (As soon as continuity was achieved and a through flow of blood established, then the first mentioned process would immediately be augmented.)

Nor was it clear whether greyish thrombus, composed mostly of fibrin, was in fact more readily penetrated by blood, and by injection medium, than was red thrombus; or conversely whether the occurrence of fissuring and tidal blood flow hastened the removal of red cell elements from thrombi, which were thereby rendered grey. I tend to favour the second explanation, but again both factors may have been operative.

There was no evidence at this early stage that the primitive channels were continuously lined by endothelium<sup>1,2,3</sup>. As in the case of channels formed by separation, cells resembling endothelial cells were found here and there on

- 
1. 14 ADA 2:4 micro.(6).
  2. 7 ADA 1 micro. (1,2).
  3. 9 RC (low power only).

the lining of the blood spaces in the fibrin lattice, but did not form a continuous coat.

Before undertaking this investigation, I had supposed that, canalisation of thrombus involved the process of organisation in the usual sense. I expected to find evidence of cellular activity of the macrophage type, accompanied by capillary formation. I had supposed that substance of the clot would be progressively digested away in the van of the invading vascular and fibroblastic tissue. Following my observations on thrombotic occlusions, I do not deny that these processes may occur: and it was evident that at a later stage they did. But I was much impressed by the finding that the primitive, blood-bearing channels which had developed in recent thrombi, as in a spongework, were in the first instance simple spaces in the lifeless thrombus; and were formed, for the most part at any rate, without cellular agency. Accordingly I have given greater emphasis to this feature in my description.

The imagination may be caught by the apparently purposeful direction and formation of these channels - as if seeking a passage through the clot and attempting to bring about restoration of the arterial lumen, or vascularisation of the thrombotic mass. And indeed both these objectives may be reached. I would stress, however, that there is no more justification for attributing purpose to the infiltrative process at this stage than to the passage taken by rain water after drought through fissures in the soil. Both phenomena are purely mechanical, and the result of inanimate forces.

The description of the process of primitive blood-channel formation in thrombus given so far has been based on the observation of lesions of a few days up to 6 or 8 weeks duration. Thereafter the part played by cellular agency came increasingly into evidence. It will be appreciated that no exact time relationship for the changes observed can be given, and that different stages of the process could be found taking place concurrently at different levels in the same lesion.

In sections taken from the distal end of a thrombotic occlusion, judged to be about 8 weeks duration from the related myocardial damage, there was no doubt that a number of small channels had been lined by endothelial cells.<sup>1</sup> In some, the endothelial lining was complete and was supported on a layer of condensed fibrin. In others, a nucleated cell was placed to one side of a lacuna, almost as if to suggest it had been responsible for the removal of the material in its neighbourhood. Some of these cells were flattened against the lining of the spaces which they occupied, and it seemed not impossible that they represented transitional stages between macrophages and endothelium. It is quite likely that the continued invasion of the clot by blood channels might be assisted by the fibrinolytic agency of cells such as these; although, as already remarked, cellular agency did not appear to have been part of the mechanism involved in the earliest stages. More deeply placed in the same occlusion,<sup>2</sup> endothelial lining to the blood filled channels could not be discerned.

At a still later stage (6 months - 2 years) a similar formation of small tracks filled with injection medium was found.<sup>3,4,5</sup> There were however important differences. Although the same basic pattern was detected, the channels were now more defined and had taken on a closer resemblance to definitive blood vessels, as distinct from blood filled spaces in a spongework. On micro-section it was seen that such vessels had a definite lining. In some the endothelium was supported on little more than a condensation of fibrin.<sup>3</sup> This lesion was not more than 6 months in age. But in the two older lesions quoted above, and in others<sup>6,7,8,9</sup> the small channels were each invested in a definite vascular coat in which the endothelium was supported on fibrous and, in some instances, elastic tissue. (Indeed some workers using special stains have described muscle cells as well but of these I was not certain in my preparations.)

In these lesions the substance in which the small vessels lay /

- 
- |                      |    |                        |                     |
|----------------------|----|------------------------|---------------------|
| 1. 16 ADA 3:1 micro  | 3. | 4. 22 ADA 4:4a         | 7. 11 ADA 2:2 micro |
| 2. 16 ADA 2:6 micro  | 2. | 5. 23 ADA 2:10a        | 8. 11 RC 1/8 micro  |
| 3. 24 RC 2:5b, 2:8a, | 3. | 6. 25 LCxA 2:5b(colour | 9. 1 ADA micro 2    |
| 3:5a, 5:7a, etc.     |    | transparency)          |                     |

had likewise undergone change. It was no longer fibrinous material but was a fibrous type of atherosclerotic tissue. Some portions of this tissue stained with the tinctorial qualities of "fibrinoid". In the atherosclerotic tissue in the immediate neighbourhood of the small vessels lipid tended to be scanty, but was not entirely absent.

It has been my impression that these definite arterial vessels which have "invaded" the thrombus from the lumen of the artery have also had their origin in the irregular spaces in the fibrin network. Intermediate stages could be traced. Indeed well-formed endothelial-lined channels at one end of an occlusion could lead into old thrombus which had been incompletely organised; and as this material was entered the character of the channels changed, to form ill-defined, sinusoidal blood spaces. 24 RC shows such an appearance, as does also the lower part of 22 ADA.

I conclude from my observations on these channels that the mechanically and fortuitously formed fissures in the early blood clot form the mould in which the organised blood vessels are later cast. If indeed this be the case, then one might expect that, initially at any rate, these blood vessels would lack the smooth tapering outlines of primary blood vessels; that they would be of irregular calibre; and would carry in their formation the stamp of their origins. Thus they might be expected to show purposeless bulges and constrictions, divisions into several channels and their joining up again, blind alleys, and tortuosity. When in fact we look at the arteriograms of such obstructive lesions with these features in mind, all may be found (e.g., 25 LCxA, 24 RC, 23 ADA, 22 ADA, 18 ADA, 5 LCxA). The stereo-arteriograms are more eloquent than any verbal description.

It was noticeable that the canalising processes which were found in relatively early, and also in older but still complete, occlusions often

EXAMPLES OF CANALISATION : Stereo-pairs

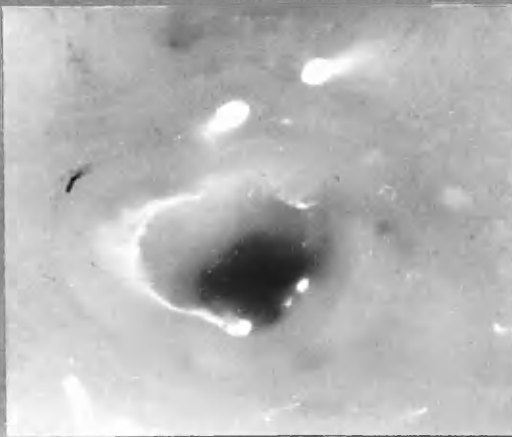
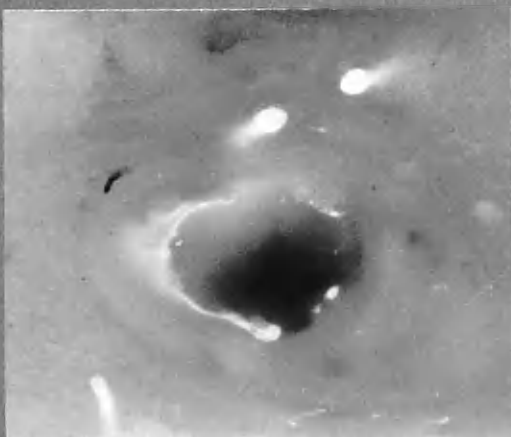
2 mm. thick sections

See also 22 ADA 4:4 a stereo.

"Separation"

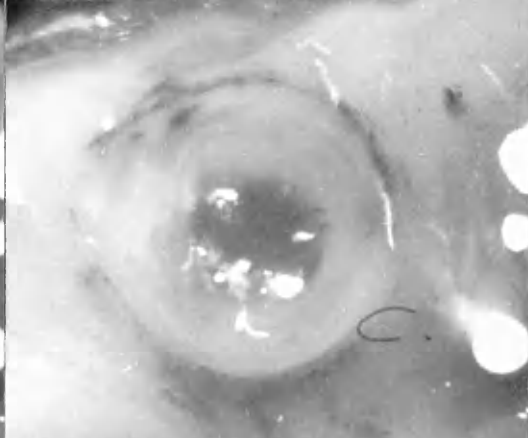
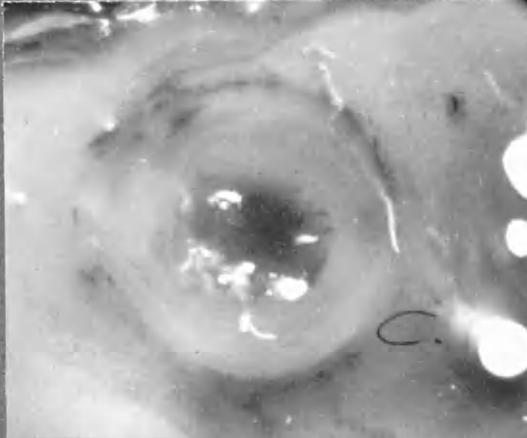
15 ADA

3:6 a.

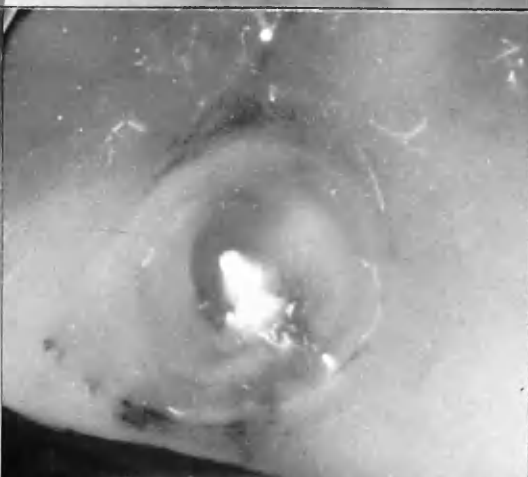
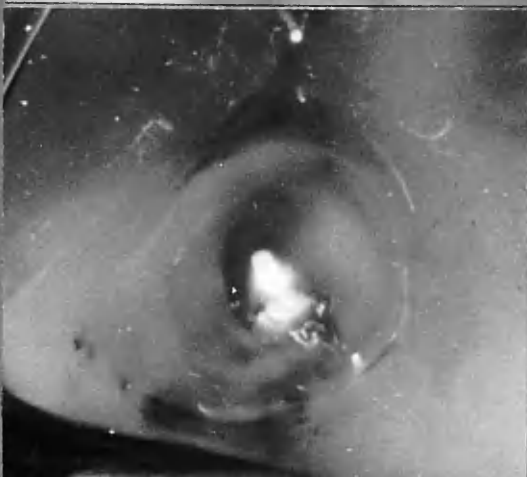


"Separation"  
+  
"Pressing"

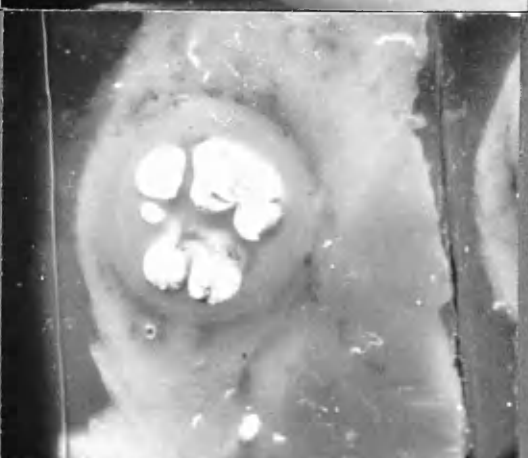
11 ADA  
branch.  
4:4 a.



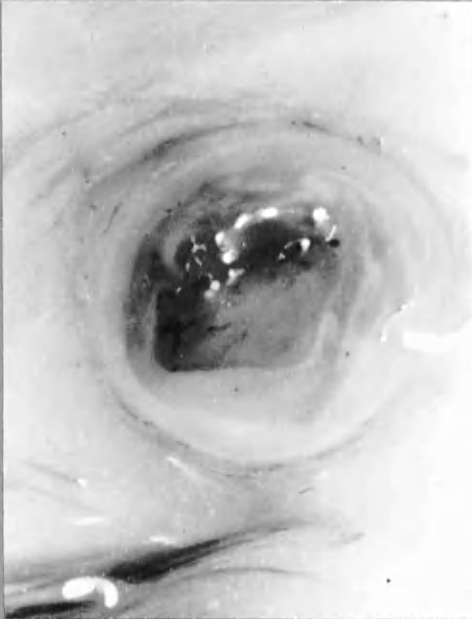
11 ADA  
branch  
5:1 b.



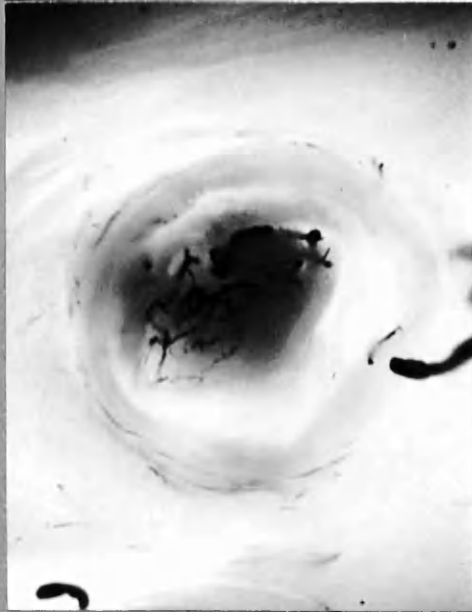
11 LCxA, branch  
1:5 a.



24 RC 3:4 b.



A



B.

A Photographed by incident light.

B " " transmitted "

Small vessel in thrombus (c. 6 months). Entry of injection medium was halted, apparently by secondary thrombosis in the small canalising vessels themselves.

involved a multiplicity and complexity of smaller channels. Whereas in lesions which had been completely canalised, continuity of the lumen had usually been restored by one, or a few, larger channels; and the complexity of smaller channels, which characterised incompletely canalised occlusions, was conspicuously absent. It was thought that in some instances the relatively uncomplicated nature of certain lesions may have been but a reflection of the original simplicity of the process which brought about canalisation in the first instance (i.e., the channels involved in the canalisation of such lesions were few from the beginning). In other lesions I think it is likely that there had been some regression of lesser channels, a process which would lead to simplification of the lesion with the passage of time. When union of channels approaching each other from the proximal and distal ends of an occlusion had restored continuity of the lumen, it is probable that in the course of time the larger channels, and those placed more directly in the course of the renewed blood flow, would tend to become more firmly established, and to enlarge still further for a time; while the smaller and more devious channels would tend to be obliterated. In 24 RC 3:4b the dark outlines of channels in the paler thrombus are due to blood. A trickle of injection medium has penetrated to this point and there been halted; although it could readily have penetrated channels of smaller calibre than these had they been unobstructed. I think that the channels seen in this section were occluded by secondary thrombosis. It is likely that their ultimate fate would be organisation and obliteration.

Thus, in some cases, single, though somewhat tortuous, channels traversing old-standing canalised thrombotic occlusions may represent the only channel remaining after the obliteration of subsidiary channels. In most instances however it is probable that single channels coursing through old occlusions have been formed in the first instance by the process of separation of the thrombus at one point on its circumference, as first described. Such channels are typically eccentric in position, situated close to the thinnest part of the arterial wall.

Crawford, 1955.

"If the subject survives after complete occlusion of a vessel the subsequent structural changes may take one of two courses:

(a) A new lumen may develop quite quickly by retraction of the thrombus, the thrombus becoming separated from one side of the vessel. Organization converts the retracted thrombus into an eccentric thickening of the intima, and the net result is simply an increase in thickness of the original plaque at which thrombosis developed.

(b) If the thrombus fails to separate from one side of the vessel as it retracts, then no main lumen will be re-established, but, instead, several small channels will develop. These result from fusion of the capillaries which extend into the thrombus during the process of organization and sometimes they are so numerous as to amount almost to cavernous transformation of a segment of the vessel. These new channels seem often to be of only temporary value to the circulation, for one often finds evidence of the thrombotic process being repeated in them.

Crawford, T., 1955 Proc. Roy. Soc. Med. 48: 661  
Discussion on coronary artery disease: "The morphology of coronary atherosclerosis in man."

---



"Separation" and "Fissuring" Combined

Sharp distinction between the two primary processes, separation and fissuring, could not always be made. In a number of instances they appeared to have proceeded, as it were, hand-in-glove. (See Diagram 7:3, k-n.) The early part (X) of the lesion in 24 RC art. is a case in point. The new channels were deeply placed in the artery. The radiograph would suggest that the network of fine channels so formed, which has a fanciful resemblance to the coloured spirals in the centre of an old-fashioned glass marble, was an example of fissuring. But when the transverse sections<sup>1</sup> through this area were examined it was evident that the vessels composing this network were interposed between the thrombus and the thickened intimal wall. The process in this lesion therefore shared some of the features of fissuring and separation. This is a common finding, although this is a particularly good example of it.

Indeed, in older lesions those channels which had penetrated far into the occlusion apparently by the process of fissuring, and especially those which had linked up from either end, were usually running in the junctional zone between tissue formed from the most recent episode of thrombosis and the previous intimal wall, and not through the depths of the clot itself. Where the lumen before thrombotic obstruction was already severely narrowed, then the channels might appear at first glance to have penetrated through the centre of the lesion. But when, for instance, the finger-like processes in 23 ADA art. were examined in section, it was seen that the lumen of the artery had been narrowed to about half its original diameter before the final episode of thrombosis.

It seemed to me that channels developing in the plane of cleavage between intima and thrombus tended to be guided in an apparently purposeful direction in the long axis of the artery. In that way they were more likely to travel the

---

1. 24 RC 2:5b, 2:7a, 2:8a.

full length of the obstruction and so effectively to restore continuity of arterial lumen. By contrast, channels which were formed in more aimless fashion in the substance of the clot appeared to have less chance of reaching this objective.

In many instances the direction of some of the channels in the substance of the thrombus was oblique or at right angles to the long axis of the artery. Such channels could arise from the eccentrically-placed primary channel formed by separation. I think it is likely that many of intimal vessels arising from the narrow lumen in the neighbourhood of old-standing obstructive lesions had been so formed originally.

In the processes of separation and fissuring, the new channels were found either within the substance of the thrombus, or between it and the underlying intima. I wish to stress this point. In no instance did injectable vessels, which appeared to take part in canalisation of thrombotic occlusion, enter or traverse the previously formed intimal coat. This rule was invariable, both where the intimal coat was the seat of atherosclerotic thickening and where it was nearly normal. No matter the nature of the atherosclerotic plaque underlying thrombosis, the new vessels formed in the early stages of canalisation were never observed to invade it. These early vessels were entirely confined to the previous lumen of the artery as it existed before occlusion (so far as could be judged in retrospect).

The appearances of older lesions in which the thrombotic material had been converted into atherosclerotic tissue were also entirely in keeping with the earlier findings. Thus the channels taking part in canalisation were almost encapsuled in an investing layer of relatively translucent and lipid-free fibrous material which had, with little doubt, been formed from thrombus. Many examples may be found in the illustrations, especially the thick arterial sections photographed by transmitted light (e.g., 23 ADA 2:10a, 22 ADA 4:4a stereo).

There are however a few points to raise in regard to these absolute statements, lest they be misunderstood:

Firstly, it is to be noted that the small vessels referred to were those arising from the lumen, and did not include small vessels arising from the vessels of the adventitial coat, which may accompany organisation of atherosclerotic tissue or thrombus (see Chapter 8).

Secondly, at the site of thrombosis there was often intimal haemorrhage. Sometimes this took the form, or so it appeared, of rupture of blood from the lumen into the intimal plaque. On occasion this might be followed by injection medium after death and the appearances suggest that the process of canalisation had also invaded the arterial intima (15 ADA 3:3a stereo.). Again, previously formed primitive intimal vessels which had evidently arisen in connection with an earlier episode of thrombosis might communicate with a channel formed after a later episode. An example of this may be seen in 14 ADA 2:3b and 2:4 micro. A single micro-section is more liable to misinterpretation than one whose micro-anatomical relations can be determined. With care these pre-existing features could be distinguished from changes which had clearly developed as a sequel to recent thrombosis. No difficulty arose at points in occlusions where the underlying intimal surface had evidently been intact at the time the thrombus was formed.

Thirdly, anatomical branches leaving the artery at the site of severe atherosclerotic disease were often grossly distorted and narrowed as they passed through the thickened intimal tissue. Moreover, small vessels might arise from these branches and enter the intimal plaque. Indeed, so often was this phenomenon observed that I should regard the anatomical branch in transit through atherosclerotic thickening as one of the commonest origins of intimal vessels, a point which was also recognised by Wintermitz et al., 1938. These details are

important because the anatomical branches, and the vessels arising from them before their exit through the internal elastic lamina, may add confusion to the arteriographic picture in canalised and partially canalised occlusions and their status be wrongly interpreted. Thus, on section, the appearances may on occasion falsely suggest that the occluded area had been invaded by these vessels from without. In some sections it even seemed as if the atherosclerotic tissue had been canalised by them and that they had, so to speak, been attempting to reach the lumen and to take part in the canalisation of the occlusion itself.<sup>1,2,3,4</sup> On careful examination however the changes in these branch vessels were seen to be the reverse of what at first glance they appeared to be; and the vestige could be distinguished from the rudiment.

In the radiograph of section 14 LCxA, the vessel of larger lumen, outwith the wall of the main artery, is of approximately its original size. The narrowed channel which communicates with the lumen is simply all that remains of the original branch lumen as it passed through the intima. Likewise in the examples already given (1,2,3) and in section 24 ADA 3:2a the finger-like processes which appear to probe into the occlusive thrombus merely represent all that survives of the branch lumen before occlusion. In some instances the appearances had evidently resulted from encroachment on the origin of the branch by intimal thickening. In others the small channels were clearly the product of canalisation of the thrombus obstructing the branch itself, as in 24 RC 2:8a. The misleading impression which might be given by a random section through this lesion needs no further emphasis.

- 
1. 24 RC 4:1b.
  2. 24 RC 2:8a.
  3. 24 RC 2:7a.
  4. 22 ADA 3:3a, 3:2b.

Time-limit in Canalisation

The manner in which the vessels directly taking part in canalisation of thrombotic occlusion were restricted to the confines of the previous arterial lumen introduces a concept of importance. For it has seemed from the foregoing observations that the organised atherosclerotic tissue composing the intimal wall was much more resistant to the formation of new vessels within its substance than was thrombus.

I envisage a race against time in the process of canalisation. On the one hand the fissuring and separation, described above, prepare the way for the formation of new channels. On the other, at least two changes in the thrombus itself tend to retard and even halt the progress of canalisation.

1. Sclerosis: the result of organisation. The first of these is the fibrous change which takes place in thrombi, which leads eventually to the formation of fibrous atherosclerotic tissue. (This process is described in greater detail in the next chapter.) Fibrous change seemed to occur with greater readiness in the grey thrombus characteristically found near the ends of occlusions. Accordingly at these levels a section would often pass through several channels of fair size, embedded in semi-translucent sclerotic tissue which formed a sort of core, surrounded by the previous atherosclerotic intimal wall. Several examples may be found among the 2 mm. thick sections<sup>1,2</sup> and micro-sections.<sup>3,4</sup> As one follows their course more deeply into the obstruction the channels tend to become smaller and sometimes more numerous and complex, as for instance in following the main stem occlusion upwards in Case 22 ADA art. Z. The impression may be gained, both from the arteriograms and from the sections, that in life these small vessels were actively growing and were invading the sclerotic tissue. I suggest that this impression might well be in error. It is not easy to determine whether these structures were in fact increasing in size or

- 
1. 23 ADA 2:8a, 2:9a, 2:10a.
  2. 22ADA 4:4a, 4:5a.
  3. 7 RC micro. (2,3).
  4. 5 LCxA micro. (1).

number or were static or even regressing at the time of death. Again, if we pass higher up the same artery it can be seen that a fairly long stretch of successfully canalised occlusion has been interrupted by a short obstruction (Y). From the distal end this obstruction has been penetrated by a tapering finger-like process which has come within an ace of establishing continuity. Or so it would seem. Giving reign to the imagination, it seems such a pity that death should have interrupted this beneficent process of canalisation, already so far advanced and just as it was so near to completion; and the new channel so formed might conceivably have been life saving. But this fancy may be without solid foundation. It is quite possible - and indeed probable - that the process of canalisation in this lesion had been halted for a long time; and that no matter how much further time had been available continuity would never have been established. The gap was blocked by firmly organised sclerotic tissue. It may well have been that the time for further changes had passed. The occlusion in question was 2 years old. In 24 RC similar appearances are seen after 6 months.

I found little to suggest that new vessel formation readily took place in sclerotic tissue. Indeed the opposite appeared to be the case. The manner in which the vessels taking part in canalisation were contained within the confines of the previous lumen (now occupied by thrombus) seemed to indicate that new vessel formation proceeded more rapidly in this material, and led to channels of considerable dimensions. It also indicated that collagenous material by contrast did not favour invasion by blood vessels. The appearances were more in keeping with the development of collagenous material around the blood channels already formed in the fibrin network than the other way round. I cannot deny the possibility that vessels of capillary size may grow out into the collagenous tissue after its formation. I simply have no clear evidence to this effect.

The most numerous injectable vessels (with the medium used) were found in the six months old occlusion in 24 RC in which thrombotic material was still recognisable. I think it is likely that by the time the fibrin network has been fully replaced by collagenous tissue the main opportunity for successful

canalisation has passed. Thereafter progress may perhaps continue slowly; but it is equally possible that progress may be halted indefinitely and regression of the channels and their secondary obliteration set in.

2. Necrosis. Replacement of the fibrin network by collagen was not the only change in old-standing thrombi observed to have an adverse influence on canalisation. Necrotic changes were often evident in the central parts of occlusions of greater length, as for instance 11 ADA<sup>1</sup>, 12 ADA<sup>2</sup>, 7 RC<sup>3</sup>. The material in these central necrotic areas was essentially similar to the material found in "atheromatous abscesses", including its content of lipid.<sup>4,5</sup> The semi-liquid material composing these central areas seemed to oppose an impenetrable barrier to the development of new blood channels. Accordingly in lesions such as those quoted above<sup>1,2,3</sup> there were stretches of occluded artery of more than 1 cm. in length in which no injected blood vessels were found. In other instances a narrow channel, evidently formed originally between thrombus and intimal wall, lay to one side of an orange-brown stained mass of necrotic material, which showed no evidence of vascularisation by injected vessels. (See, for instance colour transparency of 22 ADA 2:5B.) It would seem that for the process of canalisation to be successful, continuity of lumen must be achieved before a barrier of necrotic material has had time to develop. Conversely it is probable that the arrival of new blood channels may favour the organisation of the thrombotic material and delay the advent of necrotic change.

There is, as it were, a season for successful canalisation. With the mechanisms available, the cutting of irrigation channels can only be accomplished in the soft soil of thrombus, and cannot proceed when the ground is hardened by fibrosis or rendered boggy by degeneration. But with this difference - there is no return of the season in coronary occlusion.

- 
1. 11 ADA arteriogram.
  2. 12 ADA 2:5 micro.
  3. 7 RC not illustrated.
  4. 10 RC 1:13 micro.
  5. 7 ADA micro. (2).

SOME FACTORS WHICH MAY INFLUENCE THE CANALISATION OF  
THROMBOTIC OCCLUSIONS OF THE CORONARY ARTERIES

Thrombotic occlusions of the coronary arteries were seen to be the product of many factors compounded in infinite variety of quantity and sequence. Some of these factors were definitely recognisable, being of a structural nature, while others were functional or speculative.

Definite:

1. Anatomy of the occluded artery including the detail of its branches.
2. Position of the occlusion.
3. Dimensions of the thrombus.
4. Underlying changes in the artery wall, intimal thickening and encroachment of the lumen.
5. Composition of the thrombus.
6. Age of the occlusion.

Speculative:

7. Collateral enlargement.
8. Contraction and relaxation of the arterial wall.
9. Secondary thrombosis, and anti-coagulant therapy.

In general terms, the importance of the extent of an occlusion and its position in relation to the arterial anatomy is obvious. The manner in which these factors influenced the configuration of occlusions will have been apparent in the specimen arteriograms already considered and will be further elaborated later in this chapter.

Intimal Thickening and Encroachment on the Lumen

The degree to which the lumen of the artery had already been obstructed before thrombotic occlusion was seen to vary greatly. Before an accurate assessment of the situation in a particular occlusion could be made, it was necessary that the entire length of the obstructed portion be examined. Thus a single section taken through the centre of a given occlusion might reveal a previous lumen of, say, 2 mm. in diameter. When serial sections were followed



through the full length of the same obstruction it might well be found that the anterior lumen had previously been throttled down to 1 mm. or less, possibly for only a very short distance. The serially mounted 2 mm. thick sections were of the greatest usefulness in investigation of this feature. (An indication of the previous lumen, in two dimensions, is provided by the drawings on transparent sheets placed in front of the stereo-arteriograms.)

While thrombotic occlusion was shown to have involved arteries in which previous narrowing of the lumen from atherosclerosis had not been great, in about half the obstructive lesions in this series the lumen had been reduced by 50 per cent or more  $\phi$  beforehand. (See Diagram 5:1)

It was readily appreciated that a short stretch of severe narrowing of the previous lumen could have a profound influence on the process of canalisation. It has already been emphasised that the newly formed vessels were restricted to the confines of the previously existing lumen. At the best therefore only a fraction of the original lumen could be restored. It need hardly be pointed out that a great difference in terms of useful capacity for blood flow exists between a channel which may develop as a fraction of 2 or 3 mm. diameter and one which can be no more than a fraction of 1 mm. (The significance of narrowing of the lumen diameter to 1 mm. or less is examined in Chapter 5)

It also seemed likely that a sufficiently severe degree of previous narrowing might completely prevent effective canalisation. In several examples in this series canalisation apparently by separation of thrombus from intimal surface had evidently occurred along a considerable length of the artery where the previous lumen had not been greatly narrowed. 25 RC shows such a stretch about 2 cm. in length and other examples are seen in 22 ADA, 14 ADA and LCxA, 16 ADA. Sometimes the process seemed to halt at the point where more severe narrowing of the previous lumen began, e.g., 14 ADA. It was thought that

$\phi$  i.e., in diameter.

separation of the clot from the vessel wall may have taken place more readily where the clot was large than where it was small on cross section. On the one hand the forces produced by shrinkage would have been lesser in clots of smaller dimensions. On the other, generally speaking, the smaller the lumen the lesser the distensibility of the surrounding vessel wall, because of its greater thickness.

One might further suppose that the process of separation would proceed the more rapidly where the previous lining of the occluded stretch of artery was smooth and there was no great variation in calibre; and that the converse would obtain where the intimal surface in contact with thrombus was disrupted by recent disease. Again, canalisation by the infiltrative process, being dependent on fissuring of the clot and being therefore a slower process, was less likely to effect continuity except in very short occlusions.

#### Composition of the Thrombus

The impression was gained that grey fibrin thrombus was more readily converted into collagenous tissue than was red thrombus. It was further observed that the larger new channels in the older lesions were commonly embedded in a substantial layer of translucent collagenous material. It might therefore have been concluded that fibrin thrombus was also the more readily canalised, and that the nature of the original matrix was a major factor in the development of blood channels. This may well be so. It is however but one of the many features of atherosclerosis and coronary disease in which cause and effect cannot at present be clearly distinguished, or in which cause and effect are reciprocally interwoven. Thus it may equally have been the case that the presence of primitive channels in thrombus led to the removal of red blood elements in their vicinity; and that through this agency the same channels came to be embedded in material which was predominantly fibrinous in the early stages, and predominantly collagenous in the later. The difference may therefore lie not in the original

quantitative composition of the thrombus, but in the readiness with which it separates from the intimal wall or undergoes fissuring, thereby favouring the washing out of cellular elements or their breakdown products from the meshes of the fibrin network.

Nor did it always seem that the predominantly collagenous material which characteristically surrounded the new channels was necessarily formed from material that had contained mainly fibrin and relatively little red blood at the time of collagenous change. In several instances<sup>1,2,3</sup> the translucent material in which the canalised channels lay contained extensive deposits of iron. The presence of iron in large quantities would strongly indicate an abundance of red blood elements in the original composition of the clot. Indeed in the lesions quoted the quantity of iron present was greater than in many lesions in which derivation from red thrombus was more obvious. (This would further suggest that factors other than the original composition of the clot dictated the quantity of iron that remained after organisation in the arterial intima.)

Although lipid deposition was sometimes found in the translucent core surrounding new channels and formed from thrombus, lipid deposits were characteristically scanty in the immediate neighbourhood of these structures. By contrast abundant lipid was found in the outer portions of these lesions. In some it was apparent that the outer portions represented previously existing atherosclerotic plaques. In others this was not obviously so, and the possibility could be entertained that they too had been the product of change in the occluding thrombus.

The manner in which thrombus was laid down may also have had influence on canalisation. It was evident on examination of the cut surface of thrombus as seen in the 2 mm. thick sections that thrombus formation had often taken place in layers (see 14 ADA 3:1b and colour transparency). As a rule the layers were ill

- 
1. 25 RC 4:3 micro. (P.B.R.) and colour transparency 2:5b.
  2. 18 ADA 1:8 micro.(P.B.R.).
  3. 5 LGxA micro. (P.B.R.).

defined and probably did not indicate any great difference in the time of their deposition. In others the layers had evidently been formed in separate episodes. It was thought that layering in this fashion might have provided planes of cleavage which would favour the formation of new channels. This appeared to have been the case only in instances where the layers were clearly defined and presumably of different ages.

#### Possible Influence of Anastomotic Enlargement

In the race between favourable and adverse factors in canalisation of thrombotic occlusions of the coronary arteries, I wondered whether the development, or previous presence, of enlarged collateral vessels might have an influence.

(1) It occurred to me that a gradient of pressure from one end of an occlusion to the other might favour the initial stages in the development of blood channels. In so far as the enlargement of collateral channels which by-passed an occlusion might reduce or annul this gradient of pressure, it seemed possible that anastomotic enlargement might have an adverse influence on canalisation. It was not however possible to bring any evidence to bear upon this possibility. Clearly in the case of old-standing lesions it was impossible to distinguish between the effect of enlarged anastomoses on completeness of occlusions and of occlusions on the enlargement on anastomoses. It can merely be stated that anastomotic enlargement was usually more advanced in the presence of complete occlusions of old-standing than in the presence of canalised occlusions.

(2) On the other hand, it was noted in a small number of occlusions that the track apparently formed by separation of thrombus from artery wall had apparently proceeded to a greater length from the distal than from the proximal end of the occlusion. One might speculate about the possible influences which could have had a bearing on this finding. In this connection I wish only to

raise the possibility that anastomotic enlargement may have played a part, and in the following way. After occlusion, or immediately beforehand at a point when narrowing was extreme, there would be an interval of time during which the intra-arterial pressure distal to the obstruction would be less than on the aortic side of it. The arterial walls beyond the first point of occlusion would accordingly have been distended to a lesser degree and the arterial lumen reduced (provided of course that the artery was not rigid at all points) without necessarily involving changes in tonus of the medial coat. In conformity with the smaller lumen size, thrombus formation occurring at this interval of time would therefore have a dimension in section somewhat less than the maximum for the lumen in which it lay. When, in the course of time, collateral development should have brought about a rise in the intra-arterial pressure distal to the occlusion then there would have been a tendency for the artery wall to stretch to separate from the thrombus. Experimental evidence would suggest that following occlusion of a coronary artery in a previously normal circulation the pressure distal to the obstruction falls immediately to a very low level and that no significant change takes place in this pressure for several days but after a week or so the peripheral coronary pressure is elevated considerably, ultimately reaching nearly normal levels (Gregg, 1950).

It is conceivable therefore that collateral development may have both favourable and unfavourable influences on the process of canalisation. The possibilities considered above are of course entirely speculative. In this respect they are in the same category as "spasm" and subsequent relaxation of the coronary arteries in the presence of thrombotic occlusion - factors which might exert a similar influence on the separation of thrombus from the arterial wall.

The linking-up of new channels arising from the proximal and distal ends of a thrombotic occlusion results in an end-to-end arterial anastomosis within an artery. The functional status of such channels through which blood can flow uninterruptedly is clear. But what of the remaining channels which have not taken part in effecting continuity of the arterial lumen?

The position of these other channels was not fully elucidated in this investigation. I am certain that in the first instance they were but spaces in the blood clot and that they were blind (except in those instances where end-to-end continuity was established early). As they developed into more organised structures they came to resemble other small arteries and one would not have been surprised had they led into a capillary bed and thence into veins. An extensive capillary network in established atherosclerotic intimal thickening was demonstrated by Winternitz et al., 1938, using Indian ink injection, and in some instances communication with veins was thought to have been found by these workers. In my own preparations I was not able to demonstrate capillaries in the ordinary sense in communication with the vessels arising from the arterial lumen. In some instances the vessels could be seen to lead into thin-walled sinusoidal blood spaces. I was left in doubt whether these spaces had venous communication or were simply blind, in which case the only movement of whole blood would be to-and-fro with systolic and diastolic pulsation. This form of blood movement would be out of keeping with what is known of the conditions of blood flow at other sites and accordingly on first principles its occurrence is to be doubted. The concept should not however be summarily dismissed on those grounds alone and without examining closely the conditions of blood flow likely to obtain within the wall of an artery. There seems little doubt that the conditions of blood flow are peculiar to this site, and not found in other tissues.

1. The pressure filling the intimal blood spaces derives from the pressure within the arterial lumen. At each phase of the cycle this pressure must be balanced, or nearly so, by the resistance offered by the internal elastic lamina and structures lying outside it. The thickened intima and the blood spaces within it are compressed between the pressure in the arterial lumen and the counter-pressure of the internal elastic lamina. But for the counter-pressure the poorly supported thin walled intimal blood channels would inevitably rupture. Providing that the structures surrounding them remain intact there must be very considerable obstruction offered to the entry of blood into these channels. Any local weakening of the counter-pressure as from stretching of the internal elastic lamina will of course alter the situation profoundly and could precipitate the sudden charging and rupture of these channels, but that is another matter. It seems to me that while equilibrium is maintained in the structure of the arterial wall the blood entering or leaving the intimal blood channels will do so largely under the influence of fluctuations in pressure, and not under a gradient of pressure with arterial-venous direction. Factors which may play a part include the variations of systolic and diastolic pressure, modified by the influence of intermittent changes in velocity of flow, and the elasticity, inertia and irregularity of thickness and consistency of the diseased intima. Further consideration of these factors is outwith the scope of my investigation - and indeed my comprehension. I find it possible however to conceive of variation in pressure relations within the arterial wall, dependent on the influence of pulsatile blood flow yet sufficiently out of phase with it to permit tidal blood flow within the intimal blood channels.

2. In many portions of the coronary tree in my own preparations, and in those of others, no intimal vessels were found even in the presence of considerable atherosclerotic thickening. It appeared that for the most part the metabolic requirements of the thickened intima had been supplied by the percolation of

plasma through its substance without the agency of definitive blood channels.

3. Had the intimal vessels, arising from the lumen of the artery, outlet through a capillary bed into venous channels lying in the outer coat of the artery, one might have expected, in view of the high pressure gradient, short distance and nature of the structure of the vessels concerned and the friable nature of their supporting matrix, that arteriovenous fistulae would have been common findings in coronary artery disease. I had no instance of such a lesion. At any rate, one would have expected that the establishment of sustained forward flow from artery to vein would have favoured the persistence of intimal blood channels as permanent structure in the same way as channels taking part in successful canalisation of occlusion tend to become established. And yet I found that such channels were more numerous in comparatively recent lesions (up to 6 months), and were scanty in older lesions. From this observation it may be inferred that - with the exception of channels through which continuity was restored - regression was the usual ultimate fate of small vessels taking part in the process of canalisation. Secondary obliteration seemed a fate more in keeping with blind channels than with channels subject to ordinary arterial conditions of blood flow.

I am therefore not disposed to discount the possibility that the ordinary condition of blood flow in the primitive intimal vessels, which have had their origin in thrombus, is tidal and that for the most part these channels are blind. I cannot justifiably draw firm conclusions on these points from my own preparations, for the demonstration of truly capillary channels by injection was outwith the scope of my examination: failure to demonstrate capillary and venous connections such as described by Winternitz et al. does not prove their absence. In this connection it may be noted that similar conditions exist during post-mortem injection and in blood flow in life in regard to the pressure relations between the arterial lumen and intima and the counter pressure of internal elastic lamina



and outer walls. On this account the filling of intimal channels by injection medium is not so readily achieved as is the case with small vessels at other sites. I did not use pulsatile injection for fear of causing unnecessary trauma to friable post-mortem tissues. It is possible that pulsatile injection might have revealed intimal channels not filled by the method used. Winternitz et al. routinely employed pulsatile injection of the coronary arteries, together with pressures far in excess of that which I employed.

Recent thrombosis of small channels in older lesions was occasionally observed. Recent thrombosis was found in the upper part of a blind(?) channel in a lesion 2 years in age (22 ADA 3:7b). Thrombosis was also noted in more recently formed channels, as in 11 RC 1:8 micro. after perhaps 3 months and in 24 RC 3:4 at 6 months. In this way early and sometimes successful attempts at canalisation may have been brought to naught. The surprise was how seldom this phenomenon was witnessed, or at any rate recognised. It is possible that secondary thrombosis would not have been distinguishable from comparatively recently formed thrombus in early lesions and may therefore have been overlooked. It is also possible that anticoagulant therapy may have contributed to a reduced incidence of secondary thrombosis in early canalising channels. It was not possible to assess whether the thromboses of this order which were observed had in fact taken place before or after the commencement of anticoagulant therapy in the terminal illness. The point is obviously one which could have great importance but for lack of sufficient evidence the matter is not laboured further here. It may be noted however that Wright et al. 1953 reported accelerated recanalisation of occluded femoral arteries in rabbits receiving anticoagulant therapy. The arteries involved were not of course of a scale comparable to the coronary arteries of man.

Although I have suggested that the primitive blood channels commonly regress and become obliterated, before leaving this topic I would draw attention also to my earlier proposition: that many of the small channels which may be witnessed in the earlier stages of canalisation of thrombotic occlusion may remain as intimal vessels, after a single main channel carrying through blood flow has emerged.

THE "AGING" OF THROMBOTIC OCCLUSIONS OF THE CORONARY  
ARTERIES

---

In this series the age of thrombotic occlusions was for the most part determinable by correlation with the corresponding clinical episodes of myocardial infarction. In some cases the history was doubtful in respect of myocardial ischaemia and sometimes entirely absent. In these circumstances estimation of the approximate age of arterial occlusions was made from the apparent age of the related myocardial damage.

When the arteriographic, gross and microscopic features of coronary occlusions were examined in relation to the assumed age of the lesions, correlation was found possible only in the broadest terms. I was unable to derive criteria which would permit the "aging" of occlusions except within very wide limits. I have found no criteria in reported series which would serve as guides to the age of occlusions, comparable to the criteria of Mallory et al. 1939 for myocardial damage. It only seemed possible to divide the lesions into very recent, intermediate and old-standing groups.

The duration and nature of the intermediate changes constituted the greatest stumbling block. At the risk of excessive repetition I would stress again that the situation varied so much from lesion to lesion and at different parts of the same lesion, in respect of such a complexity of factors, that the greatest difficulty was encountered in relating any one feature to its duration alone. In this the situation in coronary artery occlusions contrasted with that in myocardial infarction. In the latter, the size of the lesions was the only important variable which needed to be taken into account when correlating myocardial changes with their duration. It has already been noted in Chapter 5 that this introduced a difficulty that was far from inconsiderable in the "aging" of myocardial infarcts. Far greater was the difficulty encountered in the complex situation found in thrombotic occlusions.

Much of the importance in the "aging" of thrombotic occlusions centred on the early lesions. With accurate determination of the ages of occlusions and related myocardial infarcts, the degree of correlation or discrepancy between them could have been critically assessed. I should have required many more observations however before I would have been prepared to derive reliable criteria for the determination of the age of very recent thrombus. My own observations so far have permitted little distinction to be drawn between thrombotic occlusions of a few days and a few weeks in age. It surprised me a little when I realised that this was the case. I think it is important at the outset to stress again the apparent inertness of thrombus deposited in the lumen of a diseased coronary artery, and the unexpectedly long period of time which could elapse before recognisable changes in it or in its surroundings became manifest.

In this investigation three types of observation were available: stereo-arteriograms, 2 mm. thick, serial sections and selected semi-serial micro-sections. Of these the magnified gross picture presented by the serial thick arterial sections was the most readily correlated with the known or presumed age of the occlusions. More attention will be paid however to the microscopical appearances, which lent themselves to description in greater detail and in more precise terms. The arteriographic appearances, though characteristic in certain instances, in general could afford little reliable indication of the age of the lesions.

In the examination of the microscopical appearances great care had to be exercised in order to avoid placing too much weight upon a finding made at a particular level without relating it to the findings above and below it. Error in relating findings to duration was presumably reduced where the examination included sections taken at all levels throughout the length of the lesions and

did not depend upon one or two random sections alone. The instance of endothelial overgrowth of thrombus may be cited. This is generally described as an early feature. Where, however, thrombus at one end of an occlusion was found to have been invested by endothelium, close scrutiny was necessary before it could have been assumed with any measure of certainty that the main body of the obstructive thrombus was of the same age. The possibility had to be entertained that the latter might have been formed at a considerably later date. Conversely, lack of endothelial overgrowth at the ends of an occlusion did not necessarily indicate a very short duration for other portions of the lesion; for again there was the possibility of thrombus deposition during the last few days at the ends of an occlusion a few weeks old. I think, however, that this must have been a distinctly unusual occurrence; or so it appeared at any rate in subjects in receipt of anticoagulant therapy at the time, upon which most of my observations have been based. Nevertheless, in such an instance it was a contingency which had to be considered before it be assumed that appearances of blood clot on section which might be indistinguishable from agonal clot, including lack of endothelial covering, necessarily meant that the occlusion itself was more recent than the episode of muscle damage related to it.

#### The very recent appearances.

The early features were readily recognised as such:- evidently recent blood clot in the 2 mm. thick sections; and in the micro-sections, red cells well preserved in outline and staining quality, little or no endothelial overgrowth, fibrin network showing strong affinity for methyl violet, no clearly related changes in the underlying intima. Estimation of the duration of time for which these features might persist was by no means so readily determined. Sections taken through the centre of occlusions which were almost certainly 3 weeks in duration, showed appearances in the thrombus indistinguishable from very recently formed or "agonal" blood clot. I was unable to distinguish a

continuous endothelial layer with certainty on the intimal surface where it had been overlain by thrombus and suspect that the disappearance of this layer - as such at any rate - is a very early feature.

The development of blood channels, in the form of primitive spaces in the fibrin network, seemingly indicated a duration of more than a few days and were clearly found in lesions about 2 weeks old. The absence of such changes was not taken to indicate the converse. Likewise continuous investment of thrombus with endothelium was definitely found at the end of a lesion less than 3 weeks old. I do not deny the possibility that endothelial overgrowth may be detected at the extremities of a thrombotic occlusion in a matter of a few days, but I did not myself observe this under nearly three weeks. Likewise a continuous endothelial lining was not found in the blood channels in the depths of the occluding thrombus until the second month. Again the absence of such a lining did not necessarily indicate a particularly early stage.

After 3 to 4 weeks, degenerative changes were detectable in the red cells (H. and E.) in which the outlines tended to be less well defined and the cells somewhat heaped together. They remained intensely eosinophil and very few ghost forms suggestive of haemolysis were noted. Pallor of the thrombus in contact with flowing blood was also noted in the gross specimen, but for reasons already discussed, close correlation with duration was not thought to be reliable.

#### Old-standing appearances.

In old-standing, canalised occlusions the thrombotic material was largely converted into a translucent fibrous substance with the staining properties of collagen. Typically this contained relatively little lipid material in the immediate neighbourhood of the canalising channels, and typically iron deposits were scanty. As already noted, exceptions existed, sometimes to a marked degree. It was not clear whether the accumulation of lipid increased with the age of the lesions, although this was thought possibly to be the case.

In portions of old-standing occlusions that were still complete, the obstructive material was sometimes grey and translucent, microscopically similar to collagen, as described above. Sometimes however it was a brownish or orange coloured, structureless mass of necrotic debris. In such instances it was evident that the material had been derived from mixed thrombus; and even on gross appearance the pigmentation of altered blood was still evident in lesions thought from the related clinical episodes to be 2 years old. It was not determined how much longer than 2 years such appearances might persist, where the material had been cut off from all contact with circulating blood. (See colour transparency 12 RC 2:1b .)

Sometimes the configuration of the micro-anatomy as seen on cross section clearly indicated the previous state of the vessel wall and the size of the lumen before the final episode of occlusion. In other instances the line of demarcation was less well defined, and it was uncertain whether the previous lumen was represented solely by the core of translucent material in the immediate vicinity of the new channels, or whether in fact the larger plaque of atheromatous material had also been derived from the same episode of thrombosis (e.g., 22 ADA<sup>1</sup>).

In old-standing occlusions the vessels formed in the process of canalisation were well organised structures. The endothelial lining was supported on concentric layers of collagen and sometimes of elastic tissue as well. <sup>2,3</sup> In the arteriograms such structures were often similar to small arterial branches laid in the long axis of the artery. It has already been noted that others had a bizarre configuration even in lesions of long standing. Although such vessels were readily distinguished in the arteriograms from primitive blood spaces, the radiographic appearances did not permit distinction to be made between vessels of about 6 months in age and those found in older lesions.

- 
1. 22 ADA 2:5b (colour transparency), 3:1a, 4:5b.
  2. 11 ADA 2:2 micro.
  3. 1 ADA micro. (2).

It cannot be over-emphasised that appearances which might well have been related to age, such as changes in the composition of the thrombus, could differ greatly in the same lesion depending on the level through which the section had passed. Thus comparatively advanced changes of organisation could be found at the free ends of an occlusion while at its centre, far from contact with flowing blood, very little change had taken place. If therefore a section taken through one level showed a canalised lumen embedded in translucent fibrous material while a section at another level showed the arterial lumen to be completely obstructed by material grossly and microscopically recognisable as thrombus, this did not necessarily indicate that the occlusion had taken place in more than one stage. 24 RC is a case in point. The possibility cannot of course be excluded with certainty that the dark thrombus had been laid down at a later date (and indeed extension by more recent thrombosis of a complete occlusion could pass unnoticed symptomatically and would not cause a separate episode of muscle damage on its own account). The point I make however is that in this instance, and in others, it was not felt necessary to implicate more than one episode of thrombosis. It may be further noted that in 24 RC there was grey thrombus undergoing change at the proximal free end of the occlusion, and the dark thrombus was more deeply placed.

#### Intermediate changes.

Intermediate changes were observed but instances of occlusion in this group were few. Histological details are discussed in more detail in Chapter 8, in which the transition from fibrin to collagen is examined. Well formed vessels surrounded by collagenous tissue were found in parts of lesions thought to be 5 and 8 months in age. In other portions, where the material had undergone less organisation, the vessels lay in material still fibrinous in character, or intermediate in staining quality between fibrin and collagen. Thus it stained



poorly with methyl violet (and with picro-Mallory) and did not stain with acid fuchsin in van Gieson's stain. The vessels lying in this material were less well defined, but had endothelial coats supported on "fibrinoid" material or early collagen.

Iron deposition was not a feature of early thrombotic occlusions. In those of intermediate age (6 months approx.) the presence and quantity of stainable iron deposit was exceedingly variable. For reasons discussed elsewhere (Chapter 8) its presence was taken to imply a haemorrhagic or thrombotic origin for the material in, or close to, which it lay; but its scarcity or absence was not accepted as good evidence to the contrary.

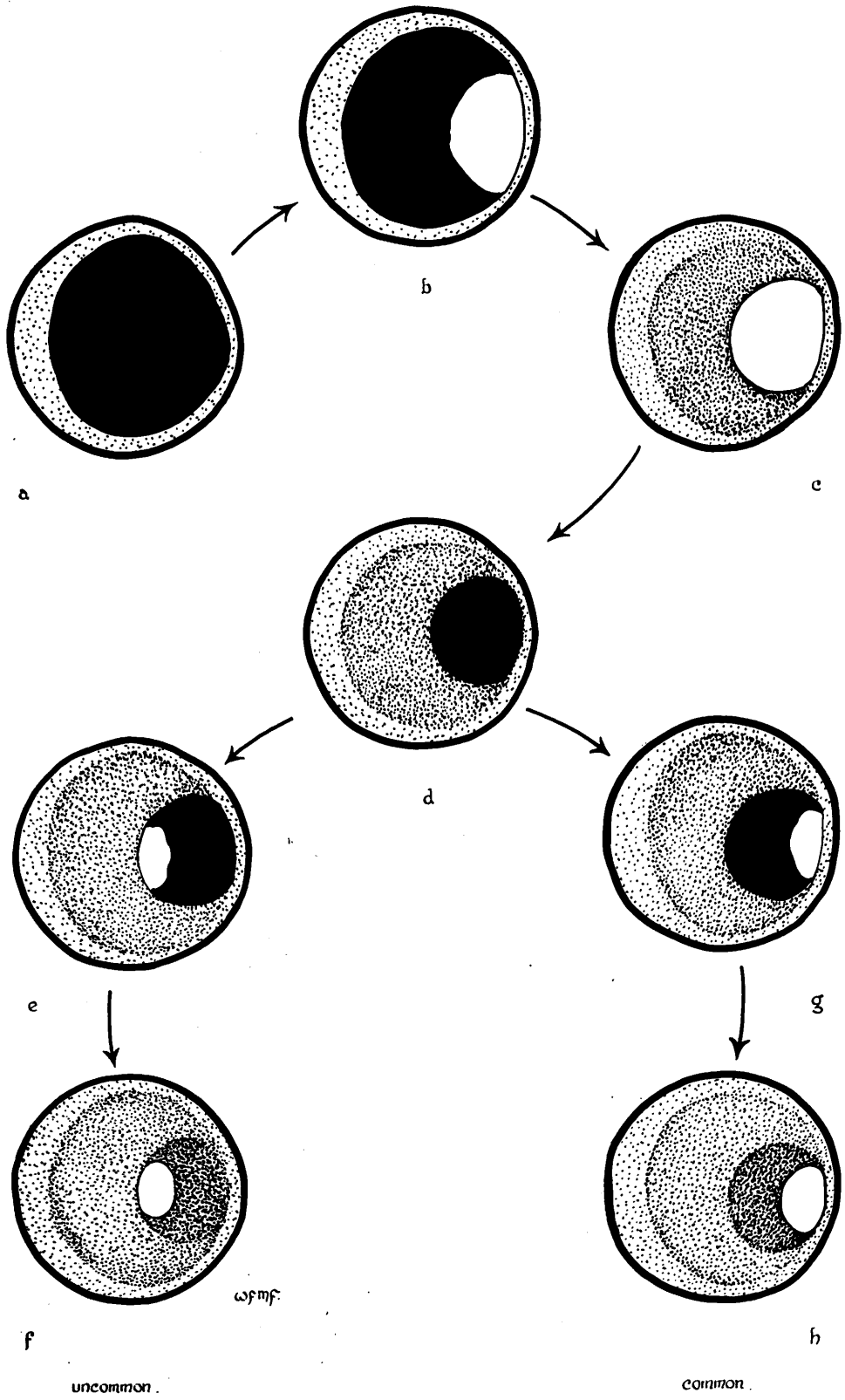
THE POSITION OF THE NEW LUMEN IN CANALISED OCCLUSIONS

As already indicated, it was thought that the main channel of a canalised occlusion had usually been formed initially by the separation of thrombus from artery wall. If we suppose an artery to have been but little narrowed by intimal disease beforehand - and the clot correspondingly large on cross section - the channel formed by separation would lie close to the artery wall and would be eccentric in position. In course of time, when changes had converted the substance of the thrombus into atherosclerotic material, the new lumen would be placed at one side, with at its back, so to speak, the bulk of an atherosclerotic plaque. This was a common finding. Many examples may be seen in the illustrations (e.g., 22 ADA 3:1a, 23 ADA 2:7a, 14 LCxA 3:5b) and reference may be made to Diagram 7:5. (In this diagram the black areas represent thrombus and the stippled areas, atherosclerotic tissue.)

Where there had been gross eccentric thickening of the intima beforehand, as the result of a large atherosclerotic plaque, separation of occlusive thrombus from the artery wall could take place at any point. It was however observed that in general separation took place more readily between the clot and the thinner part of the artery wall, than between it and the main body of the plaque. It may have been that greater distensibility of the thinner portion played a part in favouring separation at this point. Alternatively, adherence of the clot to the diseased intima may have been firmer over the thicker portions than to the healthier, thin wall opposite. When separation took place in this fashion the centre of the new lumen would naturally be still more eccentrically placed than had been the centre of the previous lumen (Diagram 7:5g). A good example in a recent lesion may be seen in 14 ADA 3:1b. In older lesions the formation of several layers can often be made out, converging as it were on the remaining - or most recently formed - lumen (Diagram 7:5h).

Where severe atherosclerotic thickening had surrounded the previous lumen on all sides the same process could take place and result in a new lumen, eccentrically placed in respect of the outer walls of the artery (e.g.,

Diag. 7:5 The position of the new lumen in canalised occlusions.



(e.g., 14 ADA 2:5b). It was noted that the process of separation of the clot did not appear to have taken place with the same readiness in these circumstances.

On occasion, separation of the clot from the surrounding artery wall could also take place at its inner or deeper aspect, so that centre of the new channel came to be placed more centrally than was the centre of the lumen before occlusion, as is illustrated in Diagram 7:5 e,f. This phenomenon was distinctly uncommon, in contrast to the development of the new channel between the thrombus and the thinner portions of the vessel wall.

In a number of instances however the central position of a much narrowed lumen was not readily explained on this basis. In some there appeared to have been episodes of concentric thickening of the intima, and the layers were not evidently compounded of crescentic formations.<sup>1,2,3</sup> It may be considered possible that the appearances were the product of canalisation through the centre of an occluding clot, but I am inclined to view this explanation with some doubt. In no instance in this series was a recent thrombus canalised by a single channel through its centre. The larger or single channels in recent lesions were always placed between thrombus and intimal wall. At least two other possibilities remain.

(1) Centrally placed channels may have been so produced by gradual intimal thickening. (2) Dissection of the intima by a large haematoma might strip the inner layers from the outer and leave the lumen much more narrowed in the centre. I think that this may have been the case at one point in 18 ADA<sup>4</sup> but the other portions appear to have had their origin in thrombus, formed doubtless in relation to the haematoma. In cases 11 and 12<sup>5,6</sup> occlusion seemed to have been formed by old intimal haematoma. (3) It is possible but unlikely that a centrally placed lumen may have developed as indicated in Diagram 7:5 e,f and in course of time adjustment in the texture of the artery wall will take place so that by the time of death a formation of concentric rings have replaced the original eccentric crescents.

1. 18 ADA 3:1.

2. 25 LGxA 2:6a, 2:5b.

3. 19 RC 1:7 micro.

4. 18 ADA 2:3 micro.

5. 11 ADA main br.(E) 2:1.

6. 12 ADA 2:5 micro.

NOTE ON VESSELS ARISING FROM THE ADVENTITIAL COAT IN REGARD TO  
CANALISATION OF THROMBOTIC OCCLUSIONS OF THE CORONARY ARTERIES

In my preparations of severely diseased coronary arteries it was not unusual to find small vessels entering the thickened intima from without, having arisen from the vasa vasorum in the adventitial coat. Description of these vessels and discussion of their significance is given elsewhere (Chapter 8). At this juncture the point is made that in this series there was very little evidence that these vessels played any part at all in the canalisation of thrombotic occlusions. They were found only in the peripheral portions of old established atherosclerotic material and were not features of the early or transitional changes in occlusive thrombus.

It has been noted that thrombosis took place with but two exceptions in this series in arteries that were already the seat of advanced coronary artery disease. In such arteries the thickness of the diseased intima appeared to have interposed a substantial barrier between the thrombus in the lumen and the vessels in the adventitial coat. It may have been largely on this account that vessels from the periphery were never observed to take part in canalisation of thrombotic occlusions. Their presence in the depths of atherosclerotic tissue underlying thrombotic occlusion may well be another matter altogether.

It is commonly observed in thrombotic occlusions of previously healthy arteries (or for that matter of veins) that a profusion of small vessels appear to be growing into the margins of the clot in company with the other changes or organisation. It is true that in a few instances it would seem that these vessels can be traced to an origin in the adventitial vessels. I question however if this is their usual origin. It seems more probable that in keeping with thrombotic occlusion of diseased arteries, these small invading vessels

have arisen from the processes already described. It is to be noted that they are commonly interposed between thrombus and artery wall and in transverse sections are most commonly cut across owing to their direction in the long axis of the artery. The cleft-like configuration that may be seen is also in keeping with the process of separation. The micro-section from 1 ADA clearly indicates the luminal origin of intimal vessels in this artery which was evidently normal before thrombotic occlusion. I suspect that this is the usual origin of the vessels taking part in the organisation of blood clot in previously normal arteries no matter how close to the internal elastic lamina they may be found on micro-section. I have however not taken the opportunity of injecting such vessels myself. I note with interest that in a recent paper, Dible (1958) states that the small vessels in question always arise from the lumen. He stresses the barrier to ingrowth of vessels from without that is offered by the internal elastic lamina.

The above is a very faint and illegible section of text, likely bleed-through from the reverse side of the page. It appears to contain several paragraphs of scientific or medical discussion, but the characters are too light to transcribe accurately.

COMMENTS ON THE VARIED CONFIGURATION OF CANALISED OCCLUSIONS

It was possible to regard most of the appearances seen in canalised occlusions as derived from one or other of the primary processes of "separation" and "fissuring" or infiltration of thrombus or from various complex combinations of the two. When one considers also the very diverse conditions of antecedent disease of the artery wall and the many different sites at which occlusion may develop, the great variety of pictures found in canalised occlusions need not occasion surprise.

Sometimes the infiltrative process seemed to approach both from proximal and distal ends of the clot and to link up as in 23 ADA. Photographs of the mounted 2 mm. thick serial arterial sections through this area show that the tissue in which the vessels lay had undergone change into atherosclerotic-like material. In others the infiltrative process had apparently approached from one end only.

The occurrence of two or more channels of similar size was not uncommon. Examples are shown in 25 LCxA art. and in 24 ADA (arteriogram of whole heart, accompanying case report).

In 24 RC near the proximal end of the occlusion (X) an early stage in the emergence of a single channel from a network of small channels is well shown. In course of time this picture might well have changed and be dominated by a single, eccentrically-placed, channel of perhaps  $\frac{1}{2}$  - 1 mm. in diameter. As the thrombotic material became converted into atherosclerotic tissue a proportion of the other finer channels would remain as intimal vessels. Figure 14 LCxA 3:6b shows such an artery in which a single narrow channel gives rise to a number of fine intimal vessels which enter the atherosclerotic tissue - which has with little doubt, in this instance, had its origin in thrombus. These intimal vessels are too fine in calibre to be distinguished clearly from the parent artery or the radiograph.

The part played by anatomical branches of the coronary arteries is of interest not only in the changes which may follow thrombotic occlusion but also in determining the site and extent of the original thrombus. Winternitz et al. (1938) have stressed that the occlusive thrombus typically extends from one point of bifurcation to the next. In my own series the majority of lesions confirmed this concept, provided that relatively small branches rather than true bifurcations be accepted. There were also uncommon exceptions.

The contribution made to the process of canalisation by anatomical branches may add complexity to the radiographic picture (see Diagram 7:4). In 22 ADA art. an example may be seen in which a branch appears to leave - or to feed - the middle portion of the canalising channel. The channel is wider at this point and one is in doubt whether the presence of the branch had simply limited thrombosis near its point of exit or whether retrograde entry of blood after occlusion had also contributed to the process of canalisation. In either event the occlusion was divided into two portions. (See also 24 RC and 16 ADA.) One would suppose that the presence of such branches might greatly have increased the likelihood of complete canalisation of a lengthy occlusion.

Commonly branches linked up through anastomosis at some distance from the artery and in this way restored continuity of blood flow through an extra-arterial by-pass. This was also a common occurrence through the adventitial arteries (*vasa vasorum*), which are of course initially of exceedingly small calibre. A short communication of this order can readily be traced in 7 RC art., and a somewhat devious and much longer communication may be followed in 22 ADA art. The upper part of 16 ADA shows a remarkably well developed network derived from the *vasa vasorum* at the level of complete occlusion. The third dimension is essential for the appreciation of these features.



On occasion communication was traced between the fine intimal vessels and vessels of this order outside the artery, or in its outer coat. The arteriographic demonstration of such a communication is shown in 17 RC art. For the most part few injectable arterial communications were demonstrated in this series between the vessels of the intima and the vessels of the adventitial coat.

Abrupt narrowing and abrupt widening after a short stretch of severely stenosed lumen is to my mind an arteriographic appearance highly suggestive of thrombotic occlusion which has been canalised. Several examples are to be found in the arteriograms.<sup>1,2,3,4</sup> In several narrowings of this order which were examined the material composing the intimal thickening gave evidence of its origin in thrombus.

- 
1. 18 ADA art. (lower part).
  2. 24 ADA art. (lower part).
  3. 19 ADA art.
  4. 7 RC art.

THE FUNCTIONAL SIGNIFICANCE OF CANALISATION

When one examines the arteriograms of canalised occlusions it is quite obvious that hair-line tracks, such as may be seen in 23 ADA and 18 ADA, can have little contribution to make in terms of blood flow to the heart muscle. In this degree, they are phenomena of pathological interest but no clinical importance. But when we come to consider channels of larger calibre it is equally obvious that their potential capacity for carrying a useful measure of blood flow cannot be ignored. Determination of the measure of potential blood flow which may have been carried by a particular canalised occlusion is not an easy matter. Some points of observation and inference have bearing on this problem.

In several cases there was widespread myocardial infarction related to recent thrombotic occlusion. The extensive nature of the muscle damage together with the relatively slight degree of anastomotic enlargement provided indirect evidence that the arterial lumen before occlusion had been functionally adequate. Indeed, it could be assumed from the clinical features also that the lumen beforehand had been adequate not only for the survival of the myocardium but for the pursuit of ordinary activities. The surprise came to me when I found that in some arteries the lumen had been remarkably narrow before occlusion. 20 ADA, 21 LC, 24 ADA, 14 ADA and 11 ADA are cases in point. In these cases the narrowing of the artery in question was less than 1 mm. before terminal occlusion. A measure of the importance of the blood flow through these narrow channels was provided by the disastrous consequences which followed its withdrawal.

In Case 21 all the blood entering the left coronary artery passed through an aperture less than 1 mm. in diameter. Its occlusion led to widespread infarction of the left ventricle. One was put in mind of the entire circulatory volume of the body passing through an aperture less than 1 cm. in diameter in the mitral valve - and doing so under a head of pressure from the

left atrium which was probably substantially less than must have been the gradient of pressure across this obstruction in a major coronary artery. This obstruction was of very short length, about 1 mm. Had it been of greater length, the increased resistance offered to blood flow might have reduced the volume of blood passing through it to a level insufficient for the basal needs of the myocardium.

According to Poisseuille's law increasing length of a channel, other things being equal, increases the resistance to fluid flow eight-fold. With this in mind it would seem unlikely that the long narrow track in Case 18 could have made useful circulatory contribution. The point however was not put to the test by thrombosis. In Case 20, anterior descending artery was narrowed to less than 1 mm. for a straight course of 5 mm. in length beforehand. Obliteration of this narrow track by thrombosis was followed by myocardial infarction of great severity and death was due to rupture of the interventricular septum. Before this narrow track, 1 mm. x 5 mm., was occluded it had supported the ordinary activities of an elderly woman, who had suffered no angina of effort.

It may therefore be postulated that if canalisation can re-open a short straight track of this order restitution of a useful measure of blood flow may take place. In 24 ADA and 18 ADA (lower part) are shown narrow tracks which were believed to have been the product of canalisation of thrombotic occlusions. These channels were still patent at death so that their functional sufficiency had not been put to the test, and could only be inferred indirectly from the lack of recent myocardial damage; and then only after the degree of collateral enlargement had also been taken into account.

It may also be noted at this point that in those instances where the lumen before terminal occlusion had been severely narrowed, it seemed likely that

the narrow lumen itself had been the product of canalisation of an earlier episode of thrombosis. Cases 20 and 14 are examples. If this was indeed the case occlusion by thrombosis must have been either incomplete or of short duration, for the myocardial damage of old standing, related to the earlier episodes of occlusion in these cases, was restricted to focal lesions.

The shorter a thrombotic occlusion to begin with, the shorter can be the canalised lumen and, other things being equal, the greater the functional adequacy of the new channel. Each episode of thrombosis is likely to increase the length of the obstructive lesion as well as the degree of stenosis. Thus we may find examples in which, to judge from the retrospective reconstruction of events, thrombotic occlusion of an artery not previously greatly narrowed had been followed (possibly rapidly) by canalisation of a comparatively wide channel. The incident may have had trivial clinical effects, or indeed have passed unnoticed at the time. Subsequent thrombotic occlusion of the track left by the previous thrombotic incident, or produced by canalisation of previous thrombotic occlusion, cannot be re-opened so readily and profound myocardial damage ensues. This was probably the train of events in Cases 14 ADA and 20 ADA.

When myocardial damage was examined in correlation with the degree of anastomotic enlargement and the presence of canalisation of occlusions, one was led to the tentative conclusion that a single canalised occlusion was, in terms of useful blood flow, worth several, or many, anastomotic channels of similar calibre. This was not altogether surprising. Compared to enlarged arterial anastomoses, a channel passing through an occlusion has several advantages. It is usually much shorter in length and relatively straight; and it usually receives blood at its proximal end at approximately a full head of arterial pressure. Whereas the anastomotic channel is often distantly placed, long, tortuous and arises from small scale branches. It is moreover often

deeply placed within the myocardium with all the attendant disadvantages for blood flow in this situation in the beating heart (see Chapter 4).

Anastomotic blood flow enters, as it were, through the back door and finds its way by long and devious, sometimes underground, passages, in retrograde fashion for part of the way at any rate. By contrast, the blood passing through a canalised occlusion is distributed to the myocardium in the normal direction, through normal channels.

The issue of successful canalisation seemed to depend mainly on changes taking place during the first few weeks. These changes are described in detail and two primary processes are described. In many lesions processes were operative simultaneously.

1. "Separation" of the clot from the arterial wall at one pole, with formation of channels between intima and thrombus.
2. "Fissuring" of the clot with formation of irregular pits within the substance of the thrombus itself.

The first of these processes was probably influenced by retraction and subsequent shrinkage, of the clot and by contraction of arterial smooth muscle. As a result, separation tended to take place between the clot and the intima on the least stressed portion of the vessel wall. The second process seemed to be

SUMMARY

Observations on 47 main-stem coronary artery occlusions in 25 cases have been presented in this chapter. Attention has been specially directed to the changes leading to canalisation of thrombotic occlusions.

It was evident from the collective, numerical data that the relationship between successful canalisation and the passage of time was not a close one, and that other factors were of greater importance. Attention was drawn to the probability that early canalisation favoured survival, whereas persistent complete occlusion tended to cause early death, in a sufficiently large proportion of cases significantly to affect the incidence of complete and canalised occlusions of different ages which presented in a post-mortem series.

The issue of successful canalisation seemed to depend mainly upon the changes taking place during the first few weeks. These changes were examined in detail and two primary processes are described. In many lesions both processes were operative simultaneously.

1. "Separation" of the clot from the arterial wall at one or more points, with formation of channels between intima and thrombus.
2. "Fissuring" of the clot with formation of irregular blood channels within the substance of the thrombus itself.

The first of these processes was probably influenced by retraction, and subsequent shrinkage, of the clot and by variations in arterial calibre. As a rule, separation tended to take place between the clot and the thinner and least diseased portion of the vessel wall. The second process seemed to depend upon the removal or displacement of loose blood elements from the fibrin lattice and may have been influenced by the original composition of the clot.

In either case the processes involved in the first instance appeared to be mechanical and did not depend upon cellular agency. The changes were later extended and consolidated by cellular activity. Endothelial lining to the primitive blood channels appeared in the course of a few weeks, and more definitive vascular coats developed in the course of a few months. Recent and old-standing changes were compared and the conclusion was reached that the early, fortuitously-formed channels formed the mould in which the later developments were cast. The changes observed are described in detail and are illustrated by drawings, stereo-arteriograms, photographs of 2 mm. thick transverse sections and micro-photographs.

After the first few months, the tendency was for channels of injectable size to diminish in number, in the course of time. Nevertheless, it was thought that old-standing canalised lesions of simple construction (in regard to gross and arteriographic appearances) had for the most part resulted from processes of canalisation which were simple from the outset.

It seemed that channels forming in the plane of cleavage between clot and intima had a tendency to extend in the long axis of the artery, and that successful canalisation was more commonly the result of separation than of fissuring. Accordingly, the single, narrow and relatively straight channels arising from separation were characteristically eccentric in position and situated close to the thinnest portion of the vessel wall. The origin of centrally placed channels in established lesions is also discussed.

Attention is drawn to the manner in which the channels formed in the process of canalisation were entirely contained within the confines of the arterial lumen as it existed immediately before the episode of thrombosis in question. Vessels of injectable size never entered previously established atherosclerotic tissue.

Indeed it appeared that there was a time limit for successful canalisation. The opportunity for the development of new vessels (at any rate of injectable size) seemed to have passed by the time that (1) the fibrin clot had been converted into fibrous tissue, or (2) necrotic degeneration of the clot had led to liquefaction of the solid substance. In either case a barrier to the development of new channels was created.

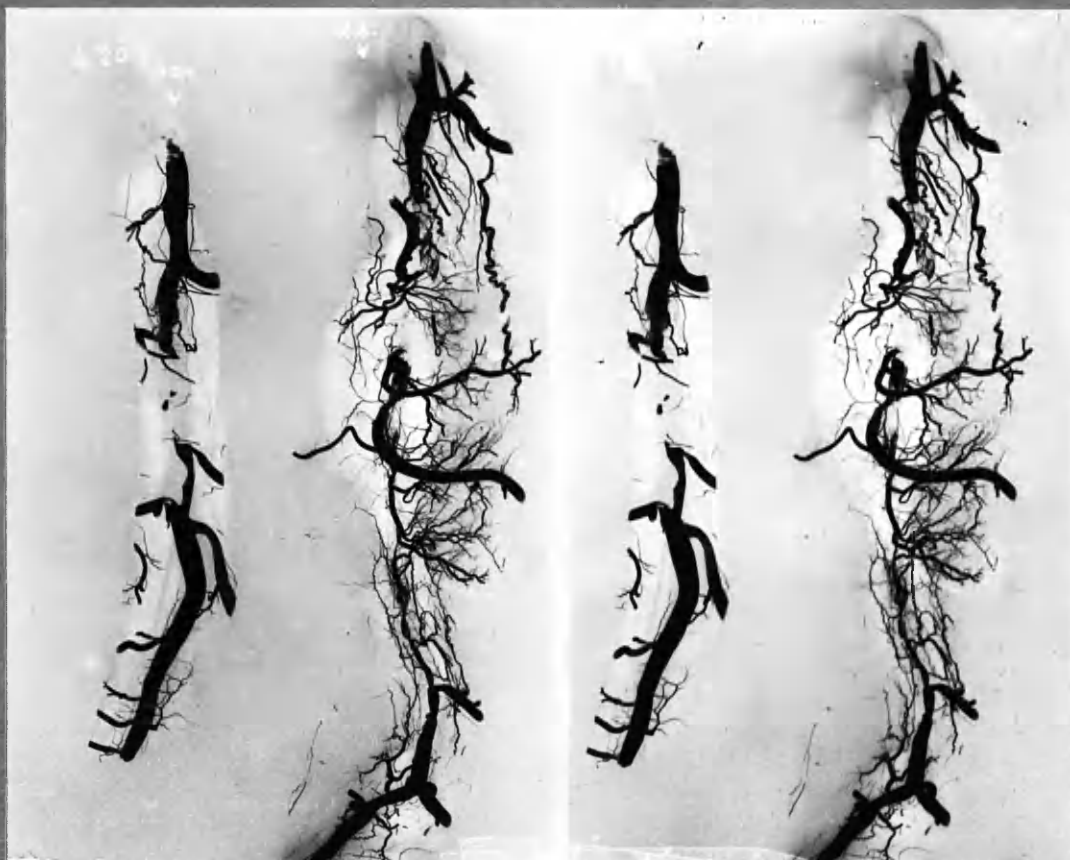
The fate of primitive channels running obliquely or at right angles to the long axis of the artery, and not taking part directly in the formation of through channels, was traced. It was thought that some of these channels persisted and formed the intimal vessels which were found arising from the lumen in established atherosclerotic lesions. The fate of other small channels is discussed and the conditions of blood flow in the primitive channels, in blood clot and intimal wall, are considered. It was further noted that vessels arising from the vasa vasorum in the adventitial coat took no part in the process of canalisation.

Factors which appeared to influence the processes of canalisation are listed and discussed.

The attempt was made to "age" thrombotic occlusions of the coronary arteries according to the features observed in relation to the known or inferred age of the lesions. It was not found possible to recognise more than three broad groups in regard to duration: (1) Early features, up to a few weeks. (2) Intermediate changes of a few months duration. (3) Fully established or old-standing appearances of one or more years duration. The very diverse appearances which could be found at different levels in the same lesion is stressed.



The functional significance of canalisation was examined. It was shown that channels of about 1 mm. in diameter could result from canalisation and also that occlusion of channels of this calibre could promote widespread and fatal myocardial infarction. The importance for the nutrition of the heart of channels of this order could thereby be inferred. It appeared that a single channel resulting from canalisation could make a contribution to the blood supply of the myocardium comparable to that provided by many anastomotic channels of similar calibre.



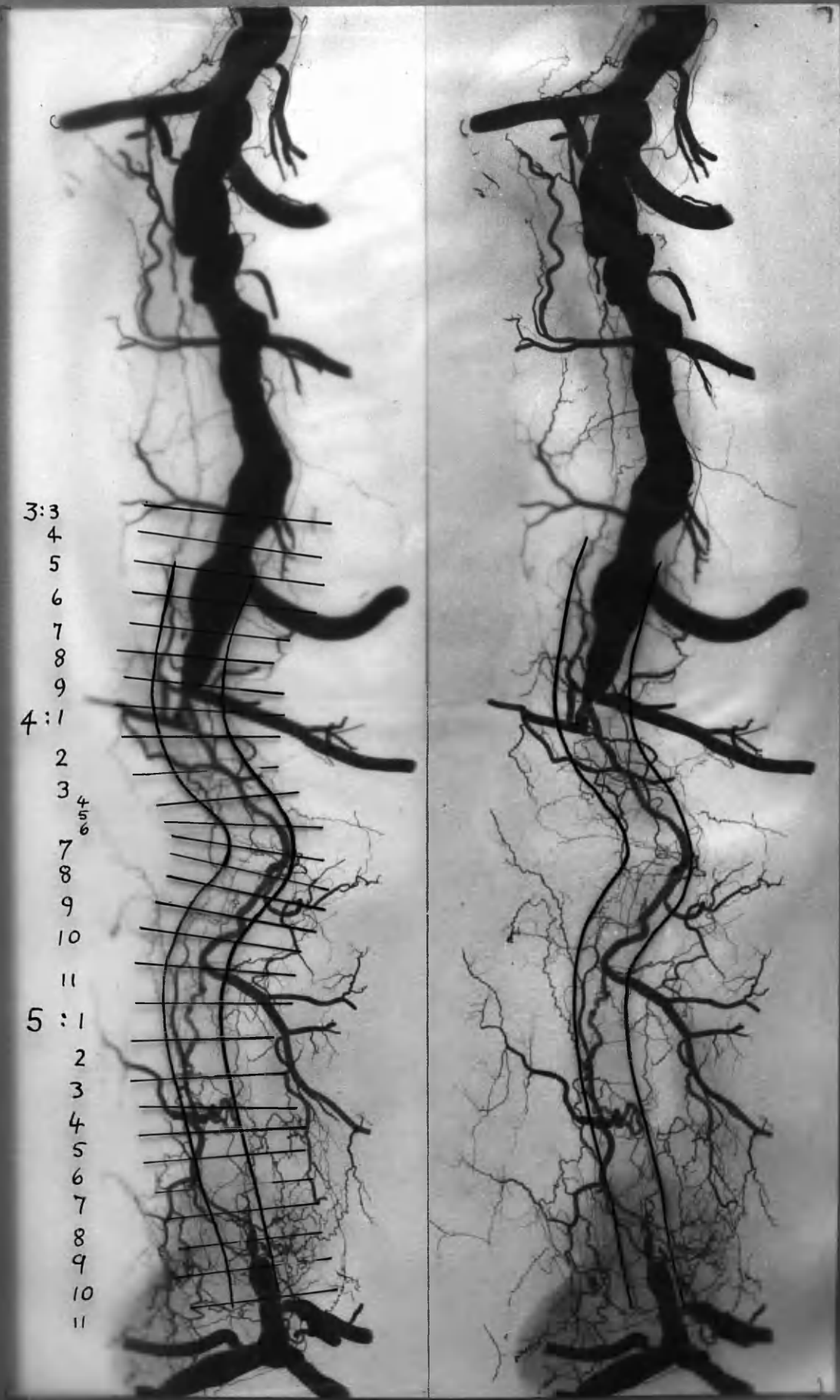
ADA

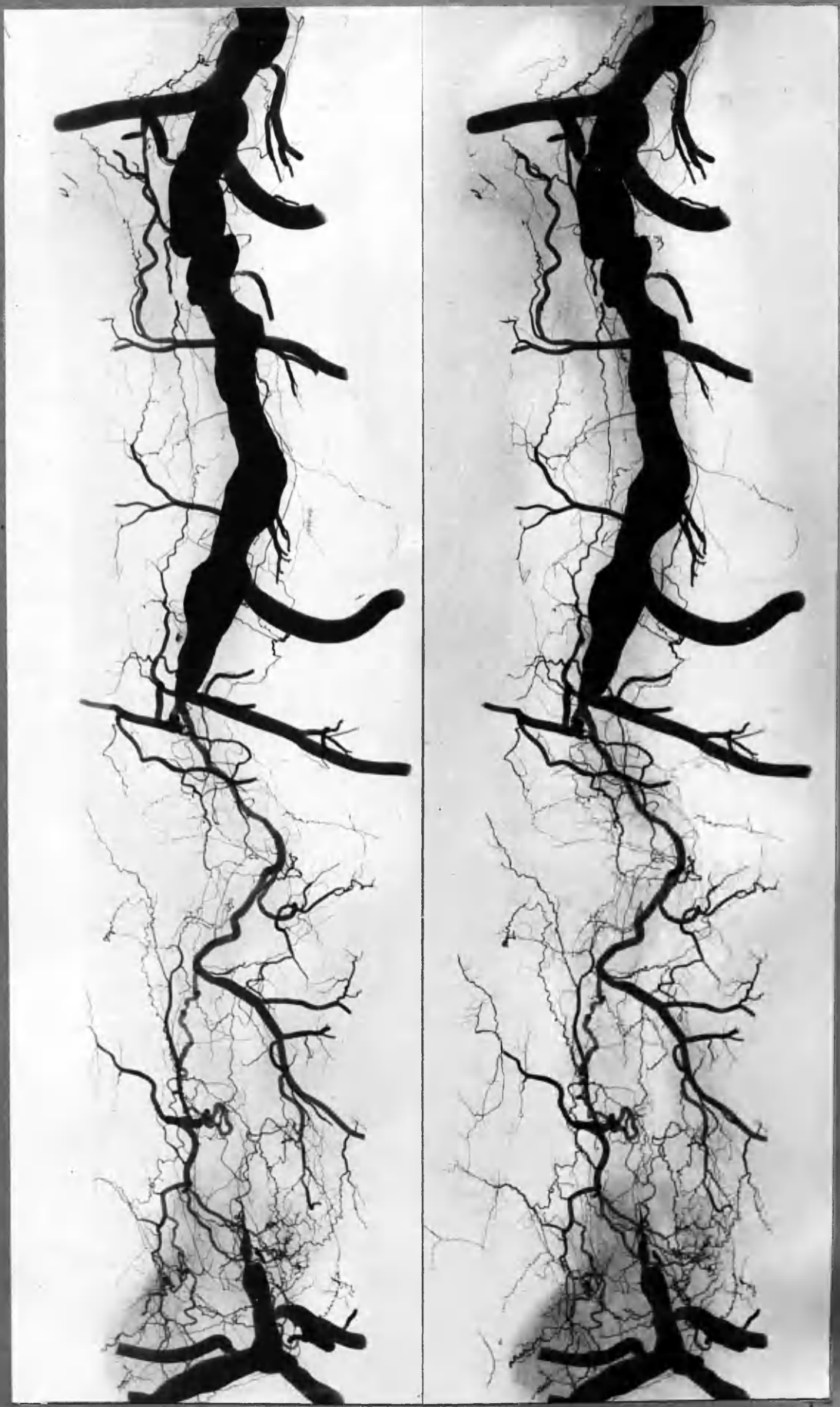
RC

CONTACT PRINT

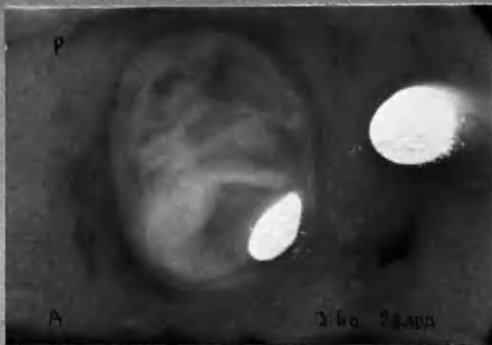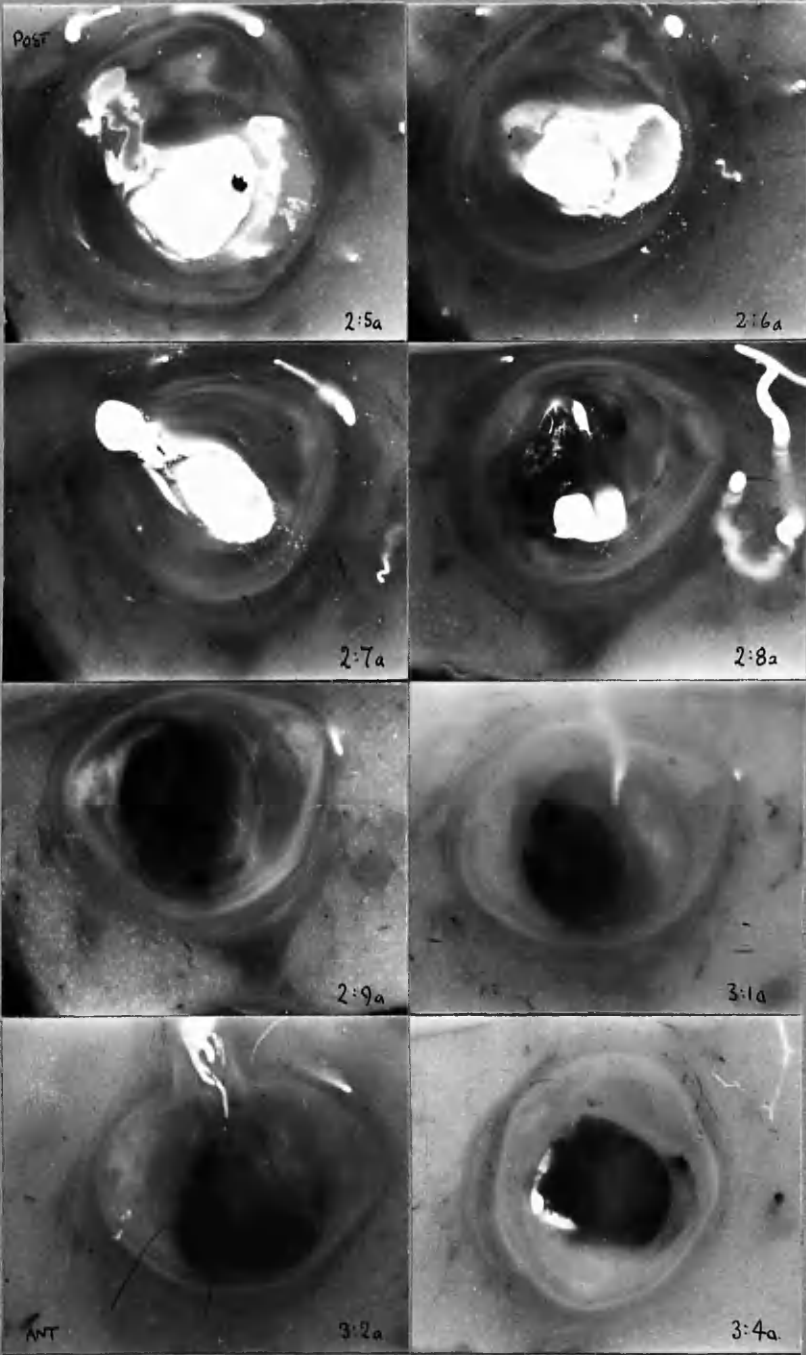
This contact print of a typical stereoradiogram of isolated coronary arteries indicates the natural size of these structures, but is of too small a scale for the appreciation of detail. Enlargements of these two arteries and several others are to be found in the illustrations which follow.

For the most part the stereoradiograms are presented at X3-4 magnification and are accompanied by selected sections. The sections are mounted according to a standard method, so that they are correctly orientated in relation to the arteriograms; and their site is indicated on the overlying transparent sheet.



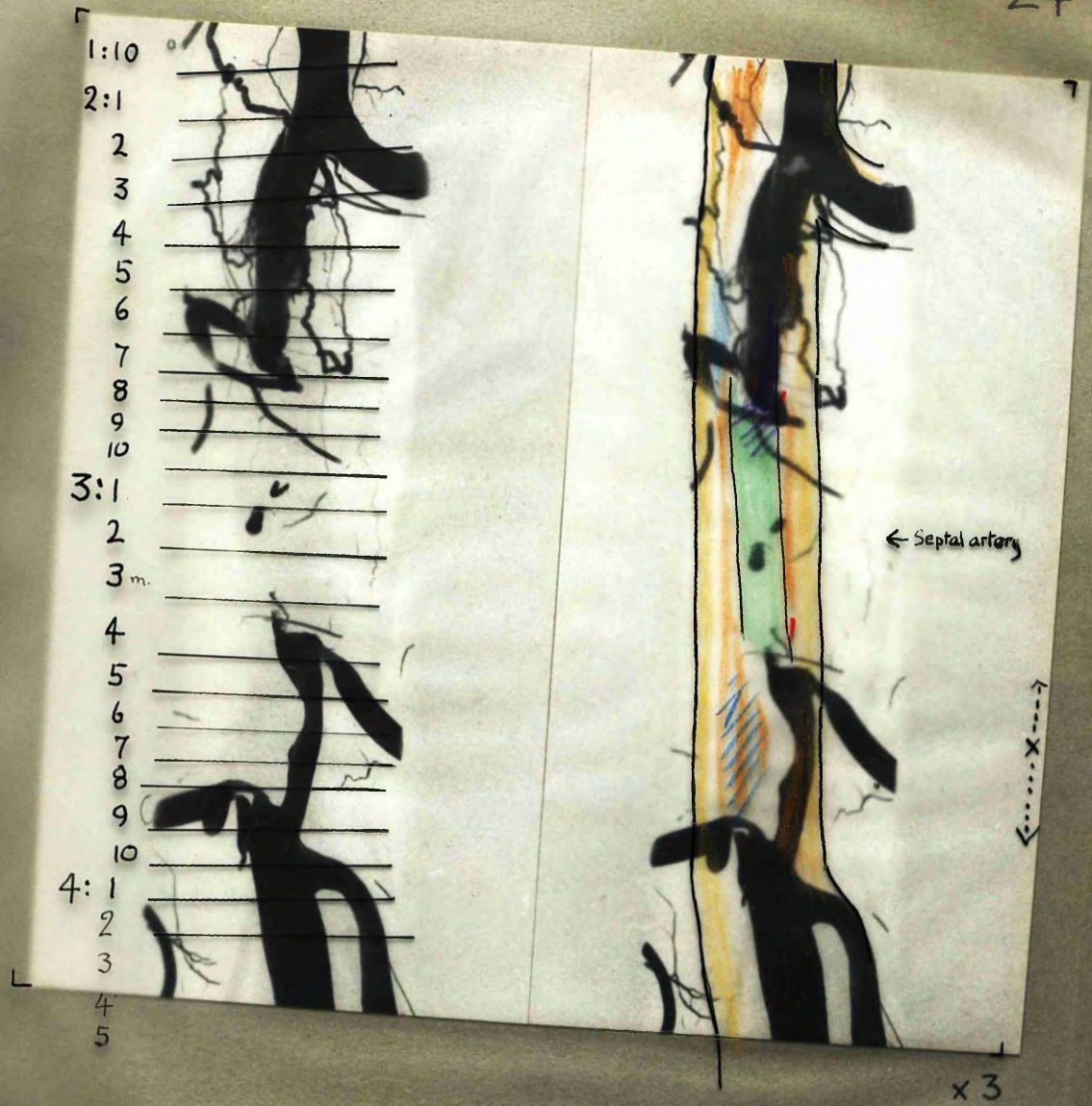


x 2 1/2



x 8





Dark Red Thrombus. (9 days)

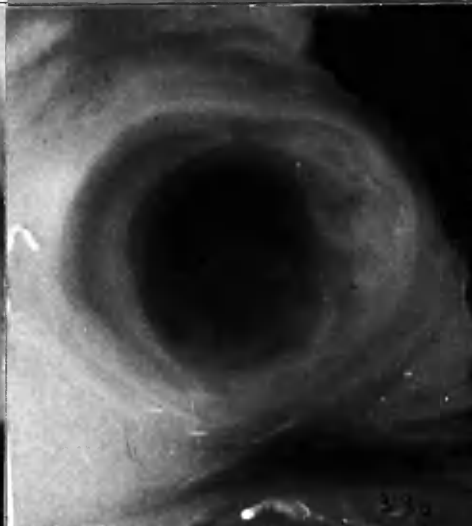
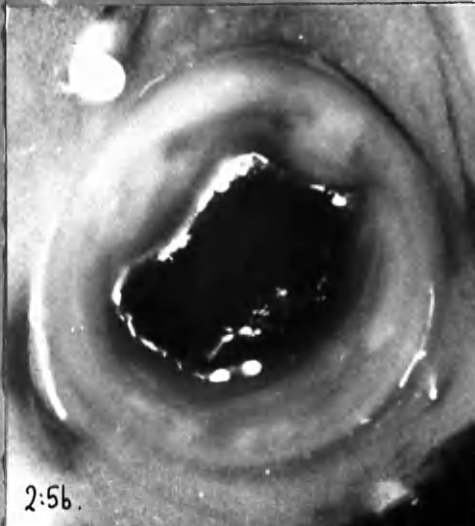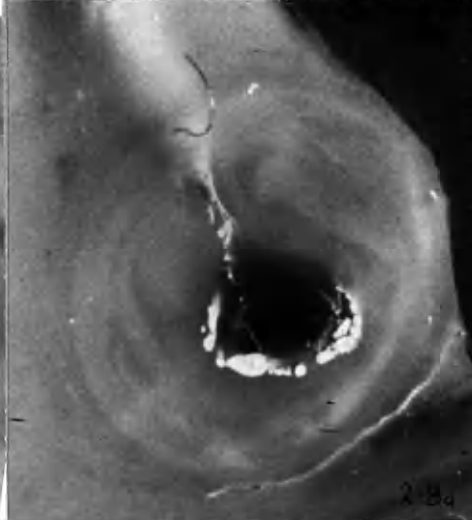
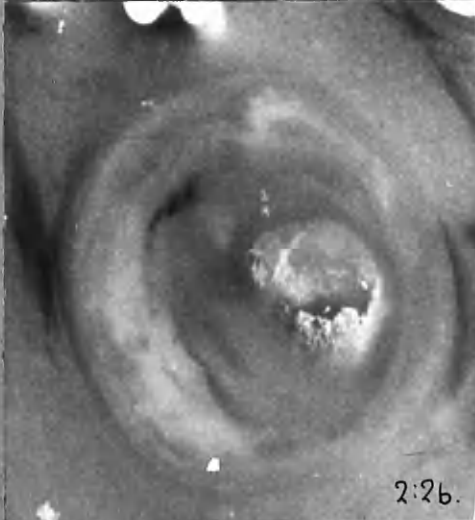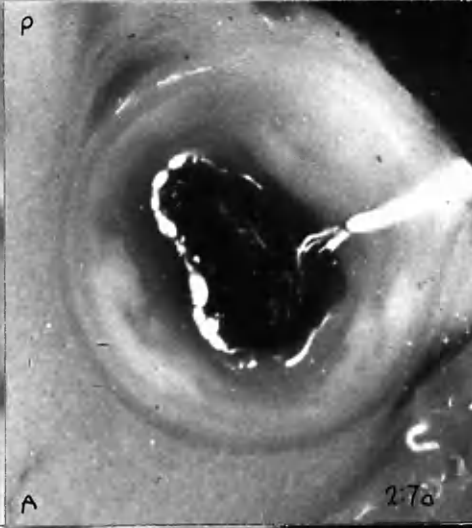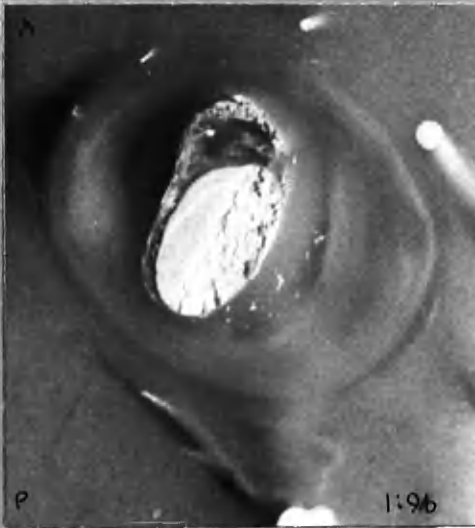
Pale fibrin thrombus (9 days)

? Haemorrhage

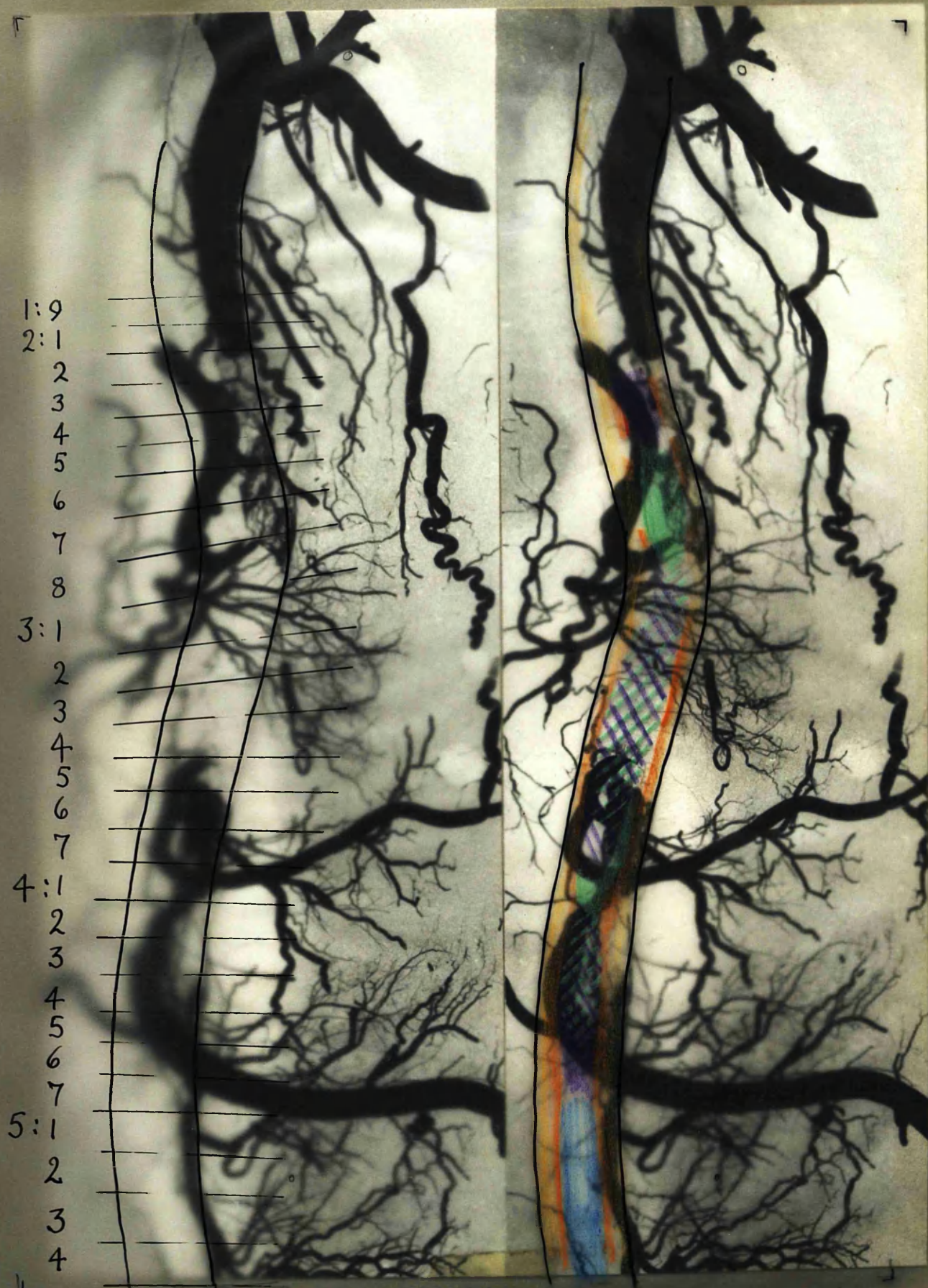
Pale atherosclerotic tissue

Pigmented atherosclerotic tissue







Translucent atherosclerotic tissue





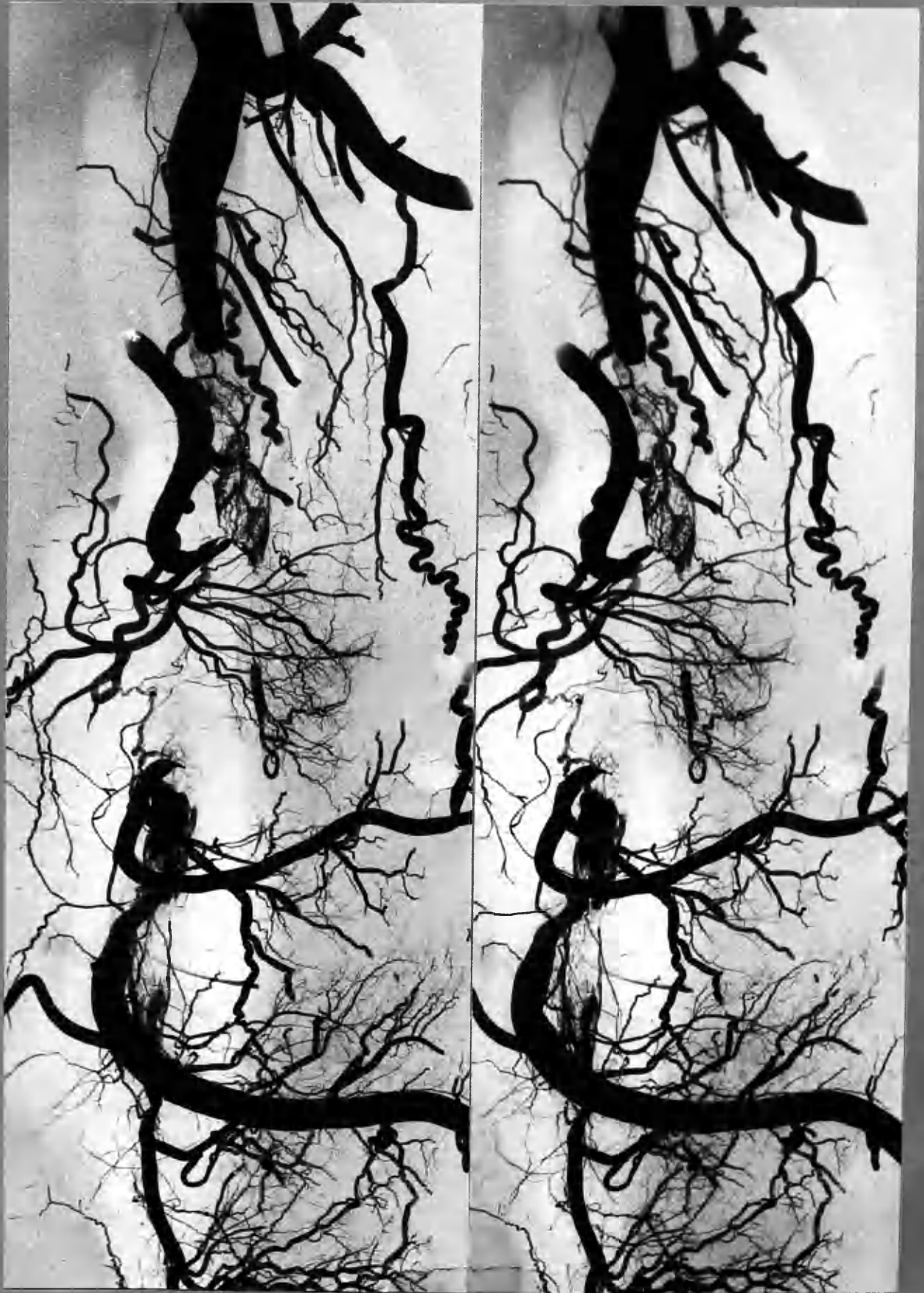

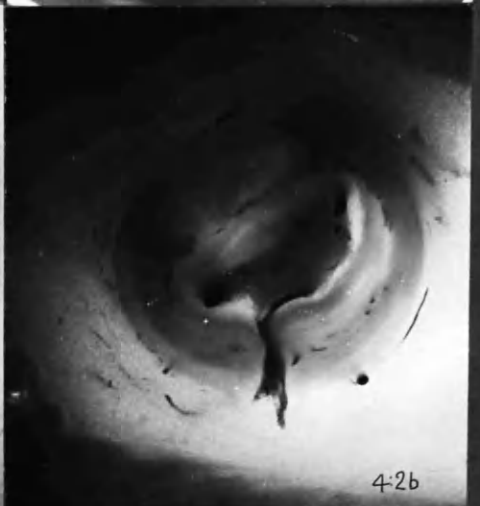
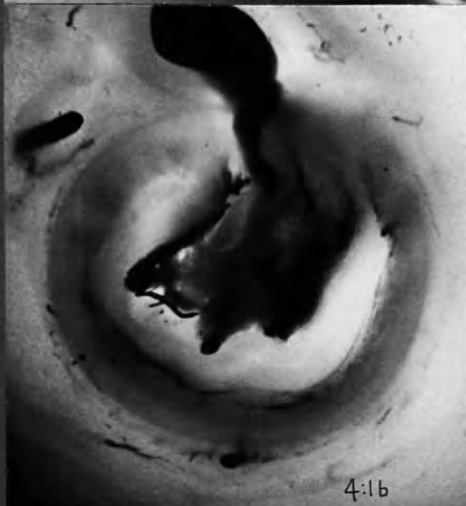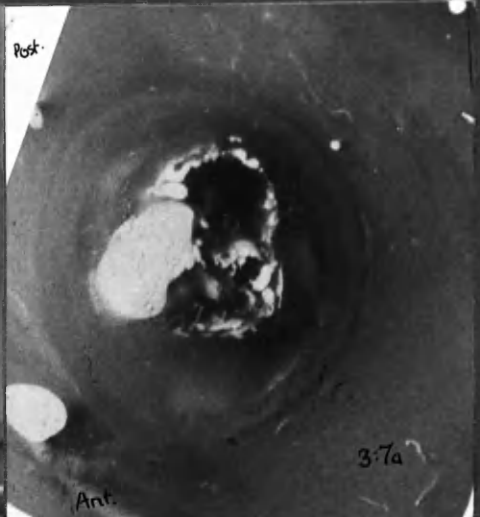
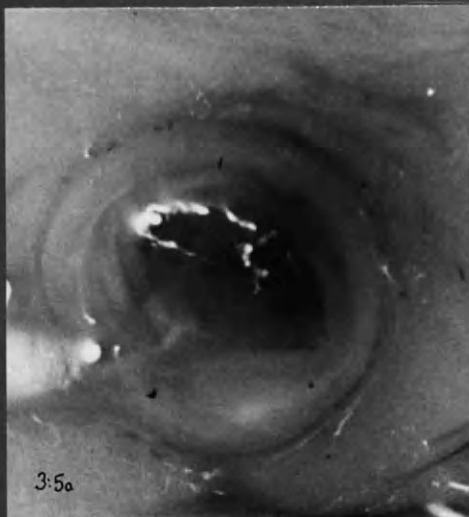
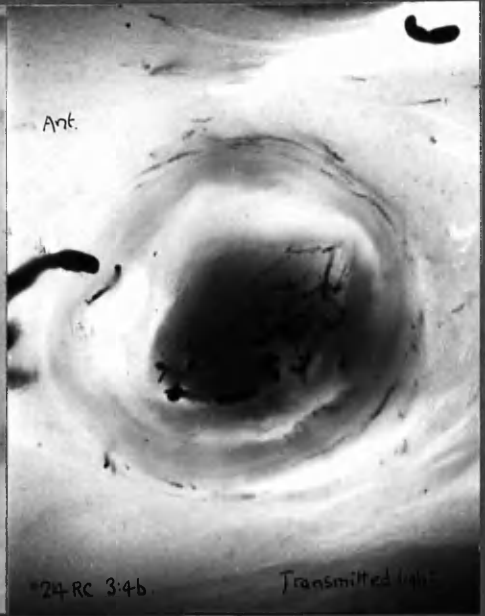
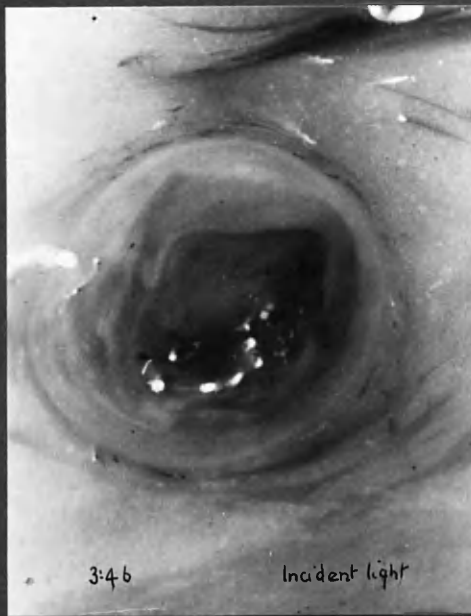1:9  
 2:1  
 2  
 3  
 4  
 5  
 6  
 7  
 8  
 3:1  
 2  
 3  
 4  
 5  
 6  
 7  
 4:1  
 2  
 3  
 4  
 5  
 6  
 7  
 5:1  
 2  
 3  
 4

- |   |                                  |   |                             |
|---|----------------------------------|---|-----------------------------|
|  | Dark red Thrombus . c. 6 months. |  | Pale atherosclerotic tissue |
|  | Mixed " " "                      |  | Pigmented " "               |
|  | Grey, fibrin " " "               |  | Translucent " "             |

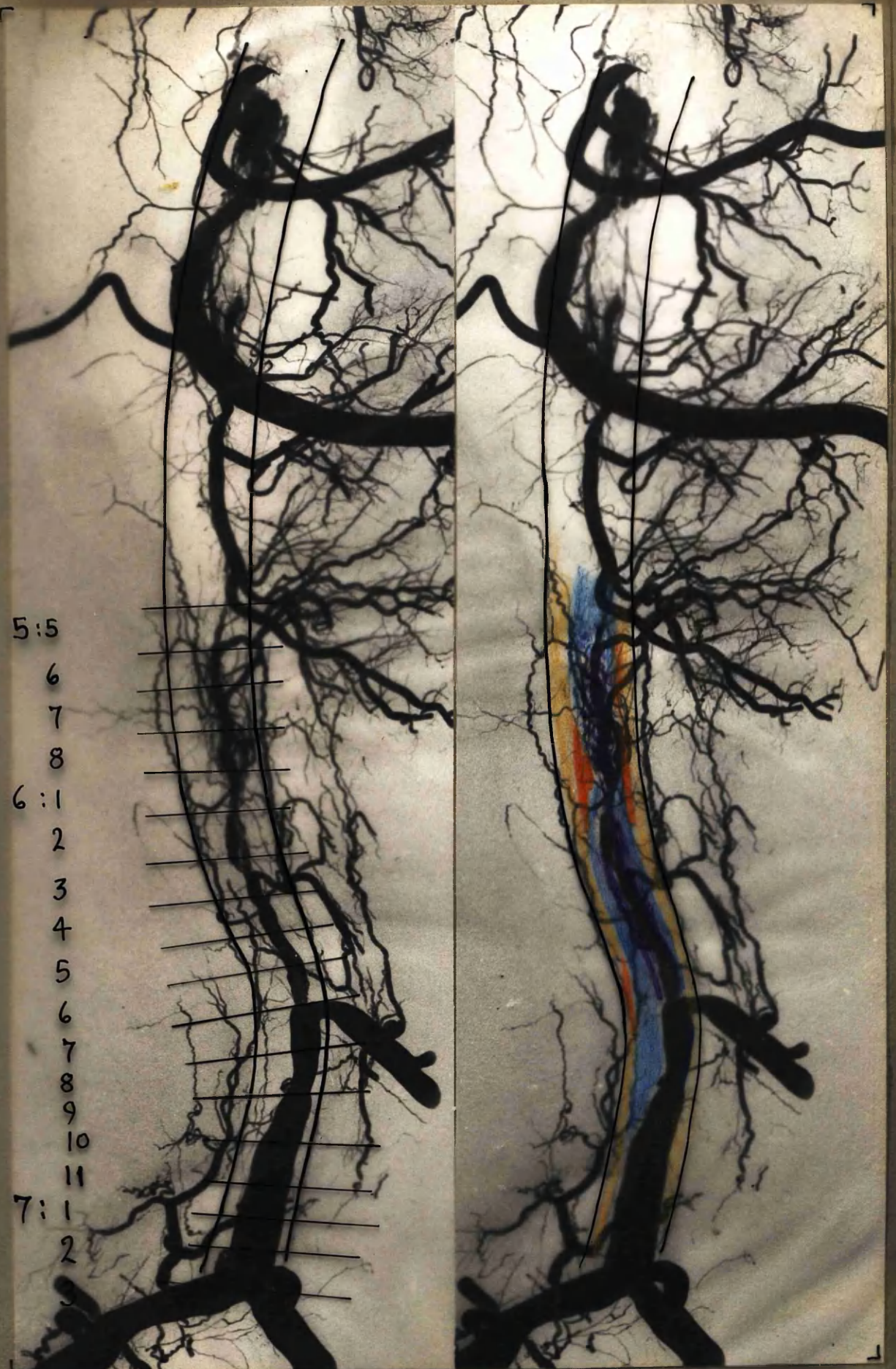
x4











5:5

6

7

8

6:1

2

3

4

5

6

7

8

9

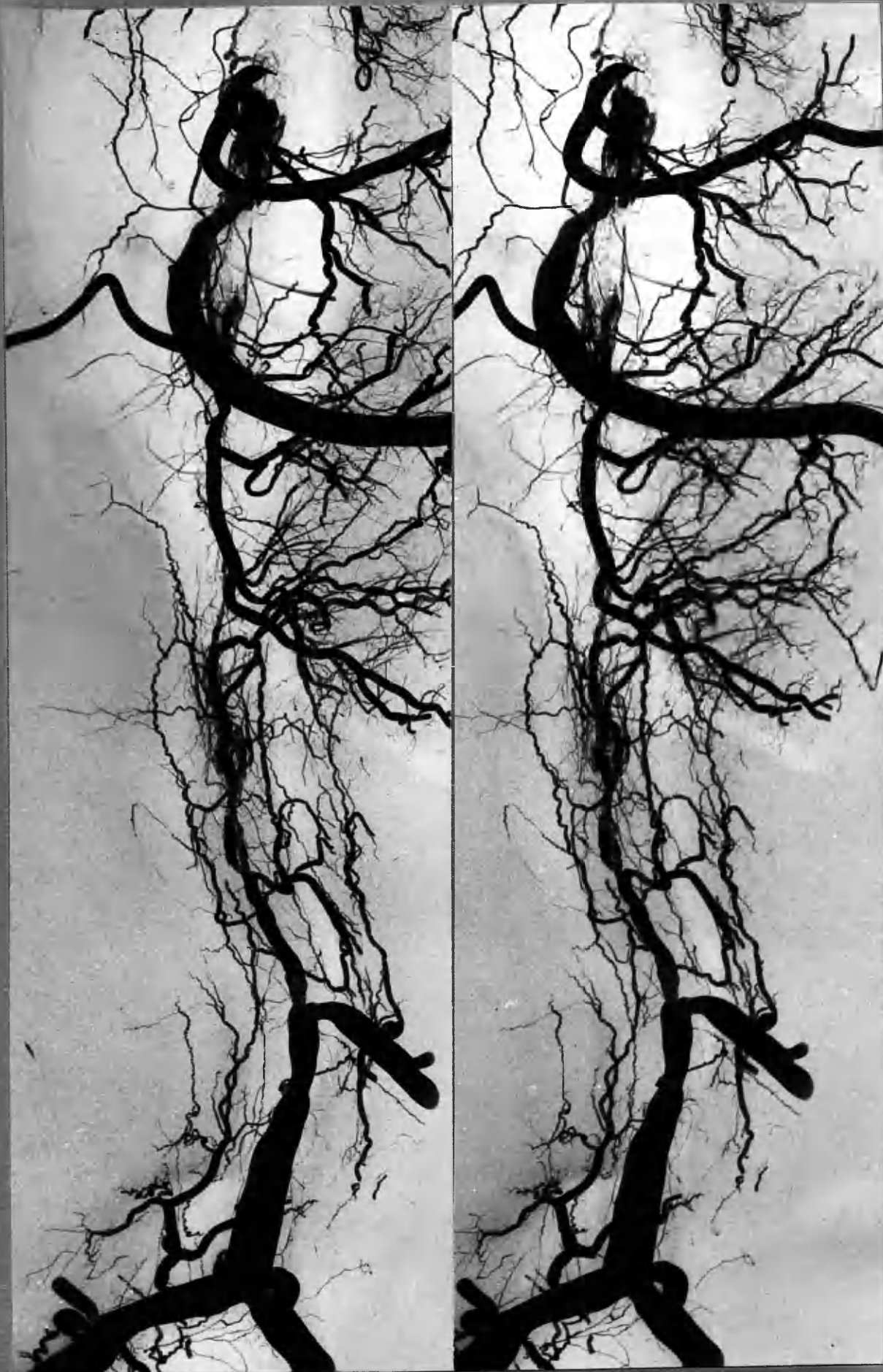10

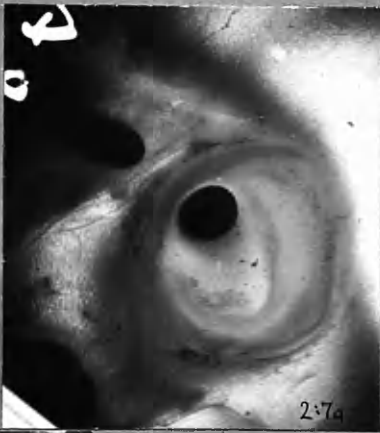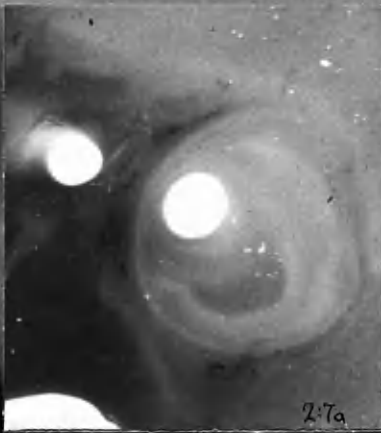
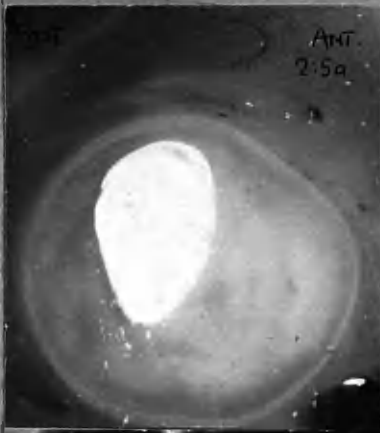
11

7:1

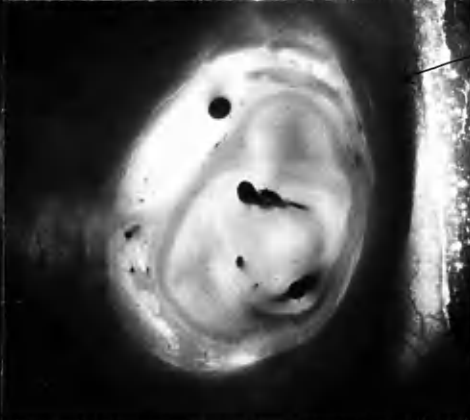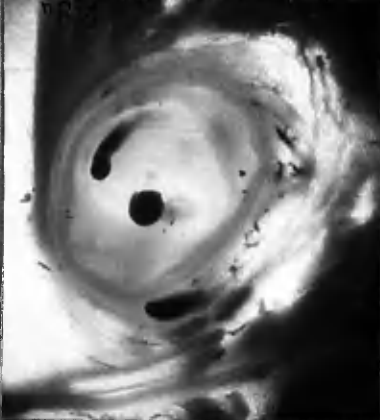
2



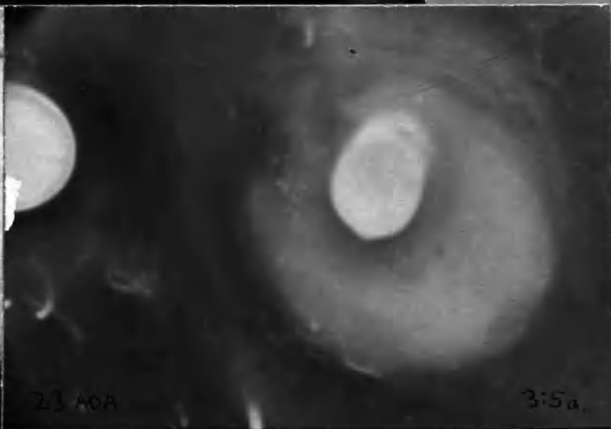
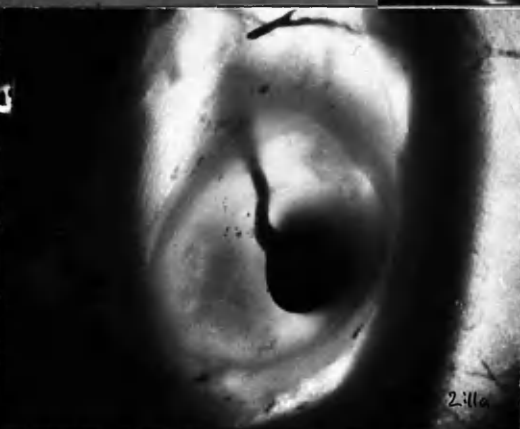
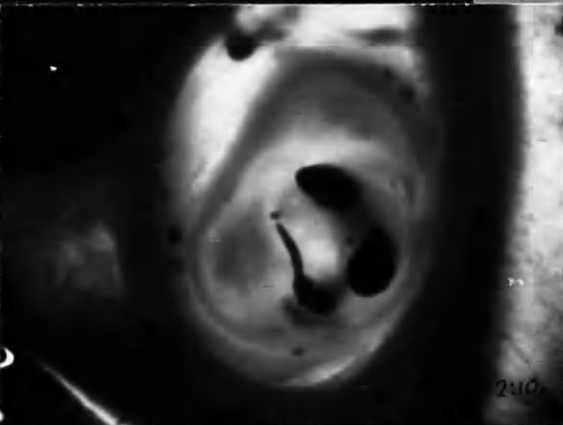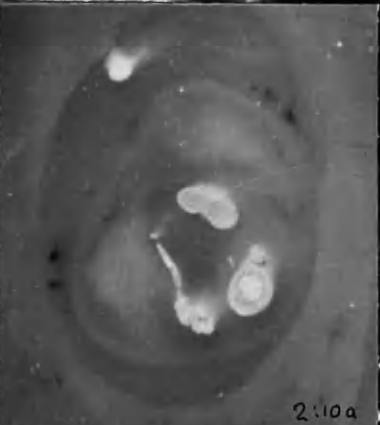




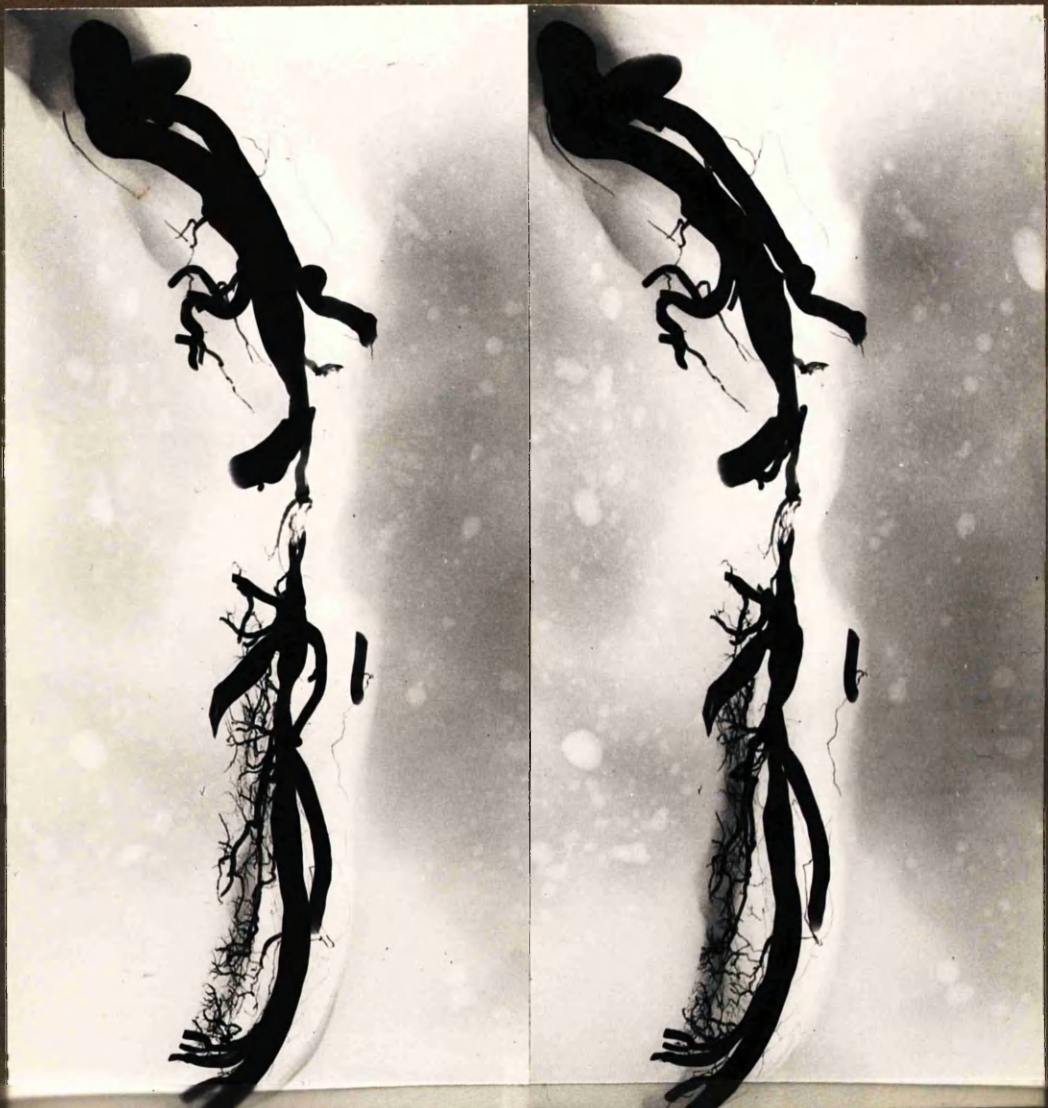Mounted upside down, in error



Myocardial Bridge.







Injection from L. coronary  
 " " R. "

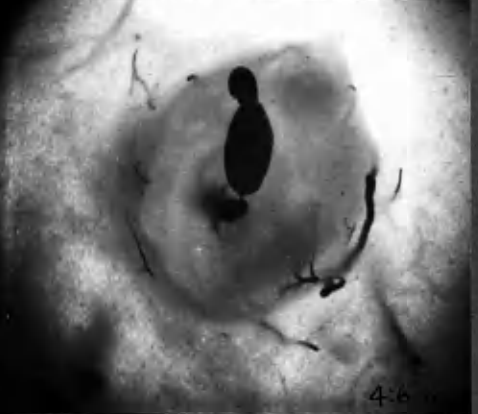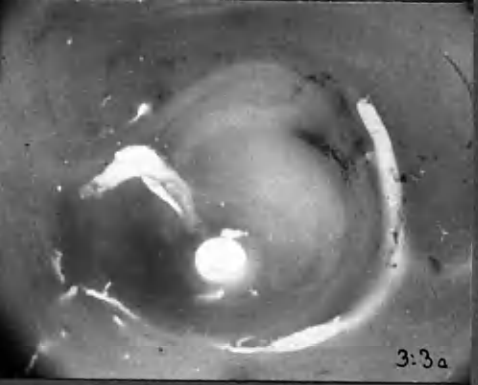
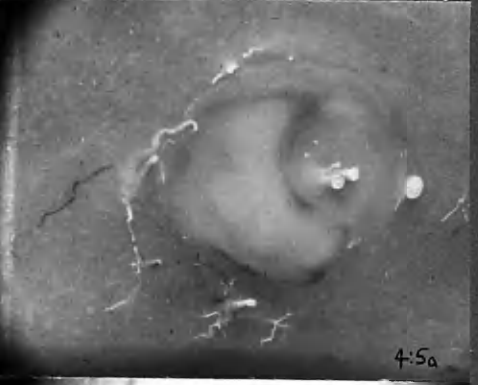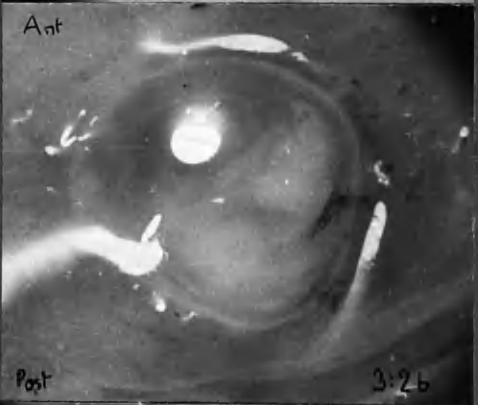
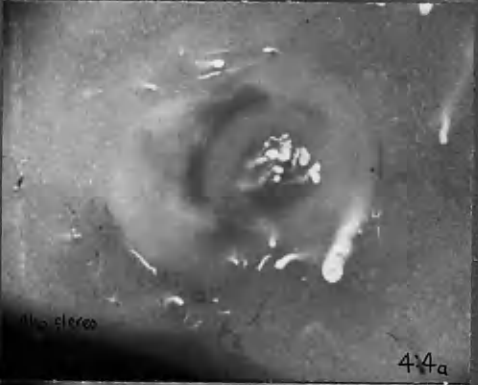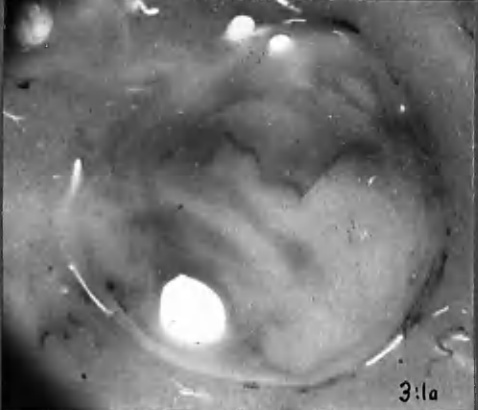
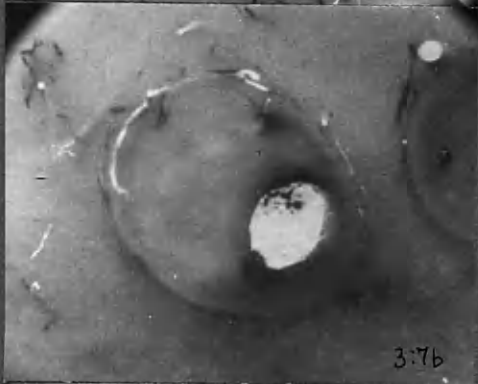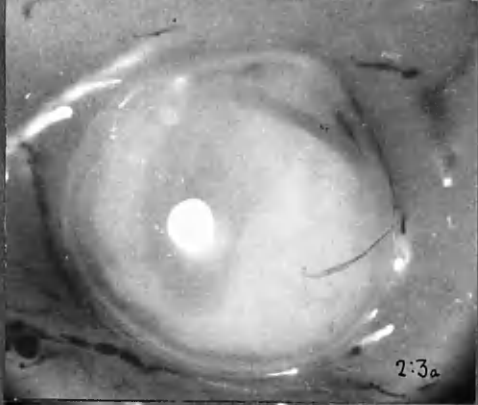
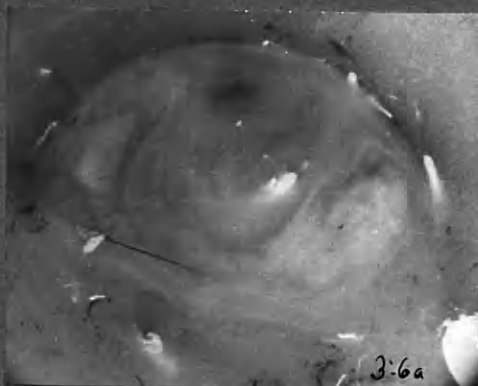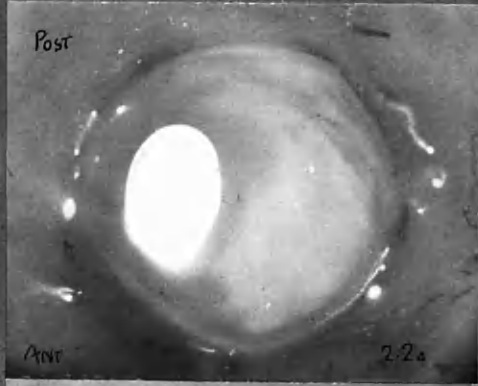
Pale atherosclerotic tissue  
 Pigmented " "  
 Translucent " "  
x4



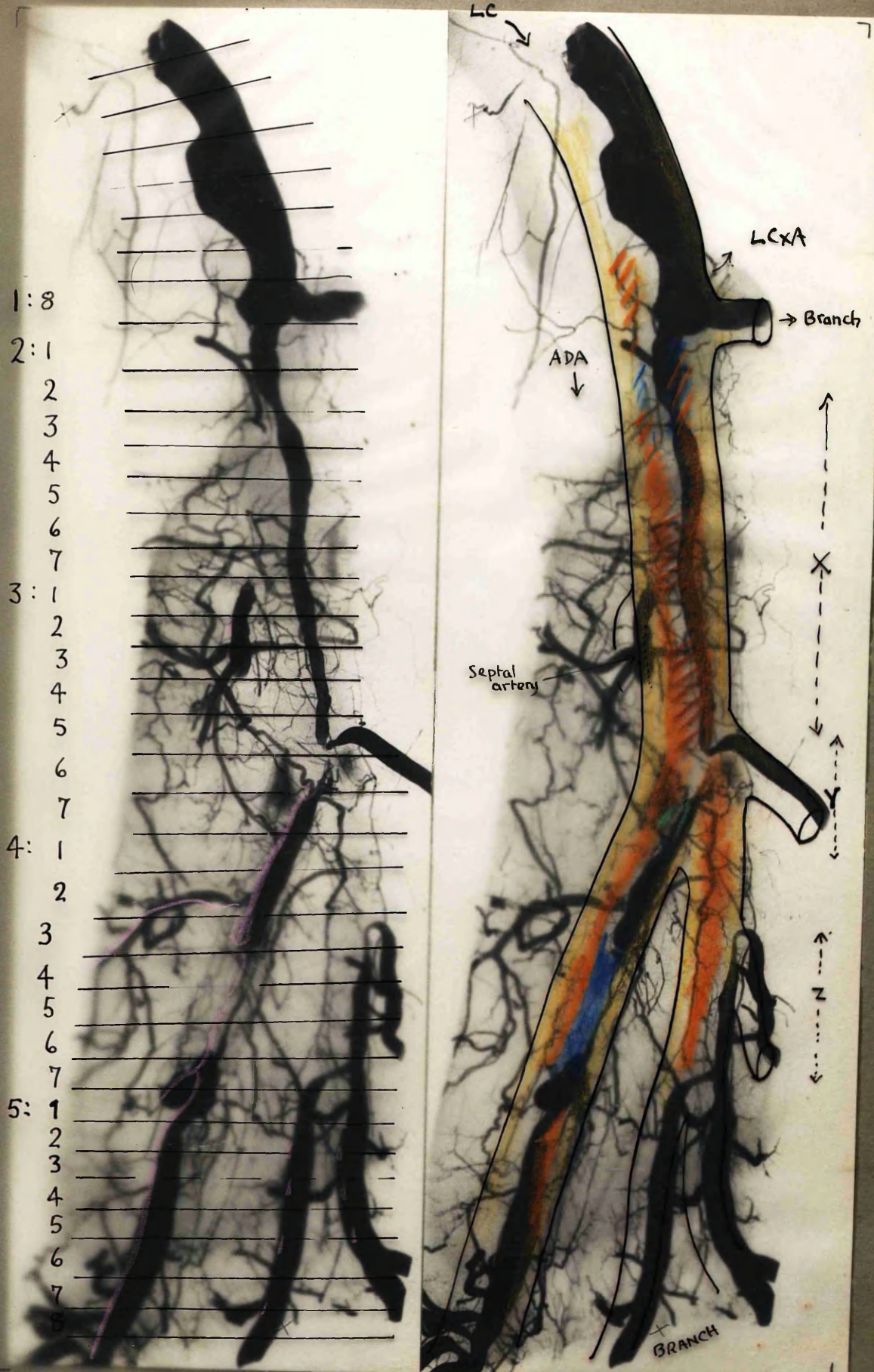
x2



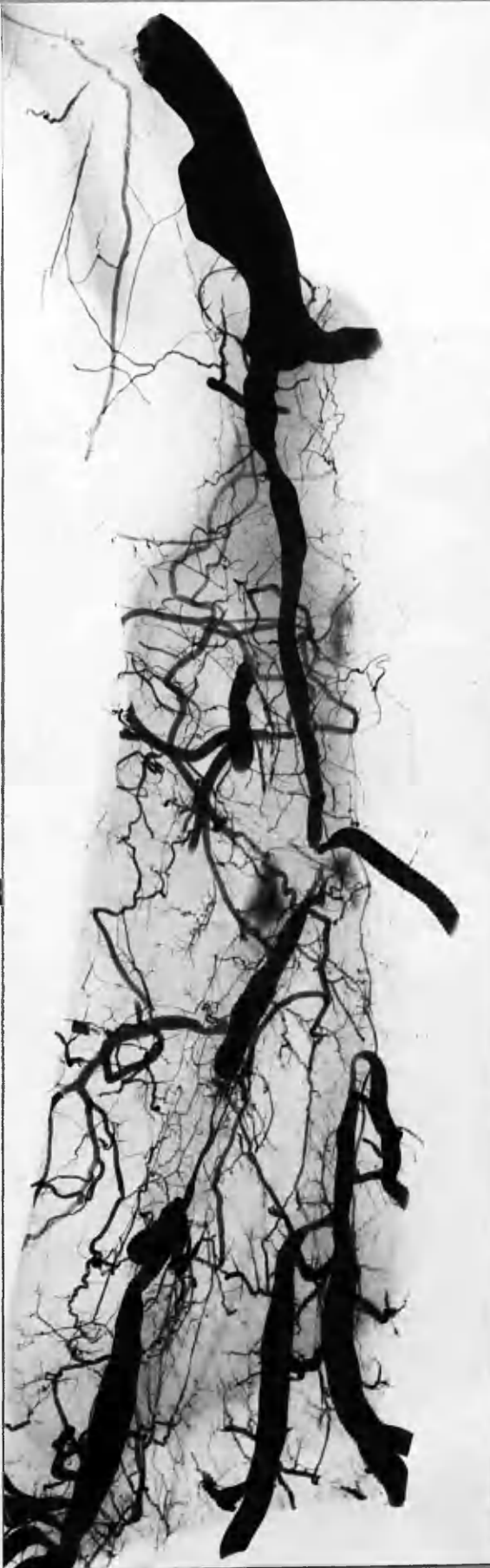
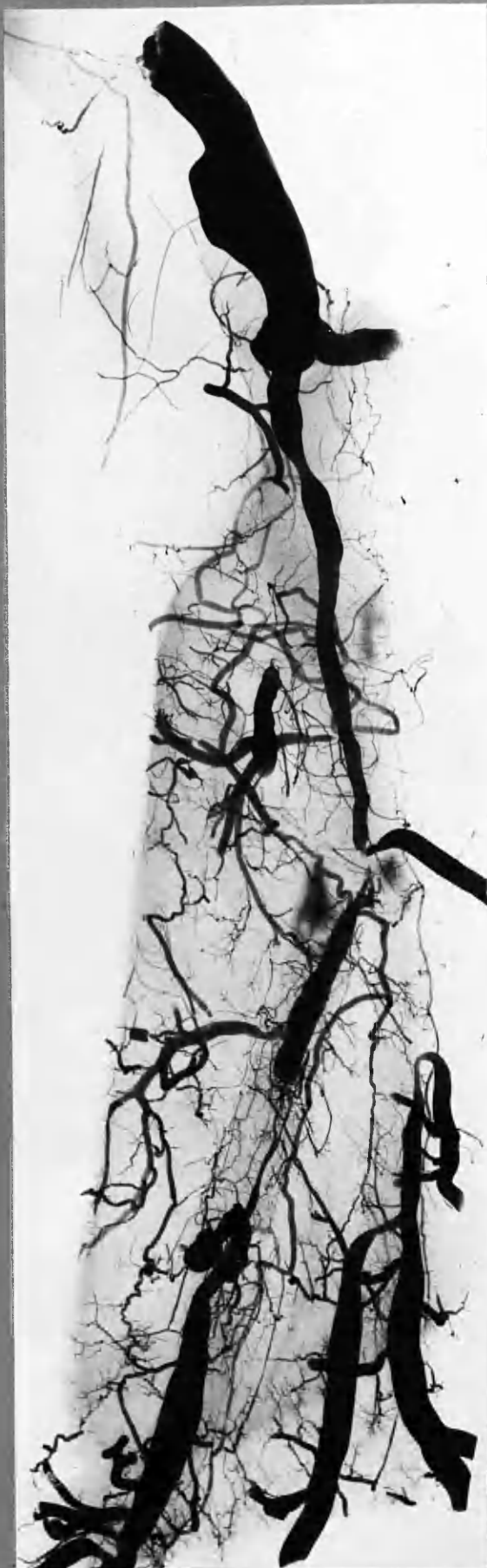x4





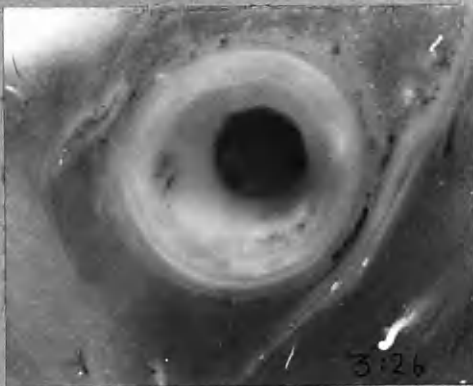
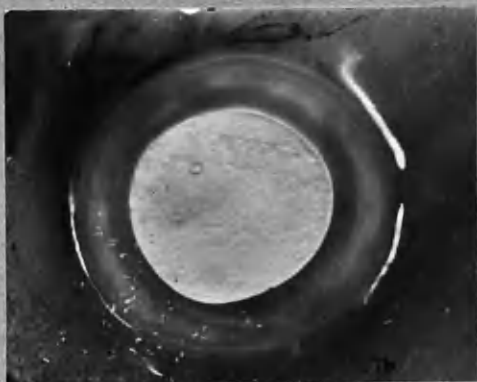


- |   |                                   |  |  |
|---|-----------------------------------|--|--|
|  | Recent, dark thrombus.            |  | Pale atherosclerotic tissue <sup>3</sup> |
|  | Injection from RC.                |  | Pigmented " " (≡ thrombus 2 yrs)         |
|  | Very dark pigment (altered blood) |  | Translucent " "                          |

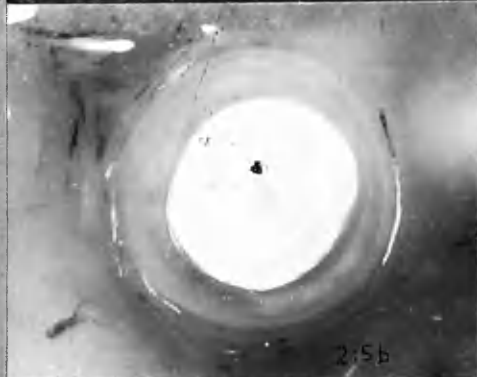



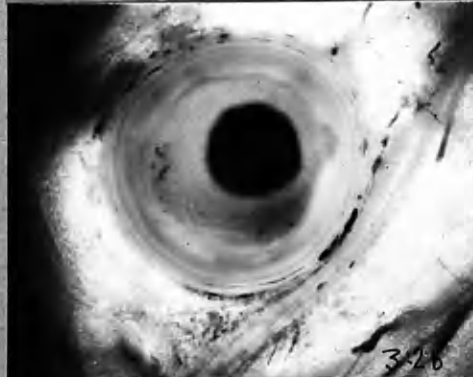
20 ADA



3:26



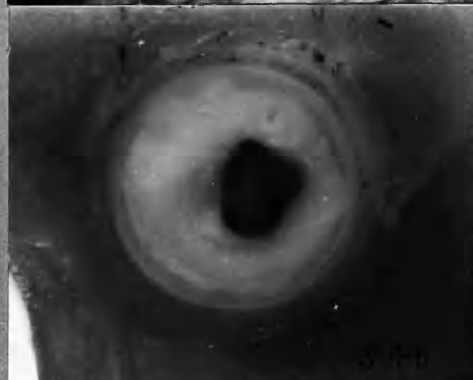2:5b



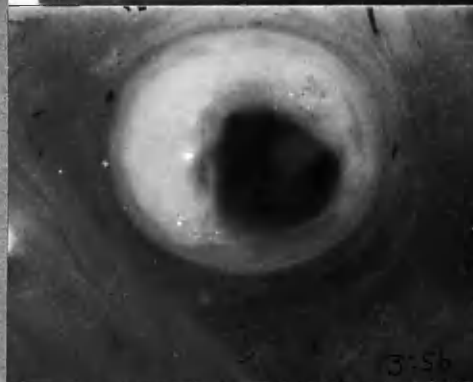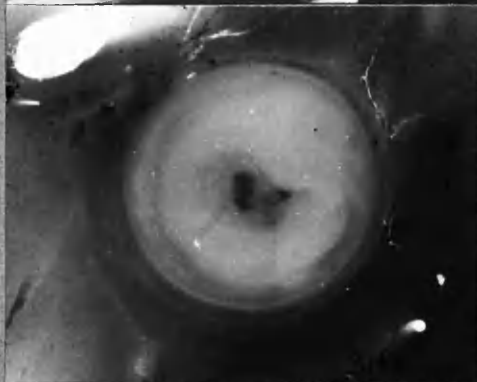
3:16



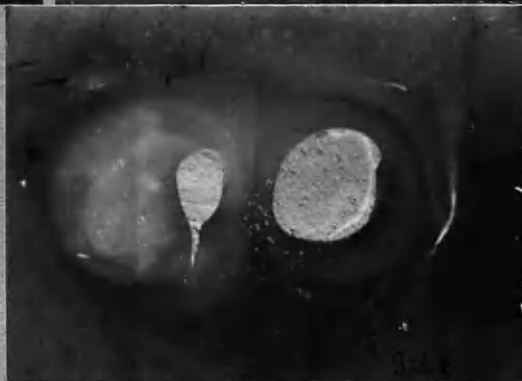2:16



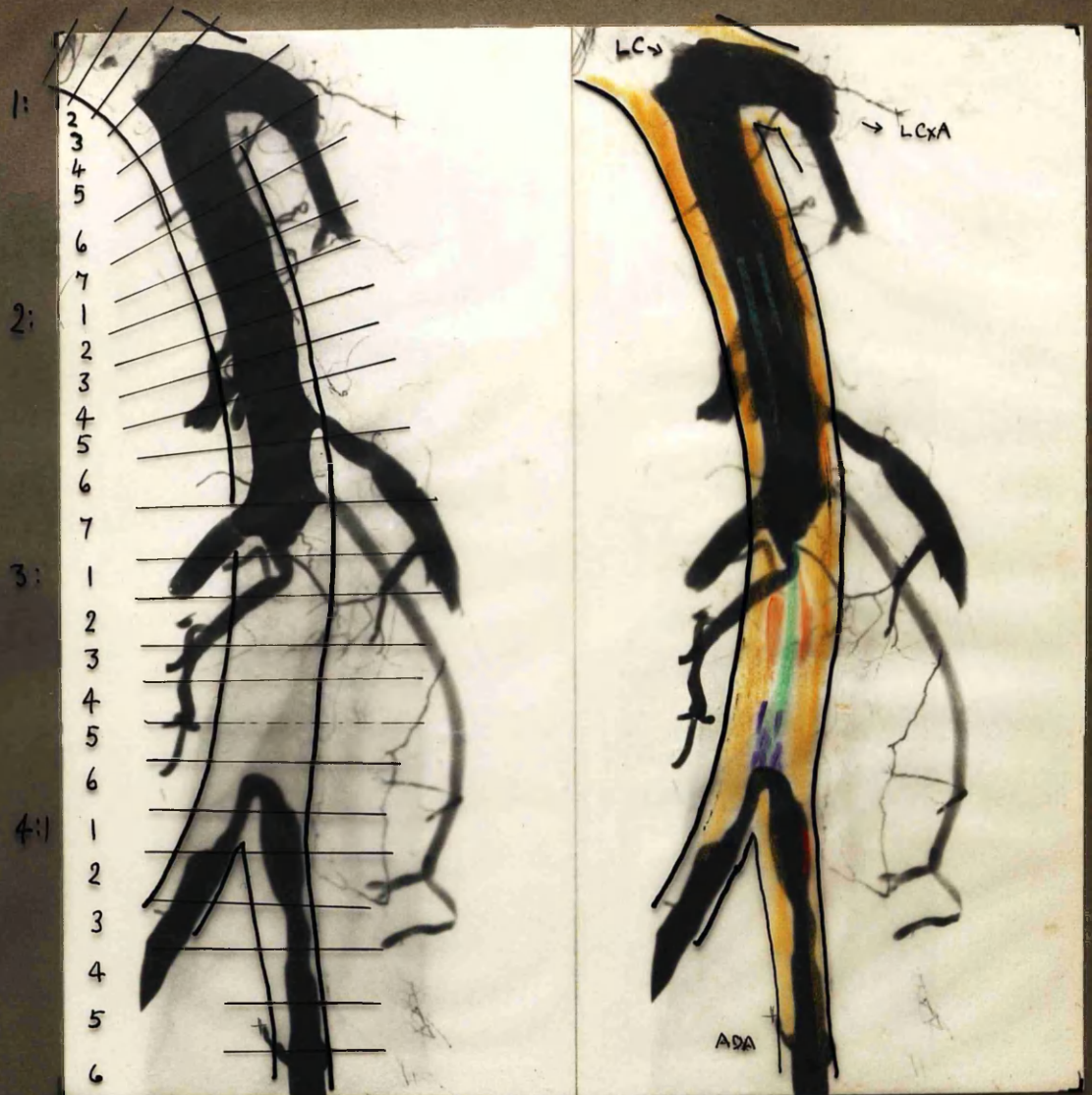
3:16



3:5b



x 10




1: 2  
3  
4  
5  
6  
7  
2: 1  
2  
3  
4  
5  
6  
7  
3: 1  
2  
3  
4  
5  
6  
4: 1  
2  
3  
4  
5  
6

- Dark Red Thrombus, ? Bulks.
- Grey, fibrin thrombus, " "
- Dark red mural " , ? age
- ? Haemorrhage.

- Pale atherosclerotic tissue.
- Pigmented " "
- Injection from R.C. cannula.

x4

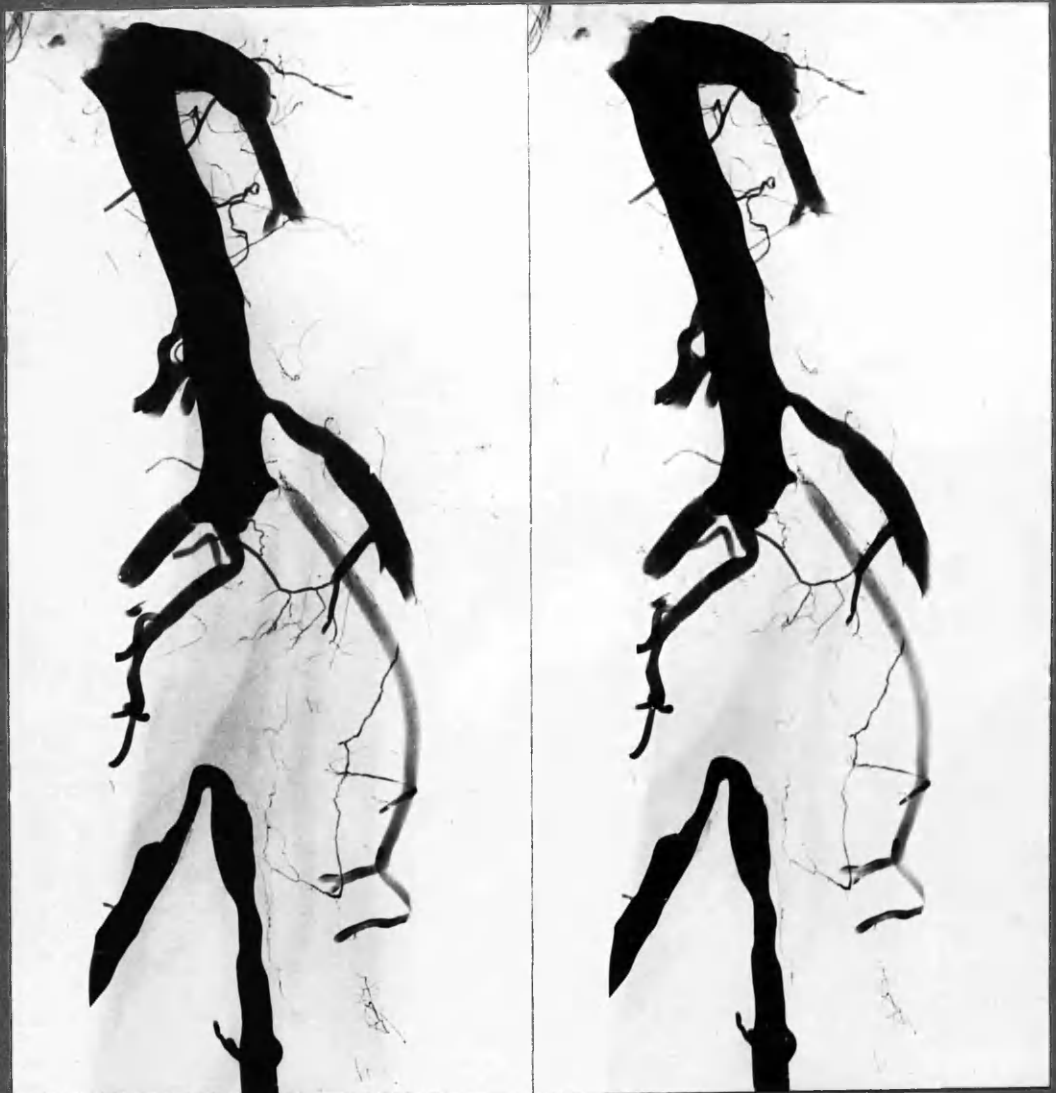

x 10


20ADA

21b

21c



x4



x 10

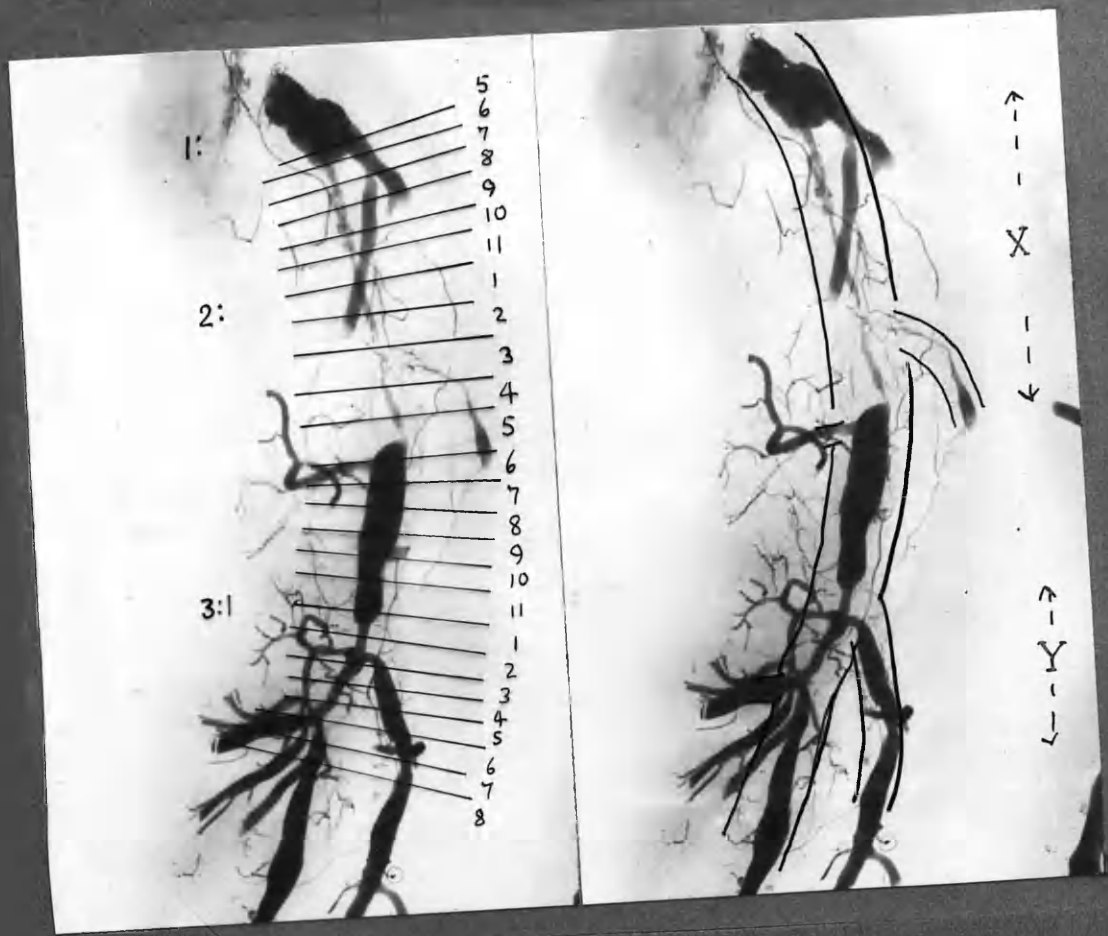
20ADA

21b

21b

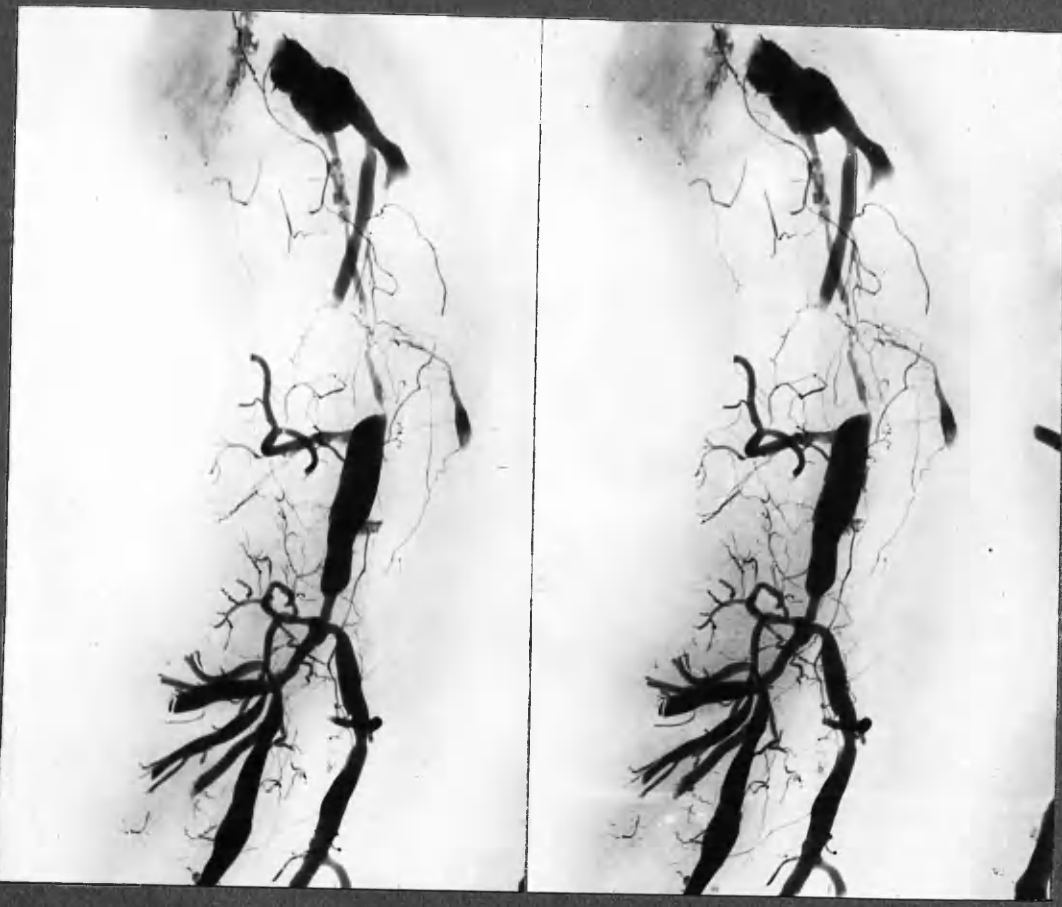


18 ADA

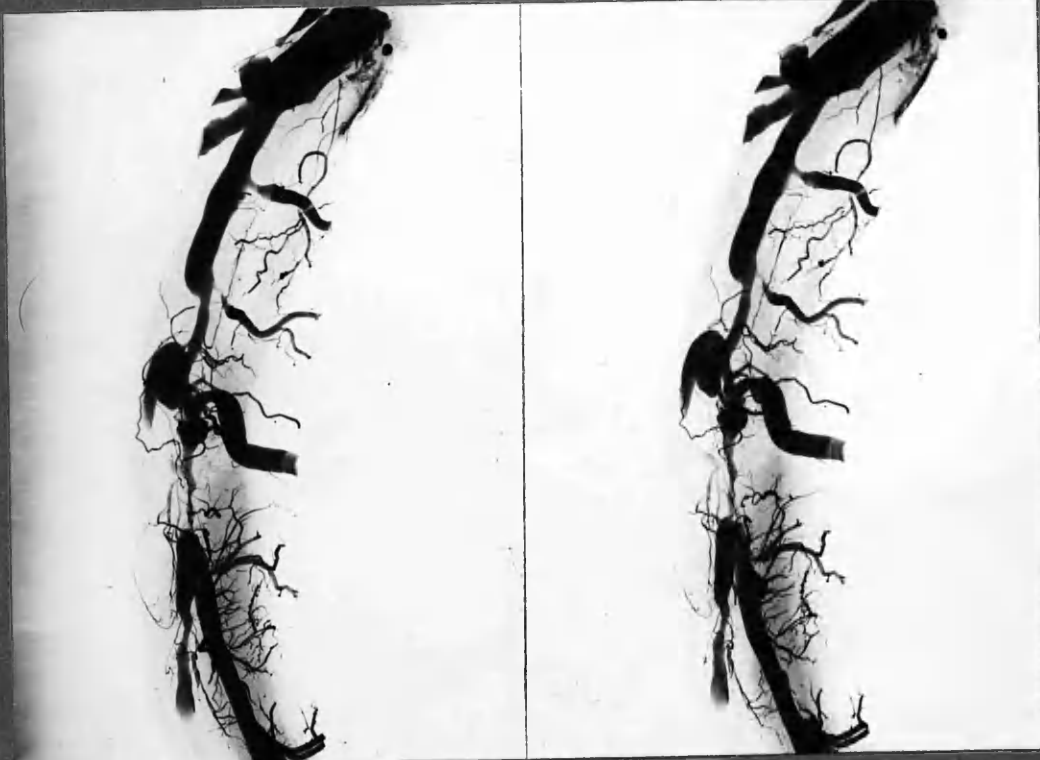


x2

18 ADA

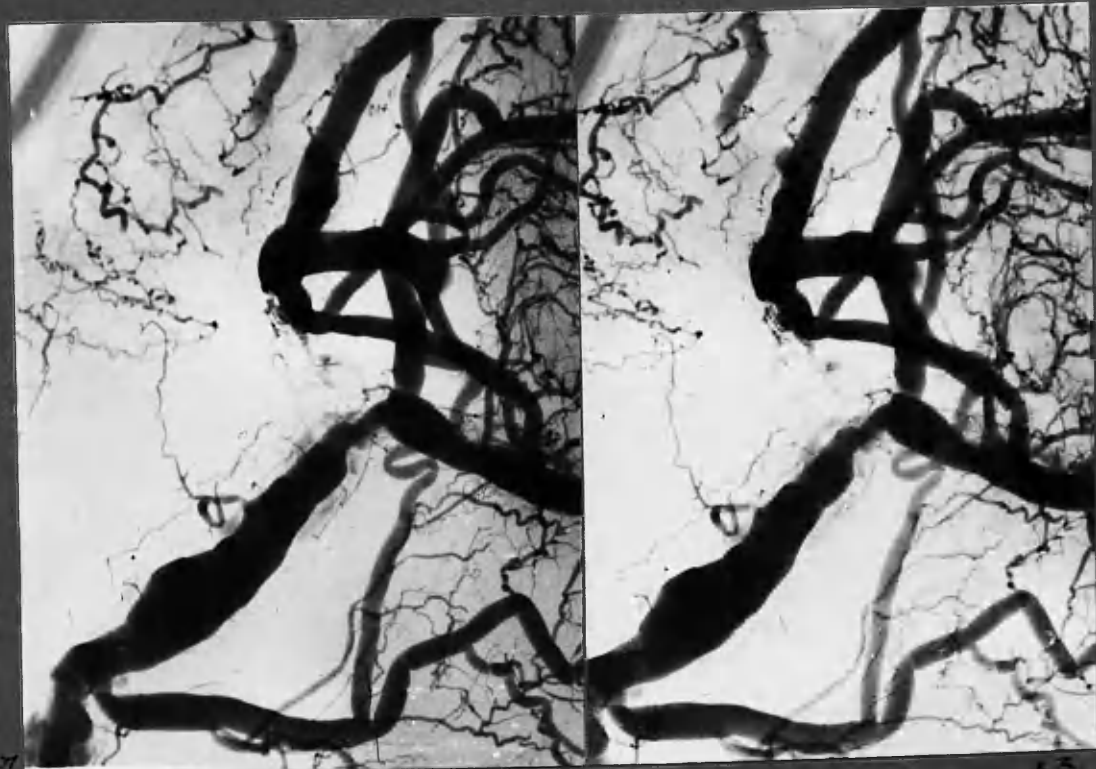


x2



x2

17 RC



Post. l.-v. art.

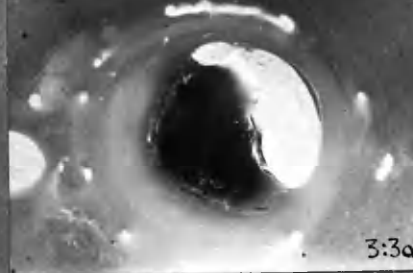

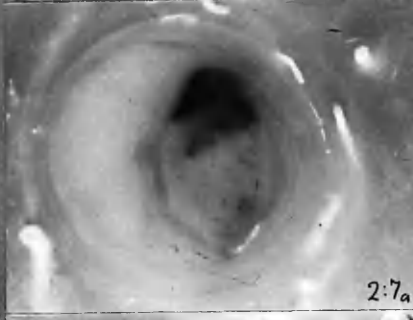
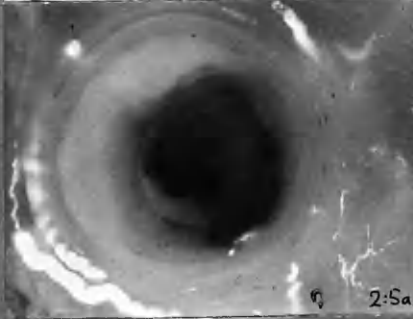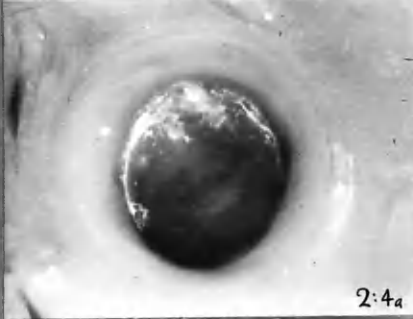
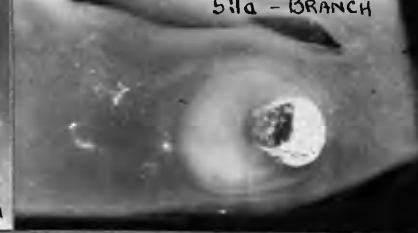

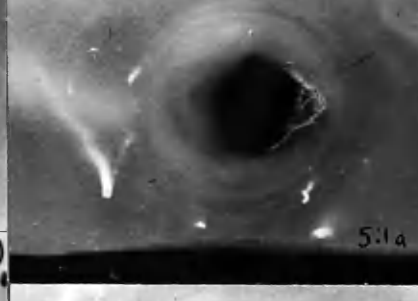
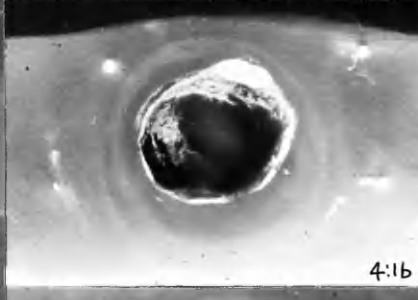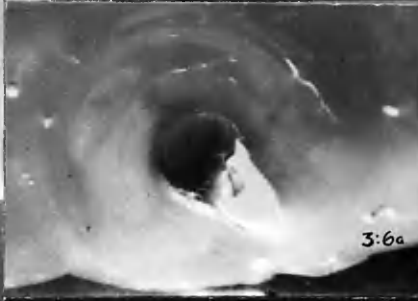

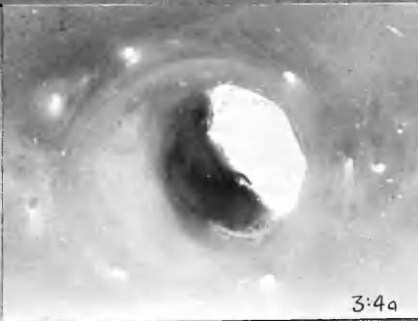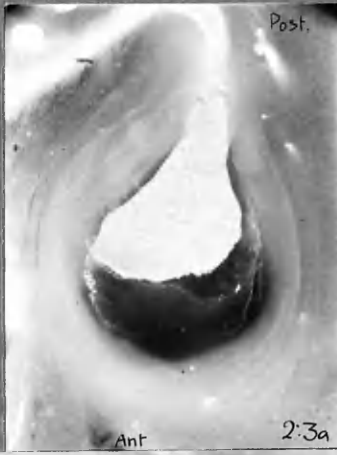
x3

RC →

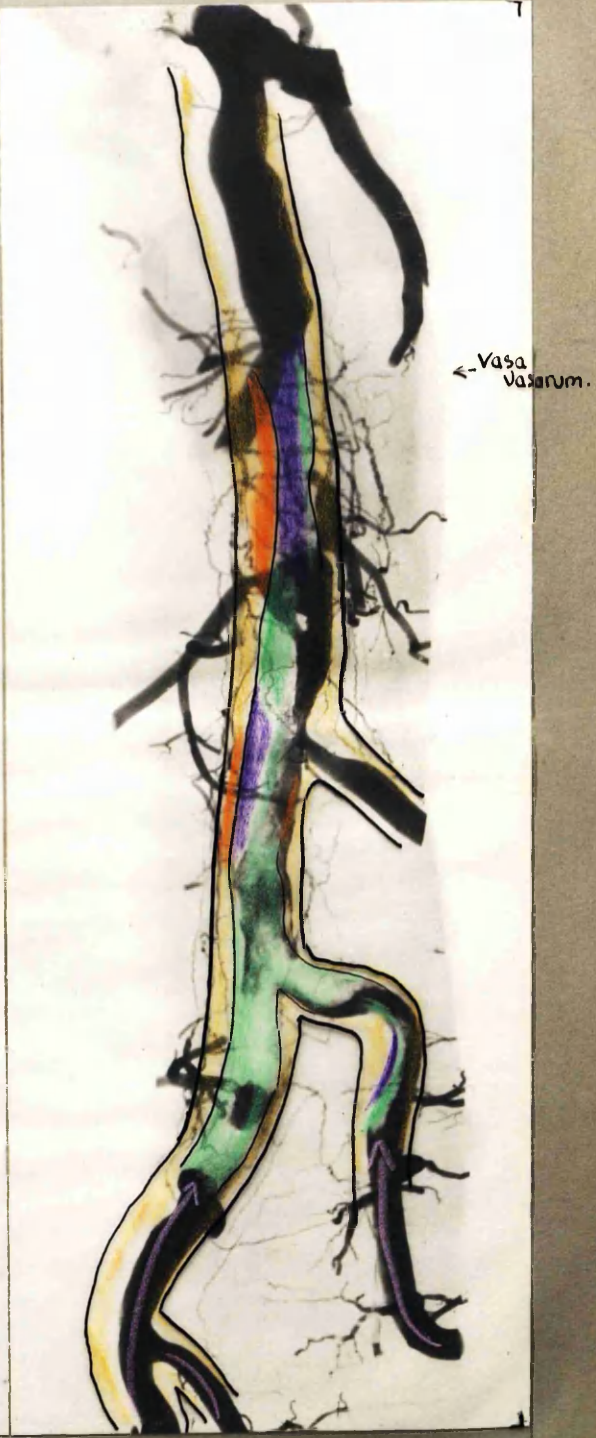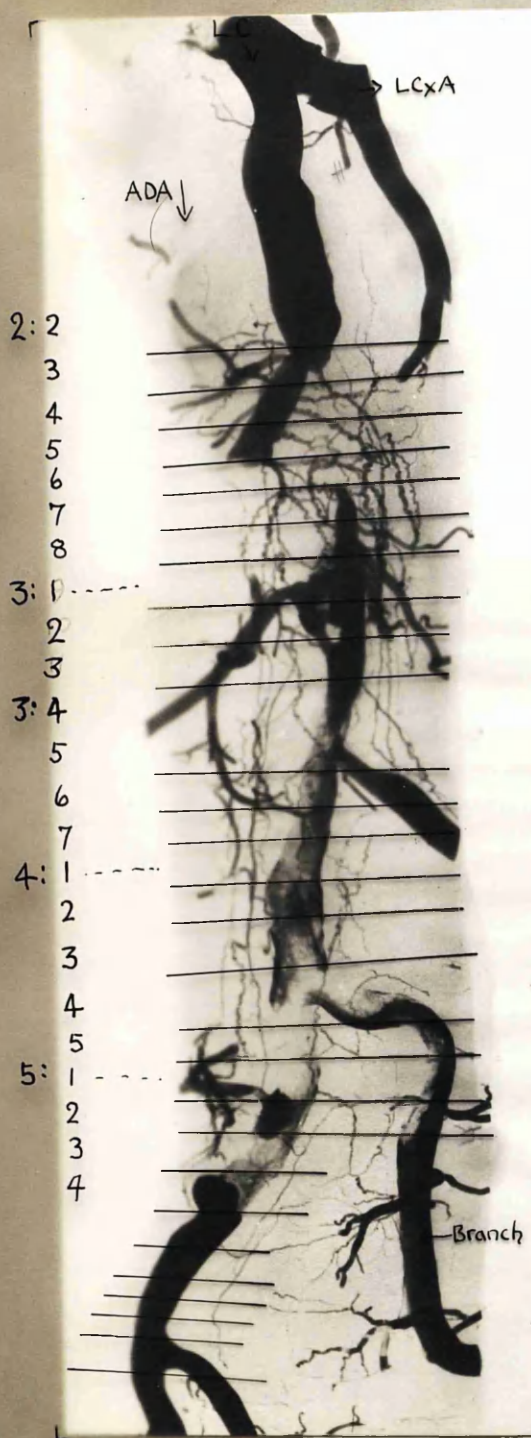
Distal (posterior) end of RC., showing anastomosis between canalising and adventitial vessels. This was unusual.








16 ADA

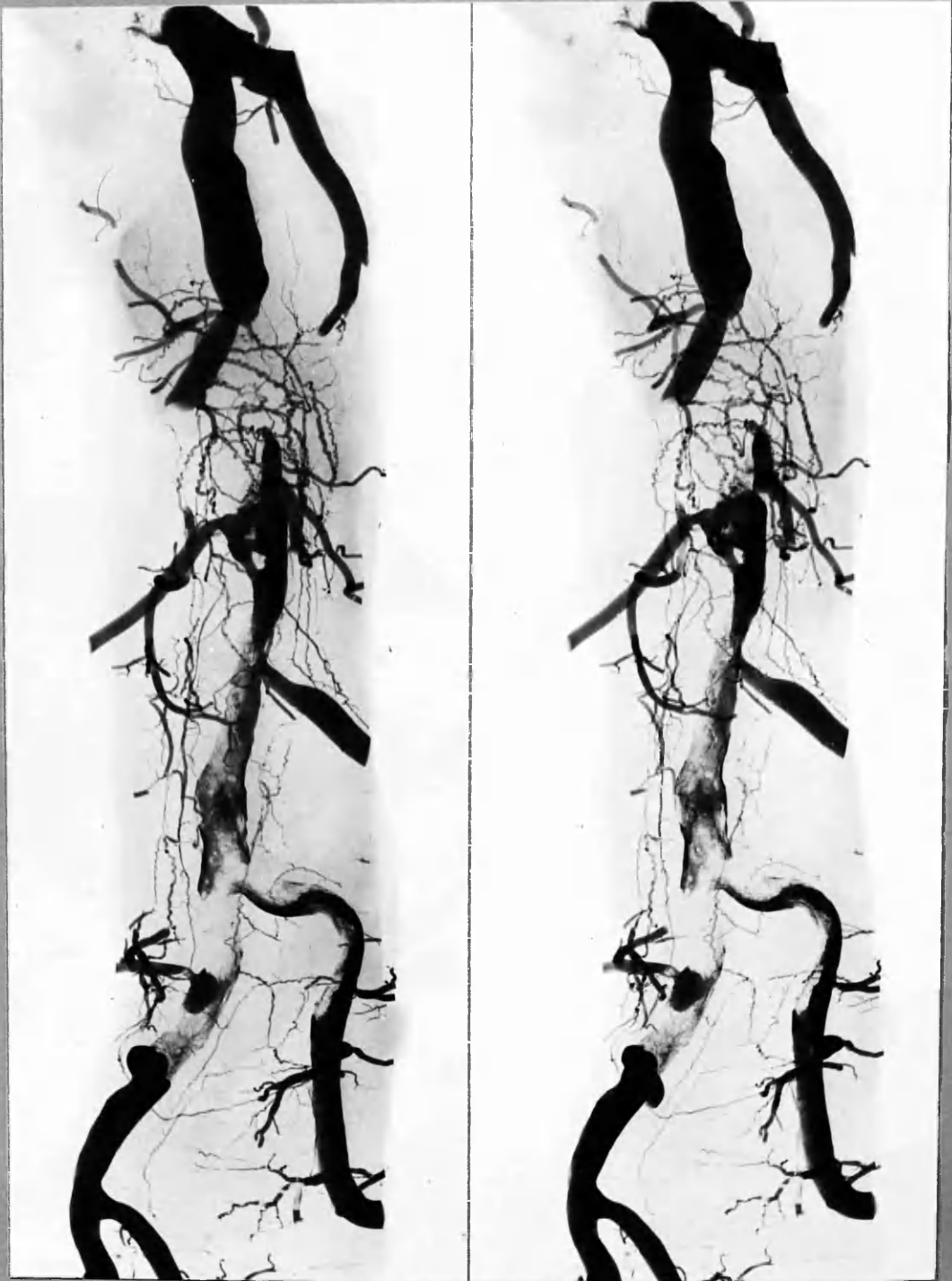


x 8



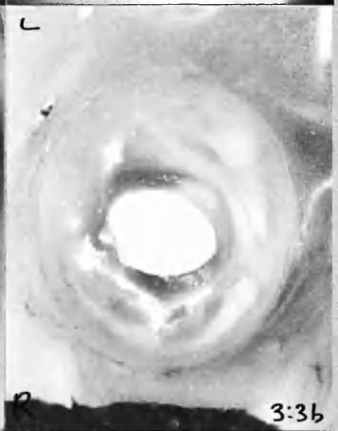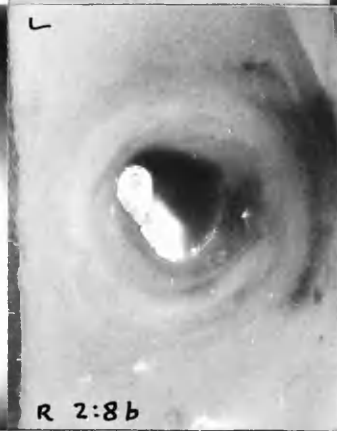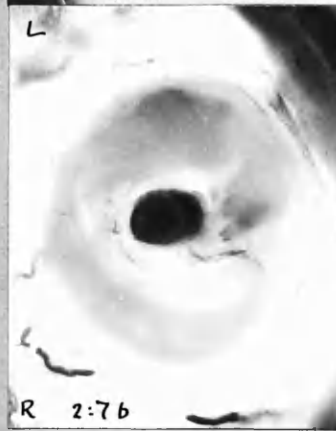
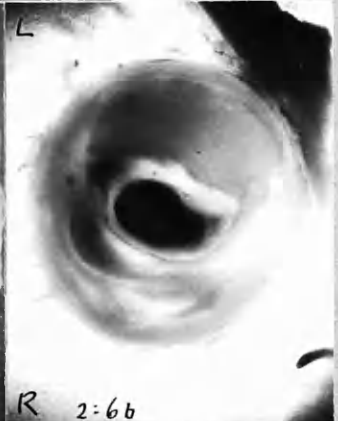
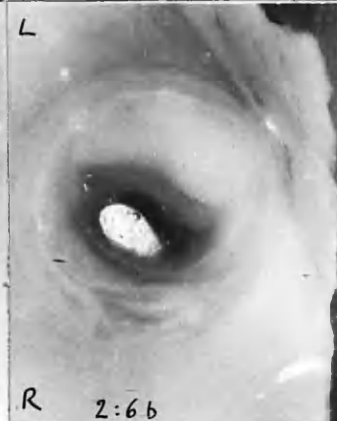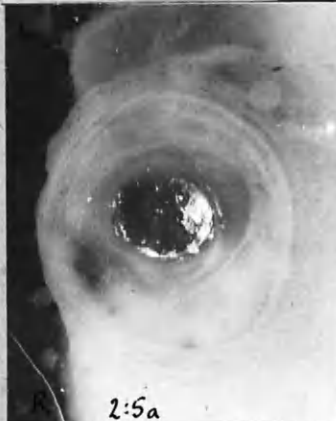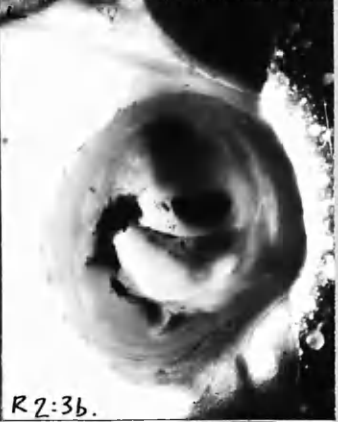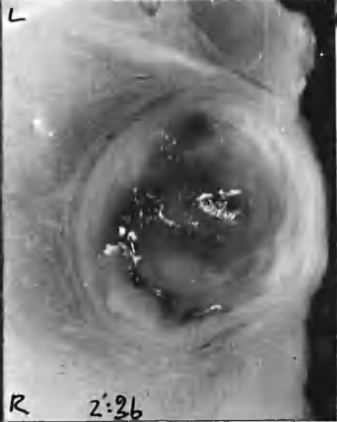
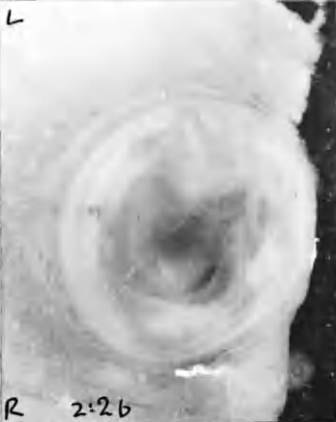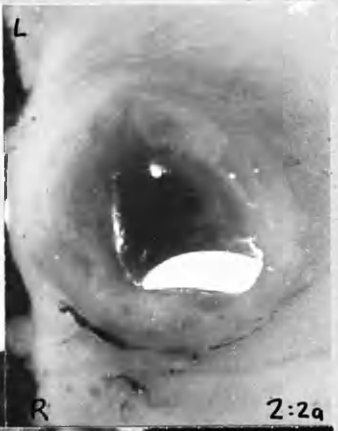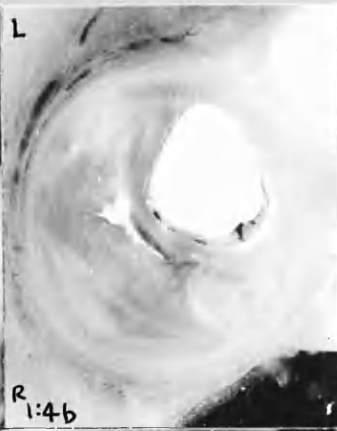
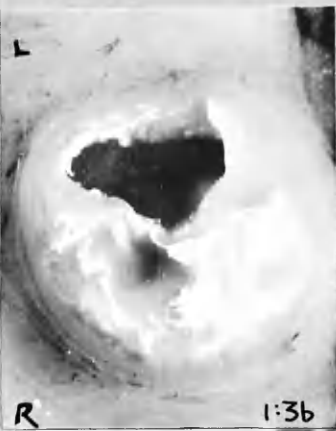- |   |                              |   |   |
|---|------------------------------|---|---|
|  | Dark red thrombus, c. 8 wks? |  | Pale atherosclerotic tissue <sup>x3</sup> |
|  | Grey, fibrin " " "           |  | Pigmented " "                             |
|  | Injection from R.C. cannula. |   |   |





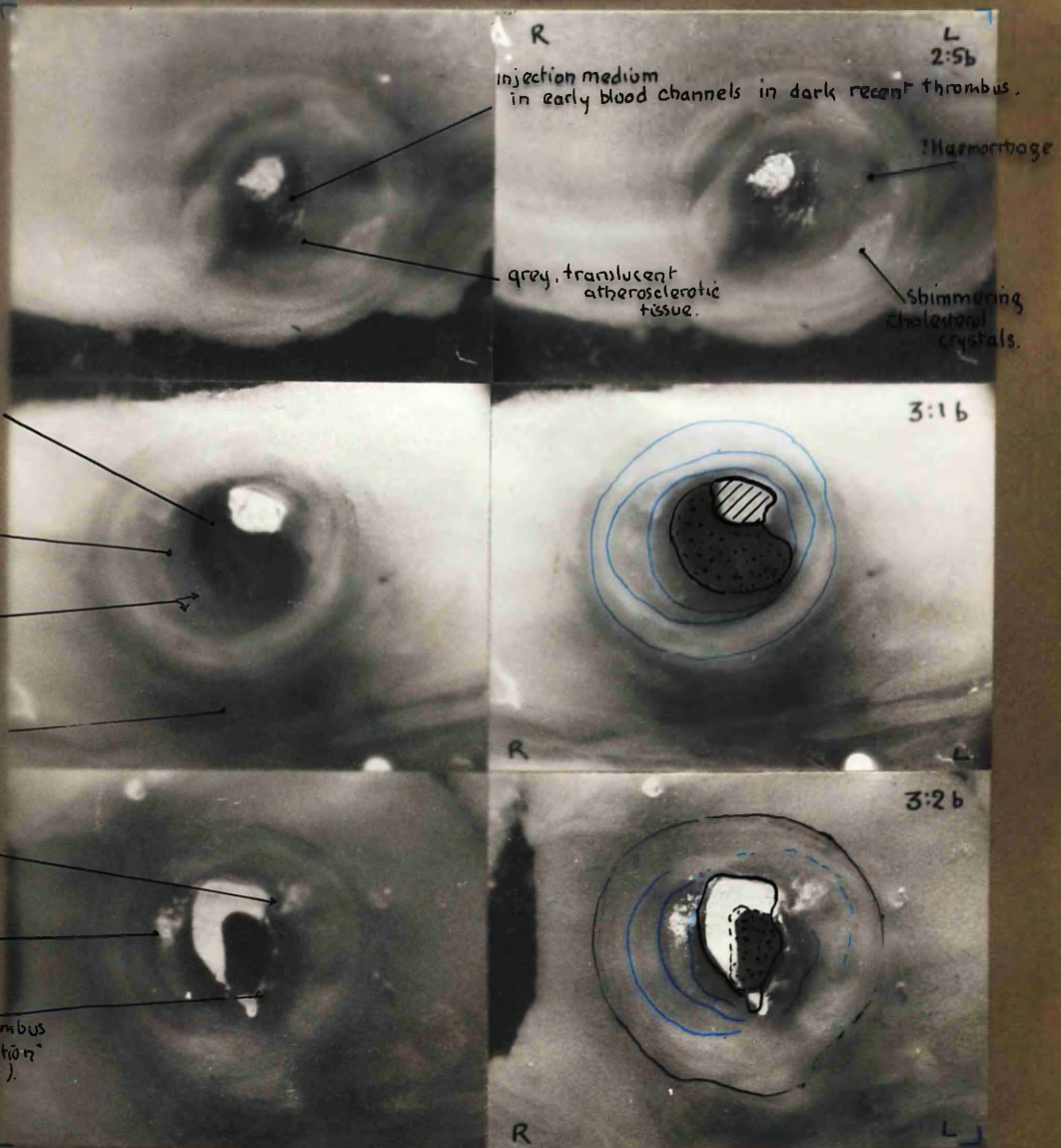
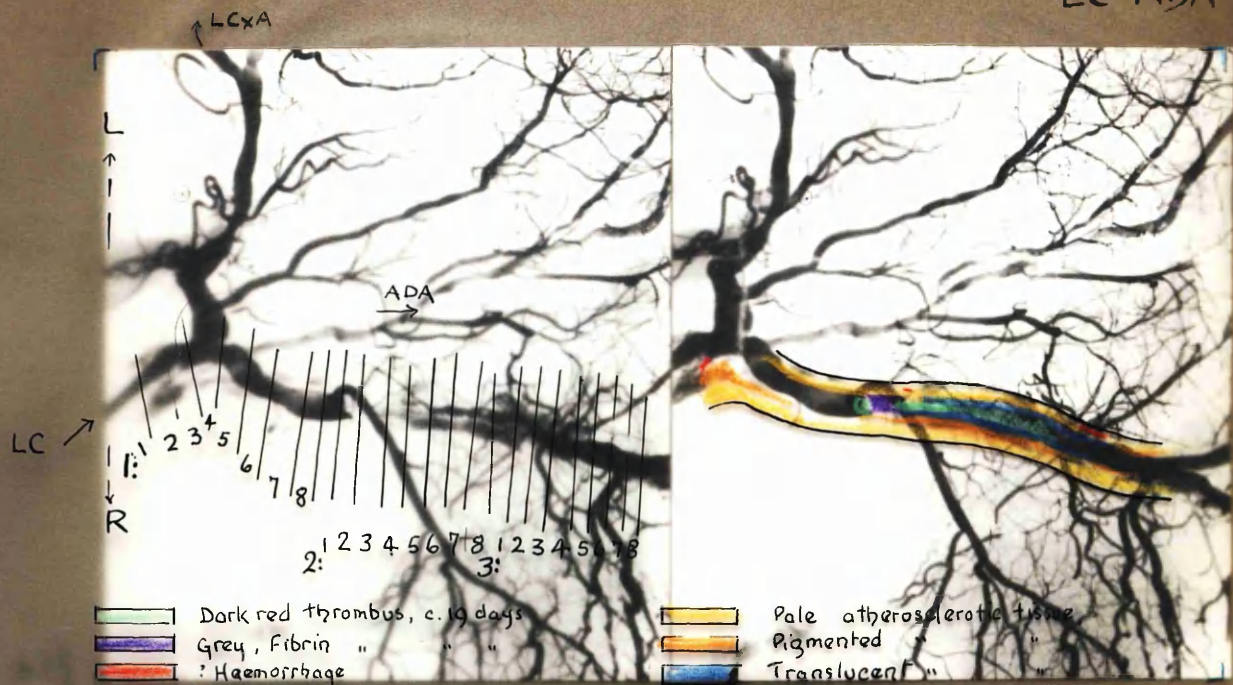
x3

14 ADA

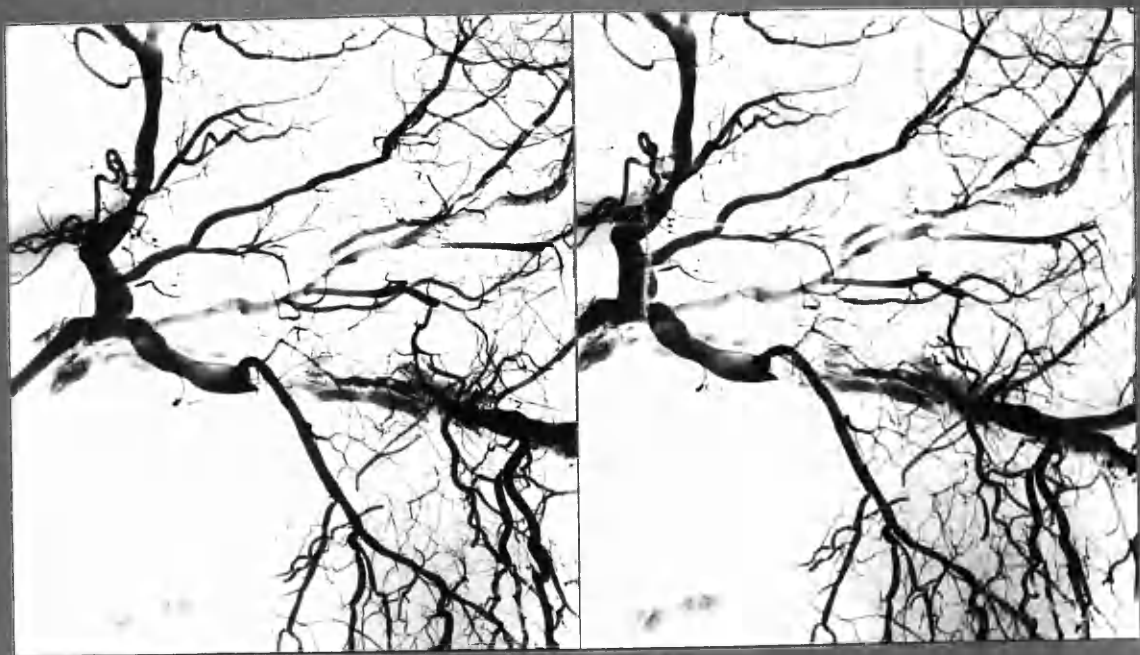


x 7 1/2

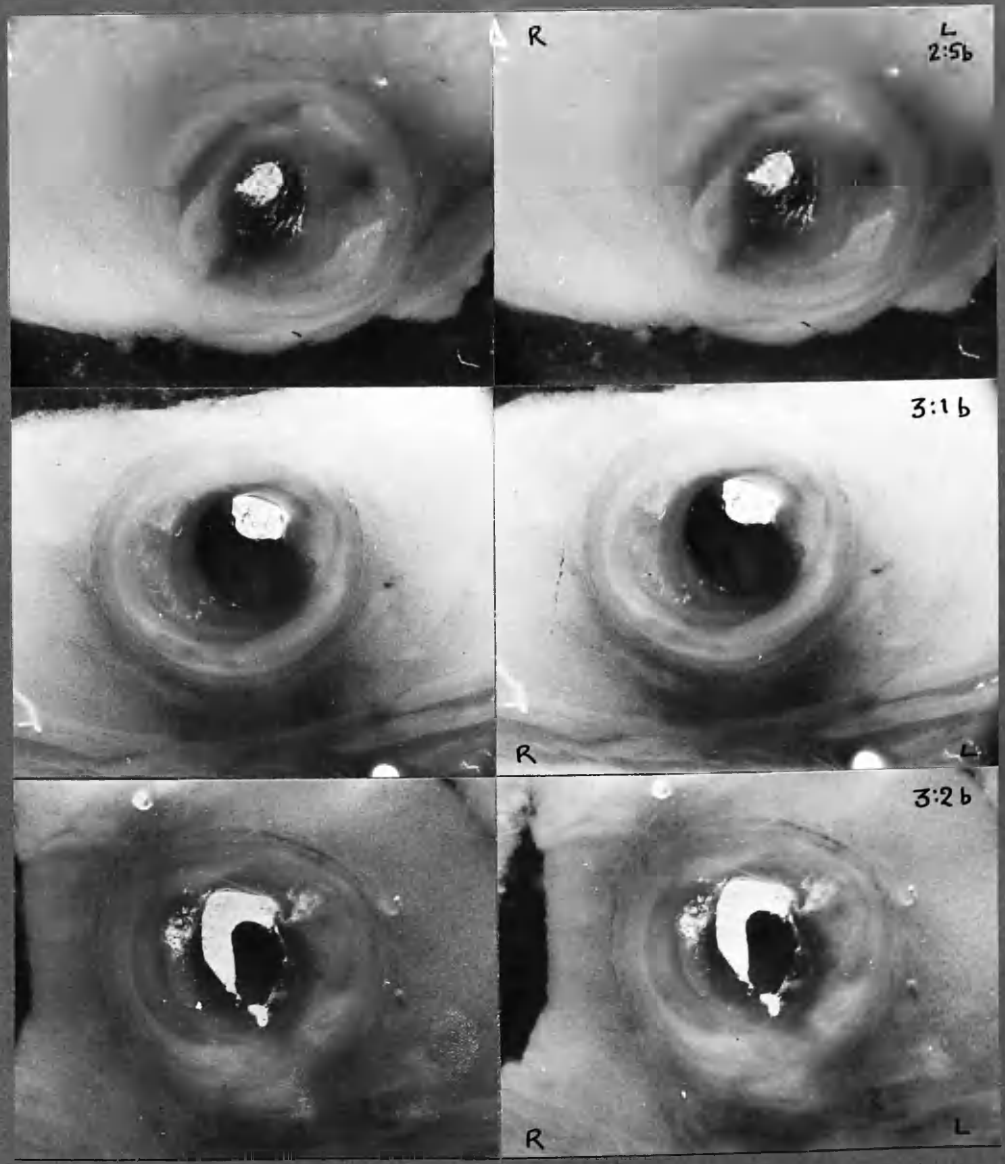




3 Stereo pairs of arterial sections viewed from the distal aspect: swing through 90° anticlockwise for orientation with arteriograms. See also COLOUR TRANSPARENCIES, Chap. 8.



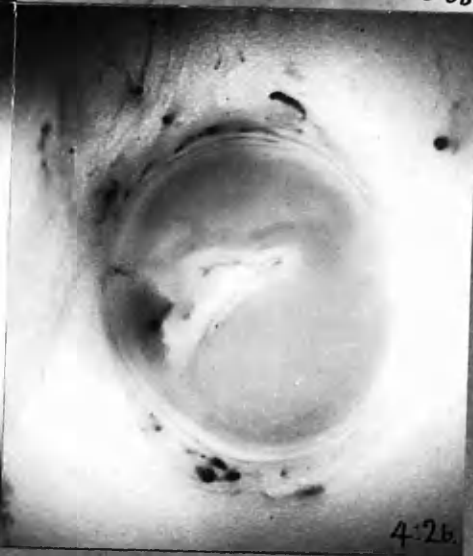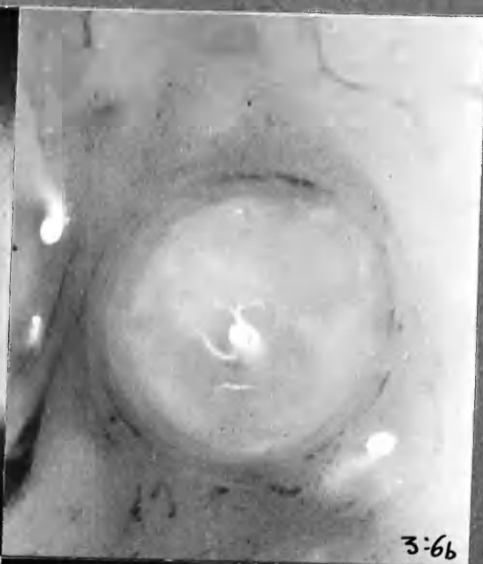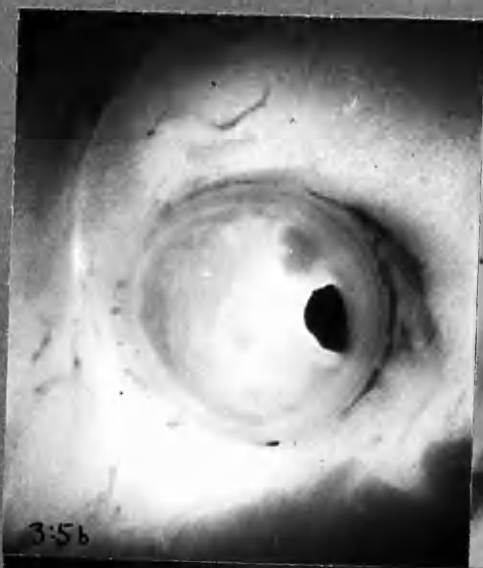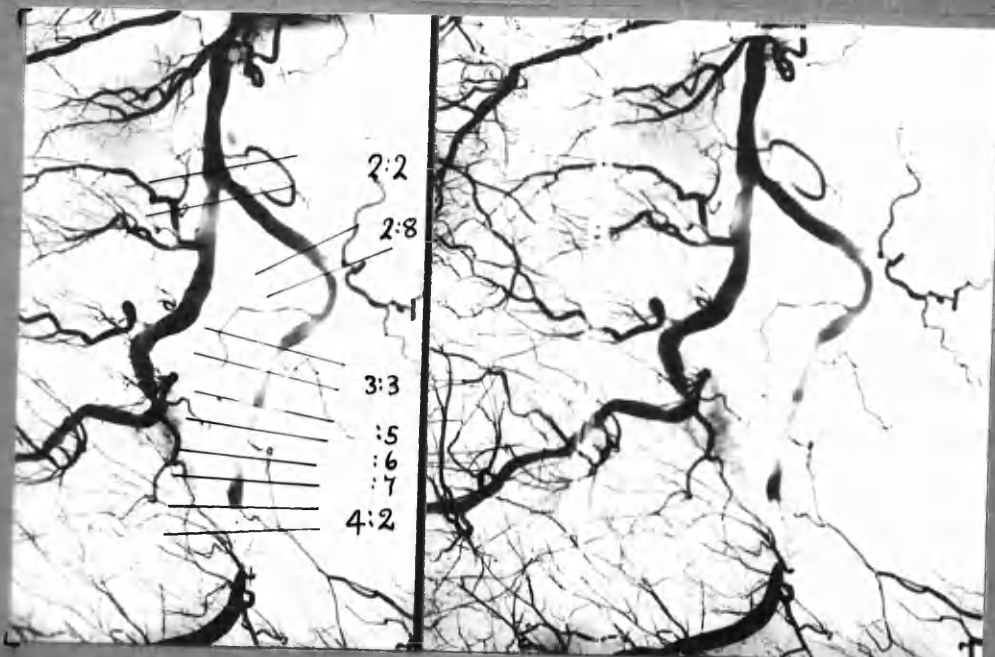
x1 1/2



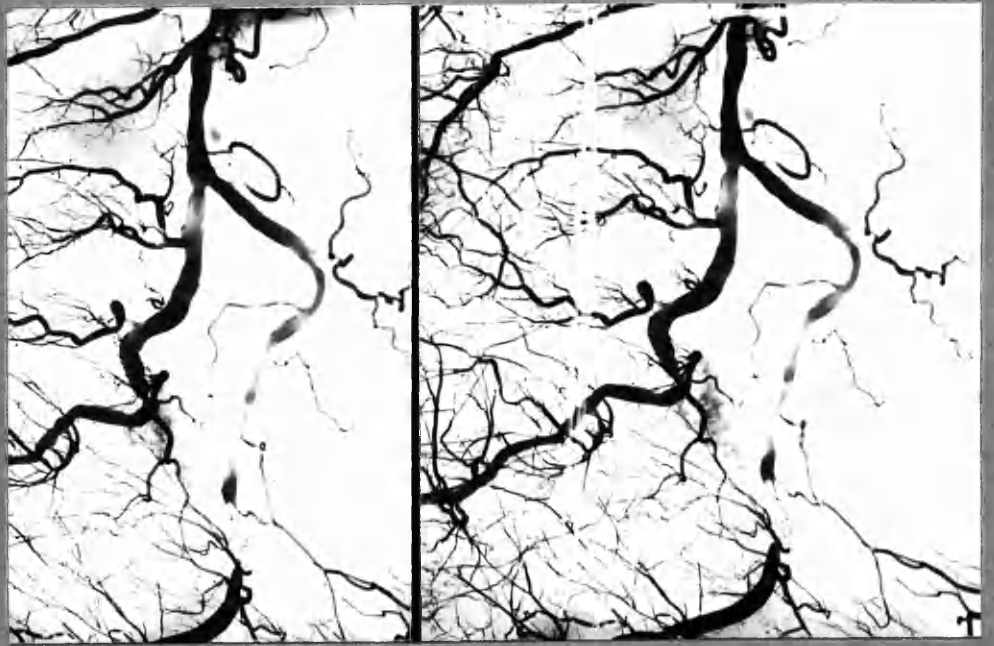
x7 1/2

3 Stereo-pairs of arterial sections viewed from the distal aspect:  
Swing through 90° anticlockwise for orientation with arteriograms.  
See also COLOUR TRANSPARENCIES, Chap. 8.

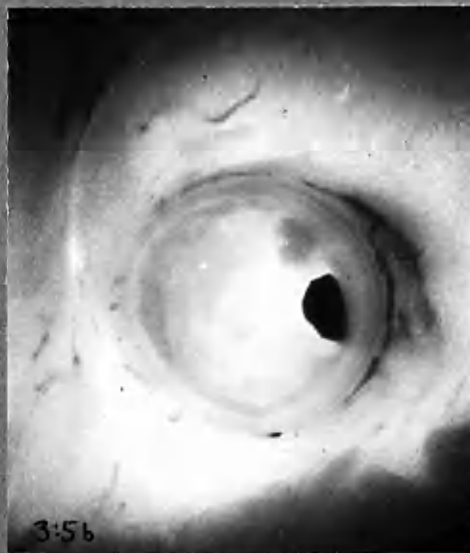




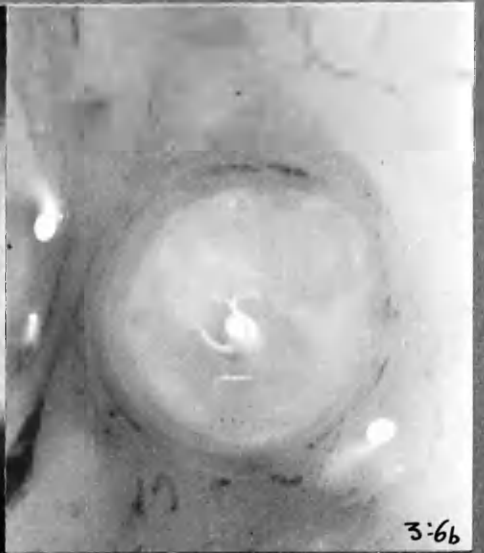x 13



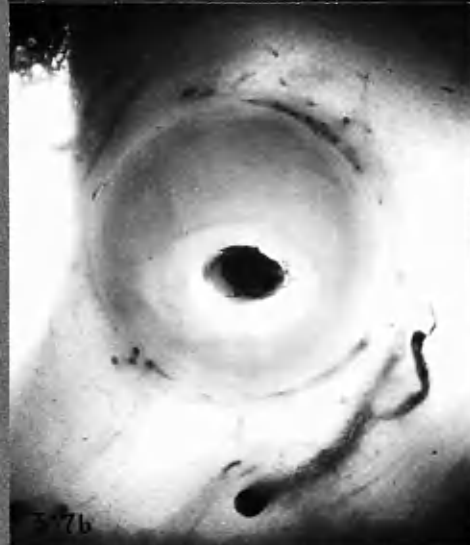
x 1 1/2



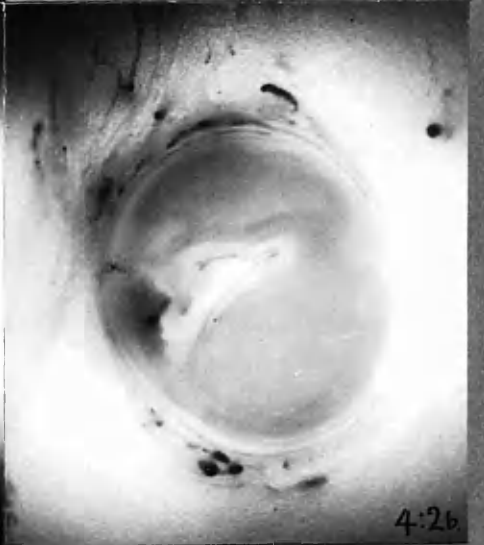
3:5b



3:6b



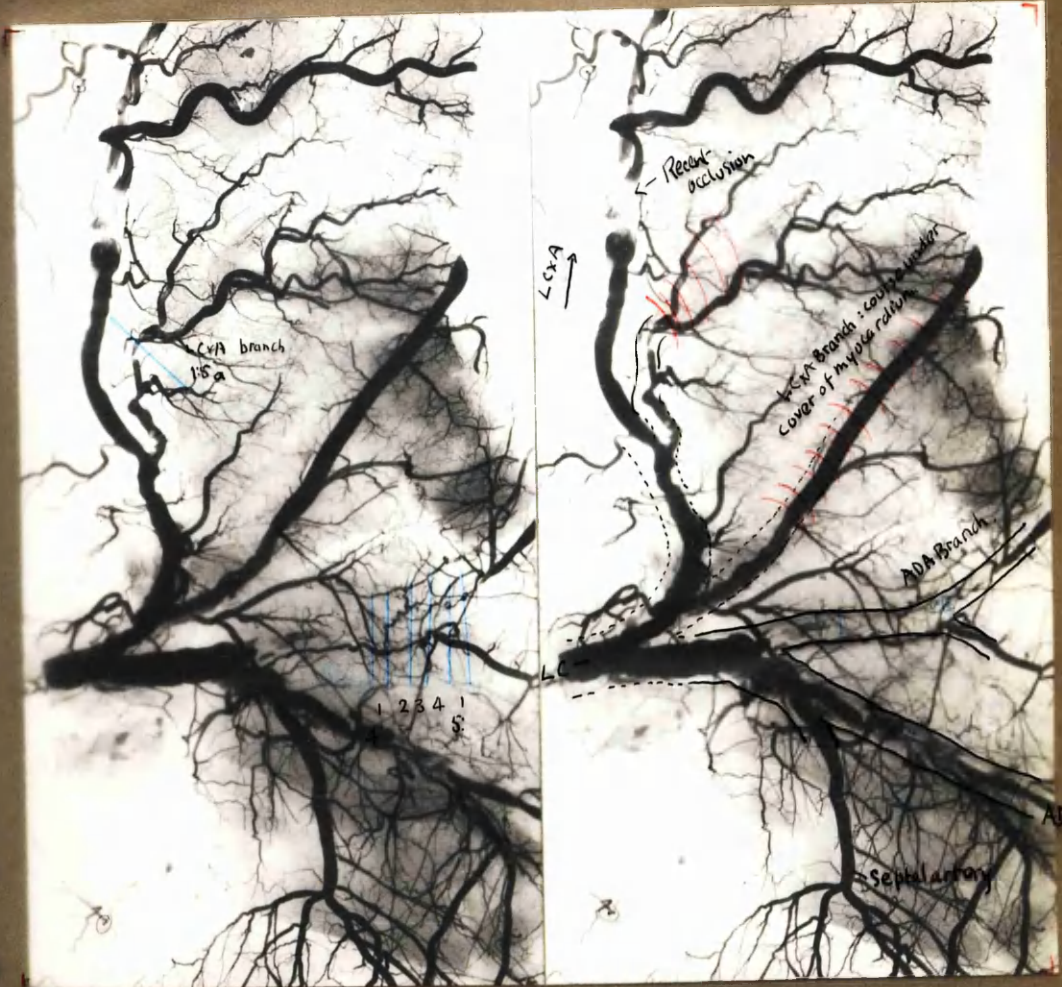
3:7b



4:2b

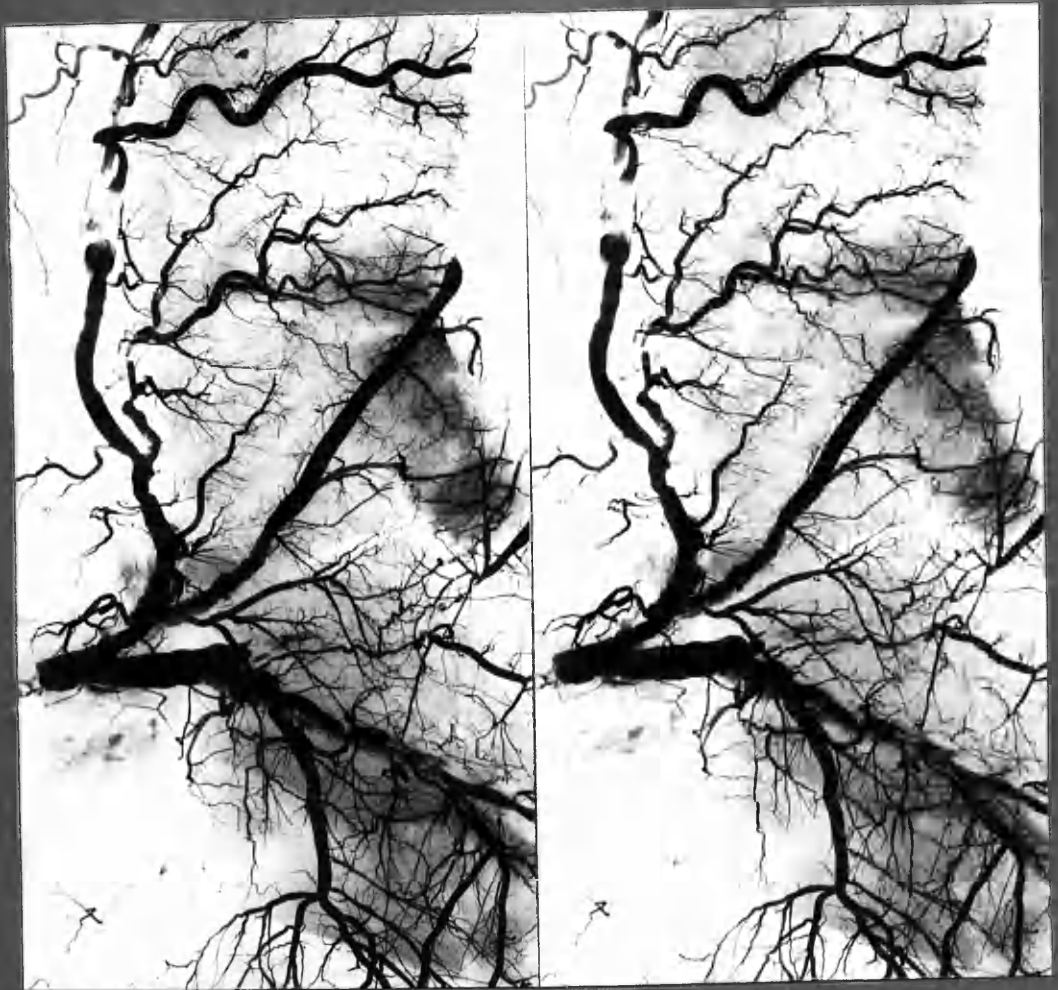
x 13





x 1 2/3

11 ADA  
+ LCx A



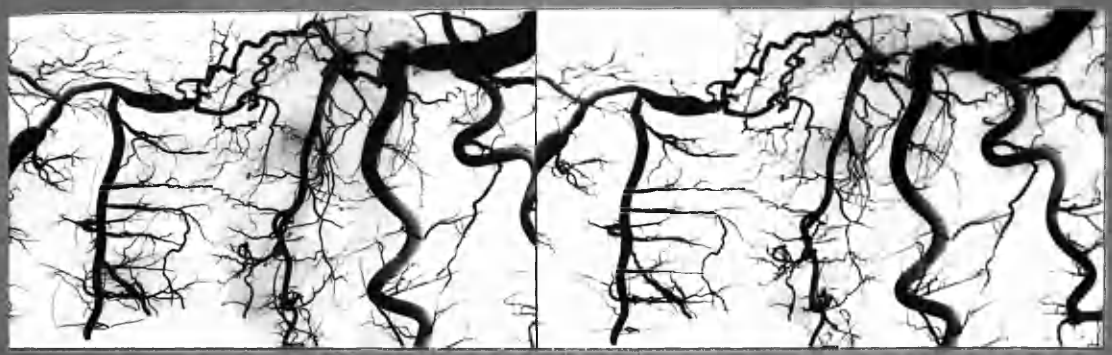x1

7 ADA



x1 3/5

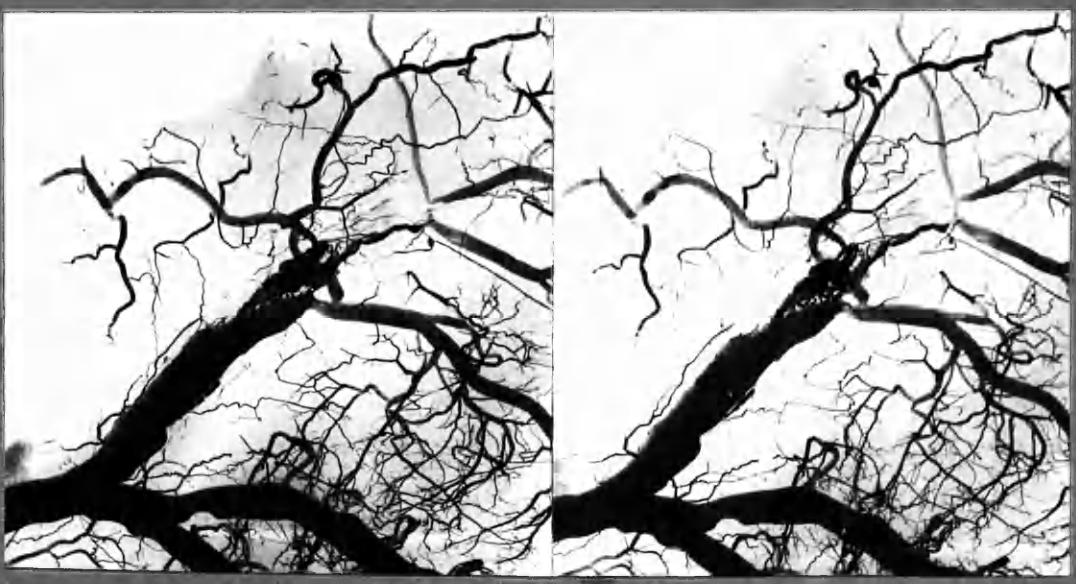



x1

7RC

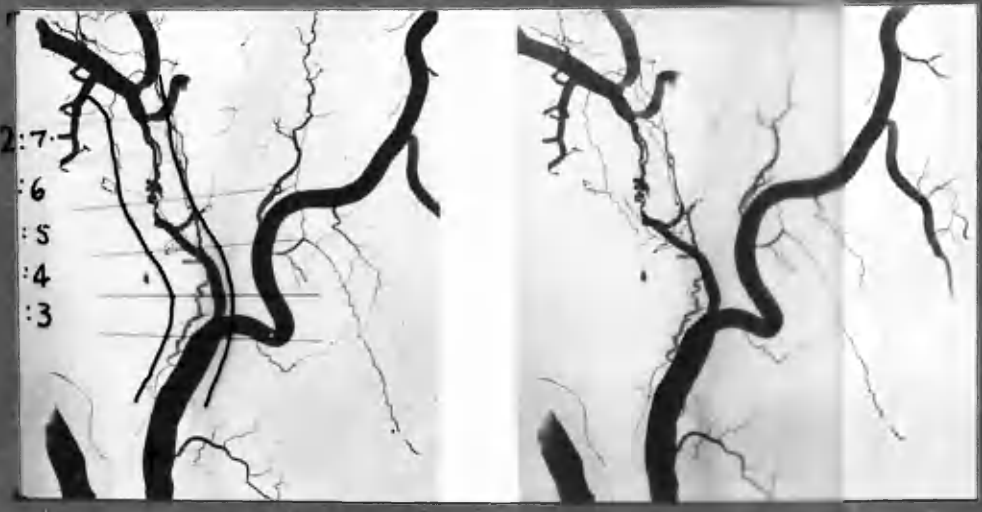contact.



x2

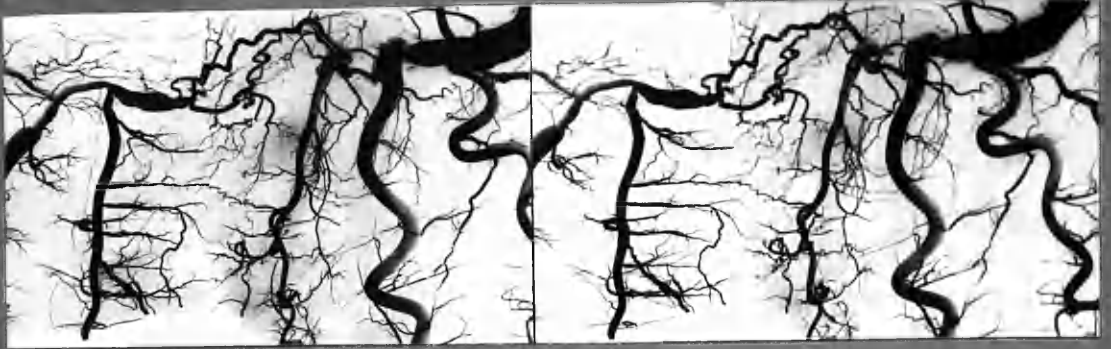5 LCxA

x2



x2

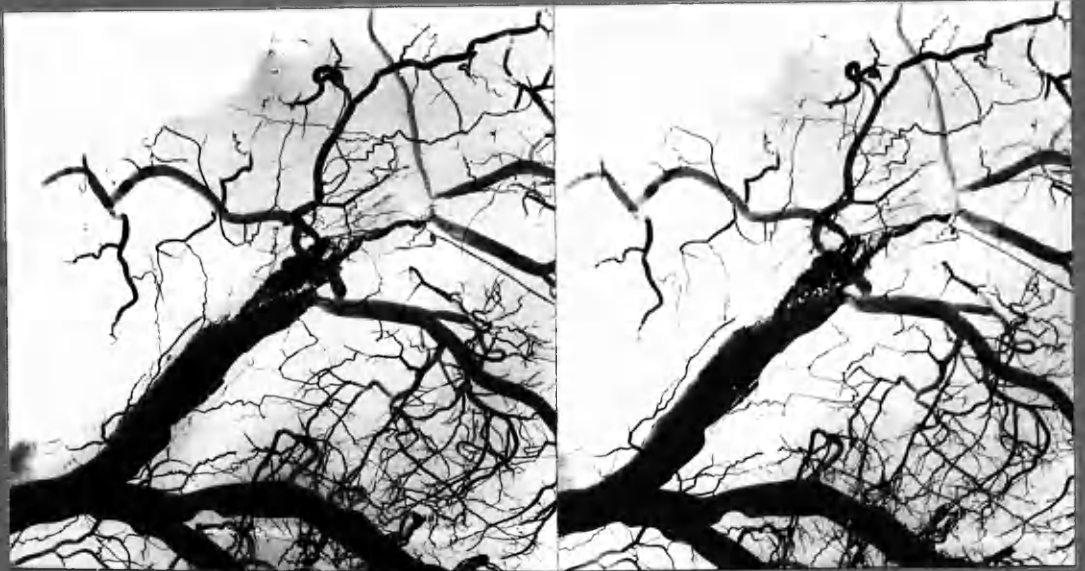25 LCxA



x1

7RC

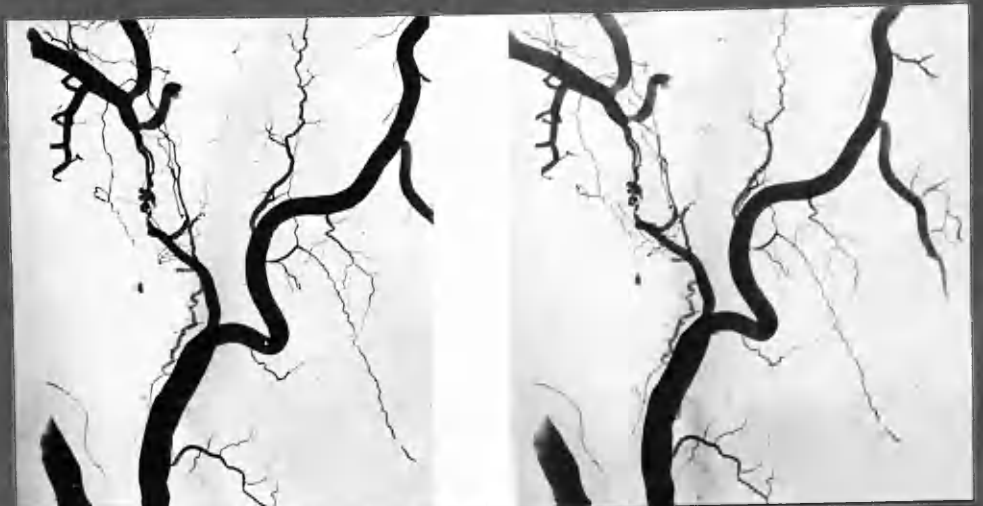contact.



x2

5 LCxA

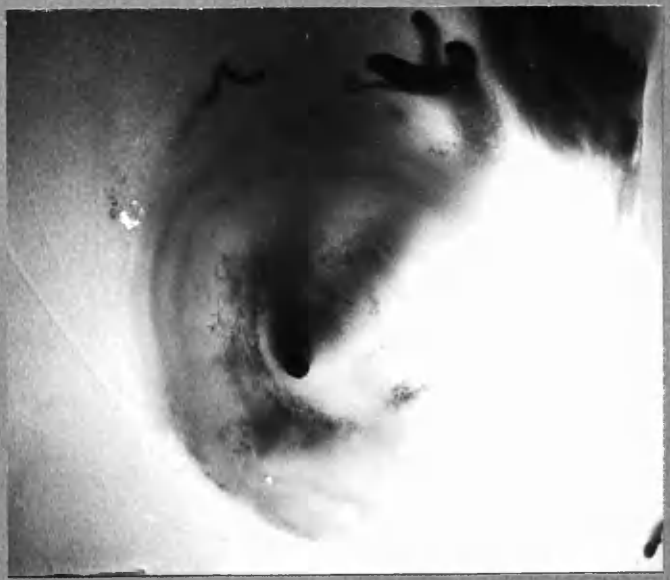x2



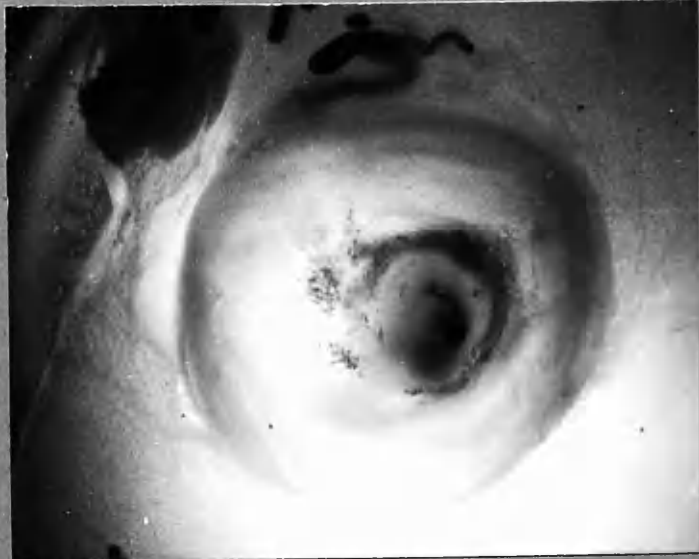
x2

25 LCxA

LCxA 2:5b

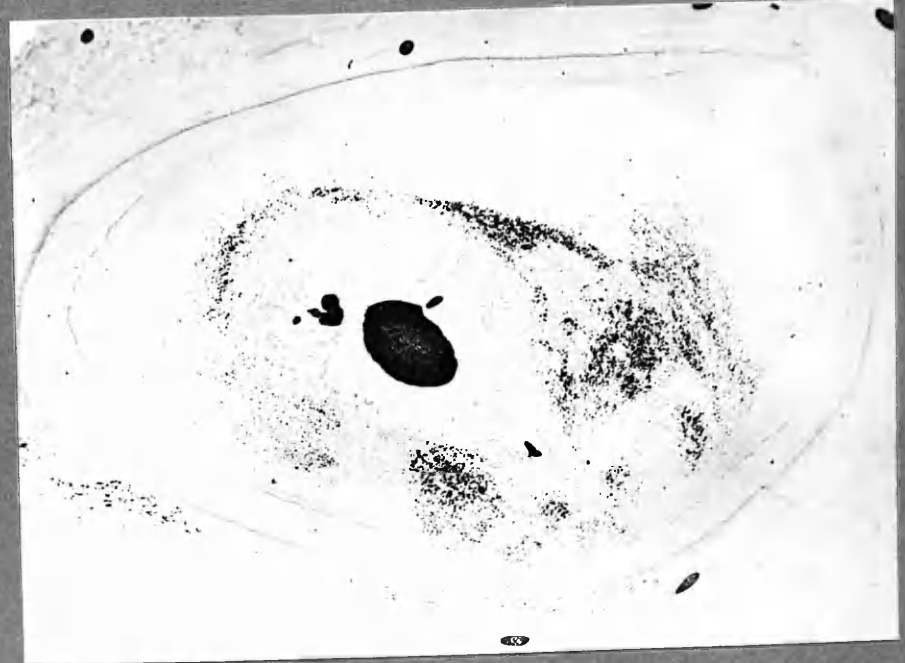


x18



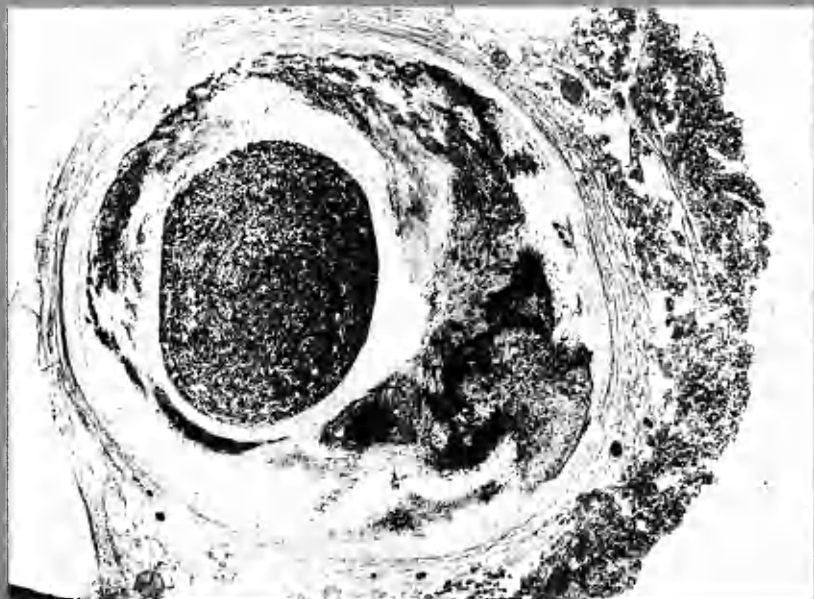
LCxA 2:6a

x18



x18

RC 4:3 micro. (PBR) Heavy iron deposit.



LC-ADA 1:9  $\phi$  (Frisen section)

x16



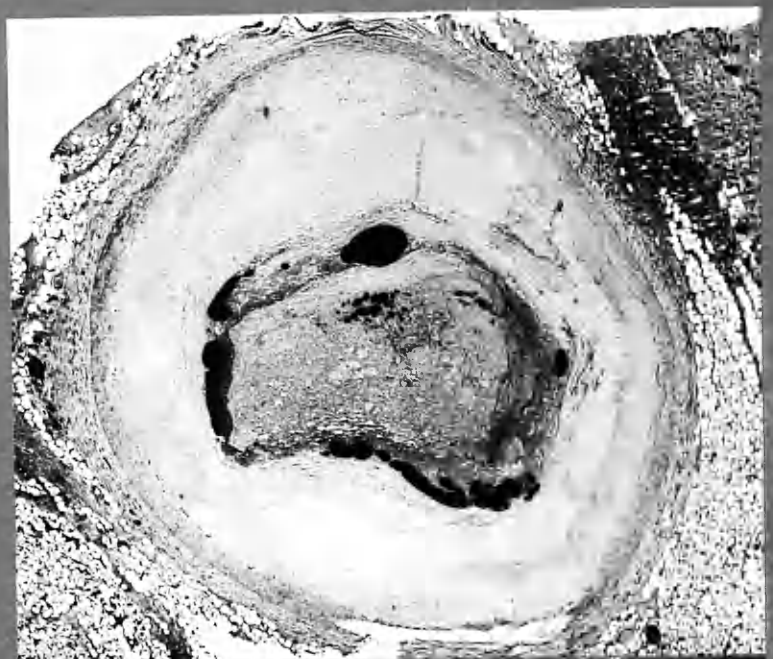
ADA 2:2  $\phi$ .

crescentic formations.

x11



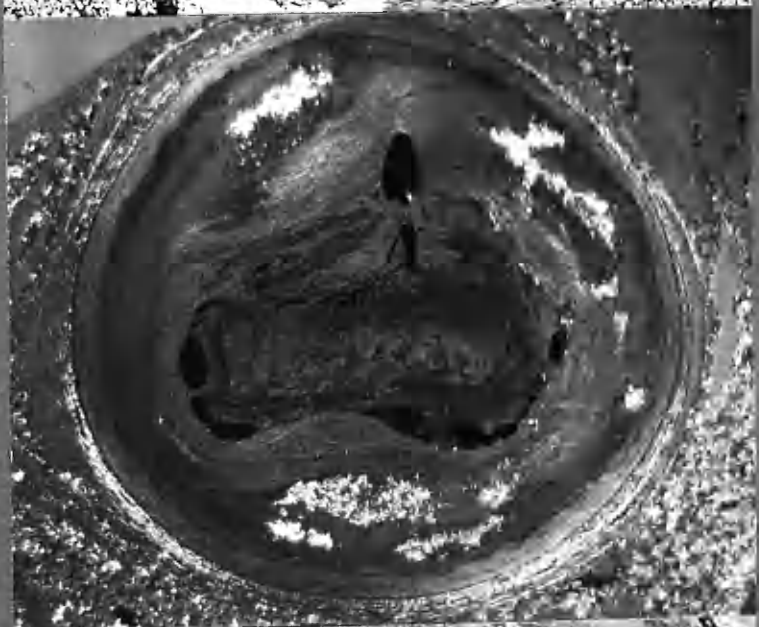
RC 2:6



H&E.

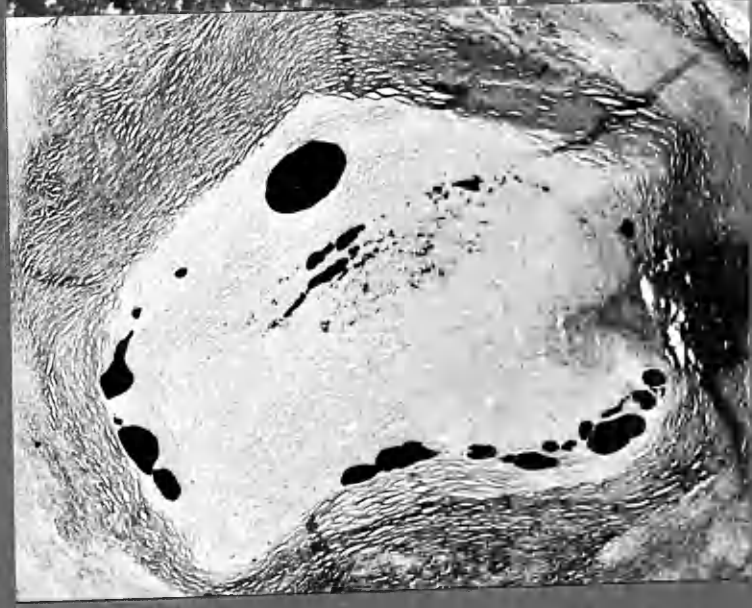x20

POLA.



x18

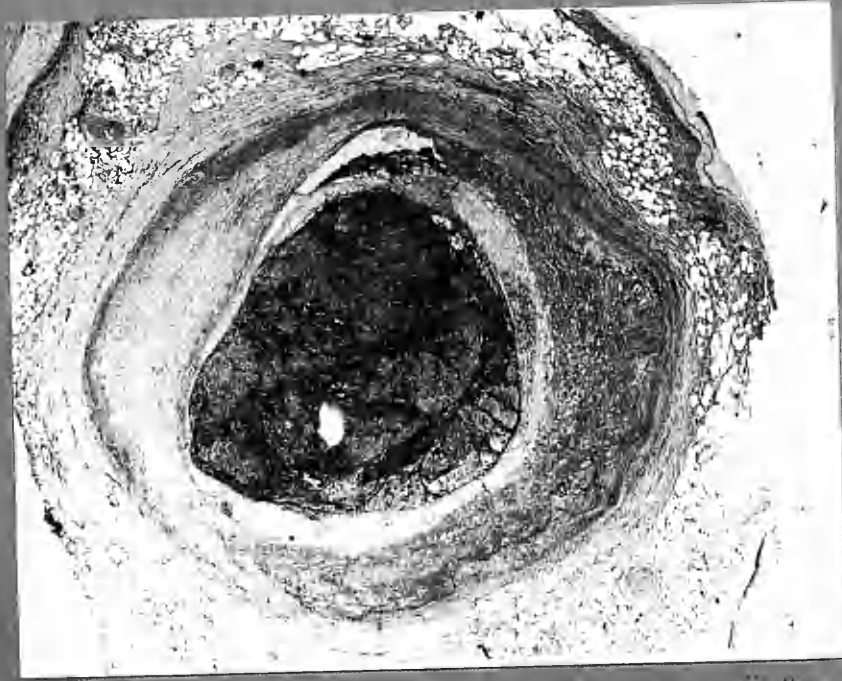V. van G.



x36

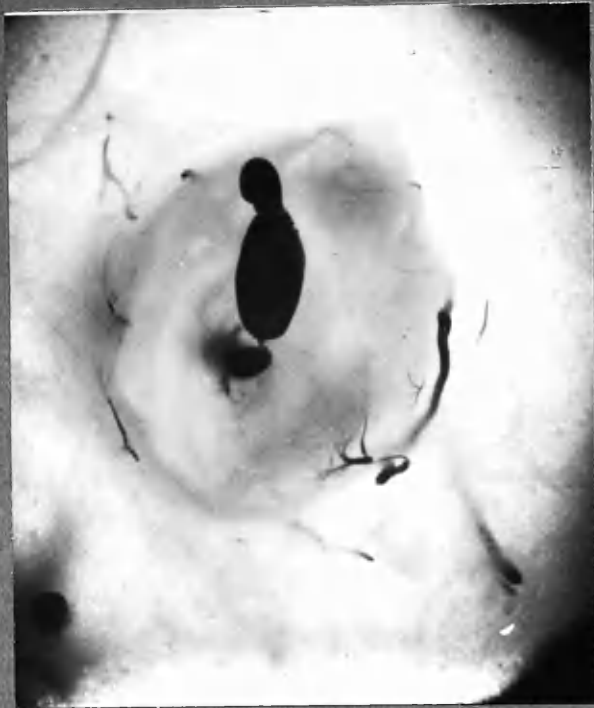
Central thrombus, 6 months, undergoing conversion into meta-sclerotic tissue. New channel characteristically placed between previous intima and more recent thrombus.

24



24 ADA 3:3 micro. (Picro-Hailey - Fibrin, "collagen")  
x18

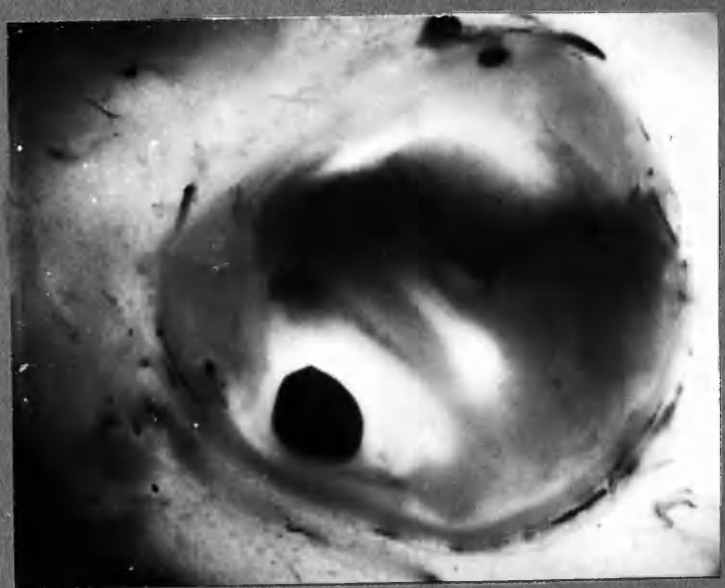
22



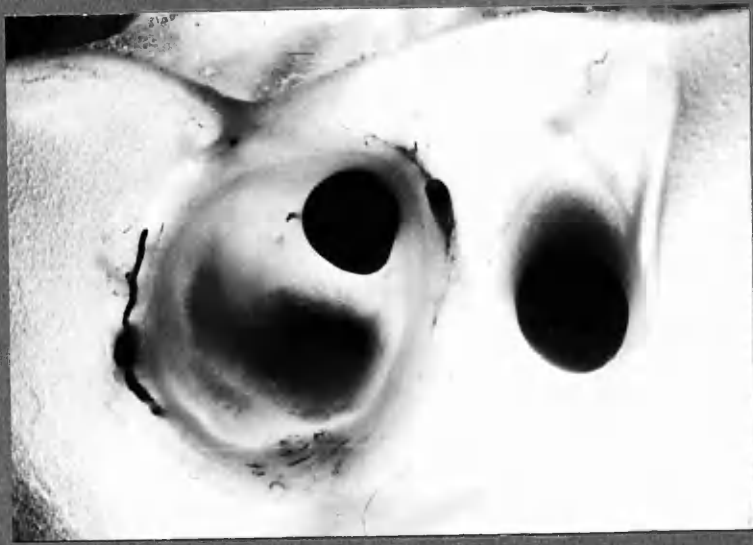22 ADA 4:6 b. x12



ADA 3:1a



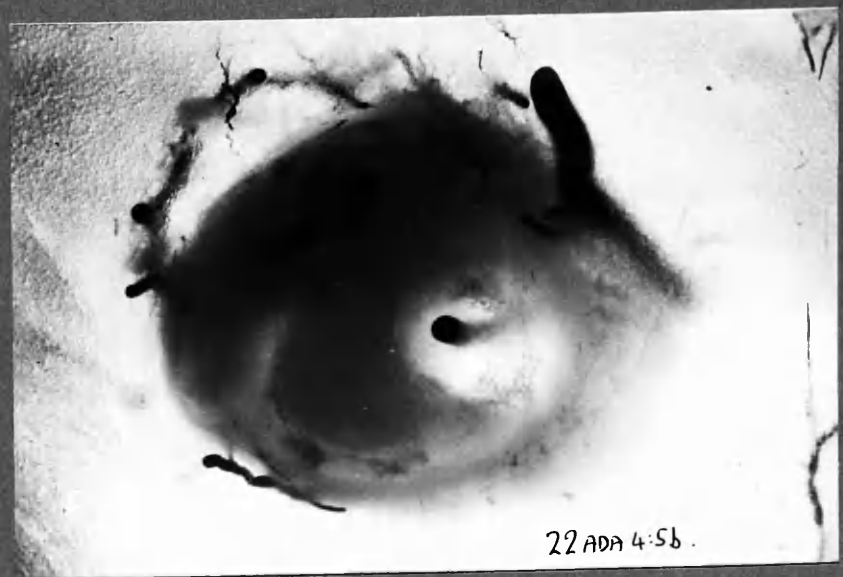
x 12



ADA, Brandy  
4:4 b.

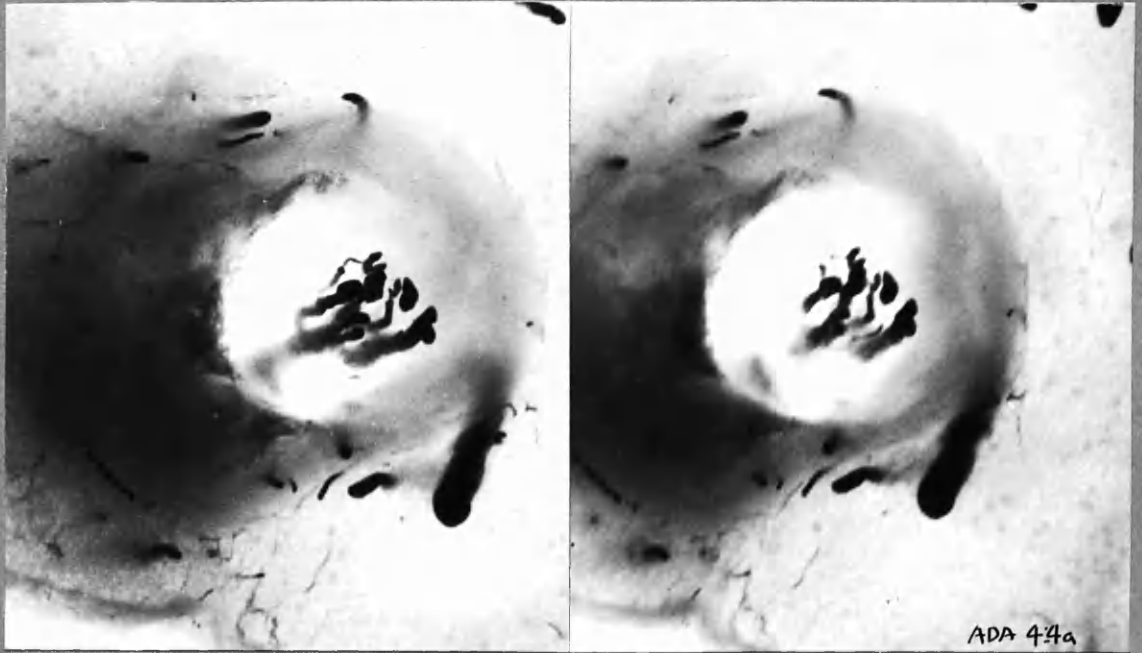
x 16

ADA  
4:5b



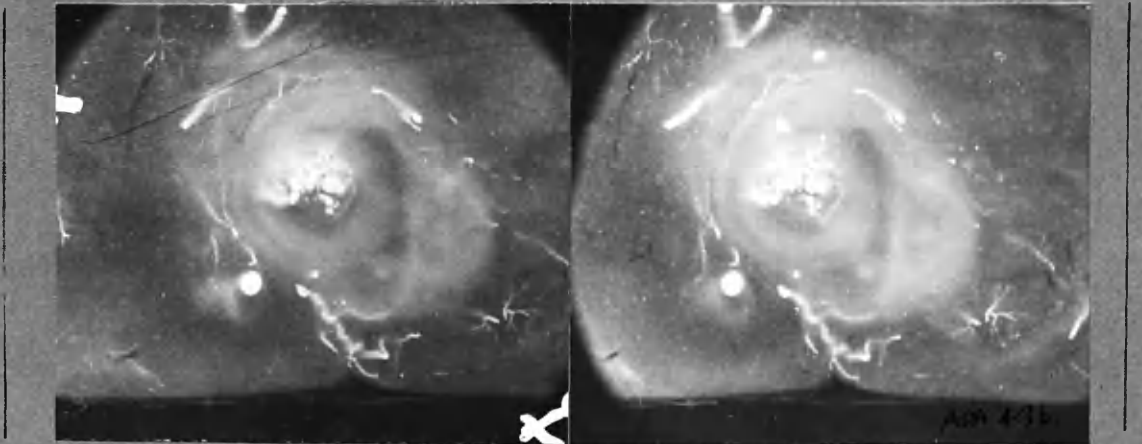
x 16

22 ADA 4:5b.



x 17


ADA 4:4a



x 10

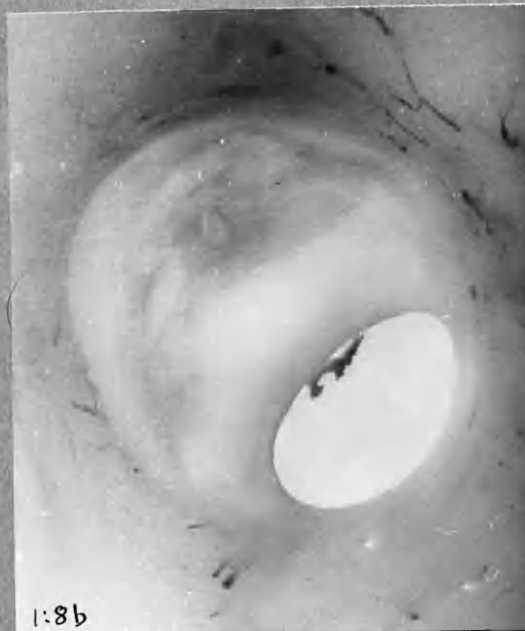
ADA 4:3b

ADA 4:4 a and 4:3 b. (photo. by transmitted and incident light).  
 Stereo-pairs of contiguous sections showing canalisation through centre  
 of core of translucent atherosclerotic tissue, evidently derived from thrombus,  
 about 2 yrs.

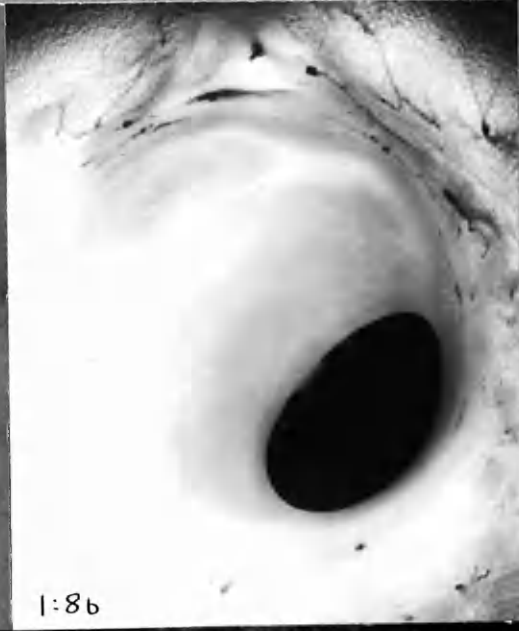

x 10

LCxA 2:5 a. Intimal vessel arising from adventitial artery - Does not  
 communicate with nearby injection mass in intima - which came  
 from lumen.



1:8b



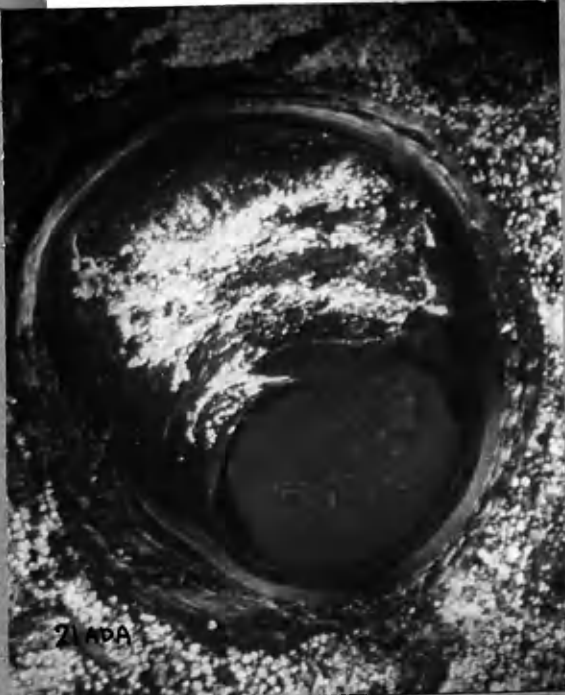1:8b

x15

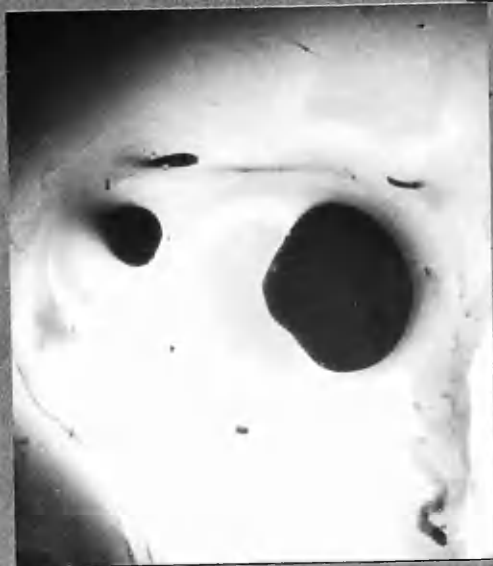1:8b

1:7  
POLA

(1:6b and others mounted  
in chapter 2.)



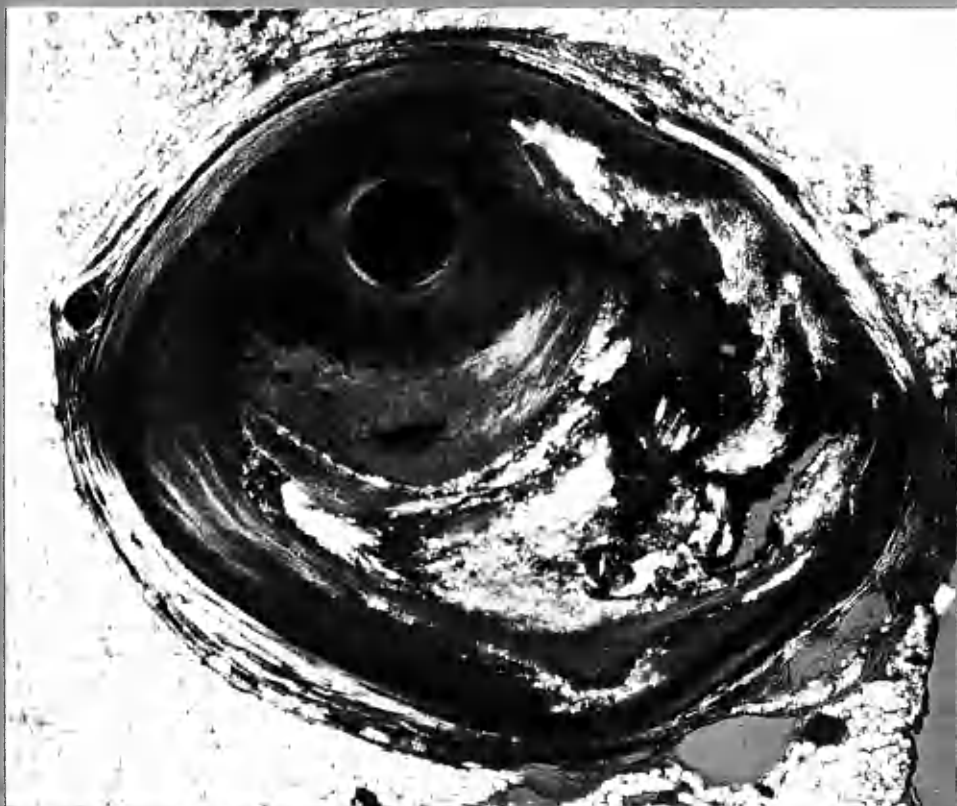2:ADA



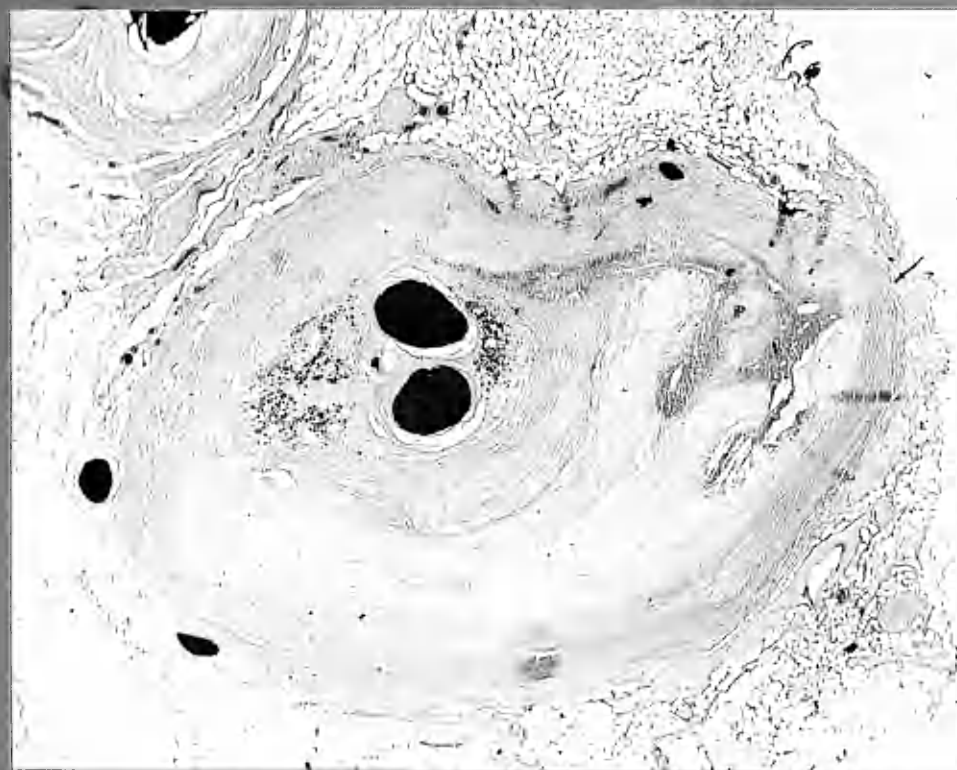
3:3a

x15

18: ADA

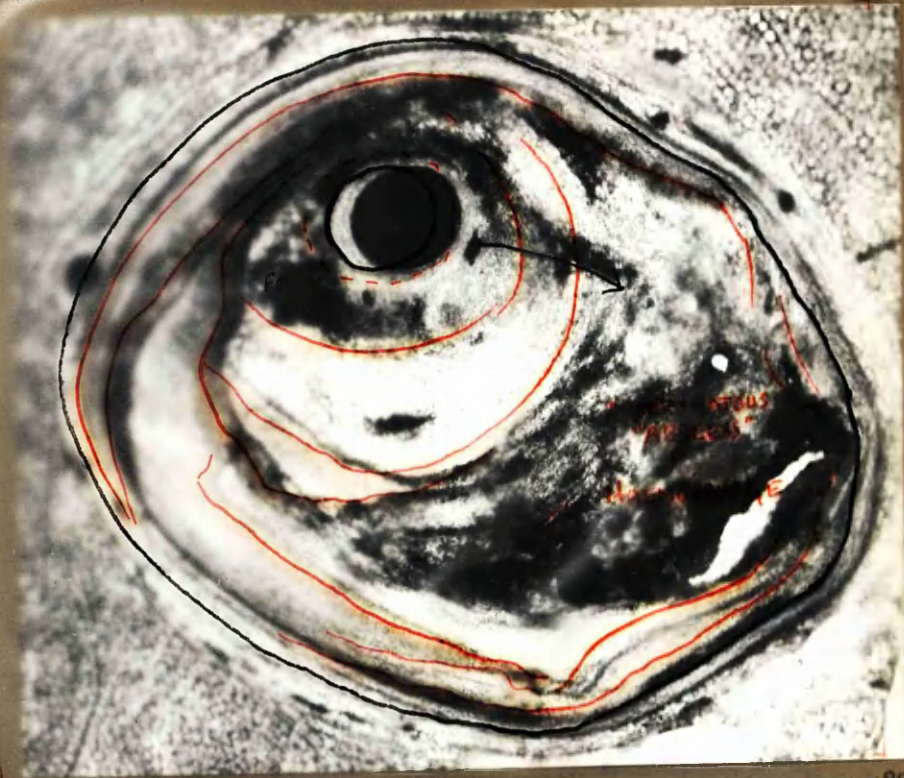


1:8 POLA cf. opposite x25



1:8 PBR Iron deposition near centre (cf H&E opposite) x25





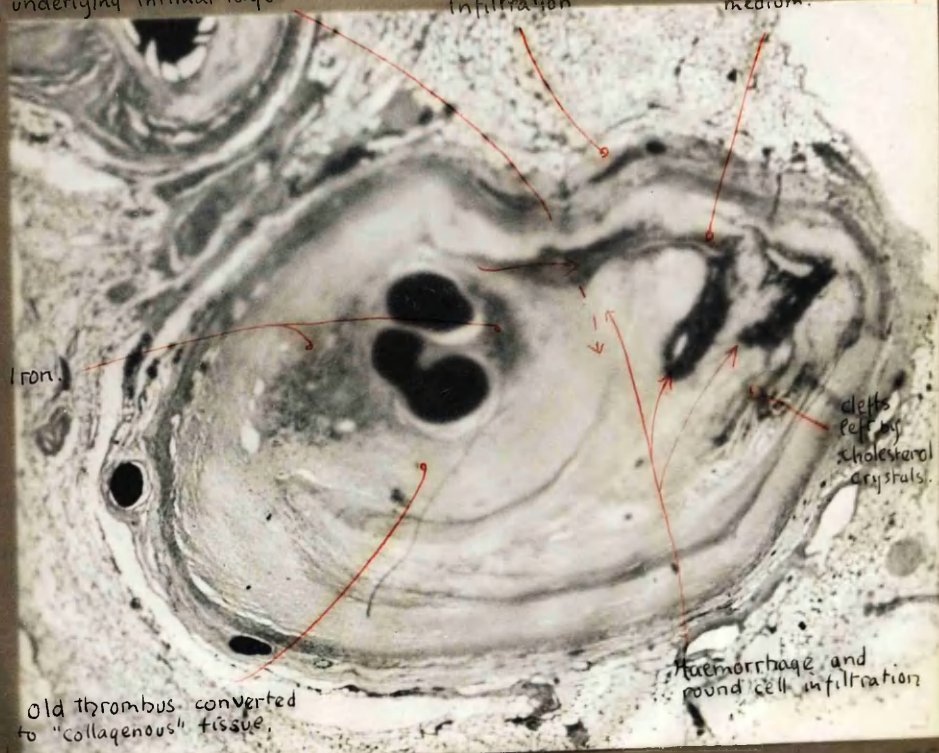1.8  $\phi$ . Crescent formation.

x25

weakness between old thrombus and underlying intimal layer

Adventitial round-cell infiltration

Small vessel carrying injection medium.



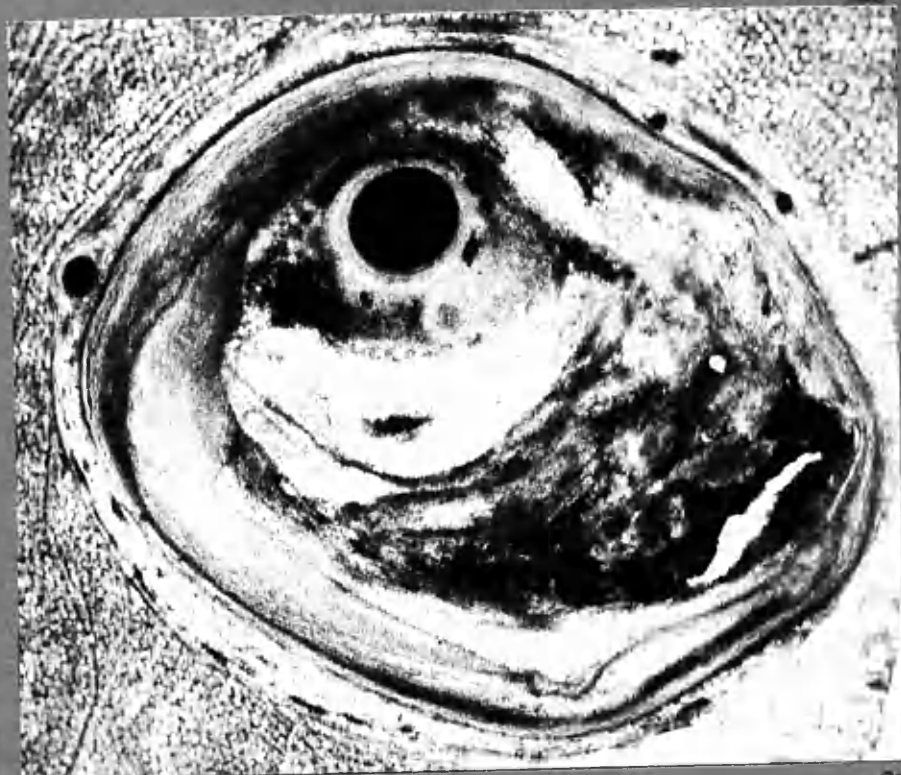
Old thrombus converted to "collagenous" tissue.

Haemorrhage and round cell infiltration

defts felt by cholesterol crystals.

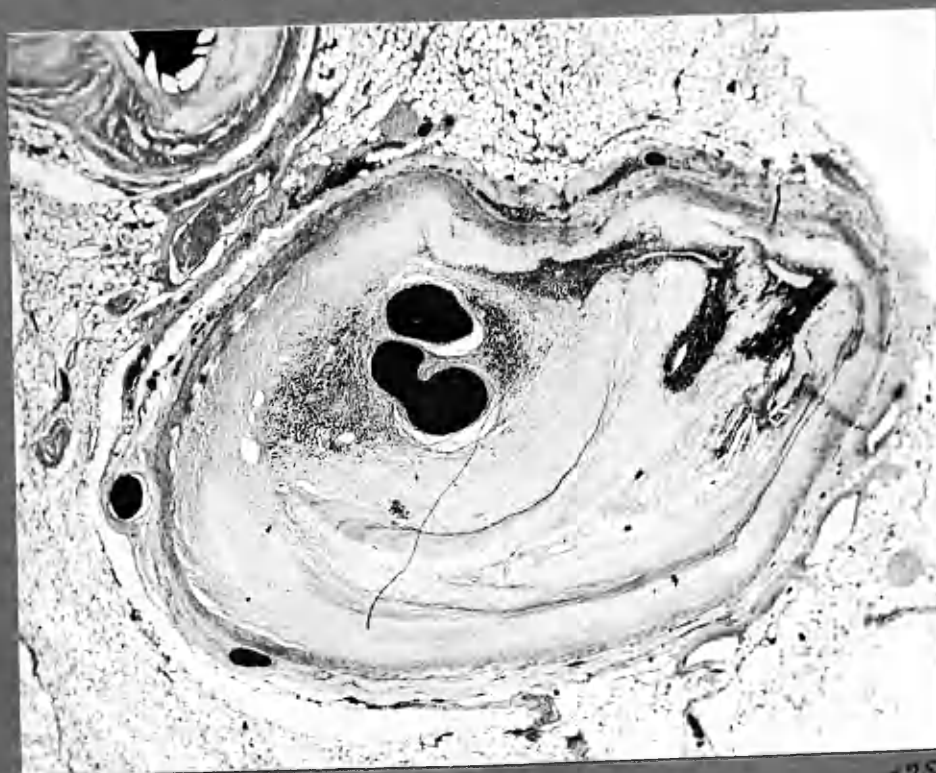
1.8 H+E  
cf. illustrations on opposite page.

LIFT.



1:8  $\phi$ . Crescent formation.

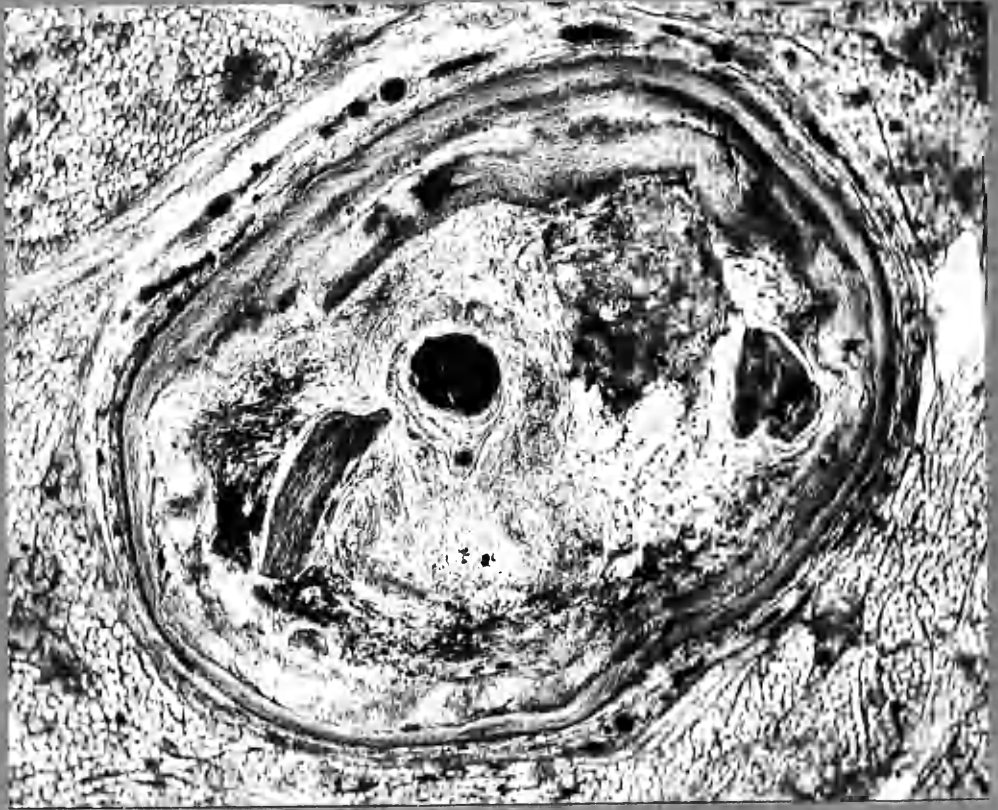
x25



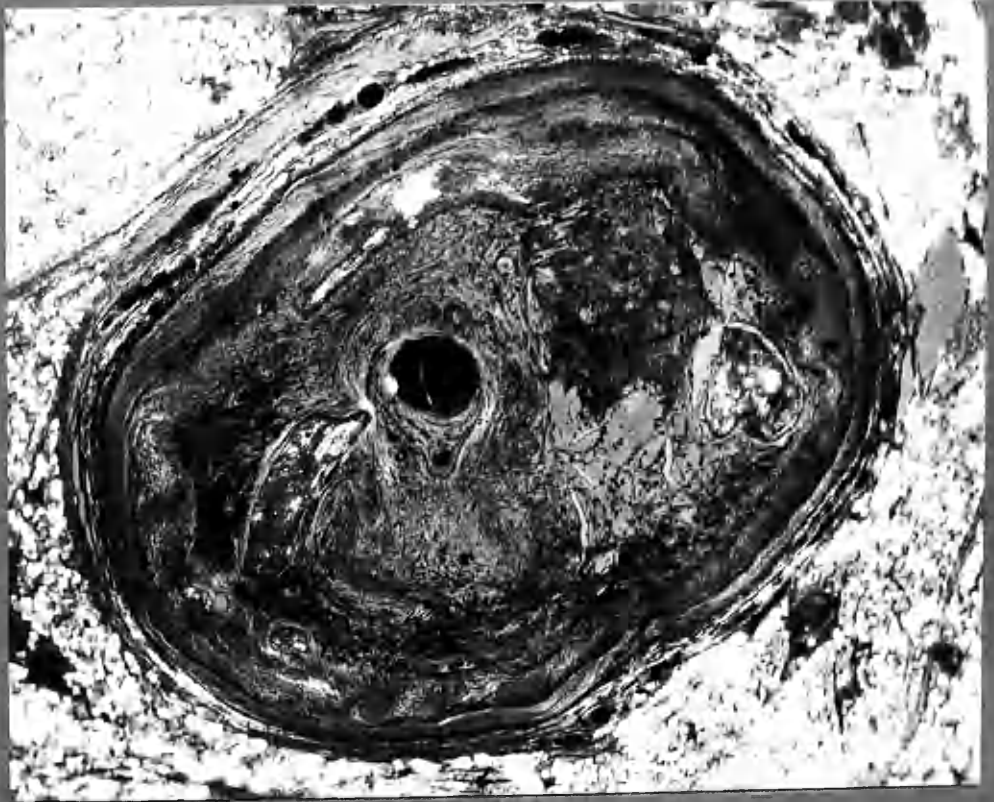1:8 H&E.

x25





φ

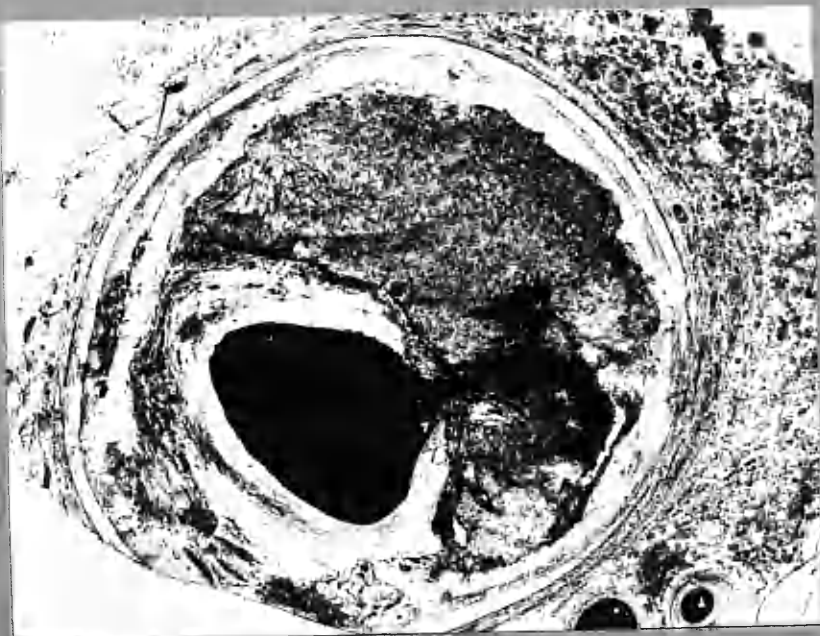


POLA.

ADA 2:3 mikro. φ & POLA.


x95

18 LCxA



φ

x 20



PoLA

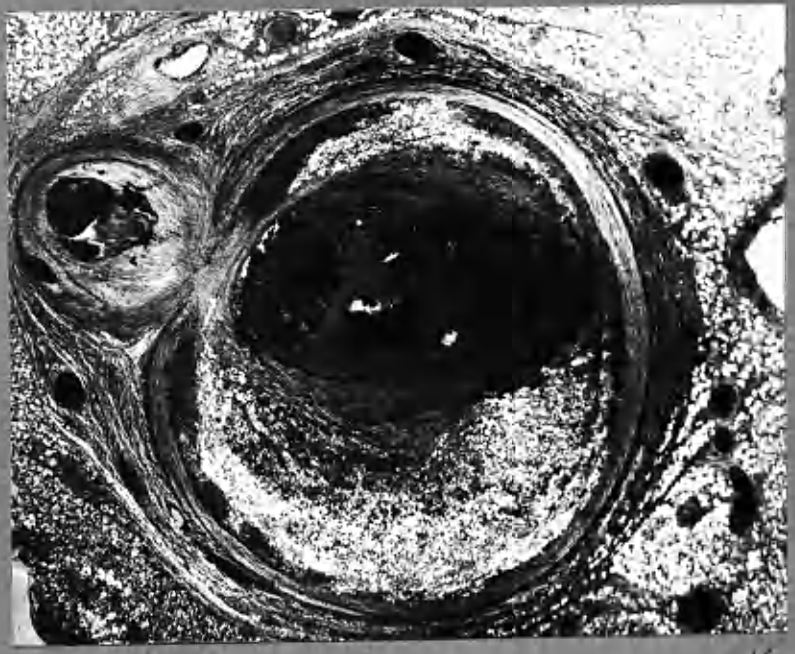x 20

LCxA 1:5 micro. φ & PoLA.

see also colour transparency.

Rupture of injection medium from lumen into atherosclerotic plaque post mortem has followed tracks of intimal haemorrhage in life.

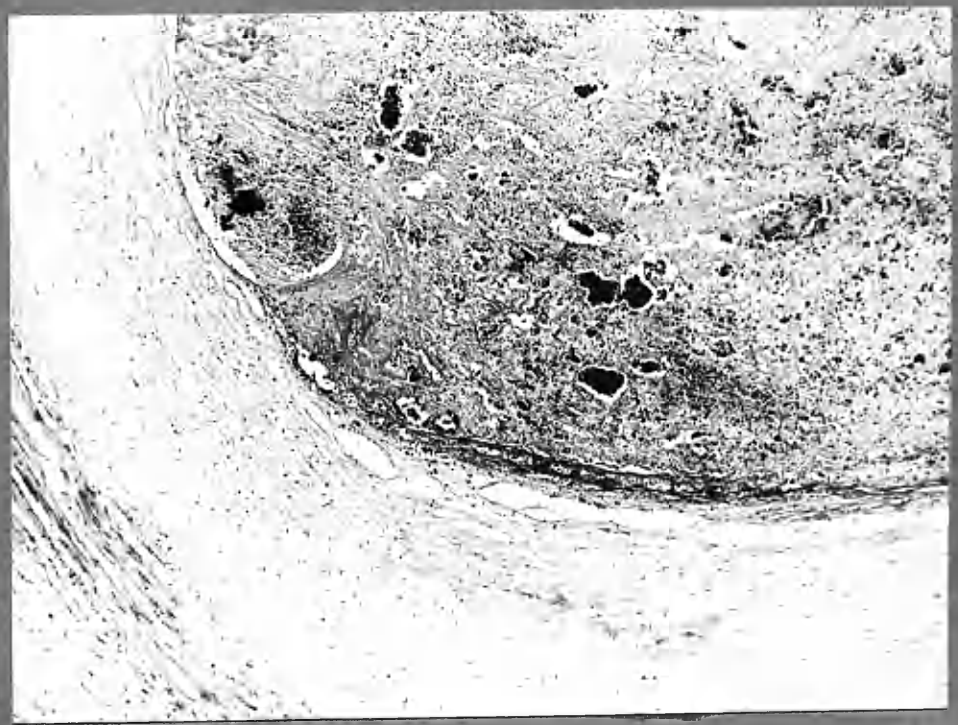



POLA

2:6

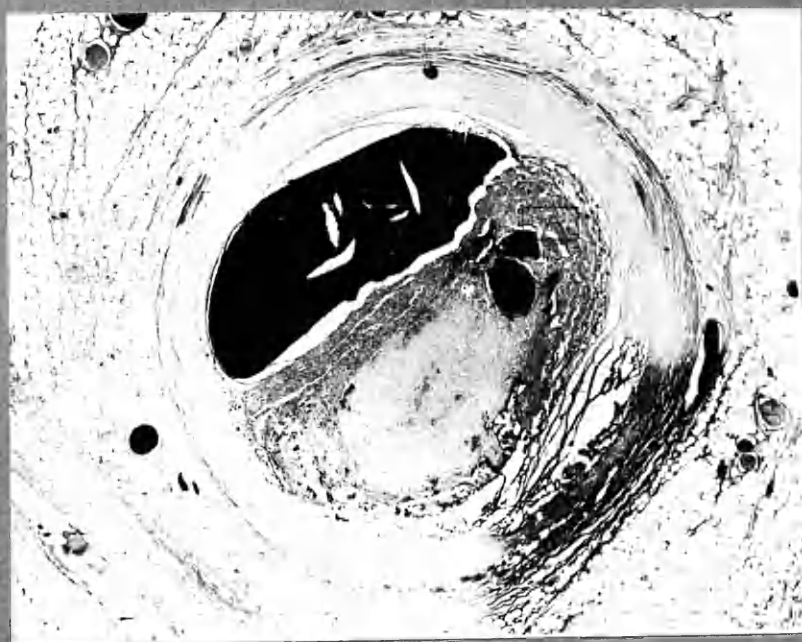x16



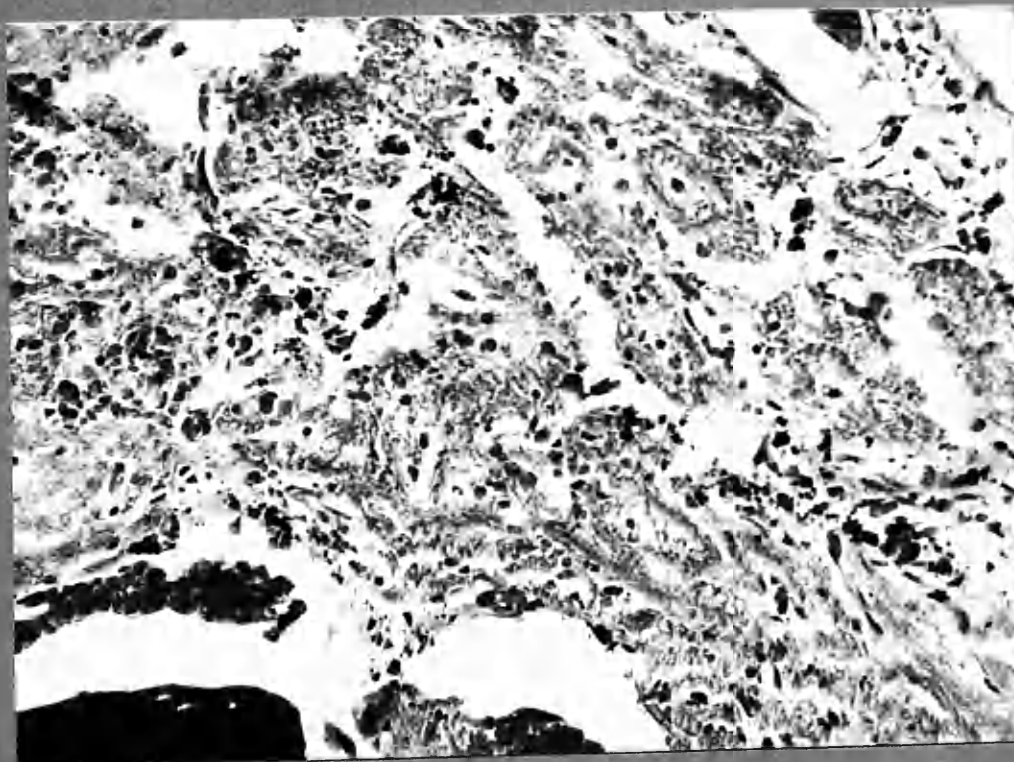
2:6 H+E

x90

H+E  
3:1



x20

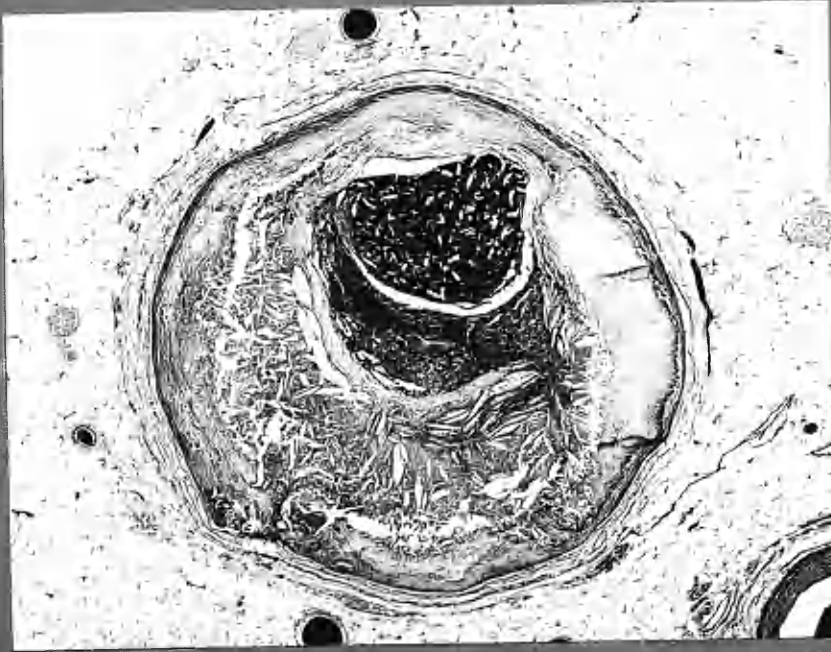


3-1 H+E

A

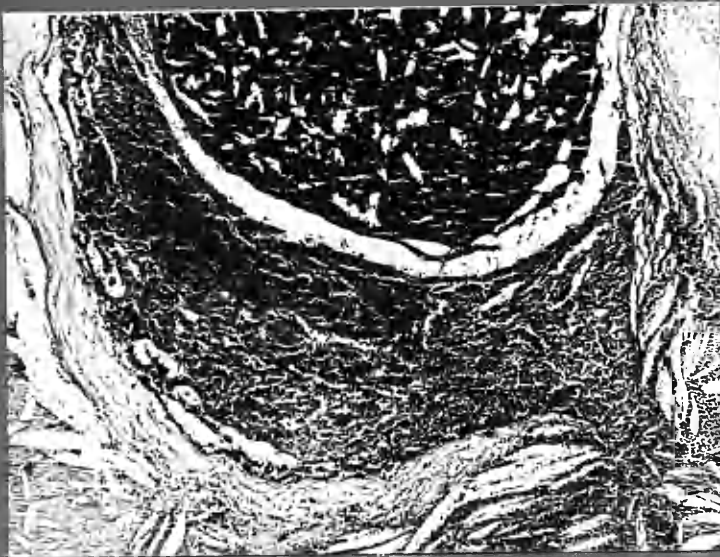x340

15  
ADA



3:2 H+E

x18



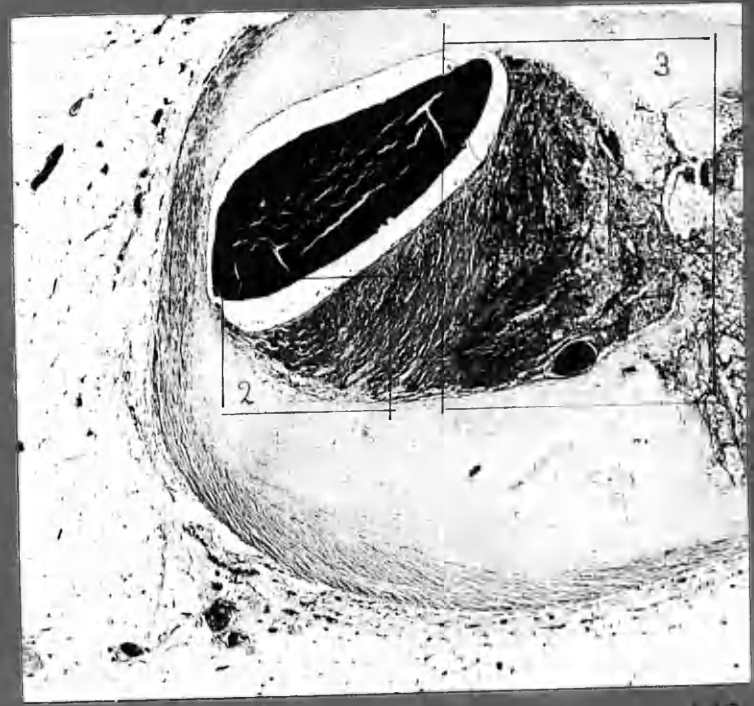
3:2 H+E

x36

Thrombus is seen overlying an atheromatous "abscess", (in which the clefts left by cholesterol crystals are well preserved). At one side there had apparently been break in continuity of the "roof" with entry of blood into the abscess locally. With thrombosis the fault was firmly sealed. ~~is~~ not "ulceration".

[Other illustrations closely related follows p. 8-12 and include 2mm. thick sections (stereo), ~~and~~ and pola.]

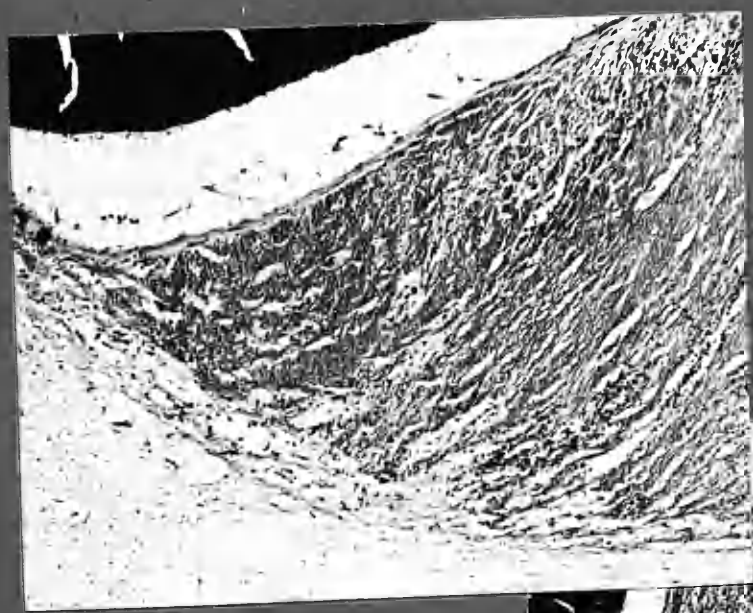
14  
ADA 2:1



①  
H+E

ADA  
2:1

x40

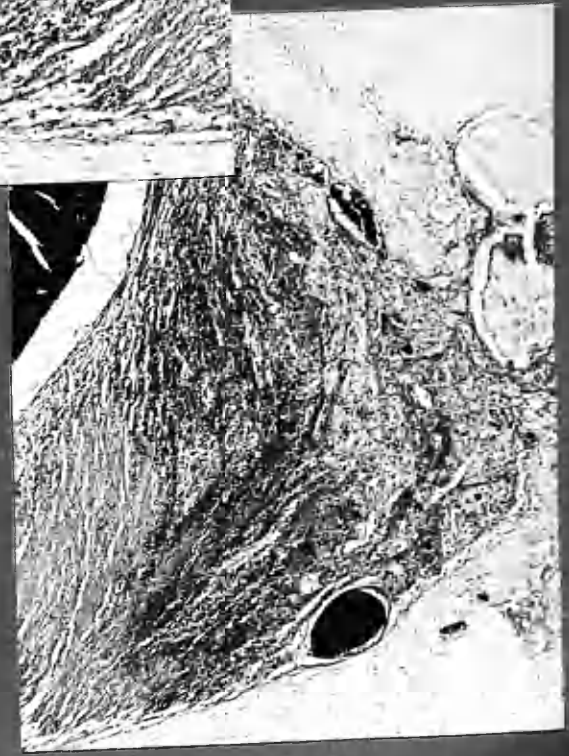


②  
H+E

x40

Endothelial covering to thrombus.  
? 19 days.

Interface changes:  
Fibrin-collagen conversion.  
Fibrinoid, evidently derived  
from fibrin. (F)

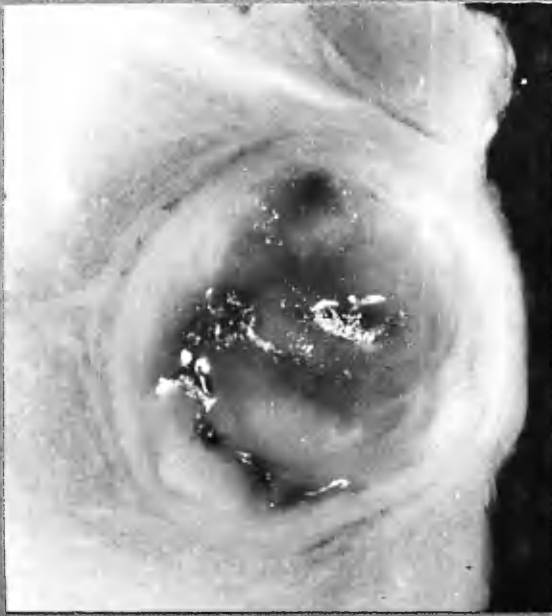


x40




14  
ADA

2:3b



x 12

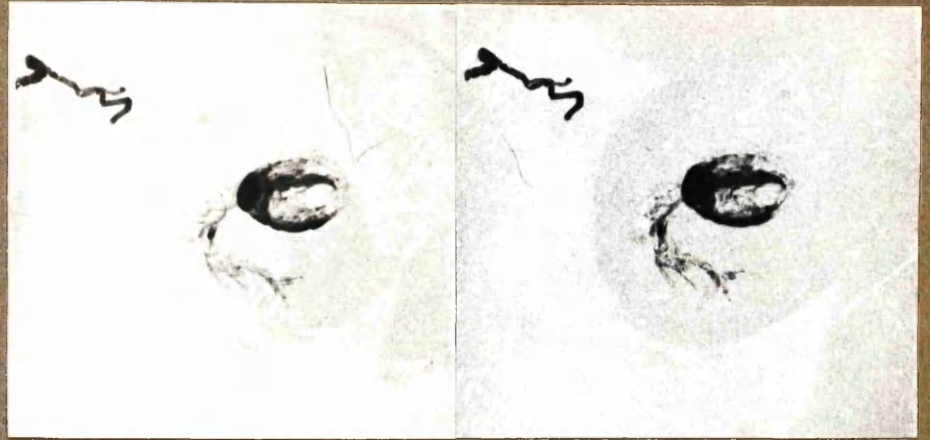≡ 2:4 micro, opposite. ↘



x 24


② 2:4 POLA.





x9

14 ADA 2:4 Stereogram. Radiography of the 2mm. thick block was undertaken before microsections were prepared from it. Process film was used but coarseness of grain has nevertheless impaired detail, when enlarged to this extent. However, the manner in which the curved, frond-like leash of intimal vessels is arranged between layers is clearly seen and should be correlated with photomicrographs 2:4  $\phi$  and POLA, and with 2:3b opposite. The formation of blood spaces in recent thrombus is also demonstrated by the injection medium - and between thrombus and intimal wall. (see photomicrographs 2:4 1-B.)



Recent Thrombus + Injection mass.

Early fibrous tissue, ? derived from fibrin

Medial coat.

Crescent

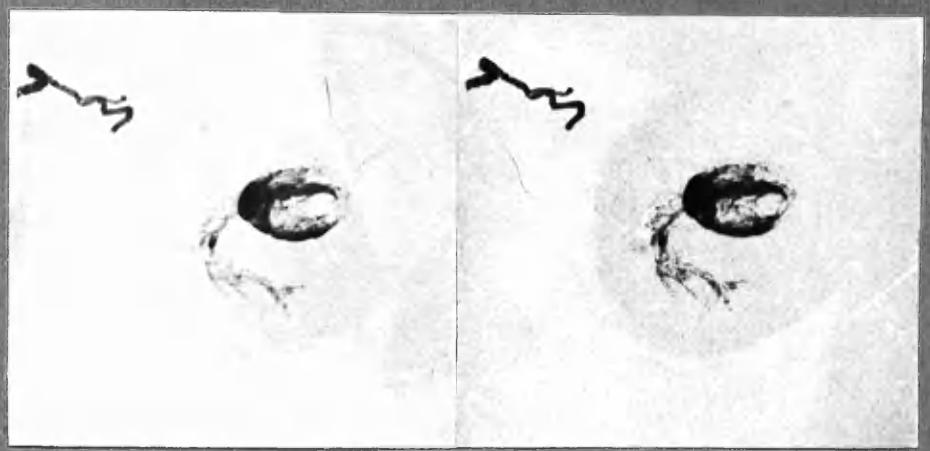
Leash of intimal vessels + haemorrhage, between layers.  
cf. stereogram of the same block, above.

① 2:4  $\phi$

LIFT.

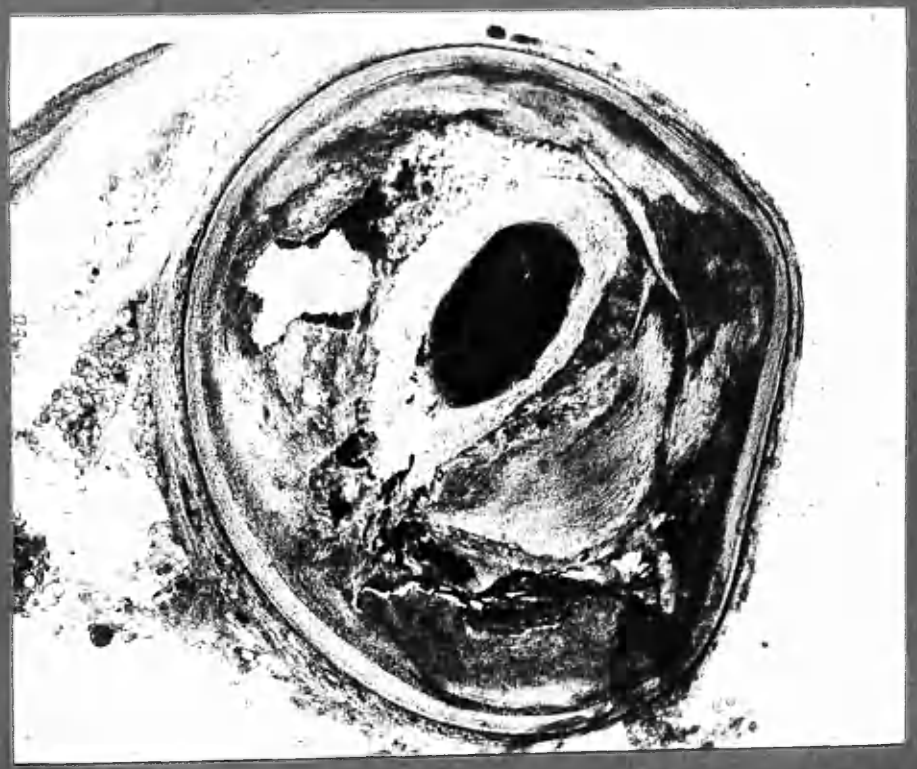
XI

14  
ADA  
2:4



X9

14 ADA 2:4 Stereogram. Radiography of the 2 mm. thick block was undertaken before microsections were prepared from it. Process film was used but coarseness of grain has nevertheless impaired detail, when enlarged to this extent. However, the manner in which the curved, frond-like leaflets of intimal vessels is arranged between layers is clearly seen and should be correlated with photomicrographs 2:4  $\phi$  and POLA, and with 2:3b opposite. The formation of blood spaces in recent thrombus is also demonstrated by the injection medium— and between thrombus and intimal wall. (see photomicrographs 2:4 1-8.)

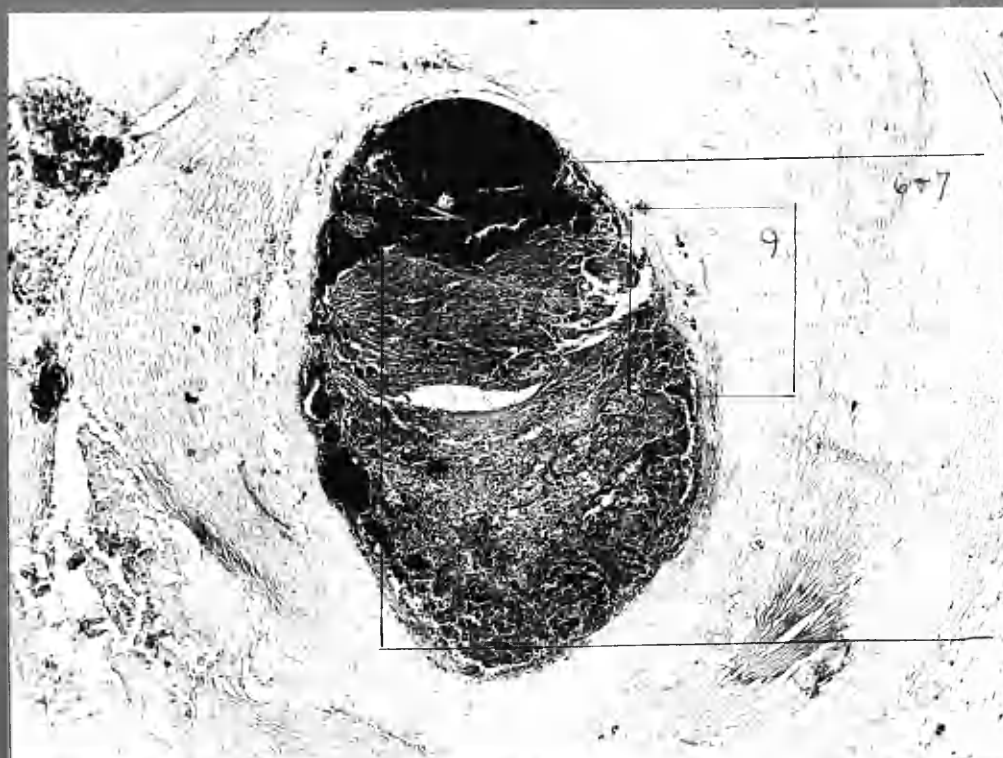


① 2.4  $\phi$

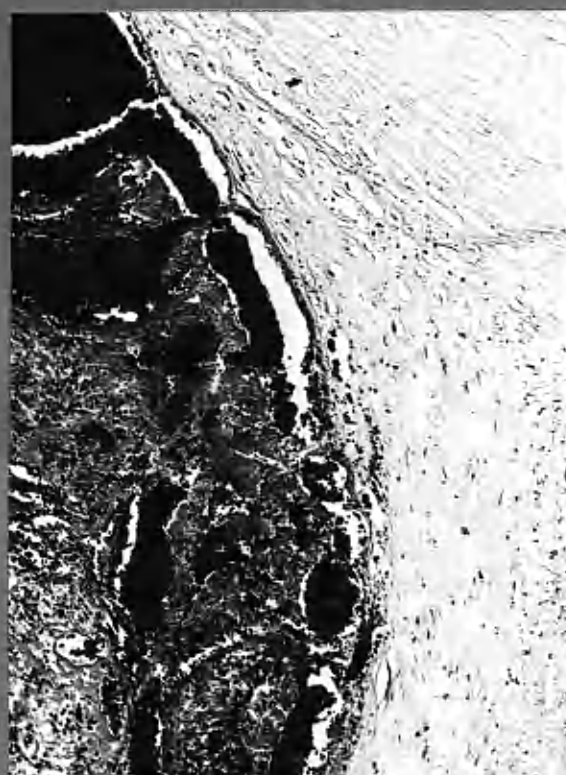x 24



14 ADA



③ 214 micro. Weigert's Fibrin stain x50



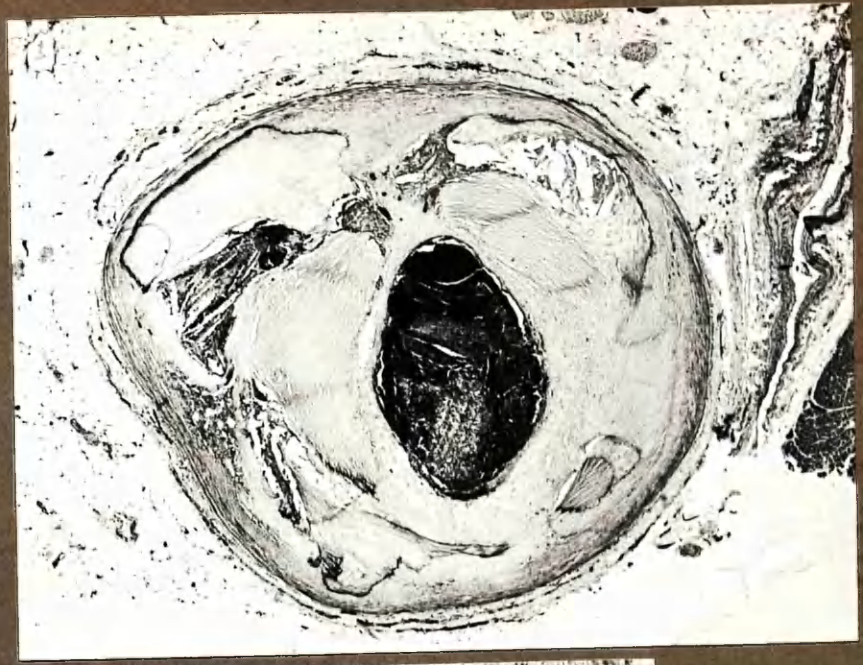
④ 214 micro. H&E. x105



⑤

2:4

H+E



x24



⑥

H+E

2:4


x64

⑦

2:4

Acid Picro-Mallory

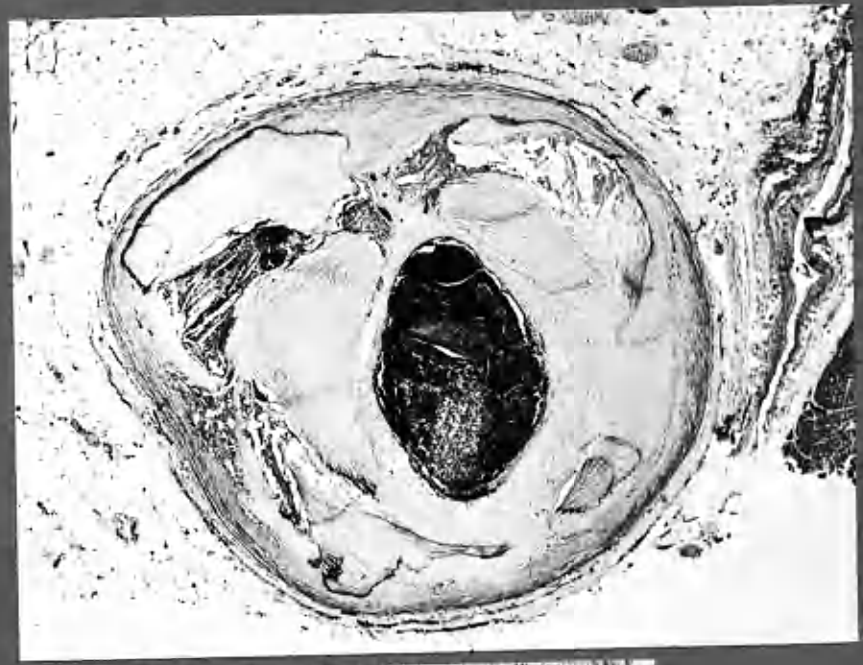
- A. Fibrous network, recent thrombus.
- B. Intermediate zone, in which red and blue staining of fibres merge.
- C. Established fibrous tissue staining as for collagen.



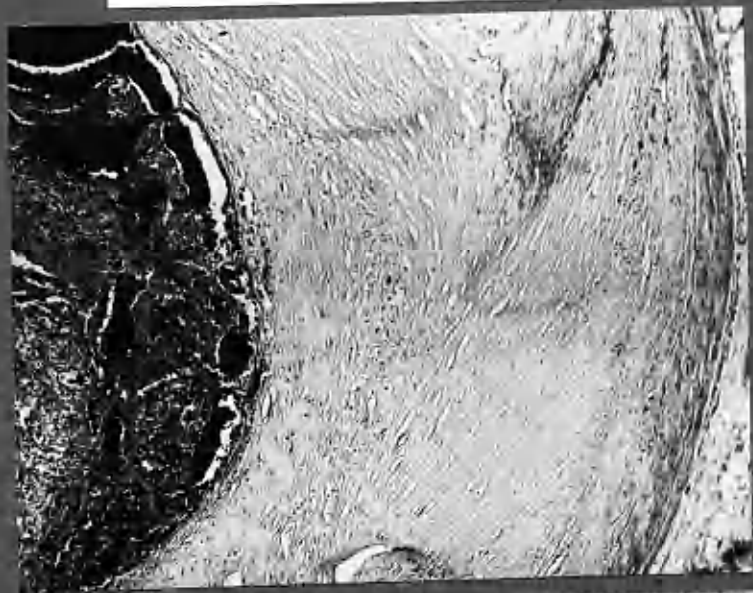(5)

2:4

H+E



X14



(6)

H+E

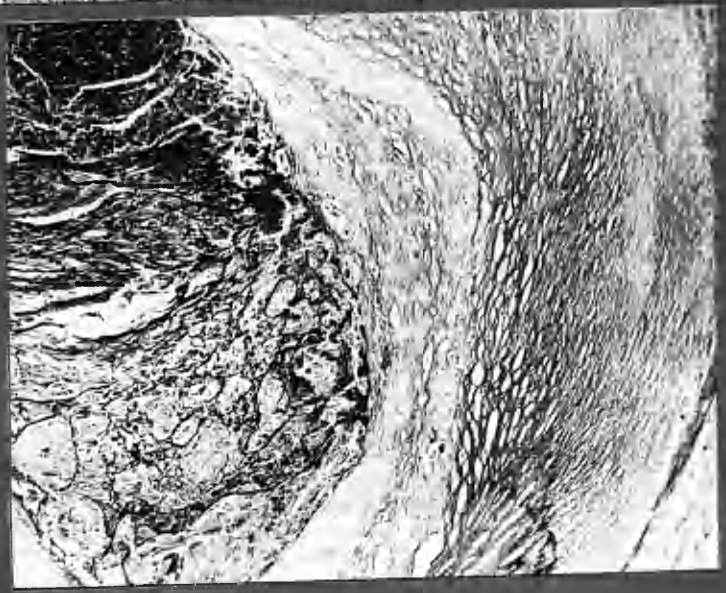
2:4

X64

(7)

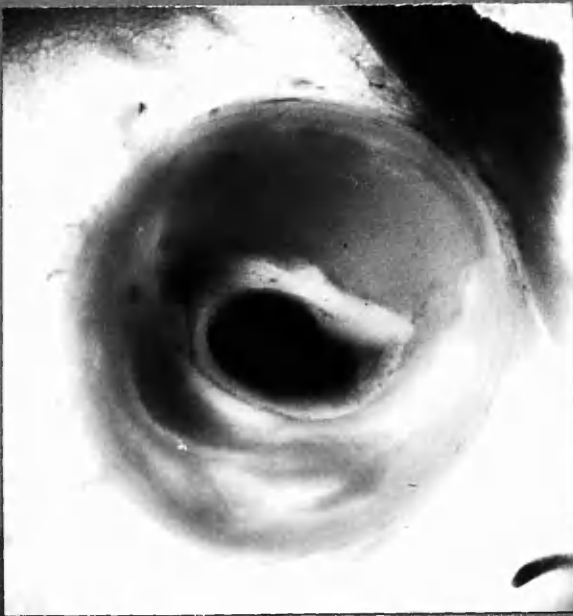
2:4

and from  
Pituitary



X60

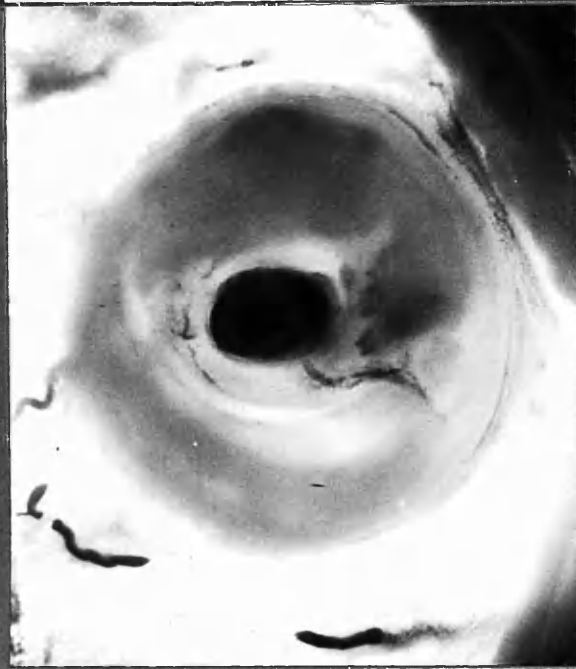



2:6b.

Crescents.

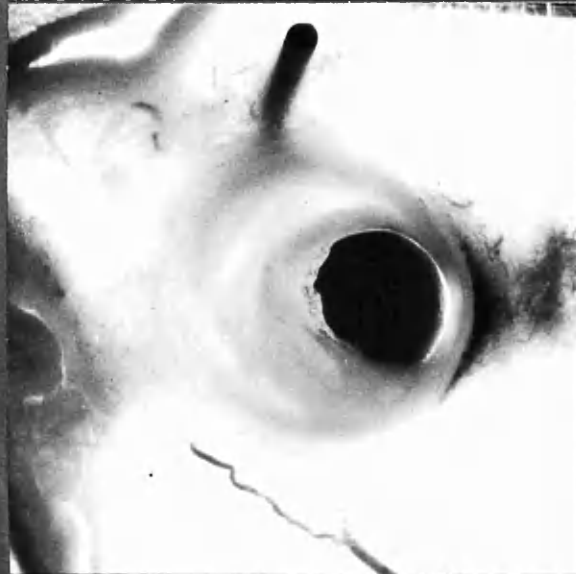x 12



2:8b.

Intimal vessels, between layers.

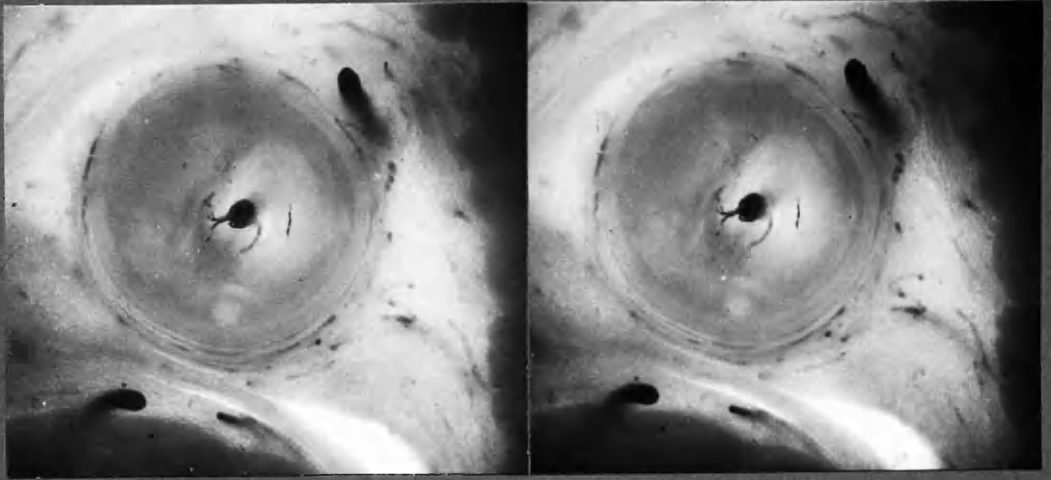
x 12



3:9b.

Crescents.

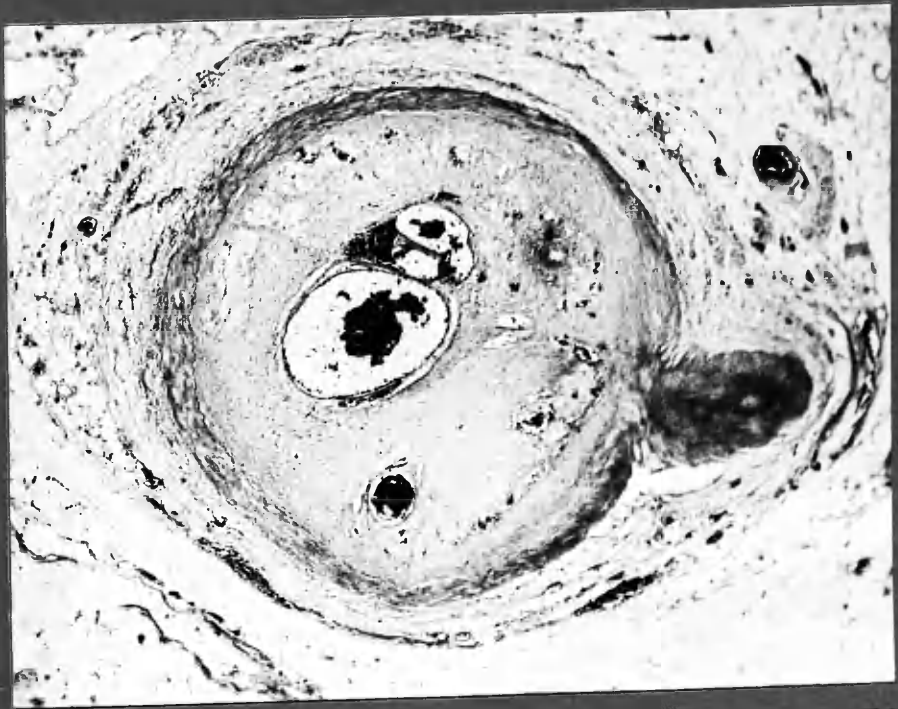
x 12



3:6 b, stereo-pair,  
origin of small intimal vessels from lumen.

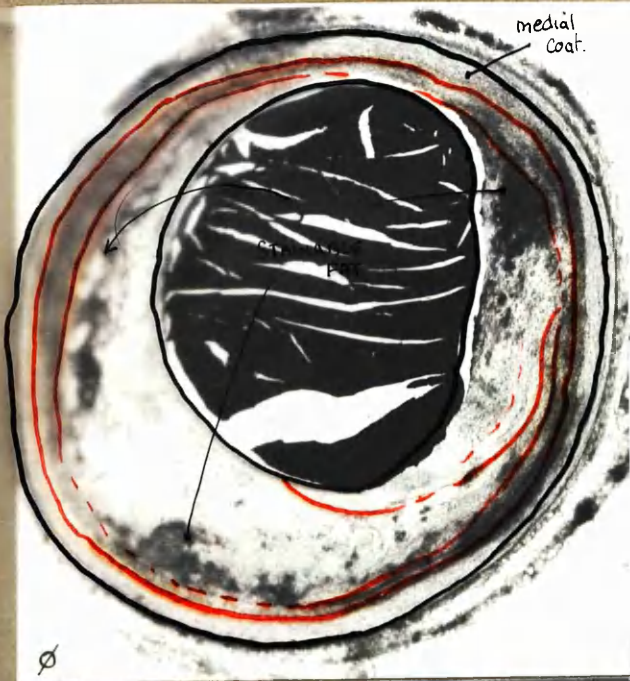x 11

4.4 H&E showing tendency for intimal vessels to be situated  
between previous artery wall and occluding thrombus, in this  
instance completely converted to fibrous tissue.



x 30





x20

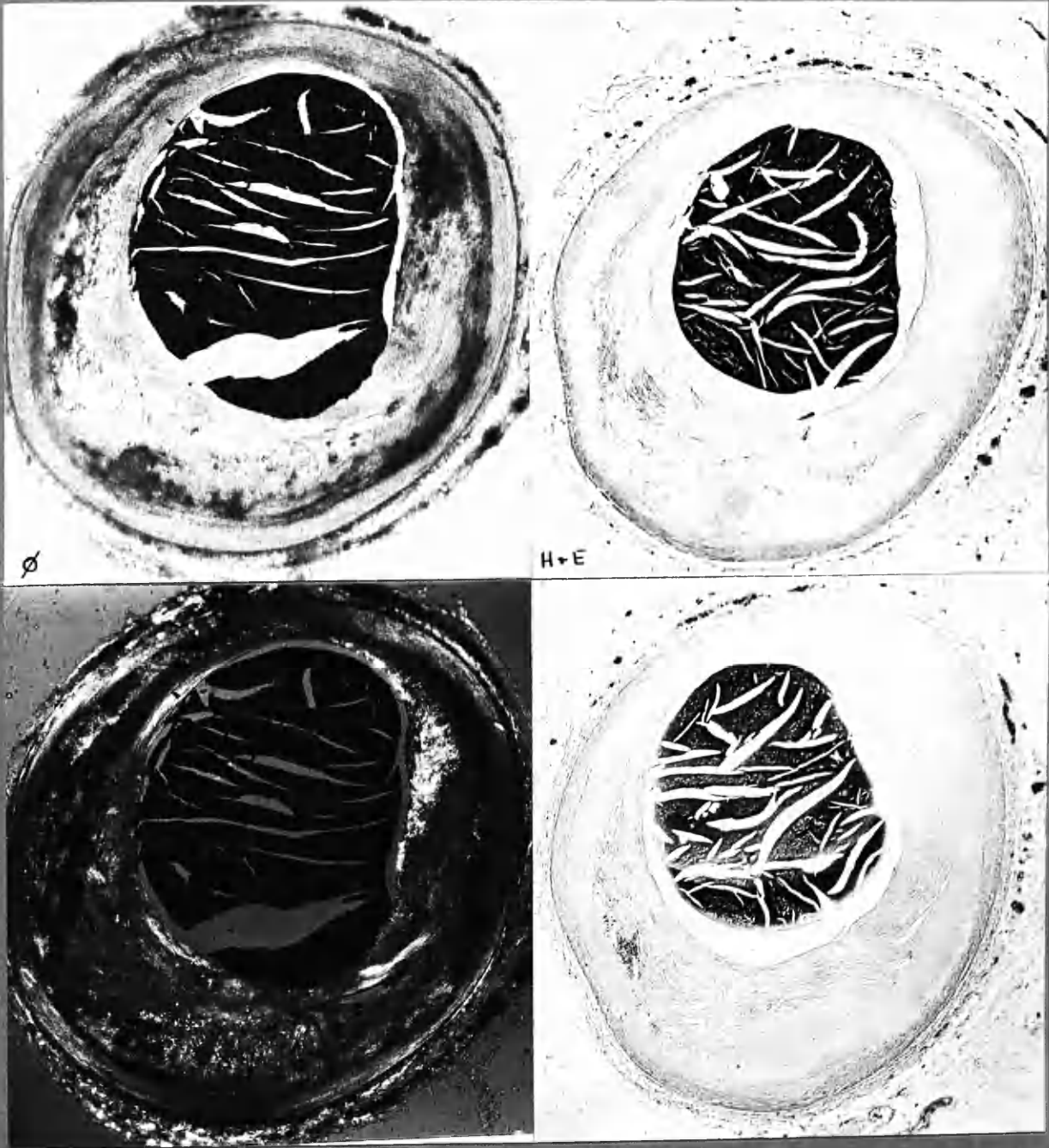
1. Scharlach R. (fat).

2. H+E

3. POLA.

4. P.B.R (Iron)

Frozen sections may reveal micro-anatomy not discernible in H+E. preparations.

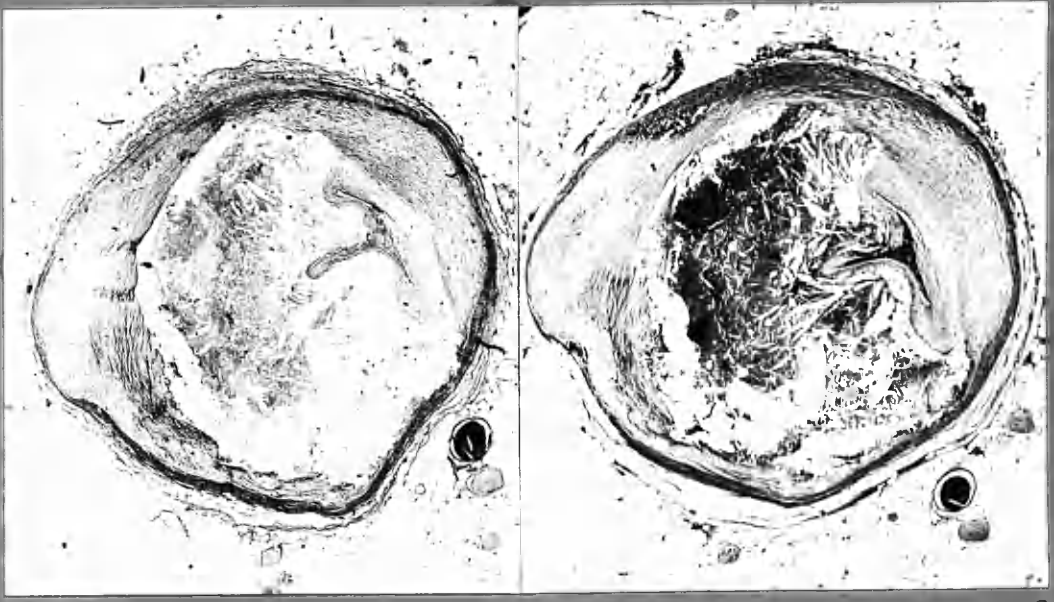


1. Scharlach R (fat)  
 3. POLA

2. H+E  
 4. P.B.R (iron)

Frozen sections may reveal micro-anatomy not discernible in H+E preparations.





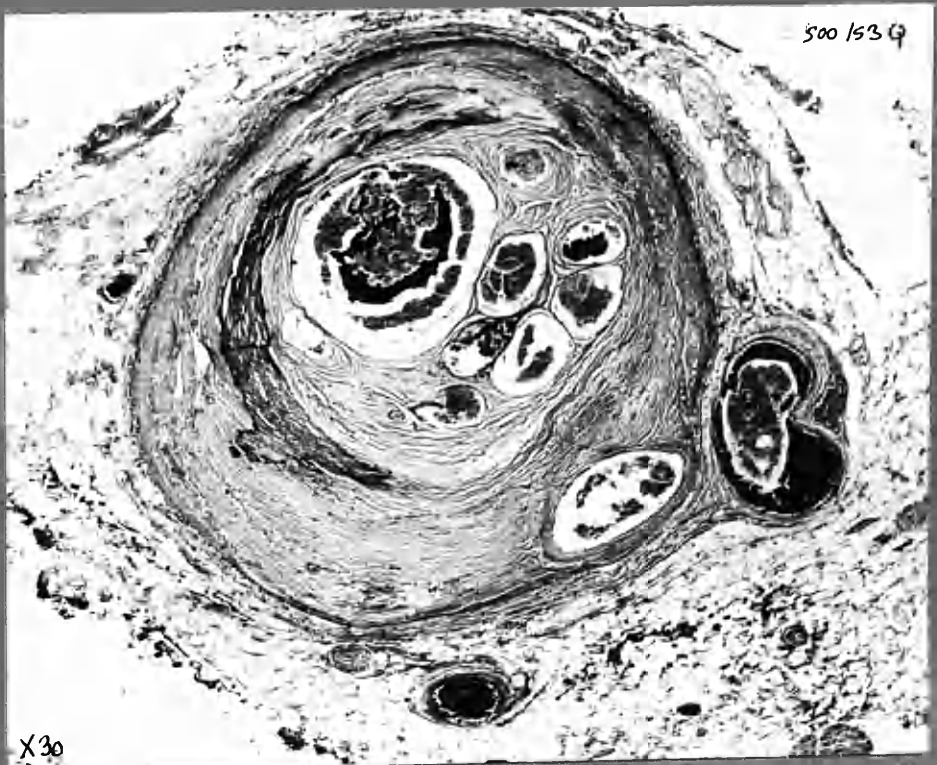
12 ADA 2:5 V. van G.

H+E

X 18

Appearances suggest that occlusion resulted from compression by large haematoma, reducing the lumen to a tri-radiate slit. Central autolysis of haematoma, with cholesterol clefts. Fibrous change at periphery apparently arrested.

11 RC



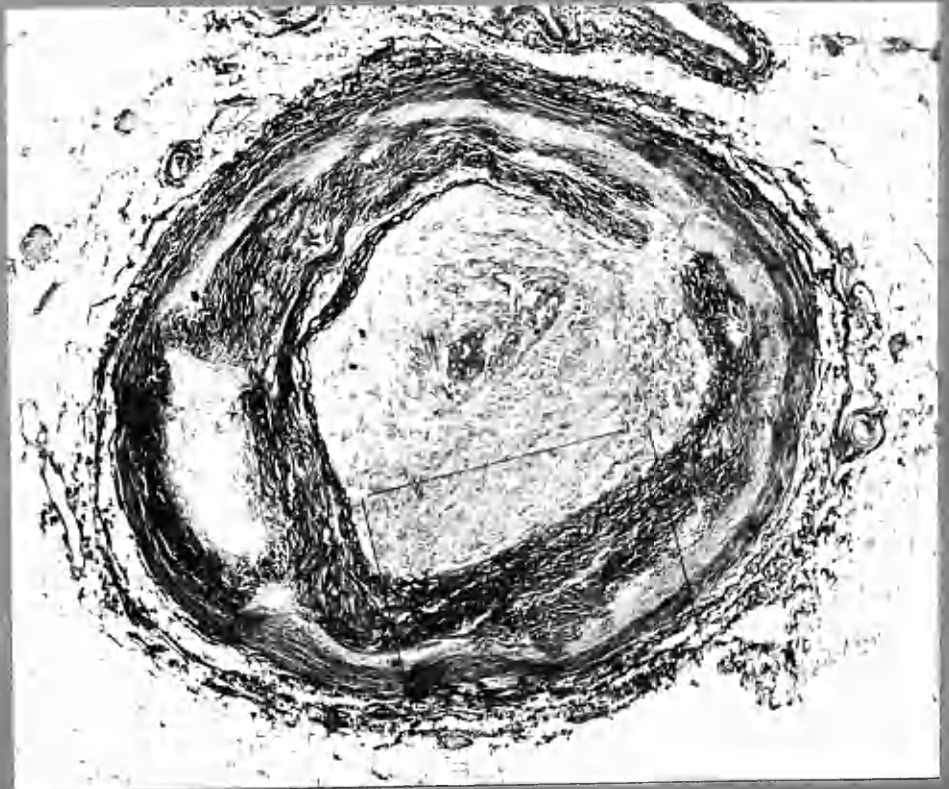
500 / 53 G

X 30

X 30

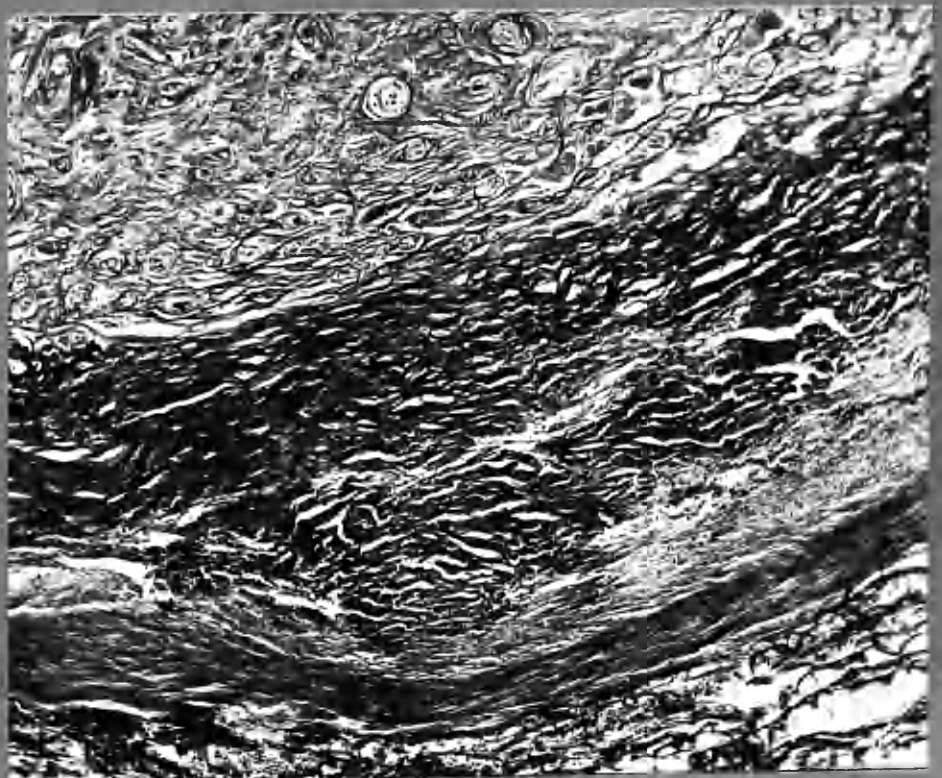
11 RC 1:8 V. van Gieson.

Old occlusion of a narrowed lumen by thrombus which has been converted into fibrous tissue and canalised by a few relatively large scale channels. These show recent secondary thrombosis.



V. van G

x30

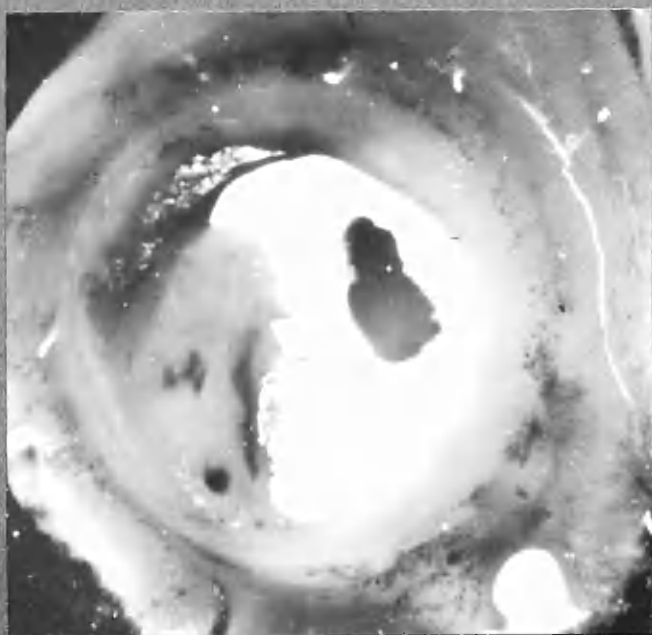


V. van G

x30

Thrombotic occlusion of old-standing. Thrombus still completely converted to fibrous tissue, in which there are numerous well-formed vessels of small calibre, most of which were still patent at time of death.





x12

LCxA "c" 1:3



x12

ADA "F" 1:3

10 LGA  
main branch  
(2)  
H+E

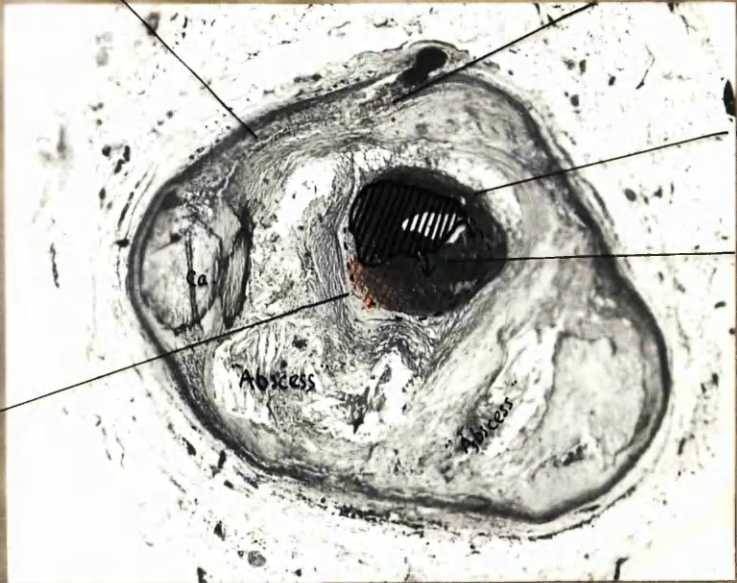
cellular infiltration

Iron deposit

Foam cells

Massive  
"fibrinoid"  
partially con-  
verted old  
thrombus.  
Penetrated  
by injection  
medium.

Zone where thrombus  
is undergoing conver-  
sion into infimal  
tissue.



x20

Iron.

wrinkle

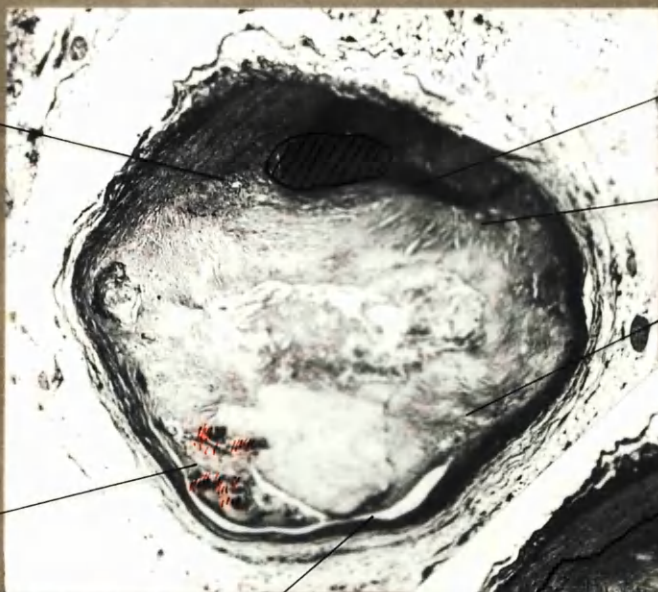
RC 1:13

iron

inimal vessel.

Internal elastic  
lamina.

Massive  
"fibrinoid"  
x20

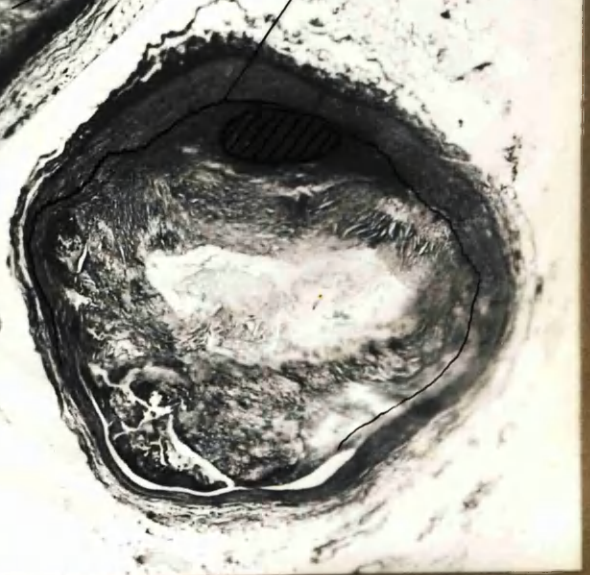


H. & E  
Artefact of shrinkage,  
reveals plane of cleavage.

Atheromatous "abscess" and  
eccentric lumen.

Lumen in contact with healthy  
wall at one side. This could  
be a result of thrombotic  
occlusion, with canalisation by  
"separation" at one point; conver-  
sion of thrombus into fibrous  
tissue except in centre where  
there is degeneration; and at the  
region marked where fibrin has  
been only partly changed to collagen-  
like material.

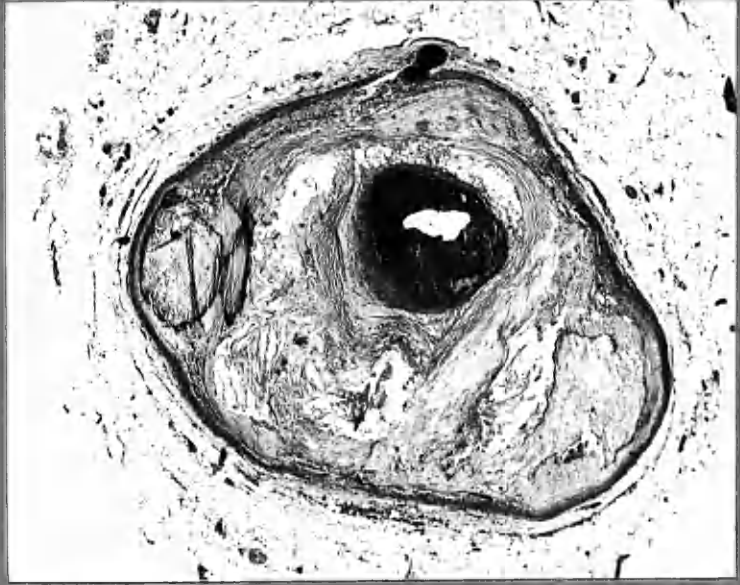
V. van G



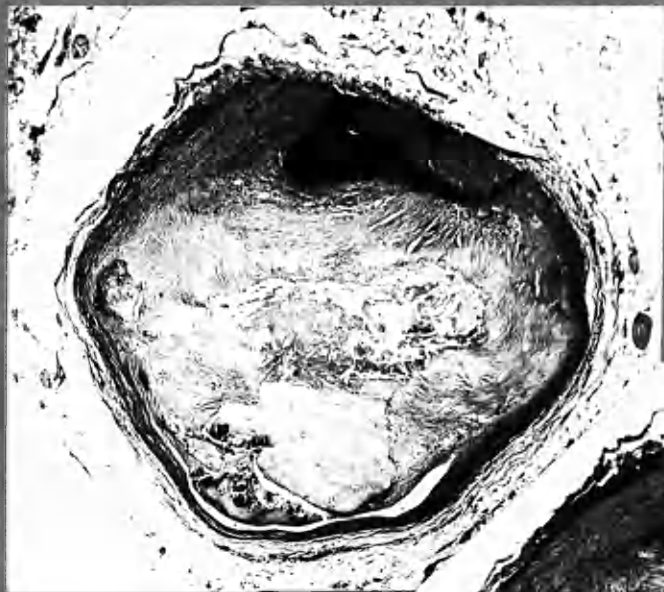

10  
LGxA  
RC

10. LGxA  
main branch  
(2)  
H+E



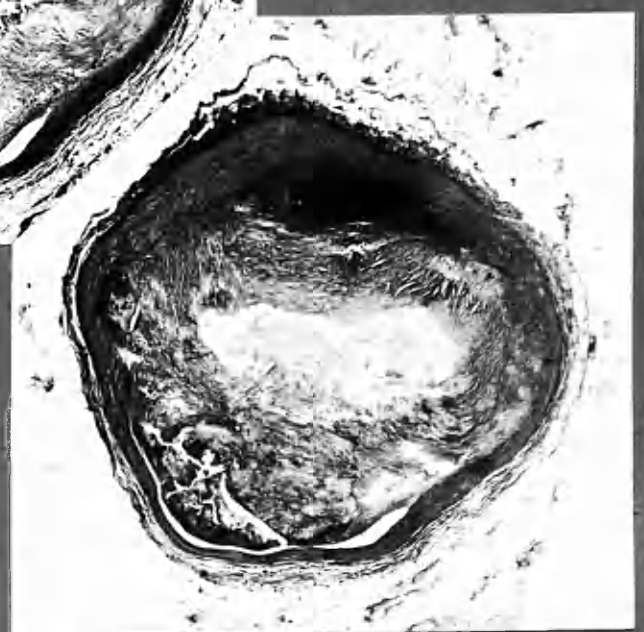
x20



x20

H+E

RC 1:13

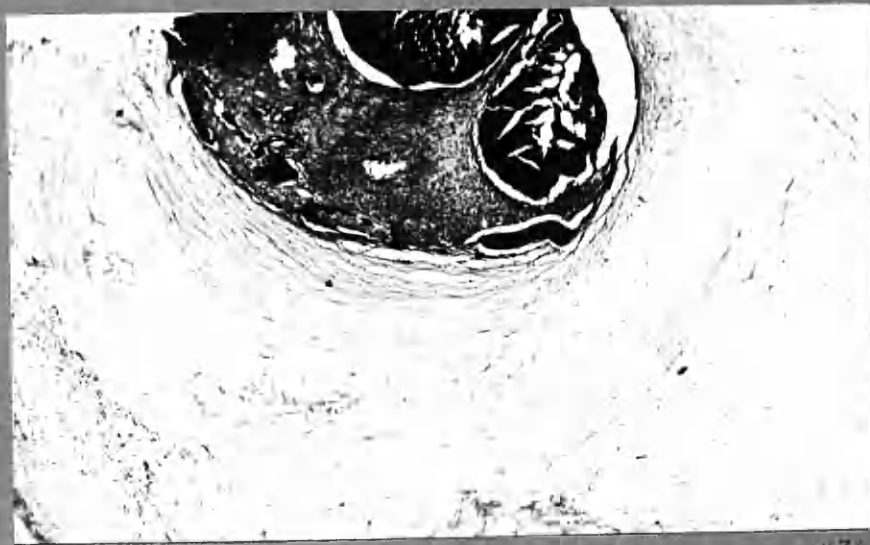

x20

V. van G

①

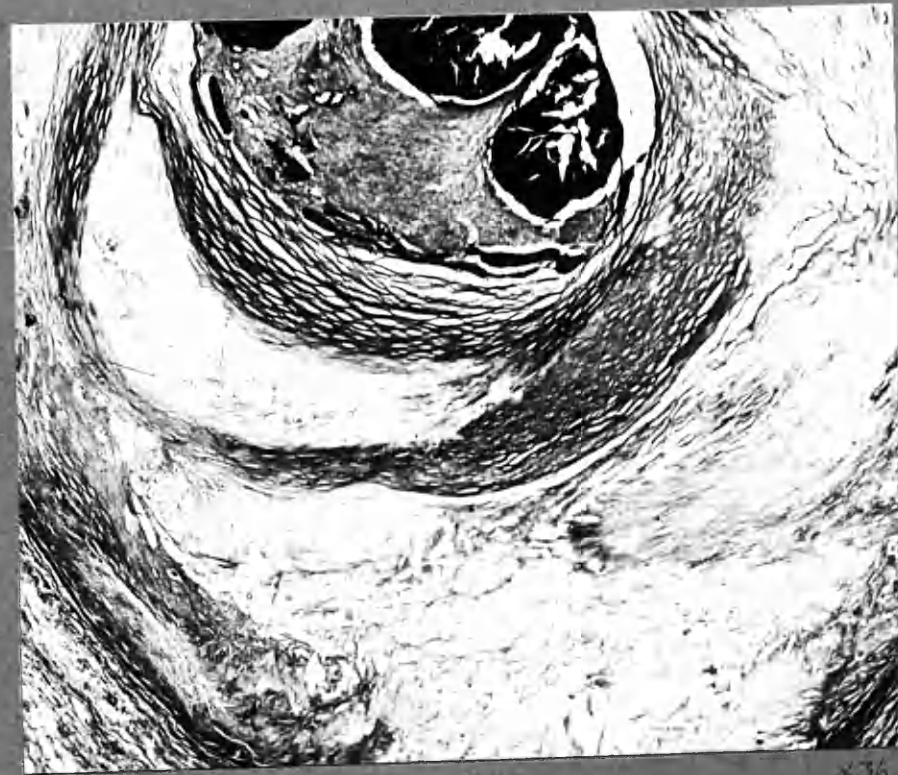H+E



x36

②

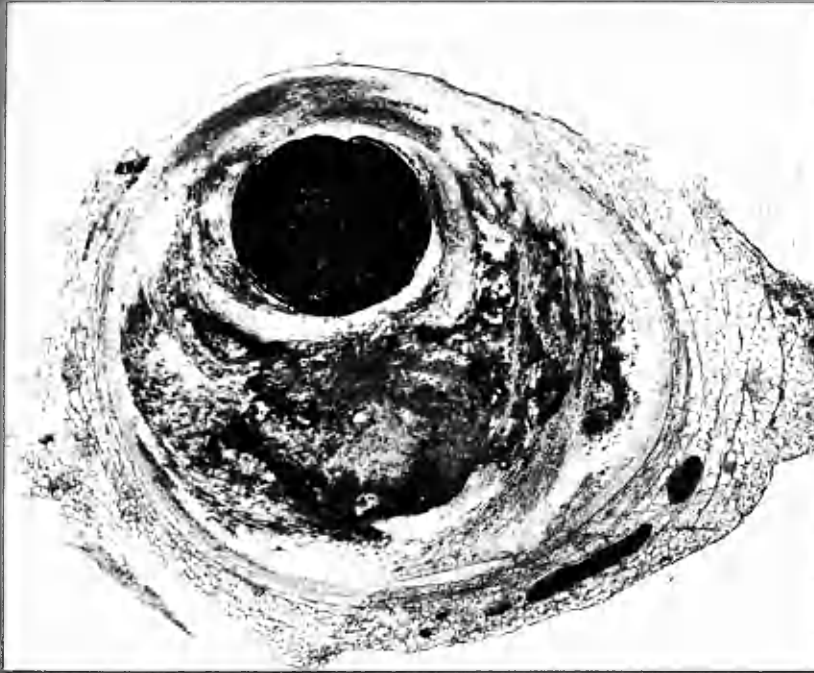V. van G



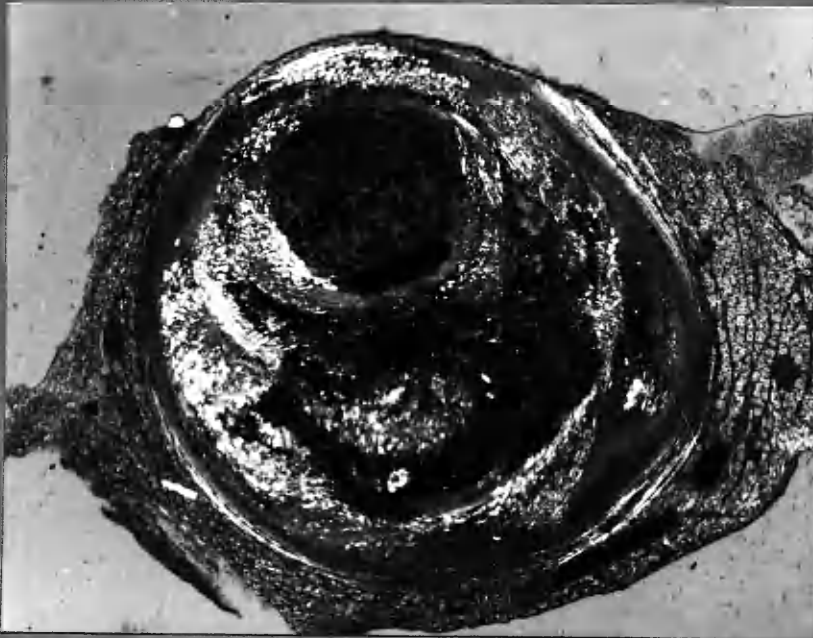x36

Episodic formation of atherosclerotic plaque. Recent thrombus overlies the last crescentic layer. New vessel formation by separation and fissuring.

7 ADA, 2



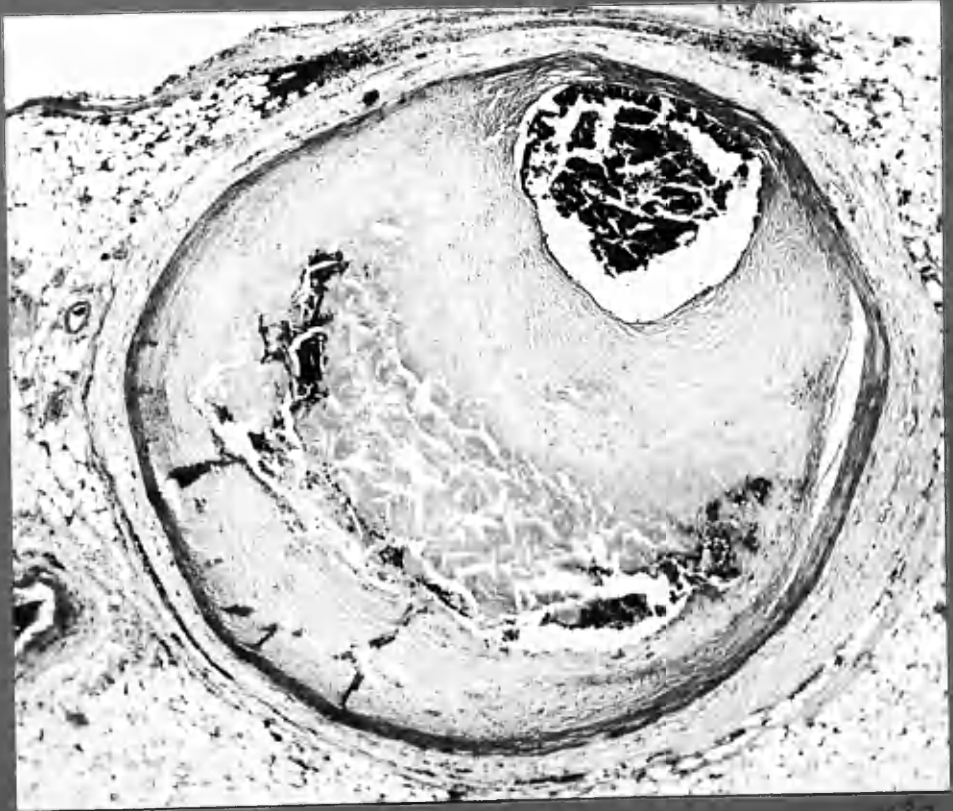
⊕  
①



POLA  
②

x18

Dissection of atheroma by injection medium

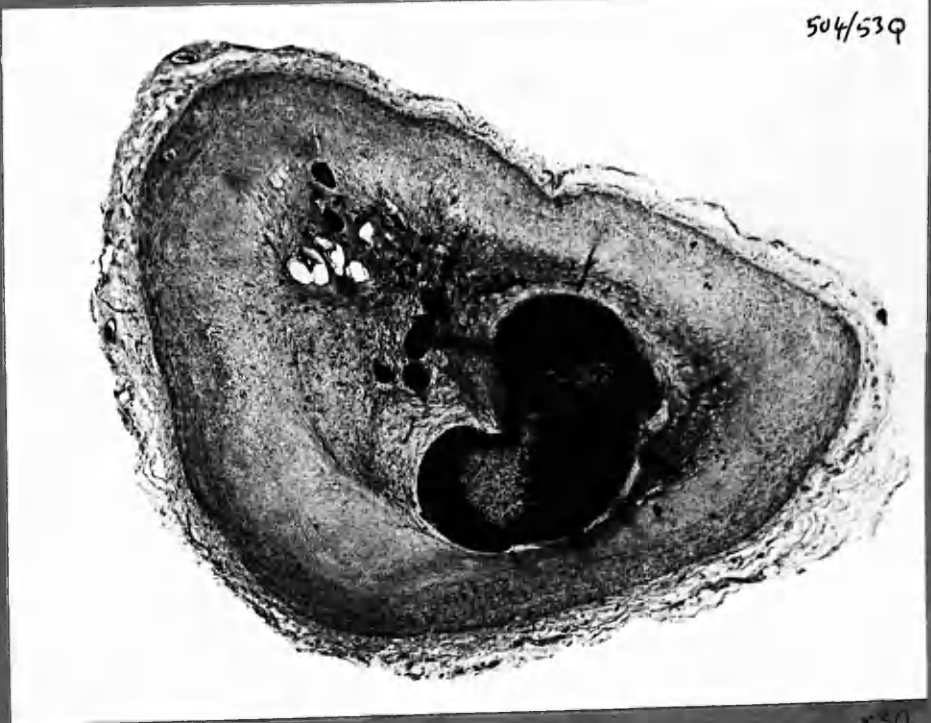


H+E

3

x30

7 RC.3



504/539

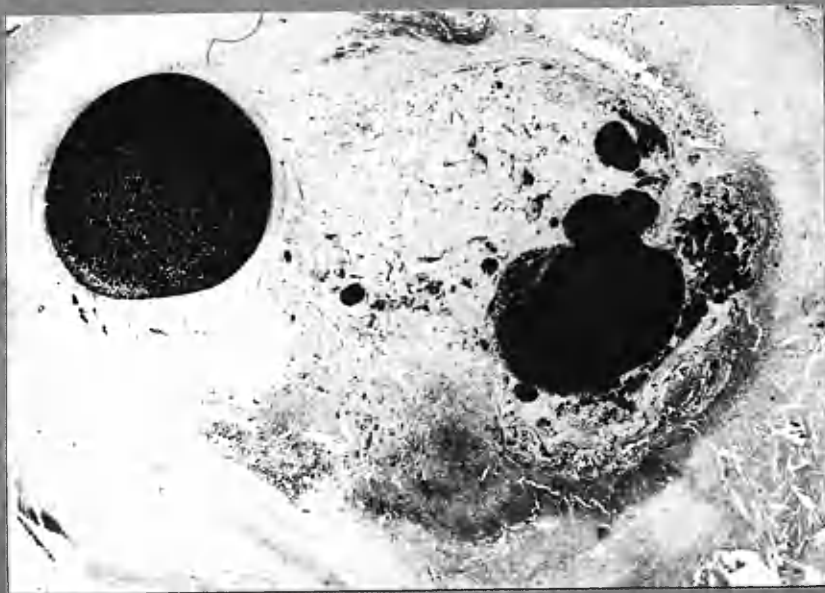
x30

H+E. Canalisation of old thrombus, now converted to atherosclerotic tissue.



7 RC2

(RC3 on previous page)

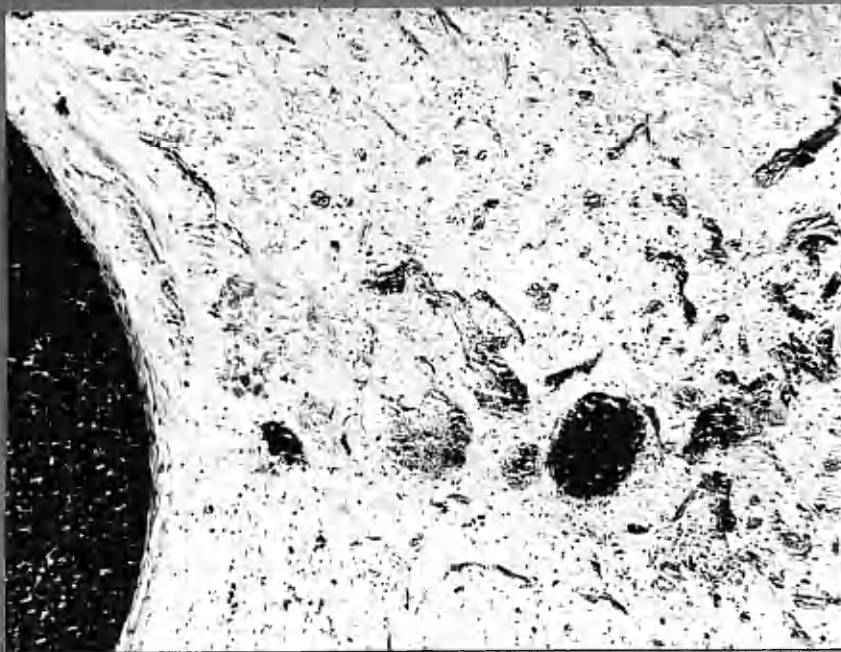


← dark, masses of  
"fibrinoid"

(1)

H&E

x22



(2)

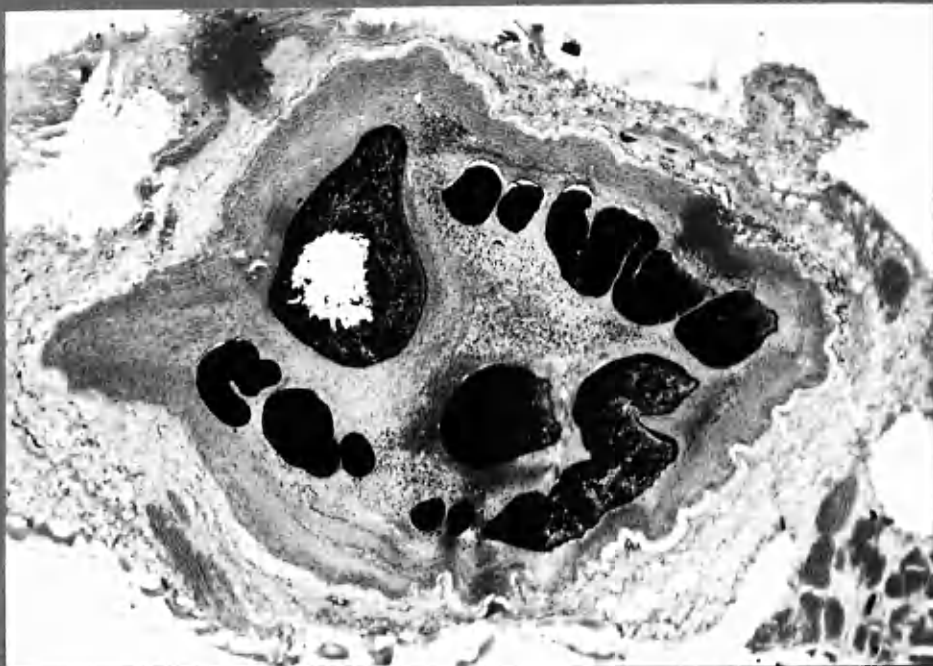
H&E

x90

Numerous small vessels in fibrous material derived from thrombus.  
The structure of these vessels is less fully developed than seen in  
11 ADA branch 'E' 212 or 1 ADA2

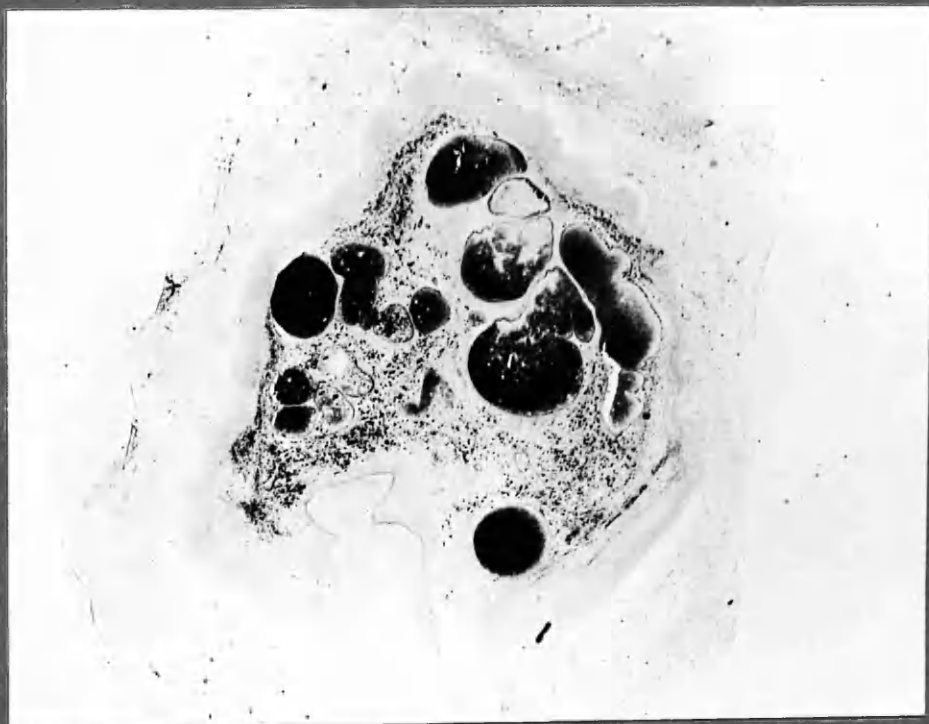H&E

x28



P.B.R.

x28

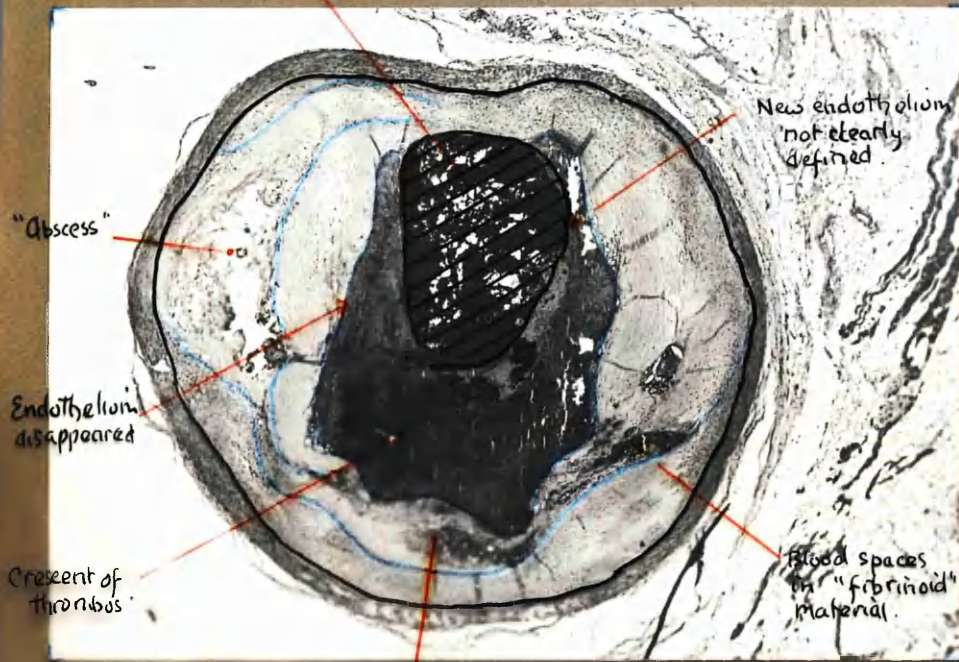


Iron deposit in old canalised thrombotic occlusion.



3 ADA ,

New lumen between clot and artery wall.



New endothelium  
not clearly  
defined.

"Abscess"

Endothelium  
disappeared

Crescent of  
thrombus

Blood spaces  
in "fibrinoid"  
material.

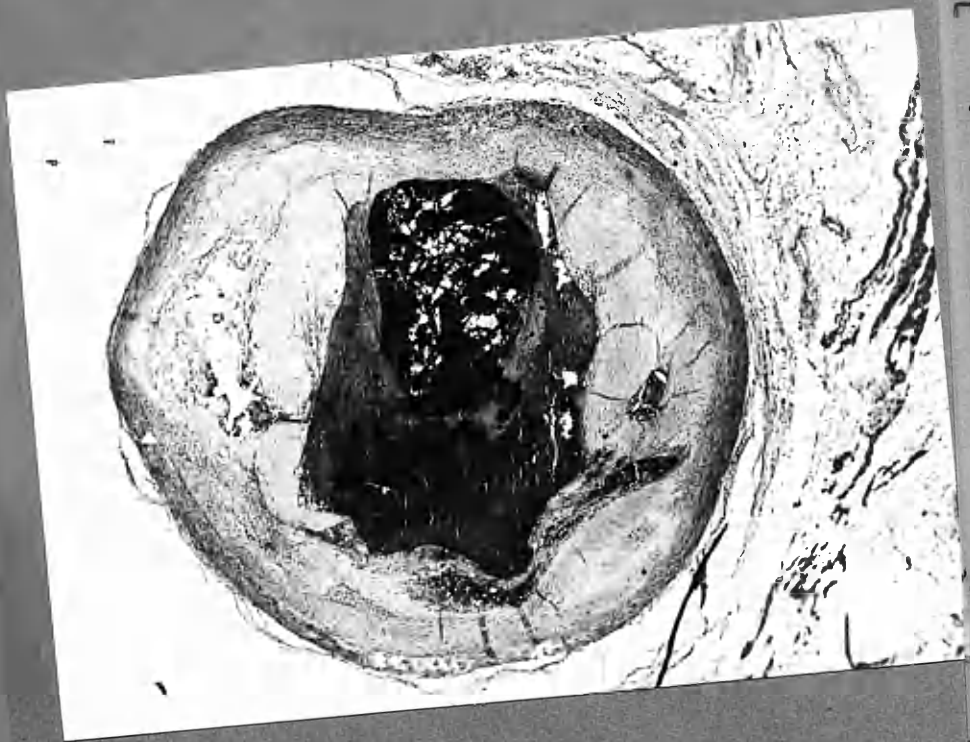
x22

? previous haemorrhage  
⇒ "fibrinoid" change.

Partial occlusion by thrombus, deposited in 2 layers. Intimal haemorrhage. At a lower level occlusion was complete. ? is the appearance above the result of canalisation, or was occlusion incomplete to begin with at this level?



3 ADA 1

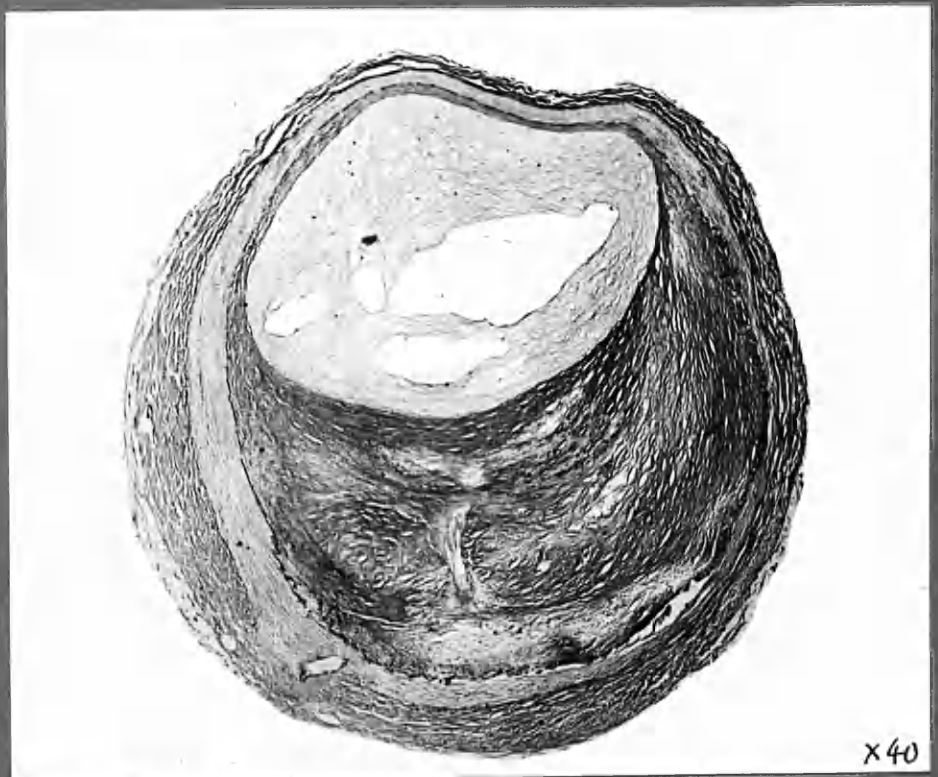


New thrombus with  
not clearly  
defined  
border

Blood spaces  
in "fibrous"  
material

"spade"  
spaces

H&E  
Partial occlusion by thrombus, deposited in 2 layers. Intimal  
haemorrhage. At a lower level occlusion was complete. ? is  
the appearance above the result of canalisation, or was occlusion  
incomplete to begin with at this level?

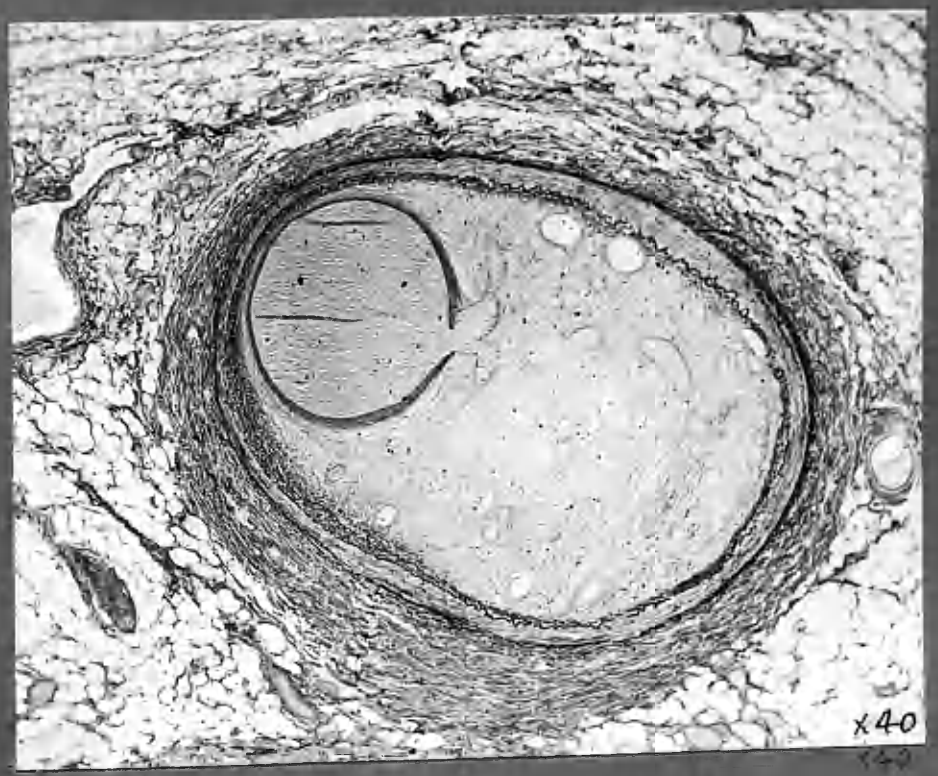


x40

Weigert's Elastic stain & van Gieson's stain

x40

1 ADA 2



x40

W van G  
 Old standing thrombotic occlusion (Type 1) of a previously healthy artery - Canalisation by a single eccentric channel from which small vessels arise and are distributed throughout the organized thrombus. These vessels were well formed, with clearly defined walls, containing fibrous and elastic tissue.  
 (Injection medium is dissolved in processing for Weigert's Elastic stain)

CHAPTER 8

THROMBOSIS

and ATHEROSCLEROSIS

Chapter 8: THROMBOSIS AND ATHEROSCLEROSIS

	<u>Page</u>
Illustrations and System of Reference.	8:1
Terminology Used in this Chapter.	2
<u>INTRODUCTION.</u>	3
<u>SOME TECHNICAL CONSIDERATIONS IN THE EXAMINATION OF ATHEROSCLEROTIC LESIONS:</u> Artefacts and their avoidance.	6
<u>PRELIMINARY OBSERVATIONS ON THE FIBROUS STRUCTURE OF THE PLAQUE:</u> Crescents, layers and thrombus deposition.	9
Crescentic layers.	11
Concentric layers.	14
<u>FURTHER FEATURES OF MICRO-ANATOMY:</u> Lipid, intimal vessels, intimal haemorrhages and dissection by injection medium.	17
<u>CHANGES AT THE INTERFACE BETWEEN THROMBUS AND UNDERLYING INTIMA.</u>	
Scope and limitations of observations.	20
Observations on thrombi outwith the coronary arteries.	21
Interface changes in the coronary arteries.	26
<u>SOME FEATURES OF ESTABLISHED ATHEROSCLEROTIC LESIONS</u>	
1. Evidence from 2 mm. thick transverse sections : Pigmentation.	31
2. Evidence from micro-sections: iron deposition.	37
A common origin?	39
<u>LIPID</u>	
Nature of lipid in atherosclerotic lesions.	40
Distribution of lipid in atherosclerotic plaques.	42
<u>FURTHER POINTS IN THE "ORGANISATION" OF THROMBUS:</u> Race between autolysis and sclerosis.	48
<u>DISTRIBUTION OF LIPID IN RELATION TO "NECROSIS".</u>	52
<u>ORIGIN OF LIPID IN INTIMAL LESIONS.</u>	53
<u>THE "EARLY" ATHEROSCLEROTIC LESION.</u>	
Evidence from frozen sections.	59
Evidence from gross specimens (2 mm. thick sections).	61

SOME /

Chapter 8: THROMBOSIS AND ATHEROSCLEROSIS .... 2

	<u>Page</u>
<u>SOME OTHER FEATURES OF THE ATHEROSCLEROTIC PLAQUE.</u>	
Calcification.	8:65
Cellular infiltration of the intima.	66
Medial degeneration.	67
Elastic tissue: Degeneration.	69
Development of elastic tissue in atherosclerotic plaques.	70

INTIMAL VESSELS. "VASCULARISATION" OF THE ATHEROSCLEROTIC PLAQUE AND INTIMAL HAEMORRHAGE.

Technical note.	71
Findings	72
1. Vessels which entered the intima from without.	73
2. Vessels arising from the lumen.	74
Comments on the origin, significance and hazards of intimal vessels.	76

PROXIMATE CAUSES OF THROMBOSIS IN SEVERE ATHEROSCLEROSIS.

Ulceration of the atheromatous plaque.	82
Interference with the flow of blood.	83
Intimal haemorrhage and thrombosis.	85
Haemorrhagic disruption and extension of atheromatous material into lumen.	91
Other local factors in the promotion of thrombosis.	94

SOME CONCEPTS OF ATHEROGENESIS.

a. GENESIS OF "EARLY" ATHEROSCLEROTIC CHANGES.	95
A highly speculative concept of gradual intimal thickening.	103
b. GENESIS OF THE LARGER ATHEROSCLEROTIC PLAQUE.	106

<u>SUMMARY</u>	113
----------------	-----

- C -  
ILLUSTRATIONS

(The majority of the illustrations are to be found in the group between Chapters 7 and 8.)

Illustrations interspersed in the text of Chapter 8:-

DIAGRAMS

	<u>Page</u>
8: 1 An artefact of shrinkage.	8: 9
8: 2 Evolution of the compound atherosclerotic plaque.	10b
8: 3 Distribution of lipid in atherosclerotic plaques.	42a
8: 4 Atheromatous abscess.	42a
8: 5 Intimal thickening and lipid accumulation.	62
8: 6 The intima as a filter.	96

PHOTOGRAPHS AND PHOTOMICROGRAPHS

	<u>Page</u>		<u>Page</u>
7 ADA	8:18a	19 ADA 2:6 micro (1-3)	8:10a
9 RC micro (1)	12a'	19 RC 1:6b	14a'
10 ADA micro (1)	12a'	19 RC 1:7 micro (1-3)	14a
12 RC 2:1b (CT)	30b	19 RC 1:10b	71a
14 ADA 2:3b (CT)	30c	19 RC 2:10b	18a
14 ADA 2:4 micro.	22b'		
14 ADA 2:5b (CT)	30d	20 ADA 2:2 micro	59a
14 ADA 3:1b (CT)	30d	20 ADA 3:3 micro (1-4)	14b
		20 ADA 3:4b (CT)	30a
15 ADA 3:2 micro F.S.	12a	20 RC 1:4b	59a
15 ADA 3:3a stereo (1, 2)	12a		
15 ADA 3:5b	18a	21 ADA 1:10b stereo	18b
		21 RC 4:2 micro (1-3)	59a
16 RC 2:5a	86a		
		22 ADA 2:5b	86a
17 RC 3:8		22 ADA 3:5b (CT)	30a
18 ADA 1:7b	86a	23 RC 2:4b	71a
18 ADA 2:9b	10a'		
18 ADA 3:5b	86a	24 ADA 3:6a	10a'
18 RC 3:10b	18b		
18 RC 3:12b	18b	25 LGxA 2:5b (CT)	30b
18 RC 4:13b	86a	25 RC 4:1b	71a
18 LGxA 1:4b	18b	25 RC 5:2b	71a'
18 LGxA 1:4b (CT)	30c	25 RC 5:9a	18a
		25 RC 5:10a	71a'

Atrial thrombus, case 13	8:22a Atrial thrombus MHA 5125	8:22b'
.. .. D9	22a Interface changes in a	22b'
Thrombus in subclavian artery	22b coronary artery	

---

CT = colour transparency. 71a = page following 71 and 71a' is on the  
obverse side of 71a.

## ILLUSTRATIONS

(The majority of the illustrations are to be found in the group between Chapters 7 and 8.)

### Illustrations interspersed in the text of Chapter 8:-

#### DIAGRAMS

		<u>Page</u>
8: 1	An artefact of shrinkage.	8: 9
8: 2	Evolution of the compound atherosclerotic plaque.	10b
8: 3	Distribution of lipid in atherosclerotic plaques.	42a
8: 4	Atheromatous abscess.	42a
8: 5	Intimal thickening and lipid accumulation.	62
8: 6	The intima as a filter.	96

#### PHOTOGRAPHS AND PHOTOMICROGRAPHS

	<u>Page</u>		<u>Page</u>
7 ADA	8:18a	19 ADA 2:6 micro (1-3)	8:10a
9 RC micro (1)	12a <sup>†</sup>	19 RC 1:6b	14a <sup>†</sup>
10 ADA micro (1)	12a <sup>†</sup>	19 RC 1:7 micro (1-3)	14a
12 RC 2:1b (CT)	30b	19 RC 1:10b	71a
14 ADA 2:3b (CT)	30c	19 RC 2:10b	18a
14 ADA 2:4 micro.	22b <sup>†</sup>		
14 ADA 2:5b (CT)	30d	20 ADA 2:2 micro	59a
14 ADA 3:1b (CT)	30d	20 ADA 3:3 micro (1-4)	14b
		20 ADA 3:4b (CT)	30a
15 ADA 3:2 micro F.S.	12a	20 RC 1:4b	59a
15 ADA 3:3a stereo (1, 2)	12a		
15 ADA 3:5b	18a	21 ADA 1:10b stereo	18b
		21 RC 4:2 micro (1-3)	59a
16 RC 2:5a	86a		
		22 ADA 2:5b	86a
17 RC 3:8		22 ADA 3:5b (CT)	30a
18 ADA 1:7b	86a	23 RC 2:4b	71a
18 ADA 2:9b	10a <sup>†</sup>		
18 ADA 3:5b	86a	24 ADA 3:6a	10a <sup>†</sup>
18 RC 3:10b	18b		
18 RC 3:12b	18b	25 LCxA 2:5b (CT)	30b
18 RC 4:13b	86a	25 RC 4:1b	71a
18 LCxA 1:4b	18b	25 RC 5:2b	71a <sup>†</sup>
18 LCxA 1:4b (CT)	30c	25 RC 5:9a	18a
		25 RC 5:10a	71a <sup>†</sup>

Atrial thrombus, case 13	8:22a Atrial thrombus MHA 5125	8:22b <sup>†</sup>
.. .. . D9	22a Interface changes in a	22b <sup>†</sup>
Thrombus in subclavian artery	22b coronary artery	

---

CT = colour transparency. 71a = page following 71 and 71a<sup>†</sup> is on the obverse side of 71a.



NOTE ON ILLUSTRATIONS AND SYSTEM OF REFERENCE

This chapter is illustrated by drawings, photographs of 2 mm. thick transverse sections of coronary arteries and photomicrographs.

Some of the photographs of the 2 mm. thick sections are colour transparencies, mounted in conjunction with photographs of the same sections in monochrome. Others are presented in stereo-pairs.

The majority of the illustrations are shared with Chapter 7 and accordingly are placed in a group between the two chapters. In this group, many of the photographs of 2 mm. thick artery sections are mounted in company with the stereo-arteriograms, and should be sought there in the first instance.

Photomicrographs, and such photographs which have not been placed with the arteriograms, are to be found in a second group immediately after the arteriograms.

In addition, a number of photographs and photomicrographs are interleaved with the text of this chapter, and are usually to be found opposite to, or within a few pages of, the reference to them in the text. These illustrations are listed under "Illustrations" on the previous page.

The colour transparencies are mounted together between pages 30 and 31.

The System of Reference to individual sections is the same as used in Chapter 7.

e.g., 15 ADA 3:2 micro 1 is the 1st mounted photomicrograph selected from sections taken from block No.2 in the 3rd row of mounted 2 mm. thick sections of the anterior descending artery, Case No. 15.  
(For further details see Chapter 7.)

TERMINOLOGY USED IN THIS CHAPTER

The three walls of the artery are referred to as the adventitia, the media and the intima. The intimal lining is the endothelium, and subendothelial refers to the situation immediately under the endothelium. The terms "sub-intima" and "sub-intimal" are avoided.

"Atherosclerosis" is used for all lesions which show intimal fibrosis and lipid accumulation.

"Atheroma" is restricted to bulky lesions with a large lipid content.

"Atheromatous abscess" refers to the necrotic centre found in many atherosclerotic lesions. It is not used as a description of the entire lesion.

"Atherosclerotic, or atheromatous, plaque" is used in a two-dimensional sense. It refers to an eccentric thickening of the intima as seen in cross section, without taking into account its limits above or below this level.

"Stainable fat" applies to fat stained by Scharlach R. and corresponds to neutral fat, or triglyceride.

"Doubly-refractile fat" was identified by crossed polaroid filters and corresponds to crystalline cholesterol, or lipid, when the term is used specifically.

Where both stainable fat and doubly refractile fat are spoken of together, or where no attempt is made to distinguish the one from the other, "lipid" is used.

"Collagen", "Collagenous change" and "Collagenous fibres" are used guardedly, referring to the extracellular material which showed staining qualities in H. and E. van Gieson's and - in a few instances - Mallory's stains which were consistent with the staining qualities of collagen at other sites.

"Organisation" of thrombus is likewise applied guardedly, in reference to the processes which lead to the replacement of thrombus by atherosclerotic tissue.

Abbreviations used are standard throughout, as used in Chapters 5 and 7.

"In the 32 instances in which thrombi were encountered in the coronary arteries, the thrombi were located on atheromatous ulcers."

Saphir et al., 1935

95 per cent of cases of coronary occlusions are attributable to atherosclerosis .

Wartman and Hellerstein, 1948.

"Thrombosis never happens in a healthy vessel."

Morgan, 1956 .

This opinion is supported by the observations of:-

Wearn,	1923
Willius,	1925
Hamman,	1926
Levine and Brown	, 1929
Wolkoff	, 1929
	(Morgan, 1956)

It is not clear if it has been ascertained that diabetes is being treated.

THROMBOSIS AND ATHEROSCLEROSIS:  
 An Essay on the Genesis and Micro-anatomy of Atherosclerosis  
 of the Coronary Arteries

---

Despite the immense body of research into the genesis of atherosclerosis, the subject is still full of uncertain concepts and unanswered problems. In coronary artery disease, death is most commonly caused by recent coronary occlusion by thrombosis. It is well recognised that, in the great majority of cases, the intimal lining of the artery in which thrombosis develops is already the seat of severe disease. Fatal coronary thrombosis is therefore the end-result or complication of a pre-existing disease process. The origins and evolution of this process are still obscure. That is not to say that little has been revealed of the details of atherosclerotic lesions - far from it - but that there is little certain agreement about their interpretation and genesis. Indeed, there is scarcely a feature of atherosclerosis about which sincere doubt cannot be entertained as to its significance in terms of cause and effect.

For instance, no observer can fail to be impressed by the enormous quantities of lipid material sometimes present in an atheroma. This material is best seen in frozen sections viewed under polarised light,<sup>1,2,3,4,5</sup> or stained for fat.<sup>2,3</sup> But is lipid a primary deposition and the cause of other changes? Or is it a secondary development, the result of other changes? Or is it part of a vicious cycle? Whence comes this lipid? Is it a deposition of constituents of the blood serum, as is generally supposed, or does it develop from other material in situ? These are questions which are not fully answered. There is a vast body of literature relating to the experimental deposition of lipid in the arterial intima of animals, apparently as a primary result of grossly abnormal serum lipid concentrations. But this does not prove that the

---

(1) 18LGA 1.5 micro.  
 (2) 19 ADA 2:6 micro.  
 (3) 20 ADA 3:3 micro.

(4) 15 ADA 3:2 micro.  
 (5) 7 ADA (2) micro.

the lipid in naturally occurring human atherosclerosis is so derived, nor the atherosclerotic lesions so caused. Likewise there is a world wide search for the elusive relationship between atherosclerosis in the arteries of man and the patterns and absolute levels of lipid fractions in his serum. I do not propose to discuss this aspect of the subject except where serological considerations and the findings of this pathological investigation bear upon each other. At this point the old question may again be raised, if lipid deposition in the human intima be a primary phenomenon in the genesis of atherosclerosis, and if that deposit be related to serological changes, how is it then that the lesions themselves are so unevenly distributed? And further, I would ask, how is it that the obliterative lesions which have paramount importance in coronary artery disease should so often have so little fat in them?

Many factors of an anatomical or dynamic nature have been considered in the localisation of atherosclerotic lesions,<sup>1,2,3,4</sup> but the problem is still largely unsolved. Again, when such lesions have developed, the causes of thrombosis on their surfaces are not clear. Intimal haemorrhages (Paterson, 1941, 1952) and "ulceration" of the atheroma as the result of degeneration (Saphir et al., 1935) have been invoked. When these appearances are seen to underlie thrombus, the question arises, are they causal or are they secondary results of thrombosis? Are cellular infiltrations or intimal vessels of primary or secondary significance? Do small atherosclerotic lesions develop in course of time into larger lesions so that the one is in fact the "earlier" stage of the other?

These are but a few random questions which serve to sketch in outline some of the many uncertain factors in the genesis of this important disease. In this chapter I shall present a number of the features observed in the present investigation which have some bearing on this problem.

---

1. Dock (1946).

2. Geiringer (1951).

3. Winternitz et al. (1938).

4. Hueper (1956).

82

Although it will be necessary to enter into considerable histological detail, the main considerations in this chapter are micro-anatomical rather than truly histological or cytological. I have written this chapter as an essay on the genesis and micro-anatomy of atherosclerosis of the coronary arteries. Here and there under this title, I have permitted myself the liberty of indulging in a certain amount of speculation, and I have hazarded comment on topics outwith the scope of my own experience. The vagaries of this investigation have enticed me to stray into territories previously unfamiliar to me, and I have recorded some of the things which arrested my attention. I am aware that I have seen, as it were, through the eyes of the traveller. I embarked upon the journey without the advantages - and prejudices - of special indoctrination in regard to what I was to see. I explored with sketch-book, camera and collecting-box in hand and became acquainted with the terrain. My observations have been made upon material so collected. Were I to re-explore the territory, seeking confirmation - or refutation - of the conclusions I have reached, I should have the advantage of knowing better which points to look for and to record, and what equipment to carry. I am conscious of the shortcomings of my first survey of this field. Nevertheless I feel it has been worthwhile to commit to paper in this chapter the preliminary findings I have made and the ideas I have formulated.

These ideas have been derived almost entirely from observations which I made before undertaking close study of the findings of others. Point by point I have found most of my observations previously or subsequently recorded in the vast literature on atherosclerosis and coronary artery disease. Likewise I have found my opinions severally held, or denied, in the writings of a great many observers. That is but the way of the study of atherosclerosis. An investigation of this order may not bring to light new information, and yet be of value. My own enquiry and observations have helped me to make my own selection from the many available interpretations of phenomena which may be observed, if looked for; and to come to some understanding of this disease, and the extent and limitations of our knowledge of its pathology. I also hope that presentation of my findings may have some illustrative value, and be acceptable as evidence in support of the concept of thrombosis as a major factor in the genesis of coronary atherosclerosis.

070

SOME TECHNICAL CONSIDERATIONS IN THE EXAMINATION  
OF ATHEROSCLEROTIC LESIONS: Artefacts and their  
Avoidance

---

The histological examination of diseased arteries is a matter of considerable technical difficulty. The conventional methods of post-mortem examination are fraught with artefact. Attempts at visualising the lesions by snipping down the lumen with scissors or by cutting across unsupported, and often calcified, arteries with the knife are bound to cause distortion and destruction of the evidence. And yet, until the lesions have been visualised, how can the blocks for sectioning be selected? And having been visualised, how can the fragmented evidence be interpreted with accuracy? That is the dilemma with which the pathologist must compromise should his preliminary examination follow a conventional method.

A more subtle artefact is introduced when the selected portion of artery, no matter how carefully handled is placed in fixative and processed for paraffin sectioning. Shrinkage of the tissues takes place, but not uniformly. This is seen to cause severe distortion where there is a large, friable, eccentrically placed, atheromatous lesion. As a result of differential shrinkage - or so it would seem - the atheromatous plaque bulges into the lumen of the artery and shearing strains tend to tear the delicate tissues ~~ap~~under. Fat solvents remove much of the substance of the atheromatous lesions and very often some portions are defective by the time the sections have been stained. Shrinkage of the walls of the artery continues to cause trouble after cutting and tends to cause the section to buckle and to be thrown into folds. Portions not in contact with the glass slide come adrift.

In the case of an atheromatous lesion, a fortunate section will retain a proportion of material in which crystal-shaped spaces indicate the previous lodging of cholesterol, and a shelf of collagenous tissue separates the

1

atheromatous "abscess" from the lumen. In a less fortunate section most of the amorphous material of the atheromatous "abscess" is lost and the shelf, especially if thin, is deficient or absent. In this way the artefact appearances of an "ulcer" formed by the rupture of an atheromatous plaque are very readily produced. It is common experience that the artery packed solid with organised thrombus presents a much simpler problem to the microtommist.

It was partly in order to avoid as many artefacts as possible that the elaborate method of examination used in this investigation was devised. Sectioning of arteries was facilitated by the support given by the injection medium. Friable tissue was further supported by gelatin embedding. Decalcification was made routine before sectioning. The blocks for microscopic examination were chosen from the serially mounted, 2 mm. thick sections of the arteries after these had been excised by block dissection, aided by reference to the stereo-arteriograms. (For details of the method see Chapter 1.)

Before submitting a 2 mm. thick block for paraffin embedding, frozen sections were taken from it or from its immediate neighbour. Frozen sections had the advantage of retaining the lipid material in situ.

Few manipulations of biological material are free from artefact on their own account, and the injection technique used in this investigation was no exception:- (1) Occasionally it seemed that the post-mortem tissues had been over-stretched by the injection, with break in the continuity of the intima and rupture of injection medium alone into the substance of atherosclerotic plaques. This finding is discussed in more detail elsewhere. As a simple artefact it was an unusual occurrence. On the other hand, entry of the injection medium, in the company of blood, into the intimal lesions was encountered more frequently. This was probably not an artefact appearance. (2) Sometimes the close application of injection medium to the intimal surface made it difficult to identify the endothelium itself.



These two disadvantages of the method were only occasionally encountered and were far outweighed by the advantages. Saphir et al. (1935) assumed that injection would carry the risk of dislodging thrombus and accordingly these workers did not use injection methods. Had they done so it is possible that they might have been less impressed by "ulceration" of atheromatous plaques, a concept that has been widely quoted. In this investigation I found no evidence to suggest that thrombus had been dislodged by the injection medium, and there was but a single example of displacement of the contents of an atheroma (22 RC).

As already indicated elsewhere (Chapter 7) random sections taken through a diseased portion of artery may be far from representative. The serially mounted 2 mm. sections allowed accurate orientation of the micro-sections of the arteries in relation to changes which had taken place above and below the plane of section. In this way a third dimension was added to the histological examination.

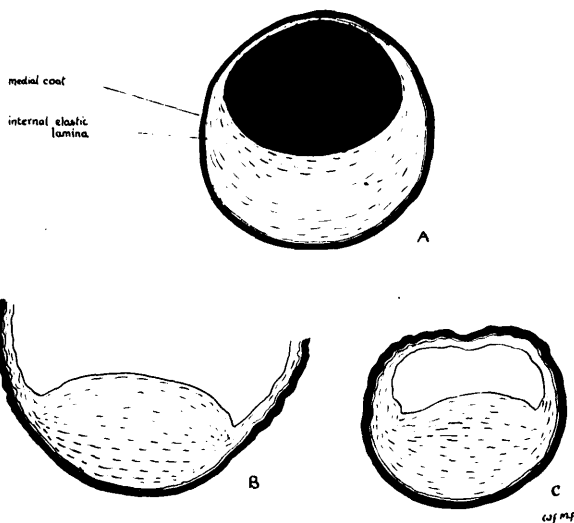
These technical considerations have been raised at the beginning not without reason: for certain of the findings that will be presented have depended upon freedom from artefact distortion of the lesions. This is a matter which has special importance in examination of the micro-anatomical configuration of atherosclerotic plaques.

PRELIMINARY OBSERVATIONS ON THE FIBROUS STRUCTURE OF THE  
 PLAQUE: Crescents, Layers and Thrombus Deposition.  
Further Technical Considerations.

When an atherosclerotic artery is snipped open with scissors, according to a method commonly employed at autopsy, atheromatous plaques are seen to bulge into the lumen much as a tumour of its wall may protrude into the lumen of a hollow viscus (as noted by Harrison and Wood, 1949, and by Crawford and Levene, 1953). A similar appearance was found on section of the unsupported (i.e., empty) artery in the fresh specimen or where fixation had been carried out without prior support by injection. These appearances are represented graphically in Diagram 8:1. With rare exception the protrusion of atherosclerotic plaques into the lumen is an artefact in the sense that it is not representative of the situation obtaining in life.

DIAGRAM 8:1

AN ARTEFACT OF SHRINKAGE




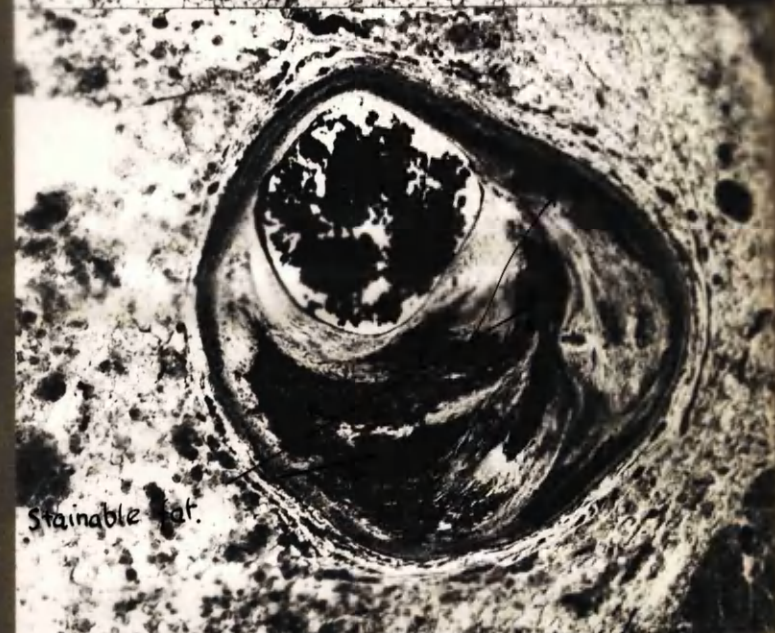

A. Artery distended, and thereby supported, by injection medium: note direction of stretched fibres and internal elastic lamina. B. Artery snipped open with scissors. C. Artery fixed but not supported for sectioning: distortion partly due to shrinkage.

A glance through the many sections of sclerotic arteries with which this presentation is illustrated will serve to demonstrate that the artery which was filled to capacity with a solid supporting medium before sectioning had a lumen

which was usually nearly circular, sometimes oval, occasionally flattened on one or more sides. Hardly ever did the thickened intima bulge into the lumen to produce a convexity of the lining, as viewed from the luminal cavity, although this appearance was occasionally encountered (e.g., 21 ADA 1:6b). It may of course be argued that an approximately circular outline of the lumen will inevitably result if the pressure at which it is distended be sufficiently high. (Winternitz et al., 1938, have applied as much as 2500 mm.Hg. to the carotid artery of the dog and 1000 mm.Hg. to the coronary arteries of man - without rupture.) The pressure used in this investigation was 150 mm.Hg., at which it might be expected that the physiological pressure conditions were mimicked, or at any rate not grossly exceeded. (The effect of muscle coat tonus could not of course be taken into consideration.)

It may be seen in most of the micro-sections, in which the arrangement of fibrous strands in the intima can be made out, that the fibres appear "comfortably" stretched as was probably their state in life. This applied to "collagenous" and elastic fibres alike. Indeed the course taken by the fibres of the sclerotic tissue was always concentrically round the lumen, at any rate as it had existed at the time of their formation - presumably in response to the lines of stress existing during life. I was inclined to regard serpentine formation of these fibres, or of the internal elastic lamina (as seen in the cross section), as an index of insufficient distension of the artery - i.e., of failure to stretch the tissues to the degree that was normal for the artery in question. It will also be appreciated that measurement of thickness of wall and diameter of lumen will differ substantially in the stretched and unstretched state.

Sections stained with haematoxylin and eosin were specially useful for general appearances and for cytological detail. Certain features of the architecture of atherosclerotic lesions were however much more strikingly demonstrated by other methods. Frozen sections, unstained, viewed by ordinary or by polarised light, or stained for fat, were particularly informative in this connection, and even the 2 mm. mounted sections often showed the crude micro-anatomical structure of the plaques more clearly than did the H. and E. sections.



⊙

Sch. R

Fibrous tissue

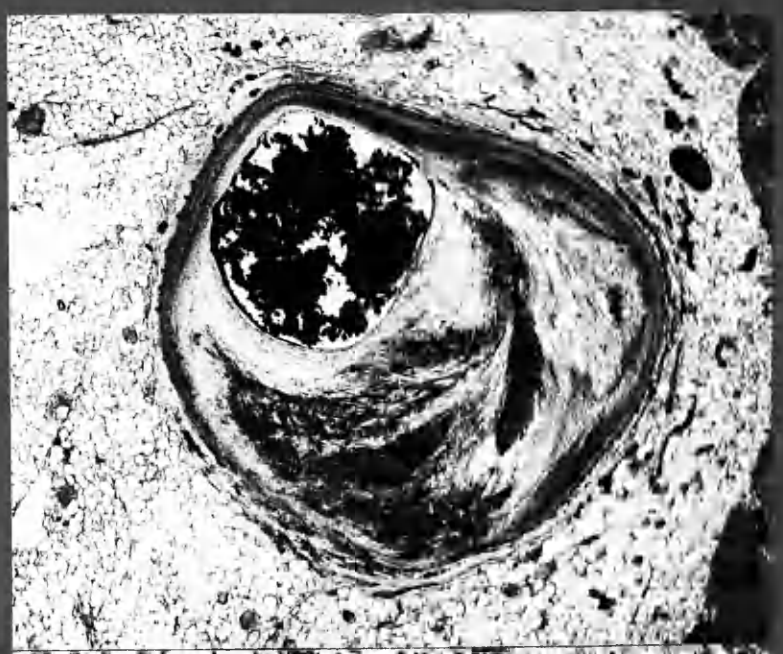
Polyp.

Cholesterol

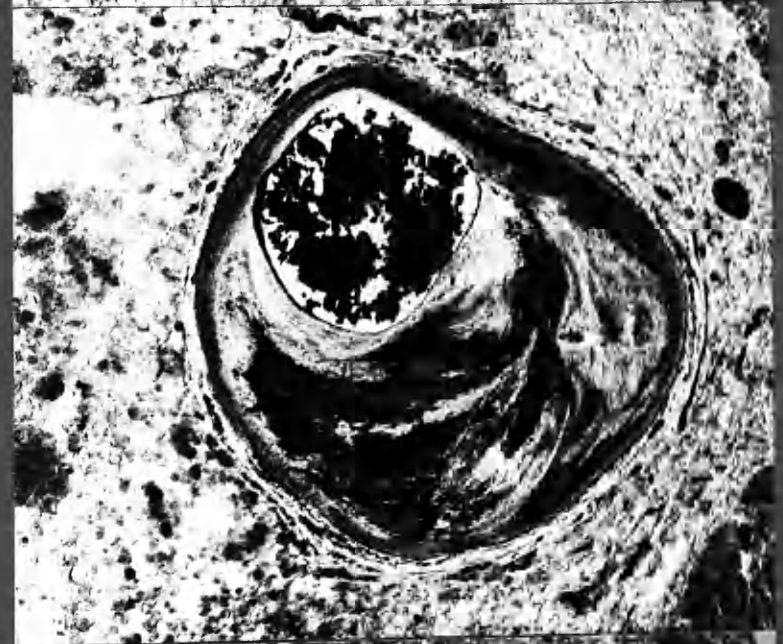x20




Ø



Sch. R



POLA.

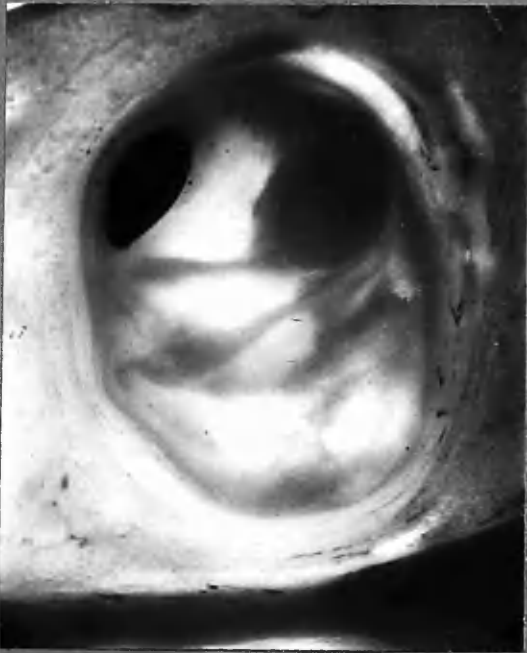

K20

8:10a


24 ADA 3:6a.

18 ADA 2:9b.



x14

24 ADA 3:6a. Compound atherosclerotic plaque formation in at least 4 crescentic layers, leaving eccentrically placed lumen in contact with nearly normal wall.



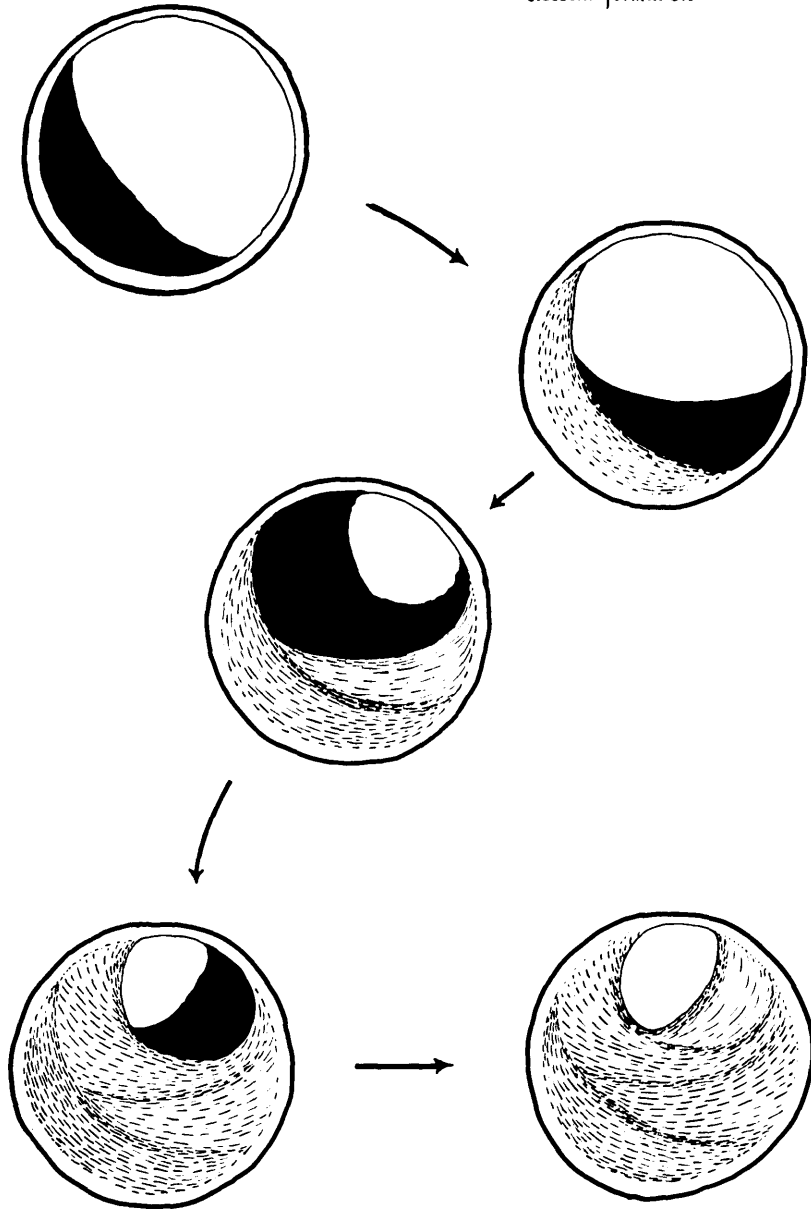
x11

18 ADA 2:9 b. Recent crescentic layer of thrombus.

DIAGRAM 8:2

EVOLUTION OF THE COMPOUND ATHEROSCLEROTIC PLAQUE

through successive episodes of thrombus and fibrous  
crescent formation.



WFMF

### Crescentic Layers

An example is shown in 19 ADA 2:6 micro. in which the appearances suggest that the plaque had been formed in several layers. These layers, as they appeal to my eye, are indicated on the transparent sheet. Other examples are shown, <sup>1,2,3,4</sup> and many more examples may be picked out, each with its own variant on the same theme. Some showed one, some two, some three or more such layers. In each case the layers had evidently been laid down in the form of crescents, the tapering extremities of the crescents merging in concentric fashion into the intimal wall.

These appearances were suggestive but not, by themselves, proof of anything. The more the eye sought for a crescentic formation in the structure of the atheroma the more often could crescents be discerned. Even the most compound appearance could often be broken down by the eye into basic crescentic components. The one crescent was overlaid upon the other, each encroaching further upon the lumen, each having a concavity facing inwards. There were exceptions but this was the general formation as it seemed to me.

When I looked at a section such as the first one (19 ADA 2:6 micro), and particularly if I followed the pattern of crescentic formation up and down the artery as seen in the mounted thick sections, I could imagine some unseen hand within the lumen of the artery applying lumps of soft material to its wall, which it smoothed out to the edges, as a mason may apply cement to the lining of a chimney; but with this difference that the material was applied here and there, and again at long intervals of time, the one layer overlying the other and yet preserving its identity. Almost always, and this may be important, the surface presented to the lumen was smoothed off and was concave or flat, so that the lumen remained approximately round.

---

(1) 18 ADA 1:8 micro.

(2) 14 ADA 3:16 stereo and colour transparency.

(3) 14 ADA 2:6b and 3:9b.

(4) 24 ADA 3:6a.



When examining an artery at a point where it was the seat of mural thrombus, such that the lumen was encroached upon but not obliterated,<sup>1,2,3,4,5</sup> it was seen that mural thrombus could also take up a crescentic form very similar in gross appearance to the crescents observed in atherosclerotic plaques. Perhaps this was just a chance resemblance; or could it have been that, in the processes which led to the assimilation of thrombus into the intimal wall, the original formation of the thrombus set the mould or scaffolding upon which this change took place? The nature of the change will be considered later. The more one looks at the evidence with this possibility in mind the more probable it becomes. But before such a view could be acceptable, intermediate, transitional forms must be demonstrated. (See diag.8: 2)

A few examples:-

(1) Sections 15 ADA 3:2 micro. were taken from an artery in which thrombosis had taken place in two stages within recent date. The older of these formed a crescent filling nearly half the lumen at a time when the lumen was about one-third of its original diameter. It features in the H. and E. and frozen sections. In the frozen sections the layer of thrombus of more recent deposition is also seen. Stereoscopic views of the adjacent thick section 3:3a are included. Thrombosis in this case probably took place some 4 weeks before death. The transition from thrombus to underlying collagenous tissue was abrupt and no endothelial lining separated the two. Merging of fibrinous material into the meshes of the collagenous fibres was seen only on a very small scale (save at one side where the appearances suggested haemorrhage into the intima perhaps at the time of thrombosis). The inanimate fibrin of the thrombus already showed some orientation into concentric fibrillary layers.

(2) In 14 ADA 2:1 micro., a crescentic, almost semicircular clot occupied about half the lumen. It was thought to be about 19 days in age and was covered by endothelium. At its base the thrombus merged with the underlying intima, but the transition was, as in the previous example, fairly abrupt.

(3) In 20 ADA 3:3 micro. series, a crescent of tissue is seen to underlie complete occlusion by recent thrombosis. The gross appearances are very similar to those seen in 20 ADA 3:4b (colour transparency) and in 20 ADA 3:2b.

(4) In 9 RC micro.1, recent occlusion of a much narrowed lumen is seen. Surrounding the recent thrombus was a crescent of tissue which stained as for collagen. At its peripheral margins (A-A) the "collagenous" fibres did not blend with those of the underlying intimal thickening, although at its base, where it rested on the underlying tissue at one side, no clear demarcation could be distinguished. At the other side, a zone of small scale vessels interposed

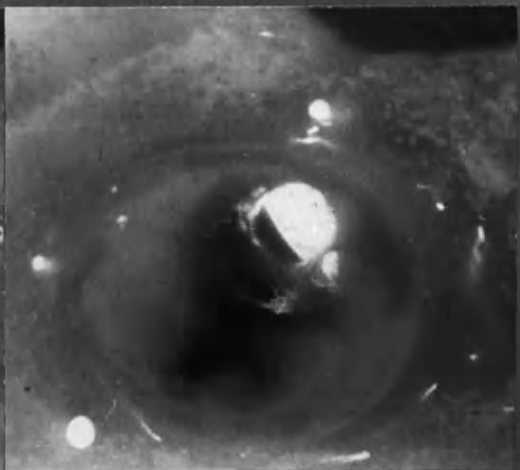
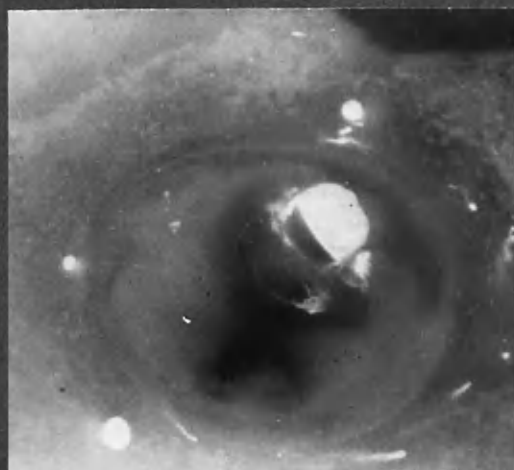
---

(1) 16 ADA 3:4a or 2:3a.  
(2) 16 ADA 3:1 micro.

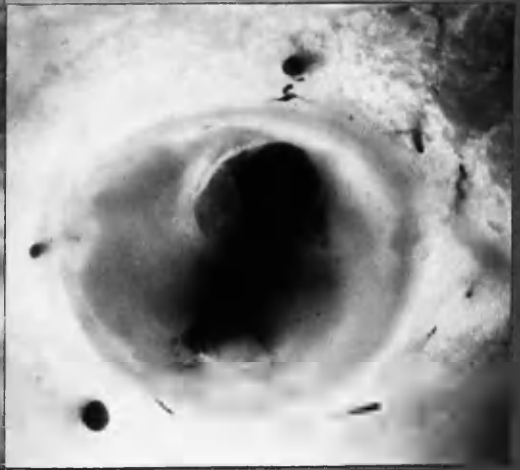
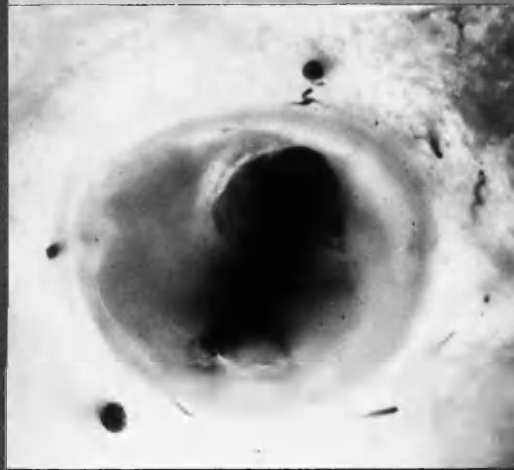
(3) 15 ADA 3:3a or 3:2 micro.  
(4) 14 ADA 2:1 micro.  
(5) 7 ADA.

STEREO-PAIRS.

Incident light

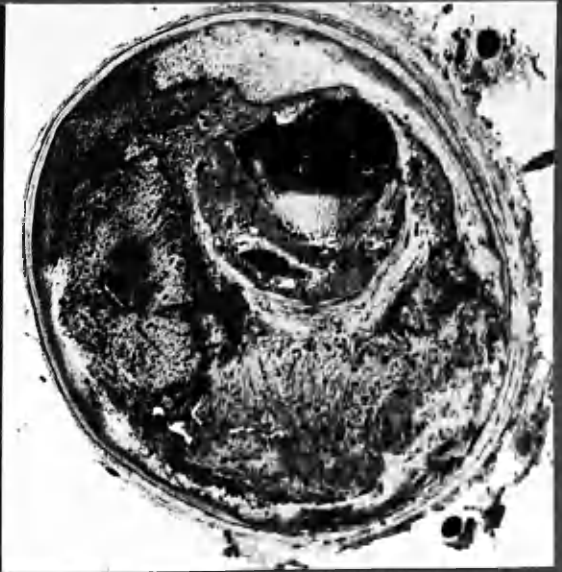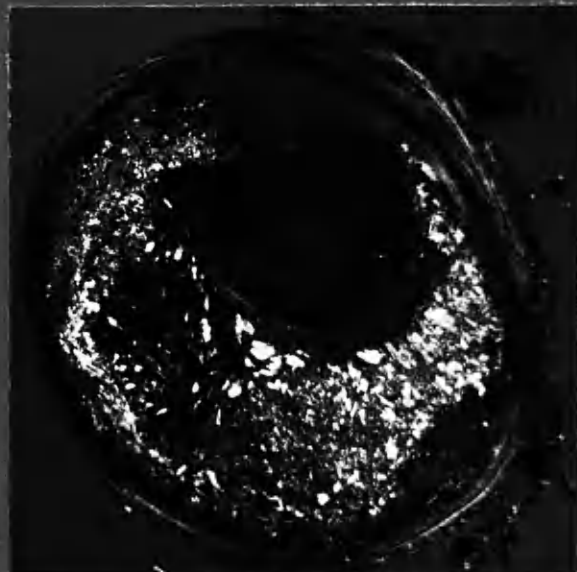


Transmitted light



x10

FROZEN SECTIONS.



x16

POLA.

φ

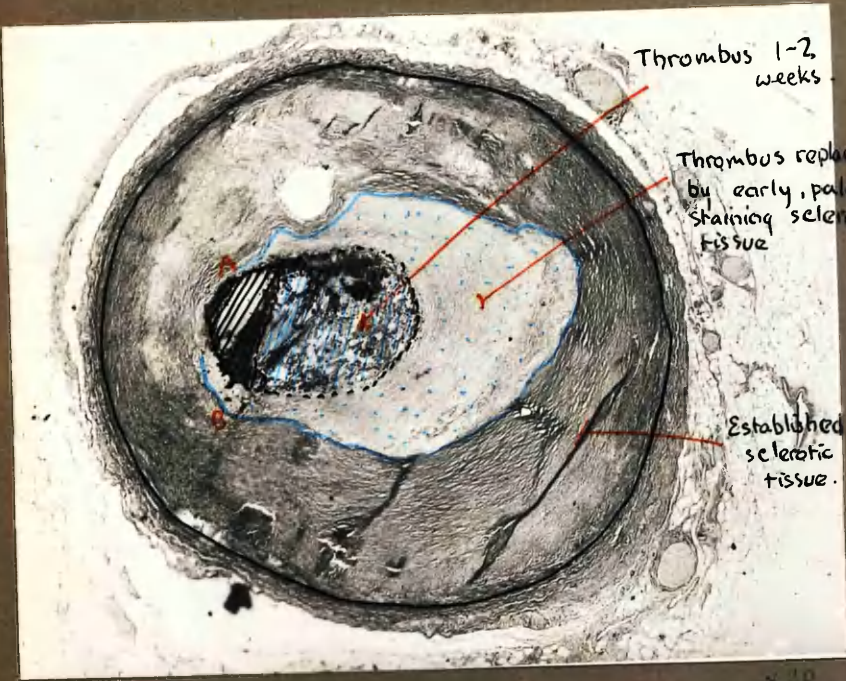
3:2 micro

Thrombus in 2 layers partially occluding the lumen. Haemorrhage into the substance of underlying atheroma.

H. & E. sections included in main group between Chapters 7 & 8



9 RC (1)  
10 ADA (1)



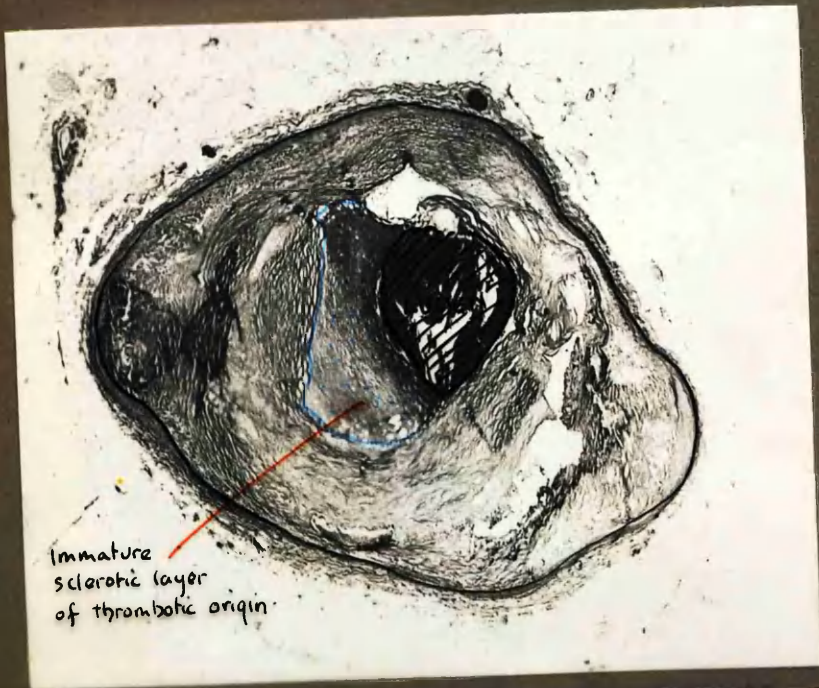
Thrombus 1-2 weeks

Thrombus replaced by early, pale-staining sclerotic tissue

Established sclerotic tissue.

9 RC (1) V. van G

x 10

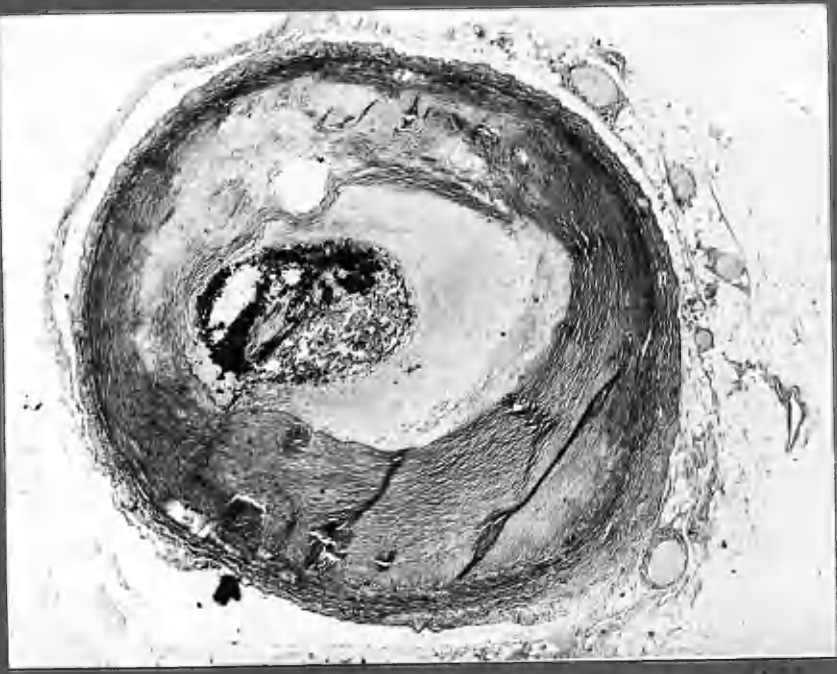


Immature sclerotic layer of thrombotic origin.

10 ADA V. van G

x 20

9 RC (1)  
10 ADA (1)

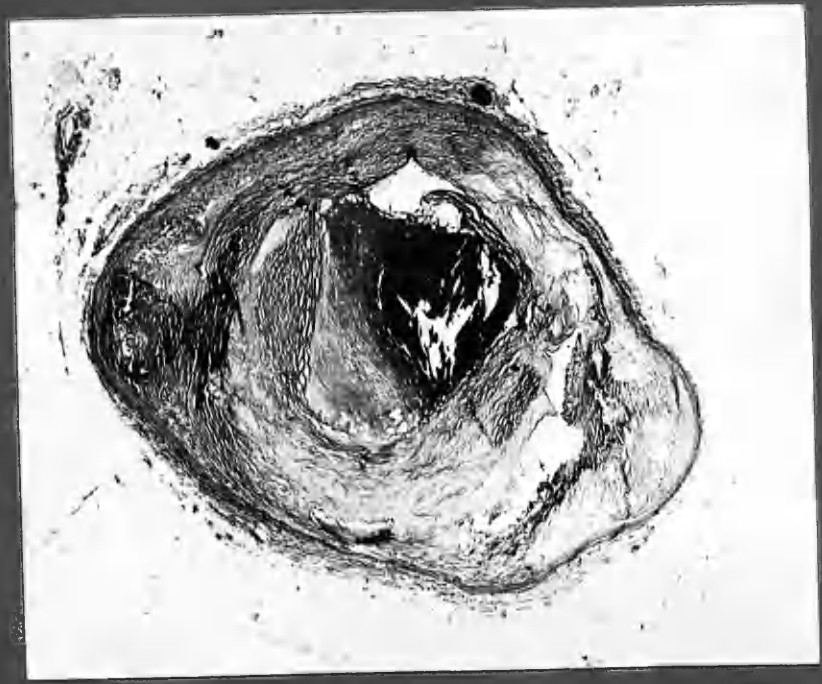
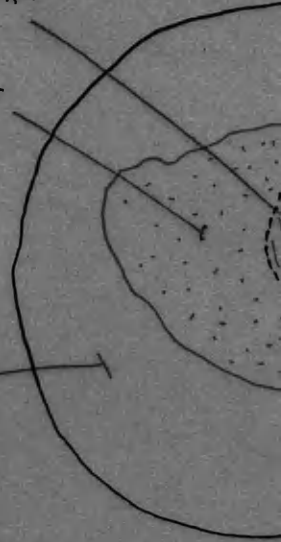
9 RC (1) V. van G.

Thrombus 1-5 weeks

Thrombus retracted  
- old, pale staining  
- tissue

Established  
- tissue



10 ADA V. van G.



themselves between the crescent and the tissue against which it lay (B). This section may be compared with section 3 ADA micro. 1.

(5) Very similar appearances were seen in section 10 ADA micro. 1.

It would be hard to imagine that crescents of tissue (as in the last three examples above) had their origin other than in the organisation of material superimposed on the intima from the lumen of the artery. It is not easy to conceive of deposition or other change within the substance of the intima adopting this configuration. The question of conversion of thrombus into sclerotic material therefore demanded close examination. The process in its earliest stages was looked for in the junctional zone between the crescents of collagen-like material and the recently developed thrombus.

In this pathological investigation, many examples of recent thrombosis were found. The opportunity was also taken to examine many examples of old-standing established atherosclerotic lesions. Transitional appearances showing intermediate stages in the organisation of thrombus were fewer. This was not altogether surprising. It has been noted in Chapter 7, and will be further considered in this chapter, that the process of assimilation of the clot into the intimal wall evidently began only after a few weeks had elapsed and was completed in the course of several months, in the case of a crescentic, mural thrombus. Generally speaking, subjects dying as the result of coronary occlusion tend to die within a few weeks of the deposition of thrombus; in which case the changes seen by the pathologist are very early. Those which survive the acute incident on the other hand tend to continue in life until a further occlusive incident, which is commonly delayed for several months and often years. By this time the transitional changes in the assimilation of thrombus into arterial intima may well have been completed. The pathologist's opportunities of observing the intermediate stages therefore are fewer than is the case with old-standing change or mural thrombus which has been part of a recently fatal thrombotic episode.



In the available cases in this series (5,7,9,11,12,13,14,20,21,22,24) which showed recent thrombosis of assessable age, relatively little change was found in the mural portions of thrombus in the course of several weeks (approximately 3). The time-relations of changes in isolated mural thrombi of similar or longer standing could usually only be guessed, or derived from somewhat unsubstantial clinical evidence. This was presumably because deposition of mural thrombus of insufficient size to cause severe narrowing or complete occlusion of a coronary artery could well have passed unnoticed clinically. My impression - and it must in this connection remain but an impression - is that thrombus which occupied about half the lumen of a coronary artery was converted into tissue that would ordinarily be described as atherosclerotic in the course of some 6 months; but I should not like to be committed to this figure at present. In any case, the rate and nature of the changes seemed to depend much upon the composition of the thrombus, its bulk, whether it was seated on thin, nearly normal intima or upon established atherosclerotic tissue, the degree of occlusion caused by it and the formation of intimal vessels.

#### Concentric Layers

The crescentic formation of atherosclerotic plaques has been mentioned first in order to stress this feature, which I believe has much significance. It was moreover common. Not in every case however could the structure of the plaque be so analysed. In a number of instances it seemed that intimal thickening had occurred, not in eccentric crescents, but in concentric layers which entirely surrounded the lumen, although the layers were commonly thicker at one side than the other.<sup>1,2,3,4</sup> Sometimes concentric rings were compounded of crescentic formations;<sup>5</sup> and sometimes crescentic and concentric rings were combined.<sup>6,7</sup>

---

(1) 19 RC 1:7 micro.

(2) 18 ADA 3:1.

(3) 17 RC 2:1 and 3:8.

(4) 25 LCxA 2:6a.

(5) 20 RC 1:4b and 1:5 micro.

(6) 19 RC 1:7 micro.

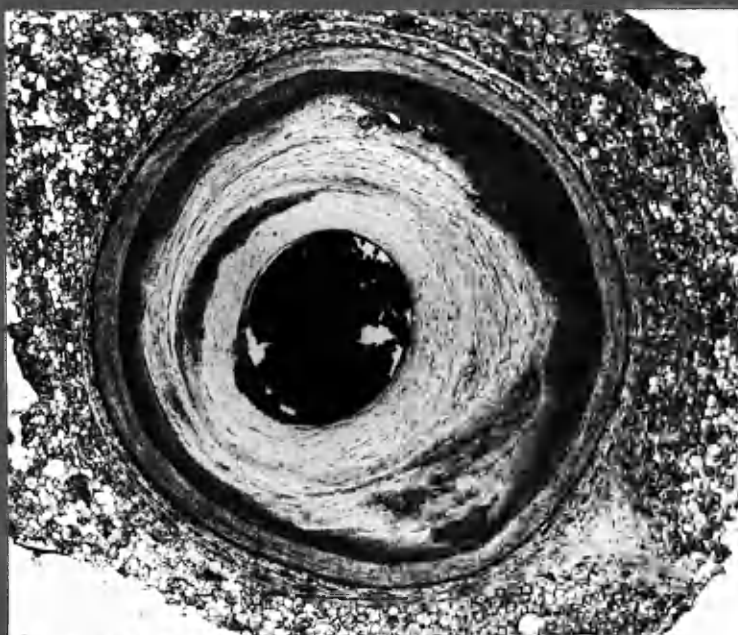
(7) 17 RC 2:2.

-8:14 a

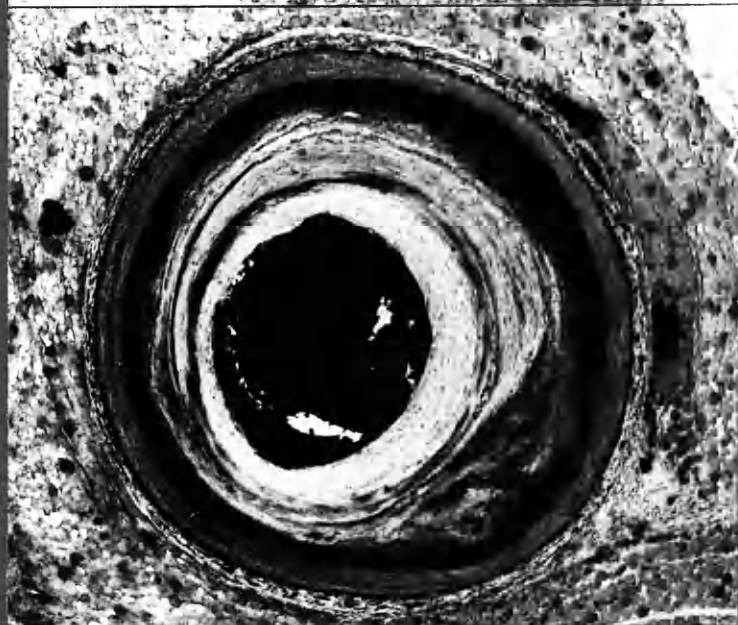
19 RC  
117

CONCENTRIC LAYERS.

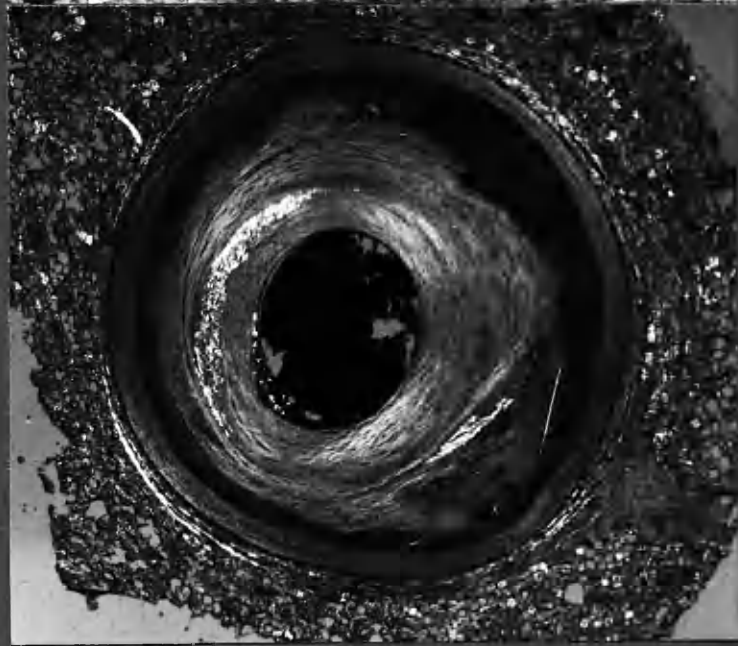
Ø



Sch. R



POLA



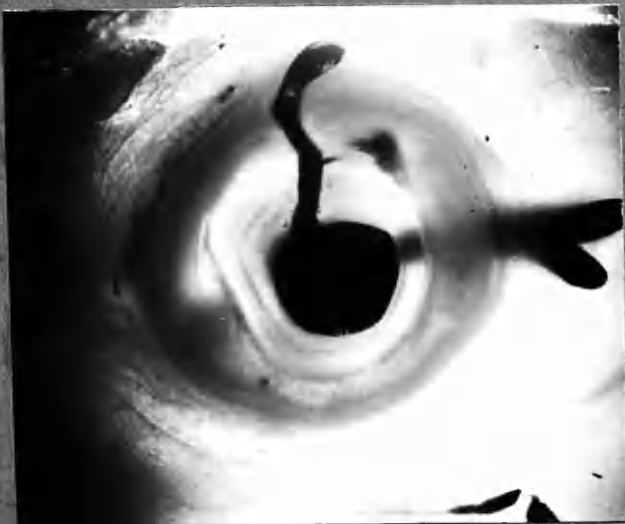(See 2mm thick section  
over leaf.)

x20

19 RC 1:6b.

19 RC 1:6b.

Concentric layers. Small vessel arising from branch directed towards small area of haemorrhage.

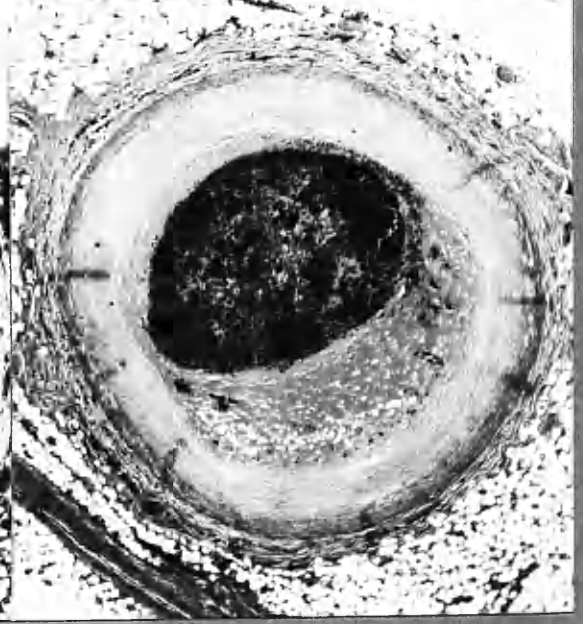
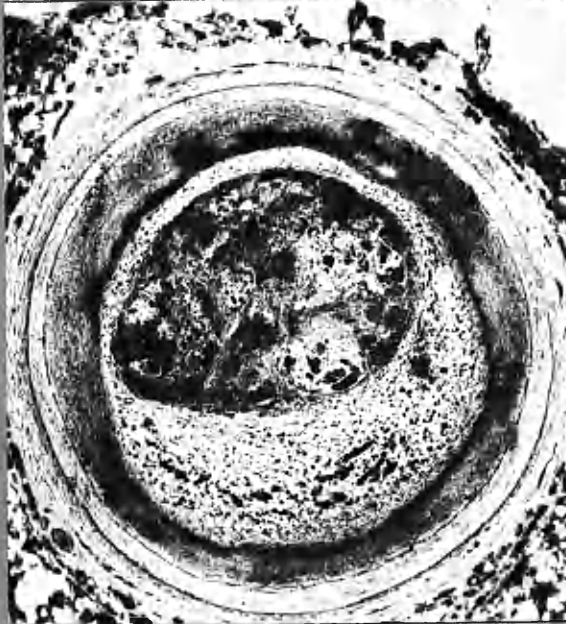
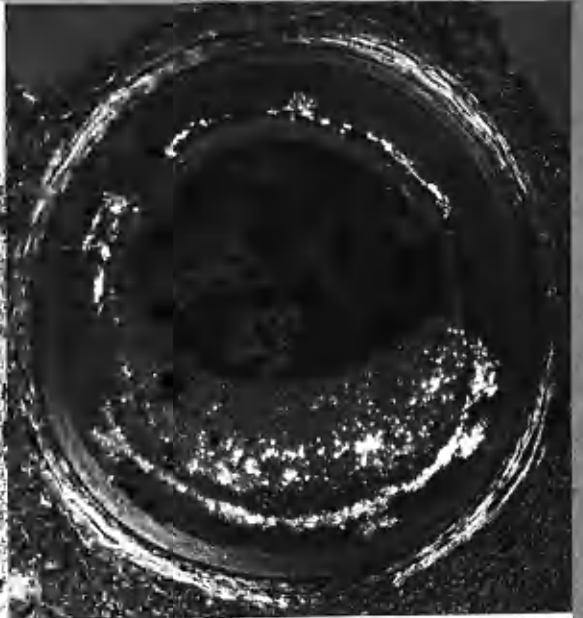
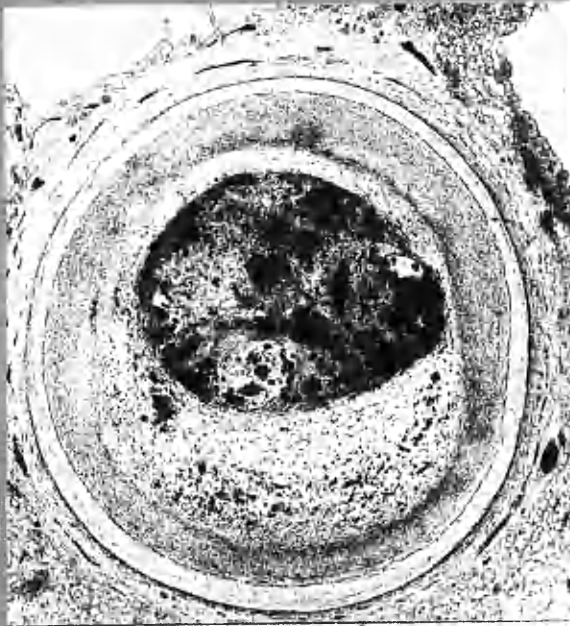


(See micro. on preceding page.)



CONCENTRIC INTIMAL THICKENING WITH TWO SUBSEQUENT THROMBOTIC EPISODES.

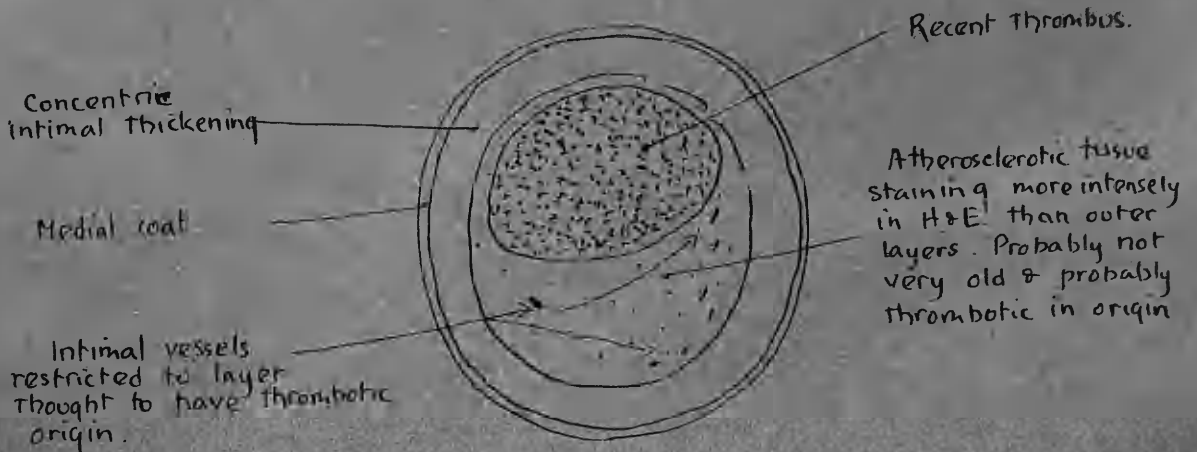
20 ADA  
3.3 micro



Ø  
Scharlack R

POLA  
H&E.

x18



I see no absolute reason why fibrin should not be deposited in a layer round the entire circumference of the lumen in the same fashion as thrombus occupies a sector of the lumen in crescentic form. I have however no convincing example of such a phenomenon in its early stages. Moreover, concentric thickening of the intimal wall would seem to be more in keeping with deposition of material within the intima, or with primary tissue growth, than with the incorporation of surface thrombus into its substance.

Indeed the majority of atherosclerotic lesions showed concentric thickening of the intima as a primary change which underlay subsequent more localised plaque formation internal to it. Examples are seen in 20 ADA 3:3 micro. and many others. Intimal thickening of this order was however not found in every case. In several eccentric massive atheromatous lesions the intima on the side opposite to the lesion was nearly normal in thickness (e.g., 19 ADA 2:6 micro.)

The genesis of primary concentric intimal thickening is obscure. At this point it may be noted that the tissue of which it was composed in no fundamental way differed histologically from tissue apparently formed by organisation of fibrin thrombus, when this had occurred in shallow crescents; and that it was only after considerable thickening had taken place that fatty material was also found in the specimens that I have examined from human coronary artery disease. I am aware that this differs from the situation described in experimentally induced intimal lipid deposition in the aorta of small lower animals (Hueper, 1956; Katz and Stamler, 1953). I do not think that it is clear whether primary increase in the thickness of the human arterial intima, as the result of tissue growth, takes place with aging, or in response to mechanical stress; or whether some constituent of the blood serum is gradually deposited within the substance of the intima and converted into collagen-like material; or whether the same appearances are reached through

recurrent episodes of surface fibrin deposition and its subsequent incorporation into the intima, in the fashion described for crescentic lesions.

I think that in the case of the primary concentric intimal thickening one of the former possibilities is the more likely. These matters will receive further consideration in this chapter. At this juncture I would like to suggest (that intramural fibrin deposition be not discounted among the possible processes leading to primary intimal thickening; and assimilation of fibrin thrombus on the luminal surface of the intima be given a high place in the genesis of crescentic atherosclerotic plaques. In this way the same hypothesis in slightly modified form may be used to explain the basic formation of "early" and of "advanced" atherosclerotic lesions. A comprehensive hypothesis must also explain the occurrence of lipid deposition and intimal vessel formation, and these matters will be dealt with in greater detail later. This simplified hypothesis for the genesis of atherosclerotic lesions in general will be tested against the evidence of this investigation. It may well be that two or more fundamental processes will have to be acknowledged in this complex disease.

... was usually fibrous and contained little lipid. ...  
... (10 to 17 microns, pale). ... at the base of it  
... with the underlying ... fibrous ...

There are further points to be considered in the crude structure of the atherosclerotic plaque. Initially I have stressed the manner in which the arrangements of collagenous fibres and other general appearances allowed the eye of the observer to break down the structure of these lesions into crescentic (components or into concentric layers. The more one looked at such lesions (suitably prepared) with this interpretation in mind, the more often it seemed to fit the picture. I do not think that this was an illusion, nor a product of the imagination. Like following tracks in sand, practice and knowing what to look for take the eye much of the way to seeing. None the less, it is desirable to have other, and more objective, means of breaking the lesion into its component layers and crescents. Some observations on other aspects of the crude structure of atherosclerotic plaques are now considered.

Lipid material was readily demonstrated in frozen sections. An abundance of doubly-refractile cholesterol often presented pictures of striking beauty when seen by polarised light. The quantity of lipid in these lesions varied greatly and at first glance the disposition of it seemed haphazard. But this was not so. In most cases the distribution of lipid followed a pattern based upon the layers and crescents already noted. Characteristically the fatty material was found in the deeper layers of each layer or crescent. Close to the luminal surface as existed at death, or where the luminal surface was thought to have been before it was overlaid by a more recent layer, the tissue was usually fibrous and contained little lipid. Exceptions occurred (e.g., 19 RC 1:7 micro. pola.). Similarly at the base of the layer or crescent in contact with the underlying intima, fibrous material predominated. In the deep or central portions lipid material abounded. If in large quantity lipid was usually embedded in amorphous material which shared some staining properties with fibrin and did not stain like collagen. In a large

"atheromatous abscess" the bulk of the lesion was formed of this pultaceous fatty material containing cholesterol crystals.<sup>1,2</sup> In more fibrous lesions pockets of this material were enmeshed in collagenous fibres.<sup>3,4,5</sup> (See also Diagram 8:3)\*

Lipid material therefore also followed the configuration already noted, usually somewhat internal to the junction of the one layer with the next.

The distribution of intimal vessels also conformed to the general pattern. In the chapter on canalisation it was demonstrated how new vessel formation seemed to take place mainly between thrombus and intimal wall (e.g., 24 RC 2:6 micro.). The same appeared to hold true for mural thrombus. Characteristically intimal vessels were found in the deepest portions of each layer or crescent, when they were found at all. Had they grown into atherosclerotic plaque in this fashion merely to misdirect the imagination of the histologist? Or had they developed in this position as part of the process of assimilation of thrombus into the intimal wall? I believe that the latter is nearer to the truth, and that their location in the junctional zone between two layers or in the depths of a crescentic formation was closely related to the development of the atherosclerotic plaque from thrombus. In this way the distribution of intimal vessels was not without significance, and gave support to the concept suggested by other features.\*

Intimal vessels were not always easily demonstrated in low power microphotographs; and were not seen in the thick mounted sections unless the injection medium had entered them or they were charged with blood. On the other hand small intimal haemorrhages from these vessels were of not infrequent occurrence. In favourable circumstances dissection of the atherosclerotic plaque had evidently occurred without undue disruption of the structure as a whole.<sup>6,7,8,9,10,11</sup>

- |                       |                      |                       |
|-----------------------|----------------------|-----------------------|
| (1) 15 ADA 3:2 micro. | (5) 19 RC 1:7 micro. | (9) 18 ADA 1:8 micro. |
| (2) 7 ADA micro.(2)   | (6) 17 RC 3:8.       | (10) 19 RC 1:6b.      |
| (3) 14 RC 5:1 micro.  | (7) 17 ADA 3:4.      | (11) 11 ADA "F" 1:3.  |
| (4) 14 ADA 2:4 micro. | (8) 18 ADA 1:7.      |                       |

\* p. 8:42a.

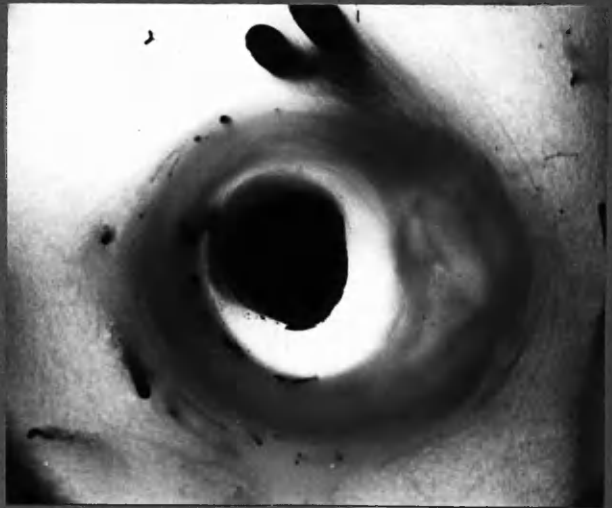\* see 19 RC 2:10b and 25 RC 5:9 a, overleaf.

8:18a


INTIMAL VESSELS BETWEEN LAYERS

19 RC  
2:10b  
25 RC  
5:9a  
15 ADA  
3:5b  
7 ADA

19 RC  
2:10b.

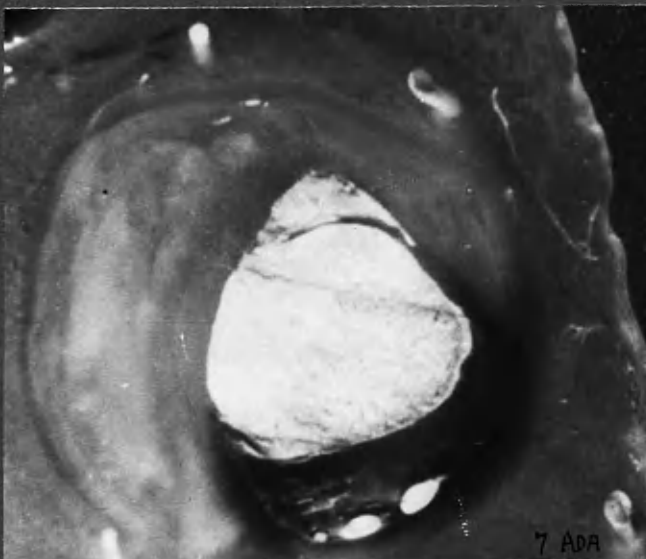


x15



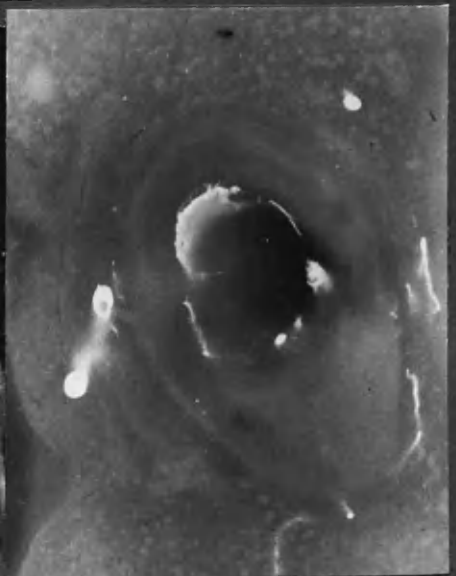
25 RC  
5:9a.

x18



x 15

7 ADA



x15

7 ADA

15 ADA 3:5b.


Primitive channels characteristically develop between thrombus and underlying artery wall, as shown in complete occlusion (15ADA) and mural thrombosis (7ADA). Their persistence at this site after conversion of clot to fibrous material is characteristic.



- 8:18b -

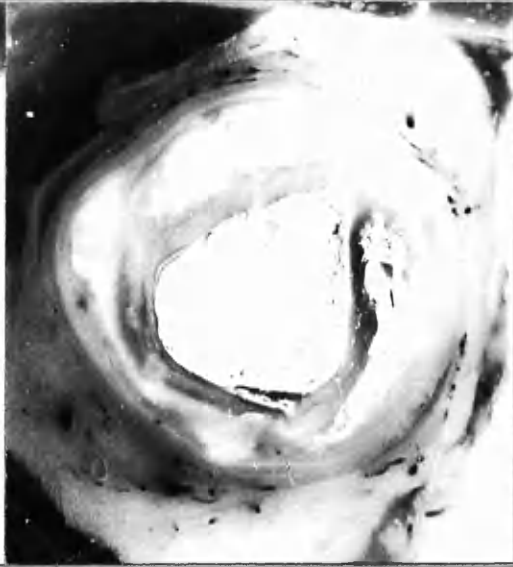
DISRUPTION OF PLAQUE BY INJECTION MEDIUM

18 RC  
21 ADA



x9

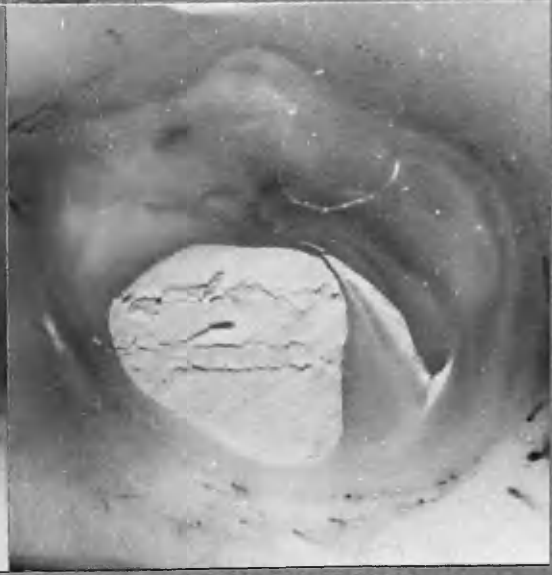
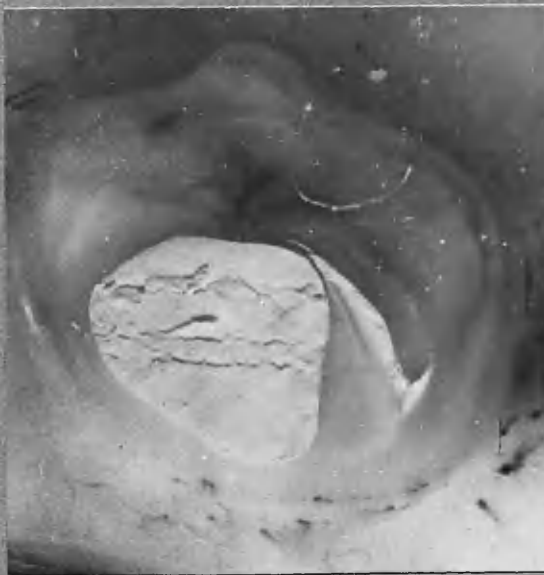
18 RC



x9

3:10 b.

3:12b.



21 ADA 1:10 b.

STEREO-PAIR.

x14

It was seen in most haemorrhages of small size that the track taken by the blood was usually concentric, following - and thereby demonstrating - lines of cleavage between the layers or crescents. Rupture of a vessel into the structureless pultaceous material of an atheromatous "abscess" could however spread in any direction.<sup>1,2,3,4.</sup>

Not infrequently injection medium followed the track of intimal haemorrhage and in some cases appeared to have increased the dissection of the intima which was begun in life. Examples of this phenomenon are shown.<sup>5,6,7.</sup>

On the other hand, haemorrhage not infrequently distorted as much as it revealed. For instance in 18 LCxA 1:4b (colour transparency) rupture of considerable size can be seen carrying blood and injection medium in a fashion which does not correspond to concentric layering - nor to intimal vessel formation. This is a haemorrhage into an atheromatous abscess and can readily be recognised as such at this stage. Organisation of material introduced in this fashion however might in the course of time lead to a bizarre configuration of structure in this plaque which could not then be interpreted in terms of concentrically laid down crescents and layers. Was, for instance, this the manner in which the appearances in 18 ADA 2:3 micro were reached, or the radially directed structures in 2 RC micro.(1) or 22 ADA 3:1a (colour transparency)?

Thus it was seen that the anatomising of atherosclerotic plaques into concentric layers by the eye of the observer was supported by the distribution of lipid, intimal vessels and intimal haemorrhage. Under certain circumstances the track taken by extravasated blood and for injection medium in the substance of the intimal plaque afforded evidence of lines of cleavage which corresponded to the crescented formations already noted - and to their origins in superimposed layers of thrombus.

- 
- |  |   |
|--|---|
| (1) 15 ADA 3:3a.                       | (4) 7 ADA micro (2).                          |
| (2) 18 LCxA 1:4b. colour transparency. | (5) 17 RC 2:3                                 |
| (3) 18 LCxA 1:5 micro.                 | (6) 18 RC 3:10 and 3:12                       |
|  | (7) 21 ADA 1:10 b. stereo. (on previous page) |



CHANGES AT THE INTERFACE BETWEEN THROMBUS AND  
UNDERLYING INTIMA

Essential to the concept of atherogenesis from thrombus is the demonstration that collagenous tissue can replace the fibrin structure of thrombus on the intimal surface. The changes that take place at the interface between thrombus and the underlying intima will now be examined more closely.

Scope and Limitations of Observations

It has already been remarked that the opportunities of examining examples of transitional stages between mural thrombus and mural atherosclerotic plaques were somewhat scanty in the histological specimens of this series. Again, blocks for micro-section were for the most part selected from regions of arterial occlusion for therein lay the main interest in this investigation. Relatively few were taken from less severely affected portions of the arteries unless some special feature directed attention to them. Nevertheless a considerable number of random sections of atherosclerotic lesions of slight and moderate severity were included.

The occlusive lesions showed transitional stages essentially similar to those found in mural thrombus, and at the same time had the advantage in many cases of being of known age as judged from the corresponding clinical episodes and myocardial damage. Moreover the changes in complete occlusions were delayed in the central - as opposed to the end - portions of a segment of artery obliterated by thrombus. In this way, depending upon the level at which the section was taken, several stages might be represented in the one occlusion and a suitable example selected for demonstration. Examination was also made of thrombi at various sites within other arteries and the heart chambers.

The situation in the coronary arteries themselves will not be considered first, because the interpretation of the appearances in these relatively small

arteries was hindered by several factors. In them the background to thrombosis was usually complex. As a result, when transitional stages in the assimilation of thrombus into the vessel wall were examined, it was a matter of judgement rather than precision to determine where the previous intima ended and changes that had already taken place in the base of **the** thrombus began. The picture was often further complicated by fresh episodes of thrombosis or of haemorrhage. (Moreover, it could not be concluded that changes in the underlying intimal thickening, such as cellular infiltration or intimal vessel formation, were necessarily the result of the thrombotic episode in question; nor that they were its cause. Often they might equally have been related to a previous episode. Many changes taking place concurrently within the confines of a short segment of coronary artery served therefore to confuse the picture and make interpretations of the findings more difficult and less secure.

#### Observations on Thrombi Outwith the Coronary Arteries

Accordingly I turned to thrombi in other intravascular sites, where the changes were presented on a larger scale and where a base-line of previously normal, or nearly normal, structures could be assumed.

Quantitatively a difference was found in the changes depending upon the mass and site of thrombus. Qualitatively however the changes that occurred in all thrombi seated on an endothelial or intimal surface seemed to be similar. Examination will first be made of examples of thrombi of larger size in order to demonstrate the transition from fibrinous material to collagenous tissue, and then attention will be directed to the situation in thrombi of smaller scale.

Repeated examples of mural thrombus of the aorta were lost for convincing demonstration through stripping of the thrombus and endothelium during processing with loss of the essential portions. I think that technical difficulty was

chiefly occasioned by differential shrinkage of the vessel wall and thrombus. Thrombus in the atria was more easily handled technically.

A photograph has been taken of a portion of thrombus of old standing on the wall of the left atrium in a case of mitral stenosis and coronary artery disease.<sup>1</sup> In order to obtain this section intact, the tissue was first embedded in gelatin. It can be seen that the endocardial lining of the atrium was greatly thickened where it lay under the clot; and that the extent of the thickening corresponded to the extent of the clot. Indeed, the thickening extended somewhat beyond the present limit of recognisably thrombotic material.

I think that there is little doubt that this projecting portion was originally formed from thrombus. When this region was examined under higher power it was seen that a thin rim of collagenous material covered by endothelium had overgrown the clot at its margin, and that there was merging of fibrin and collagen in the immediately underlying portion.<sup>2,3</sup> On following the junctional zone along to the right it was likewise seen that here too there was merging of collagenous tissue and fibrinous material, collagen fibres reaching a short distance into the thrombus. The appearances suggested that there was an advancing zone between thrombus and intima, with gradual replacement of fibrinous material by collagenous fibrous tissue.

It may be argued that the opposite point of view was also tenable, that fibrin had invaded the meshes of fibrous tissue leaving some collagen fibres behind. Conclusions cannot be reached from a single section on this point, but I favour the former interpretation which accounts not only for the appearances at the interface but also for the thickening of the underlying tissue.

(N.B. Care was taken in the cutting of this section that it be at right angles to the atrial wall.)


Thickening of this nature has been observed a number of times in the walls of the atria and the left ventricle exactly underlying old-standing thrombus which was undergoing change. On the other hand recent thrombus in the atria and ventricles was not observed to correspond closely to the distribution of underlying endothelial thickening where present (except in so far as recent thrombus might have formed over an area of old thrombus still in the transitional stage).

- 
- (1) 13 left atrium, thrombus. Frozen section.
  - (2) 13 left atrium, thrombus. Verhoeff and van Gieson.
  - (3) 13 left atrium, thrombus. Weigert's fibrin stain.

8:22a-

# ATRIAL THROMBUS

Case 13.



FROZEN SECTION, STAINED FOR FAT, (Sch-R)

x 5



V. von G.

Collagenous fibres  
on surface and  
in substance of  
(old) thrombus, as  
if advancing into it  
and investing it

(Collagen - blue)

x 35

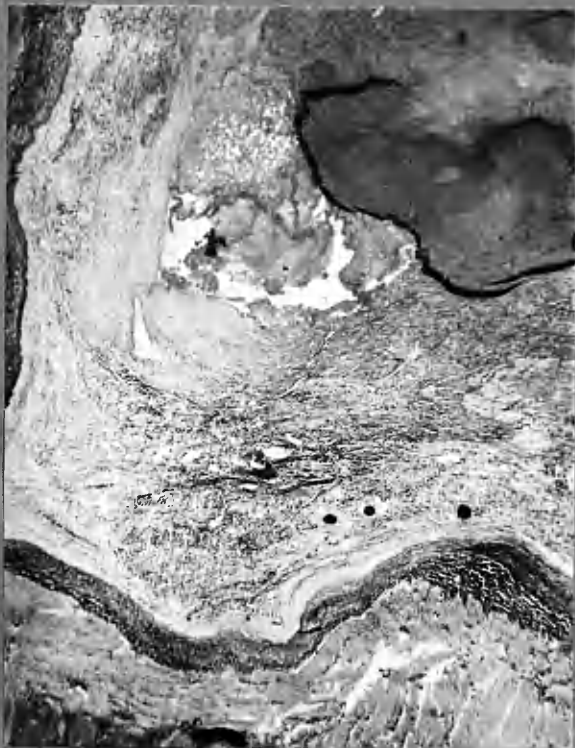


x 30

Collagenous fibres  
in wall of old  
thrombus, as if  
advancing into it  
and investing it  
(Collagen - blue)

D9

ATRIAL THROMBUS.



← fibrin - autolysis.

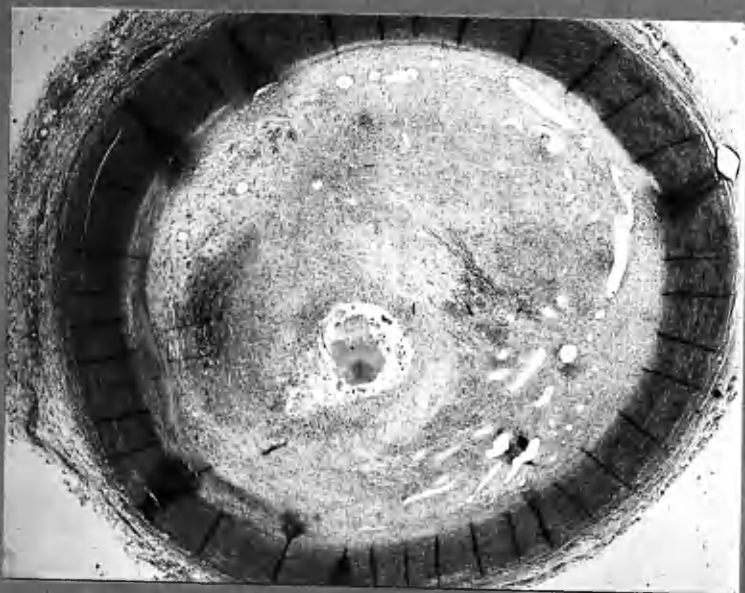
"Fibrinoid"

← "collagen" fibres (black) in depths of old thrombus.

← injected new vessels.

← atrial wall.

x20



P.M. No 297/57

Stobhill Hospital

by courtesy of Dr Rhoda Taylor  
and Dr J.C. Dick.

Lendrum's acid-picro-Mallory.

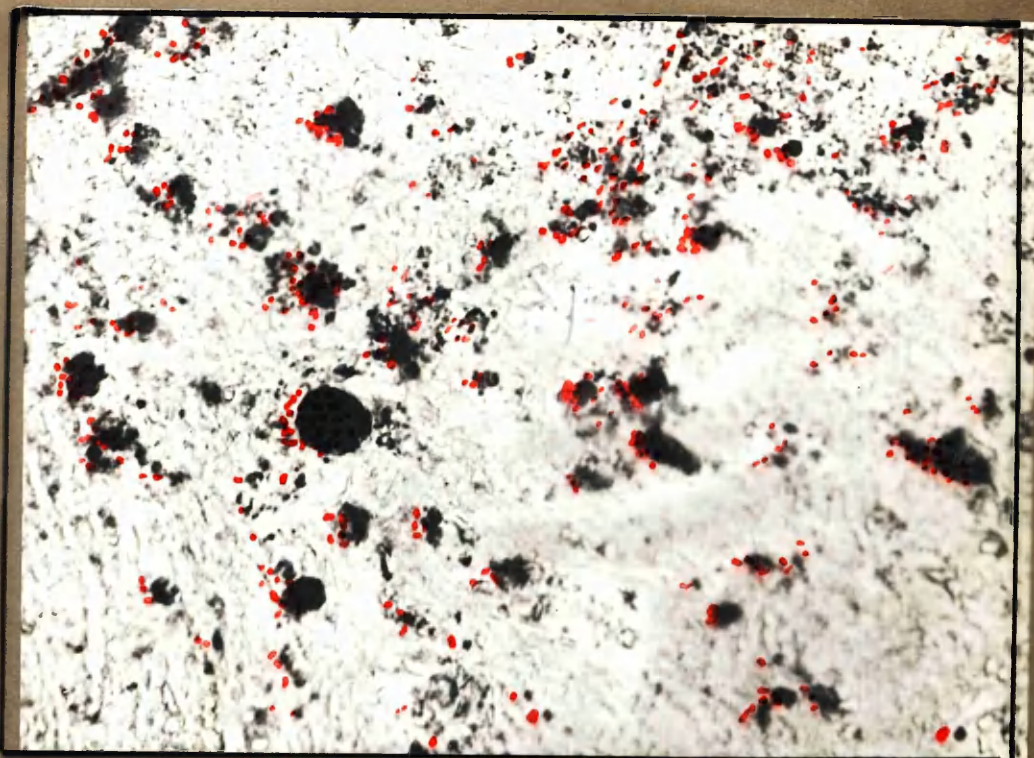
x10

THROMBOTIC OCCLUSION OF SUBCLAVIAN ARTERY, 8 months.

Marked area, opposite.

Central softening. Peripherally placed blood spaces. Thrombus mostly converted into collagenous tissue, a few areas of fibrin and 'fibrinoid' remaining.





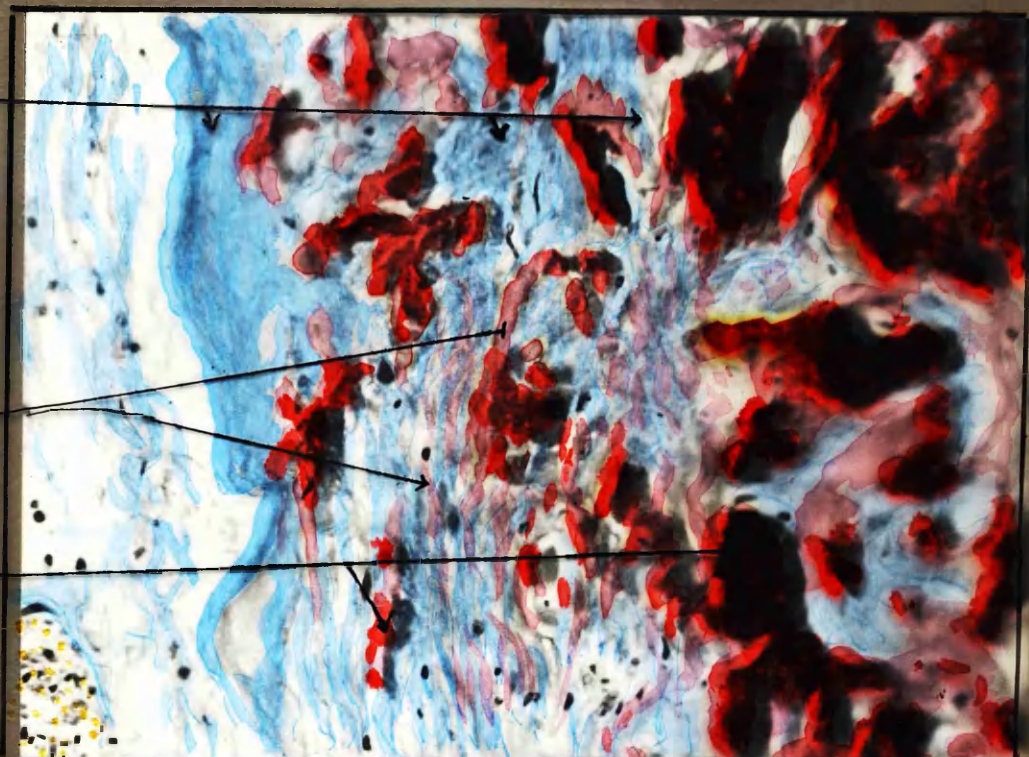
Scharlach R

x 180

Collagen  
Fibres

Intermediate  
staining of  
"fibrinoid"

Fibrin.

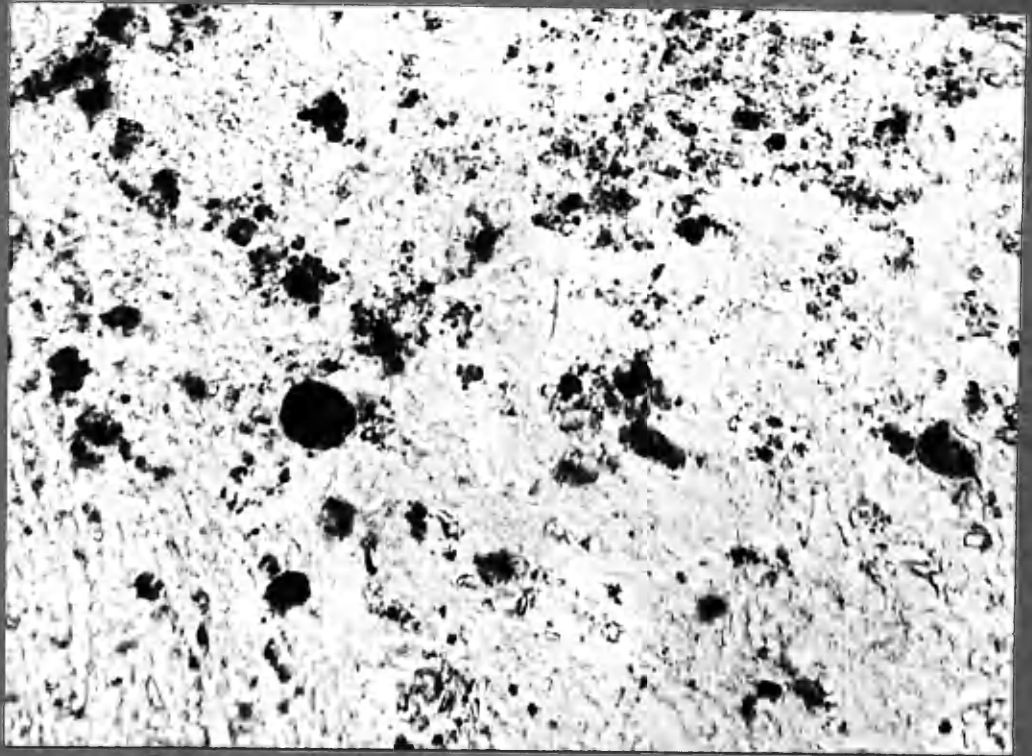


Lendrom's acid Picro-Mallory stain.

SUBCLAVIAN ARTERY, marked area (opposite)


High power of conversion of fibrin to collagen-like fibres, while there is a paucity of cellular activity. The staining merges imperceptibly from red of fibrin to blue of "collagen" (with intermediate staining qualities of fibrinoid) along the course of individual fibrous bands.





Scharlach R

x130



Lendrom's acid Picro-Mallory stain

x280


## SUBCLAVIAN ARTERY, marked area (opposite)

High power of conversion of fibrin to collagen-like fibres, while there is a paucity of cellular activity. The staining merged imperceptibly from red of fibrin to blue of "collagen" (with intermediate staining qualities of fibrinoid) along the course of individual fibrous bands.



14 ADA  
2:4 micro(8)

Lendrum's acid-Picro-Mallory.

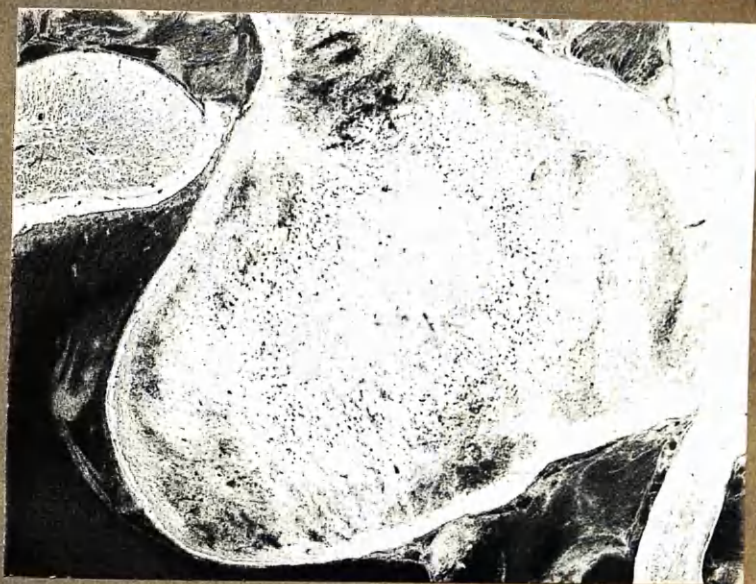

See also 14 ADA 2:4 (1-7)  
mounted between Chapters 7, 8.

X150

Transitional appearances at interface between blood clot and recently formed fibrous tissue. Intimate mingling of fibrinous fibrils and collagen fibres, individual fibres often showing staining with both blue and red as well as intermediate tints consistent with "fibrinoid".  
Newly formed blood vessels are incompletely lined with "collagen", without evidence of continuous endothelium.

Case MHA 5125 - ATRIAL THROMBUS.



Scharlach R.

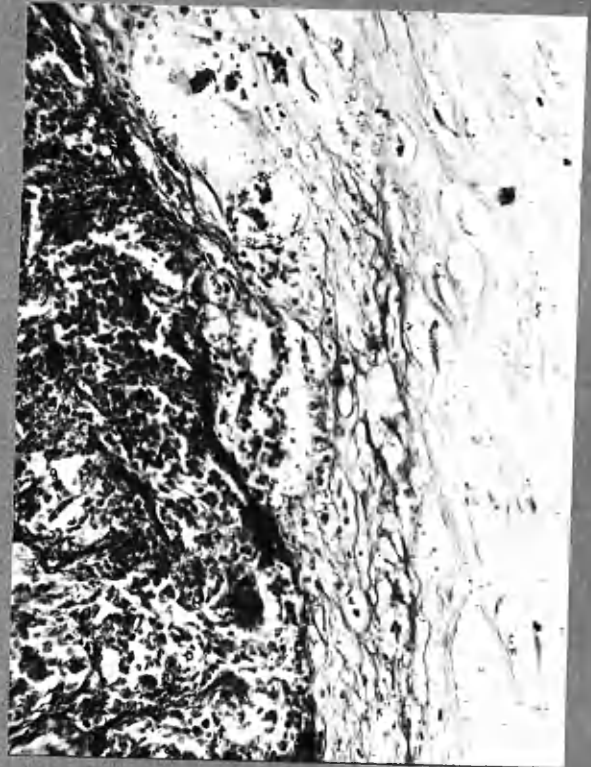
X15

Note distribution of fat droplets (black dots).



14 ADA  
2:4 micro(8)

Lendrum's acid-Picro-Mallory.



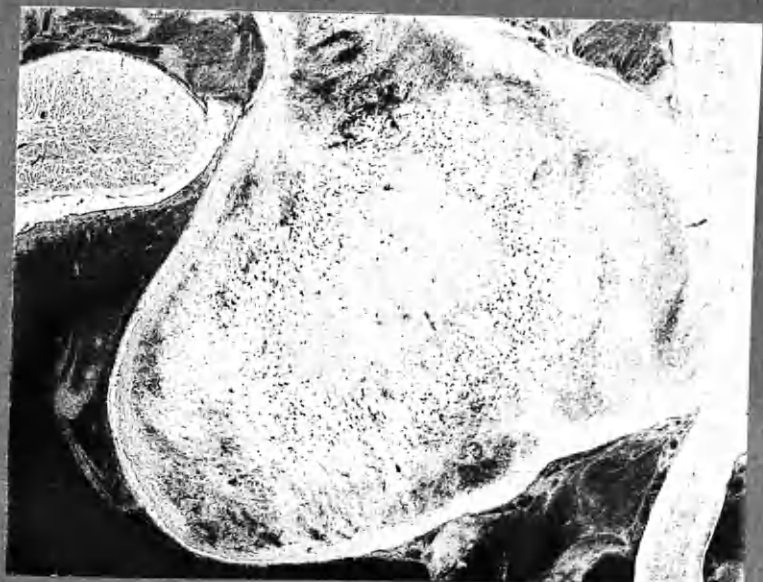
See also 14 ADA 2:4 (1-7)  
mounted between Chapters 7, 8.

X150

Transitional appearances at interface between blood clot and recently formed fibrous tissue. Intimate mingling of fibrinous fibrils and collagen fibres, individual fibres often showing staining with both blue and red as well as intermediate tints consistent with "fibrinoid".

Newly formed blood vessels are incompletely lined with "collagen", without evidence of continuous endothelium.

Case MHA 5125 - ATRIAL THROMBUS.



Scharlach R.

X15

Note distribution of fat droplets (black dots).

1

A more surprising feature seen in the same section was the appearance in the depths of the thrombus, remote from contact with the underlying organised tissue, of fibres which stained as for collagen by van Gieson's stain. In this particular case this feature was not very clearly defined and other examples more suitable for photography were sought. In another<sup>2</sup> the phenomenon was more readily demonstrated. (See also section of 8-month old thrombotic occlusion of a subclavian artery.) The interesting point was the very different histological response in these lesions when compared with the response of other tissues to foreign substance. Generally speaking, foreign material, be it necrotic tissue or extravasated blood, provokes intense cellular reaction. The cytological response includes macrophage activity, which is followed and accompanied by ingrowth of vascular granulation tissue. The foreign material is broken down and removed to a large extent. As the cellular activity wanes it can be seen that fibroblasts have been laying down fibrous tissue and, depending on the circumstances, they continue to do so for a time - as, for instance, in "replacement fibrosis" in myocardial infarction. The resultant scar may comprise but a fraction of the bulk of the original tissue which it represents. The sequence is demolition and then building, fibrous tissue being formed in the rear of the invading forces, or in company with them.

The course of events in intravascular thrombosis as observed in this investigation differed in some important respects which will be described before further comparison is made with tissue reaction to foreign matter in extra vascular sites.

Thrombus formation on a thickened intimal surface seemed to have provoked remarkably little reaction in the underlying tissue. Indeed as far as could be judged little change was seen at the base of thrombi in coronary arteries up to several (c.3) weeks in age, by which time early degenerative changes in the entrapped red cells were becoming evident (Chapter 7). In the case of thrombus

---

(1) 13 left atrium, thrombus.  
(2) D:9 atrial thrombus.

in contact with thickened intima, there was at this stage still remarkably little cellular reaction in the underlying tissue. When the atrial thrombus from Case D:9 was examined closely it was observed that the nuclei of cells which were probably fibroblasts were widely dispersed through the thrombus in all parts where collagenous fibres could be seen. It was striking however how scanty these cells were and how far they had migrated from base. In the depths of the thrombus they existed almost in cytological isolation, being unaccompanied by the macrophages and vascular tissue which would be expected to greet foreign protein in other sites. The fibroblasts did not look "active". Perhaps their activity was subdued by the relatively rarified atmosphere in respect of oxygen in which they must have existed, for they were sometimes far from the surface and unaccompanied by blood vessels. Perhaps too this was why more active cells, which in other circumstances would have been in the van of invasion, declined to keep them company. It is likely however that these fibroblasts were responsible for the collagen-like fibres which were to be seen in the depths of the clot.

It appeared at first glance that fibroblasts had laid down a network of collagen on the scaffolding of fibrin. At the interface between established collagenous tissue and thrombus, collagen fibres seemed to have been invading the fibrin network. In the rear of this advancing front, the usual galaxy of active fibroblasts, macrophages and young vascular tissue followed, as it were, at a safe distance. It is curious how the battle order was reversed in these respects; and this is probably not without special interest and importance.

I think there is room for doubt that the collagen-like tissue, that is the product of "organisation" of thrombus, is formed in the same way as fibrous tissue in other sites. I have had the impression that fibrin may be converted into this collagen-like material (doubtless under the influence of fibroblasts) without necessarily being broken down into its simplest constituents. For, on occasion,

"There is nothing to suggest that these masses represent necrotic collagenous fibres. Evidence of an exudative cellular response has never been observed in such foci, and well preserved fibres staining as collagen are seen side by side and even dovetailing with fibrin-staining bands."

Clark et al., 1936

a merging of staining qualities was observed, especially in H. and E. and acid picro-Mallory stained preparations where fibres of apparently fibrinous nature blended with the paler and more defined "collagenous" fibres.<sup>1</sup> I formed the impresssion that "fibrinoid" material did not represent a degeneration of collagen, as is implicit in "fibrinoid degeneration", but that staining of this intermediate character marked a transitional stage in the conversion of fibrin to collagen. I should like however to have made more numerous and more critical observations upon this point, aided by the use of staining techniques not employed in this investigation.

At any rate it seemed clear that fibrin was replaced by, and/or converted <sup>an</sup> into, /approximately equivalent bulk of collagenous tissue. Accordingly, on the assimilation of a fibrin thrombus into the tissue of the arterial intima, there may well be added to the vessel wall a cushion of tissue little different in size from the original thrombus. This was well seen in thrombi which nearly or completely filled the remaining arterial lumen. In this connection, I think that the manner in which fibrin-collagen conversion appeared to come first, and thereby lay down solid tissue before the arrival of macrophage activity, has important implications. Were the reverse the case, were vigorous cellular activity to come first, so that the ground be cleared of inanimate debris in advance of fibroblastic activity, then the arterial lesions resulting from the organisation of mural thrombus would be of smaller bulk, and correspondingly lesser clinical importance.

1. 14 ADA 2:4 (8) micro.

Interface Changes in the Coronary Arteries

Changes taking place at the interface between thrombus and the underlying thickened intima of coronary arteries may be seen in micro-sections 7 ADA (1), 10 LCxA main branch (2), 14 ADA 2:1, 14 ADA 2:4 (8,9), 15 ADA 3:2 (2). The section stained by acid picro-Mallory method (14 ADA 2:4 (9) ) shows merging of staining qualities as the fibrin network on the left is converted to collagen-like fibres on the right. The paucity of cellular reaction is striking.

Much seemed to depend upon the tardiness with which the arterial intima mounted its attack upon the thrombus seated upon it. It is possible that more than one factor was involved in this apparent lack of response. Foremost perhaps was the unprovocative nature of thrombus itself, when in an intravascular site. The evidence would suggest that fresh thrombus was only physically and not chemically foreign to the endothelial lining and to the subendothelial tissues of the thickened intima. On the other hand one might well expect that autolytic changes in thrombus would have produced agents of greater power to provoke reaction from the underlying tissue. And indeed, in older lesions, considerable cellular activity was witnessed in the region of old-standing fragments of thrombus and around necrotic debris; whereas for several weeks, or so it has seemed, fresh thrombus rested in contact with thickened intima without provoking evident reaction. It is tempting to suppose that the peaceful acceptance of recent thrombus by the sub-endothelial tissues of the thickened intima may have been in keeping with its own origins from thrombus at an earlier date.

The thickened state of the intima has been specified in these remarks, partly because my own observations have been mainly concerned with thrombosis on previously damaged, or atherosclerotic, intimal surfaces; and partly because

I think that the reactivity of the underlying intima is probably different when this structure is normal than when it is grossly, or perhaps even only slightly, thickened.

The normal arterial intima of man is exceedingly thin and is probably without intrinsic blood vessels (Winternitz et al., 1938).

Thrombus resting on the normal intimal surface is therefore separated from the vascular medial coat by the internal elastic lamina, and by a minimum of other connective tissue, upon which is supported the endothelium. If the barrier of endothelium should break down (perhaps through anoxia) there is then but a short distance separating thrombus from the potential cellular responsiveness of the vascularised medial and adventitial coats. In contrast to the tolerance of intimal tissue for thrombus, the medial coat appeared to react to the presence of extravasated blood elements. Intense cellular activity likewise accompanied adventitial haemorrhage. Accordingly one might expect that after a much shorter period of time attack upon the thrombus would be mounted from the normal vessel wall. It would seem that close to the media and internal elastic lamina the attack is not dissimilar to the reaction to foreign substance in other sites. But as the forces of invasion and organisation, in the few specimens which I have examined, extended further into the depths of the clot and away from their base, the pattern of invasion changed. The fibroblasts migrated in advance of organised tissue into the inert thrombus and collagenous change was taking place before the demolition squads had arrived. An artery, previously normal and now completely obliterated by old-standing thrombus, can show dense necrotic debris in the centre, then a layer of collagenous tissue and so-called "fibrinoid" with relatively few vascular channels, and finally at the periphery vascular tissue and much cellular activity. An example is shown in which thrombosis took place 8 months before death in a previously normal subclavian artery. A similar state of

"The newly formed capillaries are not derived from the vasa vasorum.... They are abnormal structures and originate from the lumens of the larger arteries."

Paterson, 1952.

"We have been forced to the conclusion that these incarcerated endothelial cells take on the properties of fibroblasts and are responsible for the organisation of the superficial parts of the thrombus."

Crawford and Levene, 1952.

If blood was left in the ligated vessel, endothelial cells emigrated into the blood clot in a fashion similar to that of fibroblasts in tissue cultures. Myelopoietic foci were then formed in the organising blood clot, which was finally converted under formation of vascular lumens into an angiomatous structure.

Malyschew, 1929, cited Hueper, 1945.



affairs was demonstrated in a pulmonary artery. It may also be noted that,<sup>8:28</sup> by the time a certain amount of collagen-like tissue has been laid down in the peripheral parts of the clot, a situation has been reached closely similar to previously thickened intima overlain by thrombus. It is therefore mainly in the earliest stages that differences may be found in the reaction of the artery wall to thrombus, depending on the normal or thickened state of the intima at the time.

I have already noted (Chapter 7) that for the most part the blood channels found between blood clot and artery wall had arisen not from the outer coats but from the lumen of the artery and were part of the process of canalisation. I have not however carried out injection studies on thrombotic occlusions of previously normal arteries. I cannot therefore add to Dible's view that in such occlusions the blood channels taking part in canalisation have likewise arisen from the arterial lumen and not from the vasa vasorum (Dible, 1958). I have no reason however to doubt that this is so.

Thrombosis taking place on an atherosclerotic intimal surface presented some features of difference. Atherosclerotic tissue was often devoid of demonstrable blood vessels. The clot was thereby separated from the vascular outer coats by a considerable thickness of relatively avascular tissue. It has already been remarked that the tardiness with which the forces of invasion were mounted was partly conditioned by lack of transport routes. The immediately available cell types noted were the scanty fibroblasts of atherosclerotic tissue. The possibility may also be entertained that endothelial cells may undergo metaplasia. Fibroblasts are evidently able to survive in relatively avascular circumstances, for they are found in tendons and in dense scar tissue. It has also been remarked already that their lack of the company of other cell types in the depths of thrombus may be on this basis. (Polymorph and other blood cells entrapped in thrombus presumably at the time of its formation have sometimes

"A gradual transition from masses which are clearly surface deposits to those covered by epithelium and collagenous tissue containing proliferating fibroblasts may be observed in the sections. . . . . Subsurface "fibrinoid" masses represent the remnants of a partially organised surface deposit. "

Clark et al. ,1936.

---

"Some regard them (fibrinoid deposits) as deposits in the connective tissues and others as swellings of the tissues themselves, but ,so far as I have found, only one group of writers in recent years, namely Clark, Graef and Chasis (1936), have suggested that they represent surface deposits which have subsequently been overgrown. My own observations lead me to believe that the latter is the case, and that these "fibrinoid" deposits in fact provide the essential link in the chain of evidence which connects atherosclerosis with thrombosis "

Duguid, 1946.

---

"First, there is the appearance in many arteries of layers of occlusive material apparently representing successive deposits of fibrin, each perhaps with resultant myocardial damage. In many instances the most superficial layer of this material, next the blood stream, is clearly fibrinous, but the remainder of the plaque stains not for fibrin but for collagen. We are not in a position to say whether this is truly collagen, or how it is formed, but we have seen no evidence to suggest that it is due to organization . . . . In our experience, however, organization very seldom reaches the superficial parts of the plaque where transformation to collagen (as demonstrable histologically) would appear to take place by some other method."

Branwood and Montgomery, 1956.

---

appeared to have survived for several weeks in its depths. In many cases however of older thrombi nuclear debris probably indicates the fate of such cells. In more spongy thrombus of course there may be later entry of polymorphs from the blood.)

The foregoing descriptions have concerned the simple state of affairs where relatively solid thrombus composed mainly of fibrin had rested upon a previously quiescent intima. In many coronary artery lesions the position was much more complicated. Thus the presence of intimal vessels in the tissue underlying the thrombus, haemorrhage from such vessels, and the processes of canalisation of thrombus greatly altered the picture. These complicating features were not uncommon and accordingly it was not without difficulty that a few examples have been selected for photographic demonstration of the process described. The direct examination on the other hand of the multiple microsections taken from each lesion showing transition from thrombus to organised intimal tissue permitted interpretation of the changes according to the concept which has been outlined above, in the majority of instances.

In the examples shown, and in many others, evidence for the conversion of fibrin thrombi into atherosclerotic intimal tissue was at the least highly suggestive. The fate of red cells and haemoglobin has not yet been considered, nor the origin or significance of lipid in atherosclerotic plaques. Attention will be given to these topics shortly. At this point it is submitted that collagenous development has been conclusively shown to replace the structure of thrombus; and - more tentatively - that "collagen" is probably formed from fibrin.

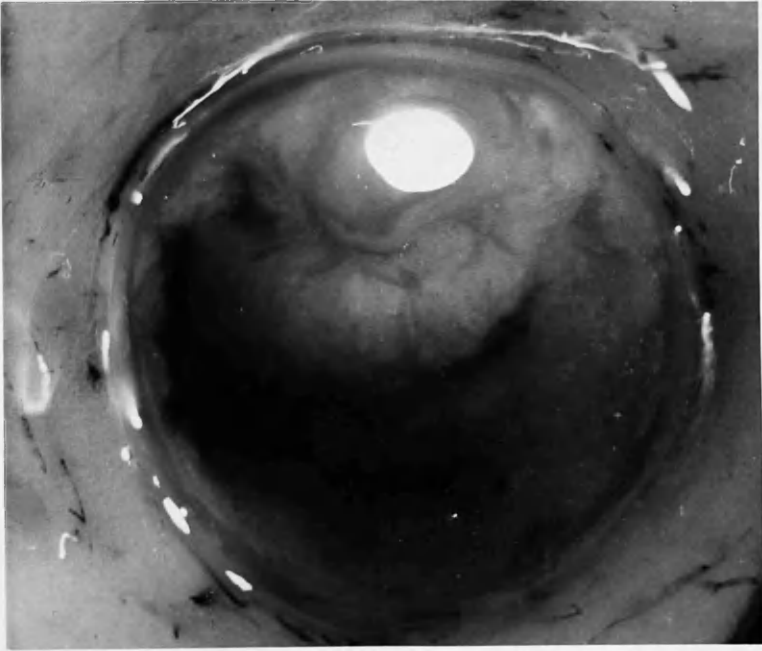
COLOUR TRANSPARENCIES

of

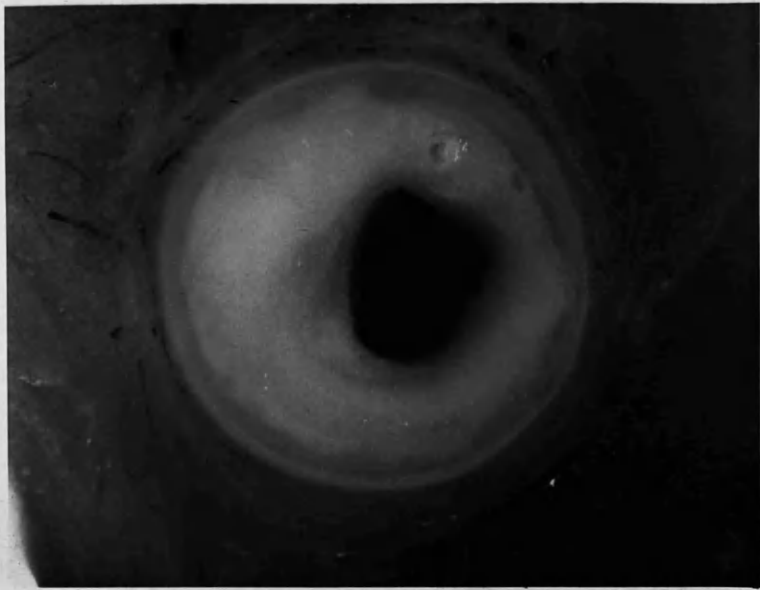
2 mm. thick sections

of coronary arteries

*Raise mounted transparencies so that light  
falls on underlying white page.*



x13½



x 18



8:30b

22 ADA  
20 ADA



x12

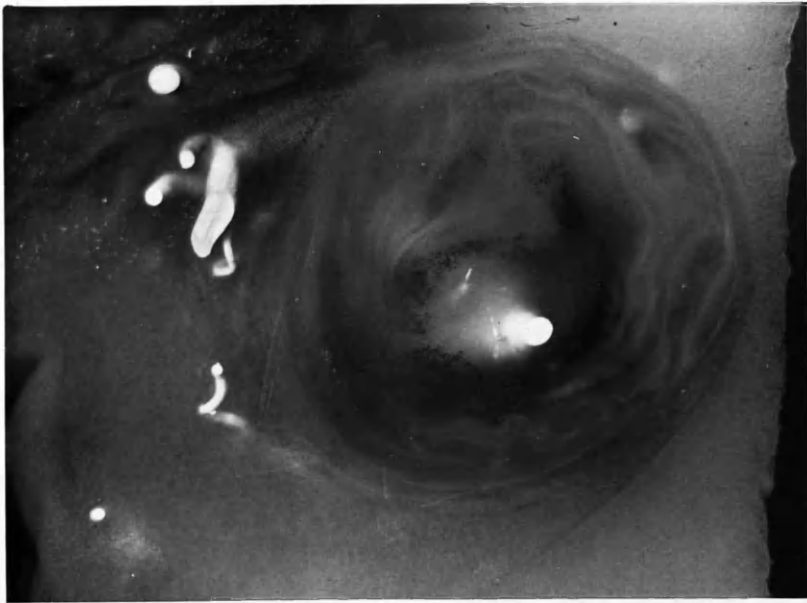
22 ADA 2:5 b



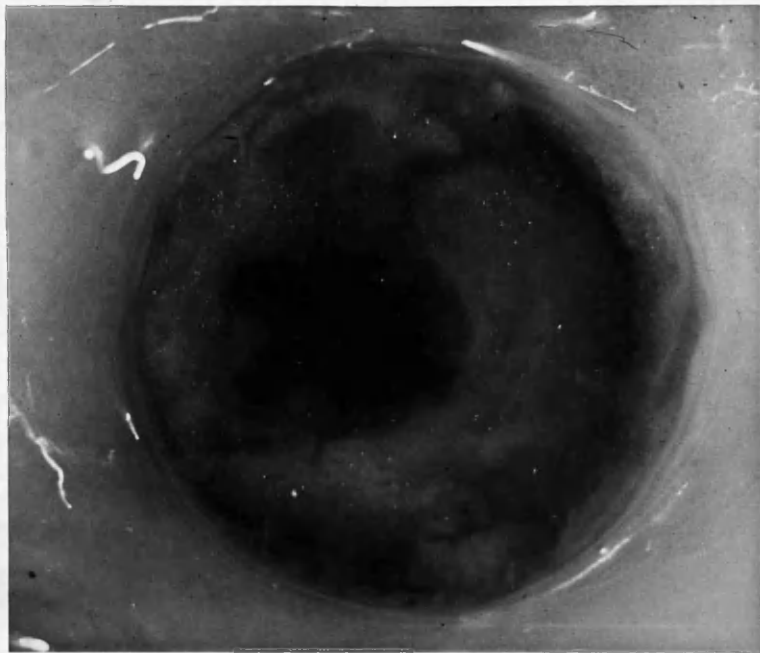
x13

20 ADA 3:4 b





X 15



X 20



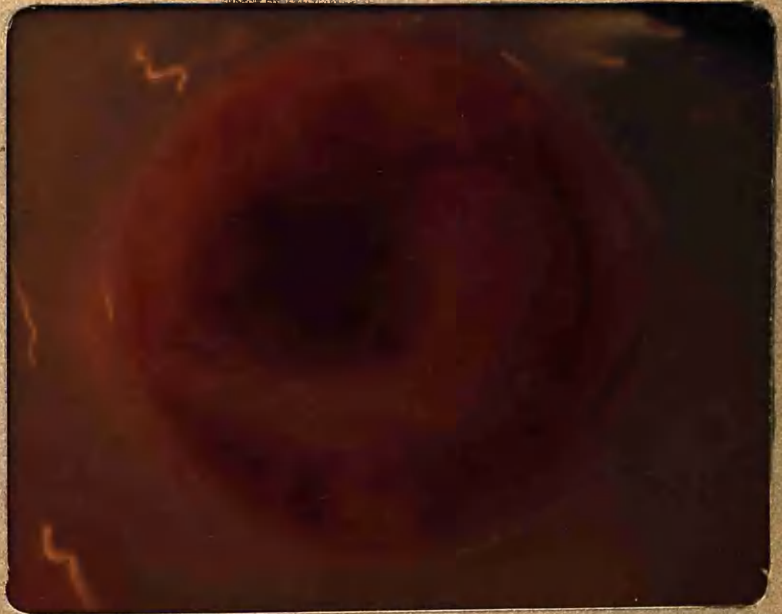8:30 d

25 LCxA  
12 RC



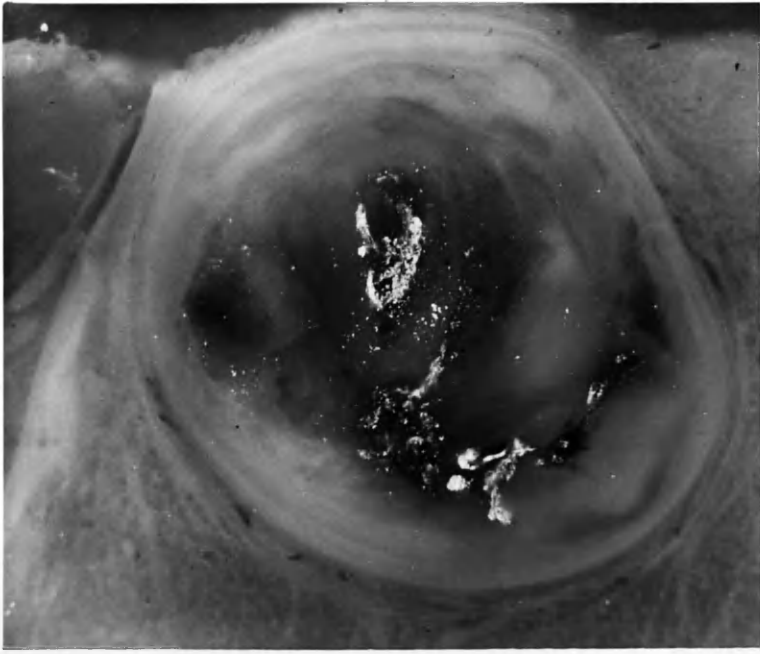
x15

25 LCxA 2:5 b

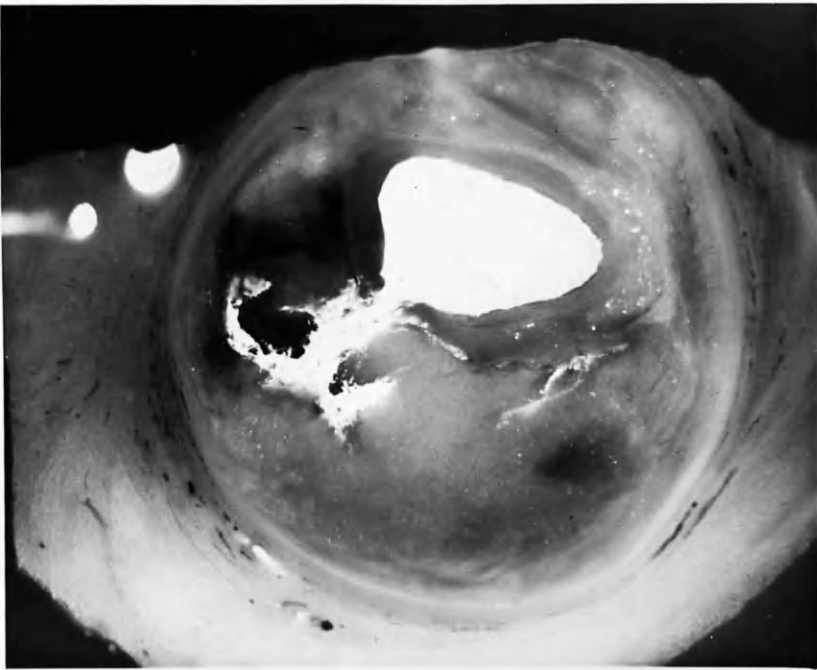


x19

12 RC 2:1 b.



x16

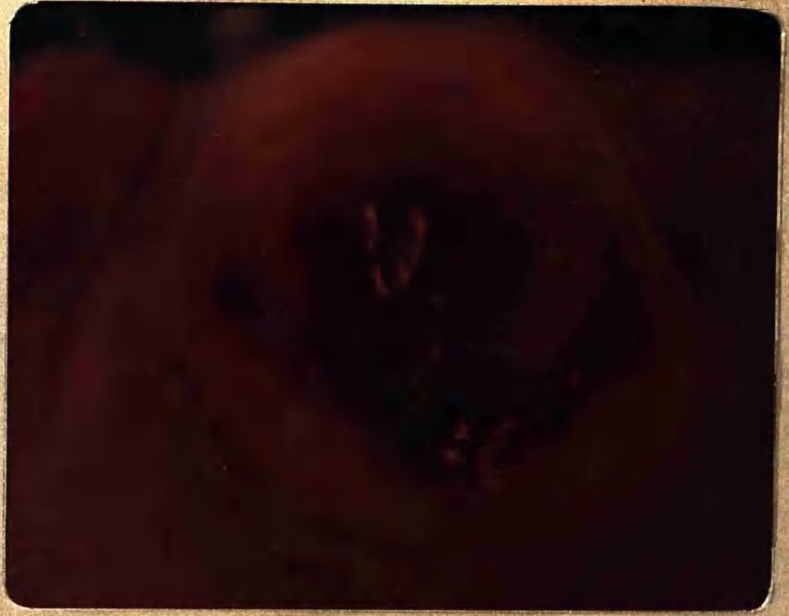


x16



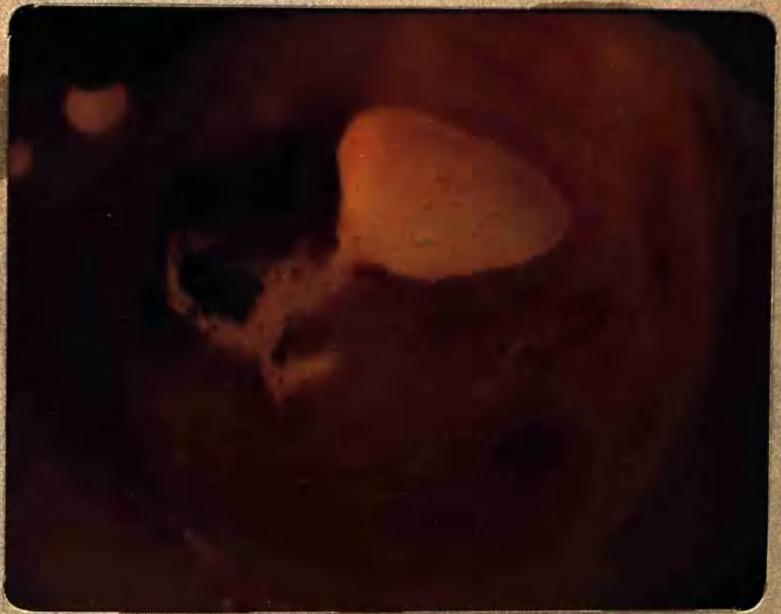8:30f

14 ADA  
18 LCxA



x 15

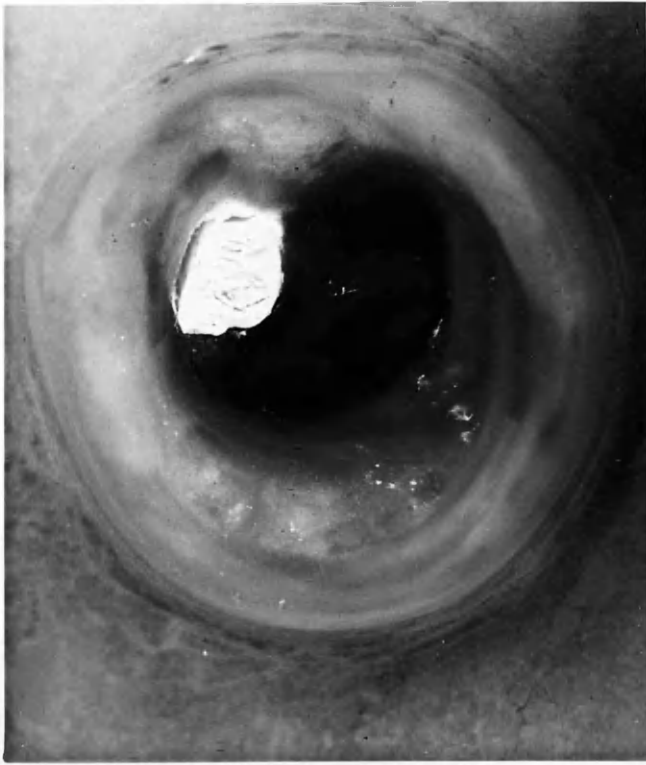
14 ADA 2:3b



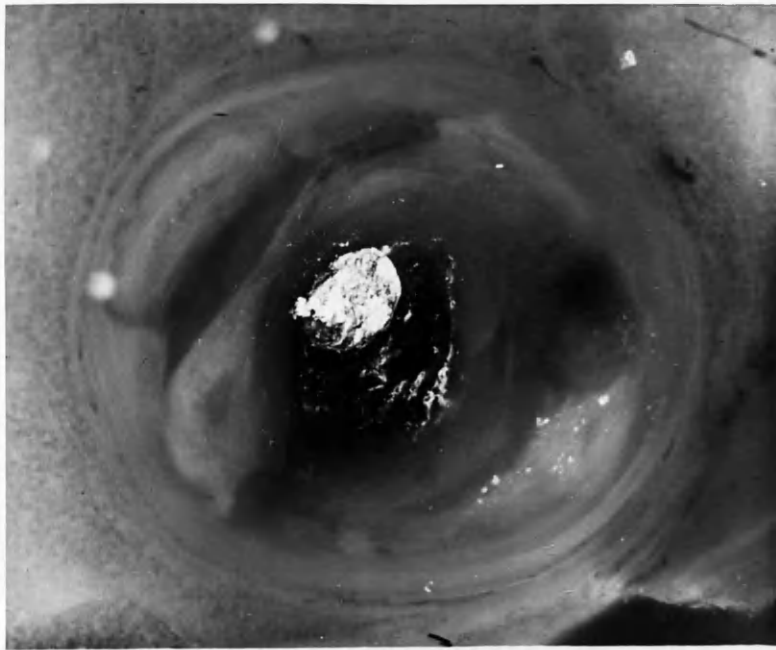
x 18

18 LCxA 1:4b

(



x16



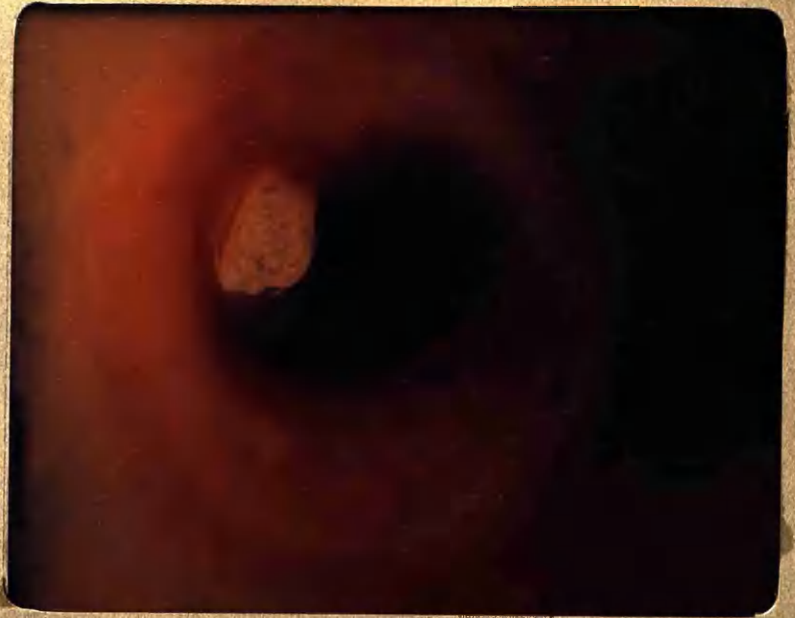x16



8:30 b

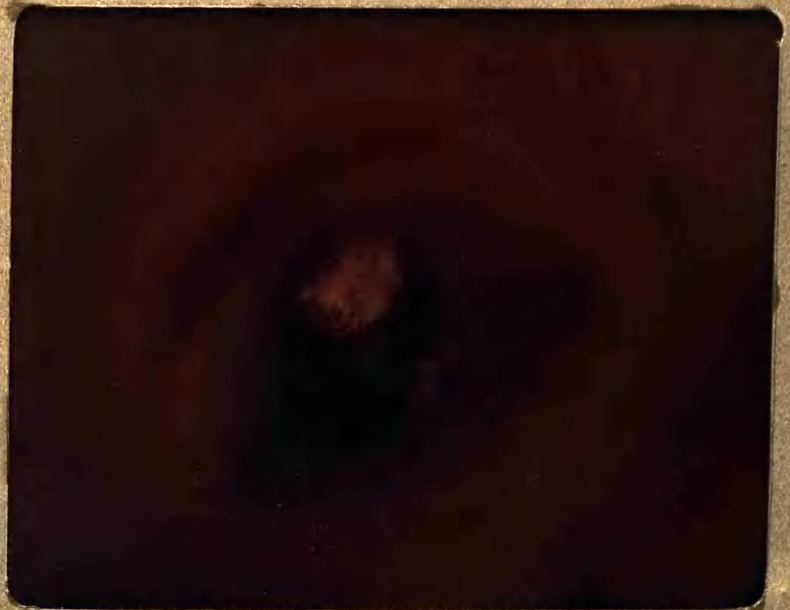14ADA

" "



x 15


14 ADA 3:1 b



x 15

14 ADA 2:5 b

(



SOME FEATURES OF ESTABLISHED ATHEROSCLEROTIC LESIONS

1. Evidence from 2 mm. thick Transverse Sections: Pigmentation.

In the course of organisation of thrombus, islands of degenerating red cells may be entrapped in the fibrous network. As a result, as seen in the gross specimen, the tissue itself was sometimes stained by pigment derived from haemoglobin. A further stage was represented by deposits of iron. It is impossible to indicate the colour changes observed in these preparations in black-and-white photographs and accordingly a few selected colour transparencies are included.

It will be recalled that the 2 mm. thick sections were of formalin-fixed tissue which had previously been washed in normal saline and at no time had been in contact with hypotonic solutions; that the injection medium contained no diffusible dye stuffs; and that the tissue was embedded in glycerin-agar which imparted a moderate translucency, especially to the non-fatty portions. All these points are important when colour changes in these specimens are under consideration. Clearly these colour changes might have been distorted by washing in water before fixation and completely obscured by inclusion in the injection medium of diffusible dyes, as is common in the techniques of others. Because of fixation and glycerin embedding there was naturally some departure from the colours that might be witnessed in the fresh specimen. Direct comparison with fresh specimens therefore may not be valid. In particular the red colour of haemoglobin was altered to brown.

In these specimens, prepared and mounted in this way, the colour of an established uncomplicated atherosclerotic plaque was a delicate pale yellow, similar to the epicardial fat surrounding the artery and similar in tone to the natural colour of untinted butter.<sup>1</sup> Portions of atheromata which contained large quantities of lipid material were more glistening and of a still paler colour when viewed in incident light. In transmitted light lipid material cast a darker shadow. Conversely, portions of the sclerotic plaque that were mainly fibrous in composition were of a greyer and duller tone than were the fatty portions, when viewed by incident light;<sup>2</sup> but in transmitted light were seen to be relatively more translucent. If the temperature was raised approximately to

---

(1) Colour transparency 20 ADA 3:4 b.  
 (2) Colour transparency 14 ADA 2:3 b and 2:5 b.



blood heat, the translucency of the lipid material was greatly increased.

Using a binocular dissecting microscope with a magnification of approximately x 20, the combined advantages of three dimensions, various light effects, the texture of the material and the sometimes subtle, sometimes marked, colour changes, made the examination of these specimens most informative. The reader is asked to accept that the photographic illustrations fall short of the original. Much could be observed about the detailed anatomy of the atherosclerotic lesions, both mural and occlusive.

This manner of examining atherosclerotic lesions may seem somewhat crude by comparison with the highly evolved histological techniques commonly employed. Yet it is another approach in the analysis of the lesion and I do not think is the less valuable or reliable because it is relatively simple and direct, and involves no artificial stains or complicated processes. Moreover it has certain advantages. These include freedom from damage and artefact distortion, which bedevil the histological examination of diseased arteries; and the number of observations made economically possible. Thus in this investigation roughly three coronary arteries in each of 16 cases and 2 controls were rendered into serial sections, 2 mm. in thickness. This yielded something of the order of 3000 cross sections of arteries for inspection. The majority of these sections transected atherosclerotic plaques of varying degree of severity.

The majority of atherosclerotic lesions were pale in colour. Some were frankly orange-yellow or orange-brown in colour, and all gradations of shade existed in different cases and in different portions of the same artery. The most intense orange colouration was seen in the central portions of complete occlusions, where the colour was without doubt due to altered blood pigment, and originally derived from mixed thrombus.<sup>1</sup> At the ends of such lesions where surfaces had been in contact with flowing blood the intimal tissue was paler.

---

(1) 12 RC 2:1b, colour transparency.

This tissue was found on histological examination to contain less necrotic debris and to be composed largely of organised fibrous tissue. In the central, more highly pigmented portions the reverse was the case.

Frequently in atherosclerotic lesions the pigmentation, or its absence, was not uniformly distributed, but small patches or layers of yellowish or brownish pigment were found embedded in tissue which was elsewhere of pale colour; or pale and pigmented layers might alternate. Tissue which had been clearly formed by the recent organisation of thrombus usually showed pigmentation, the degree of colouration presumably having some relation to the proportion of red cells in the original thrombus, particularly where this was still partly present.<sup>1,2</sup>

It is speculative whether the reverse held true; that lesions which showed pigmentation of this order had therefore been formed from thrombus. Indeed the reverse could obtain only for a proportion of instances, for almost certainly some pigmented areas were the result of old-standing intimal haemorrhage. Nevertheless the incidence of pigmented areas in established atherosclerotic lesions was taken as suggestive support for the concept of atherogenesis from thrombosis.

It was no easy matter to put a numerical figure upon the incidence of such changes. On examination of the mounted 2 mm. thick sections of the more severely affected arteries, it became obvious that separation of the disease process into individual plaques would be entirely artificial. The one incident overlapped the next both circumferentially and in the long axis of the artery in such a complex fashion that I was discouraged from attempting to distinguish one "plaque" from another, in a three-dimensional concept of the process. The term is therefore used in this chapter in a two-dimensional sense, referring to an eccentric thickening of the intima as seen in cross section and

---

(1) 14 ADA 2:3b.  
(2) 22 ADA 2:5b.

without taking into account its limits above or below this level.

When the mounted 2 mm. arterial sections of the series were reviewed, it was estimated that the great majority of sections through atherosclerotic plaques revealed no pigmentation other than the "normal" pale tones. Perhaps one in ten showed pigmentation, apart from sections through old occlusions in which some degree of pigmentation was usual.

Although the majority of pigmented atherosclerotic lesions were large, occasionally quite narrow intimal thickenings showed distinct pigmentation. One of these is illustrated also in microsection (14 RC 5:1) which shows intimal vessels and iron deposition. Conversely, many very large atherosclerotic lesions showed little or no pigmentation.

Increase in fat content was considered as a factor producing pallor of the atheromatous plaque. In general it could be said that the lipid content, as judged visually, in the large pale lesions was higher than in those showing pigmentation of a degree which suggested a recent origin from blood elements. On the other hand, in some lesions, pigmented areas contained large amounts of lipid. While the shimmering whiteness of certain lesions evidently depended upon a high cholesterol content, the opinion was formed that this was not as a rule the main factor in determining the pallid or pigmented appearances of atherosclerotic plaques.

One interesting point that emerged was the nature of the atherosclerotic lesions which underlay recent thrombosis. With but one or two doubtful exceptions, out of 13 instances of recent thrombotic occlusion (one month or less in duration), the underlying intimal tissue was itself pigmented in places. Another remarkable finding, to which allusion will be made later, was that, almost without exception, intimal vessels of sufficient size to be demonstrated by injection lay in tissue that showed pigmentation. In some of these

instances, as already indicated, the pigmentation might have resulted solely from haemorrhage from the intimal vessels, but I think the more tenable explanation is that intimal vessels and pigmentation were each features which occurred in tissue derived from thrombus - notwithstanding the possibility that further pigmentation might result from subsequent haemorrhage from the vessels so formed.

What, it may be asked, of the pale atherosclerotic plaques, can they too be derived from thrombus? The pathogenesis of these lesions is still more obscure than is the origin of the pigmented plaques, but is a matter of no lesser importance. After all, the pale lesions were in the majority, even though the overwhelming majority of lesions of clinical importance were pigmented. The pale lesions were, however, in their general configuration, in no fundamental way different from lesions whose pigmented tissue had probably developed from thrombus. I do not see any cogent reason for dismissing a possible common origin for these two types of lesion simply on grounds of pigment in the one and lack of it in the other:

(1) Pigmentation is the result of breakdown of red blood elements and not of fibrin, and it is the conversion of the fibrinous into the fibrous structure that is the basis of the concept under review, not the fate of the haemoglobin. In many of the more recent thrombi that were examined the proportion of red blood elements entrapped, or still entrapped by the time of death, varied greatly. Sometimes the thrombus was very dark. In others it was as pale as atherosclerotic tissue itself. I can only speculate upon the proportion of haemoglobin (at first intracellular and enmeshed in the fibrin network at the time of thrombosis) that was eventually incorporated into the substance of the organised tissue. Much must have escaped before this occurred.

(2) Quite possibly some haemoglobin continued to escape after investment in fibrous tissue, by diffusion aided by the percolation of serum through the intima, by the development of blood vessels in the intima or possibly by macrophage activity. If removal of blood pigment continued under these influences after its investment in the intimal wall, then one would expect to have found less pigment in the smaller than in the larger lesions, and less in mural atherosclerotic plaques (where the surface has been bathed by flowing blood during its formation, and serous fluid able to percolate from the lumen outwards thereafter) than in complete occlusions. Indeed such were the findings in general in these preparations.

One would also have expected to find less pigment in the older lesions of longer standing and indeed this also seemed to be the case, but it had to be acknowledged that the assessment of the relative ages of older atherosclerotic lesions was a matter of conjecture. Lesions which showed continued activity, haemorrhage, thrombus on the surface - and pigmentation - were thought probably to be of more recent date than those which did not show these features, but there was no indication of the true time relationship. If, however, for the sake of argument, it were supposed that overt pigment could be removed from an intimal lesion in the course of one, or maybe two, years, and if it be accepted that atherosclerotic lesions of considerable size may exist and continue to be formed over a number of years (say 10 or 20, for this purpose) before symptoms usher in the clinical course of the disease, then it would not be discordant with the present concept that the majority, even nine out of ten, of the lesions should show no excess pigmentation by the time of death. Refutation of the concept must rest upon grounds other than lack of altered blood pigment in the majority of lesions.

---

♠ The tissue at the ends of a segment of complete thrombotic occlusion was pale for a distance of one, 2 or more mm. in lesions of this age.

2. Evidence for Micro-Sections: Iron Deposition.

Iron deposition is probably a more secure index of the breakdown of blood than is the staining of the lesion by brownish pigment. Staining has been mentioned first because of the large number of available opportunities for its observation, compared to the relatively few microsections stained for iron which were in any case mainly taken from the more severe lesions. A particular type of pigmentation of the intima, in the form of punctate yellowish-brown or rust-coloured areas, was also shown to be due to stainable iron deposits.

Iron deposition was revealed in the microsections by the Prussian Blue reaction and was found to vary greatly in amounts. Its quantity and even its presence seemed to bear little relationship to the amount of pigment in general or other evidence of thrombotic origin of the tissue. In some instances (e.g., 18 ADA 1:8 PBR) abundant iron deposition was found. In others very little. Iron deposits were not diffusely distributed but tended to form small clumps, mainly near the periphery of the lesion and especially in regions the seat of intimal vessels. Sometimes<sup>1,2</sup> large quantities of stainable iron were deposited in tissue which was largely fibrous and had obviously resulted from the organisation of an old thrombotic occlusion. On the other hand only relatively small amounts of iron were on occasion found in the depths of occlusive lesions such as 11 "E" micro in which orange-yellow pigmentation was pronounced and was clearly the result of breakdown of blood elements. The iron was placed near the interface between thrombus and intimal wall and several deposits were found in the adventitial coat.

As in the case of pigmentation of the intimal tissue in the mounted arterial sections, I am inclined to regard the presence of stainable iron deposits in the microsections as good evidence of the breakdown of red blood elements in situ. Likewise, I am disinclined to regard scantiness of iron or its absence as reliable

---

(1) 25 RC 4:3 PBR.

(2) 18 ADA 1:8 PBR.

evidence to the contrary, for a variety of reasons. Firstly, if the iron is liberated only slowly it is possible that it may be carried away from the arterial wall by diffusion, by percolating fluid or by the blood stream. Secondly, it may be transported by macrophages. Round cell activity is commonly pronounced in the region of iron deposition. Thirdly, it tends to be found in aggregations and a random section may fail to pass through an iron deposit, despite its presence nearby. (This contingency was less likely in view of the semi-serial manner in which numerous sections were taken from each block in this investigation.)

In any event, the quantity of red blood elements originally incorporated in the thrombus may have been small and the amount remaining by the time iron was liberated from the blood pigment may have been very much less, for reasons already considered.

All these considerations make me cautious in using the quantity of stainable iron found in the microsections as an index of the quantity of haemoglobin present at the beginning of the process of assimilation of thrombus into the intima; and in using the paucity of iron in certain lesions as evidence against their origin in thrombus. Nevertheless stainable iron was found in nearly all sections taken from the region of arterial occlusion and also in a high proportion of sections taken from non-occlusive atherosclerotic lesions. In the latter the quantities of iron were usually small but not invariably so. And, significantly enough, stainable iron was sometimes found in sections taken from pale atherosclerotic plaques.

As was the case with pigmentation, attempts at reaching firm conclusions from the presence of iron about the thrombotic origin of atherosclerotic plaques could be made only with reservation on account of the possibility that in some cases the iron had been derived from intimal haemorrhage.

A Common Origin?

If we lay aside considerations of pigmentation in the gross specimen, stainable iron in the microsection, and the presence of injected intimal vessels, there was little difference to be found between the pale atherosclerotic plaques and those which showed these features. Thus the two types of lesion were similar in respect of the general appearances of the atherosclerotic plaques in cross section (as described in the early part of this chapter); the formation in layers and crescents; the eccentric position of the lesions; the distribution and nature of lipid material (although its quantity was sometimes larger in the paler lesions); the presence of thin-walled sinusoidal blood channels; and the histological staining qualities and detailed structure of the collagen-like and elastic fibres. It would be tempting to envisage a common origin for each. So far the evidence presented from this investigation would favour thrombosis and the assimilation of thrombus into the intimal wall as the common origin of all types of atherosclerotic lesions.

But there is a large body of opinion that favours lipid deposition as a primary or causal factor. Attention will therefore now be directed to the findings in this investigation which bear upon this difficult topic.



LIPID

The origin and significance of lipid accumulations in the human arterial intima are among the most puzzling problems in pathology. No one can fail to be impressed by the enormous quantities of fatty material which may be present in an atheroma. Indeed it is because the appearances are so dramatic that introduction of this aspect of the subject has been intentionally deferred until this point. It is not surprising that the scintillating constellations of cholesterol crystals should fascinate the eye of the observer and catch his imagination; and that his processes of thought upon this subject should start with lipid deposition and remain preoccupied with it. And yet this may not be the proper sequence, nor the proper emphasis. (Nor must it even be assumed at the outset that "deposition" is the correct description.) Many terms used in this subject, such as "lipid deposition", "fibrinoid degeneration", "vascularisation of the intima", to mention but a few, serve to stultify original thought and to bias observation.

I shall attempt to present therefore as objectively as possible my own observations on the occurrence of lipid in atherosclerotic lesions. If in discussion I should devote more space to features which seem to run contrary to conventional concepts rather than to those which confirm them, I would plead that I do so for the sake of provocative argument and not out of prejudice.

The Nature of Lipid in the Atherosclerotic Lesions

Lipid was readily observed in frozen sections of atherosclerotic lesions, in which it could be strikingly demonstrated by fat-soluble stains such as Scharlach R. Doubly-refractile cholesterol crystals were revealed by polarised light, with the dazzling brilliance of reflectors caught in the headlights. These crystals were also clearly recognisable in the frozen sections by transmitted light, when they cast a shadow darker than their surroundings. Larger crystals could even be identified in the surface view of the 2 mm. thick mounted arterial sections,<sup>1</sup> both by transmitted and by incident light.

---

(1) 22 ADA 2:5b, colour transparency.

"Macrophages containing lipide were almost never observed in the early lesions."

Moon and Rinehart, 1952.

---

It need hardly be remarked that original observations on lipid in atherosclerotic lesions cannot be made from paraffin sections alone, for all lipid has been removed from them by fat solvents. Crystal-shaped faults in the necrotic debris of atheromatous abscesses may of course bear witness to the nature of the material which once occupied them;<sup>1</sup> but such appearances were only identifiable when the crystals were large. Moreover, breaks in continuity of the amorphous material were not always distinguishable from artefacts.

For the most part the fatty lesions contained doubly-refractile crystalline lipid and also fat which stained with Scharlach R. Sometimes small accumulations of re-stained fatty droplets, and individual droplets dispersed throughout larger lesions, occurred without evidence of doubly refractile material. The reverse was never the case. It was accordingly thought possible that neutral fat might make its appearance in the intima before cholesterol. In the larger lipid accumulations both elements were always present. As far as could be judged on inspection alone, the proportion of neutral fat to cholesterol was not constant, and even some very small lesions contained a very high proportion of cholesterol crystals. Fatty droplets varied greatly in size, from about half the diameter of a red blood cell down to the most minute particles.

The tiny droplets were aggregated into clumps in some places but it was not determined with certainty whether or not these aggregations were intracellular. Combined staining was avoided in this survey in the frozen sections in order to simplify the photographic record. In regard to the exact location of fatty droplets this was probably a mistake and no firm conclusions could be reached on this point. It was however thought that many of the accumulations of fatty droplets and the widely distributed minute fatty droplets in general were largely extracellular. This was certainly the case with much of the lipid in the necrotic areas and with large cholesterol crystals at any point. In certain lesions on the other hand foam cells were in abundance in the preparations stained by H. and E.

---

(1) 15 ADA 3:2 micro.

In addition to clearly defined, round, fatty droplets, there was also a more diffuse staining by Scharlach R. of the fibres in the region of definite fatty accumulations. These fibres may have been mainly in the transitional phase between fibrin and collagen. I am uncertain of the significance of this diffuse staining. It did not seem to be an artefact for it occurred repeatedly in similar distribution in neighbouring sections. Between the fibres aggregations of small particles took on elongated form as if compressed between them.

It was observed with interest that on warming the slide to body temperature the doubly-refractile crystals in the epicardial fat-cells disappeared, and that they slowly reappeared on cooling. The same phenomenon was also observed with some of the smaller cholesterol crystals in the intima, although the larger, and majority of crystals remained unaltered. It would seem likely that a certain amount of the doubly-refractile lipid which may be observed in crystalline form in the cold section was in solution in liquid fat in the living artery.

#### The Distribution of Lipid in Atherosclerotic Plaques

I should like to preface the observations that I have to make upon the distribution of lipid in atherosclerotic lesions by emphasising the very diverse appearances which were found. I could illustrate this aspect of the subject with hundreds of sections of atherosclerotic plaques, each one of which would show some feature to distinguish it from the others. By appropriate selection of examples it would be possible to lend suggestive support to almost any concept that, within reason, one cared to put forward. To be more precise, it would be possible to place before a reader, who might not happen to have personal experience of the histological features of atherosclerosis, a range of examples that would leave him in little doubt that atherosclerotic tissue had its origin

DIAGRAM 8:3

DISTRIBUTION OF LIPID IN ATHEROSCLEROTIC PLAQUES.

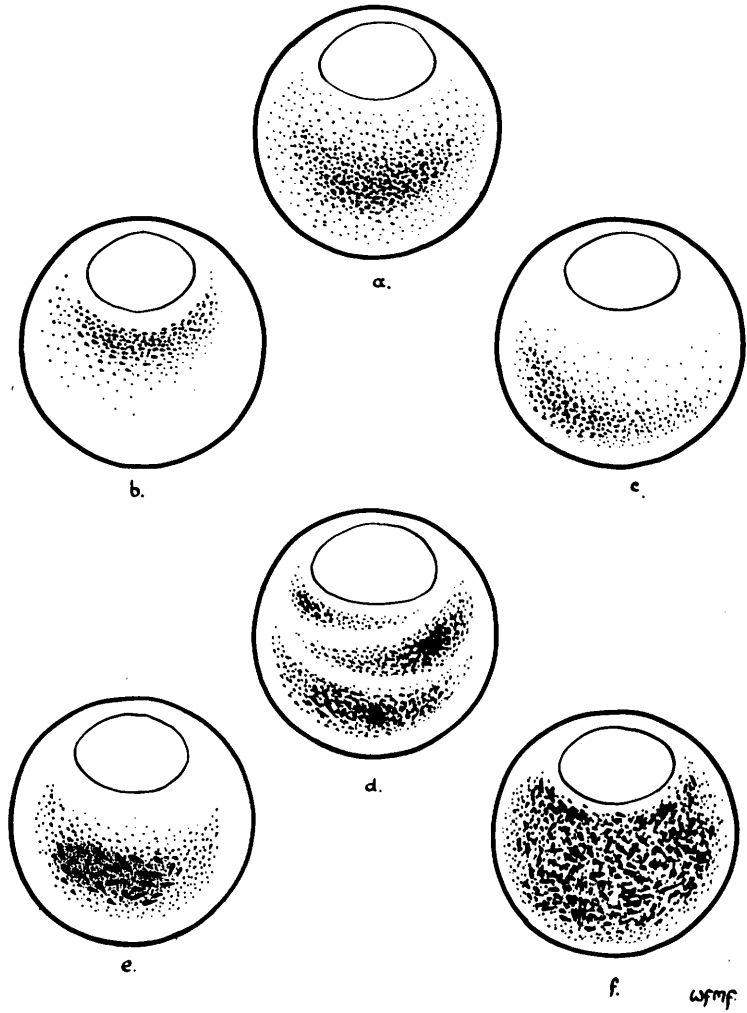
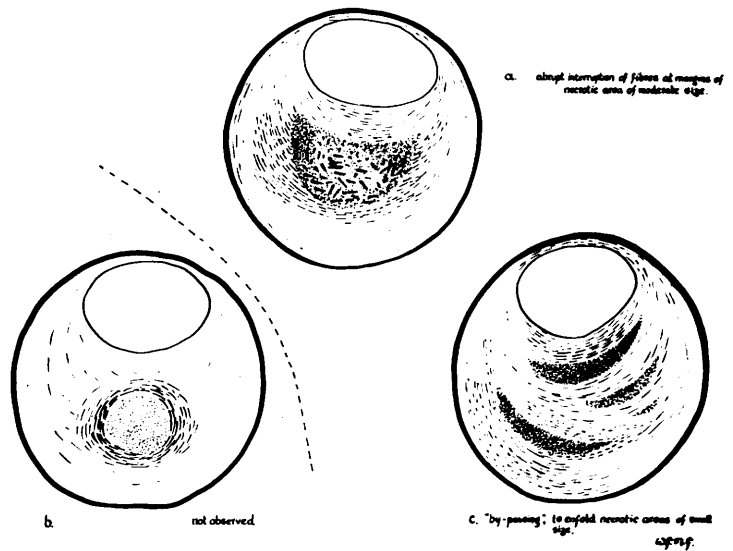


DIAGRAM 8:4

ATHEROMATOUS "ABSCESS"

DIRECTION OF FIBRES IN RELATION TO NECROTIC MATERIAL.



in thrombus, or conversely that such a concept was unlikely; that lipid distribution conformed closely to the structure of organised thrombus, or that the appearances were more consistent with lipid deposition as a primary or independent phenomenon. It is not easy, and indeed may be treacherous, to describe any particular feature as "characteristic" or "typical"; for so many, and such diverse, departures from it may be found. Nevertheless in order to give a measure of cohesion to the description of the features observed it will be necessary to use such terms. It will be appreciated that the decision to adopt a particular feature as characteristic was reached after the scrutiny of many examples; and also that no matter how objectively each observation might have been made, the synthesis of many such observations was inevitably partly a subjective process.

I shall describe firstly the situation that was found in uncomplicated atherosclerotic lesions which occupied approximately  $1/3$  to  $3/4$  of the original lumen of the artery. In such lesions the greatest accumulation of lipid material was "characteristically" found in the depths of the atherosclerotic plaque. It might be concentrated in the central portion of the lesion, which was thought to be the more typical site in a lesion of otherwise simple structure, or it might be nearer to the lumen or to the outer walls. The distribution is indicated schematically in Diagram 8:3 (a,b,c).

There was usually a layer of lipid-scanty or lipid-free collagen-staining tissue separating the lipid-containing portions of the lesion from the lumen. An "atheromatous abscess" might be separated from the lumen by a collagenous layer of considerable thickness, as in Diagram 8:3 (e), or by a thin shelf only a few fibres in depth (f). Although the inner layer was "typically" free from lipid, examples of lipid accumulation in this layer were also found. Sometimes the innermost layers of lipid merged with the larger accumulations, of which they may have been part. In others they were discrete, as though representing separate episodes (d).

Likewise a layer of relatively lipid free material characteristically separated the lipid bearing tissue from the internal elastic lamina or, where this structure was not discernible, from the outer coats. Staining for neutral fat tended to approach somewhat more closely to the internal elastic lamina than did refractile crystals of cholesterol. Approximate measurement of this relatively lipid-free "rind" of intimal tissue was 50 to 200 microns. Often in cases where such a rind appeared to exist at most parts of the circumference, here and there lipid material had broken through, so to speak, and was in contact with the internal elastic lamina or media. (Indeed in a few instances there appeared to be small scale extrusion of lipid material into the media.)

A rind of lipid free intimal tissue was by no means a constant feature however. In a considerable proportion of large atheromata the lipid material was in contact with the internal elastic lamina almost throughout its extent. Whether the site of small lipid particles at death corresponded to the site of their primary deposition or formation was not clear. Large (and thereby immobile) crystals were never found in contact with the outer walls.

It was noted that the field occupied by the lipid material was not round, even in cases which were appropriately described as "atheromatous abscesses", but was of crescentic shape, in conformity with the configuration of the atherosclerotic plaque as a whole. In some lesions of simple structure the lipid material was distributed in diffuse form while in others it was curiously concentrated in, and confined to, a particular layer or region. Where an atheromatous abscess existed, larger crystals of cholesterol were characteristically found at the junctional area between organised tissue and necrotic debris; again, large crystals were not invariably found at this junctional area, and some of the largest were found in the depths of the necrotic material. Really large cholesterol crystals were typically absent from fully organised parts of the lesions.

The term "atheromatous abscess" is adopted in the sense of an area composed largely of "necrotic" debris which contains lipid material. A few ill-defined strands of tissue staining as for collagen may nevertheless be dispersed throughout a predominantly necrotic lesion. I do not use the term however where the lesion is soundly laced across by collagen staining fibres, no matter how large the plaque nor how much lipid it may contain. It was not found an easy matter to define the limits of an atheromatous abscess in the unstained frozen sections, nor in those stained for neutral fat, although an approximate junctional area could be made out. The boundaries of the abscess were more clearly delimited in paraffin sections stained by van Gieson's stain. When comparison was made between these and the corresponding frozen sections it seemed that the point at which collagen staining ceased and the necrotic material began in some instances bore no very close relationship to the general disposition of lipid staining or of cholesterol crystals. The point made here is that sometimes an essentially similar distribution of fatty material may be found in the atheromatous abscess and in the organised portions of the plaque. In other cases, as just noted, the junctional area and the depths of the necrotic material were marked by cholesterol crystals of large size.

When the configuration of collagen fibres was examined in the neighbourhood of an atheromatous abscess, there was little to suggest that the necrotic material had been "walled off" by fibrous tissue - as would have been the fate of a chronic sterile abscess in extravascular sites. Nor was there necessarily much evidence of cellular activity in this region. Indeed the collagen fibres in most instances followed their concentric direction (in respect of the arterial lumen) until they dwindled in size, number and staining quality at the boundaries of the abscess (see Diagram 8:4(a)). In others there was a change in the direction of the fibres as if to enclose or by-pass the object in their path (b). Rarely did they seem to encircle the necrotic area in a continuous



"The fatal issue most frequently arises as the result of a new and different type of necrosis, fibrinous or fibrinoid, arising focally in the fibrous tissue near the lumen and extending to the endothelial layer. Endothelial necrosis is followed by thrombosis."

Leary , 1935 a.

fashion (c). In other lesions of similar gross appearance the fibres swept across the atheroma in unbroken span, entrapping in their meshes fatty material (and, I think, also small aggregations of necrotic debris). In such cases one could not have told from the H. and E. or van Gieson stained paraffin sections alone that large quantities of lipid had in life occupied the collagen network.

( Sometimes on looking at sections through atheromatous abscesses I have thought the appearances in the centre of the plaque in keeping with necrosis of a previously organised tissue. At other times, and in other sections, I have on the contrary thought that the central "necrotic" areas represented material not yet organised (and perhaps never to be organised). The question arose therefore was the boundary between fibrous tissue and unorganised debris the point at which collagen formation had halted, or was it the limit reached, by necrosis? At this juncture I wish merely to indicate that the issue is by no means decided to the effect that the necrotic central portions of some atheromata are the product of tissue breakdown. It may well be otherwise.

So far the description has concerned atheromatous lesions of relatively uncomplicated construction. Where by contrast the lesion was formed of a compound arrangement of crescentic formations, as described in the early part of this chapter, the distribution of fatty material was likewise complex. Indeed the distribution of lipid often directed attention to, and emphasised the crescentic formation of, the underlying fibrous structure. In these instances a common trend in the distribution of lipid could be discerned. The fatty material tended to be concentrated in the deeper or more central portions of each crescent. In this way the lipid distribution in individual crescents of intimal tissue conformed to the distribution found in single plaques of simple composition. Ill-defined crescents of scattered lipid material were thus separated from one another by more clearly-defined layers of fibrous tissue. The fibrous tissue could be of varying thickness and of scanty or absent lipid content. This is well seen in 19 ADA 2:6 micro. and is illustrated in Diagram 3 (f).

"The foregoing experiments..... suggest that atherogenesis is a discontinuous process even when atherogenic stimuli are continually operating. When these stimuli are intermittent, atherogenesis is certainly intermittent." Katz and Stamler, 1953

"Once atheroma formation occurs, secondary sclerotic processes supervene. These are slowly developing changes, gradual rather than episodic. They are primarily responses to the tissue irritant effects of cholesterol."

Katz and Stamler, 1953.

Katz and Stamler note that the aortas of experimental animals fed cholesterol for long periods show "fresh atheromas adjacent to, as well as superimposed on, old fibrosed, calcified lesions". They cite this evidence, together with similar observations in human specimens, in support of the concept that "atherogenesis is a focal, discontinuous, episodic process, with acute (primary) and chronic (secondary) phases.

These authors offer no satisfactory explanation for the phenomena observed.



**FURTHER POINTS IN THE "ORGANISATION" OF THROMBUS:**  
Race Between Autolysis and Sclerosis

I wish to turn again for the moment to the "organisation" of intravascular thrombus. It has already been noted that, after an interval, changes could be recognised in thrombus that had formed on an intimal surface. (Aspects related to canalisation have been considered in Chapter 7, and a certain amount of repetition is unavoidable.) The manner in which the fibrin network was gradually converted into, or replaced by, collagen at the interface between thrombus and the underlying intimal tissue has also been described.

In the course of this process, lifeless thrombus was gradually encroached upon from all sides, not only from its base on the pre-existing intima but also from its luminal surface. (It was thought that endothelial investment of thrombus preceded, or proceeded pari passu with, collagen formation at this site, but observations were insufficiently critical for certainty upon this point.) While collagenous change was gradually advancing it should not be imagined that all other changes in the thrombus were suspended. In the case of larger thrombi, such as occurred in vessels larger than the coronary arteries, autolytic changes can be recognised in the more deeply placed portions (see, for instance, section of subclavian artery). I had no reason to suppose that thrombus in the coronary arteries was likely to behave in any fundamental way differently from thrombus in other intravascular sites, but I have an insufficient range of observations for satisfactory comparison.

My material from the coronary arteries falls into four groups:

(1) thrombus up to 4 (and 6)<sup>\*</sup> weeks duration, (2) thrombus of 5 to 8 months duration, (3) thrombus approximately 2 years old, (4) lesions probably thrombotic in origin of unknown age, or of considerably greater age than 2 years.

One of the features which struck me as remarkable was the length of survival of the red cell as a recognisable structure. In the course of a few weeks, perhaps 3-4, the outlines of some of the red cells was somewhat blurred and

\* 6 wks x 1

the cells were clumped together. They looked degenerate, but while one would have supposed that some haemolysis would have taken place, I had no direct evidence of this. Ghost-forms were rarely evident. In complete occlusions of 5 to 8 months in age the ill-defined but heavily stained forms of red cells could be recognised without undue difficulty in their central portions and composed a considerable proportion of the necrotic debris. (Even after 2 years the necrotic debris in the centre of complete occlusions bore an appearance in its granular formation still suggestive of its origin from red cells. In addition, well stained, clearly defined red cells were present in places in the lesions 5 - 8 months and 2 years in age, but these were regarded as newcomers to the field.) This remarkable delay in lysis of red cells must, I think, be without parallel in bleeding outside blood vessels.

It seemed therefore that in the depths of a segment of artery obliterated by thrombus the red cells are enclosed as in a sarcophagus, and remain there undisturbed, changing only very slowly. In the more vigorous organisation that takes place at the ends of such a segment and in mural thrombus, I imagine that, for the most part, the changes in the red cells will be accelerated.

White cells were evident in the recent thrombi, but whether they had migrated after its formation or were entrapped at the beginning was not clear. There was no evidence of degenerate nuclei in the older thrombi in the coronary arteries, but degenerate nuclear debris was found in the larger thrombi from other sites. On the fate of blood platelets or their importance in the composition of the thrombi I have no observations.

Fibrin which had not been replaced by, or converted into, collagen showed slow degenerative changes. In the early thrombi - up to 6 weeks - there was a clearly defined fibrin network, stainable differentially with methyl violet. By 5 - 8 months the affinity for this stain was uncertain and a fibrin network

"The nutrition of the newly formed fibrous tissue is dependent upon imbibition from the lumen. As the fibrotic layer increases in thickness, the nutrition of those portions which are most distant from the lumen tends to suffer. The lesions are usually eccentric, the narrowed lumen dislocated to one side. . . In advanced lesions it is usual to find a crescentic region of necrosis of those portions of the intimal tissue most distant from the lumen, i.e. next to the media. The necrosis of the intimal tissue tends to be preceded or accompanied by a deposit of fat either in droplets or more diffusely along the broad collagen bands, which often make up the deeper layers. Lymphoid cell infiltration, absent from the early stages, tends to occur at this time."

Leary, 1935 a.

was no longer evident. At 2 years the old thrombus was represented by a somewhat coarsely granular amorphous debris with staining characters identical with the non-lipid material of an atheromatous abscess. That is to say, it was eosinophil in H. and E. staining while in van Gieson's stain it had no affinity for acid fuchsin but was of a pale khaki colour. It had inconstant or absent affinity for crystal violet in Weigert's fibrin stain. In the few instances in which the stain was used, the staining properties of this material in acid picro Mallory fibrin stain paralleled the affinity for crystal violet.

In the organisation of a thrombus therefore we may find a zone of collagen at its periphery and in its centre an area of necrosis. Eventually these two processes - organisation and autolysis - come into contact. My impression was that very little change took place thereafter, or at least that the process of organisation proceeded much more slowly. The appearances suggested that the "necrotic" debris derived from thrombus neither favoured the ingrowth of collagenous tissue nor excited the attentions of macrophages nor the development of vascular tissue. One wondered whether by the time autolytic changes had reached this stage the opportunity for organisation had passed.

I envisage a race between collagen formation and autolysis. So long as the fibrin network and integrity of red cells persist, fibroblasts can lay down collagenous fibres, and vascular and other cellular tissue can advance. Whenever the autolytic process has reached the stage of liquifaction the race has been lost. (It will be recalled that a similar train of thought was pursued in connection with canalisation.) I think it is reasonable to suppose that in mural thrombi and the ends of complete occlusions in contact with flowing blood, especially where additional advantage comes from canalisation, autolytic changes will be relatively delayed and the activities of the



fibroblasts enhanced. Whereas the reverse will obtain in the central portions of complete occlusions and in the depths of large unfissured thrombi.

In the case of shallow mural thrombi one would imagine therefore that the process of organisation would usually be successful in reaching completion before autolysis has rendered the material unacceptable to tissue growth; and that in more massive mural thrombi, autolytic changes might render the centre of the field too boggy for the support of a fibrous structure.

It would be in keeping with this concept were atheromatous abscesses characteristically found only in larger lesions, and were shallower mural plaques never the seat of "necrosis". Indeed the concept was closely borne out by the sections of diseased coronary arteries examined in this investigation. No instance was found of necrosis in the centre of an atheromatous lesion which occupied less than  $1/3$  of the original lumen area. Whereas necrotic centres were frequently found in the larger lesions.

The presence or absence of necrosis was not, as might be expected, explicable on this simple basis in every instance. Thus, lesions which occupied three-quarters or more of the original lumen area were not infrequently without necrotic centres; while, at the other extreme, the shelf of fibrous tissue separating a large necrotic area from the lumen was sometimes very narrow. (This could apply also to the shelf dividing the innermost crescent from the remainder of a larger compound atheromatous plaque.) I am cautious therefore in claiming for the concept just put forward more than a partial explanation of the phenomena observed. It is possible that discrepancies in the composition of two lesions of comparable size may have been related to differences in the original composition of the thrombi. Nor do I wholly discount the classical view that secondary necrosis may occur in the centre of a large, previously organised, atherosclerotic plaque. I merely suggest that this may not be the only, or indeed the usual, origin of centrally placed necrotic debris in atheroma.

These suppositions depend on the assumption that some degree of diffusion of oxygen and percolation of nutrient bearing serous fluid takes place in the thrombus and intima; and that those portions more distantly placed from contact with flowing blood will be at a disadvantage in this respect.

Christianson, 1939, injected various fatty substances into the femoral arteries of dogs and observed that most of the injected material was rapidly absorbed, but cholesterol tended to remain and to provoke a fibrous reaction.  
Morgan, 1956.

"There is a suggestion that metabolism of the lipoids within the cells is responsible for the stimulating effect upon the neighboring connective tissue. Free lipoid, in lipoidosis, does not have this effect."

"The deposit is evidently bland and does not provoke a fibrous reaction even in the very young"

Leary, 1935 a.

DISTRIBUTION OF LIPID IN RELATION TO "NECROSIS"

To turn again to lipid, what, it may be asked, has necrosis in the centre of an atherosclerotic lesion to do with lipid deposition? Perhaps quite a lot. If so, foregoing considerations have been of fundamental significance.

It was noted with interest that lipid accumulation occurred particularly in the region of necrotic debris. Large crystals of cholesterol and abundant stainable fat were actually embedded in the lifeless debris as well as in its neighbourhood. How it got there or whence came it are other matters. At this point, I wish to put forward the suggestion that fatty material had accumulated particularly in these portions of the lesions because of some underlying difference in the tissue, rather than the other way round. That is to say, lipid had developed, or been deposited with special predilection, in the deeply-placed, necrotic debris found in the centre of old-standing thrombus. The peripheral portions of the thrombus had meanwhile become organised and had formed part of the **structure** of the intimal wall.

There are of course alternative explanations. It can be held that lipid merely tended to accumulate in the depths of the thickened tissue and as the lesion increased in bulk, through lipid deposition, necrosis took place in its centre. In such circumstances necrosis and the greatest concentration of lipid could have coincided in position without other inter-relationship. The cause of necrosis in this event would simply have been one of distance from a surface in contact with flowing blood. The possibility may also be entertained that lipid itself can exert a harmful influence - which I doubt.

Ribbert, 1904, claimed that plasma containing lipid infiltrates the vessel wall and initiates atheromatous changes. Support was given to this view by the observations of Aschoff, 1907, Lemoine, 1912 and Anitschkow, 1913.

Morgan, 1956

- 1 The fatty acid spectrum of total lipides of plaques is very similar to that of serum.
- 2 The fatty acid of cholesterol esters include about 40% linoleic acid, otherwise are similar to fatty acids of total lipides.
- 3 The cholesterol esters of serum and plaques are quite similar.

Tuna et al., 1957.

see also: Wright et al., 1959 Lancet 2: 594.  
"Cholesterol ester fatty acids in atheroma and plasma."

The position of circulating lipids and lipoproteins in health and in coronary artery disease has been concisely reviewed by Oliver and Boyd, 1957, in the Postgraduate Medical Journal.

53

Although serum cholesterol in experimental atherosclerosis is usually raised several fold, atherosclerotic lesions have been reported as the result of dietary regimes with only minimal or moderate elevations of serum cholesterol, (e.g. Stamler et al., 1951, in chicks, in which the elevation was from a mean of 90 mg % to 140 mg. %). (Also Anitschkow, 1933)

Katz and Stammler, 1953.

"The various lipids in atheromatous lesions are in proportions approximate...to those normally found in the serum."

Duff and McMillan, 1951

THE ORIGIN OF LIPID IN INTIMAL LESIONS

It is generally assumed, with the support of a great body of indirect evidence, that the lipid found in atherosclerotic lesions derives from deposition of blood lipids. There is evidence to suggest that particles of large molecular size may be deposited in the arterial intima from plasma as it percolates through this tissue (Gofman et al., 1950).

Lipid fractions in the blood serum and in atheromata have been compared and found to correspond qualitatively (Tuna et al., 1957; Böttcher et al., 1958). Much attention has been given to correlation of serum lipid levels and clinically recognised human atherosclerosis. In carefully controlled series of observations trends in serum lipid values which differ from control groups have been demonstrated in subjects with coronary artery disease (Oliver and Boyd, 1953, 1955; Gertler et al., 1950; and others).

A detailed discussion of this aspect of the subject would not be appropriate in this presentation. Suffice it to say in general terms that, while it is evident that there is some correlation between atherosclerosis and plasma lipid levels and colloidal stability, a causal relationship of the one to the other has not been established. The differences found in the levels of serum lipid fractions in groups of coronary disease cases and controls is not large in contrast to the tremendous differences that may exist in the lipid content of arterial lesions. The marginal difference between the serum lipid levels in the abnormal and control groups may none the less be critical.

But there are many features of atherosclerosis not least of which are the distribution of fatty material within the lesion itself, as detailed earlier, and the wide variation in the severity and localisation of the lesions which cannot be explained on serological grounds alone. Although fatty accumulations can be induced in the previously normal intima of the aorta of small animals by alterations of normal levels several fold, it is far from proved that lipid deposition has a primary place in the pathogenesis of atherosclerosis in man.

Before discussing the possible deposition in the arterial intima of serum lipid, it would be pertinent to question whether intimal lipid accumulations might have other origins. Even the most unlikely avenues might merit exploration. I began to wonder whether it could be possible that change in the material derived from thrombus could result in lipid formation. It seemed improbable, but in a field in which so little was known with certainty, I decided to examine thrombi as they presented with this point in view. I found the evidence in the coronary arteries conflicting and indefinite, but I shall mention it shortly. As in the examination of fibrin-collagen changes I turned to the large sized thrombi which had formed in the atria. In my series, after this idea occurred, I encountered three large atrial thrombotic masses of long-standing. The true age of these thrombi was unknown but they were firmly adherent, were undergoing incorporation as already described into the underlying endocardial tissue and presented a shiny, one might almost say greasy, brownish-grey surface on section. I cut frozen sections from each and stained them with Scharlach R. To my surprise in each case there was evidence of stainable fat. This took the form of multiple small droplets deeply placed in the thrombus. An example taken from the section illustrated in 13 LA thrombus is shown.

The fat droplets were widely distributed throughout the deeper portions of the thrombus. They were found in Case 13 at least 5 mm. from the surface and similarly in Case D9. The tissue in which they lay was obviously showing aging changes, staining strongly eosinophil as for fibrin and haemoglobin in Case 13, but having lost its affinity for crystal violet. It had however still a fibrous structure, or so it appeared. In Case D9 the material had an almost myxomatous appearance in the centre where most of the fat lay but fatty particles were also found in the peripheral parts into which had advanced well organised collagenous tissue accompanied by blood vessels. In Case MHA 5125 (not belonging to injected series) the fat was restricted very clearly to the central portions of the auricular thrombus. In each instance there were degenerate white cells and it was wondered whether the fat might have been the product of their disintegration. There was no close relationship, however, between the distribution of fat and the distribution of the white cells, or nuclear debris. As far as could be judged the lipid was not intracellular but certainty is not expressed upon this point.

There is insufficient lipid in the blood for the breakdown of red thrombi to give rise to a significant quantity of sudanophilic material.

Leary, 1938

"The quantity of lipids that accumulates in atheromatous lesions is so large as to preclude the possibility that they originate from simple breakdown of tissue in the intima."

Duff and McMillan, 1951.

The fat stained strongly with Scharlach R. There is no question that it was a staining artefact, for it was reproduced on repeated sections in identical position. The droplets were small, the larger ones being, at a rough estimate, half the diameter of a red cell, while many were minute. They occurred however in small aggregations. The appearance they presented was very reminiscent of some aggregations in the intima itself. So also was the material in which they lay. Viewed by polarised light, a high proportion of the larger droplets revealed the presence of tiny doubly refractile crystals. It was thought that these might indeed be cholesterol.

The fascinating problem was the origin of this lipid. If it were deposition of plasma lipid, under what agency was it differentially deposited at such a distance from the surface? Could it be that serum diffused throughout these relatively massive thrombi and that some factor favoured fatty deposition in the depths of the thrombus to a greater degree than at the surface? Or that the fat was the product of lipid containing white cells or platelets, was liberated on their disintegration and removed differentially from the surface layers? Or could it be that it was engendered from the substances composing the thrombus, a product of autolysis? I do not hazard any answer to these questions but merely record a finding which caught my imagination at the time. I would only ask further, is it beyond the realm of possibility that the conversion of protein into lipid material, which is commonly acknowledged to occur in the liver and perhaps in other tissues, should not take place in thrombus, at a very much slower rate? I would concede from what is commonly known that it is improbable but not that it is impossible.

Since making these observations I have noted that Duguid, 1946 refers to "fatty degeneration" of thrombi in the coronary arteries. Cholesterol development at various sites also received comment in this connection by Winternitz et al., 1938.



In the case of mural thrombi of the coronary arteries, the dimensions of the thrombotic masses involved are much smaller than in the cases of larger atrial thrombi which I have described. The closer the aggregation of lipid is to a surface in contact with flowing blood, the lesser is one's inclination to invoke autolytic changes rather than deposition from the lipid-laden blood plasma. The counterpart in the coronary arteries to the conditions existing in the depths of an atrial thrombus of large size would be most nearly found in the central portions of lengthy complete thrombotic occlusions, which had not been penetrated by the processes of canalisation. Accordingly I examined such lesions with the purpose of testing the concept of lipid as a product of autolysis.

The point was however not so easily brought to proof as it seemed at first sight. There appeared to be several such lesions in my preparations, in which a length of 1-3 cm. of artery was completely blocked by a deep-orange coloured, structureless material which had clearly had its origins in degenerated blood products. One of these is shown in colour transparency, 12 RC 2:1b. In these lesions, remote from contact with flowing blood, large quantities of crystalline lipid were demonstrable. The difficulty was not in demonstrating lipid in this material, but in determining the true nature of these old-standing occlusions. Could one be certain that thrombosis had occurred without disruption of the intima, then the appearances would be suggestive to the point of proof. The probability existed however that in Cases 11 and 12 the obstructive mass was really a large intimal haematoma undergoing degeneration (see remnant of previous luminal lining in 11 "E" 2:1). The occurrence of haematoma as the result of haemorrhage into an atheromatous plaque already loaded with crystals of cholesterol would of course completely invalidate any conclusions regarding the development of cholesterol subsequent to occlusion.

In regard however to deep orange pigmentation, complete occlusion and the presence of necrotic debris containing cholesterol crystals, the appearances were identical in Case 22 ADA, in which there was nothing to suggest haematoma, and were entirely consistent with thrombotic occlusion. In Case 7 RC crystals were likewise found in a long stretch of complete occlusion thought to be thrombotic and 7 months in age.

Curiously enough, lipid droplets were found in recently formed thrombus in Case 20 (20 ADA 3:3). In this instance no doubly refractile material was demonstrated. The fatty droplets were present in identical distribution in 2 stained and one unstained frozen section. (Photographic demonstration in monochrome has not been possible.)

(In 22 RC occlusion occurred as the result of dislodgement of the contents of a large atheroma and associated thrombosis. In the sections cholesterol crystals could be seen interspersed in the thrombotic arterial and in the injection medium.)

If I now venture some inferences for atherosclerosis from this finding, I should like to make it clear that they are tentative. If we consider the atherosclerotic plaque derived from thrombus, initially the clot tends to take up a bulky concentration or to lie across the artery lumen. By compression (or is it from shrinkage ?) the bulkier centre recedes more towards the artery wall than do the thinner margins. Supposing for the moment that the protein material (which has much water in its constitution) were totally converted, dry weight for dry weight, into fat then it would occupy a very much smaller volume and the lesion originally formed from thrombus would shrink markedly. If, however, only a fraction of the protein substance were to be converted into lipid, say  $1/3$ , then the crescentic mass of material which would result would correspond closely to the configuration of many naturally occurring atherosclerotic plaques.

I very much doubt that the "dry" weight of 1/3 of the protein could account for the very large amounts of fat that is commonly present in these lesions. Yet, on the other hand, if no diminution in the bulk of material took place in the development of an atherosclerotic plaque from thrombus and if, in addition, large amounts of fat were to be deposited, then the lesion would progressively encroach upon the lumen (which would be in keeping with some views on atherosclerotic arterial narrowing).

Further speculation arising from the finding of fat in the depths of thrombus would be inappropriate in the lack of greater numbers of observations. I have a suspicion that the large amounts of lipid in atheromata are, at any rate for the most part, otherwise derived, but the finding perhaps merits further and more critical enquiry.

Theoretically, a number of processes may be invoked to account for the presence of lipid in atherosclerotic plaques. As suggested above, lipid may develop in situ as a product of autolysis. If on the other hand it be held that deposition takes place from the blood plasma, the question is invited - which comes first, intimal sclerosis or lipid deposition? Again, is the one the cause of the other, or are they inter-related, as components of a vicious cycle? It has been held that lipid deposition provokes fibrosis. I concede that this may be so. I am more certain however that fibrous thickening favours lipid deposition. It would be reasonable to suppose that some factors of plasma lipid chemistry favour intimal lipid deposition in a general way, and that structural changes in the arterial intima condition its occurrence, severity and distribution. I shall now turn to the examination of "early" atherosclerotic lesions.

THE "EARLY" ATHEROSCLEROTIC LESIONEvidence from Frozen Sections

So far attention has largely been directed to the lesions of greater severity, on which the interest in this investigation mainly centres. Opportunity was however taken to examine a considerable number of early lesions microscopically, and also coronary arteries showing intimal thickening without recognisable fatty accumulation in the gross specimen (2 mm. thick sections). An example of a very small lipid-containing lesion in a section showing intimal thickening is illustrated in Figure 21 RC 4:2 micro. A small accumulation of fatty droplets is seen at one point in the section. (This section was taken less than 1 mm. distal to the point at which a small branch left the artery and the occurrence of lipid accumulation here may be not without significance.) The lipid droplets were stained with Scharlach R. and tiny cholesterol crystals were seen in the cold specimen by polarised light. A few areas of very fine diffuse staining by Scharlach R. were seen at one or two other points in the intima. In the neighbouring H. and E. stained paraffin sections it would have been impossible to have told that lipid had been present in this intima. The only cell types represented appeared to be fibroblasts. No "foam cells" corresponded to the distribution of lipid.

In a lesion of this sort there was nothing to indicate whether the development of intimal thickening was a gradual or a rapid process nor whether fibrin deposition took place on the surface, within its substance or not at all. The lipid likewise may or may not have resulted from deposition of serum lipid. Its very localised distribution however is striking. In this it bears similarity to experimentally induced lipid deposition, but it differs from such lesions in that the intima is diffusely thickened and the

The appearance of lipid cells provokes no fibrosis.  
(Leary, 1935 a.)

"Intimal fibrosis and lipide deposition are  
separate pathological entities."

Moon and Rinehart, 1952, (citing Dock, 1946,  
and Moschowitz, 1950).

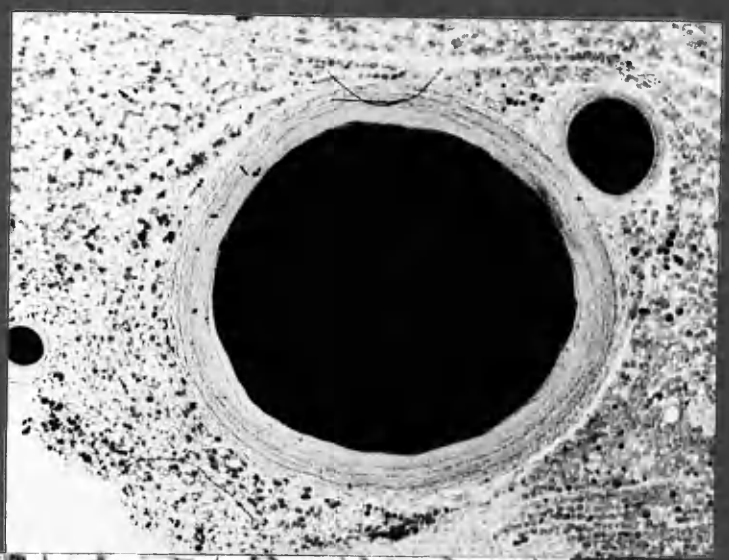---

"The lack of correlation between lipide and  
early arteriosclerotic change leads us to  
believe that the deposition of lipide is not  
the initiating factor in the development of  
coronary arteriosclerosis."

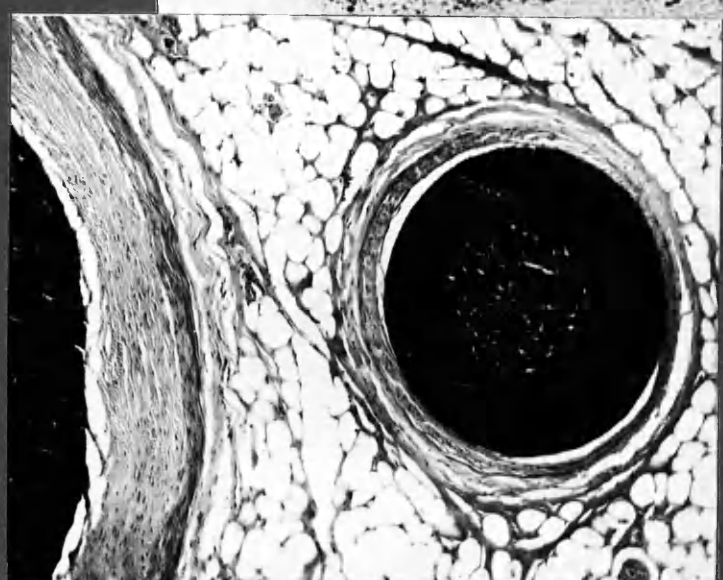
Moon and Rinehart, 1952.

---

Sch. R



x18



H&E

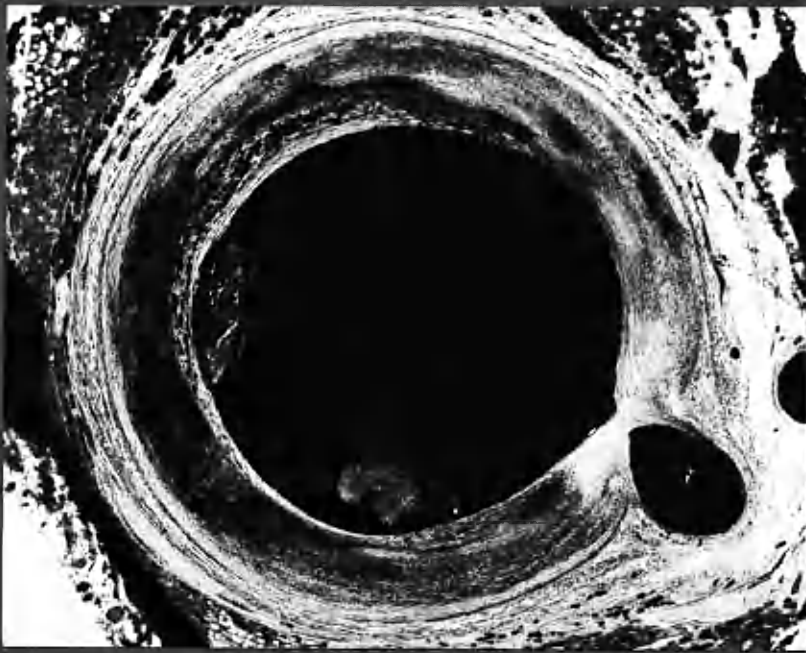x70

POLA



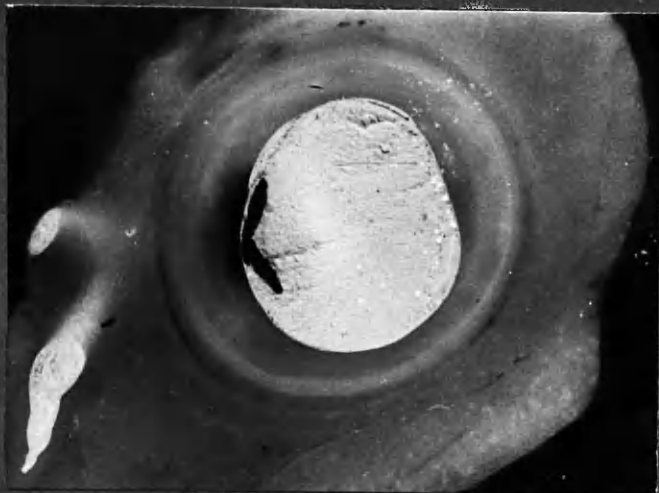x58

20 ADA 219 micro  
20 RC 1-A b.



x 10

20 ADA 219 micro      Sem. R.  
Intimal thickening      lipid deposition      loosely attached  
medial thinning



x 12

20 RC 1-A b.

The dark shadow underlying clot contained much cholesterol, as confirmed in frozen sections.  
Concentric layers of intimal thickening.

lipid is not contained in foam cells immediately beneath the endothelium. Generalised thickening of the intima in the presence of small atherosclerotic lesions was a common finding and is typified by this section.

It has seemed to me that lipid accumulation in the intima is uncommon except in the presence of antecedent thickening of that structure to a certain critical degree. In the case of early lesions such as the one just described it seemed a long stretch of the imagination to suppose that the localised presence of lipid was primary and at the same time was the cause of the generalised intimal thickening. It seemed much more probable that the sequence was the other way round. I had however too few examples of micro-sections (frozen) with which to make a satisfactory test of this hypothesis.

(In addition to selected blocks of the coronary arteries, paraffin sections were routinely taken in all cases, including controls, in such a way that at least the anterior descending and left circumflex arteries were included. Frozen sections were taken routinely from each of the last 15 cases of coronary artery disease, in which the main interest centred on the lesions of greater severity, and from only a few control cases. Accordingly I have for reference frozen sections from only about a dozen coronary arteries at points where intimal lipid deposition was minimal or absent.)

On the other hand, I had abundant examples of lesions of all degrees of severity in the 2 mm. thick serially mounted sections. The interest lay in sections through arteries that were not the seat of atherosclerotic lesions; and also in those passing through early or small atherosclerotic plaques. It was not possible to recognise with certainty in these specimens the presence, or more particularly the absence, of minimal fatty lesions, such as shown in 21 RC 4:2 micro., but slightly larger accumulations, accompanied by localised intimal thickening, could be distinguished. It must be emphasised that the examination of these gross specimens was insufficiently critical to rank with the examination of thin frozen sections. Nevertheless



"No direct or consistent relationship of lipide to the early lesions could be demonstrated."

"If alterations in lipide metabolism play a role in the development of coronary arteriosclerosis, such derangements are localised to pre-existing fibrous plaques."

Moon and Rinehart, 1952

it was thought worth undertaking as a crude test of the probability of the concept of intimal thickening as a primary phenomenon and not merely as an accompaniment of, or sequel to, lipid deposition. In this it had the advantage of numbers, freedom from artifact and serial sequence.

Before indicating the findings made on this examination of material unfamiliar to others the limiting factors in the observations are indicated below.

#### Evidence from Gross Specimens (2 mm. thick mounted sections)

The specimens were scrutinised for this purpose using a binocular dissecting microscope at a magnification estimated to be x 45. It was found possible in the case of arteries which were not the seat of advanced disease to distinguish the medial coat from the intima with a fair degree of assurance. Indeed with appropriate lighting the internal elastic lamina could sometimes be made out as an incomplete dark line.

Incident light using a bright focussed source at a very narrow angle gave the clearest differentiation. Transmitted light through a small aperture was the next most useful illumination. The direction of the light rays were important.

Under optimal conditions the medial coat was clearly seen as a band of even width and texture, translucent and rather more straw-coloured than the intima. In transmitted light the intima was translucent to about the same degree as the media and of a slightly more orange tint.

Fatty material was a glistening white in incident light and cast a dark, granular shadow on transmitted light. The presence of lipid could be detected by these criteria in the smallest lesions that raised a definite localised thickening.

The presence of lipid was recognised with about the same degree of assurance that tuberculous infiltration is recognised in the radiograph of the chest; a negative finding likewise having no sure significance.

Estimation of the thickness of the intima was made by direct comparison with a scale, viewed under the same conditions.

The findings are expressed in Diagram 8:5. (1) Lipid accumulations were recognised only where the intima was definitely thickened. Thickening up to about 200 microns commonly occurred without crude evidence of lipid, but for the most part intimal thickening beyond this range always contained recognisable lipid. Where the intima was less than 50 microns in thickness,

Geiringer, 1951, measured the thickness of the

intima of the upper 1/3 of the anterior descending artery in routine autopsy cases.

These measurements were made on fixed tissues, with the artery wall not stretched.

Accordingly the measurements are not directly comparable with those made in the present investigation.

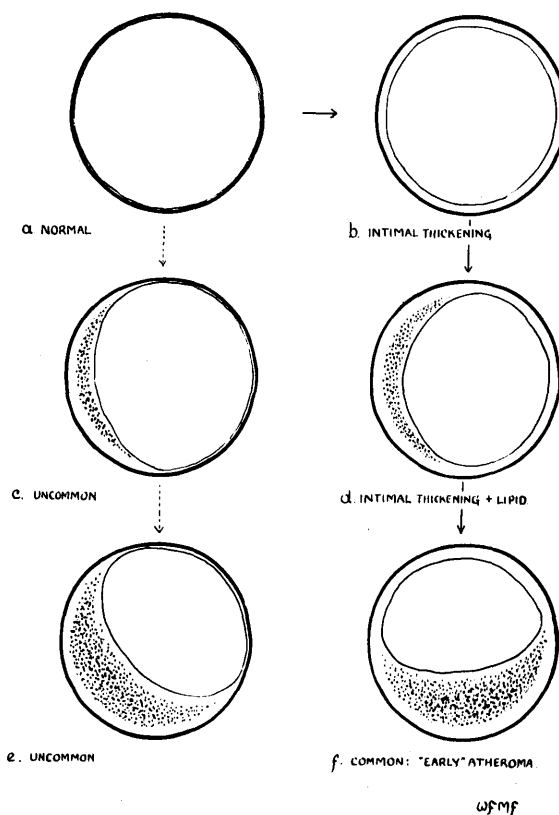
	Intimal thickness
Epicardial position	0.407 mm.
"Mural" ..	0.193 mm.

Normal values for coronary arteries are given as 0.35 mm. and for the aorta as 0.5 mm.

These measurements were made on fixed tissues, with the artery wall not stretched.

Accordingly the measurements are not directly comparable with those made in the present investigation.

DIAGRAM 8:5 INTIMAL THICKENING AND LIPID ACCUMULATION.



lipid was never recognised. Between 50 and 200 microns the situation was variable, lipid being for the most part detectable where the intima measured 100 microns and more in thickness (Figures A,B,C). (2) Where a shallow crescentic lesion contained lipid in its centre and the lesion tapered off at the edges to 100 microns or so in thickness (which was usual (C) ) or less (which was unusual (D) ) lipid was not detected in those sectors of the intimal wall below 100 microns in thickness, in most cases, and never below 50 microns. (The truly normal intimal lining was not distinguishable at all in these 2 mm. thick sections, and measured only a few microns in thickness in the micro-sections of normal arteries.) (3) In shallow crescentic lesions, or in generalised intimal thickening greater than 200 microns, lipid was restricted to those parts of the lesion internal to a narrow rind of tissue, which was translucent and was regarded as "lipid-free" or at any rate "lipid-poor". In the case of shallow crescentic

lesions, this peripheral "lipid-free" zone was similar in thickness to the whole intima at other parts on the circumference where there was no lipid deposition (as shown in Diagram 8:5, C-F).

Thus the crude observations made on the 2 mm. thick sections appeared to support the relatively few observations made on stained frozen sections of minimal atherosclerotic lesions, and of intimal thickening without lipid deposition. It was concluded that lipid tended not to accumulate, unless in minimal amounts, in the intima of coronary arteries until thickening of that structure had exceeded a certain critical dimension, which appeared to lie between 50 and 200 microns, when measurements were made on the stretched arterial coats.

In this respect, there seemed to have been greater difference in critical intimal thickness between individuals than between different portions of the coronary arteries in the same case. It was therefore wondered whether individual variation in susceptibility to lipid deposition for a given thickness of intimal wall could be an important determinant in atherosclerosis.

I wondered too whether larger atherosclerotic lesions would also show this kind of lipid free intima at their periphery, and in that way give added support to the concept that thickening of the intima precedes lipid accumulation. But it has already been indicated that in the larger lesions this rule applied only to a proportion of cases. It seemed strange that there should have been this difference between the shallower and more massive lesions, had intimal thickening been a condition pre-requisite to the development of atherosclerotic plaques. Was it possible that the smaller plaques were not indeed the fore-runners of the larger but that each developed from the beginning as a smaller or a larger lesion (speaking of simple lesions only)? And that in this way there was a difference between them from the beginning? Or could it have been, in the drift of fluid from the bloodstream outwards through the lesion, that in the older and larger

plaques lipid particles were displaced into the outer zone, beyond the point of primary lodging? Or, could primary deposition of lipid in this layer take place only when it was in the base of a large lesion? I have no answer to give to these questions. It would however be in keeping with a thrombotic origin for atherosclerotic lesions were larger simple lesions large from the beginning, and increase in the size of the lesions result, not from overall increase in bulk, but from subsequent and recurrent episodes of thrombosis. I have no evidence in this investigation that would seem to contradict this point of view. I feel that the gradual growth of atherosclerotic plaques from small to large should be regarded as only one of several possible processes in the development of the larger lesions; and not too readily assumed to be the usual or most important mechanism.

The deposit of lime salts in tissues is always an end-result of monumental character, marking the site formerly occupied by living tissue. From any standpoint calcification is of no importance in the aetiology of the lesions...

"The deposit of lime salts in tissues is always an end-result of monumental character, marking the site formerly occupied by living tissue. From any standpoint calcification is of no importance in the aetiology of the lesions..."

Leary, 1935 b.

"Moreover, as Buff (1935) pointed out, no one has postulated a disorder of metabolism to explain calcification in atherosclerosis."

Morgan, 1956

SOME OTHER FEATURES OF THE ATHEROSCLEROTIC PLAQUE

There are several features commonly found in atherosclerosis which I have scarcely mentioned in this chapter so far. These include intimal haemorrhage, intimal vessels, cellular infiltration of the intima, and calcification; also medial degeneration, degeneration of the elastica, cellular infiltration and haemorrhage in the adventitial coats. The first two of these, haemorrhage and blood vessels in the intima, will be given more detailed treatment. I wish only to make brief mention of a few points about the other features in passing.

Calcification

Calcification in the atherosclerotic tissue was frequently of great severity. The radiograph of an uninjected heart<sup>1</sup> shows the major coronary divisions patchily outlined by calcification of the intima. Calcification so interfered with the detail of arteriograms that latterly a final arteriogram of the excised arteries was taken after decalcification.

In the microsections of the coronary arteries, calcification was characteristically seen to accompany the necrotic tissue of atheromatous abscesses. It was however quite often found without any evidence of necrotic tissue in the same section. It was not established whether in these cases it was related to nearby necrotic material further up or down the artery. Its distribution, as judged in H. and E. sections, took the form of a wavy band surrounding the "atheromatous abscess", in the fashion of a watermark on fabric, and seemed to lend itself to interpretation along similar lines. It seemed as if a calcium precipitating material had diffused from the central necrotic material to meet calcium from fluid percolating through the lesions, and an insoluble calcium compound was precipitated a short distance beyond the margin of the necrotic area.

---

(1) Case 8, p. 2:80 (stereo.)



Perhaps the most significant point about intimal calcification is the unequivocal illustration which it affords of deposition of material from the blood serum after the formation of the plaque in the human artery, and in the absence of gross disturbance of blood chemistry.

A feature of calcification of intimal plaques important for the pathologist is the difficulty with which the artery may be cut in the fresh state. In this investigation **decalcification** was made a routine before attempting to section the artery. Artefact damage to the other delicate structures of the diseased artery was otherwise unavoidable. But also during life the rigidity of one portion of the artery wall resulting from calcification may well introduce shearing strains under the stress of effort or excitement. Intimal haemorrhages noted in the neighbourhood of calcification may indeed have been so introduced.

#### Cellular Infiltration of the Intima

Infiltration with round cells was frequently found in atherosclerotic lesions. The cells occurred for the most part in small aggregations in the deeper layers of large atheromata, but sometimes extensive sheets of such cells existed, especially in the peripheral zone. They were particularly found in the neighbourhood of haemorrhages, at the margins of atherosclerotic abscesses and in areas where there was also iron deposition. Sometimes cellular infiltration both of the intima and outer coats appeared to be related.

I came to no conclusions about the significance of round cell infiltration. Infiltrations seemed to occur in many apparently old established lesions. Where cellular infiltration and thrombosis of recent date occurred in the same section it was not clear whether a causal relationship existed between them, and if so in what sequence.

Adventitial infiltrations in coronary atherosclerosis were discussed, with bibliography, by Gerlis, 1956.

I cannot subscribe to the significance accorded to these lesions, which were attributed to local anoxia and were regarded as an indication that coronary artery disease was directly associated with the cause of death, and not merely as incidental phenomena.

Cellular Infiltration in Atherosclerosis

Infiltration with foamy cells was frequently found in atherosclerotic lesions. The cells occurred for the most part in small aggregations in the intima, but sometimes extensive sheets of cells existed, especially in the subintimal space. They were particularly numerous in the neighborhood of macrophages, as the majority of atherosclerotic lesions in areas where there was also heavy deposition of cholesterol crystals. In some cases, however, they were also observed in the intima of arteries which were free from atherosclerosis. In one case I observed a large area of intima in which there was a heavy infiltration of foamy cells. This area was situated in the neighborhood of a large atherosclerotic lesion, but some distance from the main body of the lesion. It was especially in the neighborhood of macrophages that the majority of atherosclerotic lesions in areas where there was also heavy deposition of cholesterol crystals were found. In some cases, however, they were also observed in the intima of arteries which were free from atherosclerosis.

With adventitial cellular infiltrations there was likewise no close correlation with recent thrombosis. Commonly iron deposition and haemorrhage were found in the neighbourhood of adventitial round cell infiltration. It was uncertain whether iron deposited in these sites was the product of adventitial coat haemorrhage or whether it had been transported from breakdown of blood pigment in the intima.

#### Medial Degeneration

Medial degeneration and degeneration of the internal elastic lamina accompanied each other. Stretching of the outer walls appeared to have taken place in sectors in which medial degeneration was found. One effect of medial coat stretching was that the encroachment upon the arterial lumen by a large atheroma was proportionately less than would have been suggested by the mass of the lesion - a point which was also noted by Crawford and Levene (1953). Whether the stretching was due to degeneration of the media, or the other way round, was not clear. Thinning of the media was found only in the sector occupied by an atheroma of large size. It was never encountered in relation to "early" lesions and was therefore not of primary significance in atherosclerosis. Moreover it was never observed in the relatively thin arterial wall opposite to an eccentrically placed atheroma. Atherosclerotic plaques seated upon degenerate, thinned-out, media were always of large bulk and it seemed likely that they had exerted a mechanical effect upon the outer coats.

It is commonly supposed that a coronary artery which is the seat of advanced, calcified, atherosclerotic narrowing is "rigid"; and that variation in the calibre of the lumen at this point cannot therefore result from contraction and relaxation of the medial coat. Admittedly in many lesions, where there is calcification and thickening of the intima at all points, this concept doubtless obtains. I would question that it holds true in all instances. In the majority of severe lesions the narrowed lumen was eccentrically placed,

close to the wall at one side. At this point it was often bordered for about half its circumference by an arterial wall of normal or nearly normal thickness. At such points the medial coat was invariably intact. It would therefore seem that the assumption that such arteries are "rigid" in this sense is only half-founded.

While on the topic of medial coat contraction in the presence of severe atherosclerotic lesions, there is a further consideration not without theoretical importance. Where contraction takes place in the region of evenly distributed intimal thickening, it would be reasonable to suppose that the resultant compression will likewise be evenly distributed circumferentially, no matter how substantial the lesion. On the other hand, where the lumen is close to the arterial wall on one side and the other side is occupied by a large, incompressible mass of atherosclerotic tissue, contraction of the muscle coat may well produce shearing strains between it and the relatively immobile atheroma. (Shearing strains will also occur in the region of areas rendered truly rigid by calcification.) It is probably significant that a proportion of intimal haemorrhages seemed to have originated at points where these shearing strains would be expected to be maximal. Thus, where separation of a large crescentic mass of atheroma from the artery wall existed, this had commonly taken place at the point where the lesion tapered off rapidly in thickness, to join the thinner portion of the intima - at the shoulder, so to speak, of the lesion. (The same site for separation from the arterial wall was noted for crescentic thrombi.) It was evident that haemorrhage into an atheromatous plaque had sometimes been produced traumatically in this fashion during life. Similarly, post-mortem damage to an intimal plaque tended to take place at this point in the lesion, as an artefact produced by shrinkage, rough handling or distension.

Stretching of the walls of the aorta in the presence of severe atherosclerosis is a familiar phenomenon. It was thought possible that this process might also occur in the coronary arteries. It may be commonly observed that coronary

arteries, the seat of severe obliterative disease, may, if dissected out, be surprisingly large. It was therefore decided to measure the diameter of the coronary arteries in disease, and for this purpose the anterior descending artery was selected, being the coronary artery of least variable size.

Measurement was made of the largest diameter, media to media, in the mounted 2 mm. thick sections. The details of this and other measurements appears in the chapter on Anatomy (Chapter 3). At this point it is noted that the average diameter in cases of coronary artery disease was 5 mm. and that the largest was 7 mm. in an unobstructed artery and the smallest 3 mm. in an artery which was completely occluded. If anything, stretching of the artery wall was more to be related to wide patency than to severe constriction or complete obliteration of the lumen. It appeared from examination of these arteries that, while a slight degree of stretching of diseased coronary arteries was usual, the degree to which it occurred seemed to bear little relationship to the severity of the underlying arterial disease. .

Without exception the arteries which measured more than 5 mm. in diameter were from large hearts, while those 4 mm. or less in diameter were from hearts of normal size. Correlation of artery size and heart size was fairly close.

Localised aneurysm formation of small size was observed in a few instances, as noted in Chapter 3.

### Elastic Tissue

#### Degeneration.

Degeneration of the internal elastic lamina was seen to accompany medial coat degeneration. Where the medial coat was stretched at a point of bulging, at the base of a large atherosclerotic plaque, and greatly thinned there was also at this point break in continuity and deficiency of the elastic lamina.

I formed no opinion as to which came first. At such points of medial and elastic

"Elastic fibres also develop at an early stage."  
Crawford and Levene, 1952

Microscopic

tissue degeneration, blood vessels were sometimes found entering - or leaving (?) - the base of the plaque through the breach so formed. Commonly at such points there was also round cell infiltration and sometimes haemorrhage.

The development of elastic tissue in atherosclerotic plaques.

Sections from every arterial lesion examined were stained for elastic tissue by Verhoeff's and/or Weigert's methods. Regrettably by the time opportunity presented for analysis and review of the material as a whole, and for the selection of sections for photography, these specimens showed varying degrees of deterioration. Attempts at re-staining and the staining of spare sections, were only partially successful. I had however already made the observation that the development of new elastic fibres more or less paralleled the collagenous fibre development. In direction of course and variation in density of deposition they likewise conformed to the supposed development of the plaques from successive layers of thrombus. Wherever a new blood channel had become established, with the development of a definitive arterial coat, elastic tissue formed an integral part of that structure. This applied alike to the incorporation of mural thrombus into the arterial wall, the formation of a main channel in canalisation and also smaller channels, including some intimal vessels. Good examples were seen in sections 1 ADA micro.(2) and 11 ADA 2:2 micro. There was no feature of configuration of new elastic tissue out of accord with the concept of atherosclerotic development from thrombus.

It was also noted with interest that fibrous intra-ventricular plaques, believed to have resulted from the incorporation of thrombus into the thickness of the endocardium, likewise showed layers of elastic fibres running parallel to the lines of stress.

INTIMAL VESSELS, "VASCULARISATION" OF THE ATHEROSCLEROTIC  
PLAQUE, AND INTIMAL HAEMORRHAGE

Some illustration and description of intimal vessels has already been given in connection with canalisation of occlusions. In this chapter the significance of intimal vessels in atherosclerotic plaques will be considered. In doing so, a certain amount of repetition of description is inevitable. Special reference will be made to the origins of these vessels and the complications which may stem from their presence in the intima of coronary arteries.

Technical Note

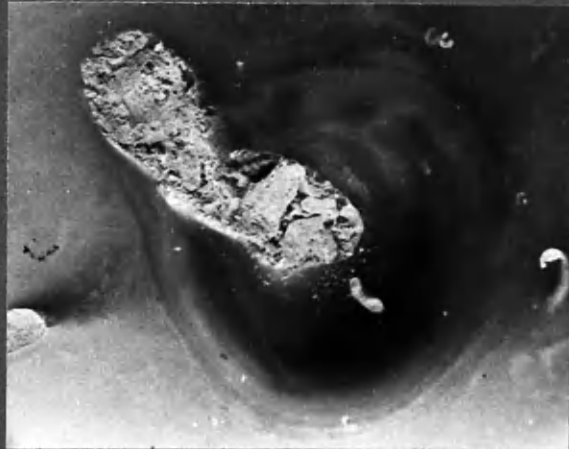
Three types of observation on intimal vessels were made: (1) Intimal vessels which had accepted the radio-opaque injection mass were seen on the arteriograms occasionally; and (2) were commonly revealed on the 2 mm. thick mounted arterial sections; (3) They were also observed in the microsections where they were recognised by their structure and by the presence of blood and/or injection medium in the lumen.

In this investigation, semi-serial sections through the entire 2 mm. block submitted for paraffin embedding were taken routinely. Where an intimal vessel took a course more or less in the plane of section, its origin from the lumen or from the adventitial vessels could be identified with comparative ease. On the other hand, the obliquity of its course might carry it for several millimetres in atherosclerotic plaques and for longer distances in canalised occlusions. Identification of its origin and course by conventional serial section methods would have been a formidable technical task. Winternitz et al. (1938) prepared as many as 1000 sections from a single lesion in pursuit of these vessels.

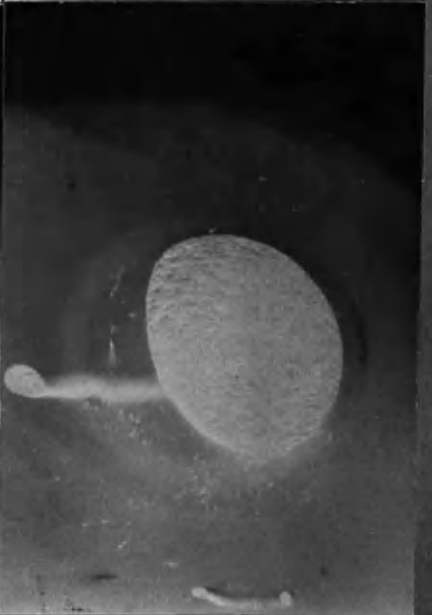
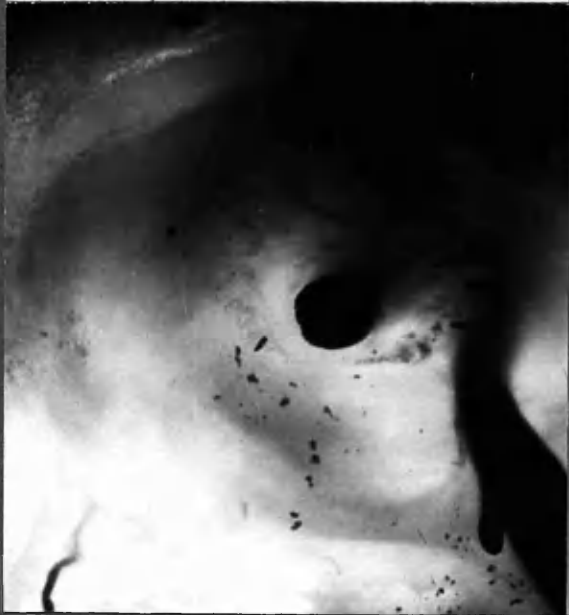


INTIMAL VESSELS

x12



x13



x20

19 RC 1:10 b.  
25 RC 4:1 b

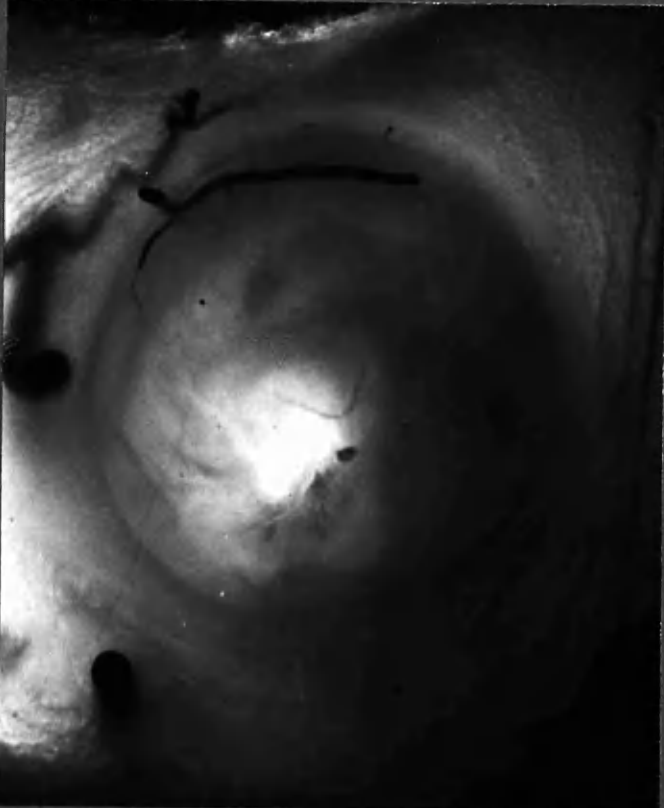
x 11

17 RC 3:8  
23 RC 2:4 b

INTIMAL VESSELS ARISING FROM ARTERIAL BRANCHES  
IN COURSE THROUGH THICKENED INTIMA.

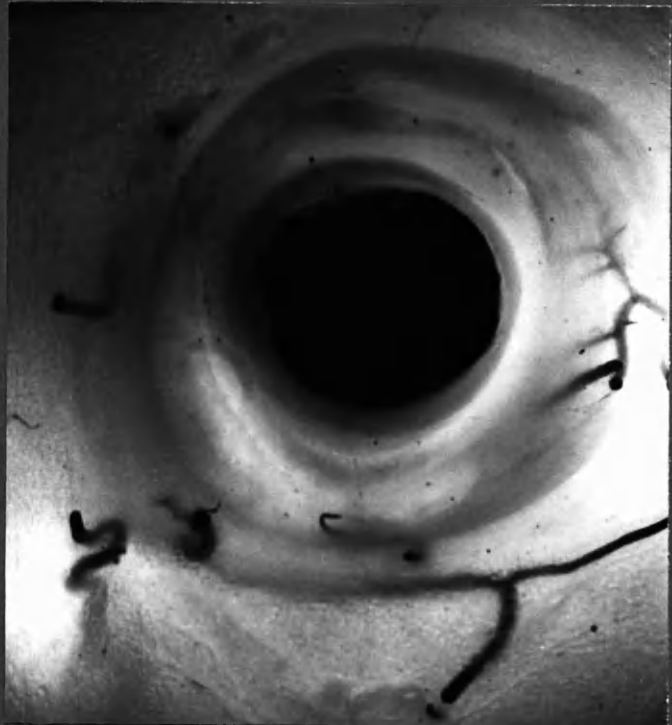25 RC

INTIMAL VESSELS ENTERING FROM  
WITHOUT.



x15

25 RC 5:26.



x15

25 RC 5:10a.

See also 22 LCxA 2:5a.

Examination of the neighbouring 2 mm. thick, serially mounted, sections were of the greatest value in this connection, and frequently permitted identification of the origin of injected vessels found in the microsections. Indeed I think that the method has advantages over serial microsections for this purpose.

It will be appreciated that identification of the luminal or adventitial vessel origin of intimal vessels could be made with assurance in many instances; and conversely that a negative finding rested on less secure ground. Statements about the absence of certain features have therefore been avoided. Although, in other sites, the injection medium used entered vessels of 15 microns lumen diameter with a fair degree of regularity, it was confirmed that intimal vessels are notoriously difficult to inject. Probably one of the difficulties arises from the compression of intima against tensed outer walls, which keeps pace with the injection pressure upon which filling depends.

#### Findings

The presence of injected intimal vessels in the inner portions of the thickened intima was recognised with ease in the 2 mm. thick sections. On the other hand a great many vessels seen at the periphery, which arose from the vasa vasorum and which at first glance appeared to be intimal, had not in fact passed through the medial coat. Difficulty in establishing this point was encountered particularly where the wall of the artery at that point had been cut obliquely. Again it is possible that some smaller vessels which had not received the injection medium may none the less have entered the intima; but this could not be ascertained in these specimens. These considerations apart, there remained a number of sections in which vessels carrying injection medium were without question seen to penetrate the medial coat from without and to enter the intima.

It is noted at the outset that injected vessels were never found in my preparations in the normal intima, nor in the intima that showed thickening up to about 200 microns in thickness. Nor were intimal vessels identified on the microsections in the intima of normal arteries. It would seem that the normal intima depends for its nutrition upon percolation of fluid from the blood stream; and that up to a point, this evidently holds true also where the intima is thickened.

It was observed that intimal vessels whose arterial origins were demonstrated by injection arose both from the lumen of the artery and from the adventitial vessels. So far as vessels which had received the injection mass were concerned, those arising from the lumen were in the great majority. Some of the intimal vessels were of very small calibre and the route taken by the injection medium through the vasa vasorum was sometimes circuitous. It is accordingly possible that vessels arising from the adventitia were less advantageously placed to receive the injection medium and that the numerical proportion of intimal vessels recognised as having arisen from the adventitia and from the lumen respectively was thereby artificially loaded in the favour of the latter. There was, however, a difference also in configuration.

1. The vessels which entered the intima from without arose mainly from the network of arteries in the adventitial coat, the vasa vasorum. They also arose from small branches of the main artery as they emerged. They were of small calibre and of rounded, well formed structure up to the point at which they entered the intima, and sometimes for a short distance thereafter. Their passage through the medial coat was sometimes tortuous. They appeared to terminate in the vascular tissue in the outermost layers of the atherosclerotic plaque. Until their identity was lost in this region, in their general course, branching and structure, these small arteries closely resembled small arterial branches.

The vascular tissue in the outer rind of the atherosclerotic plaque appeared to be part of the process of organisation, and was accompanied by fibroblastic and other cellular activity. In the absence of vessels arising from the lumen the vascular tissue seemed to be restricted to the outer portions of the plaque. It was thought that intimal arteries which entered through the media probably fed this vascular tissue in particular, and this was certainly the case where there were no vessels arising from the lumen in the same portion of artery.

2. The vessels arising from the lumen sometimes showed several contrasting features. Usually they were well-formed, rounded vessels which entered the thickened intima and branched in a tree-like fashion. This was typically the case in uncomplicated, pale plaques. Characteristically the vessels were thin-walled structures which entered the plaque abruptly, as if through a fault in continuity of the lining, notwithstanding they had an intact endothelial coat. The commonest point of entry was at the "shoulder" of the atheromatous plaque and the general course as seen on cross-section was in a curved, sweeping direction between the crescent formation and the underlying intima. In the case of compound atheromata these vessels were in evidence between a mere centrally placed crescent and the underlying tissue.

Although the intimal vessels arising from the lumen were often branched, this had not always taken place in the fashion of a tree but rather in semblance of the common sea-wrack (see 14 ADA 2:3 stereogram of section). Thus the branches were crudely fashioned, flattened by compression between fibrous layers and showing many cavernous dilatations. In the depths of the plaque there were often large, thin-walled sinusoidal spaces containing blood. Quite frequently the injection medium had also entered these blood spaces in small quantities from the intimal vessels arising from the lumen. It was often possible to identify an endothelial lining to the blood filled spaces, but not always. They were invested with a thin collagenous coat and in some cases there was also elastic tissue.

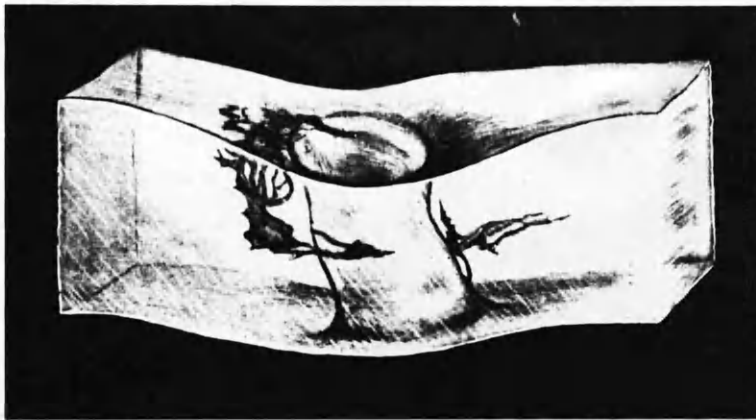


Fig. 43. Vasa arising from penetrating branch of aorta and forming encircling plexus.



Fig. 46. Coronary artery, injected and cleared, with adventitia removed. Plexus of vasa vasorum derived from two penetrating branches.

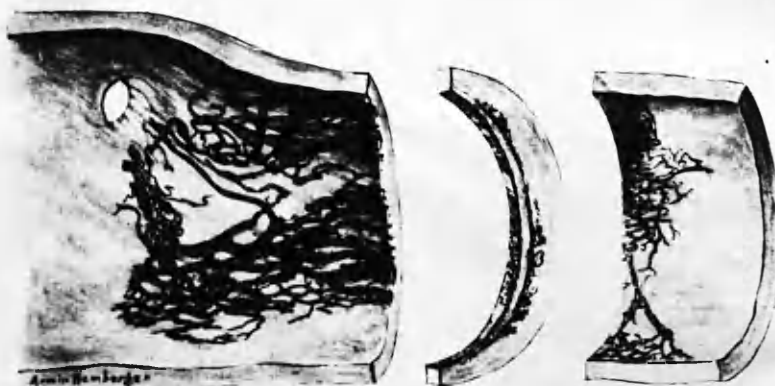


Fig. 47. Coronary artery, injected and cleared, with adventitia removed. Extensive intimal plexus arising in the vicinity of a branch.

Figs. from "The Biology of Arteriosclerosis".  
 Winternitz et al., 1938

The emphasis in description of these blood spaces rests on the thinness of their walls and the irregularity of their size and contour. I was not convinced that structures properly referred to as capillaries were to be seen in the inner portions of the atherosclerotic plaque. When a linear capillary space was observed in the microsection it was usually found to be a slit-like space rather than round in section.

I gained the impression that the thin-walled blood spaces in the intima formed a sort of spongework. I had no direct evidence that the vessels from the lumen and from the vasa vasorum formed anastomosis except occasionally. Indeed, I had no direct evidence that intimal vessels arising from the lumen had venous communication. I think it is not only possible but also in keeping with their structure that the vessels which arose from the lumen merely entered a spongework of cavernous spaces from which there was no exit and that ebb-and-flow had been the only condition of blood flow in them. There was great difficulty in injecting these vessels when small and I think that this too is in keeping with the possibility that they were cul-de-sacs. (Vessels elsewhere of similar and smaller size which branched dichotomously until they ended in a capillary bed were relatively easily injected.) In order to overcome this difficulty some workers have used enormous pulsatile injection pressures (Winternitz et al., 1938), which I have regarded as quite unsuitable for friable pathological material. These workers described capillary networks and venous communications in the arterial intima of man, demonstrated by Indian ink injection. Most of the illustrations in "The Biology of Arteriosclerosis" are drawings.

The degree of vascularisation that I was able to demonstrate in atheromatous plaques varied greatly. The majority of lesions were without injected vessels, including some atheromata of large size. On the other hand the larger and more compound atheromata commonly showed microscopically recognised intimal vessels, the origin of which was not always traceable.

The vasa which arise from the adventitial vessels and penetrate the media are probably the most abundant of all....The number of vasa arising directly from the lumen of the parent vessel varies considerably from specimen to specimen, and their size is such that they can be identified only with the aid of a dissecting microscope, and after injection. "

Winternitz et al., 1938



It was noted with interest that the vessels of injectable size which arose from the lumen were, almost without exception, in plaques which showed features to suggest their formation from thrombus. (The evidence that was accepted in this context was staining of the tissue by blood pigment in the gross specimen, stainable iron deposits in the microsection and the presence, in compound lesions, of crescentic formation highly suggestive of the organisation from thrombus, as already described.) On the other hand, "pale" atheromata of simple construction, no matter how large, less frequently showed injectable vessels arising from the lumen which were recognised in the gross specimen. In such lesions, small vessels carrying injection medium might nevertheless be found on the microsection not infrequently; and small vessels entering from the adventitia. In some instances no vessels whatsoever were found on microscopic examination of sections through atherosclerotic lesions. None of these bore evidence of having been recently formed from thrombus.

Comments on the Origin, Significance and  
Hazards of Intimal Vessels

The tentative conclusion was reached that intimal vessels which arose from the lumen had their origins in the spongework of thrombus, at the time when it was undergoing incorporation into the intimal wall. As already described in detail in connection with the process of canalisation, the appearance of channels in the thrombus, as well as separation of the thrombus from the underlying intima, tended to take place at the zone of mutual contact. It was in accord with such origin that intimal vessels arising from the arterial lumen should have lain typically between the main body of the plaque and the underlying intima. Also in keeping with this concept was the cavernous nature of the blood spaces into which these vessels entered. Indeed there was an identity of structure between the intimal vessel which arose from the lumen in the atherosclerotic plaque and their counterpart in canalising thrombotic occlusions.

Hypertrophied vasa vasorum : " On entering the base of the plaque these often link up with a series of peripheral blood sinuses... The latter, though thin-walled, are not capillaries in the ordinary sense, being much larger and often irregularly shaped. Crescents of these sinuses are seen between the media and the base of the plaque,.. and this distribution is so striking that it is difficult to escape the conclusion that they are the late result of retraction of thrombus from the vessel wall - i.e. marginal recanalization."

Morgan , 1956

This would not only suggest a common origin for intimal vessels in both situations; but, conversely, might also be upheld as an additional point in favour of a common origin for intimal tissue in the two types of lesion. There can be no question that the tissue in the case of old thrombotic occlusion has been derived from blood clot.

(Intimal vessels in complete occlusions tended to course in the long axis of the artery whereas the direction of such vessels on the atherosclerotic plaque was more nearly in a transverse plane. This difference can readily be related to the mural position occupied by the latter in contrast to the longitudinal block formed by the former. In the presence of canalisation a dominant channel was sometimes formed as seen in sections 14 ADA 2:3 and 2:4 micro. from which subsidiary channels arose and took a course largely in the transverse plane<sup>1</sup>. In this section intimal vessels also passed into the underlying atherosclerotic plaque in a plume-shaped formation, which bore a striking resemblance to the channels which develop in thrombus. Almost certainly this plaque was formed from thrombus.

I would go so far as to suggest that intimal vessels which arose from the coronary arterial lumen were at least sometimes pathological accompaniments of assimilation of thrombus into the intimal wall; that they did not necessarily represent a "purposeful" attempt at providing a vascular supply; and that they had been present from the inception of the process and did not primarily result from a process of "vascularisation". The concept that vessels grow into the intimal plaque like roots advancing into soil is not borne out by the nature and configuration of these vessels. In this respect the term vascularisation ( or worse, "re-vascularisation") of the atherosclerotic plaque is probably inappropriate and misleading.

---

(1) Note particularly the stereo-radiograph of 14 ADA 2:3.

Intimal haematoma in the coronary arteries was described by Wartman, 1938, and by Winternitz et al., 1938.

"In summary the following points may be emphasised:

(1) that hemorrhage, or an old exudative process in a thickened intima, should be regarded as a frequent precipitating factor in thrombosis;

(2) that such a process may, of itself, completely close an already narrowed lumen without the formation of a thrombus;

(3) that when a vessel is completely filled with granulation tissue, the events leading to occlusion cannot be reconstructed with any degree of certainty; and

(4) that the power of restitution of function of an occluded vessel is inherent in the elements of the vessel wall, and that channels derived from the adventitia, the media, and the intima, and even the organised thrombus, may be utilised to support effectively the life of a vital part. "

Winternitz et al., 1938

Were those intimal vessels which arise from the lumen the result of true vascularisation of tissue, then one would expect that their occurrence would be beneficial and that plaques favoured by their presence would be the more stable. Also that "earlier" plaques would show early stages in the process and that a highly developed vasculature would be found in "fully developed" plaques. But this was not so. On the contrary, intimal vessels of this order were more (often found in plaques which were the seat of haemorrhage, and often of thrombosis within recent date. Indeed, the presence of these vessels appeared to have introduced the hazard of haemorrhage. Their thin-walled sinusoidal structure would seem to be prone to rupture. This was especially noted to be the case where they lay close to the margins of an atheromatous abscess. In this situation the blood channels were unsupported on the one side except by the semi-fluid contents of the abscess and were liable to shearing strains and to direct trauma from large crystals of cholesterol or calcified masses. Haemorrhage into the atheromatous abscess was frequently observed. (Sometimes such haemorrhages when massive have been described as haematomata. In this investigation I did not have the fortune to encounter a clear example of large scale haemorrhage of this order which was recent; but in at least two cases the old-standing appearances lent themselves to this interpretation.)

It may be pointed out that the mass of necrotic material and inanimate lipid which composed the atheromatous abscess was devoid of blood vessels as a rule. Sometimes there were however formed blood spaces and it was thought on these occasions that the blood spaces had been derived from previous haemorrhage and not from organised ingrowth of vascular tissue. Necrotic material did not appear to offer a suitable matrix for the development of vascular tissue.

The relative freedom of some plaques from intimal vessels was striking and seemed to demand some explanation. There are at least two possible interpretations which may tentatively be put forward:

(1) It may well be that the issue of the presence and distribution of the intimal vessels arising from the lumen is decided at the earliest stages in the formation of the plaque. If this is indeed a process of assimilation of thrombus into the wall, the more fibrous and less vascular lesions would probably be derived from thrombi that were predominantly fibrinous; whereas an abundance of red cell material in the thrombus would favour the formation of spongy blood channels at the peripheral portions and necrosis in the centre. In established atherosclerotic lesions intimal vessels of this order, and haemorrhage as a complication of their presence, were especially found in the tissue surrounding atheromatous abscesses; whereas the pale, established lesions which were uncomplicated by haemorrhage or thrombosis were usually to a greater degree fibrous and in them intimal vessels were scanty.

(2) In the course of time many of the cavernous blood spaces may become obliterated, so that in older lesions relatively fewer intimal vessels will be found. Thrombosis in recently formed channels in the process of canalisation of thrombotic occlusion was noted. It is quite possible that irregularities in the fibrous structure of atherosclerotic plaques, in the form of minor whorls and knots, may represent obliteration of previously existing blood spaces.

It could therefore be conceived that an abundance of intimal vessels in the form of a spongework of thin-walled cavernous blood spaces is a feature of the relatively recent lesion; and that progress may commonly be towards more definitive development of a few channels and to secondary thrombosis and obliteration of the others. In this way the older lesions would tend to be relatively free from these pathological structures.

Before this fortunate train of events is complete the situation is often complicated by haemorrhage which in turn may be complicated by thrombosis and death - and the lesion brought before the notice of the pathologist. The

quiescent, chronic lesions, which have long since passed through the unstable danger period without these complications, present an innocent looking pale face to the observer. They have even lost the vasculature with which to blush from shame at the damage wrought by their successors!

These concepts are somewhat individual and in contrast to the accepted views of others. I would emphasise that they are tentative, and also that they are not readily submitted to proof, or to disproof. (In this they are in the company of a great many concepts in this subject!) I think it is important none the less for the sake of clarity of thought in reference to the human disease that it be not assumed that the smaller lesion is always the fore-runner of the larger; that "fully developed" has any true meaning; nor that intimal vessels and haemorrhage represent a later stage than simple, pale, relatively avascular and uncomplicated lesions. For the reverse may be the case - and would receive support from most of the findings of this investigation.

Only part of what has been said about vessels which arise from the arterial lumen can be confidently applied to the intimal vessels arising from the adventitial coat. For these vessels seemed to behave somewhat differently. Their configuration was a more regular one, and they resembled more closely vessels taking part in tissue formation by granulation. They accompanied the invasion from without of thrombus lying on the endothelial surface, an excellent example being afforded of this phenomenon in the thrombus in the atrium (Case D9). It was supposed that they entered the peripheral vascular tissue and that blood again made its exit via veins but I was not convinced that I had observed venous channels making their exit through the media. Venous channels of course abounded in the adventitial coat. I did not inject veins in this study. In the absence of counter-pressure within them, veins situated in the arterial wall internal to the adventitial coat would tend to be compressed and emptied during injection by the high intra-arterial pressure.

.....

"These newly formed capillaries are not derived from the vasa vasorum..They are abnormal structures and originate from the lumens of the larger arteries."

Paterson ,1952

.....



Apparent anastomosis was only rarely observed between the lumen of the artery and small vessels in the adventitia<sup>1</sup> and it was not always clear that this represented intercommunication of luminal and adventitial vessels. It is quite likely that it merely represented gross distortion of a small arterial branch which was anatomically connecting with the vasa vasorum. Micro-sections were however not taken through such vessels.

Haemorrhage in the depths of the intimal plaque has been frequently observed by others and sometimes it has been attributed to intimal vessels arising from the vasa vasorum. I would question the general applicability of this point of view. For reasons already mentioned I am **unconvinced that the** cavernous blood spaces are fed by vessels which enter from the periphery, for I was unable clearly to demonstrate communication between them; and where cavernous spaces and peripherally entering vessels were present in the same section I doubted whether there might not be communication of the latter with the lumen which had not been revealed by injection. Sometimes, on tracing a peripherally placed intimal vessel to its origin, it was found to have arisen at some considerable distance from an arterial branch before its exit from the intima, or from the lumen itself. In my material, where haemorrhage into the intima during life had been followed by injection mass after death, the injection mass had commonly entered from the lumen; or uncommonly from a source that was not clearly determined. It was never clearly observed as the result of rupture of an intimal vessel arising from the vasa vasorum.

In view of all these considerations, I tended, in hypothetical fashion, to regard intimal vessels which arose from the vasa vasorum and from the lumen as having dissimilar significance. The former were evidently accompaniments of organisation, probably beneficial and probably without harm to the intimal tissue which they appeared to supply. By contrast, the latter, which arose from the lumen could sometimes be fortuitous, pathological accompaniments of incomplete organisation, possibly of little value and undoubtedly of hazard to the intima.

---

(1) 17 RC arteriogram.



THE PROXIMATE CAUSES OF THROMBOSIS IN  
SEVERE ATHEROSCLEROSIS

"The relative rarity of the formation of a thrombus on the top of atherosclerotic lesions is an indication that this complication requires some special local conditions for its genesis, such as an atheromatous ulcer, interference with the flow of blood, or haemorrhage into an atheroma .....

(Hueper, 1956)

In every case of thrombosis of recent date observed in the present investigation, the attempt was made to discover local causes for its occurrence. Although it was not difficult to discover related disease processes in the neighbouring arterial wall, it was quite another matter to trace a causal relationship. Three possible causes are indicated in the excerpt above, and I shall mention them in turn in reference to my own findings.

Ulceration of the Atheromatous Plaque

Ever since Saphir et al. (1935) claimed that in each of 32 instances of thrombosis in the coronary arteries the thrombi were located upon atheromatous ulcers, ulceration of atheromatous plaques has been widely quoted as a precipitating cause of thrombosis. Saphir and his co-authors do not make it clear in their paper exactly what this term implies. If it means that the atheroma has lost its wall on the luminal side so that the arterial lumen has for a time been bordered on one side by the cholesterol laden tissue or necrotic debris of the atheroma, and that thrombosis has then ensued, I think that the term "ulceration" describes an artefact, at any rate in most instances. In this investigation the shelf of tissue which separated an atheromatous abscess from the lumen was not infrequently an extremely thin and friable structure. Nevertheless, on one occasion only (22 RC) had this thin shelf disintegrated (and the contents of the atheroma been carried a short distance in the blood stream) prior to thrombus formation.

Rarely blood had entered the atheroma and had clotted so that thrombus within the abscess and within the lumen were in contact through a breach in the thin shelf which separated them,<sup>1,2</sup> but that is another matter. In my preparations, in which the artery was supported from within by injection medium, was embedded in gelatin and was handled with the greatest gentleness throughout the processes leading up to sectioning, "ulceration" of an atheroma was never seen. In Saphir's cases the arteries were snipped open with scissors !

If on the other hand by "ulceration" was simply meant loss of the endothelium alone then my findings are not in disagreement with those of Saphir, for the endothelium could not be identified between thrombus and underlying intima. I do not think however that this is the sense in which the term "ulceration" has been generally used. In any case, where loss of endothelium was noted in any but the earliest of thrombi, there could have been no means of knowing whether the thrombus had formed upon an intimal surface because it had lost its endothelium; or the endothelium, normally dependent on the blood in the arterial lumen for its nutrition, had degenerated when suffocated by the overlying thrombus.

#### Interference with the Flow of Blood

In only two cases did this seem to have been important in the sense of nearly complete cessation of flow before thrombosis. In these cases it appeared that thrombus had formed in the cul-de-sac related to earlier complete occlusion. On the other hand thrombosis had commonly taken place in a region of severe atherosclerotic disease at sites where turbulent conditions of blood flow might have contributed to thrombosis locally. It was noted that when occlusion occurred where there had been rapid throttling down of the arterial lumen for a short stretch and then widening, the narrowest stretch of previous lumen was always occluded.

---

(1) 15 ADA 3:2 micro.  
 (2) 14 ADA 2:1 micro(1).

It was not determined whether this was the point of first thrombus formation or whether it lay just beyond, as might theoretically be expected, or at other levels.

Fall in blood pressure, resulting from extra-cardiac causes such as acute blood loss or dehydrated states, is commonly thought to be a precipitating cause of thrombosis in the presence of severe coronary artery disease. There was little to support this point of view in my series.

One case died following diabetic pre-coma in the course of which myocardial damage was sustained without the development of corresponding arterial thrombosis (Case 10). There was old-standing coronary narrowing from previous episodes of occlusion. Several cases died following a stage of circulatory collapse attributable to myocardial damage. In two there was no recent thrombosis. In three others there was no evidence of a further episode of thrombosis more recent than the thrombotic occlusion deemed responsible for infarction.

Montgomery and Branwood (1956) have noted the occurrence of thrombus of more recent date than the associated infarcts in 27 out of 36 instances, in which the muscle damage had been established "for at least several days". They concluded that the thrombus appeared "to have developed as the terminal stage of an established infarct". I had no instance in my series in which coronary thrombosis appeared to have followed myocardial infarction during the course of the acute illness (except in cul-de-sacs related to previous complete occlusion). I acknowledge that I was unable to assess the age of a thrombus with precision. I could do so only within broad limits. I cannot therefore assert that thrombosis was never a sequel to infarction. Nevertheless I had no observations which made departure from conventional concepts obligatory. I tended however to relate muscle necrosis to the withdrawal of blood supply occasioned by thrombotic occlusion, rather than the other way round; and to reconcile the appearance of the thrombus to the known age of the related muscle damage. In doing so I found broad agreement between my findings.

I know of no way of determining the age of human coronary thrombotic occlusions a few days old other than by relating the appearances to the duration of myocardial damage or clinical features. I had observed the remarkable delay (of 2 or 3 weeks) before changes could be observed in coronary thrombi, which I took to be the cause of the myocardial damage. The point of view expressed by Montgomery and Branwood challenges the basis of this observation. The challengers must however first establish that naturally occurring coronary artery thrombus of less than 36 hours can be distinguished histologically from thrombus of several days duration.

#### Intimal Haemorrhage and Thrombosis

Few can doubt that intimal haemorrhages occur in diseased coronary arteries. There is however less certainty about their origins and their relationship to thrombosis. I am in agreement with Paterson, 1952, that they arise from rupture of the thin-walled intimal vessels which originate from the lumen of the artery. On the other hand, my impression has been that haemorrhage was uncommon from vessels arising from the vasa vasorum. Even peripherally placed haemorrhages probably had often arisen from vessels which entered the intima directly from the lumen.

I think that it is also possible that haemorrhage may simply arise through a break in the continuity of the endothelium under the influence of unusual stress. Many examples were found in my preparations of break in continuity of the arterial lining into which injection medium had entered after death. The presence of blood accompanying injection medium was highly suggestive that rupture had taken place beforehand during life. It was by no means clear in these instances that intimal vessels had been present in the region of haemorrhage.

Paterson lists the following precipitating factors in intimal haemorrhage:-

- (1) Increased pressure within the lumen of intimal vessels,
  - a. direct communication with arterial lumen.
  - b. increased incidence of haemorrhage in hypertension.
- (2) Abnormal fragility of the vessel wall.
- (3) Lack of support from adjacent tissues.

Paterson, 1952

---

"Thrombus precipitation may occur in several ways but, regardless of the exact mechanism, everyone who has worked extensively on the subject agrees that the usual precipitating lesion of thrombosis,....., is haemorrhage into an atherosclerotic plaque....Skepticism still exists, of course, in certain quarters."

Paterson, 1952

---

see also : Drury, R.A.B., 1954, J.Path.Bact., 67: 207

"The role of intimal haemorrhage in coronary occlusion."

---

Intimal haemorrhages have been observed by many workers including Benson, 1926; Koch and Kong, 1932; Paterson, 1936, 1941, 1952; Wartman, 1938; Winternitz et al., 1938; Nelson, 1941; and Horn and Finkelstein, 1940. Observers differ widely in the incidence of such haemorrhages which they report. Those which have recorded the highest incidence have examined the coronary arteries by cutting them across at short intervals, e.g., at 2 mm. intervals, as used in my own investigation and as recommended by Horn and Finkelstein, 1940. So far as I have been able to determine, sectioning in this fashion was usually carried out by others with the artery in situ and unprepared. My own method of serial mounting of the thick sections for examination at magnification has not been a part of the examination of others. (All have, of course, used histological sections as well.) The method which I used gave, I think, the optimum opportunity for detecting these haemorrhages, and also gave me some advantage when examining them in relation to other events in their neighbourhood.

Haemorrhage into the substance of the arterial intima which had been thickened by disease was observed with great frequency in the preparations of this series. Appearances believed to be those of haemorrhage were recorded in the dissections carried out in the earlier cases and in most of these confirmation was sought for each and obtained on microscopical examination. Observations on their extent and their relationship to thrombosis were however of a more detailed and comprehensive order in the later cases (i.e., those which were examined by the mounted 2 mm. thick serial section method). Accordingly the incidence of intimal haemorrhage which is analysed in relation to thrombosis in the tables refers only to the last 16 cases. Because only selected portions were examined histologically, numerical analysis is restricted to the gross appearances.



"The evidence suggests that intimal hemorrhage is probably causally related to coronary artery thrombosis and occlusion in more than half the cases".

Wartman, 1950

Incidence of intimal haemorrhage in autopsied cases of coronary artery occlusion.

<u>Author</u>	No. of occ- lusions.	Haematoma	Ruptured haematoma and thrombosis	Total with sign. haem.
Paterson, 1941	58	0	29	52
Wartman, 1938	41	6	14	20
Horn and Finkelstein, 1940	172	13	64	100
Nelson, 1941	17	2	9	11
<hr/>				
Total 1938-41	288	29 (10%)	116 (40%)	183 (64%)
<hr/>				
Wartman, 1948-49	77	5 (6.4%)	20 (26%)	45 (58%)
<hr/>				
Grand total	365	34 (9%)	136 (43%)	228 (62%).

Wartman, 1950

Intimal Haemorrhage : Table recorded by Paterson, 1952

<u>Author</u>	<u>Technique</u>	Cases studied	Int. Haem. No.	%
Paterson, 1941	serial section at short inter- vals	58	52	89
Horn and Finkelstein, 1940	many sections	123	64	52
Nelson, 1941	many sections	10	9	90
Paterson, 1950	many sections	34	21	62
Yater et al., 1948	occasional sections	158?	26?	16

Criteria for the recognition of intimal haemorrhages in the 2 mm. thick sections, examined at x 20 magnification:-

a. Those lesions which were classed as intimal haemorrhages for the purposes of Tables 8: 1,2,3 were very dark, and clearly demarcated from the surrounding tissue. They were usually small. Occasionally communication with the lumen could be traced and sometimes small vessels were seen leading close to them.<sup>1</sup> (In many instances the histological picture was also available. Close comparison of gross and histological findings were made before the gross features were determined upon which haemorrhage into the intima could be recognised with a fair degree of certainty.)

b. There were numerous areas of dark pigmentation which resembled intimal haemorrhage, and which I should have been inclined to record as intimal haemorrhage earlier in my investigation. Where these areas were somewhat diffuse and ill-defined, or where the discolouration was not sufficiently intense, they have been classed for the purposes of Tables 8: 1,2,3 as pigmentation resembling haemorrhage.

(There were in addition numerous portions of the diseased intima which showed discolouration of lesser degree and the likelihood of recent intimal haemorrhage was not entertained. It was assumed that these dark areas, not clearly the result of recent haemorrhage, represented incorporation of thrombus into the intimal wall. In a few instances it is nevertheless possible that they represented old-standing haemorrhage.)

1. e.g., 19 RC 1:6b.

Table 8:1

Incidence of Intimal Haemorrhages and their Relationship to Recent Occlusive Thrombosis and to Small Mural Thrombi : 16 cases				
	INTIMAL HAEMORRHAGE			PIGMENTATION resembling haemorrhage
	:Underlying thrombus	:Within 1 cm.	:Else-where	
16 arteries, the seat of recent occlusive thrombosis. (10 cases)	8 + 2 <sup>∅</sup>	3 <sup>≠</sup>	2	8
32 arteries, without recent occlusive thrombosis. (16 cases)	-	-	19	18
8 arteries the seat of 12 small mural thrombi (6 cases)	1	1	(-)	(-)
	11	4	21	26

Notes on Table 8:1

- (1) <sup>∅</sup> 2 instances of 2 separate haemorrhages under single occlusive thrombus.
- (2) <sup>≠</sup> 1 artery showed only Int. Haem. at 1 cm. distance.  
2 arteries showed Int. Haem. at 1 cm. distance as well as underlying thrombus.

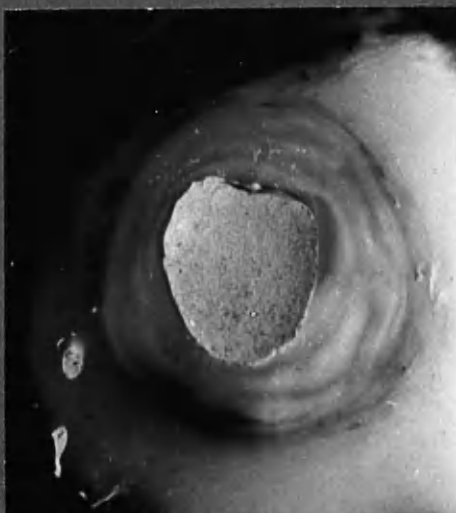
Table 8:2

Further Points in the Relationship of Intimal Haemorrhage and Thrombosis	
1.	Of the 16 instances of recent occlusive thrombosis, 8 showed underlying intimal haemorrhage, as indicated above. Of the remainder, intimal haemorrhage at 1 cm. distance only occurred in 1 instance, whereas in 7 there was no related intimal haemorrhage within 1 cm., or underlying the thrombus.
2.	In 6 cases there was no recent occlusive thrombosis. In these cases there were 17 intimal haemorrhages and 13 instances of dark pigmented areas resembling intimal haemorrhages.
3.	In 4 cases there was no intimal haemorrhage. 3 of these were free from recent occlusive thrombosis.
4.	Intimal haemorrhage without related recent occlusive thrombosis:-
a.	In 10 cases which showed recent occlusive thrombosis elsewhere <span style="float: right;">4 instances</span>
b.	In 6 cases in which there was no recent occlusive thrombosis <span style="float: right;">17 "</span>
	<hr/> <b>Total</b> <span style="float: right;"><b>21 instances</b></span> <hr/>

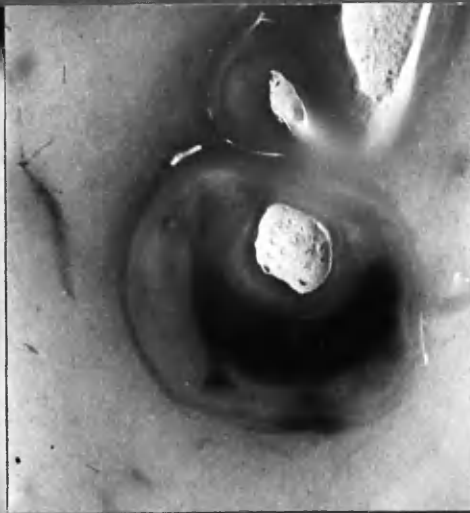Table 8:3

Summary of Findings in Regard to Intimal Haemorrhage and Recent Occlusive Thrombosis. <span style="float: right;">16 Cases.</span>	
Recent occlusive thrombosis.	16
Recent occlusive thrombosis without related intimal haemorrhage.	7
Recent intimal haemorrhage underlying or within 1 cm. of occlusive thrombus.	9
Number of intimal haemorrhages unrelated to recent occlusive thrombosis.	21
Total intimal haemorrhages.	36

### EXAMPLES OF INTIMAL HAEMORRHAGE

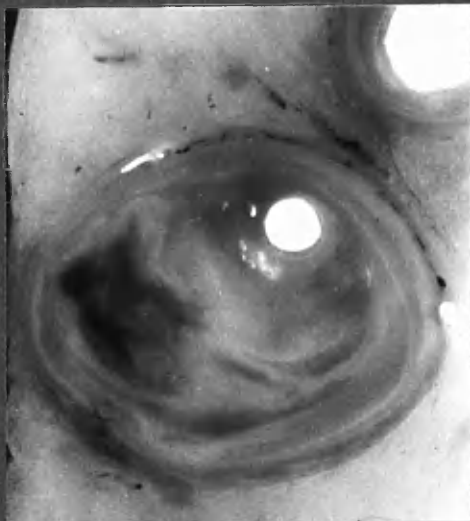


18 RC 4:13 b. x11  
Haemorrhage between layers.

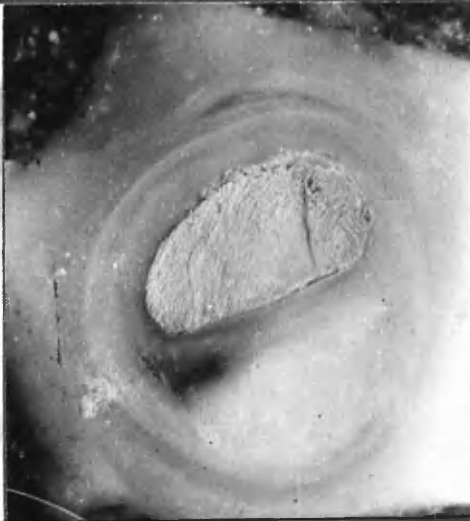


18 ADA 3:5 b. x10  
Haematoma, note crescentic form

See micro chap. 7, 8



18 ADA 1:7 b. x10  
Histologically proved haemorrhage



16 RC 2:5 a. x9  
Classed as "Pigmentation resembling haemorrhage"

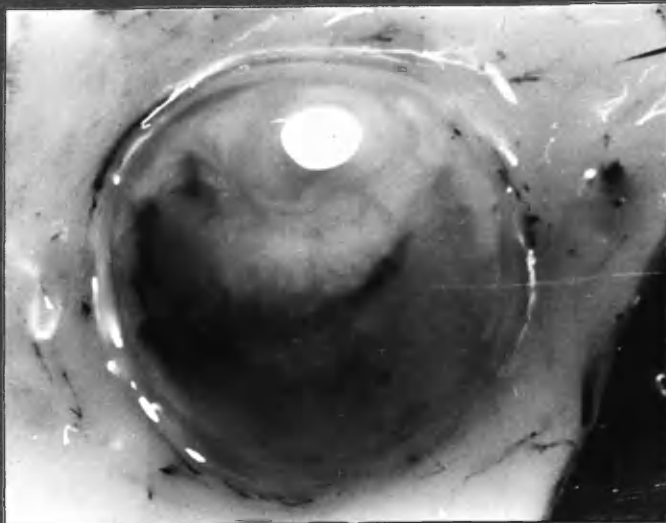
Discolouration could have been due to old haemorrhage but may equally have had its origin in thrombus.

2 yrs.

Classed as :-

"Pigmentation"

(see colour transparency.)



22 ADA 2:5 b. x10

It is evident from the tables that intimal haemorrhage was of frequent occurrence. Thirty-six separate haemorrhages were recorded in 16 cases, and were restricted to 12 of them. The incidence of hearts which were the seat of intimal haemorrhage is therefore roughly in accord with the findings of others (e.g., Paterson, 1950; 21 out of 36 cases). The main interest however lies in the relationship between occlusive coronary thrombosis and intimal haemorrhage.

It is generally assumed that intimal haemorrhage leads to disturbance, or rupture, of the overlying intimal surface and so to the precipitation of thrombus. Occasionally this has almost certainly been the case in my preparations. (Sometimes haemorrhage could be traced to the arterial lumen at a point where the lumen had been blocked by thrombus, e.g., 3 ADA micro.) In the majority of lesions the possibilities had to be entertained

- (a) that intimal haemorrhage might follow, and result from, the presence of overlying thrombus,
- (b) that the two phenomena were not causally related, and that their presence in the same lesions was purely circumstantial.

The shorter the interval time between occlusion and examination of the affected arteries the more surely will it be possible to trace the sequence of events and to reach conclusions in regard to cause and effect. It would therefore have been more satisfactory had I been able to make observations on a sufficient series of cases dying within a few days, or even hours, of coronary occlusion. Nonetheless, the observations that I have been able to make on recent occlusive lesions of various ages are not without interest. (These lesions ranged in age from 1 day to 6 months, but only 2 out of the 16 lesions were more than  $4\frac{1}{2}$  weeks old.)

I have not found it possible to trace a clear causal relationship between intimal haemorrhage and coronary thrombosis. (1) Just over half the occlusive

lesions showed both intimal haemorrhage and thrombosis, and the one may have been the cause of the other. (2) Just under half the instances of occlusive thrombosis had occurred without related intimal haemorrhage (i.e., within 1 cm.). (3) The majority of intimal haemorrhages recorded were unrelated to thrombosis. It is therefore safe to conclude that intimal haemorrhage is not a prerequisite of thrombosis, nor thrombosis of intimal haemorrhage. The close association of the two phenomena in approximately half the recent occlusive lesions is unlikely to have been due to chance, but conclusions as to which came first would not be permissible from my findings.

I would conclude that it is likely that intimal haemorrhage may be a precipitating factor in coronary thrombosis, but not that it is proved.

The relationship of small mural thrombi on the other hand to intimal haemorrhage seemed remote. The association of intimal haemorrhage and thrombi within one centimetre of each other may have been fortuitous, occurring in 2 out of 12 instances.

It may be noted that most of the cases were receiving anti-coagulant therapy during the fatal illness. The maximum incidence of intimal haemorrhage in individual cases however occurred in 2 cases which were not in receipt of anticoagulants. In one there was fresh thrombosis of more than one artery and in the other there was no recent occlusive thrombosis.

"In the young...Death is usually due to thrombosis.  
In the old...Death is usually due to rupture of an  
atheromatous abscess into the lumen."

"The formation of an atheromatous cyst, cavity  
or "abscess" ,as it used to be called,presents a  
new hazard...In the coronary artery,rupture usually  
leads to the obstruction of the lumen of the vessel  
near the point of rupture (Fig.7) or to complete  
plugging of branches. The material is not broken  
up but acts as a semisolid mass."

Leary ,1935 b.

"Rupture of an atheromatous cavity into the  
lumen or the rare reverse process,rupture  
from the lumen into the cavity,is the standard  
terminal lesion in older persons. It is poss-  
ible that thinning of the membranous partition,  
which comes to be the only barrier between the  
cavity and the lumen,may lead by its own weak-  
ness to rupture,placed as it is in a muscular  
vessel. If this were true in general , the  
lesion should be marked by the filling of the  
cavity with blood,during systole,washing out  
the contents. Ordinarily the cavity is found  
more or less empty,indicating delivery of its  
contents by positive pressure.

Leary,1935 b.

(It will be evident from the text that I  
differ fundamentally in my interpretation  
of the phenomena observed ,and could offer  
an alternative interpretation of Leary's  
own illustrations. The underlining is  
mine. )

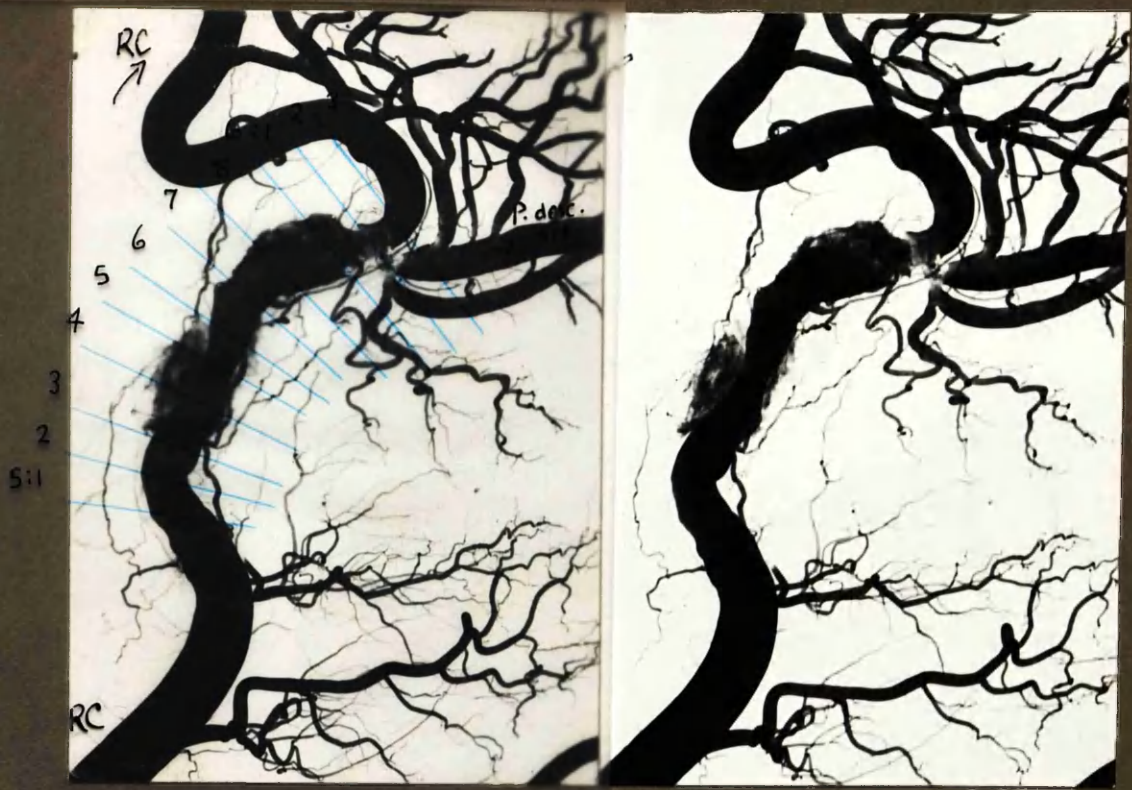Haemorrhagic Disruption of the Plaque with Extrusion of  
Atheromatous Material into the Arterial Lumen.

It is commonly held that rupture of an atheromatous abscess into the arterial lumen takes place, and that it does so as the result of haemorrhage into the plaque. It is supposed that the thin shelf of tissue between the abscess and the lumen breaks down and the contents are extruded into the lumen. One may then imagine that blood enters the cavity through the rent in its roof, and clears it out as one might blow an egg. It is believed that thrombosis tends to occur at the site of damage, and also that the extruded atheromatous material impacts further down the artery, and in turn gives rise to occlusion at that site (see, for instance, the excerpt from Leary, 1935, opposite).

I have no fundamental objection to these concepts. But I doubt that they are as commonly borne out in fact as is suggested in the writings of others. Leary, 1935, would give the impression that rupture of an atheromatous abscess into the lumen is the usual cause of death in older subjects. In my own series, appearances in keeping with the phenomenon outlined above were encountered in but a single instance (22 RC).

In this artery it seemed that blood had burst into an atheromatous plaque and had tracked through its substance to find exit through a second break in the intima about 1 cm. further down the artery. It was in fact a form of dissection of the intima. There were numerous examples in my preparations of dissection of the intima by blood and/or injection medium which had broken through the intimal lining, presumably at a point of weakness (see later). In some of these lesions there was thrombosis locally but this was the only example I had of extrusion of atheromatous debris (which, together with thrombus material, impacted at the first point of bifurcation, in this instance). It may be noted that in this example there was a point of exit separate from the point of entrance of blood into the intima. It is tempting to suppose that this may have been important. The other examples of dissection were "blind".





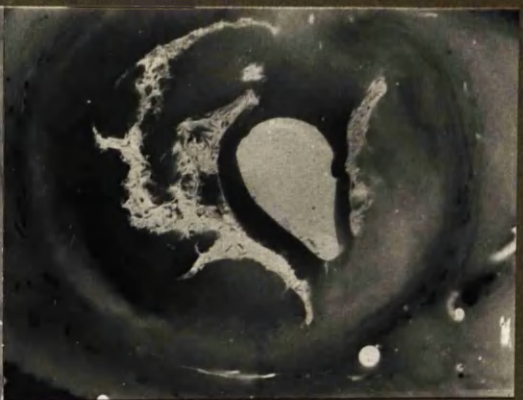
Distal end of RC.

x 2 3/5


5:3a



5:4b

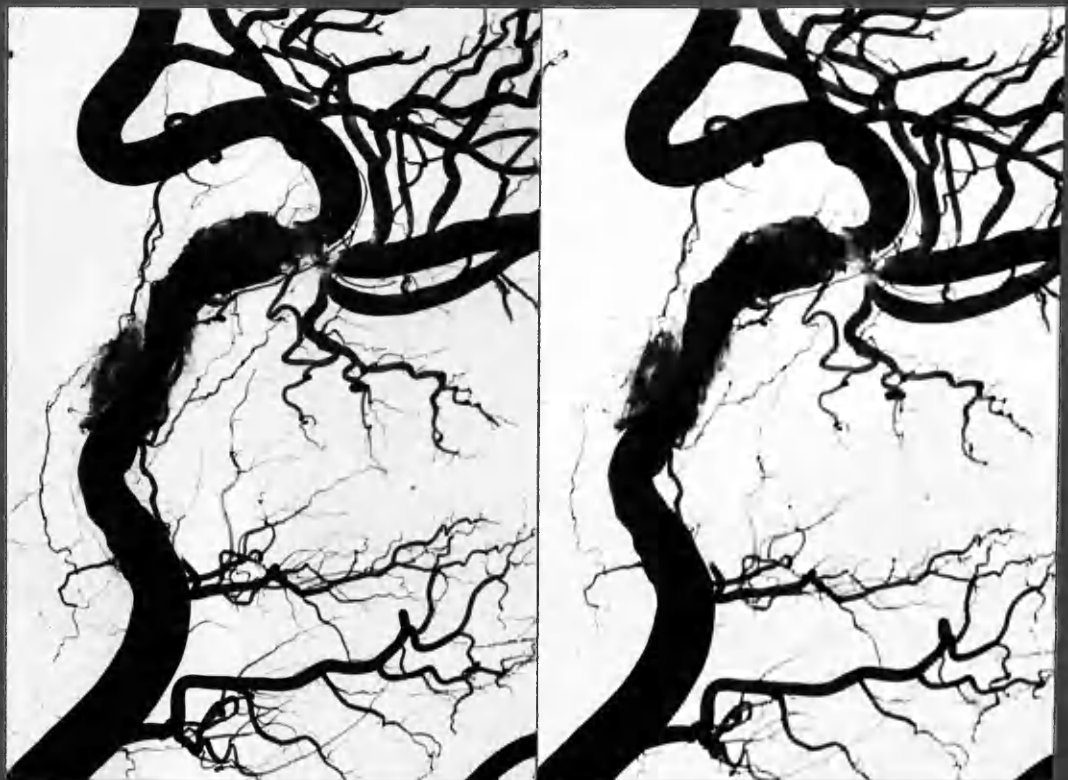

6:1b

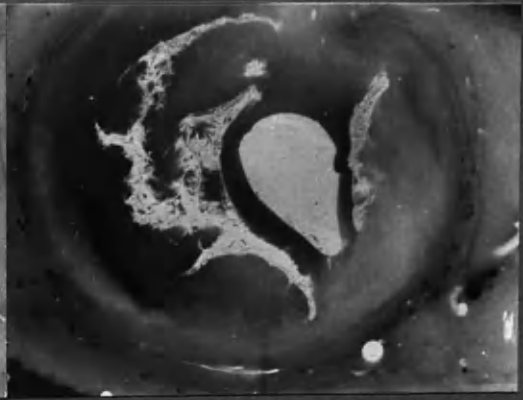


5:3a : injection medium entering discoloured intimal plaque and tracking through its substance (5:4b) to emerge later (6:1b) In this section, mixed thrombus and atheromatous material partially obstruct the lumen.

x 8



5:3a



5:4b



6:1b

5:3a : injection medium entering discoloured intimal plaque and tracking through its substance (5:4b) to emerge later (6:1b) In this section, mixed thrombus and atheromatous material partially obstruct the lumen.

x 8

The cause of the initial break in continuity of the intimal lining could not be determined in this or in the other examples, and was a matter for speculation. It may have been that bleeding from an intimal vessel had led to distension and then to disruption of the plaque. The appearances in my preparations could also have been produced by a simple break in the lining as the result of undue stress.

I can readily accept that rupture of intimal vessels in direct communication with the lumen may take place (Paterson, 1952) and lead to haemorrhagic lesions of considerable dimensions, such as the haematomata described by Wartman, 1938, 1950; Winternitz et al, 1938; and others. I am much more doubtful, because of the pressure relations which must exist, that distension of a plaque to the extent of rupture into the lumen, can occur as the result of haemorrhage from intimal capillaries arising from the vasa vasorum. The emphasis in my specimens has been on haemorrhage from the lumen into the plaque and not the other way round, so far as I could judge.

I was glad to have one example in my series of extrusion of atheromatous material into the arterial lumen. I might otherwise have been tempted incautiously to dismiss the findings of others as artefact. It would be an easy matter to compress the artery from without, either in the general handling of the heart or when cutting the artery with the knife, so that the soft contents of the atheroma were forcibly extruded into the empty lumen of the artery. In these circumstances there would be no counter pressure from the circulating blood to support the thin and friable covering of the atheromatous abscess. In my preparations this thin shelf of material was protected during processing by the solid injection medium. The observations of others on this topic were made on arteries which had not been injected - not at any rate by a medium which later gave support. Further, the pultaceous debris which forms the contents of atheromatous abscesses is readily lost during the preparation of paraffin

sections unless held in position, as by gelatin. Gelatin embedding was employed routinely in my series. The absence from my preparations of empty atheromatous cavities, as described by others (e.g., Morgan, 1956) may have been not unconnected with this procedure. I am therefore inclined to suppose that the discrepancy between my own observations and those which have been quoted may lie, at least in part, in differences of technique.

The counter objection could of course be raised that in using an injection method I might have dislodged material and in this way destroyed or disturbed the evidence. The point is a valid one, and one to which I gave attention following each injection. There was no good evidence that material taking part in thrombotic occlusion had ever been dislodged by the injection method employed. I was surprised at this; and yet not surprised when I reflected upon the manner in which the same material during life had withstood pulsatile blood pressures for days or weeks beforehand.

In each case a careful search was made for material which might have been dislodged and carried downstream. The magnified stereoscopic view of the injected arterial tree allowed me to follow the branches down to the smallest twigs. Routinely small filling defects were searched for and when found were examined. In a few instances they were due to fragments of blood clot which could have been agonal or post-mortem. A few others were due to isolated atherosclerotic patches in the smaller branches, or to bubbles. Never did they appear to be ectopic material from an atherosclerotic plaque (with the single exception described above). Moreover these small filling defects were found in branches of such small calibre and restricted anatomical territory that they could have had no functional importance even if they had existed in life as arterial obstructions. Except where due to atheroma, as in Case 24 ADA (arteriogram of intact heart), their occurrence was most uncommon in my later cases. Moreover they occurred in control cases without arterial disease. I am satisfied that these minor fragments and narrowings are not to be identified with the occurrence of coronary occlusion from embolism, following extrusion of the contents of atheromatous abscess, as described by others.

Injection medium commonly entered the intima post mortem, as remarked above. Trauma to the artery wall may have been the cause in a few instances which occurred within 2 cm. of the point at which the cannula was tied in. In the majority of such invasions of the intima by injection medium elsewhere, the injection followed the course previously taken by haemorrhage. Sometimes however it had apparently carried the dissection of the intima in a distal



proximal, or circumferential direction to a greater distance than had clearly been the case with the haemorrhage during life. Never (save once) did it "surface" again at another point on the artery. Rather it tended to track towards the outer layers. Both blood and injection medium tended to seek out planes of cleavage in the structure of the plaques. Many examples of injection medium in the arterial intima are to be found in the illustrations.

( Curiously, this is an aspect of post-mortem injection of coronary arteries upon which I have noticed only silence in the writings of others who have employed such techniques.

#### Other Local Factors in the Promotion of Thrombosis

When the arterial wall was examined, in the region of occlusive thrombosis of less than 6 months duration, it was noted - with rare exception - that there were features in its composition which suggested that it had itself been formed from thrombus at an earlier date. That is to say, the tissue which immediately underlay the thrombus was often predominantly fibrous; was stained by blood pigment; contained iron; was typically crescentic in configuration; and was the seat of numerous intimal vessels. Some lesions however were heavily loaded with lipid.

It was striking that fatal thrombosis had nearly always occurred on an artery that had clearly - to my way of thinking - been the seat of previous thrombosis. Fatal thrombus was therefore but one of a series of thrombotic episodes. The pale, relatively avascular atheromata of simple construction were by contrast remarkably free from thrombus formation on their surface.

To state that the commonest condition found to underlie fatal thrombosis was previous thrombosis is of course only to defer the issue one stage further back. Yet I feel that the observation is sufficiently striking to merit recording, and is in accord with the other concepts expressed in this chapter in regard to the pathogenesis of atherosclerotic lesions.

TABLE 7  
THEORIES ON THE PATHOGENESIS OF ATHEROSCLEROSIS

Senescence theory (aging of colloids, wear and tear, circulatory trauma).	
Theory of fatty degeneration of clotted blood in mural thrombi (Duguid) <sup>9</sup> or subintimal hemorrhages (Winternitz <i>et al.</i> ) <sup>17</sup>	
Intimal plasma cholesterol infiltration theory.	
Reticuloendothelial lipophagy theory (Leary). <sup>14</sup>	
Colloidal-macromolecular theories:	
A. Macromolecular instability theory (Hueper) <sup>20</sup> .	
B. Lipoprotein theory (Gofman <i>et al.</i> ). <sup>14</sup>	
C. Chylomicron theory (Moreton-Neecheles). <sup>20</sup>	
Mucopolysaccharide theory (Moon and Rinehart). <sup>21</sup>	

TABLE 8  
THE MACROMOLECULAR THEORY OF ATHEROSCLEROSIS

I. Primary diseases causing:	
1. Disturbances of the lipid metabolism (hypercholesteremia)	
2. Deficiencies in colloidal stabilizers (albumin, phosphatides, fatty acids) of cholesterol aggregates	
3. Deficiencies in degrading and dispersing agents of lipoproteins and cholesterol micels	
II. Secondary colloidal plasmatic disturbances (plasmatic colloidal instability) produced by:	
1. Cholesterol containing particles (micels, lipoproteins, chylomicrons) of proper size suitable for endothelial phagocytosis	
2. Cholesterol containing particles of proper low density for accumulation in marginal plasmatic stream	
3. Cholesterol containing particles of labile colloidal state favoring conglomeration and precipitation through vibration and turbulence	
III. Localization of atheromas favored by:	
1. Areas of transitory blood stagnation and vibration (coronary arteries)	
2. Areas of plasmatic turbulence at sites of intimal irregularities (bifurcations, orifices, retractions, elevations, narrows, fixation, curves)	

SOME CONCEPTS OF ATHEROGENESIS

Study of the genesis of atherosclerotic lesions may be divided into two phases:- (1) The earliest changes and primary causes, and (2) The subsequent development of the disease process which eventually leads to lesions of clinical importance. It may be that the one is but a continuation of the other but this is far from clear. My remarks upon this subject will likewise be divided into two portions. I wish to emphasise at the outset that any views or arguments which I may advance in regard to the primary genesis of the "early" lesion are based largely on theoretical grounds or on the observations and opinions of others; whereas concepts expressed on the genesis of larger lesions are closely supported by, and mainly based on, my own observations.

(a) THE GENESIS OF "EARLY" ATHEROSCLEROTIC CHANGES

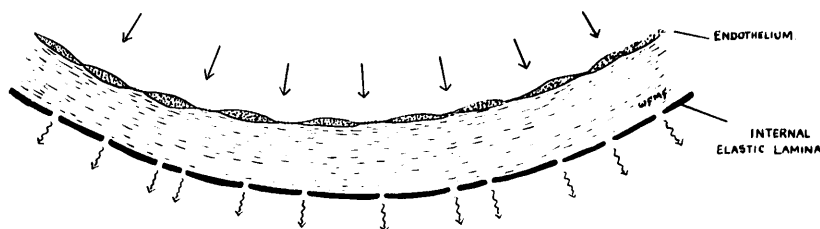
The nature of my own observations on atherosclerosis gives me an interest in the ultimate genesis of the disease process but does not provide me with any special advantage in the assessment of the vast experimental and biochemical literature that is devoted to this topic. I shall accordingly excuse myself from attempting a critical review of current concepts of atherogenesis - except in the briefest terms - on the grounds that to do so would exceed the scope of the present investigation. On the page opposite a summary of present concepts and some aspects of the macromolecular theory have been taken from a recent review article by Hueper (1956). I shall confine myself to a few comments which do not pretend to be comprehensive. And I shall take the liberty of indulging in a few ideas largely of conjectural origin.

There seems little doubt that under normal circumstances fluid from the blood passes outwards through the inner walls of the artery. The normal intima

appears to depend upon this process for its nutrition and therefore for its integrity. From the nature of the tissues which compose it, one would imagine that the metabolic requirements of the normal intima must be exceedingly low. That is not to say however that the quantity of nutrient bearing fluid passing through this structure bears any relation to its metabolic needs. It may well be far in excess of basal requirements.

The normal intima is composed of three layers: the single cell thick endothelium, the internal elastic lamina and the fibrous material interposed between these layers. The internal elastic lamina is thought to be a continuous structure in which there are numerous apertures, not unlike a sieve or strainer. Indeed if we look upon it as the perforated base of a Buchner filter funnel and upon the fibrous and endothelial layers as two layers of filter paper or other material we may have not only an anatomical but a functional simile not very far from the truth. (See Diagram 8:6)

DIAGRAM 8:6



It will be noted in this view of the structure of the arterial intima, that the fibrous material in this structure is differently situated from fibrous material at other sites (including the intima of veins and the subendocardial tissue of the heart itself). For it is compressed against the "rigid" resistance of the tensed elastic lamina. In this way a fine fibrous structure will presumably offer resistance to the passage of smaller particles than would otherwise be the case. I do not know whether this is important but I think it may be. There is also a further point that the somewhat coarse fibrous structure of the intimal tissue in micro-section is partly if not largely



"When the intima is thickened, the lipoproteins would not pass through with facility and some of their lipid would tend to deposit. Thus the quality of the vascular filter may be a determinant of atherogenesis in the presence of normal plasma lipids.

It is easy to see that the ability to penetrate the vessel wall would also depend in part on the physical characteristics of the plasma lipids. Lipids not combined with protein have the characteristic inability to be wetted by water and would not be expected to enter or pass the endothelial cells and internal elastic membrane with ease even if they were present in plasma. The hydrophylic lipoproteins would be expected to behave oppositely. The large beta-lipoproteins, heavily and unstably laden with lipid, can certainly pass through the vessel wall and appear in the lymph. But the possibility exists of their being retained in the meshes of the filter, disintegrating and shedding their lipid load which is later picked up and stored by macrophages. Without the protein to maintain its water solubility, the lipid becomes a foreign body trapped within the vessel wall."

Irvine H. Page, 1954, citing  
mainly the observations of Evans and of Wilens.

---

Filtration of serum through excised artery wall was studied by Wilens. The filtrate was unchanged serum in respect of most organic substances but contained very little cholesterol, relatively little protein, and a diminished amount of calcium. Some of the cholesterol penetrated the intima, but its further progress was barred by the internal elastic lamina.

Wilens, 1951, (cited Wood, 1956)

---

artefact, the product of differential shrinkage of the material on a microscopic scale, as occurs in fixatives and other reagents. Possibly changes also take place on freezing. I regret that I have no observations on fresh unfixed material. I question whether the fibrous layer in the intima in life has a permeability of the order that its structure, as witnessed in micro-sections, would suggest. I wish to assume, for purposes of argument, that the intimal fibrous material, supported by and compressed against the grid formed by the elastica has a porosity too fine for the passage of some larger molecular aggregates - indeed that it is capable of filtering larger particles from the fluid which passes through it.

The endothelium is an exceedingly thin single layer of flattened cells and to judge from experimental work is evidently capable of letting pass through it substances of large molecular size. I have no idea whether the permeability (in this respect) of the intimal fibrous layer or the endothelium is the greater but I do not think it should be assumed that the greater resistance is offered by the endothelium and that the resistance in the fibrous layer is by comparison negligible. The reverse might be the case.

That molecules of large size such as lipoprotein aggregates can pass through the barrier of the endothelium into the intima would suggest that all fractions of the blood plasma, except perhaps larger chylomicrons, may enter the intima. For the most part attention has been concentrated upon the lipid fractions and I shall start from this standpoint.

It has been repeatedly shown that when large quantities of cholesterol are administered to a suitable animal such that its plasma cholesterol levels are raised several fold above the normal, or substances of large molecular size such as acacia or polyvinyl pyrrolidone (Hueper, 1942, 1956; Hartman, 1952) are given intravenously accumulation of these substances appears in the arterial intima. The material is located in or beneath the endothelium and is contained in foam-cells.

Gofman et al., 1950

Using the ultracentrifuge, "it is possible to demonstrate the presence of certain lipid and lipoprotein components which are related to coronary atherosclerosis to hypertension and to other diseases associated with atherosclerosis ...

Molecules in the serum were classed according to their Svedberg flotation values ( $S_f$ )

"Species of discrete classes... migrate with rates between 10 and 20  $S_f$  units. These components, whose molecular weights are in the neighborhood of 3,000,000, appear definitely related to the presence of atherosclerosis in humans" (as judged by the presence of clinical coronary artery disease, myocardial infarction).

"These molecules are present with a much higher frequency and at higher concentrations in patients who have survived a myocardial infarction than in corresponding individuals without known vascular disease."

"These molecules do not represent any part of the acute alimentary lipaemia" ... which have  $S_f$  values of 30-70.

Gofman et al., 1950

Hueper, W.C. Ref. to substances deposited in arterial intima (exptal).

- |      |                |         |                              |
|------|----------------|---------|------------------------------|
| 1941 | Arch. Path.    | 31: 11  | - Polyvinyl alcohol          |
| 1942 | Arch. Path.    | 33: 267 | - Macromolecular substances. |
| 1944 | Amer. J. Path. | 20: 737 | - Methyl cellulose.          |

Atherosclerosis is twice as frequent in hypertensive as in normotensive subjects.

Wood, 1956, citing Wilens, 1947.

It seems to me quite reasonable to suppose that some concentration of an already grossly elevated cholesterol in the plasma may take place as it percolates through the intima, and equally reasonable that some disturbance of colloidal stability can also contribute to its deposition. It cannot however be overstressed that the conditions under which these changes occur in the experimental animal are not slightly, but grossly, abnormal. It can no more be assumed that the accumulation of lipid in the intima under these conditions has relevance for the genesis of the early lesions in man, where the deviation from normal blood chemistry is slight, than can oedema be attributed to an increased intake of salt. It may nevertheless be so in some circumstances or in gross excess. I think that factors which condition the manner in which lipid is handled as it passes through the intima may have greater importance in the naturally occurring human lesion, than the plasma lipid changes commonly found.

Is it not possible, as the plasma is pressed through the intima, that there is a progressive concentration of its macromolecular constituents? And further, that the degree of concentration attained by the time the internal elastic lamina is reached will depend (amongst other factors) upon the thickness of the intimal tissue and the initial concentration of these constituents? If this be so, deposition of lipid material in the intima may be favoured by either of two factors, or by both: (1) by increasing the plasma concentrations to saturation or supersaturation levels or (2) by increasing the thickness of the intimal tissue.

In my own preparations small collections of fatty material were found only where the intima was already thickened. This would therefore suggest that intimal lipid deposition in naturally occurring disease (in which the concentration of lipid in the plasma have not been grossly abnormal) may be conditioned by pre-existing intimal thickening beyond a critical degree. Intimal lipid deposition in the experimental subject on the contrary appears to be brought

The serum cholesterol in chicks was raised from about 100 mg.% (normal) to 1000 mg % after 2 weeks and 2000 mg. % after 8 weeks , on a diet containing 2 % cholesterol and 20 % cotton-seed oil.

Horlick and Katz, 1949, (cited  
Katz and Stamler, 1953, p.140)

Regression of experimental atherosclerotic lesions has also been noted by :

Anitschkow, 1933 cited Katz and Stamler, 1953  
(rabbit)  
(also Stukken, 1910; Krylow, 1916 ; " "  
Wada, 1926 ; Scarff, 1927 .)

Regression of human atherosclerotic lesions alluded to by:

Wilens, 1947  
Duff and McMillan, 1951 (cited Katz and  
Stamler).

"Man is the only animal that ingests eggs and milk throughout his lifetime. Man is also the only animal, as far as is known, that dies early in life of coronary sclerosis, and suffers almost universally from atherosclerosis in the later years of life."

Leary , 1935 b.

Gofman et al., 1952 cf. Gofman et al., 1950.

"The S<sub>f</sub> 12-20 and S<sub>f</sub> 35-100 lipoproteins show strong association with atherosclerosis regardless of age or total serum cholesterol level.....There is strong ability of the S<sub>f</sub> 12-20 and S<sub>f</sub> 35-100 lipoproteins to segregate atherosclerotics from normals."

"The demonstration that the S<sub>f</sub> 35-100 lipoproteins...are associated with atherosclerosis is of especial significance with respect to the ingestion of fat. This class of lipoproteins may be raised acutely in a high proportion of humans following ingestion of fat."

about by raising the plasma lipid concentrations above a certain level, below which lipid deposition would not occur in an intima of normal thickness.

In regarding intimal thickening as a pre-requisite of intimal lipid deposition from near-normal plasma lipid values, the importance of deviations from normal of lipid blood chemistry is only modified, not discounted. Thus, the greater the deviation from normal towards higher, or less stable, values, the lesser will be the critical thickness at which lipid deposition takes place, and the more rapid the progress of the early stages of the lesion; and conversely, the less readily will the condition regress. For it has been shown that regress of early lesions induced experimentally may take place when plasmatic conditions are allowed to revert to normal on cessation of cholesterol feeding (Horlick and Katz, 1949; and others). Sustained abnormal lipid plasma values may have as much significance for the irreversible establishment of the early lesion as the levels obtaining at its inception. (The maintenance of a high level of dietary intake of fat emulsions beyond infancy may conceivably be detrimental to the thickened arterial intima.)

The development of fibrous tissue in relation to experimentally induced intimal lesions has been described (e.g., Hueper, 1956). Whether this is closely related to the presence of fat or is an expression of the bulk of the lesion, the thickness of the intima or some other factor is not clear. It remains that in the experimental lesion the advent of fatty material comes first. The reverse was the case with the earliest human lesions that I have observed in the adult. In the human lesion moreover the presence of lipid seemed to excite remarkably little reaction from the tissues in which it lay. Thus there was little collagenous or cellular reaction which appeared to be directly related to the presence of fatty material.

Perhaps in coming to this point of view I am biased by awareness of an alternative explanation, in terms of thrombus and intimal haemorrhage, for appearances that might otherwise be attributed to the presence of lipid.

I do not accept that lipid in the necrotic centre of the lesion has necessarily had any causal part to play in that necrosis, but rather the other way round; nor do I hold that the presence of intimal vessels in the neighbourhood of lipid material is causally related to it. Rather I have tended to the point of view that fibrosis was due to other causes and that its influence upon the deposition of lipid was profound. Nevertheless all findings are not satisfied by any one point of view. Thus, for instance, the deposition of lipid at a little distance from the endothelium and not immediately under it is readily reconciled to the concept of progressive concentration of lipid material in the plasma in transit through the intima. Yet, it must be acknowledged that lipid deposition is sometimes seen immediately beneath the human endothelium.

I have wondered whether the rate at which plasma percolates the intima, and therefore the time for which lipid complexes pause in transit in this tissue, could have an influence on the stability of such complexes and their deposition. If this were so, it would be in keeping with the manner in which an atherosclerotic plaque is localised to one sector. The process having started at one point would thereafter favour, with progressively increasing persuasion, the further deposition of lipid at that site. Whereas, were the reverse the case, one might expect a more generalised distribution to be the rule.

No matter how suggestive the circumstantial evidence which relates changes in the plasma to changes in the arterial intima, a comprehensive theory of pathogenesis must also take into account the localisation of the lesions. Conversely, if it be held that localisation of the lesions to certain points in the arterial tree results from local strains, weaknesses or special conditions of blood flow, this does not affect the validity one way or the other of concepts based on altered plasma chemistry. It may well be that local

"If the preferred sites of atheromatous deposits are analysed from a haemodynamic point of view it is apparent that they represent spots where the uniform flow of blood is acutely disturbed, i.e., where turbulence of the blood occurs....."

..The blood in the proximal parts of the coronary arteries is subjected to a similar mechanism when the intramyocardial circulation practically comes to a temporary standstill during systole. The blood is then pressed into the extramyocardial parts of the coronary vessels and especially into their proximal portions, setting up there violent whirls in the stagnant blood. Any local dilatation of the vascular wall such as..... produced functionally from one-sided circumscribed fixation or resistance, exerts a similar effect on the current of blood. Natural or pathologic narrows, such as passages through bone, or the presence of orifices of branches, bifurcations and curves also increase the turbulence of the blood stream in circumscribed parts of the arterial tree.

Inasmuch as these disturbances in the flow of blood are likely to have most effect on the marginal plasmatic current in which the colloidal lipid aggregates are accumulated, and because vibratory forces acting on a labile colloidal solution favor flocculation and precipitation of the colloids, sites at which turbulence of the blood occurs represent favored spots for the development of atheromatous lesions."

Hueper, 1956



factors based upon anatomy determine the site of the lesions and generalised factors in the plasma determine their inception and further development. Both may be necessary for the natural occurrence of the human disease.

In this connection there are points both for and against the importance of inherent structural factors in the arteries. Thus on the one hand the predilection of the disease process for the arch of the aorta and its abdominal portion, or for the coronary arteries (especially the early part of the anterior descending artery) would suggest that there is some local factor of an anatomical nature which conditions the heavy incidence of atherosclerosis at these sites. On the other, the detail of distribution of individual lesions appears to be, within limits, haphazard and does not readily lend itself to simple anatomical interpretation. Admittedly correlation may be made with the curvature of the artery, the position of branches etc. but it remains that the detail of distribution is not uniform in essentially similar situations in the individual and at the same sites in different individuals.

Hueper (1956) has propounded a theory which attempts to relate general factors conditioning lipid deposition and localising factors in its distribution to the one primary cause. He emphasises not so much the absolute concentrations of the various lipid and lipo-protein fractions, that are generally invoked in the aetiology of this disease, but rather the colloidal stability of these substances in the plasma. He further emphasises the importance for this stability of certain physical conditions and points out the possible manner in which these conditions may differ at various sites in the arterial tree under the influence of pulsatile blood flow. His own words are quoted on the opposite page.

I find this an interesting concept but wish to pass no comment on its validity. Certainly many of the features of localisation of atherosclerotic plaques might be explained on a basis of physical conditions of blood flow.

But, I wonder, are their effects upon the arterial intima necessarily mediated by colloidal stability of lipid complexes? Is it not possible that the same saddle might be used to ride another hobby-horse? It occurs to me that the factors of turbulence and vibration may disturb the delicate balance of the blood coagulation mechanism. Is it not possible that fibrin deposition may take place on the arterial intima with special predilection for certain sites, likewise related to considerations of anatomical configuration and phasic blood flow? (What about the "impingement plaque" in mitral stenosis?) Indeed I think it may be probable.

When one looks at the manner in which the aorta has been affected it is not always possible to relate the detailed distribution of the plaques to the positioning of the orifices of its branches. It would seem either that some other factor in addition must be operative, or else the lesions may arise without any inherent localising factor. The same would apply to the right coronary artery where the distribution of lesions varies so greatly. Can it be that surface thrombosis may occur upon an arterial lining which is intact and without the influence of special physical effects of blood flow? Perhaps it is so. Surface fibrin deposits are said to be found not infrequently in the arteries post mortem (e.g., Harvey, 1956), and it is not clear that these are always agonal formations. Duguid (1948) claims that they are common and undergo organisation. To my way of thinking the miracle is not that they occur at all, or that fibrin deposition or frank clotting of the blood seems to take place mainly at certain sites, but that such events are not more common and more universally distributed. Perhaps we should in fact approach the subject primarily from the stand point of factors which stabilise the coagulation mechanism, or which lyse small fibrin depositions before their organisation can lead to intimal thickening. Fullerton (1955) recommends that "it should be borne in mind that variation in fibrinolytic

activity may be important in determining the onset of atheromatous lesions". Little is known of factors which may influence fibrinolytic activity and much still remains a mystery about blood coagulation. Theoretically at any rate, plaque formation on the intima would be favoured where the tendency to coagulation of the blood outstrips fibrinolytic activity and vice versa.

In this connection it is of interest that the coagulability of the blood was found to be considerably increased as the result of the lipaemia which follows a fatty meal (Fullerton, 1955). There may therefore be a relationship between lipid levels in the blood, enhanced coagulability of the blood, fibrin deposition and atherosclerotic changes. It is an intriguing thought that a high fat intake could have a detrimental effect upon the arterial intima, not primarily through lipid deposition, but indirectly through fibrin deposition, the result of an accompanying enhanced blood coagulability. Enhanced coagulability of the blood following a high fat intake was previously described by Duncan and Waldron, 1949, and denied by Tulloch et al., 1953

A highly speculative concept of gradual intimal thickening.

It does not necessarily follow that fibrin deposition takes place only upon the surface of the intima. In atherosclerotic lesions it is not uncommon to observe small patches in the paler staining collagenous tissue which show the staining reactions of "fibrinoid". Indeed even individual fibres may be so affected. When stained with Weigert's fibrin stain some of these areas also stain faintly purple as for fibrin. In the classical view such areas represent fibrinoid degeneration of collagen. For reasons already expressed I think that this interpretation places the changes in the wrong sequence. It is more probable that we are witnessing a late stage in the conversion of fibrinous material into organised collagen, and that only a few patchy areas remain. Is it possible that, in addition to this process, fibrin may on

occasion be deposited from the plasma as it percolates the intimal plaque? If this occurs it is surprising that there is not more abundant evidence. (It could of course be that the intimal tissues have anticoagulant or fibrinolytic properties or simply that very small quantities of fibrin are rapidly converted and are not distinguished by staining methods.)

(When we consider the intima of the normal artery, the distance from endothelium to internal elastic lamina is very short (50 microns or less, sometimes only a few microns) and one may imagine that fibrinogen-containing plasma may not linger long in transit. The length of time that would be required for fibrin to form need not bear close relation to extravascular clotting times as estimated by conventional methods, for it may be that intimal tissues do not favour blood coagulation. Indeed it is often surprising how restricted is the clotting which seems to have taken place on a grossly damaged aorta. Suppose for purposes of argument that, under the conditions of blood coagulation existing in intimal tissue, fibrinogen and other factors initially are swept through the normal intima too rapidly for fibrin deposition. The presence of intimal thickening however will produce conditions under which the time taken by the plasma to pass through the intima will be prolonged, thereby favouring fibrin formation. From the point at which fibrin deposition in the intima becomes a frequent occurrence, the tendency would be for the thickening to increase preferentially at that site. In this way a vicious cycle may be set up. *Pari passu* with thickening, and under similar influences, lipid deposition may take place. So long as the intima remains of normal thickness the vicious cycle of events may never be entrained. It is noteworthy that we may find thickening at one side of an artery, in section, and none at the other in long standing disease. The possibility may also be entertained that this cycle of events may progress until the lesion is large and the lumen greatly encroached upon. There are however a few points to consider, which may modify the progress of the lesion.

If there be any truth in these suppositions, it may also be that the initial acceleration with which the lesion gathered bulk through fibrin deposition will not be maintained. There may be an optimum period when most of the fibrinogen filtering through the thickened intima will be deposited. The time will come however when the law of diminishing returns comes into play. As the bulk of the lesion increases, so will resistance to the passage of fluid, and the smaller will become the total quantity of plasma, and therefore of fibrinogen and lipid, entering the intima in a given time. The initial rate of growth of the lesion will thereby slow down in exponential fashion. As the entry of fibrinogen and its rate of transit become reduced it might be expected that a fibrous layer would be laid down near to the inner margin of the lesion. It may be noteworthy that established large atheromata of simple construction often show a fibrous layer of some density under the endothelium. As the lesion grows in size, the resistance to percolation by plasma increases and the luminal surface through which it can enter diminishes. It may be that eventually growth of the lesion comes virtually to a halt.

In thinking about this concept I have noted that in my preparations there was no instance of narrowing of the lumen to less than 1 mm. diameter (and I think that 1.5 mm. might be nearer to the case) in which narrowing to this degree was not more readily accounted for by thrombosis and its organisation - commonly in the form of complete occlusion with canalisation. In other words there was no lesion, to judge from its structure, that seemed to have increased through gradual stages alone to such an extent that narrowing of severe degree was produced. It almost seemed as if the gradual process, if such a process takes place at all, was self-limiting unless complicated by surface thrombosis; and that the limit at which growth of the lesion halted was short of that which produced clinically important lesions. (The significance of the degree of narrowing in terms of myocardial damage has received treatment in Chapter 5.)

If there be any foundation for this concept I think it may be an important one. There is a proportion of atherosclerotic lesions of large size whose detailed structure could lend itself to this interpretation of its formation. But it is only for a proportion of atherosclerotic lesions that I tentatively advance this concept. On the one hand fibrin may be slowly deposited beneath the endothelium and be changed to collagen in the intima; on the other it may be deposited in more massive form on its surface and later incorporated into the intima. In both instances fibrin is the devil and lipid deposition his accomplice, in this fanciful conception of atherogenesis.

#### (b) THE GENESIS OF THE LARGER ATHEROSCLEROTIC PLAQUE

In the foregoing pages some theoretical considerations were put forward in the genesis of the early lesion. I wish now to summarise some of the ideas that I have formulated about the development of atherosclerotic lesions of larger size and therefore of greater immediate clinical importance. In doing so I shall be attempting to interpret the findings that I have made on the material of this investigation. In this respect, what I now mean to say differs from the views expressed in the immediately previous pages, in which I indulged in theories outwith the scope of my own examination. I shall try to prevent deviation from my own observations into arguments based upon the findings of others but shall, as elsewhere, introduce on the opposite page a selection of relevant passages or points of view from the writings of others on this subject.

I have already indicated that in my view many of the more severe lesions of atherosclerosis could have been derived from thrombus. I shall first describe what I conceive at present to be the process involved in the development of such lesions.

For some reason which may or may not be determinable in the individual lesion, thrombosis takes place in a coronary artery. Commonly this has already been the seat of earlier atherosclerotic changes, but the presence of antecedent damage in this connection is not essential to the process. It is merely more likely, so it would seem, that thrombosis will take place on such a surface. The initial lesion may or may not itself have been of thrombotic origin. I prefer not to commit myself on that point. Let us therefore consider the changes which take place after a thrombus has formed, which occupies between  $1/3$  and  $2/3$  of the lumen area, in cross section.

*What about the platelets?*

The endothelium depends upon contact with the flowing blood for its nutrition. In course of time the overlying thrombus, which is probably largely fibrinous in its base, suffocates the endothelium. The endothelium degenerates and disappears. Exactly what happens at this point I do not know, for I have not witnessed stages in the degeneration of endothelium, only its presence in early cases and its absence under thrombi a week or more in age.

Fibrinous thrombus is then left in contact with the fibrous tissue of the arterial intima. This is commonly already thickened and the presence of thrombus excites remarkably little activity. In course of time, probably a few weeks, scanty fibroblasts invade the fibrin network at the base of the thrombus. About the same time an alteration in the staining qualities of the fibrin is seen which corresponds closely to "fibrinoid". Collagen<sup>φ</sup> fibres later appear in the same situation as formerly occupied by fibrin. In this process there is no complete break down of fibrin but the material seems almost as if converted from fibrin into hyaline material, staining as for collagen.

φ I use the term "collagen" guardedly, here as elsewhere in this chapter.

The process of collagen fibre deposition which encroaches upon the thrombus does so from its base, which is the segment of a circle, and also from its surface. After a time, endothelium supported upon a thin layer of collagen is seen to have spread across the surface of the thrombus. In many cases this process continues until the entire fibrin thrombus is converted into a fibrous structure. In doing so there has probably been no great change in bulk of material, or perhaps a moderate amount of shrinkage. The resultant lesion is crescentic in shape tapering at the margins into the circumference of the artery wall.

While organisation of the clot by collagenous tissue has been proceeding, the clot has not in other respects been static. Red blood cells entrapped in the fibrous network are preserved for a long time but gradually degenerate and form an almost amorphous debris. If this debris is considerable in amount an accumulation of soft necrotic material appears at one or more places in the depths of the lesion. The necrotic material is not composed of degenerated red cells alone but also degenerated fibrin and other cellular material. The necrotic material appears to offer resistance to organisation by fibrous tissue and invasion by vascular tissue; and at the same time to favour the deposition of lipid.

I have observed that lipid may develop in the depths of a thrombus as if it were a product of decomposition. I doubt however that much of the lipid found in the atherosclerotic lesion has been so formed. I think that it probably derives mainly from the lipid in the plasma. From its earliest inception thrombus in contact with the intimal lining at the one side and circulating blood at arterial pressure on the other will have been subjected to a gradient of pressure, under which fluid from the blood will tend to be forced outwards through the clot and artery wall. Sometimes the effect is to cause partial separation of the clot from the wall, but that leads to another matter.



The fluid so pressed into the thrombus material may at first contain some blood cells but probably in course of time, and certainly after covering by endothelium, the fluid is essentially plasma. It is accordingly loaded with nutrient, fibrinogen and lipids. As the clot becomes more organised and the spongy fibrinous structure less in evidence, conditions seem to favour the deposition of lipid. Whether this is a simple matter of concentration to the point of separation from colloidal suspension is not clear. It seemed, however, in those lesions still largely composed of fibrous material, that lipid deposition took place mainly in the deep layers of the plaque. In course of time lipid accumulates in such lesions until it is almost universally distributed. The distribution is not however uniform. Lipid is deposited with special predilection in the necrotic material, where large crystals of cholesterol may eventually form. Relatively little lipid, and then only of small particulate size, is deposited as a rule immediately under the endothelium.

In my view there is probably a race between autolytic changes and the development of fibrous tissue from fibrin. By the time thrombus has undergone necrotic change it would seem that the opportunity for satisfactory fibrosis has been missed. I contend that atheromatous abscesses are commonly the result of autolytic changes in the thrombus before fibrosis; and not the result of secondary necrosis in the centre of a previously well organised lesion. Some lesions did indeed lend themselves to the second and classical interpretation but the majority that I have studied were more in keeping with the first. It may be that both processes can occur depending upon the circumstances.

Calcification is a later development and probably follows the saponification of lipid in the deeply placed, necrotic "abscesses".

Cellular activity in the form of round cell infiltration appears to be a late-comer in the field. I doubt that it plays any part in the development of the lesion. The remarkable thing about organisation of intravascular fibrin thrombus is the freedom from the usual cellular reaction which precedes and accompanies fibroblastic activity in organisation at other sites. Accompanying the cellular reaction in the base of the lesion there is ingrowth of vascular tissue from the adventitial vessels. I think that these vessels are probably at their zenith in the more recently organised lesion and that they may gradually diminish in the older lesion - but of this I am not sure. At any rate they do not to my mind have the importance in disease that is held by the intimal vessels arising from the lumen.

It is usual to speak of vascularisation of the intima. I think that this is by implication an error. I think that the intimal vessels which arise from the lumen have their beginnings in the spaces in the spongy clot before organisation. Even when the lesion has been fully organised these intimal vessels retain the spongework structure of spaces mechanically formed in blood clot. They are thin-walled, cavernous and friable. Their presence does not represent "purposeful" blood supply to a tissue but a failure of organisation, a fragmentation of the original thrombus structure and its partial separation, which fibrosis has been unable to overcome. It is doubtful whether they commonly have venous connection, and doubtful whether they make useful contribution to the nutrition of the plaque. Their presence, far from being an evident benefit, introduces the dangerous hazard of intimal haemorrhage. They are at their largest in lesions of apparently recent origin which are still unstable and liable to further complication. When found in lesions of obvious long standing and freedom from complication they are usually smaller and fewer. I do not think that their small size in these lesions represents an early stage in vascularisation of the intimal plaque but a stage in the regression of structures whose presence has been from the beginning fortuitous.

The progressive accumulation of lipid probably leads to a progressive increase in the size of the lesion, but I have no evidence to show that this is so. It is quite possible that large lesions have as a rule been large from the beginning, as determined by the size of the original thrombus. In other cases the increment in size would appear to have taken place by recurrent episodes of thrombosis and its organisation. In many cases it is compound lesions of this order that are eventually the seat of a last and fatal episode of thrombosis, blocking the remaining lumen completely.

No matter what be the status of thrombosis in the genesis of pale established lesions which at death can produce a clean sheet to proclaim their innocence from circulatory obstruction, I feel at present convinced that the overwhelming majority of lesions which give rise to clinically important obliterative coronary artery disease not only have thrombosis as their fatal complication but lesser degrees of thrombosis in their earlier development.

After following the various stages in the conversion of thrombus into atherosclerotic tissue the following features were regarded as pointing to a thrombotic origin for an atherosclerotic plaque.

1. Crescentic formation, particularly if one or more than one crescent was superimposed upon the other in the structure of the plaque.
2. Staining of the plaque by blood pigment.
3. Iron deposition.
4. Masses of "fibrinoid" tissue in the depths of the lesion.
5. Fibrinoid changes in the region of surface thrombus of some standing.
6. Intimal vessels - a) from the lumen  
b) from the adventitia, vasa vasorum

It would be easy to take each one of these points separately and provide for its presence a reasonable alternative explanation. Thus crescentic formation, no matter how closely it may simulate the initial disposition of

thrombus, could be the product of gradual lipid deposition and accompanying fibrosis; staining and iron deposition may result from haemorrhage; fibrinoid tissue from necrosis; intimal vessels may have grown into the plaque as it increased in size; fibrinoid changes at the base of a thrombus may represent the stage of fibrinoid degeneration which encouraged the thrombus to form in the first place. I doubt the probability of each one of these explanations but cannot disprove them. To quote MacKenzie (1923): "In medical observations it is not always possible to get direct evidence for the solution of a problem. We then have to proceed by inference." I contend that the common factor which can provide a tenable interpretation of all these features at once is their common genesis in the organisation of thrombus. No other concept has so much in keeping with the wide variety of configuration which may be comprised under the heading of atherosclerosis. The multiplicity of structural forms presented by the atherosclerotic lesions can be related to the variety of size, extent and composition of primordial intra-arterial thrombus.

I do not know what part lipid plays in the genesis of this disease. If it contributes to the size of the lesions then it will contribute to encroachment on the lumen. If the lipid-laden atheroma is more prone to thrombosis on its surface, or to haemorrhage, then in lipid may reside the seeds of disaster. If the initial damage, which sets in motion the train of events described, be a product of faulty lipid metabolism, then the fundamental importance of lipid in this disease cannot be overstressed. I have not sought in this thesis to belittle or to discount the importance of lipid and would not presume to do so on pathological grounds alone. I can only place on record that I have sought to make my observations as objectively as possible. I have tried alike to avoid artifact and prejudice. And in the coronary arteries I have found more to incriminate thrombosis than lipid deposition in the pathogenesis of clinically important atherosclerotic lesions.

SUMMARY

As indicated in its title, this chapter is an essay on the genesis and micro-anatomy of atherosclerosis and as such is not readily summarised, save in barest outline. The last section, however, under the heading of "Genesis of the larger atherosclerotic plaque", draws together many of the points which I feel are of significance.

In the text, observations on the micro-anatomy of atherosclerotic coronary artery disease are detailed. These observations were made on serially mounted, 2 mm. thick, cross-sections of the main arterial stems, together with histological preparations and stereo-arteriograms.

The evidence presented and discussed includes:-

General configuration and fibrous structure of established atherosclerotic plaques: the manner in which they were compounded of crescentic formations, as well as concentric layers.

Distribution of lipid and intimal vessels which conformed to the fibrous structure.

Dissection of the plaques by intimal haemorrhage in life and by injection medium post mortem.

Similarity of configuration between mural thrombi and atherosclerotic plaques.

Transitional changes, gross, micro-anatomical and histological, between thrombus and atherosclerotic tissue, with particular reference to the conversion of fibrin to collagen-like fibres. "Fibrinoid" appears to be a stage in this process and not the product of degeneration.

Tinctorial changes that could be observed in the 2 mm. thick sections which were of all degrees from brown, through orange and yellow, to the pale colour of long established atherosclerotic plaques. The colour changes appeared to be derived from altered blood pigment.

Iron deposits in a high proportion of plaques.

The most acceptable explanation for all these features appeared to be their common origin in thrombus. The reservations with which this conclusion is expressed are also detailed.

Attention was paid to the nature, distribution and possible origin of lipid in the atherosclerotic lesions. The opinion is expressed that changes in the structure of the diseased intima had favoured its deposition, rather than that accumulation of lipid in the intima had provoked changes in its neighbourhood. In particular the evidence suggested that the necrotic debris in atheromatous "abscesses" resulted from a failure of organisation of thrombus before the advent of autolytic changes; and that lipid had a predilection for deposition in this material. The possibility that lipid might also have been a product of autolysis was explored.

Detailed observations were made on the occurrence and structure of intimal vessels. For the most part they were shown to arise directly from the lumen, or from branches while still within the intima. It seemed that the origin of such vessels had been the spongework of mixed thrombus. They were regarded as fortuitous pathological sequelae of its organisation and not as evidence of "vascularisation" of established atherosclerotic plaques. Far from conferring some advantage to the plaque, their presence introduced the hazard of intimal haemorrhage.

Less commonly, intimal vessels entered the plaque from the adventitial coat, and were of different status.

The proximate causes of thrombosis were sought. The relationship between intimal haemorrhage and coronary thrombosis was examined with inconclusive results. "Ulceration" of the luminal surface of the plaque was not a feature of my preparations (and the likelihood of its being an artefact was entertained). Extrusion of the contents of an atheromatous abscess was encountered only once. Haemorrhage appeared usually to have taken place from the lumen into the plaque; and not the other way round as is commonly supposed. Dissection of the intima by haemorrhage for short distances was a common finding.

The most constant finding in the artery wall in relation to recent coronary artery thrombosis was more or less pronounced evidence in the subjacent atherosclerotic intimal thickening of its own former origin in thrombus. Increment in the size of these lesions appeared to have taken place episodically, successive thrombus deposits being converted into atherosclerotic tissue. In this way, the final thrombotic incident which obliterated the remaining lumen was but one of several in a series of similar events.

No matter the genesis of atherosclerotic disease in general, which is discussed in the last section of this chapter, it was evident that those lesions which were eventually responsible for obliterative coronary artery disease had themselves been derived from thrombus.

The present investigation has therefore afforded considerable evidence in support of a thrombotic origin for atherosclerosis, and has confirmed the observations of Rokitansky (1841), Clark et al. (1936), Duguid (1946) and, contemporaneously, of Morgan (1956).

Attempt has been made to present photographically a sample of the original evidence upon which my observations have been made and upon which I have based my conclusions.

## REFERENCES



REFERENCES

Only contributions to which reference has been made in the text are included in the list which follows. Many others have been consulted.

CAPITAL LETTERS indicate that the original has been examined. Those in small type have been cited by others but not examined, at any rate in detail, and at least one source is indicated. Nearly all of those cited by others have been checked in the original or confirmed from some other source.

The list includes many of the more important contributions to the aspects of the subject dealt with in this thesis. Inevitably the list is far from complete.

Thus, Zoll et al., 1951, present 141 references on the subject of intercoronary anastomoses; Gould, 1953, on coronary sclerosis, 305 references; on the coronary circulation in heart disease, Gregg, 1950, cited 198 references, and many others on experimental aspects of the subject. Under the title of nutrition and atherosclerosis, Katz, Stamler and Pick, 1959, have assembled 787 items in their bibliography. A great many references are also to be found in review articles by Hueper, 1944, 45, and in the monograph by Morgan, 1956, on the pathogenesis of coronary occlusion. Even as far back as 1926, Benson was able to support his survey of the status of coronary artery disease by over 300 references.

My impression is that a complete bibliography under the general headings of "The Coronary Circulation in Health and Disease" and "Atherosclerosis" would run into several thousand at a conservative estimate - without including the vast literature on the clinical, diagnostic, therapeutic and epidemiological aspects of ischaemic heart disease. The literary stockpile on coronary artery disease is currently accumulating at the rate of about forty contributions per month.

---

- Amenomiya, R., 1910, Virchows. Arch. F. path. Anat. 199:187,  
 "Über die Beziehungen zwischen Koronararterien und  
 Papillarmuskeln im Herzen." (cited Spalteholz 1926, and  
 others including Zolletal.  
 1951)
- Anitschkow, N., 1933, "Experimental arteriosclerosis in animals"  
 in "Arteriosclerosis" E.V. Cowdry p.271, The Macmillan Co.;  
 New York. (cited Katz and  
 Stamler, 1953, Fullerton, 1955)
- APPELBAUM, E. and NICOLSON, G.H.B. 1935, Amer. Heart J., 10 : 35.  
 "Occlusive diseases of the coronary arteries."
- Aschoff, L., 1906. "Die heutige Lehre von der pathologisch-anatomischen  
 Grundlagen der Herzschwäche." Jena; Gustav Fischer. (cited many  
 authors, including Appelbaum  
 and Nicolson)
- Atlas, D. H., Eisenberg, H. L., and Gaberman, P. 1950, Circulation 1 : 753  
 "Bernheim's syndrome; report of a case." (cited Gould, 1953)
- 
- BARBONI, F., 1956. Giornale di Clin. Med. 37 : 1435. "Morfologia  
 normale e patologica delle arterie coronarie intramurali del cuore".
- BARCLAY, A.E., 1951, "Microarteriography". Oxford: Blackwell.
- BARNES, A. R. and BALL, R. G., 1932, Amer. J. Med. Sci., 183 : 215  
 "Incidence and situation of myocardial infarction in 1000  
 consecutive post-mortems."
- Bean, W. B., 1937, Amer. Heart J., 14 : 684. "Infarction of the heart:  
 A morphological and clinical appraisal of 300 cases."
- Bean, W. B., 1938. Ann. Int. Med., 12 : 71. "Infarction of the heart,  
 III. Clinical course and morphological findings." (cited Gould, 1953)
- Beck, C. S., Tichy, V.L. and Moritz, A.R., 1935, Proc. Soc. Exper. Biol.  
 and Med. 32, 759.  
 "Production of a collateral circulation to the heart". (cited Mautz  
 and Beck, 1937)

- BECK, C. S. 1957, Proc. Harvey Tercentenary Congress, p.187,  
 "Applied physiology in relation to surgical operation for the  
 treatment of coronary artery disease". Oxford. Blackwell.
- Benson, R. L., 1926, Arch. Path. 2 : 876. "The present status of  
 coronary arterial disease." (cited Nelson, 1941)
- BING, R. J., HAMMOND, M.M., HANDELSMAN, J. C., POWERS, S.R., SPENCER, F.C.,  
 ECKENHOFF, J.E., GOODALE, W.T., HARKENSCHIEL, J.F., and KETTY, S.S.  
 1949. Amer. Heart J., 38 : 1. "The measurement of coronary blood  
 flow, oxygen consumption and efficiency of the left ventricle in  
 man."
- Block, W. J., Crumpacker, E.L., Dry, T.J., Gage, R.P., 1952, J. Amer.  
 Med. Ass. "Prognosis of angina pectoris: observations in 6,882  
 cases." (cited Wood, 1956) - 150:259
- Blumgart, H. L., Schlesinger, M.J. and Davis, D., 1940, Amer. Heart J.  
 19 : 1. "Studies on the relation of clinical manifestations of  
 angina pectoris, coronary thrombosis and myocardial infarction,  
 with particular reference to the significance of the collateral  
 circulation." (cited Gould, 1953)
- BLUMGART, H. L., SCHLESINGER, M. J. and ZOLL, P. M., 1941, J. Amer. Med.  
 Ass. 116:91. "Angina pectoris, coronary failure and acute  
 myocardial infarction".
- BLUMGART, H. L., ZOLL, P.M., FREEDBERG, A. S. and GILLIGAN, D.R. 1950;  
 "The experimental production of intercoronary anastomoses and their  
 functional significance". Circulation, 1 : 10.
- BLUMGART, H. L., ZOLL, P. M., PAUL, M. H. and NORMAN, L. R., 1955, Trans.  
 Ass. Am. Physicians, 68 : 155. "The effect of experimental acute  
 coronary artery occlusion on stimulation of intercoronary collateral  
 anastomoses".
- Bobb, J. R. R., Kunze, D. C., McCall, W. Jr., and Green H. D., 1948, Proc.  
 Soc. Exp. Biol. & Med. 69 : 115. "Location of communications between  
 cognate bed of descending ramus of left coronary and adjacent collateral  
 vascular beds". (cited Gregg, 1950 and Wiggers, 1950)
- BÖTTCHER, C.J.F., KEPPLER, J.G., ROMENY-WACHTER, C.C. ter HARR, BOELSMA-van  
 HOUTE, E., and van GENT, C. M. 1958, Lancet 2 : 1207. "Analysis of  
 Lipids of the arterial wall".
- BRANWOOD, A.W., and MONTGOMERY, G. L., 1956, Scot. Med. J. 1 : 367.  
 "Observations on the morbid anatomy of coronary artery disease."
- BRASH, J. C., 1951, in Cunningham's Textbook of Anatomy, 9th Ed., Oxford  
 med. Pub.

- BRINK, A. J., 1949, Clin. proceedings, 8 : 137. "Coronary vessels in the Bantu. Preliminary report on coronary artery pattern in adult Bantu."
- Büchner, Weber u. Haager, 1935, "Koronarinfarkt und Koronarinsuffizienz". Leipzig. (cited Büchner, 1939)
- BÜCHNER, F., 1939, "Die Koronarinsuffizienz", Dresden u. Leipzig: Steinkopff.
- BURNS, A., 1809. "Observations on some of the more frequent and important diseases of the heart." Jas. Muirhead, Edinburgh.
- 
- CAMPBELL, J. S., 1929, Quart. J. Med. 22 : 247. "Stereoscopic radiography of the Coronary System."
- CHICHE, P., BAILLET, J. et de CANTOGNO, R. Verdun, 1953, Arch. Maladies du Coeur, 46 : 865.  
"Ischemie sous-endocardique ventriculaire gauche et insuffisance coronarienne."
- Christianson, O. O. 1939, Arch. Path. 27 : 1011. "Observations on lesions produced in arteries of dogs by injections of lipids."  
(cited Morgan, 1956)
- CLARK, E., GRAEF, I. and CHASIS, H. 1936, Arch. Path. 22 : 183.  
"Thrombosis of the aorta and coronary arteries, with special reference to the "fibrinoid" lesions."
- COHNHEIM, J. and von SCHULTHESS-RECHBERG, A., 1881, Virchows Arch. f. path. Anat. 85 : 503. "Über die Folgen der Kranzarterienverschliessung für das Herz."
- COLE, D. R., SINGIAN, E. B. and KATZ, L. N., 1954, Circulation 9 : 321.  
"The long term prognosis following myocardial infarction, and some factors which affect it."
- CRAINICIANU, A., 1922, Virchows Arch. f. path. Anat., 238 : 1.  
"Anatomische Studien über die Coronararterien und experimentelle Untersuchungen über ihre Durchgängigkeit."

CRAWFORD, T. and LEVENE, C. I., 1952, J. Path. Bact. 64 : 523.

"Incorporation of fibrin in the aortic intima."

CRAWFORD, T. and LEVENE, C. I., 1953, J. Path. Bact. 66 : 19.

"Medial thinning in atheroma."

CRAWFORD, T., 1955, Proc. Roy. Soc. Med. 48 : 661. "The morphology of coronary atherosclerosis in man."

---

DACK, S., MASTER, A. M., HORN, H., GRISHMAN, A. and FIELD, L. E., 1949, Amer. J. Med. 7 : 464.

"Acute coronary insufficiency due to pulmonary embolism."

DIBLE, J. H., 1958, J. Path. Bact. 75 : 1. "Organisation and canalisation in arterial thrombosis."

Dock, W. 1941, J. Exper. Med. 74:177. "The capacity of the coronary bed in cardiac hypertrophy." (cited Dock, 1951, Amer. J. Med. 11:730)

Dock, W. 1946, J. Amer. Med. Ass. 131 : 875. "The predilection of atherosclerosis for the coronary arteries" (cited Fangman and Hellwig, 1947, and Moon and Rinehart, 1952)

Duff, G.L., 1935, Arch. Path. 20 : 81 and 259. "Experimental cholesterol arteriosclerosis and its relation to human arteriosclerosis." (cited Morgan, 1956)

DUFF, G.L., and McMILLAN, G.C., 1951, Amer. J. Med. 11 : 92. "Pathology of atherosclerosis."

DUGUID, J.B., 1946, J. Path. Bact. 58 : 207. "Thrombosis as a factor in the pathogenesis of coronary atherosclerosis."

DUGUID, J.B., 1948. J. Path. Bact., 60:57. "Thrombosis as a factor in the pathogenesis of aortic atherosclerosis."

Duncan, G.G. and Waldron, J.M., 1949. Tr. A. Amer. Physicians, 42 : 179.  
 "The effect of ingested fat on blood coagulation."  
 (cited Tulloch et al. 1953)

---

Eckenhoff, J.E., Hafkenschiel, J.H., Landmesser, C.M. and Harmel, M., 1947.  
 Amer J. Physiol. 149 : 634. "Cardiac oxygen metabolism and control  
 of the coronary circulation." (cited Gregg, 1950)

Ehrich, W., de la Chapelle and Cohn, A.E., 1931. Amer. J. Anat. 49 : 241.  
 "Animal ontogeny. B. Man. I. A study of the coronary arteries."  
 (cited Gross and Kugel, 1934)

ERNSTENE, A. C., 1948. "Coronary heart disease." Illinois: Chas.C.Thomas.

---

FISHBERG, A. M., 1940. "Heart failure." Ed. 2. London: H. Kimpton.

FREEDBERG, A. S., BLUMGART, H. L., ZOLL, P.M. and SCHLESINGER, H. J., 1948,  
 J. Amer. Med. Ass. 138 : 107. "Coronary failure."

FRIEDBERG, C.K. and HORN, H. 1939, J. Amer. Med. Ass. 112 : 1675.  
 "Acute myocardial infarction not due to coronary artery occlusion."

FULLERTON, H.W., 1955, Proc. Roy. Soc. Med. 48 : 661. "The role of diet  
 in the pathogenesis of coronary artery disease."

FULTON, W.F.M. , 1956, Brit. Heart. J. 28 : 341. "Chronic generalized  
 myocardial ischaemia with advanced coronary artery disease."

Fulton, W.F.M., 1953, Scottish Soc. of Exper. Med. "The clinical and  
 pathological syndrome of pan-myocardial ischaemia and zonal ring  
 infarction of the left ventricle."

FULTON, W.F.M., 1954, Brit. Heart J. 16: 123. Proc. Brit. Cardiac Soc.,  
 Oct., 1953. "The vascular pattern in chronic generalized  
 myocardial ischaemia."

- Fulton, W.F.M., 1954. Edinburgh Univ. Path. Club. "Some aspects of coronary artery disease, as revealed by sterioarteriography, with special reference to coronary artery anastomoses."
- Fulton, W.F.M., 1956, Conference on med. and surg. cardiology, symposium on cardiac ischaemia. Roy. Faculty Phys. & Surg., Glasgow. "The influence of coronary anastomoses."
- 
- GEIRINGER, E., 1951, Amer. Heart J. 41 : 359. "The mural coronary."
- GERLIS, L. M., 1956. Brit. Heart J. 18 : 166. "The significance of adventitial infiltrations in coronary atherosclerosis."
- GERTLER, M. M., GARN, S. M. and LERMAN, J., 1950. circulation 2 : 205. "The inter-relationships of serum cholesterol, cholesterol esters and phospholipids in health and in coronary artery disease."
- GOFMAN, J.W., JONES, H.B., LINDGREN, F.T., LYON, T.P., ELLIOT, H.A., and STRISOWER, B., 1950. circulation 2 : 161. "Blood lipids and human atherosclerosis."
- GOFMAN, J.W., JONES, H.B., LYON, T.P., LINDGREN, F., STRISOWER, B., COLMAN, D. and HERRING, V., 1952. circulation 5 : 119. "Blood lipids and human atherosclerosis."
- GOULD, S.E., 1953. "The pathology of the heart." Illinois: Chas.C.Thomas.
- GRANT, R.T. and VIKO, L.E., 1929-31, Heart 15 ; 103. "Observations on the anatomy of the Thebesian vessels of the heart."
- GREEN, H.D., 1936, Amer. J. Physiol. 115:1936, "The coronary blood flow in aortic stenosis, in aortic insufficiency and in arteriovenous fistula."
- Green, H.D. and Wégria, R. 1942. Amer. J. Physiol. 135 : 271. "Effects of asphyxia, anoxia, and myocardial ischaemia on coronary blood flow."  
(cited Gregg, 1950)
- Gregg, D.E., and Green, H.D., 1940, Amer. J. Physiol. 130 : 108. "Effects of viscosity, ischemia, cardiac output and aortic pressure on coronary blood flow measured under constant perfusion pressure"  
(cited Gregg, 1950)

- GREGG, D.E., 1950. "Coronary circulation in health and disease."  
London: Henry Kimpton.
- GROSS, L., 1917. J. Med. Research 36 : 327. "Studies on circulation  
of the kidney."
- GROSS, L., 1921. "The blood supply to the heart." Oxford Univ. press.
- GROSS, L. and KUGEL, M.A., 1934. Amer. Heart J. 9 : 165. "The  
arterial blood vascular distribution to the left and right  
ventricles of the human heart."
- 
- HARRISON, C.V. and WOOD, P., 1949. Brit. Heart J. 11:205. "Hypertensive  
and ischaemic heart disease."
- HARRISON, T.R., ASHMAN, R. and LARSON, R.M., 1932. Arch. Int. Med. 49:151.  
"Congestive heart failure: XII The relation between the thickness  
of the cardiac muscle fiber and the optimum rate of the heart."
- Hartman, F.W., 1952. Ann. New York Acad. Sci. 55 : 504. "Fate and  
disposal of plasma substitutes." (cited Hueper, 1956)
- HARVEY, P., 1956. J. Path. Bact. 72 : 73. "Fibrin and pulmonary  
atheroma."
- HERRICK, J.B., 1912, J. Amer. Med. Ass. 59 : 2015. "Clinical features  
of sudden obstruction of the coronary arteries."
- HIGHMAN, B. and ALTLAND, P.D., 1949, Arch. Path. 48 : 503. "Acclimatisation  
response and pathologic changes in rats at an altitude of 25,000 feet."
- HILL, E.C., 1929. Johns Hopkins Hosp. Bull. 44 : 248. "A radio-opaque  
bismuth suspension for anatomical, histological and pathological  
research."
- Hirsch, C. and Spalteholz, W., 1907. Deutsche medizinische Wochenschrift,  
No. 20, 1:790. "Koronarterien und Herzmuskel. Anatomische und  
experimentelle Untersuchungen." (cited Spalteholz, 1907)



- Hochrein, M., 1941. "Der Myocardinfarct.", Dresden and Leipsig: Steinkopff. (cited Gould, 1953)
- HOLYOKE, J.B., 1945 Arch. Path. 39 : 268. "Coronary arteriosclerosis and myocardial infarction as studied by an injection technique."
- ( Horlick, L. and Katz, L.N., 1949. J. Lab. & Clin. Med. 34 : 1427. "Retrogression of atherosclerotic lesions on cessation of cholesterol feeding in the chick." (cited Katz and Stamler, 1953)
- HORN, H. and FINKELSTEIN, L.E., 1940. Amer. Heart J. 19 : 655. "Arteriosclerosis of the coronary arteries and the mechanism of their occlusion."
- HORN, H., FIELD, L.E., DACK, S., and MASTER, A.M., 1950. Amer. Heart J. 40 : 63. "Acute coronary insufficiency: pathological and physiological aspects."
- HUDSON, C.L., MORITZ, A.R. and WEARN, J.T., 1932. J. Exper. Med. 56 : 919. "The extracardiac anastomoses of the coronary arteries."
- Hueper, W.C., 1942. Arch. Path. 33 : 267. "Macromolecular substances as pathogenic agents."
- HUEPER, W.C., 1944 and 1945. Arch. Path. 38 : 162,245,340 and 39 : 51,117,187. "Arteriosclerosis: A general review."
- HUEPER, W.C., 1956. Amer. J. Clin. Path. 26 : 559. "Pathogenesis of atherosclerosis."

---

JAMIN, F. and MERKEL, H. 1907. "Die Koronararterien des menschlichen Herzens...in stereoskopischen Röntgenbildern." Jena:Gustav. Fischer. (available Glasgow Univ. Library)

JOHNSON, J.R. and Di PALMA, J.R., 1935. Amer. J. Physiol. 125:234. "Intramyocardial pressure and its relation to aortic blood pressure."

Karsner, H.T. 1949. "Human pathology", Ed. 7. Philadelphia:Lippincott.

KATZ, L.N., and STAMLER, J., 1953. "Experimental atherosclerosis."  
Springfield: Chas. C. Thomas.

Kirch, E. 1927. *Ergebn. d. allg. Path. u. path. Anat.*, 22 : 1.  
(cited Saphir et al., 1935)

(Koch, W. and Kong, L.C., 1932. *Beitr. path. Anat.* 90 : 21. "Über die Formen des Coronarverschlusses, die Änderungen im Coronarkreislauf und die Beziehungen zur Angina Pectoris."  
(cited Nelson, 1941)

---

LAURIE, W. and WOODS, J.D., 1958. *Lancet* 2 : 812. "Anastomosis in the coronary circulation."

LEARY, T. 1935a. *Amer. Heart J.* 10 : 328. "Pathology of coronary sclerosis."

LEARY, T. 1935b. *Amer. Heart J.* 10 : 338. "Coronary spasm as a possible factor in producing sudden death"

Leary, T. 1938. *Amer. Heart J.* 16 : 549. "Vascularisation of atherosclerotic lesions." (cited Harvey 1956, Morgan, 1956)

LEVINE, H.D. and FORD, R.V. 1950. *Circulation* 1 : 261. "Subendocardial infarction: Report of six cases and critical survey of the literature."

Levine, S.A., and Brown, C.L. 1929. *Medicine*, 8 : 245. "Coronary thrombosis. Its various clinical features."  
(cited Saphir et al. 1935)

LOCKHART, R.D., HAMILTON, G.F. and FYFE, F.W. 1959. "Anatomy of the human body." London: Faber and Faber.

LOOMIS, D. 1936. *Arch. Path.* 22 : 435. "Plastic studies in abnormal renal architecture."

- Lowe, T.E. 1939. J. Path. Bact. 49 : 195. "The significance of myocardial scars in the human heart."  
(cited Gould, 1953)
- Lower, Richard. 1669. "Tractatus de corde, item de motu et colore sanguinis, et chyle in eum transitu." Amsteldami.  
(cited Blumgart et al., 1950)
- (Lower, R. 1728. "Tractatus de corde." Lugdunum Batavorum.  
(cited Spalteholz, 1924)
- 
- Mackenzie, J. 1923. "Angina pectoris." London: Hodder and Stoughton.
- MALLORY, G.K., WHITE, P.D., and SALCEDO-SALGAR, J. 1939. Amer. Heart J. 18 : 647. "The speed of healing of myocardial infarction."
- Malyschew, B.F. 1929. Virchow's Arch. f. path. Anat. 274 : 528.  
(cited Hueper, 1945)
- MASTER, A.M., GUBNER, R., DACK, S. and JAFFE, H.L. 1941. Arch. Int. Med. 67 : 646. "Differentiation of acute coronary insufficiency with myocardial infarction from coronary occlusion."
- MASTER, A.M., DACK, S., HORN, H., FREEDMAN, B.L. and FIELD, L.E., 1950. Circulation 1 : 1302. "Acute coronary insufficiency due to acute hemorrhage: an analysis of 103 cases."
- MAUTZ, F.R. and BECK, C.S. 1937. J. Thoracic Surg. 7 : 113. "The augmentation of collateral coronary circulation by operation."
- MÖNCKEBERG, J.G. 1924, in HENKE, F. and LUBARSCH, O. "Handbuch der speziellen pathologischen Anatomie und Histologie. Herz und Gefäße II. Berlin: Julius Springer.
- MOON, H.D. and RINEHART, J.F. 1952. Circulation 6 : 481. "Histogenesis of coronary arteriosclerosis."
- MORGAN, A.D. 1956. "The pathogenesis of coronary occlusion." Oxford: Blackwell Scient. Publications.

Moschcowitz, E. 1950. J. Amer. Med. Ass. 143 : 861.

"Hyperplastic arteriosclerosis versus atherosclerosis."

(cited Moon and Rinehart, 1952)

MYERS, G.B., KLEIN, H.A. and STOFER, B.E., 1948. Amer. Heart J. 36 : 535. "Correlation of electrocardiographic and pathologic findings in anteroseptal infarction."

---

NELSON, M.G., 1941. J. Path. Bact. 53 : 105. "Intimal coronary artery haemorrhage as a factor in the causation of coronary artery occlusion."

Nussbaum, A. 1912. Arch. f. mikrosk. Anat. 80 : 450. "Über das Gefässsystem des menschlichen Herzens."

(cited Mönckeberg, 1924 and Spalteholz, 1924)

---

OBERHELMAN, H.A. and Le COUNT, G.R., 1924. J. Amer. Med. Ass. 82 : 1321. "Variations in the anastomosis of the coronary arteries and their sequences."

OLIVER, M.F. and BOYD, G.S. 1953. Brit. Heart J. 15 : 387. "The plasma lipids in coronary artery disease."

OLIVER, M.F. and BOYD, G.S. 1955. Brit. Heart J. 17 : 299. "Serum lipoprotein patterns in coronary sclerosis and associated conditions."

OLIVER, M.F. and BOYD, G.S. 1957. Postgrad. Med. J. 33 : 2. "The circulating lipids and lipoproteins in coronary artery disease."

- O'Shaughnessy, L. 1936. Brit. J. Surg. 23 : 665.  
(cited O'Shaughnessy, 1937  
and Lancet 1959 2 : 653)
- O'SHAUGHNESSY, L. 1937. Lancet 1 : 185. "Surgical treatment  
of cardiac ischaemia."
- 

- PAGE, I.H. 1954. Circulation 10 : 1. "Atherosclerosis:  
an introduction."
- PARKINSON, J. and BEDFORD, D.E. 1928. Lancet 1 : 4. "Cardiac  
infarction and coronary thrombosis."
- Paterson, J.C. 1936. Arch. Path. 22 : 313. "Vascularization  
and hemorrhage of the intima of arteriosclerotic coronary  
arteries."  
(cited Paterson, 1952. Nelson,  
1941)
- Paterson, J.C. 1941. Canad. Med. Ass. J. 44 : 114. "Some  
factors in the causation of intimal haemorrhages and in  
the precipitation of coronary thrombi."  
(cited Paterson, 1952)
- Paterson, J.C. 1950: ref. series cited by Paterson, 1952.
- PATERSON, J.C. 1952. Circulation 6 : 732. "Factors in the  
production of coronary artery disease."
- Peel, A.A.F. 1948. Brit. Heart J. 10 : 239. "Dissecting aneurysm  
of the interventricular septum causing obstruction of outflow  
tract of right ventricle, secondary to coronary occlusion."  
(cited Gould, 1953)
- PEEL, A.A.F. 1955. Brit. Heart J. 17 : 324. "Age and sex factors  
in coronary artery disease."

- PIRANI, C.L. and SCHLICHTER, J.G. 1946. Ann. Int. Med. 25 : 847.  
"Subendocardial myocardial infarction."
- PITT, B. 1959. Circulation, 20 : 816. "Interarterial coronary anastomoses. Occurrence in normal hearts and in certain pathologic conditions."
- Porter, W.I. 1901, in "American text-book of Physiology" (W.H. Howell, Ed.) vol. 1. p.179. Philadelphia: Saunders  
(cited Wiggers, 1950)
- PRATT, F.H. 1898. Amer. J. Physiol. 1 : 86. "The nutrition of the heart through the vessels of Thebesius and the coronary veins."
- PRENTICE, A.I.D. and PENFOLD, J.B. 1952. Brit. Heart J. 14 : 87.  
"Aneurysm of the coronary arteries."
- Prinzmetal, M., Kayland, S., Margoles, C. and Tragerman, L.J. 1942. J. Mt. Sinai Hosp. 8 : 933. "Quantitative method for determining collateral coronary circulation; preliminary report on normal human hearts."  
(cited Prinzmetal, 1947)
- PRINZMETAL, M., SIMKIN, B., BERGMAN, H.C. and KRUGER, H.E. 1947. Amer. Heart J. 33 : 420. "II. The collateral circulation of the normal human heart by coronary perfusion with radioactive erythrocytes and glass spheres."
- PRINZMETAL, M., BERGMAN, H.C., KRUGER, H.E., SCHWARTZ, L.L., SIMKIN, B. and SOBIN, S.S. 1948. Amer. Heart J. 35 : 689. "Studies on the coronary circulation III: collateral circulation of beating human and dog hearts with coronary occlusion."
- 
- RAVIN, A. and GEEVER, E.F. 1946. Arch. Int. Med. 78 : 125.  
"Coronary arteriosclerosis, coronary anastomoses and myocardial infarction."
- RITTER, S.A., GROSS, L. and KUGEL, M.A. 1928. Amer. Heart J. 3 : 433.  
"Blood vessels in valves of normal human hearts; from study of 700 human hearts."

- Robb, J.S. and Robb, R.C. 1942. Amer. Heart J. 23 : 455.  
 "The normal heart. Anatomy and physiology of the structural units."  
 (cited Gould, 1953)
- ROBERTS, A. 1945. M.D. Thesis, Edinburgh University.  
 "Observations on the anatomy and pathology of the renal and cardiac blood vessels."
- Rokitansky, C. von, (1841-46), Lehrbuch der pathologische Anatomie: Vienna (trans. G.E. Day, 1852)  
 (cited Duguid 1946, Morgan 1956)
- Russek, H.I. and Zohman, B.L. 1950. Circulation 1 : 759.  
 "The syndrome of Bernheim as a clinical entity."  
 (cited Gould 1953)
- 
- SALANS, H. and TWEED, P. 1947. Amer. Heart J. 33 : 477. "A preliminary study of the coronary circulation post mortem."
- SAPHIR, O., PRIEST, W.S., HAMBURGER, W.W. and KATZ, L. 1935. Amer. Heart J. 10 : 567 and 762. "Coronary arteriosclerosis, coronary thrombosis, and the resulting myocardial changes."
- SCHARFMAN, W.B., WALLACH, J.B. and ANGRIST, A. 1950. Amer. Heart J. 40 : 603. "Myocardial infarction due to syphilitic ostial stenosis."
- SHILLINGFORD, J.P. 1950. London Hospital Gazette, 53 : 33.
- SHILLINGFORD, J. 1952. Brit. Med. Bull. 8 : 320. "Pathology of the coronary arteries."
- Scott, D.H. 1948. Amer. Heart J. 36 : 403. "Aneurysm of the coronary arteries."  
 (cited Prentice and Penfold, 1952)
- Schlesinger, M.J. 1940. Arch. Path. 30 : 403. "Relation of anatomie pattern to pathologic conditions of the coronary arteries."
- SCHLESINGER, M.J. 1938. Amer. Heart J. 15:528. "An injection plus dissection study of coronary artery occlusions and anastomoses."

- SCHLESINGER, M.J., ZOLL, P.M. and WESSLER, S. 1949. Amer. Heart J. 38 : 823. "The conus artery: a third coronary artery."
- SCOTT, R.W., YOUNG, A.F., ZIMMERMAN, H.A. and KROH, I. 1949. Amer. Heart J. 38 : 887. "An improved method for visualising the coronary arteries at post-mortem."
- Shipley, R.E. and Gregg, D.E. 1944. Amer. J. Physiol. 141 : 289.  
 ("The effect of external constriction of a blood vessel on blood flow."  
 (cited Gregg, 1950)
- SMITH, F.M. 1918. Amer. J. Med. Sci. 156 : 706. "Concerning the anatomy of the coronary arteries."
- Smith, H.L. 1928. Amer. Heart J. 4 : 79. "The relation of the weight of the heart to the weight of the body and of the weight of the heart to age."  
 (cited Gould, 1953)
- Smith, J.R. and Henry, M.J. 1945. J. Lab. and Clin. Med. 30 : 462. "Demonstration of coronary arterial system with neoprene latex."  
 (cited Salans and Tweed 1947)
- SMITH, G. 1957. Watson Prize Lecture: Royal Faculty of Physicians and Surgeons of Glasgow. "Cardiac hypertrophy."
- SNOW, P.J.D., MORGAN JONES, A. and DABER, K.S. 1952. Brit. Heart J. 14 : 542. "A study of coronary and myocardial lesions."  
 (Proc. Brit. Cardiac Soc.)
- SNOW, P.J.D., MORGAN JONES, A. and DABER, K.S. 1955. Brit. Heart J. 17 : 503. "Coronary disease: a pathological study."
- SPALTEHOLZ, W. 1907. Verhandl. d. anatomischen Gesell. 141: "Die Koronararterien des Herzens."
- SPALTEHOLZ, W. 1924. "Die Arterien der Herzwand. Anatomische Untersuchungen an Menschen- und Tierherzen." Leipzig: S. Hirzel.  
 (obtained from Royal Society of Medicine)
-



TUNA, N., RECKERS, L. and FRANZ I.D.Jr. 1957. J. Clin. invest.  
36 : 932. "The fatty acids of normal plasma and of  
arteriosclerotic plaques."

(Proc. Amer. Soc. Clin. Invest.)

TULLOCH, J.A. 1950. M.D. Thesis, Edinburgh. "Myocardial infarction:  
a clinical study of the aetiology and prognosis with special  
reference to the influence of anticoagulant therapy on prognosis."

TULLOCH, J.A., OVERMAN R.S. and WRIGHT, I.S. 1953. Amer. J. Med.  
14 : 674. "Failure of ingestion of cream to affect blood  
coagulation."

---

VINEBERG, A. and MILLAR, D. 1953. Amer. Heart J. 45 : 873.  
"Functional evaluation of internal mammary coronary artery  
anastomosis."

VINEBERG, A., MUNRO, D.D., COHEN, H. and BULLER, W. 1955. J. Thorac.  
Surg. 29 : 1. "Four years clinical experience with internal  
mammary artery implantation in the treatment of human coronary  
artery insufficiency including additional experimental studies."

VINEBERG, A. and WALKER, J. 1957. Amer. Heart J. 54 : 841. "Six  
months to six years experiences with coronary artery insufficiency  
treated by internal mammary artery implantation."

---

WAGNER, A. and POINDEXTER, C.A. 1949. Amer. Heart J. 37 : 258.  
"Demonstration of the coronary arteries with nylon."

- Wartman, W.B. 1938. Amer. Heart J. 15 : 458. "Occlusion of the coronary arteries by hemorrhage into their walls."  
(cited Wartman, 1950)
- Wartman, W.B. and Hellerstein, H.K. 1948. Ann. Int. Med. 28 : 41.  
"The incidence of heart disease in 2000 consecutive autopsies."
- WARTMAN, W.B. 1950 in Studies in Pathology presented to Peter MacCallum. "Vascularization and hemorrhage in the arterial wall."
- Wartman, W.B. and Souders, J.C. 1950. Arch. Path. 50 : 329.  
"Localisation of myocardial infarcts with respect to the muscle bundles of the heart."  
(cited Gould, 1953)
- Wearn, J.T. 1928. J. Exper. Med. 47 : 273. "The extent of the capillary bed of the heart." (cited Gregg, 1950)
- WEARN, J.T., METTIER, S.R., KLUMPP, T.G. and ZSCHIESCHE, L.J. 1933. Amer. Heart J. 9 : 143. "The nature of the vascular communications between the coronary arteries and the chambers of the heart."
- WEARN, J.T. 1941. Bull. Johns Hopkins Hosp. 68 : 383.  
"Alterations in the heart accompanying growth and hypertrophy."
- Wégria, R. Segers, M., Keating, R.P. and Ward, H.P. 1949. Amer. Heart J. 38 : 91. "Relationship between the reduction in coronary flow and the appearance of electrocardiographic changes."  
(cited Gregg, 1950)
- WEST, S. 1883. Lancet 1 : 945. "The anastomosis of the coronary arteries."
- WHITTEN, M.B. 1930 a. Arch. Int. Med. 45 : 46. "A comparison of the blood supply of the right and left ventricles in childhood."
- WHITTEN, M.B. 1930 b. Arch. Int. Med. 45 : 383. "The relation and the distribution and structure of the coronary arteries to myocardial infarction."
- WIGGERS, C.J. 1949. "Physiology in health and disease." 5th Ed. London: Henry Kimpton.
- WIGGERS, C.J. 1950. Exper. Med. and Surg. 8 : 402. "The problem of functional collaterals."
- Wilens, S.L. 1947. Amer. J. Path. 23 : 793. "The absorption of arterial atheromatous deposits in wasting disease."  
(cited Katz and Stamler, 1953)

- Wilens, S.L. 1951. Science 114 : 389. "The experimental production of lipid deposition in excised arteries."  
(cited Wood, 1956, Katz and Stamler, 1953)
- WINTERNITZ, M.C., THOMAS, R.M. and Le COMPTE, P.M. 1938. "The biology of arteriosclerosis." Springfield, Ill., Chas. C.Thomas.  
(see also Winternitz et al. 1937, Amer. Heart J. 14:399)
- (Wolkoff, K. 1929. Beitr. z. path. Anat. u. allg. Path. 82 : 555.  
"Über die Atherosclerose der Koronararterien des Herzens."
- WOOD, P.D. 1956. "Diseases of the heart and circulation." 2nd Ed.  
London: Eyre and Spettiswoode.
- WOOLARD, H.H. 1922. "Carnegie contributions to embryology No.70:139.  
London. "The development of the primitive arterial stems in the fore limb of the pig."
- WRIGHT, A.S., PITT, G.A.J. and MORTON, R.A. 1959. Lancet, 2 : 594.  
"Cholesterol ester fatty acids in atheroma and plasma."
- WRIGHT, H.P., KUBIK, M.M. and HAYDEN, M. 1953. Brit. Med. J. 1:1021.  
"Recanalisation of thrombosed arteries under anticoagulant therapy."
- 
- Yater, W.M., Traum, A.H., Brown, W.G., Fitzgerald, R.P., Geisler, M.A.  
and Wilcox, B.B. 1948. Amer. Heart J. 36 : 683. "Coronary artery disease in men 18-39 years of age. Report of 866 cases, 450 with necropsy examination."
-

ZAUS, E.A. and KEARNS, W.M.Jr. 1952. Circulation 4 : 593.

"Massive infarction of the right ventricle."

ZOLL, P.M., WESSLER, S. and BLUMGART, H.L. 1951 (a). Amer. J. Med.

11 : 331. "Angina pectoris: a clinical and pathological correlation."

ZOLL, P.M., WESSLER, S. and SCHLESINGER, M.J. 1951 (b). Circulation

( 4 : 797. "Interarterial coronary anastomoses in the human heart, with particular reference to anemia and relative cardiac anoxia."

ZOLL, P.M. and NORMAN, L.R. (and Cassin, S) 1952. Circulation 6:832.

"The effects of vasomotor drugs and of anemia upon interarterial coronary anastomoses."

ZOLL, P.M., WESSLER, S., SCHLESINGER, M.J., FREEDBERG, A.S. and

BLUMGART, H.L. 1952. Modern concepts of cardiovascular disease. 21 : 118. "Interarterial coronary anastomoses."