

ULTRASOUND AS A DIAGNOSTIC

AID

IN

OBSTETRICS AND GYNAECOLOGY

---

THESIS SUBMITTED FOR

DEGREE OF DOCTOR OF MEDICINE

BY

JOHN MACVICAR, M.B. Ch.B. (1950)

MARCH 1959

---

ProQuest Number: 13850374

All rights reserved

INFORMATION TO ALL USERS

The quality of this reproduction is dependent upon the quality of the copy submitted.

In the unlikely event that the author did not send a complete manuscript and there are missing pages, these will be noted. Also, if material had to be removed, a note will indicate the deletion.



ProQuest 13850374

Published by ProQuest LLC (2019). Copyright of the Dissertation is held by the Author.

All rights reserved.

This work is protected against unauthorized copying under Title 17, United States Code  
Microform Edition © ProQuest LLC.

ProQuest LLC.  
789 East Eisenhower Parkway  
P.O. Box 1346  
Ann Arbor, MI 48106 – 1346

## ACKNOWLEDGEMENTS

I should like to express my thanks to several different people for their assistance and encouragement during the work described in the following thesis.

Professor Ian Donald has been unstinting in his help and gave me all facilities to continue and improve techniques while Registrar in Gynaecology at the Western Infirmary and Registrar in Obstetrics at the Royal Maternity Hospital, Glasgow.

I should like to thank all the Consultant Physicians, Surgeons and Gynaecologists of the Western Infirmary for allowing me access to their cases.

To Professor Wyburn and Dr. Bacsich of the Anatomy Department, Glasgow University, I should like to express my thanks for their help and the facilities they gave for proving the machine safe with animal experiments.

Without the firm of Kelvin and Hughes Ltd., the work could never have been carried out, since the apparatus and almost all the financial outlay came from them. I should especially like to mention Mr. Slater, director of the Scottish Branch at Hillington and also Mr. T.G. Brown, who worked in close co-operation with the clinical working of the apparatus and who constructed and modified the scanning apparatus after the initial experiments with the industrial flaw-detector proved hopeful.

With regard to further financial support, I should like to thank the Scottish Hospital Endowment Research Trust for their assistance.

For help with the photographing of the slides, I am indebted to the Department of Photography of the Western Infirmary, Glasgow, and with the layout of the illustrations in the thesis I should like to thank Mr. Waldie of the Department of Photography, Stobhill Hospital, Glasgow.





## INTRODUCTION

Ultrasound has now been used in many industrial, military and scientific projects. It is, however, only in comparatively recent years that ultrasound has been used in medicine. Its use as a therapeutic agent has been fairly widespread, but in the diagnostic sphere the work carried out has chiefly been, up to now, of academic or experimental interest.

Everyone is aware of the manner in which sounds are "reflected" from walls, mountains and the like, as echoes. Similarly, when ultrasound is transmitted through a structure any change in type of structure will cause reflection of the ultrasound. If ultrasound is transmitted from one structure to another the amount of ultrasound transmitted through the new medium will depend on the difference in structure of the second medium to the first. The amount of ultrasound transmitted through the new medium will, consequently, be a deciding factor in the magnitude of reflection at the junction of the two structures.

The human body has numerous interfaces and so if ultrasound is transmitted into the human body numerous echoes will be obtained from tissue interfaces. To evaluate the use of this as an aid to diagnosis in pathological conditions in relation to gynaecology and in obstetrics a large number of cases were examined. It is on these that this work is based.

Before the actual review of the cases the theory underlying the use of ultrasound must be discussed.

## THEORETICAL CONCEPTS OF ULTRASOUND.

### Definition.

An audible sound wave is a mechanical vibration which is in such a frequency range that it can be detected by the human ear. The frequency is defined as the number of complete vibrations or 'cycles' executed per second at any given point in the sound field. When the frequency is higher than can be detected by the human ear, the vibrations are said to be 'ultrasonic' or "supersonic", the former term being most commonly used. Twenty-thousand cycles per second represents about the upper limit of audibility for humans, while the lower limit is of the order of sixteen cycles per second; thus ultrasonic energy or 'ultrasound' consists of mechanical vibrational energy of a frequency in excess of twenty-thousand cycles per second. It is of interest to compare this with the nominal frequency of the highest note on a standard piano keyboard which is four thousand one hundred and eighty-six cycles per second. Middle C corresponds to two hundred and sixty-two cycles per second approximately.

### Properties of Sound.

From the definition it can be gathered that the properties of ultrasonic waves do not differ basically from those of ordinary sound waves, except in those properties which are functions of frequency. Transmission of sound is essentially dependent on particle vibration, each particle of the medium being displaced sequentially as the wave travels through the medium. Any/

Any material possessing elasticity can support the propagation of sound, the elasticity providing a restoring force which tends to return each particle to its starting point. Sound waves are, therefore, purely mechanical waves. In a sound field, consequently, there will be regions of alternating compression and rarefaction due to particle vibration. Although subsequently the discussion will refer to the properties of waves of ultrasound, in most cases the same properties apply to ordinary sound waves.

The maximum distance that a particle is displaced during the passage of an ultrasonic wave is known as the 'displacement amplitude' of vibration, while the pressure amplitude (more commonly referred to simply as the 'amplitude') is the maximum difference from the ambient pressure which occurs at a point in the medium during the passage of the wave. If the vibrating particles move in such a way that their acceleration towards the rest position is always directly proportional to their instantaneous displacement from it, then the wave is said to be 'sinusoidal', i.e. a pure 'sine-wave'. If the vibrating particles do not move in this simple fashion, then the wave is said to be 'complex'. No matter how complicated the vibration is, it can be shown that the wave can be represented as the sum of a number of sine-waves of different frequencies. If a graph be drawn showing the displacement of any given particle in the sound field to a base of time, then the shape of the curve is called the 'waveform'. This is not, however, a pictorial representation of the sound wave.

A flute (not over-blown) produces almost pure sine-waves while the waveform from a violin, for example, is very complex. In the following discussion, for simplicity, we are concerned only with pure sine-waves.

As a wave passes through a medium, then at any instant there will be a number of points equally spaced along the direction of propagation at which the particles of the medium are at the same stage in the vibration - for example, points where the displacement has a positive maximum. The distance between such points is known as the 'wavelength' in that medium.

The 'wavelength' will vary with frequency and with the type of medium in which propagation occurs. The simple relationship  $\lambda = \frac{v}{f}$  connects the wavelength  $\lambda$  with the velocity of propagation  $v$  and the frequency  $f$ . For example, at a frequency of two-and-a-half million cycles per second in water the wavelength is just over  $\frac{1}{2}$  mm.

#### Types of Waves.

An ultrasonic wave being transmitted through a substance may be of three types - namely, longitudinal, shear and Rayleigh or surface waves. Each type causes a specific movement in the elements of the medium and the paths that these elements follow as they move in response to the wave are called their orbits. If these orbits are lines parallel to the direction of propagation the waves are longitudinal, while if they are lines executed in the normal to this direction the waves are termed transverse or shear.

When the wave causes a volume change in the medium they are referred to as dilatational. When no volume change takes place the waves are termed distortional. Longitudinal and shear waves, theoretically, can be either dilatational or distortional but at ultrasonic frequencies longitudinal waves are principally dilatational and shear waves principally distortional.

At the ultrasonic frequencies in use, the size of the transducer (the element which produces the waves) may be made large in comparison with the wavelength. This allows the energy to be focused into a sharper beam, from which it diverges only slightly. The actual beam spread is a function of  $\lambda/D$  where  $\lambda$  is the wavelength and D the distance across the transducer face.

Shear waves have a velocity of about half that of longitudinal waves in the same medium. Because of this, the wavelength is correspondingly shorter. Shear waves cannot be supported by liquids and gases, since there is no elasticity to shear in such materials.

Surface or Rayleigh waves may be propagated over the surface of a medium without penetrating below that surface to any extent. These are rather analogous to water waves. The velocity depends on the material but is about nine-tenths the velocity of shear waves. The properties of these waves are not yet fully understood. Considering the properties of the different waves, it is not surprising that in ultrasonic work longitudinal waves have been most often used. Not only are they capable of being transmitted/

transmitted in liquids and gases but they are easily generated and detected.

### Mode of Propagation.

Propagation of ultrasound can be either continuous or pulsed. The former is self-explanatory but the latter is where the beam of ultrasound is generated in short 'bursts' or pulses with an interval between, during which time no energy is generated.

### Pulse Forms

Pulses may be of different types. Two main forms have been commonly used:-

1. The individual waves may be of the same amplitude and the pulse may start and stop abruptly. This is known as a rectangular pulse, since a graph of particle displacement to a base of time will have a rectangular outline or envelope.
2. The pulse may also build up rapidly and decay exponentially, in which case it is called a decayed or damped wave. This pulse shape is characteristic of percussive sounds like those produced by striking a bell.

This latter type of pulse is by far the most common in nature and the most useful.

### Speed of Sound Waves

The speed of the longitudinal waves of ultrasound in solids depends on the following equation:-

$$C_2 = \sqrt{\frac{E}{D} \frac{1-p}{(1+p)(1-2p)}}$$

where  $C_2$  = velocity

$E$  = Young's modulus which can be defined as a relation between the stress intensity and the resulting strain.

$p$  = Poisson's ratio, which is the relation between a change in width and the change in length that causes it.

$D$  = density of the solid.

This applies only to longitudinal waves.

In liquids and gases the equation reads:

$$C = \sqrt{\frac{K}{P \text{ Bis}}} = \sqrt{\frac{1}{P \text{ Bad}}}$$

where  $K$  = ratio of specific heats

$\text{Bis}$  = compressibility at a constant temperature (in respect of liquids).

$\text{Bad}$  = Adiabatic compressibility (in respect of gases)

$P$  = density.



PROPERTIES OF ULTRASONIC SYSTEMS.

Transmission through different Media.

Having considered the relationship and differences of ultrasonic waves in differing materials, the consequences of a wave passing from one medium to another must be considered. When the intervening boundary between the first medium and the second is reached part of the energy travels forward through the second material, while part is reflected back into the first medium with or without a phase reversal. The characteristic which determines the reflection at an interface between different media is the difference in the specific acoustic impedance of the media. The specific acoustic impedance for a particular medium is the product of the density of the substance and the velocity of sound in it. Since the density will be in grammes per cm.<sup>3</sup> and the velocity of sound in cms. per second, the resultant product will be in grammes per cm.<sup>2</sup> per second.

The relationship between the amplitude of the reflected wave to that of incident one is determined by the following equation:

$$A_r = \frac{SA_1 - SA_2}{SA_1 + SA_2}$$

where  $A_r$  = amplitude of the reflected energy.

$SA_1$  = specific acoustic impedance of first medium.

$SA_2$  = specific acoustic impedance of second medium.

As long as the wave travels in the same medium the energy is proportional to the amplitude squared; the reflected energy accordingly can be calculated from the equation:

$$R = R_0 \left( \frac{SA_1 - SA_2}{SA_1 + SA_2} \right)^2$$

where R = reflected energy

$R_0$  = incident energy.

$SA_1$  and  $SA_2$  being the specific acoustic impedances of the two media.

Using this equation it can be seen that should the sound be travelling from a solid or liquid to air, the equation would read:

$$R = R_0 \left( \frac{SA_1 - (0.0000413 \times 10^{-6})}{SA_1 + (0.0000413 \times 10^{-6})} \right)^2$$

which to all practical purposes is:

$$R = R_0 \left( \frac{SA_1}{SA_1} \right)^2$$

Therefore  $R = R_0$  or 99.999%.

In fact, where the second medium is air almost total refraction takes place.

This is true for all gases.

Should the beam of ultrasound strike the interface with the second material at an angle refraction will take place. This angle of refraction is dependent on the velocity in two media and the angle of incidence as follows:

$$\frac{\sin \theta_1}{\sin \theta_2} = \frac{C_1}{C_2} \quad (\text{Snell's Law})$$

when  $\theta_1$  = angle of incident energy to the normal.

$\theta_2$  = angle of refracted energy to the normal.

$C_1$  = velocity in first medium.

$C_2$  = velocity in second medium.

In any medium the major loss of ultrasonic energy is due to the viscosity or damping of the medium. Besides this, heat conduction and radiation between the compressed and rarefied sections of the medium seem to have a considerable part in the losses experienced.

When high intensity ultrasound passes through a liquid, bubbles may be observed to collect. These bubbles are gaseous, the gas evidently coming out of the liquid. These bubbles may be produced when rarefaction, associated with the waves, is sufficient to overcome the ambient hydrostatic pressure, causing small voids to appear in the medium into which dissolved gases may evaporate. This peculiar phenomenon is a form of 'cavitation'.

From study of the above, it can be seen that in any ultrasonic system four major phenomena can occur, namely:-

1. Reflection.
2. Refraction.
3. Attenuation - loss of energy and generation of heat.
4. Cavitation.

## METHODS OF GENERATING ULTRASOUND

There are four main electromechanical methods of producing ultrasound. These are namely, the piezo-electric, the magneto-strictive, the electro-magnetic and the electro-static. The latter two methods are not suited to the generation of particularly high frequencies, although they are most commonly used for sound ranging in air. For frequencies up to 100,000 cycles the magneto-strictive method can be used but for higher frequencies the piezo-electric effect is the best method to adopt.

### The Piezo-electric effect.

In 1880, P. & J. Curie discovered that certain crystals would develop an electrical charge when a mechanical pressure or tension was applied.

In 1881, Lipmann predicted the reverse effect; that is, placing an electrical charge across a crystal would cause it to distort. Thus, the conversion of mechanical energy to electrical energy became known as the direct piezo-electric effect, while the production of mechanical energy by an applied electrical potential was known as the converse piezo-electric effect.

Professor Langevin, when commissioned by the French Government, during the first World War to find a means of detecting enemy submarines, was the first to apply the piezo-electric effect to the problem of ultrasonic generation.

Since then the field has been gradually enlarged.

The/

The properties required for a practical transducer are, firstly, that it has a reasonable conversion of electrical energy; the measure of this is the electro-mechanical coupling factor which is defined as the amount of energy stored in mechanical form and the amount stored in electrical form when a unidirectional voltage is applied across the faces of the crystal. Good mechanical strength is the second essential property. Since quartz has excellent mechanical properties and a reasonable coupling factor, it has been widely used.

### The Quartz Crystal

The quartz crystal can roughly be described as a six-sided prism with a pyramid attached to each end.

Three axes are recognised:

- (1) A line joining the points of the pyramids constitutes the Z or optical axis.
- (2) Lines joining the angles of the prism (three to each crystal) are known as the X-axis or electrical axis.
- (3) Perpendicular lines from the sides of the prism to the opposite side (three per crystal) make up the Y-axis.

The axes referred to in (2) and (3) are perpendicular to the optical axis. An X-cut quartz crystal will generate longitudinal waves. Such an X-cut crystal is usually mounted with an electrode on each face impressing the exciting voltage on the blank. These electrodes will also make contact with the charge produced by vibrating the crystal by ultrasonic waves. This direct and converse piezo-/

piezo-electric effect constitutes the entire crystal transducer system.

If a crystal is excited by electrical or mechanical vibrations at its own natural thickness resonant frequency, its efficiency as a transducer is enormously increased. The resonant frequency is inversely proportional to its crystal thickness. It is accordingly possible to shock a crystal with such a voltage that it will oscillate at its own natural frequency.

When the crystal oscillates, transmission takes place in both directions perpendicular to its faces. To obtain the maximum efficiency in the forward direction, the crystal will require to be backed with a material of low ultrasonic transmission, such as air or bakelite. Air will tend to damp the crystal less than most materials and so would be most effective. For maximum resolution, the crystal should cease to oscillate abruptly at the end of the pulse and this usually entails damping of the crystal. For highest sensitivity, damping should be as light as possible, but if short pulses are required, heavier damping may be necessary. If a crystal transducer is placed on a dry surface, very little energy will be transmitted through the interface because of the intervening air present. A coupling medium is therefore required. This coupling medium should match the impedance of the crystal to that of the material for conduction.

Various artificial crystals can be used in place of quartz. Of these, barium titanate is probably the one in most common use.

Having discussed methods of generation and the relevant properties of ultrasound, the work previously carried out must be reviewed.

The first practical application of ultrasound as a method of heat treatment was reported by KILPATRICK (1918) who used it for the treatment of rheumatoid arthritis. The field expanded rapidly, but rather haphazardly. The practice of ultrasonotherapy was enthusiastically adopted in the years following the Second Great War and, by the late 1940s, the ultrasonic transmitters, which were used for the treatment of rheumatoid arthritis, were being used for a wide variety of conditions. However, this widespread use and the lack of scientific investigation, rather than the pursuit of scientific knowledge, led to a more practical fashion when they were used for the treatment of five weeks per course of treatment. The results were generally disappointing and it was found that the use of ultrasound without evidence. In other words, the use of ultrasound for the treatment of rheumatoid arthritis was the main beneficiary of the

THE APPLICATION OF ULTRASOUND TO MEDICINE

Therapeutic Effects of Ultrasound.

The effect of ultrasound as a therapeutic agent was recognised many years before the use of ultrasound as a diagnostic tool. Only brief reference, however, will be made to the therapeutic effects, since these are not concerned primarily with the present work.

In 1932 FRIENDLICH et al were the first to draw attention to the general application of ultrasound as a method of heating body tissues. The field expanded rapidly, but rather haphazardly. The practice of ultrasonotherapy was enthusiastically adopted by many in the years following the Second Great War and, according to the manufacturers of the ultrasonic transmitters, was a panacea. NELSON et al (1950) criticised this widespread use and called for more scientific investigation, rather than the reporting of clinical impressions. POHLMAN and REIMAR (1948) had approached the subject in a more practical fashion when they used outputs varying from two to five watts per sq.cm. of transducer, and suggested the correct dosage to any given area to be sufficient to cause erythema without oedema. In other words, they realised that the production of heat was the main beneficial effect to any lesion. NELSON (1950) carried out experiments on dogs, studying the temperature rise in tissues, especially those adjacent to bone. Using an output of five to ten watts per sq. cm., it was shown that though, on the whole, heat production was constant for any/



any given dosage, there were occasional variations which could lead to severe reactions. It was concluded that therapy to small circumscribed lesions was most appropriate.

A report by the Council of Physical Medicine and Rehabilitation (1952) made a plea for care in the application of ultrasound, due to the likelihood of tissue damage should cases be over-treated. They recommended for therapy a frequency of Eight-hundred Thousand cycles per second for thirty minutes, using an output of up to twenty-five watts per sq. cm.

By this time it had more or less been universally recognised that ultrasonotherapy was of most value in conditions which improved with heat or short-wave diathermy. IMIG et al (1954) showed, using a frequency of Eight-hundred Thousand cycles per second and outputs of 0.5 and 1.2 watts per sq.cm. for five minutes, that with the smaller dosage no change in blood flow to a part was noted, but with the larger there was increased blood flow. This was thought to be due purely to the thermal action, but they also noted some slight necrosis in the parts studied, (hind legs of anaesthetised dogs).

LEHMANN et al (1954) carried out a comparison of what was called microwave diathermy and ultrasonotherapy. Seventy-eight cases of periarthrititis of the shoulder joint were treated by the one or other means and there seemed to be a more marked improvement in the cases treated with ultrasound. It was postulated that this might be due to a selective heating at the interfaces of fibrous/

fibrous tissue capsules, tendons and nerves, but the figures were of doubtful statistical significance. Earlier DE PREUX (1952) using Eight-hundred Thousand cycles per second frequency and five watts per sq. cm. output, had studied the effects of ultrasound on osteoarthritis of the hips, rheumatoid arthritis and ankylosing spondilitis. He found the treatment of no value in rheumatoid arthritis and only of limited value in ankylosing spondilitis, but that it was the most effective therapy in osteoarthritis of the hip. A more recent publication by MONCUR (1957) from Bridge of Earn Hospital, Perthshire, reviewed Fifty-seven cases suffering from various disorders such as prolapsed intervertebral discs, fractures of the spine, ankle and wrist, and cases of osteoarthritis who had all ceased to have continued benefit from physiotherapy. Out of fifty-one cases he found eight completely relieved, twenty-one improved and twenty-two unaffected. He found that improvement was well maintained in cases who benefited and held the view that there was a definite place for ultrasonotherapy.

TEPPERBERG and MARJEY (1953) used either continuous or pulsed ultrasound in the treatment of neurofibromas arising in amputation stumps. They used an output varying between 0.5 and three watts per sq. cm., and in their series of five cases, two were cured and two improved, while one was no better. A larger series, and consequently of more significance, was reported by RUBIN and KUITERT (1955). They used a dosage of one watt per sq. cm. for five minutes, making twelve treatments as their maximum. Of thirty-five cases treated, twenty-/

twenty-three were completely relieved, nine had some residual pain and three experienced no relief. Any recurrence responded well to therapy. In some of their cases, excision of the treated area had to be carried out for some other reason at a later date, but there was no evidence of damage.

It would seem from the above that there is still a place for ultrasonotherapy in physiotherapy, but little else can be substantiated. Probably the most exaggerated claim was made by HORVATH (1946 a & b) who maintained, using a frequency of Eight-hundred Thousand cycles per second, that there was selective destruction of malignant tissue.

MORROW et al (1950), on the other hand, when studying the effect of ultrasound on the blood in cases of lymphatic and myelogenous leukaemia, found that there was a significantly higher destruction of the normal blood cells than of the abnormal primitive cells.

HERRICK and KRUSEN (1954) and LEHMANN and KRUSEN (1955) have, however, finally disproved Horvath's claims. The latter treated Erlich's ascitic carcinoma as a solid tumour in the tails of mice and also suspensions of such cells with ultrasound at one-megacycle frequency and an output of 8.4 watts per sq. cm., and found that when cavitation and thermal effects were inhibited no cell change took place. They found that treatment of such lesions with X-rays and ultrasound produced an enhanced effect to X-rays alone, but concluded that this was merely due to thermal effects.

The effect of ultrasound on selected areas of the brain, which will/

will be discussed in more detail later, has led to the use of ultrasound as a method other than direct surgery for performing leucotomy. ZUBIANI (1951) was one of the first to recognise this and, after experimenting with dogs, carried out leucotomy on cases of general paralysis of the insane and schizophrenia, with promising results. Later, work in a more scientifically experimental manner was carried out by FRY et al (1954 and 1955) and BARNARD et al (1955, a & b). For reasonable results, however, 'burr' holes require to be made in the skull, which naturally takes away much of the advantage over surgery. With further experiment and improved techniques there may yet be a reasonable place for this therapy.

ULTRASOUND AS A DIAGNOSTIC ADJUNCT.

For use in the diagnostic field of medicine, it can be appreciated that the two properties of ultrasound most likely to be applicable are those of attenuation and reflection. If a beam of ultrasound be sent through a given tissue or body structure the variation in the amount absorbed could be picked up by a receiving crystal at a point directly opposite the transmitting one. This method of 'transmission' was the basis of the first attempts to use ultrasound as a diagnostic aid.

DUSSI<sup>K</sup> (1942) was the first to suggest the possibility of using ultrasound in this manner. Using an instrument called a hyperphonograph he studied the variations in the ultrasonic beam through the cranial cavity. DUSSI<sup>K</sup> et al (1947) had improved their technique for examination of the skull and had compared their results with ventriculograms, claiming that they too could outline the cerebral ventricles. They obviously were aware that damage could be caused, since they asserted that over one-hundred heads had been so examined and no mental damage had been detected. Such a statement tends to suggest human experiment.

BALLANTINE et al (1950) had carried out similar experiments in order to try to detect cerebral pathology by transmitting ultrasound through the skull. A method for outlining the cerebral ventricles was also described by HEUTER and BOLT (1951). They used continuous ultrasound at a frequency of two megacycles per second and took thirty to forty linear scans from above down, transmitting/

-transmitting through the skull transversely. Naturally, the more fluid-filled cavities crossed by the beams of ultrasound, the more total transmission there would be, and so the difference in the absorption at various levels would outline the ventricles. Heuter and Bolt thought that transmission of ultrasound had more possibilities as a diagnostic aid than the measuring of reflections from interfaces, but since no other published work is available, the method of transmission seems to have been unrewarding.

The use of reflected energy as a means of diagnosis depends, of course, on the variation in the specific acoustic impedance of the various tissues of the body or inherent abnormalities.

LUDWIG (1950) calculated that muscle and normal soft tissue had a specific acoustic impedance of  $1.5$  to  $1.7 \times 10^{-5}$  G. per  $\text{cm}^2$  per second.

To review the development of ultrasound as a diagnostic tool, the work previously carried out will be studied in chronological order. LUDWICK and STRUTHERS (1949) were able to detect gallstones and other non-radio-opaque foreign bodies embedded in muscle, using a frequency of 1 to  $2\frac{1}{2}$  megacycles per second. FRENCH et al (1950) were the first to attempt to detect differences in normal and abnormal tissue by this means. They studied brains removed at post-mortem examination and were able to locate tumours within the brain substance. Instead of continuous ultrasound, pulsed ultrasound was now being used with the echoes being studied on a cathode-ray tube, the echoes being represented as amplitude modul- /

modulation deflections from a base line: This was known as A-scope presentation. WILD (1950) used a fifteen megacycle frequency with a pulse of half-a-microsecond to study differing strips of small intestine and a portion of gastric carcinoma. He discussed the possibility of using a sound-head surrounded by a condom in various parts of the gastro-intestinal tract. He also hoped that the earlier diagnosis of cancer might be possible, due to the echo variation between normal and malignant tissue. The 'hopes' rather outweighed the reality.

WILD and NEAL (1951) turned their attention to breast lesions and showed differing echoes obtained from normal breast and from one containing a fibroadenoma. They claimed their output to be 0.5 watts per sq. cm., and discussed the likely harmful effects. Their estimate of output seems surprisingly low and, so, doubtfully accurate. FRENCH et al (1951(a)) reckoned that neoplastic tissue gave twice the reflection of normal tissue.

REID and WILD (1952) began to use this increased echo amplitude from cancerous tissue as a means of diagnosis in cases of breast neoplasm. WILD and REID (1952 (a)) found that in malignant tissue there were more echoes, more penetration and stronger reflections. They used the normal breast as a control and when the echoes were of less amplitude and similar in number in the suspect breast compared with the control, the lesion was thought to be simple and vice-versa. Nineteen breasts had been examined with reasonably accurate results.

The apparatus used was the standard type of radar trainer used by the U.S. Navy. They still used a frequency of fifteen megacycles per second, with a pulse length of one-half microsecond. They calculated the maximum output now to be six-hundred & forty-four watts per sq. cm., but that this was only on the initial and peak pulse, and reckoned the average output to be only 1.3 watts per sq. cm. With increase in frequency, attenuation in tissue also increases and at fifteen megacycles frequency the range is only about two cms. Coupling of the apparatus to the patient's skin was by a column of water.

At this time it was recognised that 'A'-scope presentation had its limitations, due to the small area examined with purely a linear presentation. WILD and REID (1952 a & b) developed their existing equipment to give a two-dimensional survey. They described their technique as taking a series of needle biopsies in a line across a given area. In other words, they scanned across a structure, taking soundings as they went. Instead of echoes being represented as deflections from a base line as in 'A'-scope, the echoes were now represented as dots on the cathode-ray tube, and the brightness of the dot depended on the magnitude of the echo. They illustrated the new technique in pathological specimens of kidney cortex, cancerous regional lymph nodes and a tumour of the thigh, and showed how the old 'A'-scope presentation could be transformed into an echograph.

At the same time as WILD and REID were making echographs, HOWRY/



HOWRY (1952) and HOWRY and BLISS (1952) had begun to develop what they called the somascope, or tissue vision. Their apparatus was in theory similar to that of Wild and Reid, but they did not use the standard radar trainer. They did not state the frequency used, but used a simple five-thousand volt pulse of one-third microsecond duration, applied to an X-cut quartz crystal. Two-thousand pulses per second they found to be sufficient. The average output they thought to be a milliwatt. With the somascope they illustrated different echoes obtained from pathological material (gallbladder, gall stones, etc.), and non-radio-opaque material embedded in tissue. The area covered by a single scan was very small.

WILD and REID (1953) began to use two-dimensional echography on neoplasms of the breast. By comparing the number of echoes from a given area in the normal and abnormal breast, they figured that if the number of echoes were greater in the abnormal breast then the tumour was malignant. They again reviewed nineteen cases. Later WILD and REID (1954) brought the diagnosis of malignancy of the breast on to a more mathematical basis. If the ratio of the number of echoes from a given square area in the affected breast, over the number of echoes from a similar square in the normal breast, is greater than one, then the lesion is malignant, but if it is less than one, then it is simple.

To represent this mathematically:-

$$\frac{\text{No. of echoes from a given square in breast containing neoplasm}}{\text{No. of echoes from a corresponding square in the normal breast}}$$

$$= X.$$

If X is greater than one, the lesion is malignant; if one or less, the lesion is benign. They also asserted that, because of more echoes and stronger echoes, malignant tissue should look brighter than simple tumours or normal breast tissue viewed on the cathode-ray tube.

HOWRY et al (1954) illustrated sonographs taken of pathological specimens of a breast carcinoma. They also showed a scan of the mid-third of the forearm and claimed to show nerves and veins. They accordingly claimed to be the first to show such detail in soft tissue. They pointed out their differences in technique from Wild and Reid. These were, the use of a lower frequency, lower power output and narrowing of the sound beam by focusing. They still did not state what frequency was used, or how the beam was focused. The focusing may have been by using a curved transducer. By 1955 HOWRY et al (1955) had begun to add together their small section scans, in order to build up a complete scan over an area. They illustrated their work with a cross-section of neck, showing a case with an adenoma of thyroid. They also showed quadrants of the abdomen, both normal and where there was ascites with metastatic carcinoma of the liver. HOWRY (1955) discussed some of the difficulties of the technique of scanning. Quite a small angular displacement from the perpendicular in the incidence of the ultrasonic beam produced great differences in the amplitude of the reflected echo. He calculated that angles as small as  $6^\circ$  and  $12^\circ$  from the normal caused the amplitude to fall by factors of ten and/

and one-hundred times respectively. He also suggested, instead of two-dimensional scanning, advancing to three-dimensional scanning and stereoscopic viewing. This latter, variable projection somography as it is called, is carried out by scanning the area or object under examination from slightly different angles and then combining the resultant pictures on one photographic plate. HOWRY et al (1956) showed stereoscopic views of various objects in a water bath and a stereoscopic picture of a cross-section of forearm.

REID and WILD (1955) had modified their apparatus and described how similar principles could be applied to areas other than breast lesions, on which they had concentrated particularly. These related to lesions of bowel and cervix uteri. The range of their machine was even now only four cms. The peak power, however, was down to seventy watts per sq. cm.

WILD and REID (1956) claimed they could detect a tissue interface having a fractional difference of one part in ten million. Their breast cases now numbered seventy-seven. They tended to err on the side of calling simple lesions malignant, and make the claim that if they say a lesion is simple they are ninety-eight per cent correct. This is a bold statement, when only seventy-seven cases have been examined. They also claim to have diagnosed an intraduct carcinoma when only one mm. in diameter. This is indeed impressive, and is getting down to almost microscopic diagnosis.

KIKUTCHI et al (1957) in Japan used barium titanate ceramic transducers with frequencies ranging from one to ten megacycles per/

per second. Initially they had used 'A'-scope presentation in examination of brain lesions. They had studied abnormal echoes from tumour areas and areas of focal epilepsy and claimed they could detect pulsating echoes from the ventricles, but do not reveal their experiments which prove it. They suggest variation in attenuation is present in brain tumours, epilepsy and general anaesthesia. A carcinoma of stomach is also shown, with views taken from the anterior abdominal wall and from the back. Later, they developed the P.P.I. display, immersing patients in water and traversing the surface with the transducer set on rails. They called this ultrasono-tomography. They illustrated their method with a scan of the abdomen, and claim to have detected gall stones, carcinoma of stomach and carcinoma of the pancreas. With breast lesions, they used a frequency of five to ten megacycles per second, and claimed they could diagnose carcinoma. With lesions in the chest, a difference between normal lung and a tuberculous cavity was illustrated. The presence of air in lung tissue makes examination of thoracic conditions very difficult, and lesions would necessarily require to be close to the lung surface.

By fixing the crystal and rotating the recording film slowly onward they obtained what they called T.P.I., or time-position-indication display. This was used to study peristalsis and cardiac movement. With regard to work on the heart using 'A'-scope, EFFERT et al (1957) studied the movements of the left atrial wall of the heart simultaneously with electrocardiography and phonocardiography in the/

the relative assessments of mitral stenosis and incompetence. They were able to demonstrate pericardial effusions. Actual measurements of the heart wall by this method seems imminent.

LEKSELL(1956) in Sweden had also been using 'A'-scope presentation through the intact skull, to assist in the diagnosis of intracranial haemorrhage. They examined for deviation of the falx cerebri or interventricular "membrane" indicating haemorrhage and attempted to plot the possible site. He described four noteworthy cases.

The latest published work has been by DONALD et al (1958). In this work, abdominal masses are specially studied. Their correlation of results with operative findings is of particular importance.

To be critical of the above work is easy. So many of the published articles have been only slightly more advanced than the previous ones by the same authors, that repetition is only too common.

Fantastic claims bear no relation to controlled experiment. "Bowel peristalsis and shifting positions of food was followed easily through segments of small bowel", is a quotation from HOWRY et al (1955). When one thinks of the tortuosity of the small bowel when enclosed in the abdominal cavity, it is doubtful if even direct vision could attain what is claimed. Also, when one considers the difficulty the pathologist occasionally has of differentiating the malignant from the benign cell, it would seem too premature to claim diagnosis of cancer as Wild and Reid have done.

Howry is correct when he says that an easy and reliable method of/

of visualising nerves, arteries, veins, fascial planes and gross structural changes would be of value, but should not suggest that his machine is of that accuracy. KIKUTCHI and his co-workers make many statements without support from illustrations. That general anaesthesia should cause marked variations in ultrasonic attenuation in the brain seems fantastic, and such variations are neither illustrated nor explained by these workers. The cases shown, of carcinoma of the stomach seen from the front and back, seem to take no consideration of gas in the viscus, which would cause complete reflection, and the gross amount of soft tissue when viewing from behind. Imagination seems to have outrun scientific fact. With so much air in the lungs, a tuberculous cavity would require to be very close to the lung surface before it would show up. It would also require to be filled with fluid or semi-solid material. If, however, the previous work is reviewed with a critical mind and one is not carried away by all that has been claimed, much fundamental work has been carried out which, when accumulated, leads to much assistance for the future in diagnosis.

HARMFUL EFFECTS OF ULTRASOUND.

Since there was production of heat when using ultrasound therapeutically, it was obvious that the effect of ultrasound on various body tissue cells had to be investigated. LYNN and PUTNAM (1944) were among the first to carry out such experimental work, using continuous ultrasound at a frequency of Eight-hundred & thirty-five kilocycles per second for ten to fifteen minutes of the skulls and brains of cats, dogs and monkeys. They found that there was dry sequestrations of the skull and destruction of brain tissue. FRY et al (1950) studied the physical factors involved in ultrasonically induced changes in nerve tissues. Using the sciatic nerve and vertebral column of frogs and the walking leg nerves of crayfish, they studied the effect when the temperature was kept constant for a given dose of ultrasound. Even when the temperature of the parts treated was not allowed to rise, paralysis was effected. They also found that varying the temperature of the parts exposed necessitated differing irradiation to produce paralysis. Histological examination of the spinal cord of the treated frogs revealed marked abnormality of the large motor neurons in the ventral horn. The output used was Thirty-five watts per sq. cm. at a frequency of one megacycle per second. Having proved that the effects were not thermal in origin, it was concluded that they must be due to cavitation.

Later FRY et al (1951), continuing with their investigations into the effects of ultrasound on the vertebral column of frogs, using/

using sufficient hydrostatic pressure to stop the effects of cavitation, were still able to cause paralysis, showing that at least cavitation was not the all important factor. By using thermocouples, they concluded that the absorption of ultrasound at cell interfaces in the spinal cord does not result in minute hot areas, which would cause the damage. Using constant hydrostatic pressure and temperatures, they worked out mathematical formulae to calculate the dosage required to give varying degrees of damage. Living tissue, however, is well known not to respond according to mathematical formulae. In their experiments they found difficulty when using intermittent dosage to be able to estimate the actual summation of damage.

ANDERSON et al (1951) had been working on the effect of radiation with ultrasound on the lower part of the spinal cord and peripheral nerves of rats and dogs. They used an output of three to 5.8 watts per sq. cm., and found varying necrosis of tissue, dependent on the duration of irradiation. They concluded that this was purely due to thermal damage, but their work bears no comparison to the scientific approach of Fry and his colleagues. ZUBIANI (1951) had carried out experiments on guinea-pigs. In ten guinea-pigs whose brains had been irradiated, epileptic fits were produced in three, and the remainder were shown at post-mortem to have focal and generalised brain damage. FRENCH et al (1951 b) having started experiments on the use of ultrasound in diagnosis, decided that before much work was carried out in this direction the particular/



particular machine in use had to be proved safe. They used four rabbits and one cat and, having removed the vault of the skull, they irradiated the brains for periods varying between fifteen to thirty minutes. The apparatus used had a frequency of fifteen megacycles pulsed one half-millionth of a second and recurring One-thousand & fifty-five times per second. Continuously powered, the output would have been in the region of one-hundred watts, but the actual output was reckoned to be only in the region of 0.05 watts. The animals were killed four to eight weeks later, and no lesion of any type was detected.

That all cells did not respond equally to ultrasound was first shown by WALL et al (1951). They used the spinal cord of rats and frogs and the cerebral cortex of cats. The frequency used was one-megacycle at various pressure amplitudes and varying exposure times. The overlying bone was removed before irradiation in their experiments. They noted that sensation still remained even when motor power had been knocked out with minimal paralysis dosage. This was due to the anterior horn cells of the spinal cord being the first to be damaged. They also noted that a degree of cell damage, without sensory or motor upset, could be produced. The selective action in various cells was a further factor against heat being the cause of damage.

At a Symposium on ultrasound in Biology and Medicine at the University of Illinois in May 1953, much of the work previously carried out was reviewed and conclusions discussed. The papers/

papers presented at the meeting were published in the Journal of the Acoustical Society of America, Vol. 25 1-25 1953. FRY (1953) dealt generally with the effects on the nerve cells of the central nervous system, which, of all structures of the living organism, is most susceptible. Any histological changes manifest themselves one to two hours after irradiation. The primary effect, however, is not one of gross disruption of cellular or nuclear membrane. Should there be change in structure of the cell, then the effect is irreversible whereas, although function be immediately destroyed, the change need not be irreversible, provided there is no gross change in cell structure. The larger the neuron of the nervous system, the more liable it is to damage. The glial cells and supporting structures are the first to be affected, while the vascular elements are the last to be affected. With controlled dosage, therefore, nerve cells can be destroyed without other damage.

FRY and FRY (1953) discussed the thermal effects of ultrasound on tissue and found that tissue in close proximity to bone was more liable to temperature change. This was due to the absorption at the bone interface. They also used rise of temperature to obtain the value for the acoustic absorption co-efficients of tissue. This was constant for every type of tissue.

At the same Symposium, HERRICK (1953) who had studied the therapeutic effects of ultrasound, discussed the similar effects of heat and ultrasound on nerve tissue. He had carried out experiments/

experiments with ultrasound in nerve tissue and found that as long as it was kept cool with circulating oil, the ultrasound had no effect on the nerve action, but when the oil was stopped a rise in temperature took place and the nerve was consequently damaged. He also discussed the narrow margin between reversible and irreversible change which may take place when nerves are heated. He also proved that bone growth could be inhibited by ultrasound. A great deal of the evidence presented quotes unpublished work, so that verification is difficult.

LEHMANN (1953) also studied reaction to ultrasound with special reference to its therapeutic action. He postulated that as well as the selective action of heating of tissue, such as nerve and bone, there might be a mechanical effect. Should the diffusion layer at an interface be decreased as by stirring, the exchange of metabolites is augmented. He calculated that using a frequency of one-megacycle and an output of 0.5 - 4 watts per sq. cm., the acceleration of the elementary particles of a medium was about one-thousand time gravity and that pressures in the order of several atmospheres may be found along the distance of half a wave-length. This would seem to explain the feasibility of cavitation.

WALL et al (1953) studied the histological changes which are produced in the central nervous system irradiated with high intensity ultrasound. Their experiments verified the results of Wall et al (1951), in that the nerve cell bodies were much more sensitive than the blood vessels and nerve fibres. By using a focused beam/

beam of ultrasound, they were able to produce discrete lesions deep in brain tissue without any other overlying disturbance. The parts used were, the spinal cords of frogs and the cortex of cats. They concluded that the lesions were neither the effect of heat nor cavitation.

FRY et al (1954 a), FRY et al (1955, a & b) and BARNARD et al (1955 a & b) all carried out further studies on the selective destructive action of ultrasound. They visualised its use in medicine and, as referred to previously, could be used as a means for pre-frontal leucotomy. FRY et al (1955b) found that the white matter of the brain was more readily affected than the grey matter. Since the blood vessels are fairly resistant, the chance of haemorrhage taking place following tissue destruction is quite small. They also succeeded in working out quantitatively the amount of ultrasound required to cause the same amount of damage in different animals of the same species. After white matter and grey had been irradiated, the process of damage was studied histologically. One hour after white matter was irradiated the myelin sheaths appear beaded, the perivascular spaces are dilated and some separation takes place between the fibres. Six to twelve hours later, the myelin sheaths break down into separate spheres and axis cylinder fragments increase in the lesion area. A glial scar is ultimately formed. Higher dosage is required for grey matter, and ten minutes after exposure there can be seen slight dilatation of perivascular spaces and lightening of the staining in the background matrix. Within the/

the hour, the nerve cells stain more faintly. Many will be seen to contain large clear vacuoles in their cytoplasm, while others will have the cell membrane ruptured although the nucleus is still intact. By one day the cells have disappeared, and by twelve days the glial response is well developed. FRY and DUNN (1956) were able to draw a curve of paralysis, using mice twenty-four hours old and irradiating the third lumbar vertebra. The frequency used was Nine-hundred & Eighty-two kilocycle, base temperature 10° and 20° C. The output and duration of irradiation varied between Fifty watts per sq. cm. and One-hundred & twenty watts per sq. cm., with duration of ten and one seconds. The resultant curve of paralysis seemed uniform.

The final solution to the problem of the destructive effect of ultrasound still remains undiscovered. It is clear, both experimentally and histologically, that neither heat nor cavitation is solely responsible. The main argument for the existence of an interference by ultrasound with the cell structure that is primarily mechanical rests with the findings of FRY et al (1954 b), that a subliminal dose of ultrasound, which by itself produces neither a substantial temperature rise nor any histological or physiological effect, has a 'priming' effect on the tissue, i.e. the tissue displays a 'memory' for such subliminal dose. It appears that this memory of a subliminal exposure to ultrasound is stored in the form of a subtle and reversible structural change at a submicroscopic level. If the exposure is repeated at suitable intervals the amount of these/

these changes reaches a level where a decay process is initiated. Although the effect may be mechanical, it could be possible that the changes and their progression may be dependent on the temperature prevailing at the site of irradiation. HEUTER et al (1956) pointed out that the complex molecular structure of living tissue may react in a similar way to the disrupting effect of mechanical strain as to the disordering effect of heat. Also, because of the strong dependence of biological reaction equilibrium on the temperature, it would be difficult to separate effects that are primarily mechanical and effects that are primarily thermal. On this assumption our state of knowledge rests in the meantime.

EXPERIMENTAL WORK CARRIED OUT WITH 'A'-SCOPE PRESENTATION.

Ultrasonic flaw detectors are now in common use in industry for the detection of flaws, grain size, thickness and incipient fatigue failure of metals. The original apparatus was designed by FIRESTONE (1945). He called the instrument, the Supersonic Reflectoscope. FIRESTONE (1946) and FIRESTONE and FREDERICK (1946) published refinements to the original apparatus and the description of the forerunner of the present instruments in industrial use was made by DELANO (1946), who called it, the Supersonic Flaw Detector. The basic idea of the apparatus is that should there be a break in uniformity of the part examined, there will be a difference in specific acoustic impedance, and so there will be reflection of ultrasound.

On reviewing the work previously carried out by ultrasound in diagnosis, it was noted that little work had been performed on the examination of intra-abdominal masses and, since many of these seen in the Department of Gynaecology, Western Infirmary, Glasgow, were later to come to removal at laparotomy, it was decided that this might be a profitable line of study. The Kelvin and Hughes Flaw Detector Mark (IV), see Fig. 1, seemed the most useful equipment available and initial experiments were carried out with this. The frequency range available in the Mark (IV) is five-eighths to five megacycles per second if the appropriate crystals are used. This frequency range is much lower than that used by Wild and Reid, but as LUDWIG (1950) pointed out, the choice of frequency for diagnostic/




FIG. 1. KELVIN AND HUGHES FLAW DETECTOR MARK IV.



diagnostic medical purposes involves many considerations. Since the attenuation in tissue is so great at higher frequencies, the frequency must be maintained low enough, or the intensity increased, to achieve deep penetration. The danger of tissue damage imposes an upper limit of intensity and consequently the frequency must be decreased to allow the desired amount of penetration. It would be of no value to have only a range of 4 cm., as Wild and Reid had, in examination of abdominal masses. Lowering the frequency, however, increased the wavelength, with a resultant decrease in resolving power and beam directivity. Resolution is of importance in diagnostic work, and so the choice of frequency must be a compromise, low enough to offset the increasing attenuation with increase in frequency, and high enough to provide resolution. The range of one to five megacycles, it was thought, fulfilled these requirements.

Probes (i.e. the parts containing the receiving end transmitting crystals) were available, containing quartz crystals ground for frequencies of Five-eighths; One-and-a-quarter; Two-and-a-quarter; Two-and-a-half and five megacycles respectively. Before attempting to diagnose lesions in patients, it was decided to carry out experiments with tissue in a water tank constructed of perspex measuring 40 x 30 x 20 cms. with a circular hole covered by a rubber diaphragm in one end, to enable the ultrasound to be easily transmitted into the water tank. When the water tank was filled with fresh boiled water, in order to reduce the amount of air /

air present, the ultrasonic beam had an uninterrupted passage until the opposite end of the water tank was reached. Olive oil smeared on the rubber diaphragm assured acoustic coupling. Reflections from biological material placed in the ultrasonic beam could be studied on the cathode-ray tube of the Flaw Detector. This was 'A'-scope presentation as previously described. A graduated line to which the base line of the presentation could be set, is mounted in front of the cathode-ray tube. Various ranges could be obtained and, using the water tank, these ranges were correlated with the graduation on the flaw detector. An addition to the usual flaw detector was the mounting of a fixed focus 35 mm. camera in front of the cathode-ray tube face, in order to obtain permanent records.

Various substances were tested in the ultrasonic beam, using a much-distended finger cot as a container. A finger cot so distended was used in order that the rubber would be of sufficient fineness to prevent any reflection from the rubber itself. As well as reflections from the substances within the finger cot, the reflection from the back wall of the water tank was noted, in order to appreciate if any attenuation of the ultrasound took place.

The following results were obtained:

Water - No reflection obtained. No obvious attenuation.

Air - Complete reflection. No rear wall echo noted.

Pus - Very small reflection. No obvious attenuation.

Blood - Very small reflection. No obvious attenuation. Very similar to pus.

Liquor amnii (cloudy) - Small reflection. No obvious attenuation. Stronger reflections than pus or blood.

Meconium-stained liquor - Small reflection. No obvious attenuation. Stronger reflections than with cloudy liquor and the more meconium the stronger the reflections.

A placenta placed in the water tank gave relatively small reflections irrespective of whether the amniotic or maternal surface was directed towards the probe. A uterus, freshly removed at operation, showed a small reflection but there must have been attenuation in the tissue, since the rear wall echo was much reduced.

When a simple fluid-filled ovarian cyst, immediately after removal at operation, was placed in the water tank a distinct echo was obtained, both from the front and back wall of the cyst. There was little attenuation of the sound, since the echo from the rear wall of the tank was still quite apparent. This cyst is depicted in Fig. 2. The range in this instance was  $4\frac{1}{2}$  cm. = 1 unit, so that the cyst diameter could be measured.

A fibromyoma of the uterus placed in the experimental tank gave a totally different picture. This is illustrated in Fig. 3. The fibromyoma was about three inches in diameter. On this occasion there was a very marked reflection from the front wall of the fibroid, but none from the back wall. Only a very small echo denoted the rear wall of the tank, showing that very marked atten-/

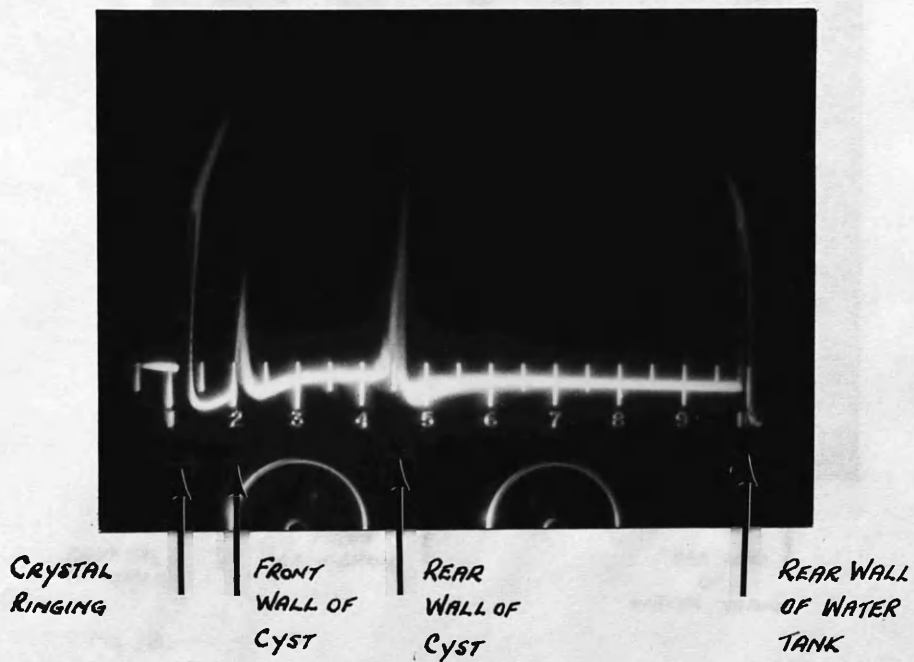


FIG 2. SIMPLE FLUID FILLED OVARIAN CYST IN EXPERIMENTAL WATER TANK.

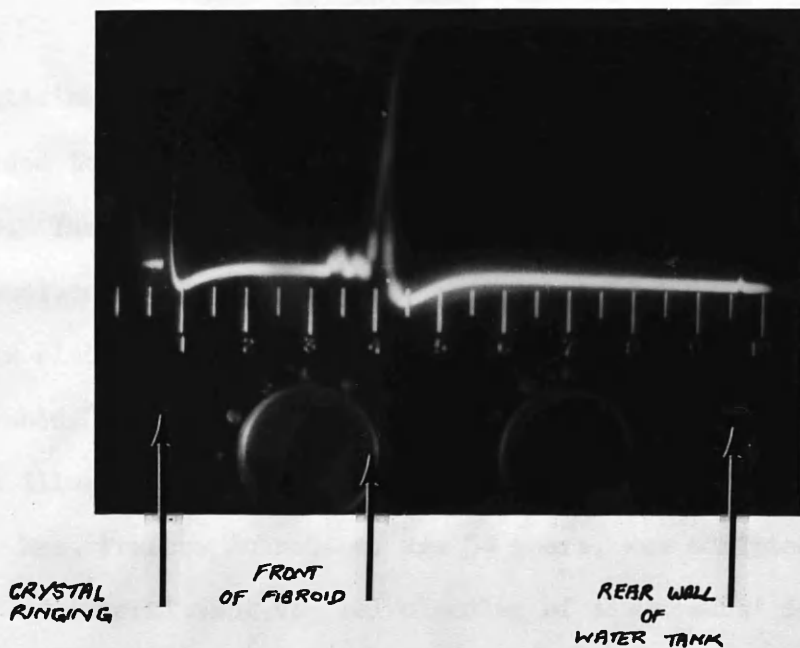


FIG 3.

FIBROID IN EXPERIMENTAL WATER TANK  
NOTE MARKED REFLECTION FROM FRONT WALL  
OF FIBROID  
BUT POOR REFLECTION FROM REAR WALL  
OF TANK  
SHOWING ATTENUATION OF SOUND.

attenuation of the ultrasound had taken place in traversing the fibroid.

Having attained such differing echoes from various structures, it was decided to carry out experiments on abdominal masses in patients. The patient's abdomen was smeared liberally with olive oil to exclude any air between the crystal and the skin. The probe was placed over several areas in each case and the results photographed. The following case reports and ultrasonic pictures obtained illustrated the results:-

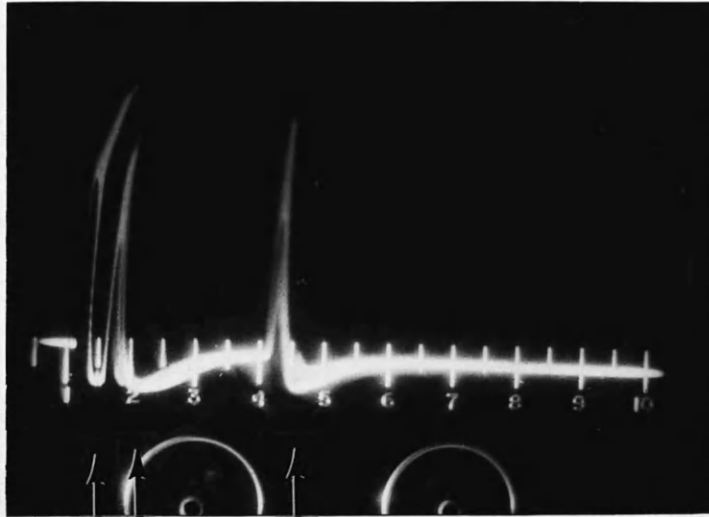
CASE I: Mrs. Frances Johnstone, age 54 years, was admitted because of intermittent vaginal bleeding of six months' duration.

On abdominal examination, a cystic mass was palpable from the symphysis pubis to three finger-breadths above the umbilicus. The swelling seemed smooth and cystic. There was no clinical evidence of ascites.

Clinical diagnosis of an ovarian cyst was made, and this was substantiated by ultrasonic examination, since the picture obtained, Fig. 4, was similar to that obtained by a cyst in the experimental tank.

The diagnosis was confirmed at laparotomy and histological examination of the cyst revealed it to be a unilocular cystadenoma.

CASE II: Mrs. Jean Wignall, age 28 years, was admitted to a Surgical Ward of the Western Infirmary. Her complaint was of increasing abdominal swelling of several months' dur- /



CRYSTAL  
RINGING

FRONT WALL  
OF CYST

BACK WALL  
OF CYST.

FIG 4.

CASE 1.

UNILOCULAR CYSTADENOMA

PROBE OVER MASS IN SUBUMBILICAL REGION.

duration. She suspected she might be pregnant.

On abdominal examination, a tense cystic swelling the size of a thirty-week pregnancy was present. No foetal parts could be felt.

A tentative diagnosis of ovarian cyst was made. On ultrasonic examination the appearance was suggestive of a cystic structure, Fig. 5. The anterior and posterior wall echoes were more complex than previously, and this suggested a thick-walled structure. At laparotomy, the diagnosis of an ovarian cyst was confirmed. Histologically the cyst was a unilocular pseudomucinous cyst-adenoma with thickened walls (0.5 cm.).

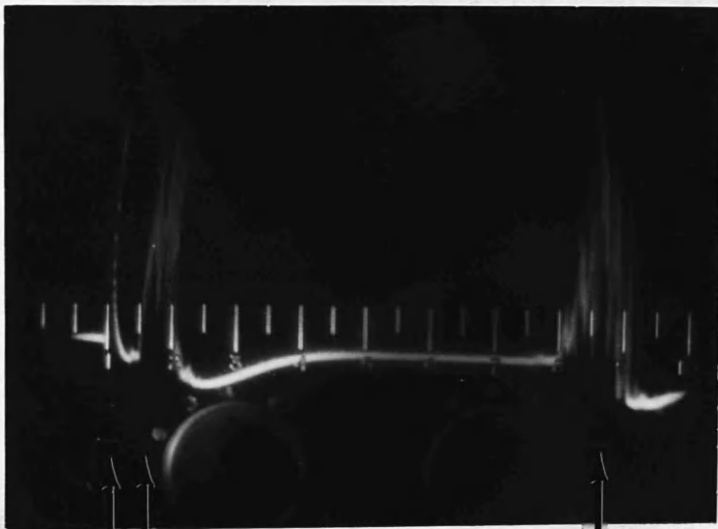
The next case is noteworthy, since it was the first occasion in which the ultrasonic diagnosis contradicted the clinical diagnosis.

CASE III: Mrs. Elizabeth MacKenzie, age 52 years, was admitted complaining of lower abdominal pain of five days' duration. An X-ray menopause had been carried out five years previously. She had some purulent vaginal discharge.

On abdominal and vaginal examination, a midline swelling was palpable, arising from the pelvis and extending three inches above the symphysis pubis. The swelling was tender to palpation. A diagnosis of pyometra was made.

On examination with the ultrasonoscope over the tender swelling, the findings in Fig. 6 were obtained. There was no doubt from this/





CRYSTAL  
RINGING

FRONT WALL  
OF CYST

BACK WALL  
OF CYST

FIG. 5. CASE II

UNILOCULAR PSEUDOMUCINOUS CYSTADENOMA.

NOTE DIFFUSE ECHOES FROM THICK WALLS.

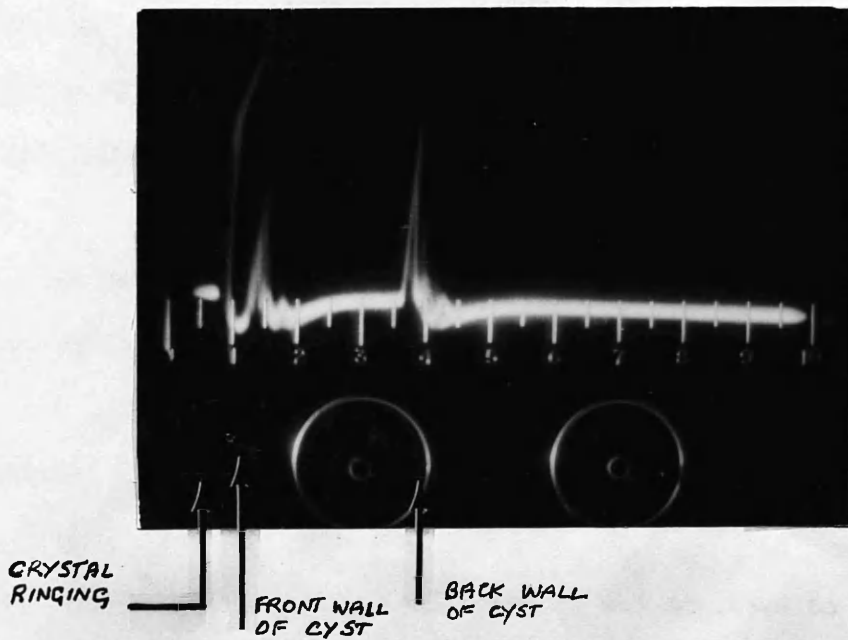


FIG 6. CASE III  
SIMPLE PSEUDOMUCINOUS CYSTADENOMA  
CLINICAL DIAGNOSIS OF PYOMETRA

this examination that the underlying structure was cystic.

At laparotomy, the ultrasonic diagnosis was proved correct, since the underlying lesion was an ovarian cyst arising from the right ovary and lying anteriorly to the uterus, having undergone slight torsion.

The cyst on histological examination was found to be a simple pseudomucinous cystadenoma.

More complex cystic structures gave different ultrasonic pictures, as can be seen from the following case:

CASE IV: Mrs. Jean Anderson, age 68 years, was admitted to hospital for investigation of Raynaud 's disease.

On abdominal examination she was found to have an irregular semi-solid, semi-cystic mass from the symphysis pubis to about two finger-breadths above the umbilicus. There was no clinical evidence of ascites. A clinical diagnosis of a malignant ovarian cyst was made.

On examination with the ultrasonoscope, various differing pictures were obtained. The structure seemed in the main cystic, but instead of a clear area between the anterior and posterior wall, there were several positions where other small echoes were obtained. Fig. 7 shows the pictures taken in the right iliac fossa. It is noteworthy that the rear wall does not show so much as one would expect. This was thought to be due to attenuation of the ultrasound, and it was postulated that although in the main the structure was cystic/

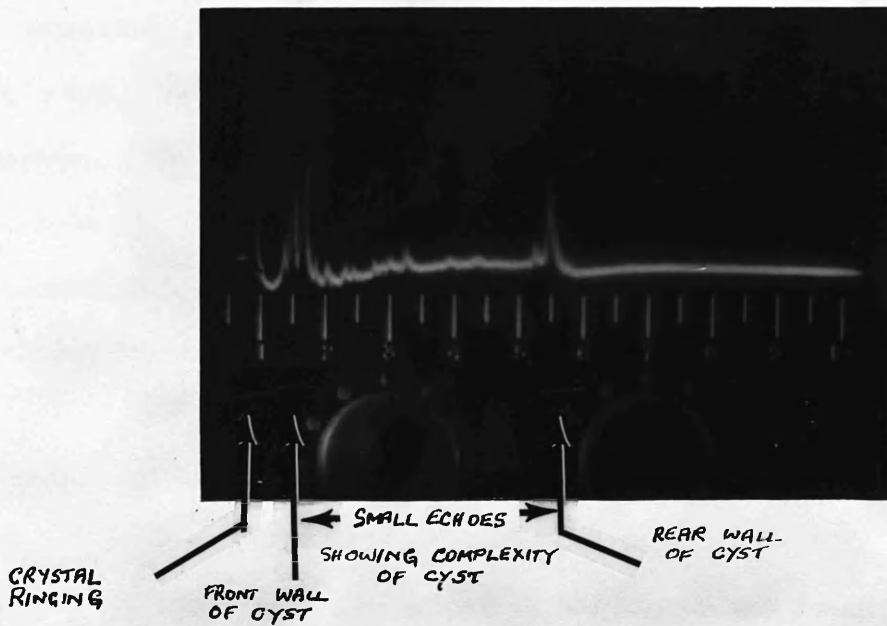


FIG. 7. CASE IV.  
MUCIN SECRETING PAPILLARY ADENOCARCINOMA  
PART SOLID PART CYSTIC TUMOUR  
PROBE OVER RIGHT IMAE FOSSA.

cystic there were several solid areas present within it.

At laparotomy, the diagnosis of malignant ovarian cyst was confirmed. Metastases were present in the peritoneum and omentum. Both ovaries were involved and the whole mass, which was made up of part solid, part cystic and necrotic tissue, was essentially cystic in structure. Histological examination revealed it to be a mucin-secreting papillary adenocarcinoma.

CASE V: Miss May Livingstone, age 26 years, was admitted because of menorrhagia of six months' duration.

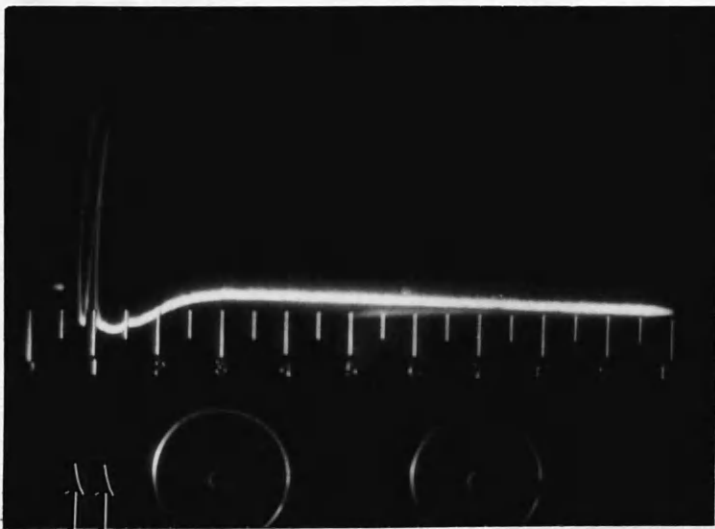
On abdominal and vaginal examination the uterus was found to be enlarged to three inches above the symphysis pubis. The swelling was very hard and regular. Clinical diagnosis of a fibromyoma was made.

On examination with the ultrasonoscope, there was a very marked anterior wall echo, but no evidence of a far wall echo, Fig. 8.

At laparotomy an anterior fundal fibroid was found and myomectomy was performed. The fibromyoma measured about four inches in diameter.

After removal the fibromyoma was tested in the water tank and a similar reflection was obtained from the anterior wall. No posterior wall echo of the tank was seen, Fig. 9. This showed reflection and complete attenuation of the ultrasonic beam.

That a solid fibromyoma should cause such reflection and attenuation seems quite reasonable, but further studies proved that differences/



CRYSTAL  
RINGING

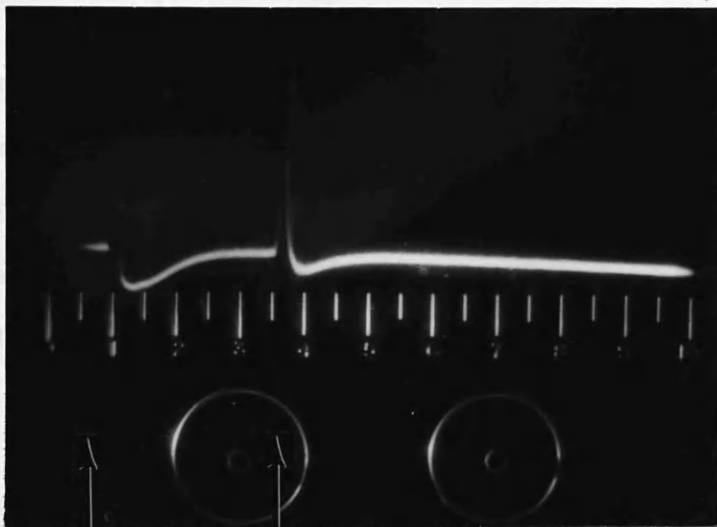
FRONT OF  
FIBROID

FIG. 8.

CASE Y

FIBROMYOMA OF UTERUS

NOTE COMPLETE ATTENUATION.



CRYSTAL  
RINGING

FRONT OF  
FIBROID

FIG. 9. FIBROMYOMA IN WATER TANK AFTER REMOVAL (CASE V)  
NOTE NO ECHO FROM FAR WALL OF TANK.

differences in consistency in a fibromyoma often revealed differences in echo patterns.

This is shown in the following two cases:

CASE VI: Mrs. Jessie Allan, age 43 years, was admitted complaining of right-sided abdominal pain of two years' duration.

On abdominal examination, a mass rising from the pelvis to the level of the umbilicus and lying more to the right side, could be palpated. The mass was smooth, firm and mobile.

A clinical diagnosis of fibromyoma was made.

On ultrasonic examination, Fig. 10, a very diffuse anterior wall echo was noted and in places a small rear wall echo was noted. No echo was obtained as marked as was found from the posterior wall of fluid-filled cysts. A provisional diagnosis of fibromyoma with cystic degeneration was made.

At laparotomy, multiple fibromyomata were found, with one large one present, nine cm. in diameter, on the right. Within this fibroid was a cystic space, five cm. in diameter, which obviously accounted for its ultrasonic properties.

CASE VII: Mrs. Rena Klar, age 48 years, was admitted because of intermittent vaginal bleeding of nine weeks' duration.

On abdominal examination a firm swelling was palpable in the lower abdomen up to the level of three finger-breadths below the umbilicus. On vaginal examination the swelling was thought to be uterine in origin and a diagnosis of fibromyoma was made.

On/



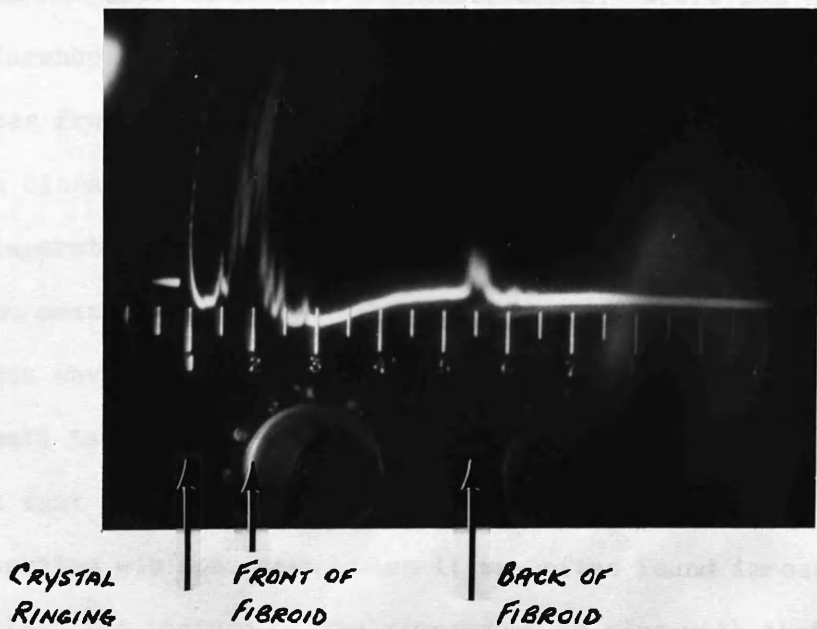


FIG. 10. CASE VI

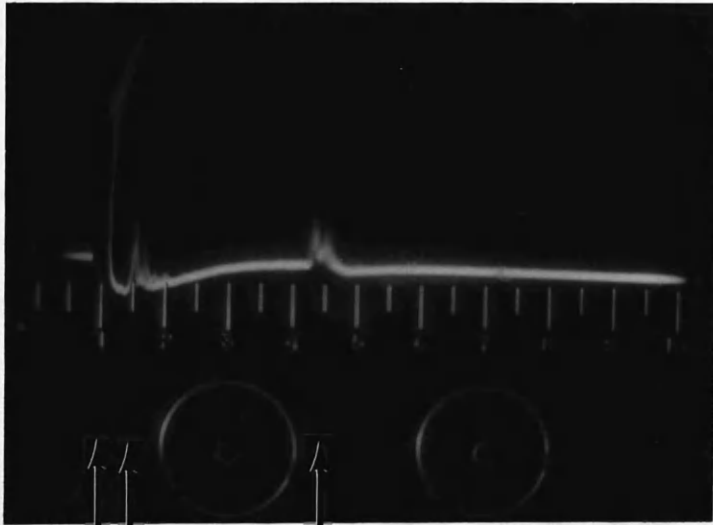
FIBROID WITH CYSTIC DEGENERATION  
PROBE OVER MAIN MASS.

On ultrasonic examination, Fig. 11, a small anterior wall echo was noted and also an echo at a greater depth. There was no obvious difference in magnitude between the echoes. There seemed to be no echoes from within the structure. A diagnosis of cyst was made. This ultrasonic diagnosis was incorrect, since the swelling proved at laparotomy to be a very vascular cervical fibroid. The fibromyoma measured 8 x 10 x 7.5 cm.

It was obvious from Cases VI and VII that the texture of the fibromyomata tended to be the deciding factor in the echo patterns. The fact that the vascularity of a structure altered its ultrasonic properties was soon seen, when it was often found impossible to simulate the picture of the fibromyoma in vivo with that after removal in the experimental water tank.

The most common cystic structure arising from the pelvis is a full bladder and occasionally leads to confusion in gynaecological diagnosis. Figures number 12 and 13 illustrate the ultrasonic picture obtained before and after catheterisation. The pictures were taken in a patient suffering from retention of urine on the third day after a Manchester type of repair operation for uterine prolapse. The bladder contained Forty-two ounces of urine and the posterior wall of the bladder was seen to close up to the anterior wall until the bladder was empty, as seen in Fig. 13.

As described previously, with a tissue/air interface there will be, for practical purposes, complete reflection of ultrasound. On probing over bowel, strong dancing echoes are obtained which, when/



CRYSTAL  
RINGING

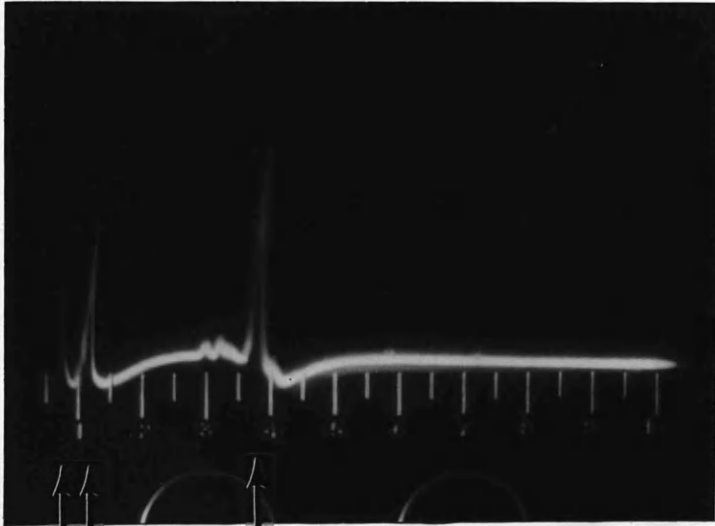
FRONT OF  
FIBROID

BACK OF  
FIBROID

FIG. 11. CASE VII

VASCULAR CERVICAL FIBROID.

INCORRECTLY DIAGNOSED AS CYSTIC.

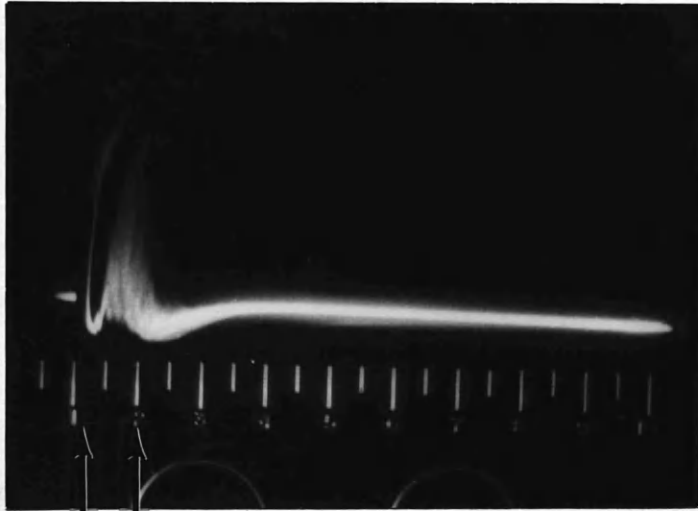


CRYSTAL  
RINGING

ANTERIOR  
WALL OF  
BLADDER

POSTERIOR  
WALL OF  
BLADDER

FIG. 12 FULL BLADDER WITH RETENTION OF URINE  
FOLLOWING MANCHESTER REPAIR.



CRYSTAL  
RINGING

BOWEL


**FIG. 13. SAME PATIENT AS ILLUSTRATED IN FIG. 12  
FOLLOWING CATHETERISATION AND WITHDRAWAL OF 42oz  
OF URINE.  
PROBE ON SUPRAPUBIC REGION.**

when photographed, show one clear echo. This is seen in Fig. 14, which is taken over the descending colon in Case III to the left of the ovarian cyst. It would seem that the dancing reflections are due to peristalsis, since they are much more apparent over small bowel. The most sharp echo is usually obtained over the stomach.

With ascites, coils of intestine will tend to be more spread out and should be at varying depths. When ascites is present, the ultrasonic echoes from bowel tend to appear much more spread out with much deeper penetration. This is shown in Figs. 15 and 17. Both cases had marked ascites, consequent on ovarian carcinoma. In each case, peritoneal metastases had been present at laparotomy. Figs. 16 and 18 show the ultrasonic echo pattern in similar situations after paracentesis of ten and thirteen-and-a-half pints of fluid respectively. It is of note how the echoes close up once the fluid has been removed.

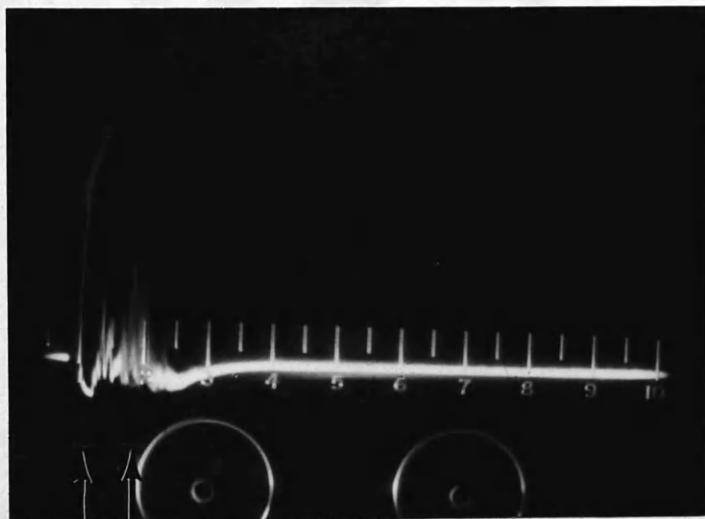
Lesions of the anterior abdominal wall are uncommon, but the following case gave opportunity for study:

CASE VIII: Mr. David Connell, aged 62, was admitted to the Surgical Wards of the Western Infirmary, complaining of pain in the right hypochondrium of 24 hours' duration. After the pain had been present for some time, bruising became apparent about two inches to the right of the midline and three inches below the rib margin. There was no history of injury. A small mass was thought/



CRYSTAL RINGING      BOWEL.

FIG. 14. PROBE OVER DESCENDING COLON  
IN CASE III. COMPARE WITH FIG. 6.

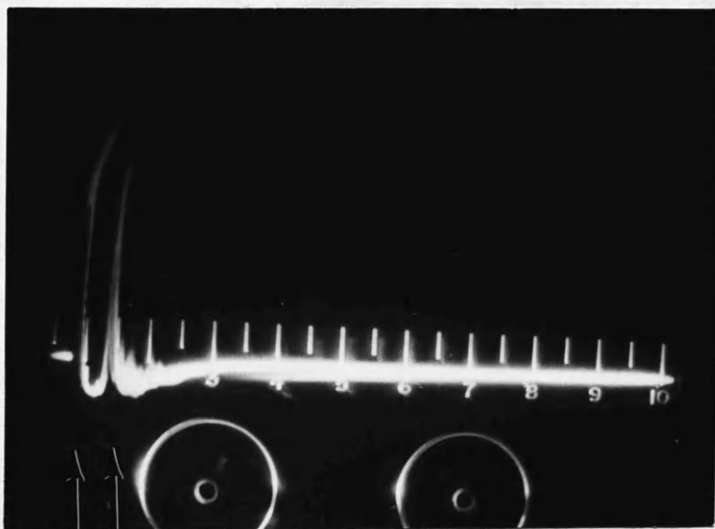


CRYSTAL  
RINGING

DIFFUSE BOWEL  
ECHOES

FIG. 15 CASE OF OYARIAN CARCINOMA WITH ASCITES.  
PROBE SUBUMBILICAL.






CRYSTAL  
RINGING

BOWEL

FIG. 16. SAME CASE AS FIG. 15 FOLLOWING PARACENTESIS  
OF 10 PINTS FLUID.

NOTE SHARPER BOWEL ECHO.

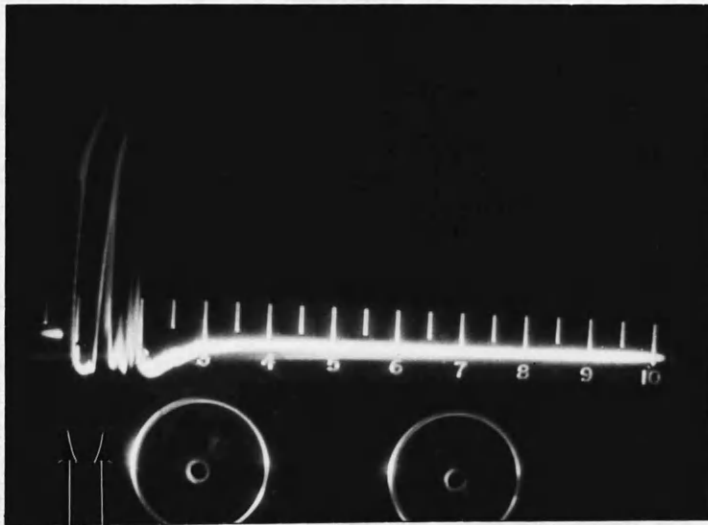


CRYSTAL  
RINGING

BOWEL  
ECHOES

BOWEL  
ECHOES

FIG. 17. CASE OF OVARIAN CARCINOMA WITH ASCITES.  
NOTE BOWEL ECHOES ARE SPREAD OUT.  
PROBE OVER RIGHT ILIAC FOSSA.



CRYSTAL RINGING | BOWEL ECHOES

**FIG. 18.** SAME CASE AS FIG. 17 FOLLOWING PARACENTESIS OF 13½ PINTS OF FLUID. BOWEL ECHOES STILL SLIGHTLY DIFFUSE INDICATING RESIDUAL FLUID.

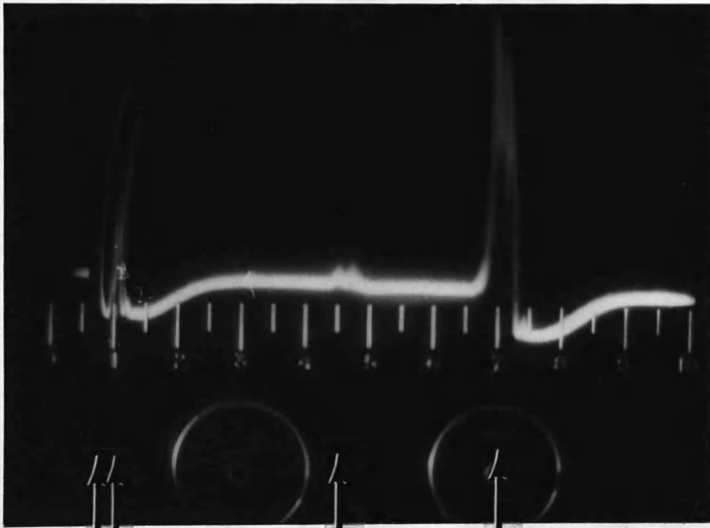
thought to be palpable in this region. A diagnosis of mucocoele of the gallbladder, or haematoma of the anterior abdominal wall, was made. On ultrasonic examination over the affected area, Fig. 19, echoes were detected between the echo of the ringing crystal and the sharp echo from bowel. The bowel was not displaced deeply and so the echoes must arise from the anterior abdominal wall. This was indicative of a diagnosis of haematoma and such was proved at laparotomy.

A number of pregnant patients were also investigated. Echoes in this type of case were difficult to interpret because of echoes from foetal parts. Where much liquor amnii is present, compared with the size of the foetus, more definite detail could be made out.

CASE IX: Mrs. Agnes McClure, aged 34 years, having had two previous normal pregnancies, was admitted to the Royal Maternity Hospital at 36 weeks' gestation, with marked hydramnios. Her girth at umbilical level was 42 inches. X-ray examination revealed an anencephalic foetus.

Fig. 20, shows the ultrasonic examination from the left side at the level of the umbilicus across the uterus. The left-side wall of the uterus is clearly seen, as also is the right far wall. A small echo, due to foetal parts, is seen which causes little attenuation of the ultrasonic beam. Fig. 21, in contrast, taken from the right side and obliquely through the uterus, shows a more marked/





CRYSTAL  
RINGING

LEFTSIDE  
OF UTERUS

FOETAL  
PARTS

RIGHT SIDE  
OF UTERUS

FIG. 20. CASE IX

HYDRAMNIOS

NOTE LARGE CYSTIC SPACE ACROSS THE UTERUS  
PROBE ON LEFT SIDE.

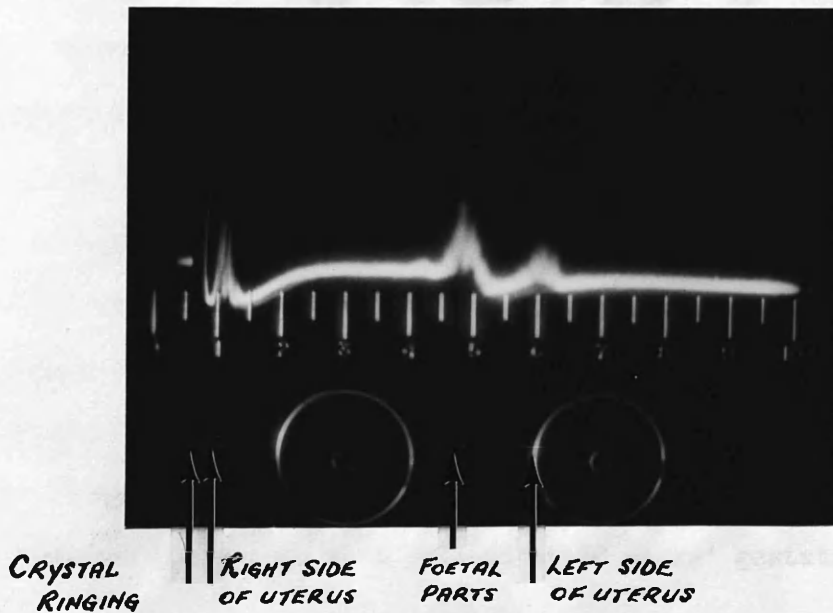


FIG. 21. CASE IX

HYDRAMNIOS.

PROBE ON RIGHT SIDE AND DIRECTED OBLIQUELY THROUGH UTERUS. NOTE MORE OBYIOUS ECHO FOETAL PARTS. COMPARE WITH FIG. 20.

marked echo from the foetus, with a consequent smaller echo from the other side of the uterus.

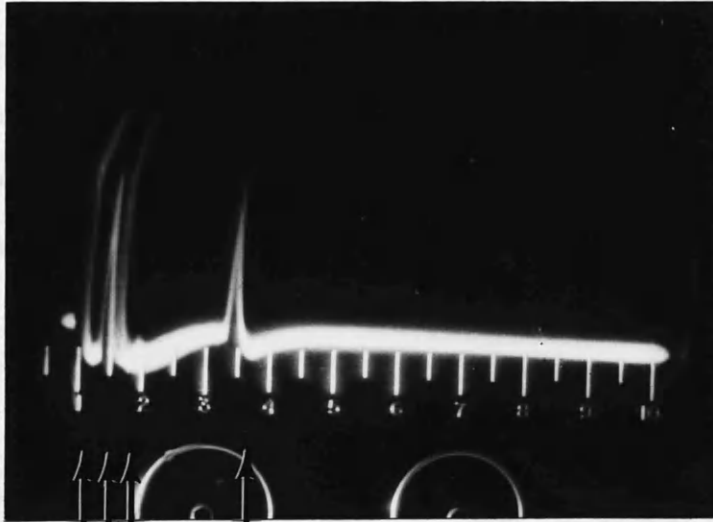
The foetal skull itself gave much more distinct echoes and diagnosis as to where the skull lay was easy. This often proved of value in differentiating breech presentation from vertex presentation, if there was any clinical doubt. Fig. 22 illustrates such a case. The echoes seen after the crystal ringing are probably from anterior wall of uterus, the side of the skull anteriorly and the last echo a combination of far wall of skull and uterus. The picture was taken suprapubically over the lower segment of the uterus in a patient at 38 weeks' gestation.

Attempts to visualise echoes from the placenta have proved disappointing, although retroplacental blood clot has been visualised.

CASE X: Mrs. Wary Watson, aged 34 years, was admitted to the Royal Maternity Hospital at 36 weeks' gestation, having had bleeding and abdominal pain of two hours' duration. She gave a history of two previous pregnancies, each complicated by accidental haemorrhages and consequent stillbirths.

On examination the uterus was the size of a 38 weeks' pregnancy and was firm and tense. The foetal heart, however, was audible. It was decided to perform Caesarean section, and ultrasonic examination was performed just prior to operation. In the right iliaç





CRYSTAL  
RINGING.

FOETAL  
SKULL.

FRONT WALL  
OF UTERUS.

BACK WALL OF UTERUS  
OR FOETAL SKULL.

FIG. 22 PROBE SUPRA PUBIC PATIENT 38 WEEKS PREGNANT.  
VERTEX PRESENTATION.

iliac-fossa, instead of a sharp echo from the uterine wall, a rather diffuse echo was seen, Fig. 23. This was thought to be due to retroplacental blood clot. At operation a large retroplacental clot (20 oz.) was present, and the placenta was lying in the upper segment to the right side and anteriorly. The clot was present in the area suspected on ultrasonic examination. The baby, who on this occasion was born alive, unfortunately died 24 hours later.

Using 'A'-scope presentation in the Mark IV Flaw Detector, a total of about fifty patients were examined, of whom one-hundred & sixty-five pictorial records are available. These include comparisons of tumours in vivo and in the experimental water tank. From this work it can be seen that the value of the examination was limited, because only one very small area was under examination at one time. A composite picture of an abdominal mass could not be obtained, and also mistakes had been made, due to distortion of echoes. By rotation of the probe, differing echoes could be obtained. It was obvious that a more elaborate machine was necessary for better results.

During the investigations varying frequency quartz crystals had been used. Initially it seemed that for best resolution and penetration two-and-a-half megacycles per second was most suitable. A barium titanate crystal, with a natural frequency resonance of two-and-a-half megacycles, was later obtained. This probe seemed/

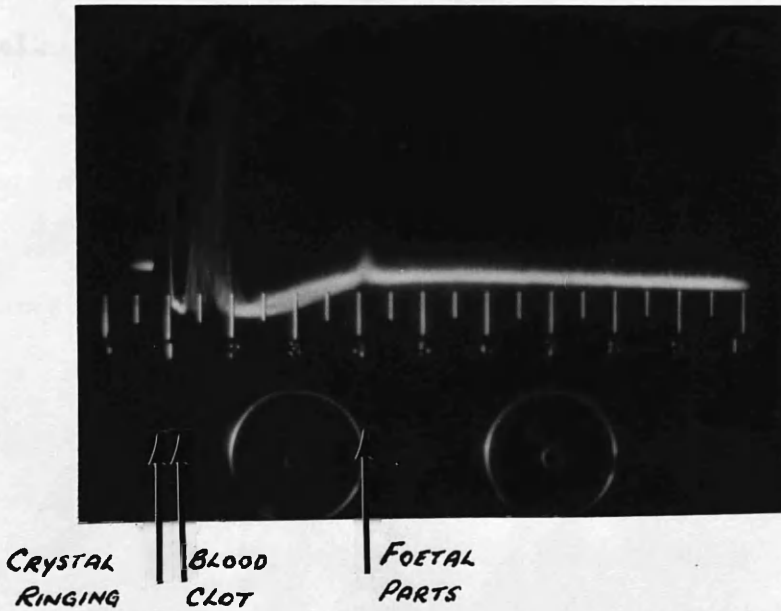


FIG. 23. CASE 7

ACCIDENTAL HAEMORRHAGE

PROBE OVER RIGHT ILIAC FOSSA DIRECTED POSTERIORLY.

seemed to give clearer definition and similar resolution and penetration, so that it was used in preference to the quartz crystal.

TWO-DIMENSIONAL PRESENTATION.

At this point in the investigation it was obvious that an improved presentation was required. The ideal presentation visualised was one that would be able to outline the tumour mass and also indicate the relationship between the abdominal mass and its surrounding structures.

'B'-scope display, whereby the probe direction is kept constant and the area is scanned by moving the probe sideways along a line at right angles to the direction of propagation, seemed to be an advance on static 'A'-scope presentation. A sensing device measures the movement of the probe and the display on the Cathode-ray tube is made to follow the probe movement. By removing the base-line of 'A'-scope presentation and instead of amplitude modulation deflections from the base-line representing echoes these be represented by varying brightness of a spot on the Cathode-ray tube, a composite picture of the area being scanned may be built up on a long persistence screen or on a photographic plate. Various adaptations of this presentation had been used previously. Wild and Reid (1955) had used a hand-held instrument, in which a propagating crystal scanned to and fro within an elliptical water chamber over a 6.5 cm. range of movement. Other methods employed by Howry (1955) and Kikutchi (1957) had the subject immersed in a water tank and the probe either moved across the surface of the water or moved in a circle round the patient, with its beam directed radially inwards.

In contrast, if the probe is made to rotate about a fixed point in or near the area being scanned and the time-base sweep caused to follow the angular movement of the probe originating from a fixed point on or off the face of the Cathode-ray tube, a radial scan or Plan-Position-Indicator (P.P.I.) is obtained.

Neither of the above two types of display seemed sufficient by itself to produce a satisfactory echo pattern of a deep seated structure within the body. Since echoes are only detected by the receiving crystal if the reflecting surfaces from which they originate are at right angles to the incident energy beam, the inadequacy of the 'B'-scope and P.P.I. displays can be visualised. A combination of the two displays seemed to meet the presentation visualised and so it was decided to attempt to produce a scanning and plotting mechanism which, as far as possible, would make each individual part of the surface of an object under examination to be scanned by the ultrasonic beam from a large number of different angles, all, however, lying in the plane of the cross-section to be represented. By this means, the composite picture would be a cross-sectional view of the part of the abdomen examined and reflecting surfaces, no matter how curved they were in the plane of the cross-section, would appear as continuous lines, as long as they were not greatly angled to the beam in the third dimension. In other words, the cross-sectional view of the part examined was obtained by registering echoes in the one picture from as many angles as possible, and indicating simultaneously not only the/

the echoes and their strength but also the position of the probe and hence the angle of the incident beam. The longest persistence Cathode-ray tube would, however, be of insufficient duration to visualise a complete scan at once, but a scan could easily be photographed if the film be continuously exposed during the taking of the scan. A similar type of fixed focus 35 mm. camera as used on the flaw detector was sufficient. The apparatus was designed and manufactured by Kelvin and Hughes Ltd., and the general principles are described below.

The apparatus for Two-Dimensional Scanning.

A probe, containing both transmitting and receiving transducers, is mounted on a measuring jig which was built on rails running along a standard hospital bed table. The probe is accordingly free to move vertically and horizontally, but as it does so it operates two linear potentiometers, which give voltage outputs proportional to its horizontal and vertical displacement from some particular point. The probe is also free to rotate about a spindle through about  $\pm 110^\circ$  from the downwards direction in the plane of its horizontal and vertical freedom. This probe spindle is coupled to a sine-cosine potentiometer.

The voltage outputs from the three potentiometers control an electrostatic Cathode-ray tube, so that the direction of the linear time-base sweep corresponds to the inclination of the probe, and the point of origin of the sweep represents the instantaneous position of the probe. The apparatus is also so calibrated that the same/

same reflecting point will repeat itself in exactly the same position on the Cathode-ray tube screen from whatever angle it is scanned, and likewise a planar interface comes to be represented as a consistent line.

Three different Cathode-ray tubes are connected to the apparatus; one is 'A'-scope presentation; and two combined 'B'-scope and P.P.I. displays - one a long persistence screen for monitoring use and a short persistence display with the camera attachment. (See Fig. 24).

In the probe two separate barium titanate crystals are used - one for receiving and one as the transmitter (For a close up of such a probe see Fig. 25). Each is a rectangle 10 mm. x 7 mm. and are placed with their 7 mm. sides adjacent. The dimensions were chosen empirically as giving the best compromise between beam divergences and beam diameter in water over the range of distances required.

The transducers lie on a conducting layer on a one-inch thick perspex block, the opposite side of which is the face of the probe. The transmitting transducer is "air-backed" and is damped by an electrical resistance and by radiation resistance of the perspex block on which it rests. The transmitting transducer is pulsed fifty times per second and rings at its resonant frequency of  $2\frac{1}{2}$  megacycles per second. For this frequency the crystal thickness requires to be about 1 mm. thick. The pulse length is approximately three microseconds in this time having lost 90% power. The maximum power is reached after 0.3 microseconds and thereafter decays exponentially. The transmitting crystal is electrically excited by using a 100/




100 pico-farad capacitor which is charged to approximately 1400 volts through a high resistance and then discharged by a thyatron through the primary winding of a pulse transformer. The power output of such a machine had to be carefully considered. Much energy is dissipated in such things as the transmitting capacitor, the thyatron, the pulse transformer and the connecting leads before the power reaches the transducer and thereafter further loss is experienced in the inefficiency of the transducer, the transmission co-efficient at the barium titanate/perspex interface and the perspex/skin interface, as well as attenuation in the perspex itself.

Accordingly, the efficiency of the machine as a whole is not high, and at any rate the maximum energy could not exceed  $0.5 \times 10^{-4}$  joules per pulse, and is probably less than  $0.2 \times 10^{-4}$  joules. This last figure is equivalent to less than 1.5 milliwatts per sq. cm. as the power actually delivered at the body surface. Since the size of the crystal is 10 x 7 mm. the actual surface irradiated at any one time is 0.7 sq. cm. and consequently the total power is approximately one milliwatt per sq. cm. This, then, is the maximum power to which living tissue is subjected and is low when compared with the power quoted in the section on 'Harmful Effects of Ultrasound', but in order to make sure that cellular damage could not be caused, it was decided to test the apparatus on living tissue.



1. LONG PERSISTENCE C.R.T. FOR MONITORING.
2. A-SCOPE PRESENTATION C.R.T.
3. 35 M.M. CAMERA ATTACHMENT.
4. C.R.T. FOR PHOTOGRAPHY.

FIG. 24. LAY OUT OF THE THREE CATHODE RAY TUBES  
AS USED IN THE APPARATUS FOR TWO DIMENSIONAL  
SCANNING.



*Fig.25. CLOSE UP OF PROBE CONTAINING BARIUM TITANATE CRYSTALS.*

Experiments to Ascertain Harmful Effects:

In consultation with Dr. Bacsich of the Department of Anatomy of Glasgow University it was decided that the brain of a newborn kitten would be the most suitable for experiment, especially since myelination of the optic tracts had not taken place, and that any susceptibility to damage was greater.

Under the direction of Dr. Bacsich the following experiments were carried out.

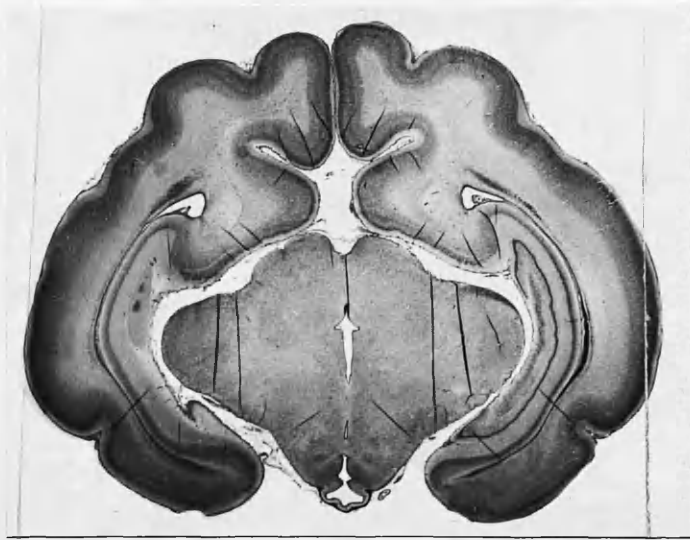Two burette stands were used to mount the probes, each of similar type to the one used in the apparatus. The probes were firmly held in the horizontal arm of the burette stand. The one probe was connected in normal fashion to the Mark IV Flaw Detector while the other remained unconnected and was used as the control. Four two-days old kittens were used. Each was anaesthetised by using intraperitoneal pentobarbitone sodium, and placed with the head resting on the base of the burette stand. The scalp was then covered with olive oil to assure acoustic coupling, and the probes were lowered by means of the horizontal arms until the probes just touched the left temporo-parietal region. Acoustic coupling was continuously checked by viewing the Cathode-ray tube of the 'A'-scope presentation, but pressure on the skull was avoided in all cases. Each kitten received treatment for one hour. In all, two kittens were irradiated with ultrasound and two merely 'controls'. Within eight to ten hours after initial anaesthesia all of the kittens had fully recovered consciousness and were returned to their mother. They all immediately fed well.

Twenty-four hours later one irradiated and one 'control' kitten were killed. Three weeks later the other two kittens were killed also, but during the first three weeks note was taken of their development. The irradiated kitten seemed in fact to develop faster than the 'control' kitten. It showed a better weight gain, its eyes opened earlier and it left the mother's basket two days sooner. The kittens were all killed by coal gas and their brains immediately removed and fixed in a 10% aqueous solution of formalin for three days. Thereafter the four brains were embedded in colloidin-paraffin and sectioned in the coronal plane. Four different sets of sections were made and stained with haemalum and eosin, toluidine-blue, a modified 'Protargol' method and a modified Weigert method respectively. The brains were sectioned in the following manner. Three 10 $\mu$  and one 20 $\mu$  sections were cut, the next forty-five 10 $\mu$  sections were discarded and again three 10 $\mu$  and one 20 $\mu$  sections were cut. This process was repeated until the whole brain was sectioned. By this means, any lesion greater than 450 $\mu$  would be discernible.

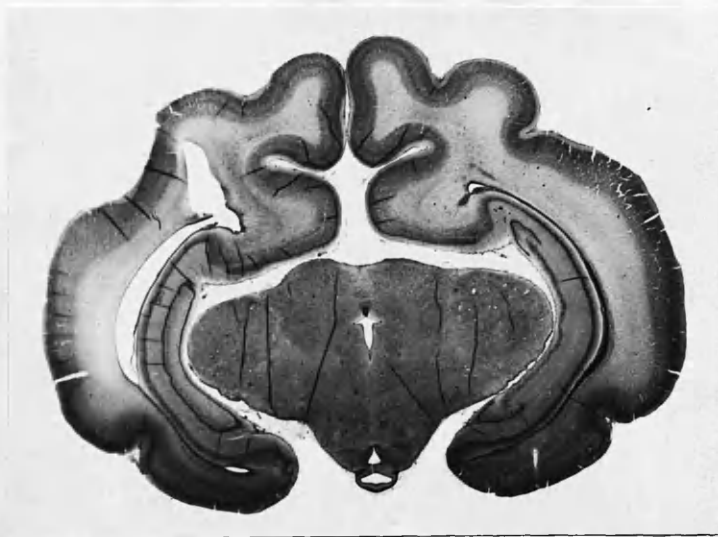
On examination microscopically no abnormality was seen either in the irradiated brains or in the controls. The brains were comparable in every way. In the kittens killed after twenty-four hours special attention was paid for any signs of coagulative necrosis, localised hyperaemia, haemorrhages and chromatolysis, and in the three-weeks old ones for cell destruction, neuroglial formation axon degeneration and localised lack of myelination.

Four examples of the microscopic examination of the kittens' brains are shown in Figs. 26- 29.

Following these experiments the apparatus was deemed to be safe for clinical use, since the kittens had been irradiated for at least twenty-five times longer than any patient was likely to be, and that in one particular spot without movement of the crystal.



*FIG. 26* CROSS SECTION OF KITTEN'S BRAIN IN REGION  
OF DIENCEPHALON.  
TREATED KITTEN KILLED AT 24 HOURS  
HAEMALUM AND EOSIN STAIN  
MAGNIFICATION 4.7X



*FIG. 27 CROSS SECTION OF KITTEN'S BRAIN IN REGION  
OF DIENCEPHALON.  
"CONTROL" KITTEN KILLED AT 24 HOURS  
HAEMALUM AND EOSIN STAIN  
MAGNIFICATION 4.7 X*



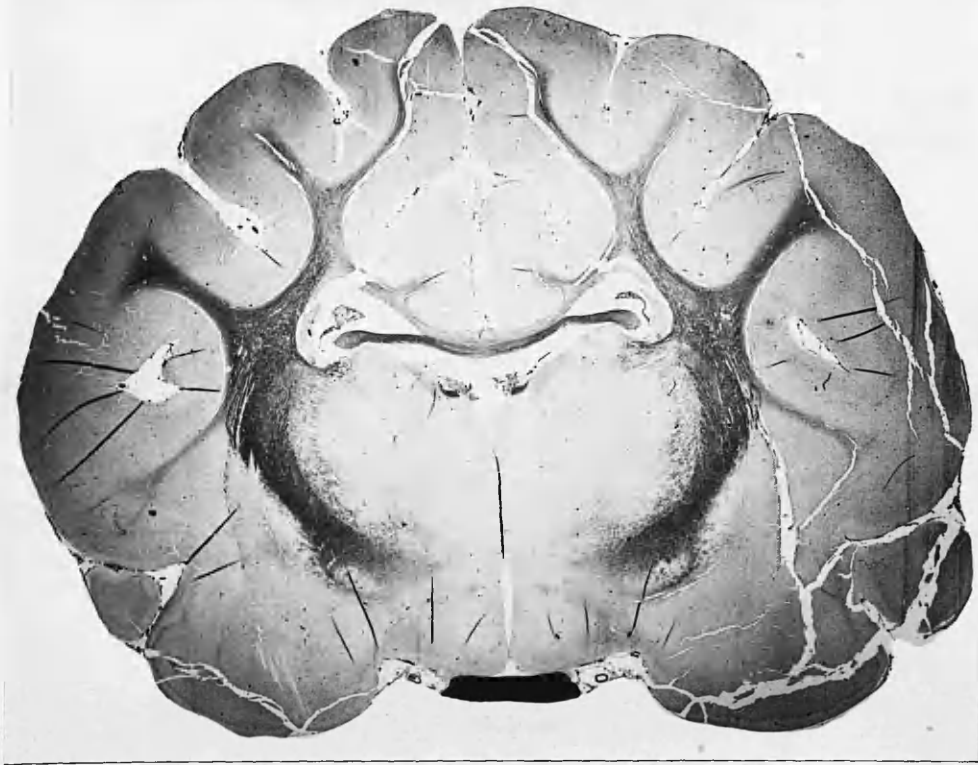
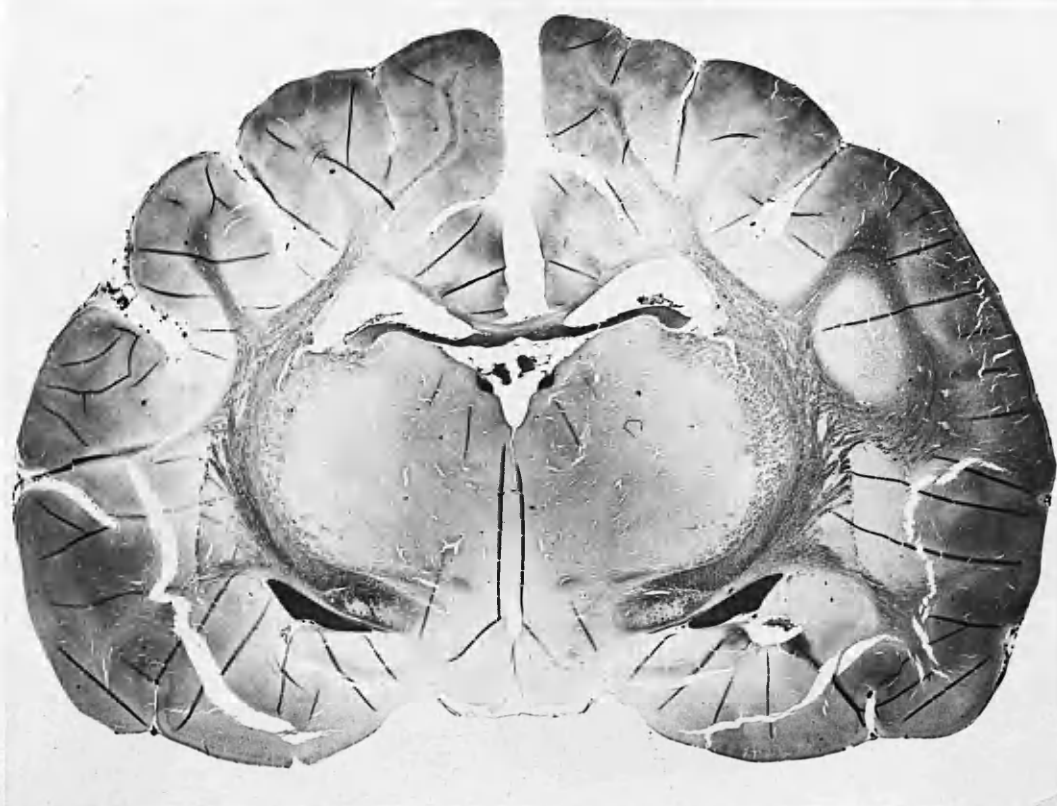

FIG. 28 CROSS SECTION OF KITTEN'S BRAIN IN REGION OF DIENCEPHALON.  
"TREATED" KITTEN KILLED AFTER 3 WEEKS.  
HAEMALUM AND EOSIN STAIN.  
MAGNIFICATION 4.7X.



*Fig. 29*    *CROSS SECTION OF KITTEN'S BRAIN IN REGION OF DIENCEPHALON.*  
*CONTROL KITTEN KILLED AFTER 3 WEEKS.*  
*HAEMALUM AND EOSIN STAIN.*  
*MAGNIFICATION    4.7 X.*

METHOD OF OPERATING APPARATUS.

The method of use clinically was, initially, a matter of trial and error. The part to be examined is generously covered with olive oil. To obtain a cross section of a part, the probe is set to the lowest available point on one side and with rotation of the probe through about an angle of 45 degrees on its spindle, and by keeping the probe in contact with the patient's skin, the vertical and horizontal components of the apparatus come into play as the part is traversed until the lowest available point on the opposite side is reached. Care must be taken to centre the probe before taking a scan, to make sure the position on the cathode-ray tube is also central. The camera shutter is only opened when the scan begins and closed as it ends. The time taken over the building up of the cross section varies naturally with its size and this was found, as far as abdominal work was concerned, to range between 90 secs. and three minutes. Each rotation of the probe should take about two to three seconds and the whole part will be viewed from at least thirty different angles, each of which will overlap due to the probe rotation and so give a composite picture. A schematic representation is shown in Fig. 30.

The bed table on which the apparatus is mounted is easily wheeled over a bed, but a fixed examination couch was more suitable, since as far as possible the complete apparatus was not transported. The apparatus in use is shown in Figs. 31 and 32.

No patient ever complained of discomfort during the examination.

The 'A'-scope was useful for 'spot' diagnosis with simple 'stills'. The picture on the monitoring tube was often sufficiently clear-cut to hazard a diagnosis, but developing of the photographic record was the surest method for a complete diagnosis.

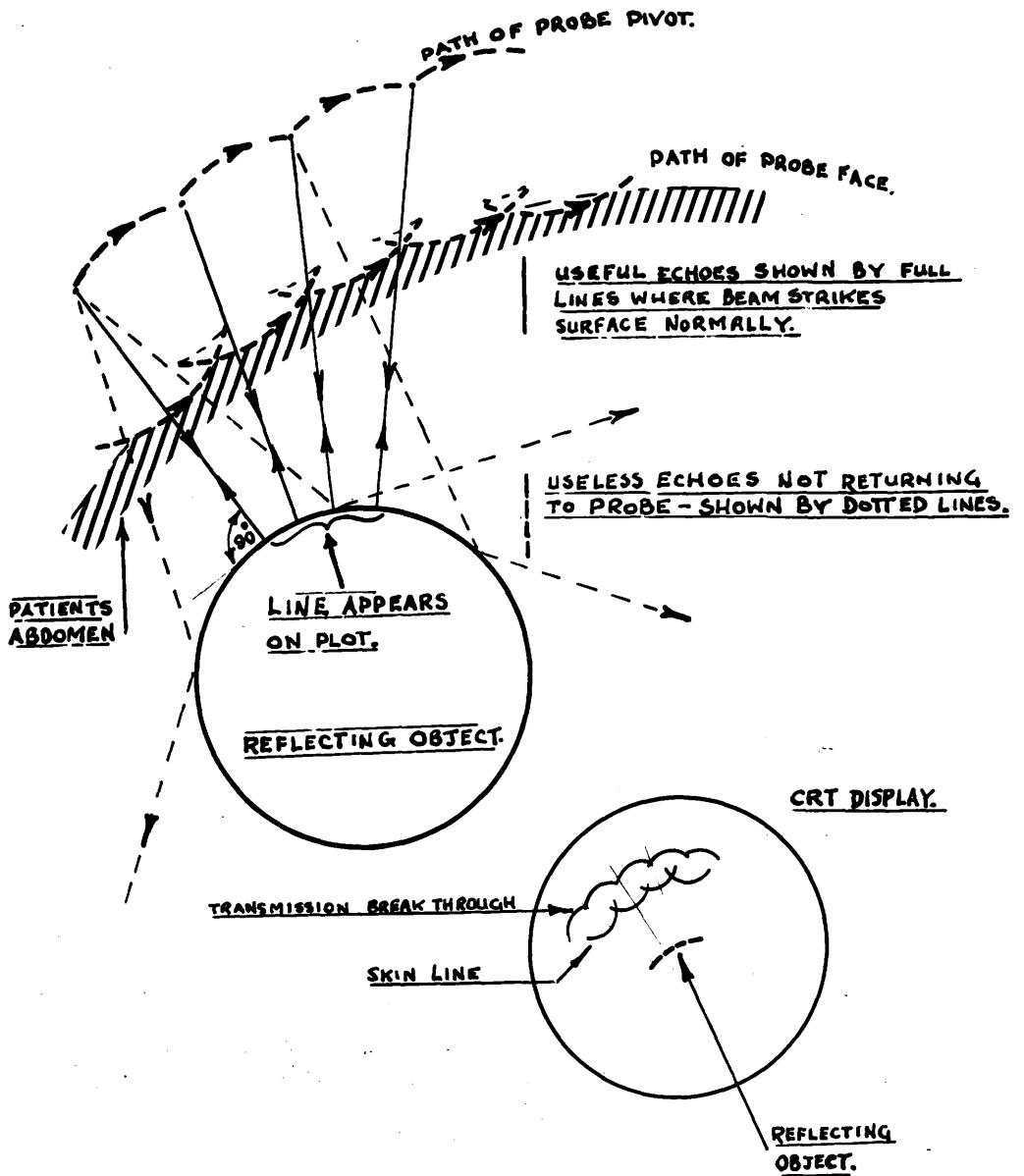


FIG. 30.



*FIG. 31 TWO DIMENSIONAL SCANNING APPARATUS IN USE.*

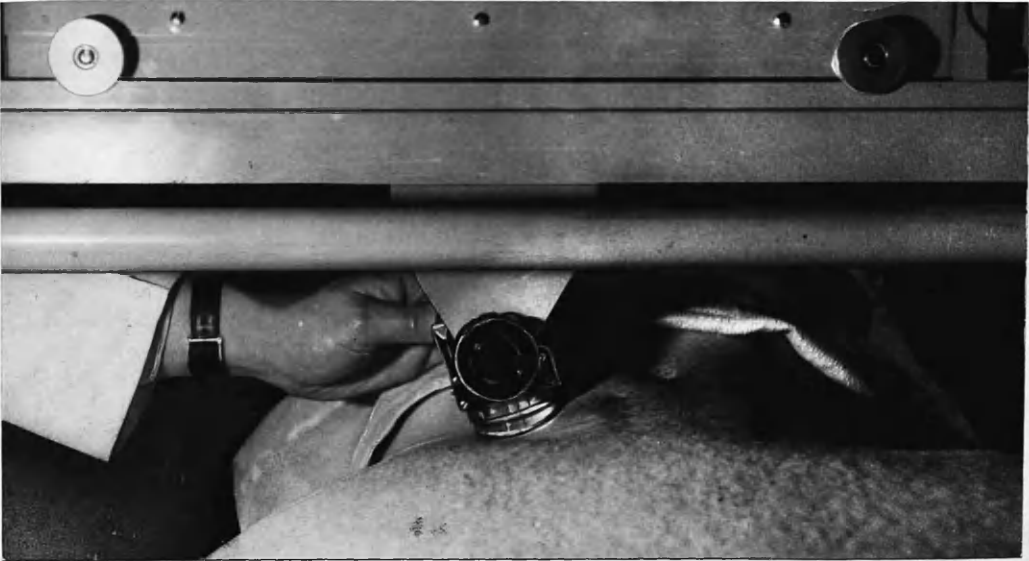


FIG. 32. CLOSE-UP OF PROBE APPLIED TO PATIENT'S ABDOMEN WHEN SCANNING IS TAKING PLACE.

RESULTS OF SCANNING TECHNIQUE.

Normal anatomy was investigated as shown in Figs. 33 and 34.

Fig. 33 is a transverse section of the right thigh taken at a level three inches above the patella. The femur can be visualised by its denser outline, whereas the large muscle bellies on the right appear much clearer. This also shows how erratic scanning can sometimes leave 'gaps' in the composite picture. It is particularly obvious at the upper margin of the femur. Fig. 34 is a scan in the neck, taken from the posterior aspect. From above down the denser area is the spinal cord, the subjacent clear area the oesophagus and, finally, the trachea. The sharp outline of the latter is due to its contained air. A normal abdomen is shown in Fig. 35. This was taken at umbilical level. The first continuous line is the crystal ringing. There follow two continuous signals arising from layers of the abdominal wall. The bowel echoes, being inconstant, are a haphazard collection. Fig. 36 illustrates these differing layers on a time-position scan, similar to those taken by the Japanese workers. The crystal was placed, stationary, over the abdomen and the horizontal shift on the cathode-ray tube was moved. The layers of the abdominal wall are probably subcutaneous tissue and muscle layer interface and the muscle layer and peritoneal interface.

As with 'A'-scope presentation, application of the new apparatus to cystic cavities gave the best results. The following cases and their ultrasonic pictures illustrate the differing cysts examined.



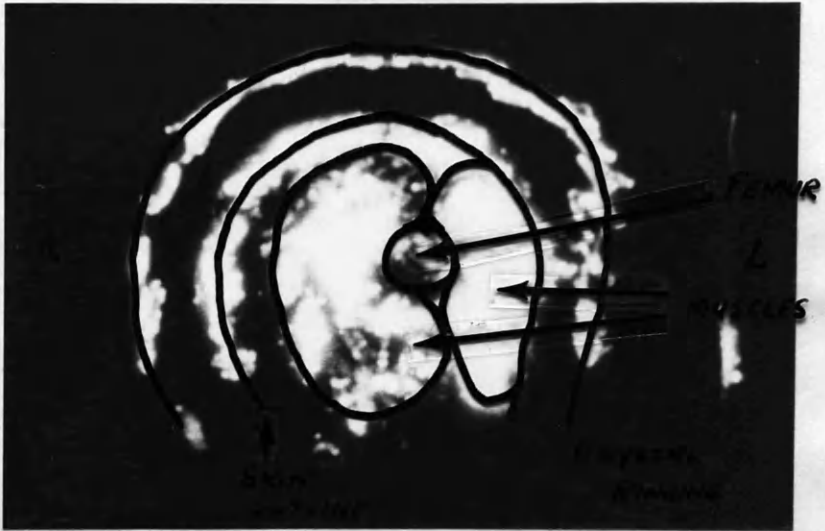


FIG 33. CROSS SECTION OF RIGHT THIGH  
THREE INCHES ABOVE THE PATELLA.

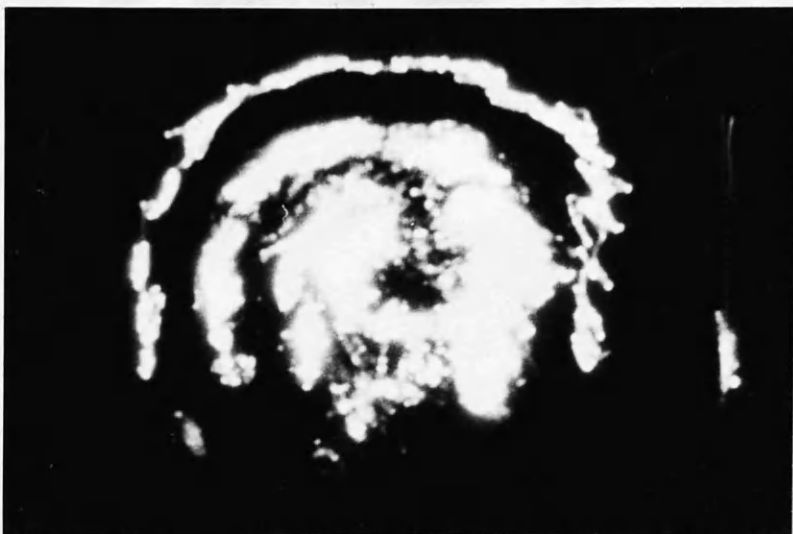


FIG 33. CROSS SECTION OF RIGHT THIGH  
THREE INCHES ABOVE THE PATELLA.

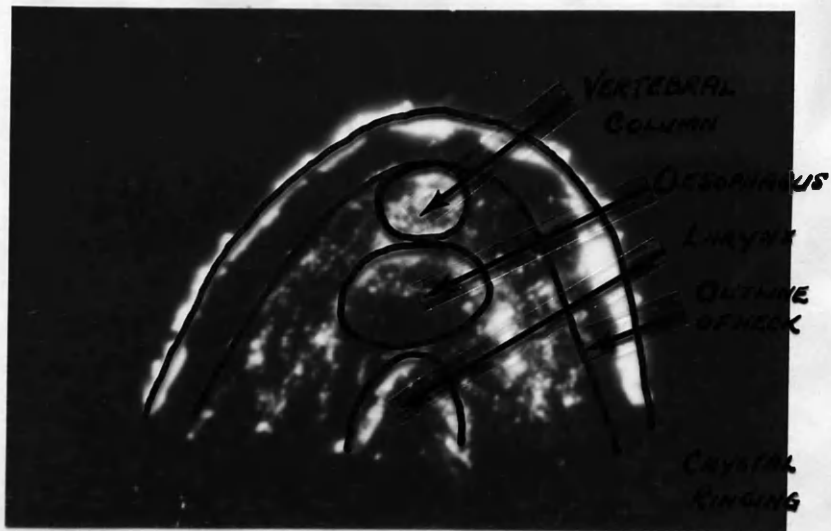


FIG. 34. SCAN OF POSTERIOR ASPECT OF NECK.

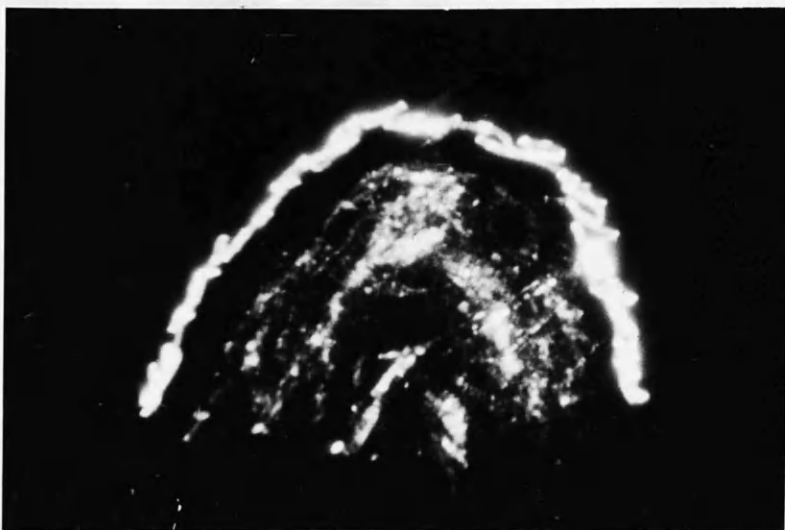


FIG. 34. SCAN OF POSTERIOR ASPECT OF NECK.

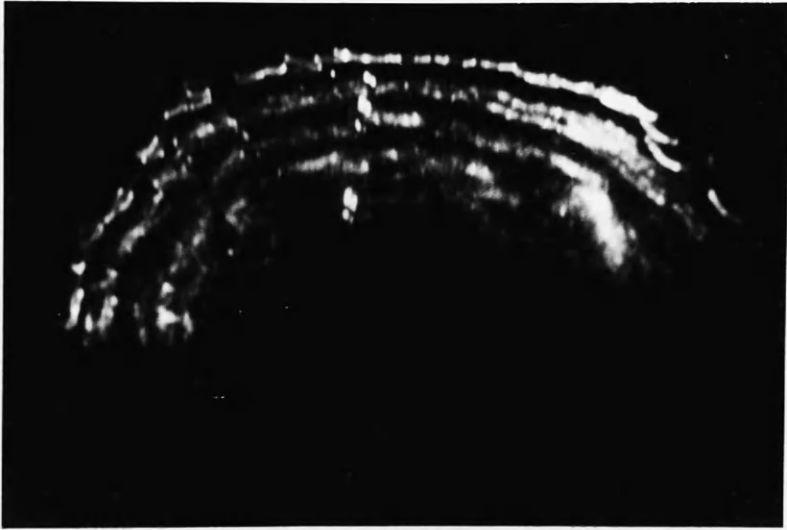


FIG 35. NORMAL ABDOMEN  
FOR DESCRIPTION SEE TEXT  
COMPARE WITH FIG 36.




FIG. 36. TIME - POSITION SCAN OF  
ABDOMINAL WALL  
NOTE DIFFERENT LAYERS AND  
COMPARE WITH FIG 35.

100  
Case No. XI: Mrs. Christina Bennett, aged 33 years, was

admitted with the complaint of lumbar pain of several months' duration. There was no menstrual upset.

On examination, a smooth cystic swelling was present rising to midway between symphysis pubis and umbilicus. On vaginal examination the cyst was lying anterior to the uterus and seemed very superficial.

The ultrasonic examination is shown in Fig. 37. The swelling was obviously cystic, with bowel surrounding it posteriorly. At laparotomy these findings were confirmed - the cyst being a simple unilocular cyst arising from the right ovary.

Case No. XII: Miss Margaret Hall, aged 51 years, was admitted complaining of abdominal distension of four months' duration.

On abdominal examination a firm swelling was present to the level of the umbilicus. Vaginal examination was unsatisfactory, due to the patient being virgo intacta.

Ultrasonic examination, Fig. 38, showed the swelling to be cystic and to be lying much more to the right than the left side. The picture was taken at a level two inches suprapubic. At laparotomy a broad ligament cyst was present on the right side measuring 16 x 18 x 12 cms. The cyst was simple and unilocular. Total hysterectomy and bilateral salpingo-oophorectomy were performed.

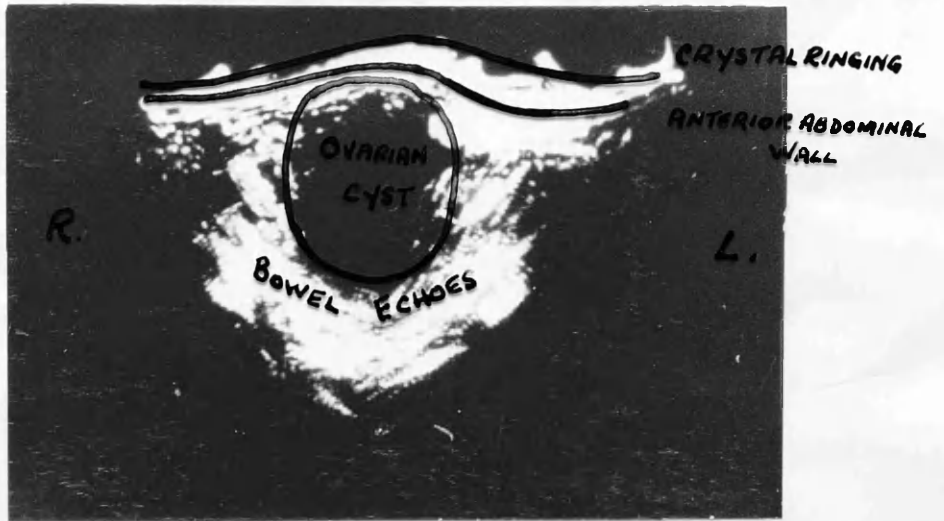


FIG 37. SIMPLE UNILOCULAR OVARIAN CYST  
CASE XI.



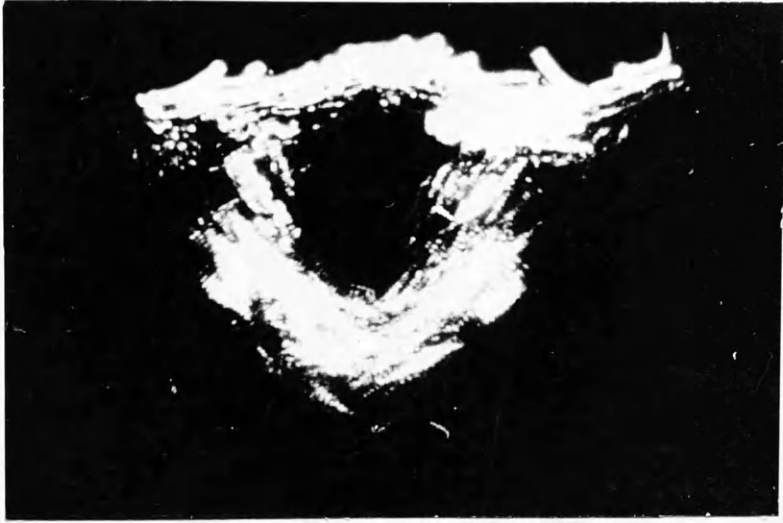

FIG 37. SIMPLE UNILOCULAR OVARIAN CYST  
CASE XI.

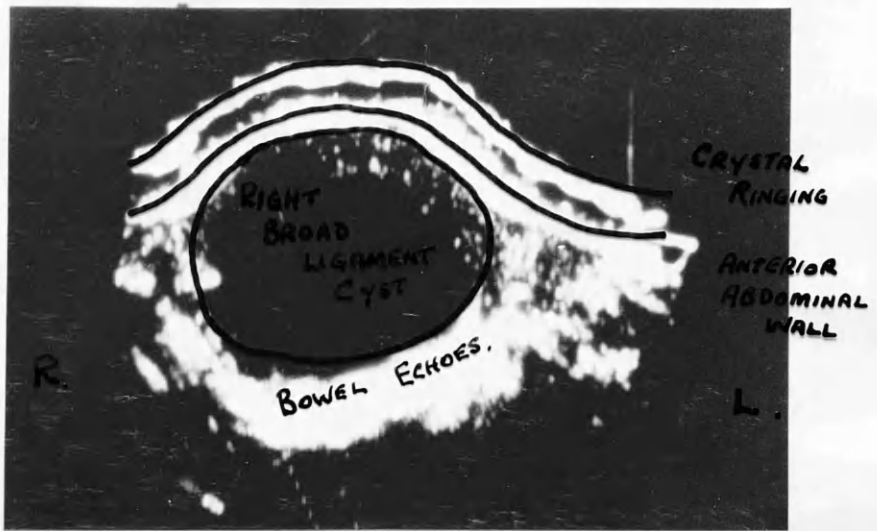


FIG 38. RIGHT BROAD LIGAMENT CYST  
CASE XII.

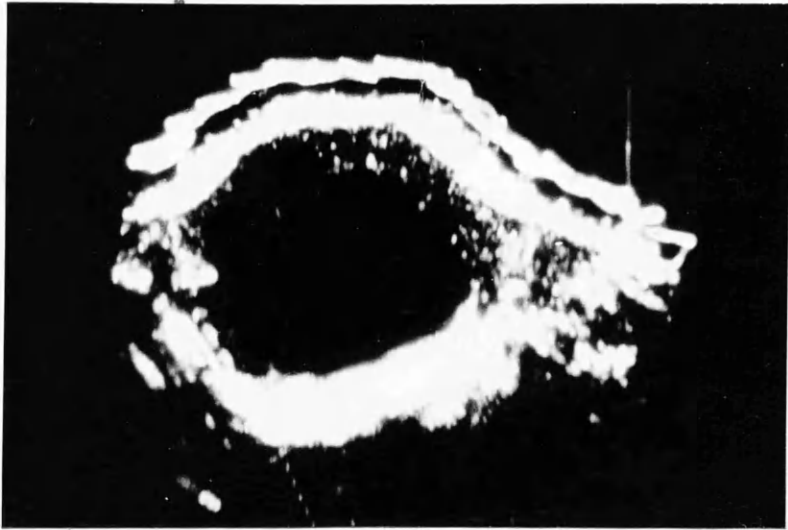

FIG 38. RIGHT BROAD LIGAMENT CYST  
CASE XII.

Case No. XIII: Mrs. Mary Brackenridge, Aged 55 years, had a complaint of increasing lower abdominal swelling of four months' duration.

On abdominal examination a solid swelling was present, the size of a thirty-two weeks' pregnancy. A clinical diagnosis of fibromyoma or ovarian cyst was made.

Examination with the ultrasonic apparatus showed that the swelling was cystic. The cyst was obviously large and the posterior wall could be seen to be indented by the vertebral column. Fig. 39 shows examination in the supra-umbilical region. A simple unilocular cyst was found at operation. Bowel was adherent posteriorly, which gave the sharp echoes behind the cyst. Total hysterectomy and bilateral salpingo-oophorectomy were performed.

Case No. XIV: Mrs. Mary Gilfeathers, aged 61 years, was admitted because of pain in the left thigh of several months' duration. She was said by her general practitioner to have massive ascites. She would not admit to increasing abdominal swelling.

On clinical examination she was found to have a cystic swelling from symphysis pubis to xiphisternum. Ultrasonic examination (Fig. 40) confirmed the swelling to be purely cystic, although of very large proportions.

At laparotomy the cyst was found to be arising from the left ovary and had undergone slight torsion. Total hysterectomy and bilateral/

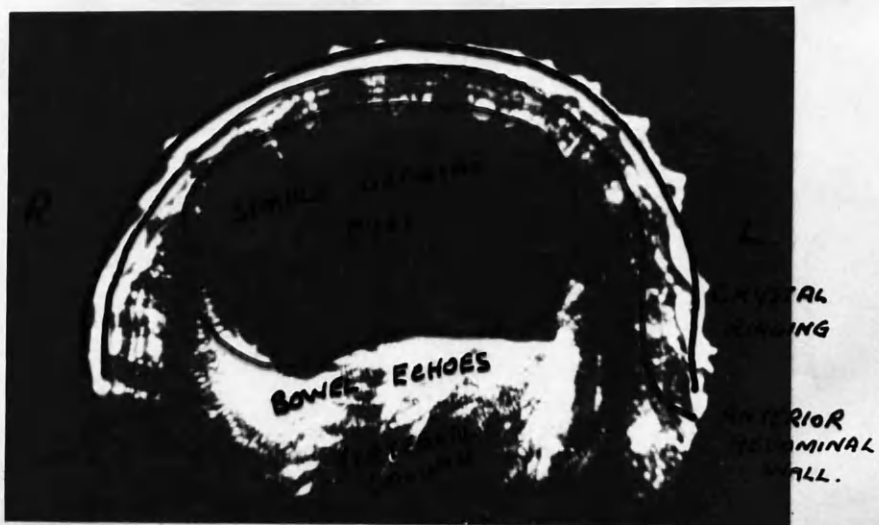

FIG 39. SIMPLE OVARIAN CYST.  
NOTICE INDENTATION BY VERTEBRAL COLUMN.  
CASE XIII.

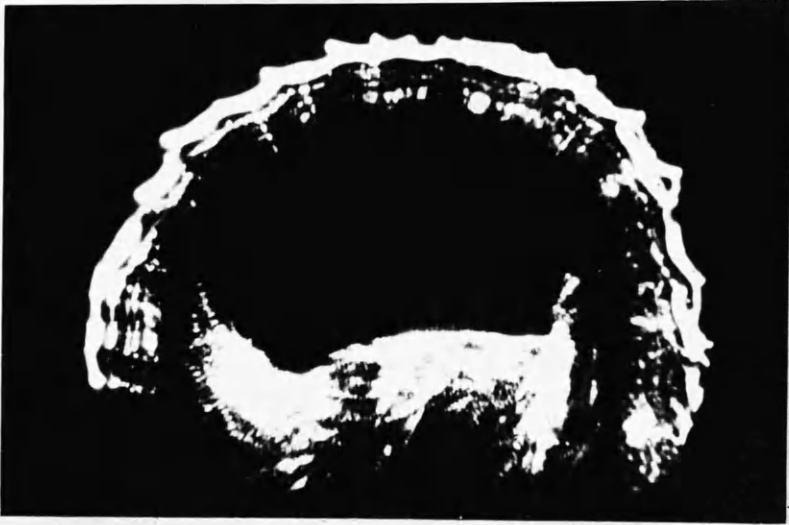
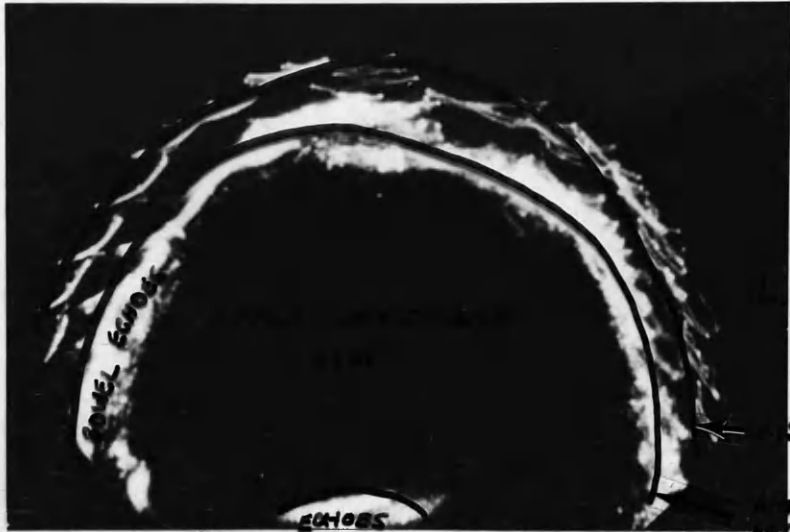


FIG 39. SIMPLE OVARIAN CYST.  
NOTICE INDENTATION BY VERTEBRAL COLUMN.  
CASE XIII.

R.



BOWEL ECHOES  
 FROM BOWEL OR  
 POSTERIOR ABDOMINAL WALL

OSTIAL RINGING

ANTERIOR ABDOMINAL WALL.

FIG 40. LARGE UNILOCULAR CYST (OVARIAN).  
 SEE CASE XIV.

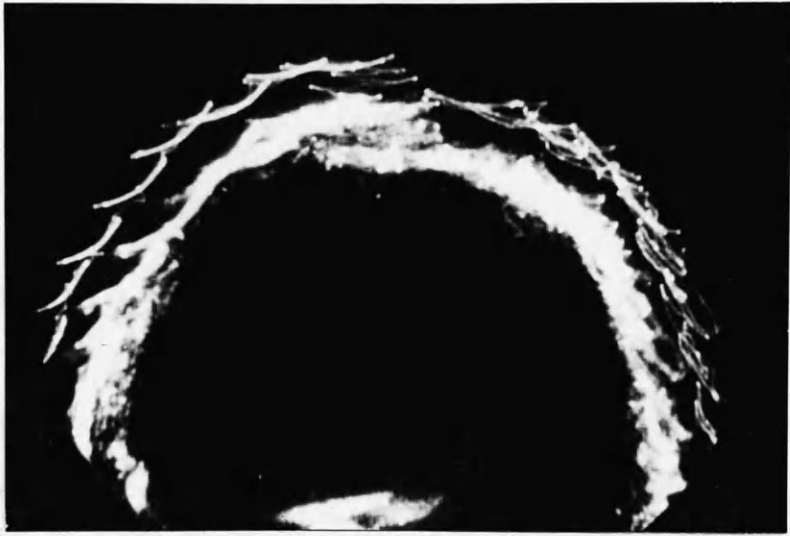


FIG 40. LARGE UNILOCULAR CYST (OVARIAN).  
SEE CASE XIV.



bilateral salpingo-oophorectomy were performed. Histologically, the cyst was a simple unilocular cyst.

Case No. XV: Mrs. May Millen, aged 56 years, was admitted with a complaint of increasing abdominal swelling of several months' duration.

On abdominal examination a cystic swelling was present, which seemed to rise from the pelvis to about four inches below the xiphisternum. A clinical diagnosis of ovarian cyst was made. Ultrasonic examination (Fig. 41) seemed to reveal the presence of two cysts and also that on the right one, anteriorly and to the right, a loop of bowel was present.

At laparotomy two cysts were present, with bowel adherent to the right one anteriorly and also the left one posteriorly. The left was the larger of the two cysts (26 cm. in diameter, as compared with 12 cm.), but at the level of the examination shown (umbilical) the cysts were approximately similar in size. Total hysterectomy and bilateral salpingo-oophorectomy were performed. Histologically the cysts were papillary serous cystadenomata.

Case No. XVI: Mrs. Lucy Gilchrist, aged 57 years, was admitted because of massive proidentia and rapidly increasing abdominal swelling of two to three weeks' duration.

She had associated complete incontinence of urine.

On clinical examination she was found to have a complete proidentia with much oedema. The abdomen was tense and shiny. No definite mass could be palpated, but the whole abdomen was tender. Catheterisation/




FIG 41. BILATERAL OVARIAN CYSTS  
SEE CASE XV.

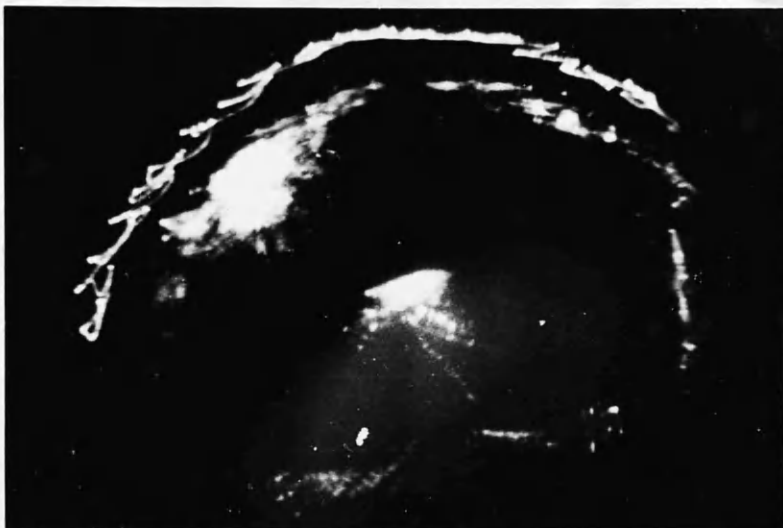


FIG 41. BILATERAL OVARIAN CYSTS  
SEE CASE XV.

Catheterisation obtained 105 oz. of urine. Thereafter her abdomen was less tense, but still no definite mass could be made out.

Ultrasonic examination just above the umbilicus revealed the picture (Fig. 42) of a cystic swelling with scattered solid areas in it. A provisional diagnosis of a large multilocular cyst was made.

At laparotomy a degree of pseudomyxomatous<sup>56</sup> peritonei was found. A large partially ruptured multilocular cyst (20 inches in diameter) arising from the left ovary was removed by left salpingo-oophorectomy. Histologically the cyst was a multilocular psuedomucinous cystadenoma.

It was feared that the patient might thereafter develop a pseudomyxoma peritonei, but six months after operation the patient was well and an ultrasonogram revealed a more or less normal abdomen (Fig. 43).

Case No. XVII: Mrs. Barbara Black, aged 42 years, was admitted because of irregular heavy vaginal bleeding of six months' duration. She was very obese, weighing 16 stones.

Accurate examination was impossible even under anaesthesia, but an ultrasonogram taken in the subumbilical region (Fig. 44) showed a cystic outline on the left side.

Laparotomy confirmed the presence of a simple cyst rising from the left ovary, three to four inches in diameter. The uterus was also/

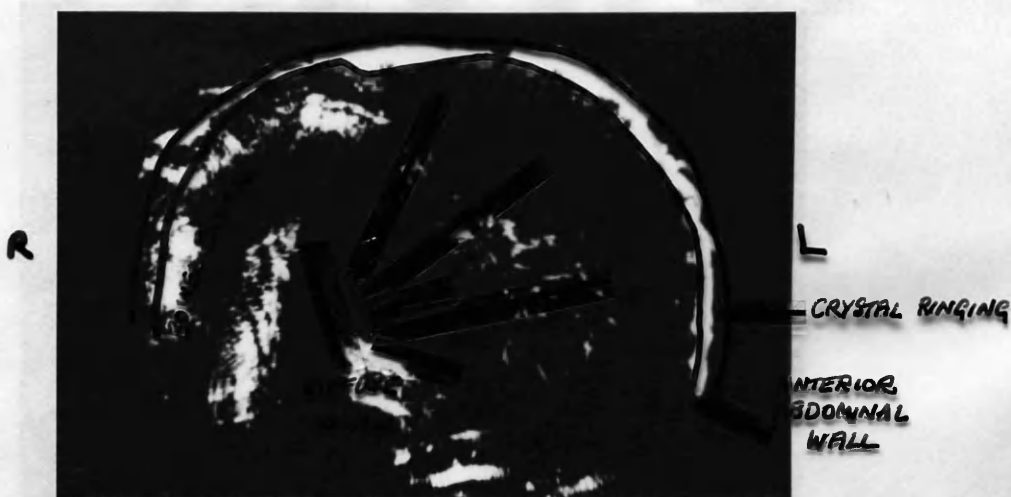

FIG 42. LARGE MULTILOCULAR PSEUDOMUCINOUS  
CYSTADENOMA  
SEE CASE XVI.



FIG 42. LARGE MULTILOCULAR PSEUDOMUCINOUS  
CYSTADENOMA  
SEE CASE XVI.

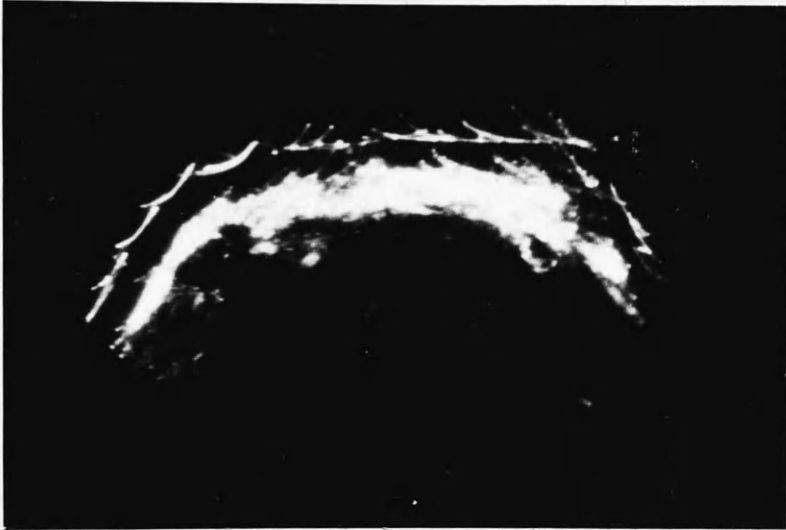


FIG 43. PATIENT DESCRIBED IN CASE XVI  
6 MONTHS AFTER OPERATION  
NORMAL ABDOMEN  
COMPARE WITH FIG 42.

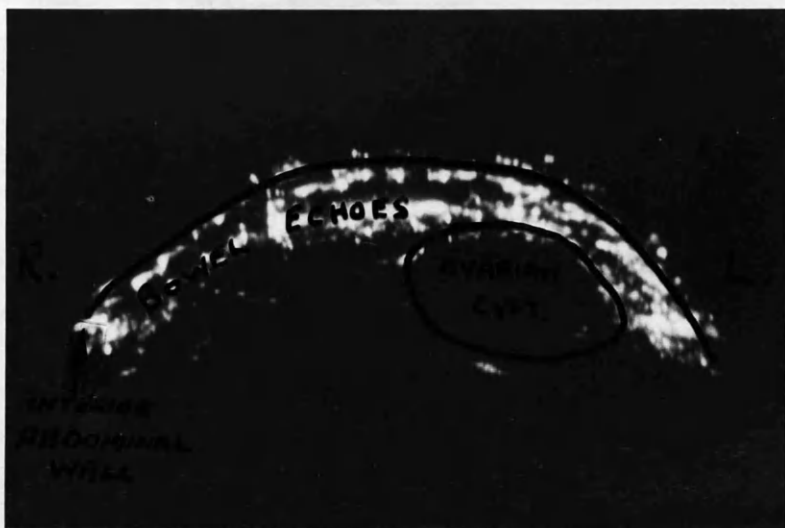


FIG 44. OVARIAN CYST NOT PALPABLE CLINICALLY  
SUPRAPUBIC  
(PATIENT WEIGHED 16 STONES).  
SEE CASE XVII N.B. PROBE ECHO ELIMINATED.



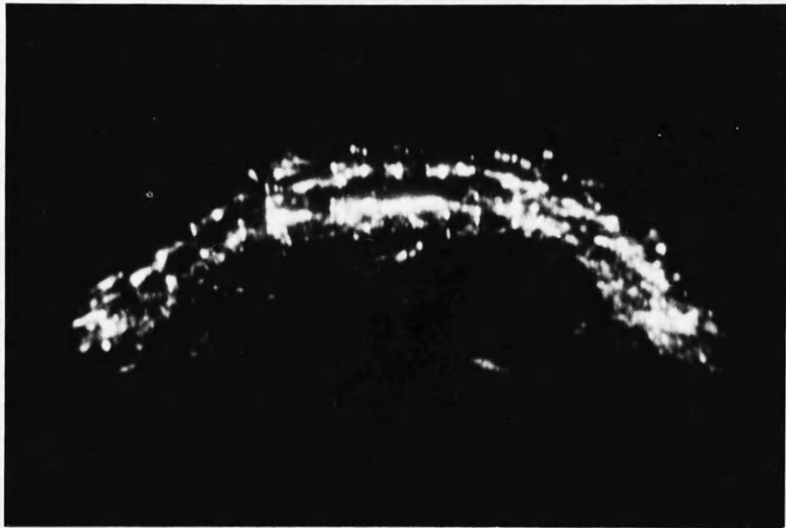


FIG. 44. OVARIAN CYST NOT PALPABLE CLINICALLY  
SUPRAPUBIC  
(PATIENT WEIGHED 16 STONES).  
SEE CASE XVII N.B. PROBE ECHO ELIMINATED.

also enlarged markedly. Total hysterectomy and bilateral salpingo-oophorectomy were performed.

Occasionally the 'cystic' appearance can be misleading, as in the following case:

Case No. XVIIII: Mrs. Irene Sheehan, aged 24 years, was admitted complaining of right-sided abdominal pain of several months' duration and amenorrhoea of three months' duration. Ascheim-Zondek test was negative.

On vaginal examination a fairly mobile, firm mass was felt to the right. It tended to lie anterior to the uterus and was just palpable abdominally. The uterus was small and non-pregnant. The swelling was thought clinically to be an ovarian cyst - probably a dermoid.

Ultrasonic examination (Fig. 45) confirmed the cystic structure of the swelling, although there also seemed to be a small cystic swelling on the left.

At laparotomy a bilateral hydrosalpinx was present, the right being much larger than the left. Bilateral salpingostomy was performed. Histologically the hydrosalpinx was thought to be tuberculous in origin.

The more complex the cyst, the more echoes will be present:

Case No. XLIX: Mrs. Anne Goudie, aged 50 years, was admitted because of an abdominal swelling of several months/

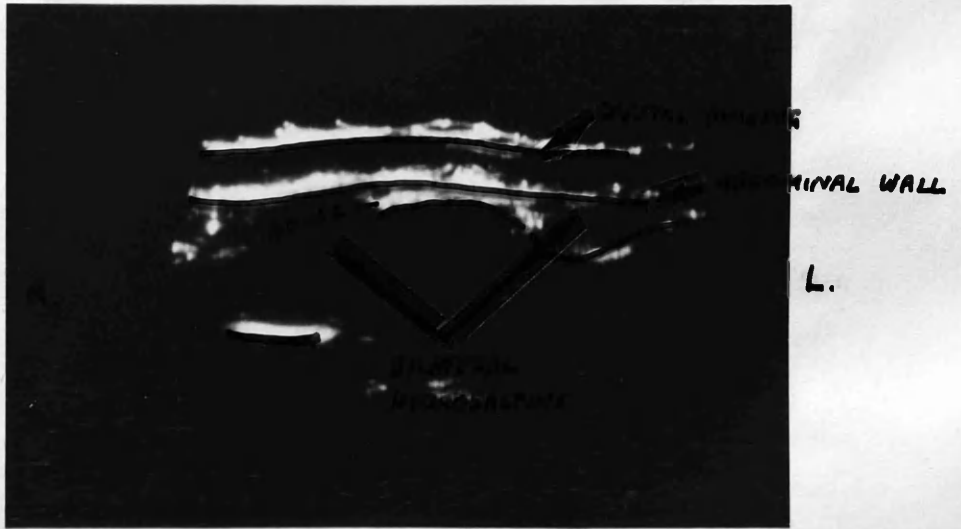


FIG 45. BILATERAL HYDROSALPINX  
SEE CASE XVIII.

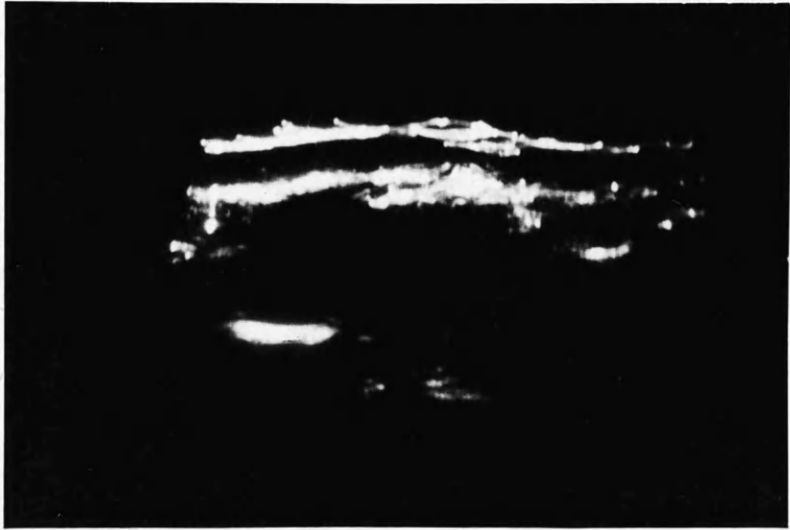


FIG 45. BILATERAL HYDROSALPINX  
SEE CASE XVIII.

months' duration. She was a patient who had been under medical treatment for several years because of steatorrhoea and subacute combined degeneration of the spinal cord.

On abdominal examination a firm irregular mass rising from the pelvis was palpable up to the level of the umbilicus. There was no obvious ascites.

On ultrasonic examination (Fig. 46) the mass seemed cystic in character, with multiple diffuse echoes present within the substance of the cyst. A tentative diagnosis of malignant ovarian cyst was made.

This diagnosis was confirmed at laparotomy. Secondary deposits were present in the liver. The main mass was originating from the right ovary, although the left ovary was also malignant. Bilateral oophorectomy was performed. The tumour was semi-solid with large cystic spaces, and histological diagnosis was difficult in that the tumour seemed to be of no definite pattern but was most like a mesonephroma of ovary. The patient died two months later.

Abdominal carcinomatosis can often give misleading pictures, especially when associated with much ascites.

Case No. XX: Mrs. Gertrude Carter, aged 50 years, had had a laparotomy because of suspected carcinoma of the ovary.



FIG 46. MALIGNANT OVARIAN CYST  
CASE XIX.

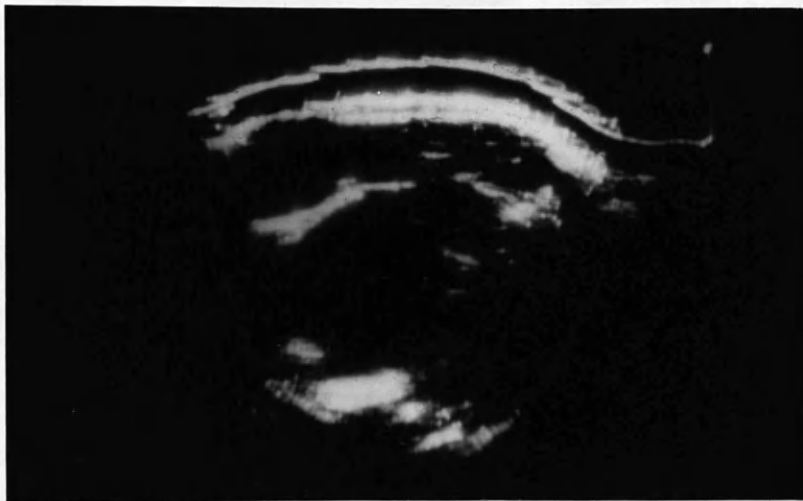

FIG 46. MALIGNANT OVARIAN CYST  
CASE XIX.

She was found to have widespread malignancy in the pelvis and large para-aortic masses about six inches in diameter. There was also widespread omental infiltration and biopsy of the tumour showed it to be a carcinoma, probably arising from ovary primarily. She was treated with cytotoxic drugs only and had repeated abdominal paracenteses at about monthly intervals. Latterly, it was thought that much of the ascitic fluid had become encysted and there were numerous palpable abdominal masses. Fig. 47 illustrates the ultrasonogram taken in the sub-umbilical region prior to tapping on one occasion. Note the 'cystic' spaces present between the bowel and/or tumour masses.

Cystic swellings other than those arising from the pelvis have also been examined:

Case No. XXI: Mrs. Mary Gray, aged 72 years, was admitted because of increasing abdominal swelling of several months' duration.

On abdominal examination a diffuse mass was palpable in the right loin and down into the right iliac fossa. Clinically this was thought to be a malignant ovarian cyst.

On ultrasonic examination the mass was obviously cystic, with small solid areas in it. (Fig. 48). The mass seemed very lateral in position and a serial ultrasonogram showed it to diminish downwards.

Intravenous pyelography revealed the mass to be a massive hydro-/



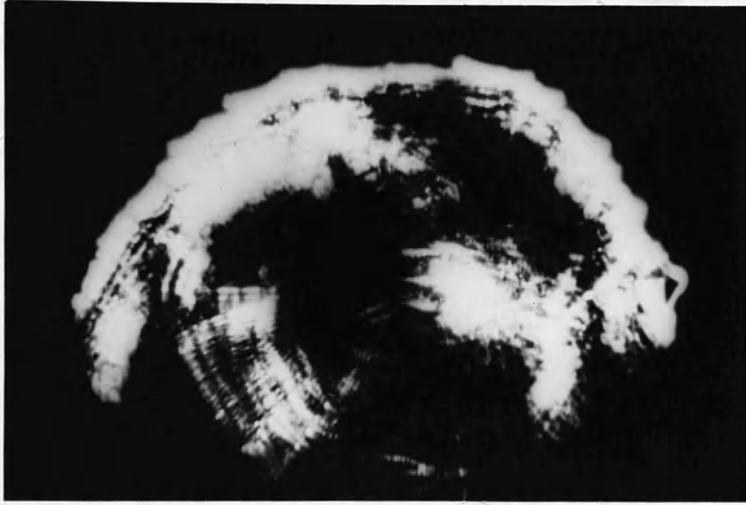


FIG. 47. ASCITES IN A PATIENT WITH  
ABDOMINAL CARCINOMATOSIS  
"CYSTIC" SPACES PROBABLY DUE TO  
ADHESIONS BETWEEN TUMOUR AND BOWEL.  
SEE CASE XX

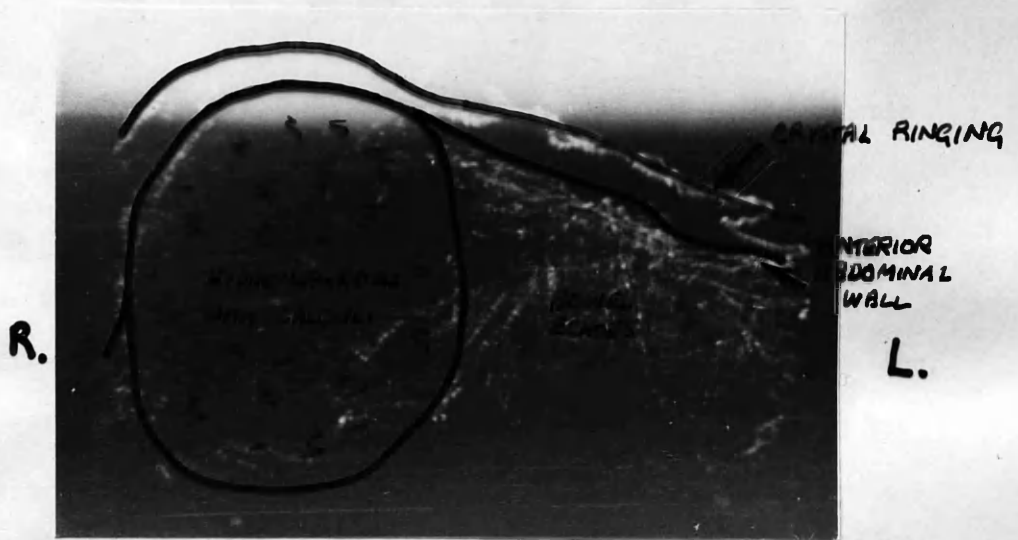


FIG 48. RIGHT HYDRONEPHROSIS WITH CALCULI.  
SEE CASE XXI.

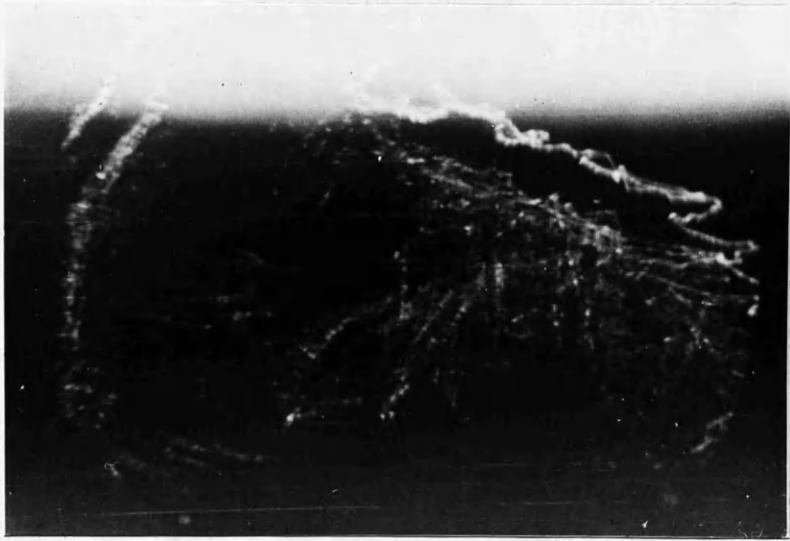


FIG 48. RIGHT HYDRONEPHROSIS WITH CALCULI.  
SEE CASE XXI.

hydronephrosis with numerous calculi. The patient was transferred to the Urological Unit for nephrectomy.

From the above series of cases it can be seen that the diagnosis of masses which are cystic in structure is fairly simple, and that an opinion can be formed prior to operation as to the type of cyst with which one is dealing.

With fibromyomata on the other hand, as in 'A'-scope presentation, different pictures were obtained, depending it is thought on the hardness and vascularity of the fibromyoma.

Case No. XXII: Mrs. Josephine Baxter, aged 39 years, was admitted complaining of abdominal pain of seven hours' duration. She also had heavy periods of six years' duration.

On abdominal examination a mass was palpable in the suprapubic region about the size of a 16 weeks' pregnancy. A small cystic swelling was present to the left and above the swelling.

Ultrasonograms were taken in the suprapubic region. As well as the  $2\frac{1}{4}$  megacycle frequency crystal probe, a  $1\frac{1}{4}$  megacycle frequency crystal probe was also used. The pictures obtained are shown in Figs. 49 and 50 respectively. A diagnosis of fibromyoma was made and it can be seen how much clearer and better resolution is obtained with the higher frequency. At laparotomy a posterior wall fibroid (6 inches in diameter) was present and also a small left ovarian cyst. Total hysterectomy and left salpingo-oophorectomy were performed. Histologically the fibromyoma was solid with no/

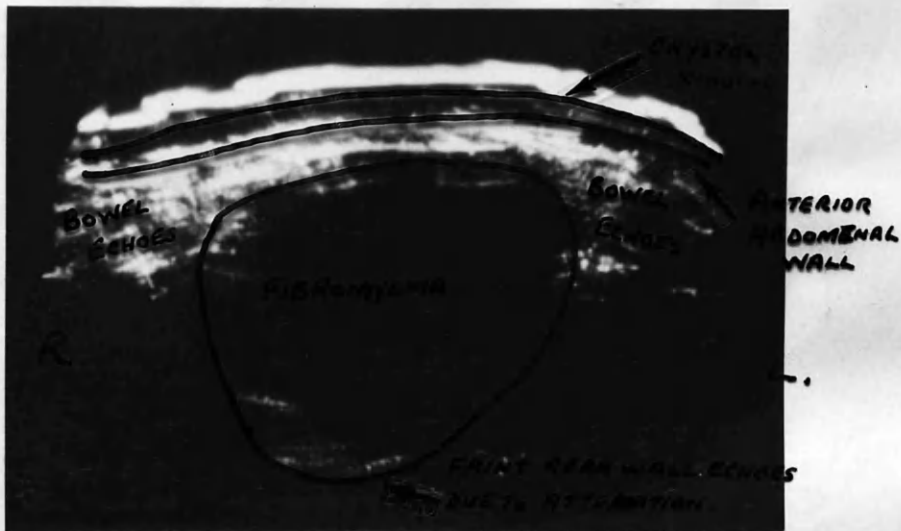


FIG 49. FIBROMYOMA SIZE OF A 16 WEEK PREGNANCY  
SUPRAPUBIC REGION 2<sup>4</sup> MEGACYCLES.  
CASE XXII.

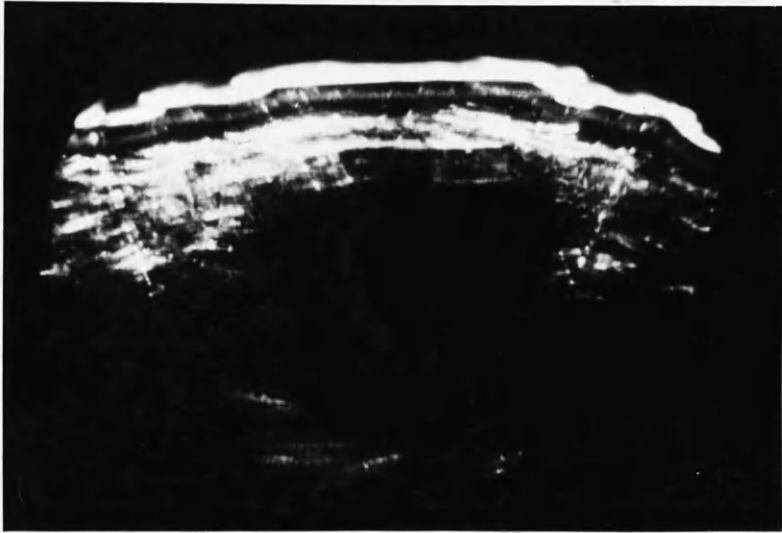


FIG 49. FIBROMYOMA SIZE OF A 16 WEEK PREGNANCY  
SUPRAPUBIC REGION 2<sup>1</sup>/<sub>4</sub> MEGACYCLES.  
CASE XXII.

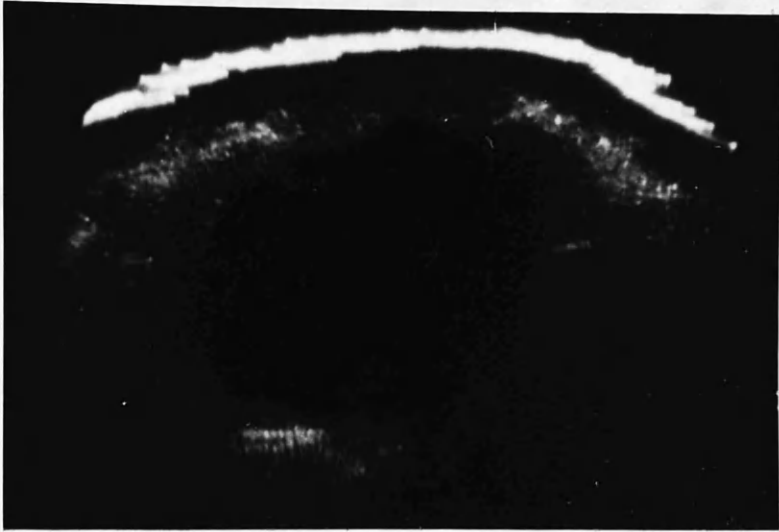


FIG 50. FIBROMYOMA SIZE OF 16 WEEKS PREGNANCY  
SUPRAPUBIC REGION  $1\frac{1}{4}$  MEGACYCLES  
COMPARE WITH FIG 49.  
NOTE BETTER RESOLUTION AND DEFINITION.

no cystic spaces or degeneration.

Case No. XXIII: Mrs. Margaret McLeod, aged 41 years, had a complaint of abdominal distension of six months' duration. She had associated menorrhagia.

On abdominal examination a hard, firm mass was present to the level of the umbilicus. Clinical diagnosis of a fibromyoma was substantiated on ultrasonic examination, as shown in Fig. 51 taken at the subumbilical level.

Confirmation was obtained at laparotomy - an intramural fibroid about nine inches in diameter being present. Total hysterectomy with left salpingo-oophorectomy was performed. The fibromyoma showed no evidence of degeneration histologically.

Case No. XXIV: Mrs. Ida Beveridge, aged 45 years, was admitted because of lower abdominal swelling of two months' duration. She had no menstrual upset.

On abdominal examination a hard, firm, irregular mass was palpable suprapubically. Vaginal examination confirmed the irregular mass to be uterine in origin and clinical diagnosis of multiple fibromyomata was made.

Ultrasonic examination (Fig. 52) outlined the irregular mass into two distinct parts, but there was no reflection deep in the mass. In other words, the mass was attenuating the ultrasound.

Diagnosis of multiple fibromyomata was confirmed at laparotomy, the main mass consisting of two fibroids at the fundus. Total hysterectomy was carried out. The fibromyomata were simple hist-/



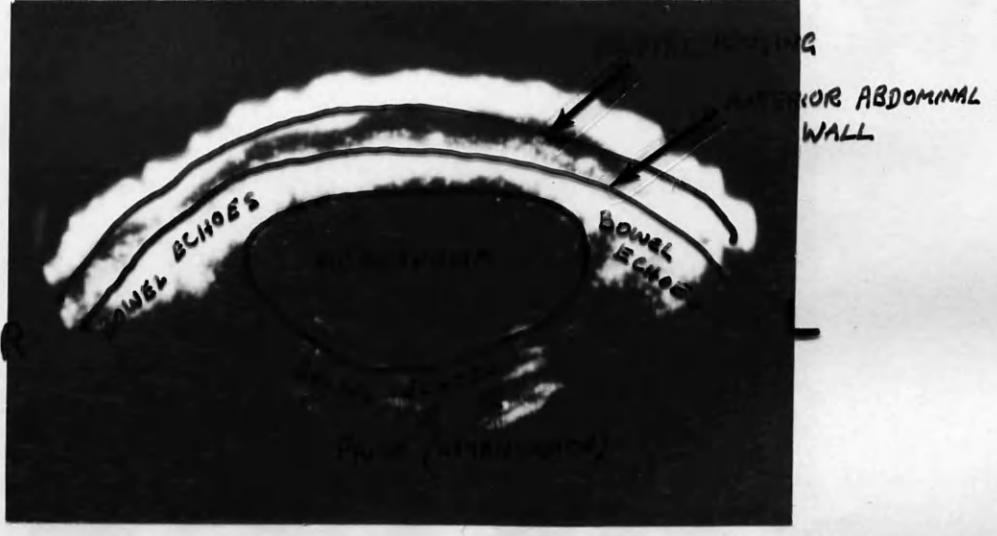


FIG 51. FIBROMYOMA TO UMBILICUS  
SUBUMBILICAL  
SEE CASE XXIII.

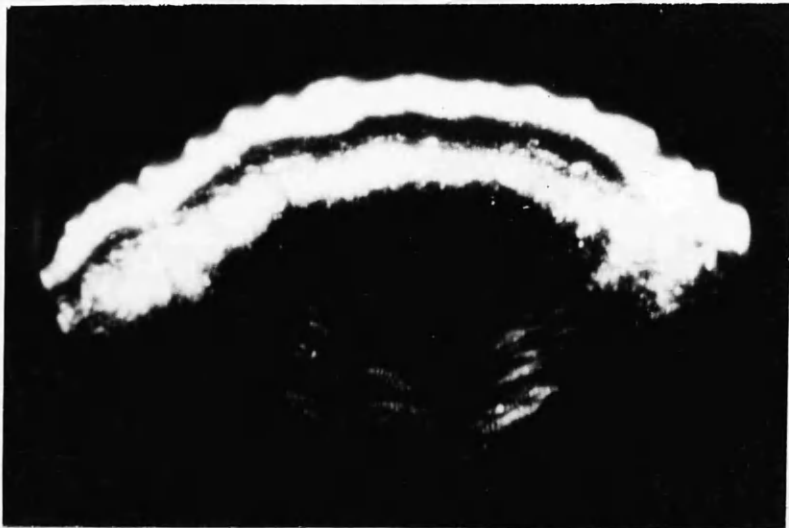


FIG 51. FIBROMYOMA TO UMBILICUS  
SUBUMBILICAL  
SEE CASE XXIII.

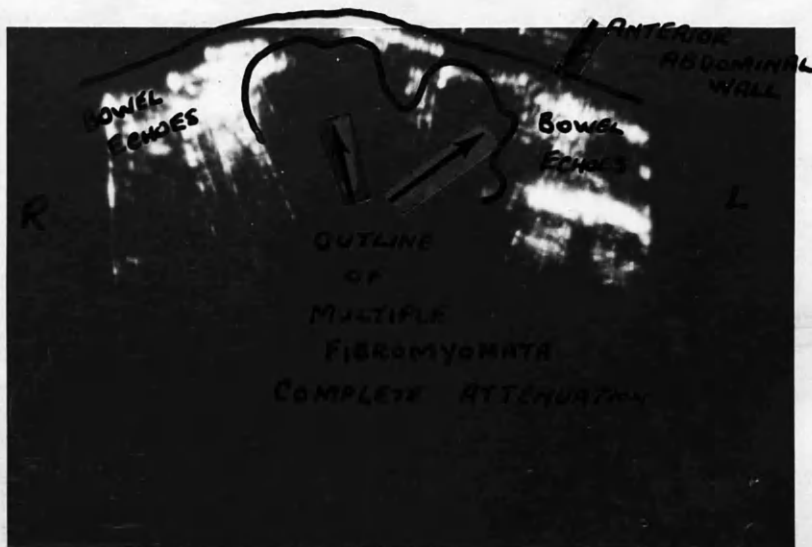


FIG 52. MULTIPLE FIBROMYOMATA  
SUPRAPUBIC REGION  
SEE CASE XXIV.

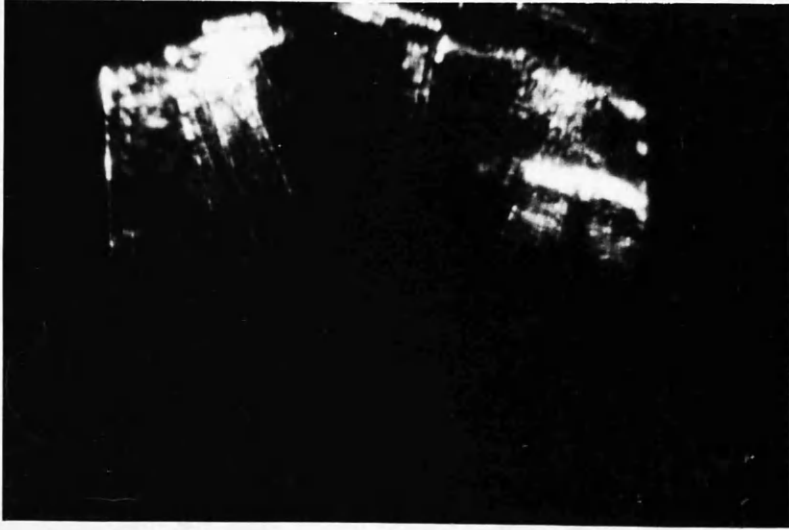


FIG 52. MULTIPLE FIBROMYOMATA  
SUPRAPUBIC REGION  
SEE CASE XIV.

histologically.

Case No. XXV: Miss Margaret Farquharson, aged 39 years, was admitted because of 'digestive' upset of three months' duration. She had no menstrual irregularity. She was mentally backward.

On abdominal examination a firm swelling was present up to the level of the umbilicus in the midline. Vaginal examination was impossible.

Ultrasonic examination in the subumbilical region revealed the sharp outline of the mass, but no penetration was obvious.(Fig. 53). Diagnosis of fibromyoma was made.

At laparotomy a large fundal fibromyoma was present with multiple small fibroids on the posterior uterine wall. Total hysterectomy was performed. The main fibromyoma was quite solid with no evidence histologically of degeneration.

Case No. XXVI: Mrs. Isabella Green, aged 47 years, was admitted complaining of heavy and prolonged periods of one year's duration. For some weeks she had also been troubled by pain in the right iliac fossa.

On abdominal examination a bilobed mass was present rising from the pelvis and reaching to the level of the umbilicus on the right and about three inches above the umbilicus on the left. A clinical diagnosis of multiple fibromyomata was made.

On ultrasonic examination in the subumbilical region, the main masses were impenetrable by ultrasound, but a cystic space was/

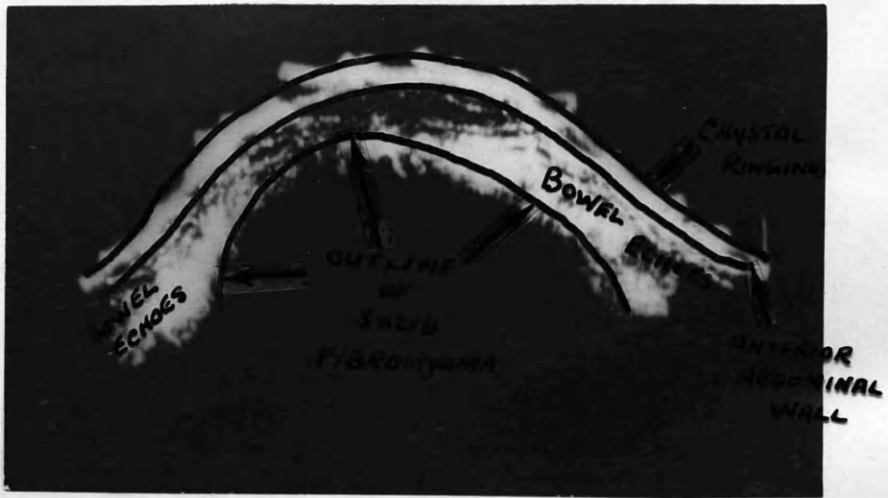

FIG 63. FIBROMYOMA TO UMBILICUS  
SUBUMBILICAL.  
SEE CASE XXV.

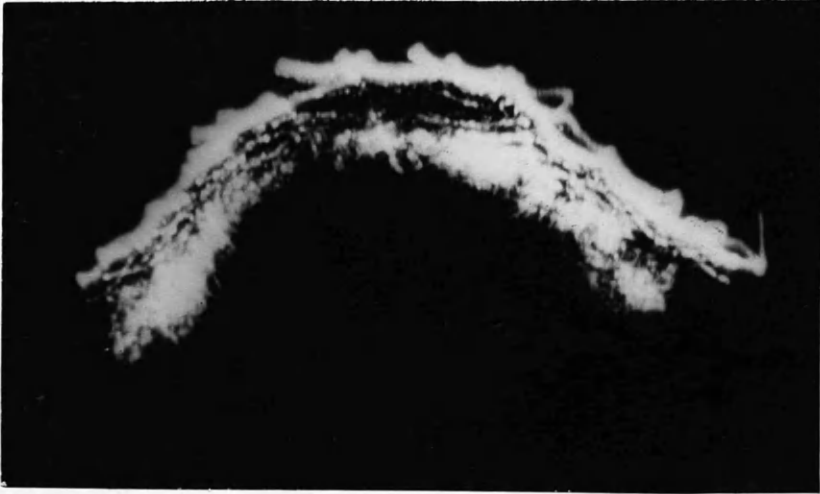


FIG 53. FIBROMYOMA TO UMBILICUS  
SUBUMBILICAL.  
SEE CASE XXV.

was present between the two main masses (Fig. 54). The patient had passed urine within an hour of examination and in the sub-umbilical region it was thought not to be due to urine in the bladder. A diagnosis of multiple fibromyomata and ovarian cyst was made.

At operation two large fundal fibromyomata were present arising more or less from each side of the uterus. The peritoneal reflection over the bladder had been pulled up and part of the bladder lay between the two main fibromyomata. Even after catheterisation before operation some urine was present in this part of the bladder.

Total hysterectomy and left salpingo-oophorectomy were performed. Although no cyst was present in this case, the ultrasonic diagnosis was vindicated due to the anatomical distortion.

A case in which a fibromyoma was known to be present but was associated with another condition was diagnosed by the ultrasonic picture before clinical diagnosis.

Case No. XXVII: Mrs. Mary Currie, aged 29 years, was admitted because of irregular vaginal bleeding of three months' duration and swelling of the abdomen of several months' duration.

She had been in the gynaecological wards a year previously with the same complaint and was known to have a fibromyoma enlarging the uterus to the size of a fourteen weeks' pregnancy.



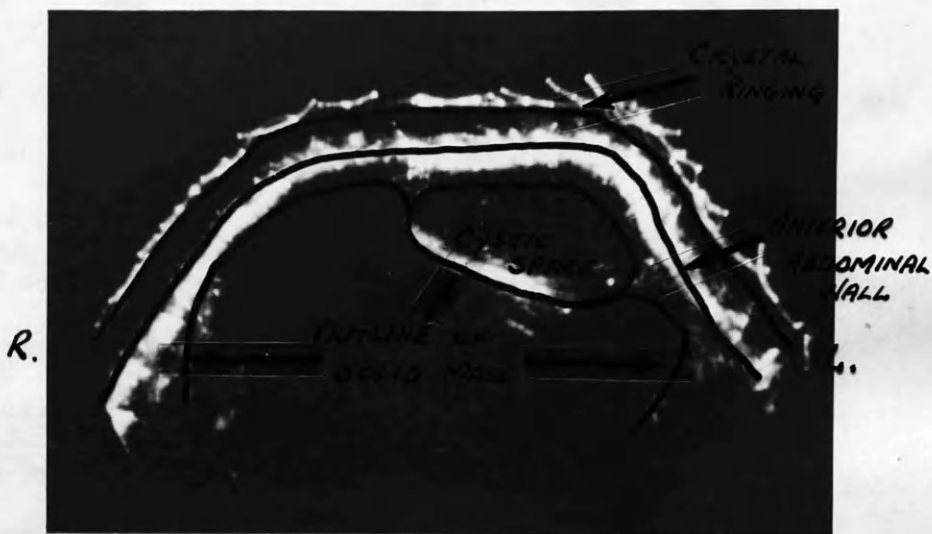

FIG 54. TWO LARGE FIBROMYOMA WITH BLADDER  
BETWEEN  
SEE CASE XXVI.  
ERRONEOUSLY DIAGNOSED AS OVARIAN CYST  
AND FIBROMYOMATA.

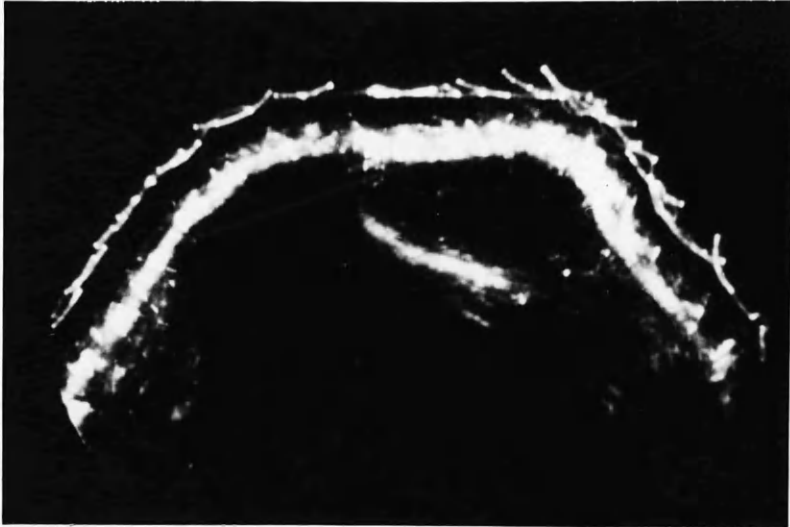

FIG 54. TWO LARGE FIBROMYOMA WITH BLADDER  
BETWEEN  
SEE CASE XXVI.  
ERRONEOUSLY DIAGNOSED AS OVARIAN CYST  
AND FIBROMYOMATA.

On abdominal examination the uterus was found to be enlarged almost up to the level of the umbilicus. It was hard and firm. She had no sickness and no breast symptoms and did not think she could be pregnant.

Prior to undertaking myomectomy, an ultrasonic examination was carried out and this showed a cystic cavity with a small shadow to the right. Fig. 55 shows this three inches below the umbilicus. A tentative diagnosis of pregnancy was made and an Asheim-Zondek test subsequently carried out was positive. The pregnancy thereafter continued uneventfully and twenty-seven weeks later she delivered herself spontaneously of a mature child by the breech. The baby was normal in all respects and well.

Following delivery involution took place well, but a fibroid could be felt at the fundus. On the eighth day of the puerperium a further ultrasonic examination was carried out over the fundus of the uterus (Fig. 56). The outline of the uterus can be seen and in the midline penetration has taken place. The slight penetration through the fibromyoma is probably due to the relative increase in vascularity consequent to pregnancy.

Cases of abdominal swelling due to ascites unassociated with intra-abdominal malignancy were also studied. As in 'A'-scope presentation the echoes from bowel were more widely spread out and deeper penetration was obtained as compared with the normal abdomen.

Case No. XXVIII: Miss Christina MacDougal, aged 63 years, was a/

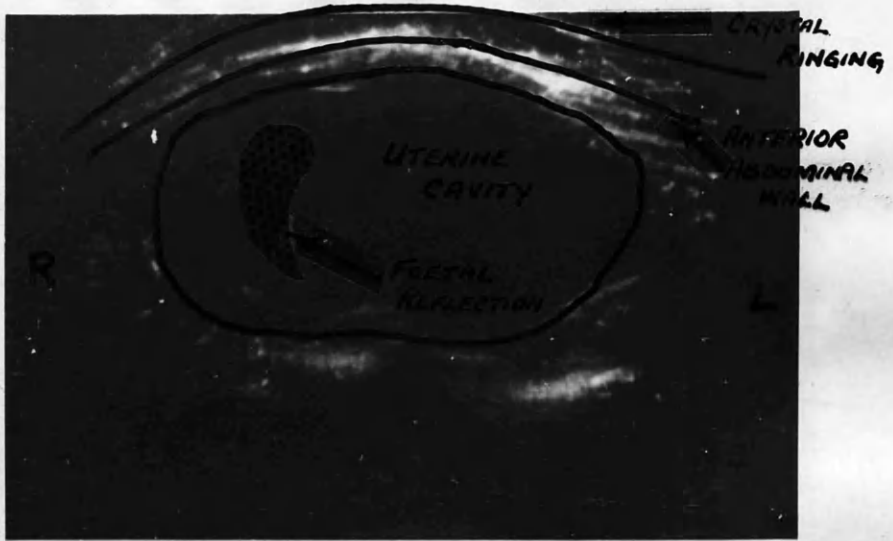


FIG 55. CYESIS MISTAKEN CLINICALLY AS  
A FIBROMYOMA. 3 INS. SUBUMBILICAL  
SEE CASE XXVII

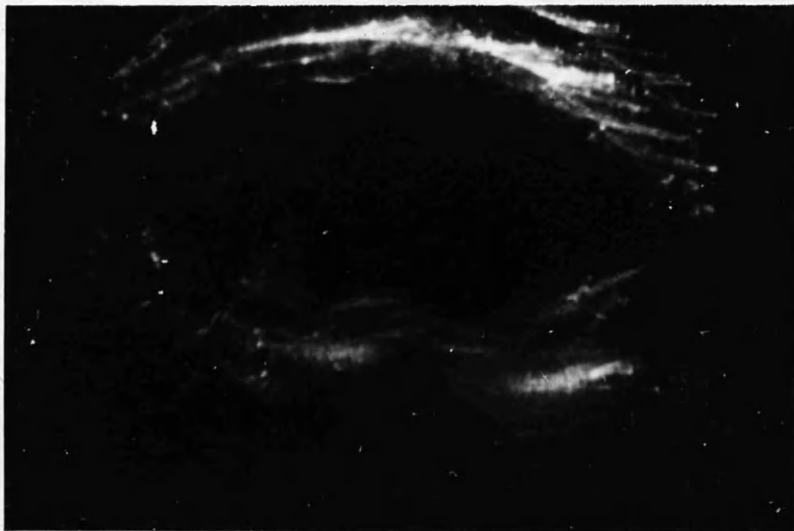


FIG 55. CYSTIS MISTAKEN CLINICALLY AS  
A FIBROMYOMA. 3 INS. SUBUMBILICAL  
SEE CASE XXVII

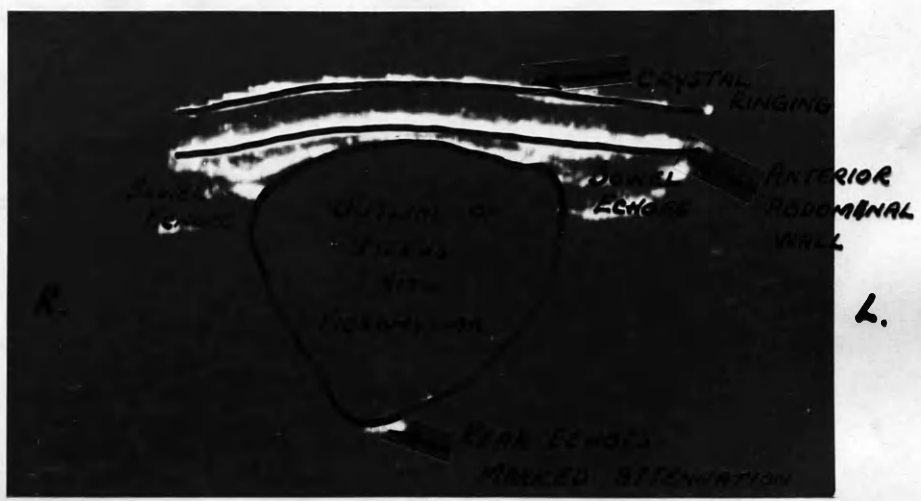

FIG. 56. EIGHTH DAY POST-PARTUM UTERUS  
WITH FIBROMYOMA  
COMPARE WITH FIG. 55.  
SAME CASE AS FIG. 55.

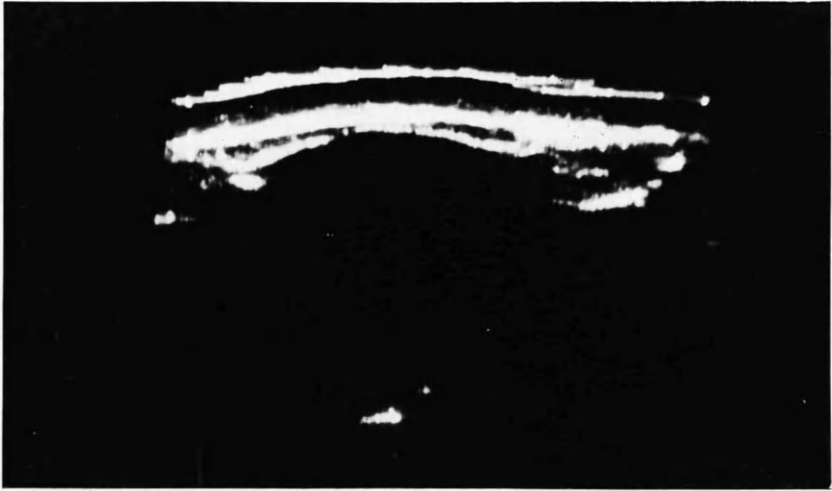


FIG. 56. EIGHTH DAY POST-PARTUM UTERUS  
WITH FIBROMYOMA  
COMPARE WITH FIG. 55.  
SAME CASE AS FIG. 55.

a patient in the medical wards of the Western Infirmary.

She had portal cirrhosis, which gave rise to jaundice, hepatic enlargement and ascites.

Fig. 57 shows the ultrasonic picture at the level of the umbilicus. Later, paracentesis abdominis obtained ten pints of fluid.

Case No. XXIX:- Mrs. Ellen McNeill, aged 67 years, was also a patient in the medical wards of the Western Infirmary. She had been admitted in cardiac failure.

Her general condition improved but she continued to have hepatic enlargement and ascites. Fig. 58 shows the ultrasonic picture at umbilical level. Paracentesis abdominis was later carried out and eight pints of fluid were obtained.

Case No. XXX: Mr. Robert Scott, aged 26 years, attended as an outpatient for paracentesis abdominis. He had tricuspid valve incompetence, associated with recurrent ascites.

On one occasion ultrasonic examination was carried out before and after paracentesis of eleven pints of fluid - Figs. 59 and 60 respectively. In view of his having had repeated abdominal tapping, previously, adhesions were probably present, and adhesions between loops of gut gave the somewhat encysted appearance. There was, also, residual fluid detectable clinically after the paracentesis had been completed.

Cases of enlargement of liver and spleen have also been studied.



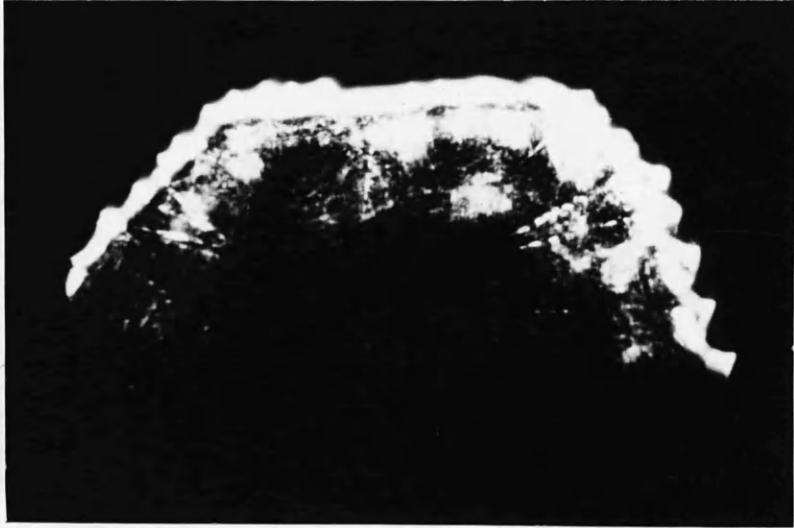


FIG 57. ASCITES DUE TO PORTAL CIRRHOSIS  
NOTE SPREAD OUT REFLECTIONS  
FROM BOWEL AND DEEPER  
PENETRATION OF SOUND  
CASE XXVIII COMPARE WITH FIG 35.

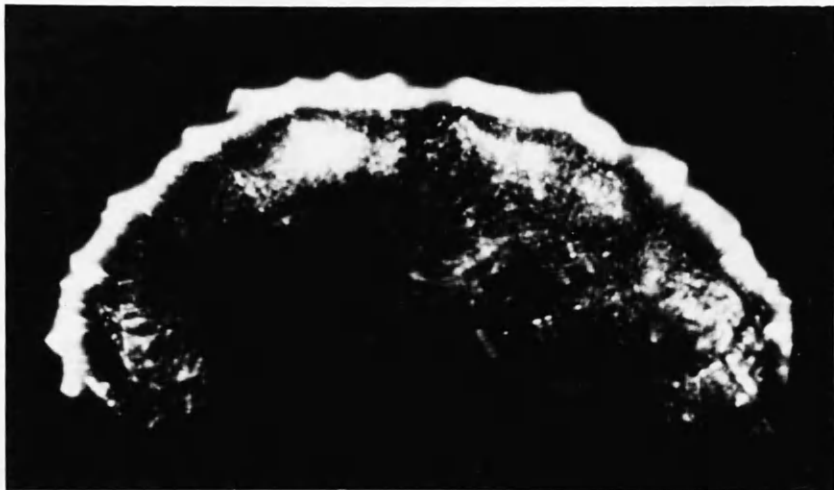


FIG 58. ASCITES IN A CASE OF CONGESTIVE  
CARDIAC FAILURE  
NOTE SPREAD OUT BOWEL ECHOES  
COMPARE WITH FIG 35. CASE XXXIX

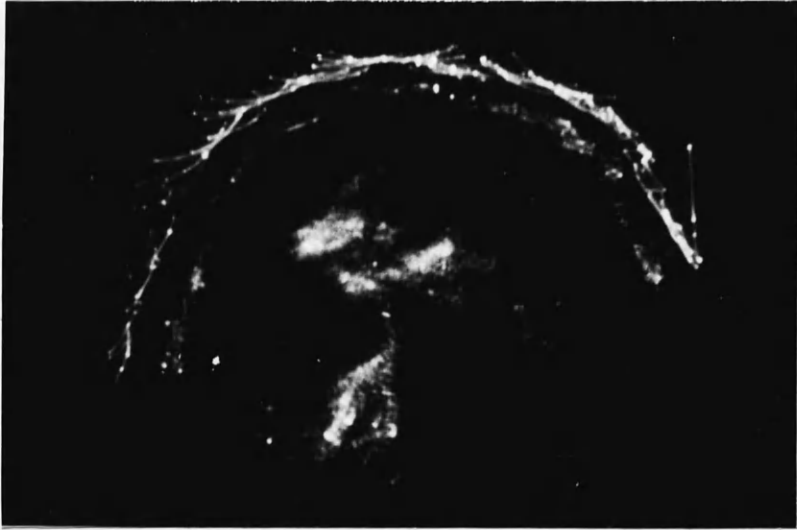

FIG. 59. ASCITES IN A CASE OF TRICUSPID  
INCOMPETENCE  
NOTE THE DEEP PENETRATION  
ENCYSTED APPEARANCE OF FLUID IS  
LIKELY DUE TO ADHESIONS CASE XXX

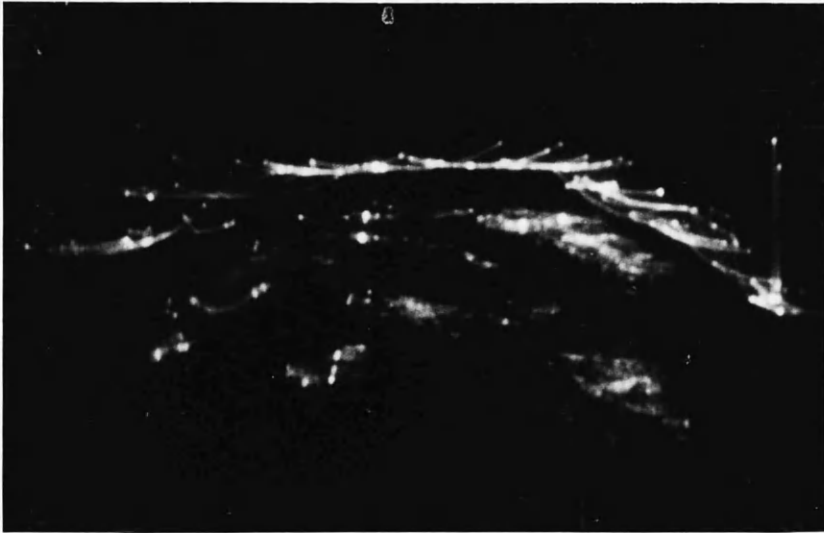


FIG. 60. CASE OF ASCITES DUE TO TRICUSPID  
INCOMPETENCE AFTER PARACENTESIS  
(SEE FIG. 59 BEFORE) OF 11 PINTS  
OF FLUID.  
ALL ASCITIC FLUID HAD NOT BEEN  
REMOVED COMPLETELY. "CYSTIC" APPEARANCE  
LESS  
CASE XKX

In view of the normal liver being behind the lower ribs, ultrasonic examination is difficult, but the normal liver seems transonic.

Case No. XXXI: Mr. Archibald McCauley, aged 51 years, was admitted to the medical wards of the Western Infirmary. He had a firm, regular enlargement of the liver to three finger-breadths below the costal margin. His spleen was also enlarged down to the level of the umbilicus.

No definite clinical diagnosis had been made.

Ultrasonic examination over the lower border of the enlarged liver (Fig. 61) showed that the liver was transonic, and so also was the spleen. Some of the echoes at depth are almost certainly bowel reflections.

A case of polycystic kidneys was also examined.

Case No. XXXII: Mrs. Letitia Lugston, aged 42 years, was five months pregnant.

As well as a uterus up to the level of the umbilicus, she had large palpable masses in both loins - the right being much larger than the left. Previous intravenous pyelography had revealed the presence of bilateral polycystic kidneys - the right being much more involved in the cystic process than the left.

Ultrasonic examination revealed the picture obtained in Fig. 62.

The right kidney has an appearance very similar to a semi-solid/



FIG. 61. CASE OF HEPATOMEGALY AND SPLENOMEGALY  
PICTURE AT LOWER EDGE OF ENLARGED  
LIVER.  
NOTE SPLEEN APPEARS "CYSTIC"  
CASE XXXI.

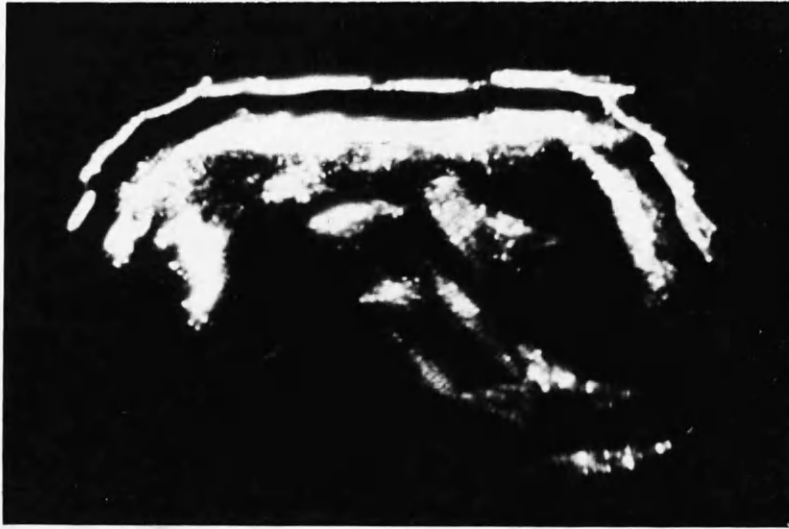

FIG. 61. CASE OF HEPATOMEGALY AND SPLENOMEGALY  
PICTURE AT LOWER EDGE OF ENLARGED  
LIVER.  
NOTE SPLEEN APPEARS "CYSTIC"  
CASE XXXI.

semi-solid ovarian cyst. The left kidney is not so clearly defined.

The patient was later delivered spontaneously, at 35 weeks' gestation, of a healthy child but she had an acute episode of abdominal pain, associated with shock, on her third post-partum day, which was thought to be due to haemorrhage into one of the cysts.



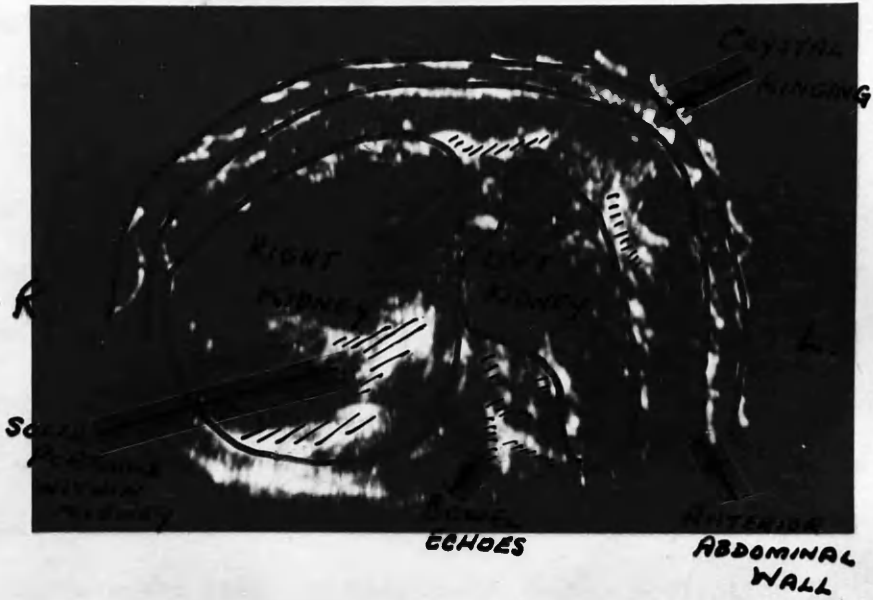

FIG 62. CASE WITH BILATERAL POLYCYSTIC KIDNEYS.  
CROSS SECTION OF LUMBAR REGION  
CASE XXXII.

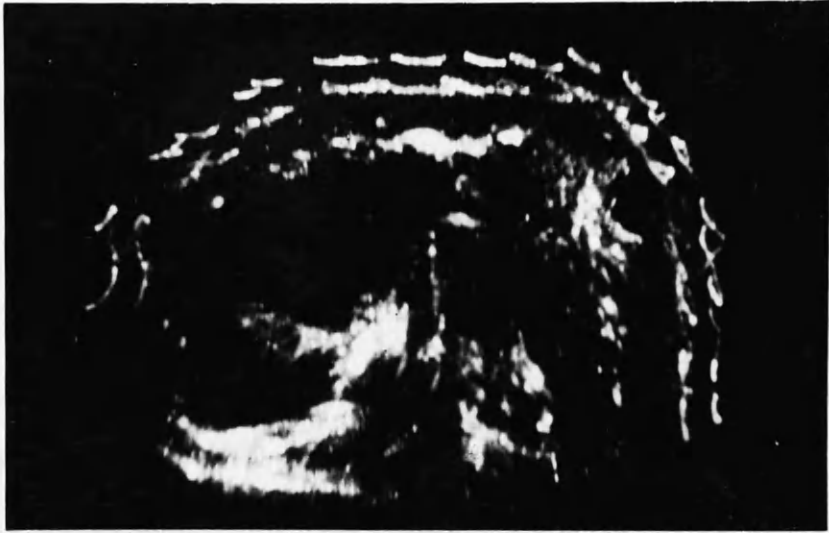

FIG 62. CASE WITH BILATERAL POLYCYSTIC KIDNEYS.  
CROSS SECTION OF LUMBAR REGION  
CASE XXXII.

CONDITIONS OF PREGNANCY.

Radiologically the foetus cannot be viewed until fourteen to sixteen weeks of pregnancy. Attempts were made to pick up foetal reflections on the ultrasonic apparatus before this duration of pregnancy. Reference to Fig. 55 will show a foetus which could not have been more than twelve to fourteen weeks size, even although the uterus was larger. Figs. 63 to 68 inclusive show ultrasonic pictures at various stages of pregnancy. Fig. 63 was taken immediately suprapubically in a patient with nine weeks' amenorrhoea, but the uterus was enlarged to about ten to twelve weeks size. A very small foetal reflection is present. Fig. 64 was also taken in the suprapubic region. The patient was unmarried and denied the likelihood of pregnancy or menstrual upset. The uterus was twelve to fourteen weeks size and just palpable suprapubically. The ultrasonic examination confirmed the clinical diagnosis of pregnancy. Fig. 65 was taken two inches above the symphysis pubis in a patient fourteen weeks pregnant. Figure 66 was taken midway between the symphysis pubis and the umbilicus in a patient eighteen weeks pregnant. Fig. 67 was taken in the subumbilical region in a fourteen year old girl who was twenty weeks pregnant and had been admitted to hospital because of vomiting and abdominal pain. The area above the umbilicus is shown in Fig. 68 in a patient who was twenty-four weeks pregnant.

Since there is no air in the foetus it seems to be reasonably/

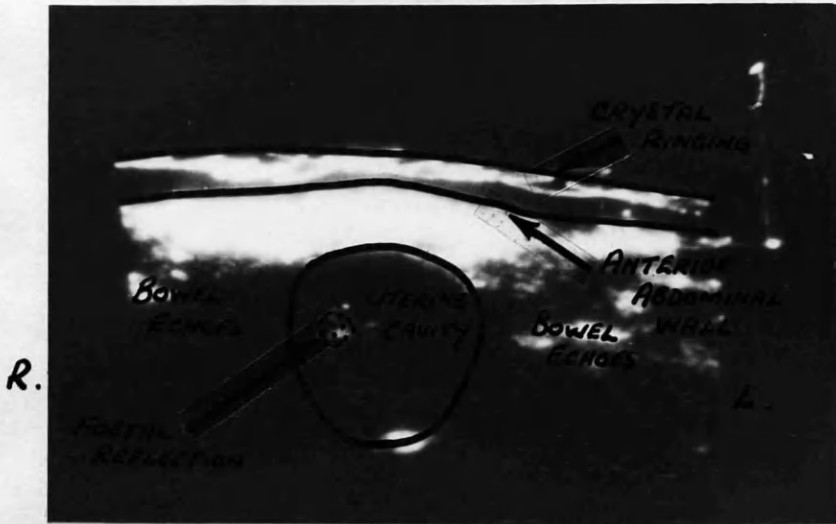


FIG 63. CYESIS PROBABLY 10-12 WEEKS  
IMMEDIATE SUPRAPUBIC SCAN.  
NOTE CYSTIC CAVITY WITH SMALL FOETAL  
REFLECTION.

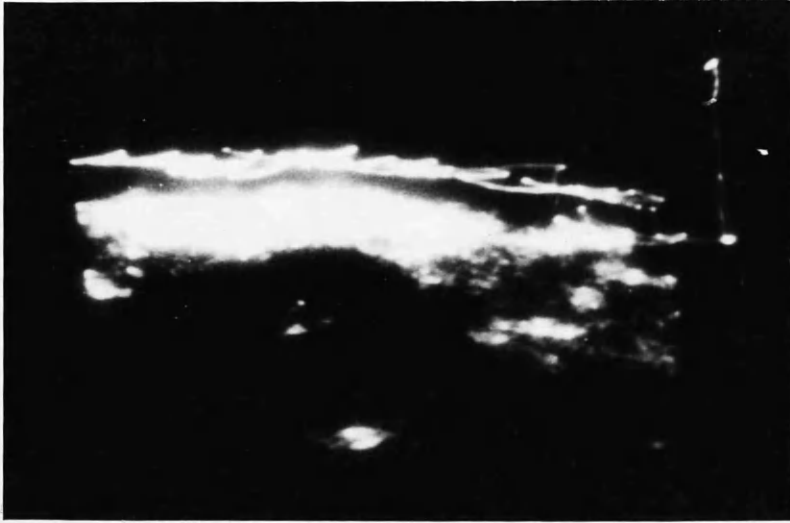


FIG 63. CYESIS PROBABLY 10-12 WEEKS  
IMMEDIATE SUPRAPUBIC SCAN.  
NOTE CYSTIC CAVITY WITH SMALL FOETAL  
REFLECTION.



FIG 64. CYESIS ADVANCED TO 12 TO 14 WEEKS  
SUPRAPUBIC SCAN.

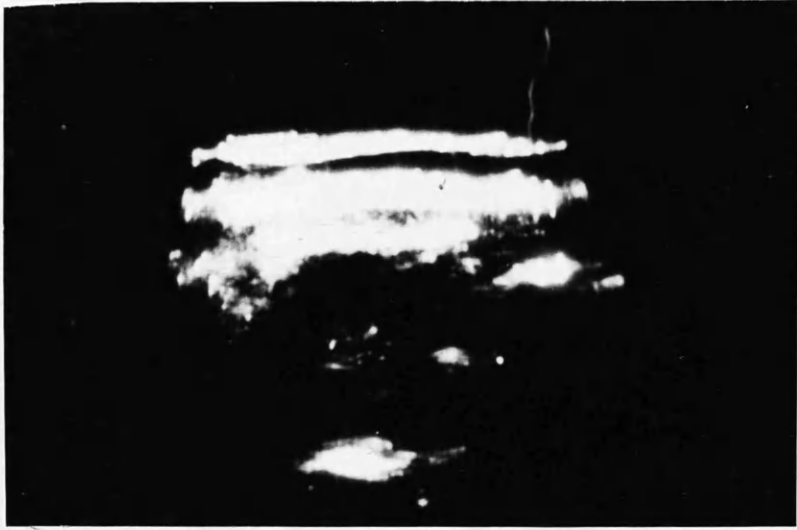


FIG 64. CYESIS ADVANCED TO 12 TO 14 WEEKS  
SUPRAPUBIC SCAN.

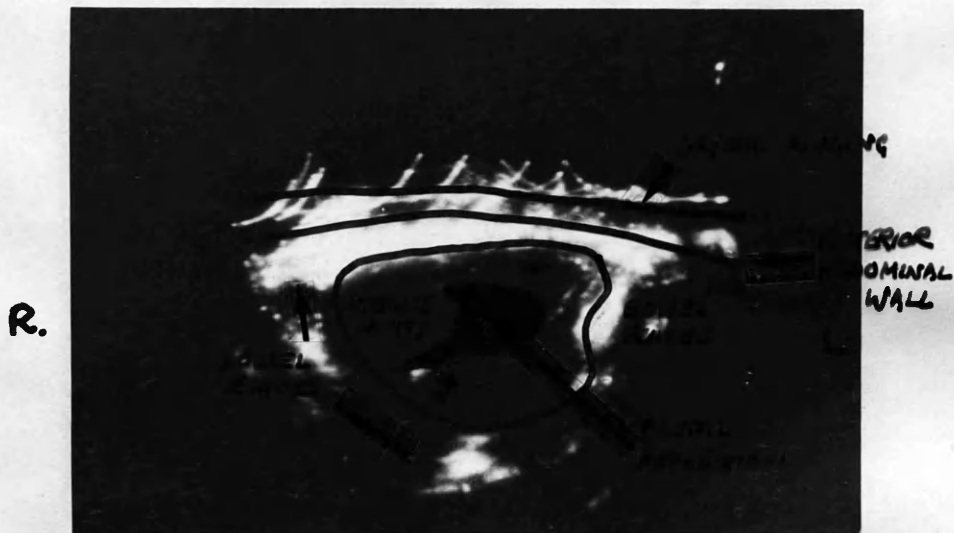


FIG 65. CYESIS ADVANCED TO 14 WEEKS  
SCAN 2" SUPRAPUBIC.



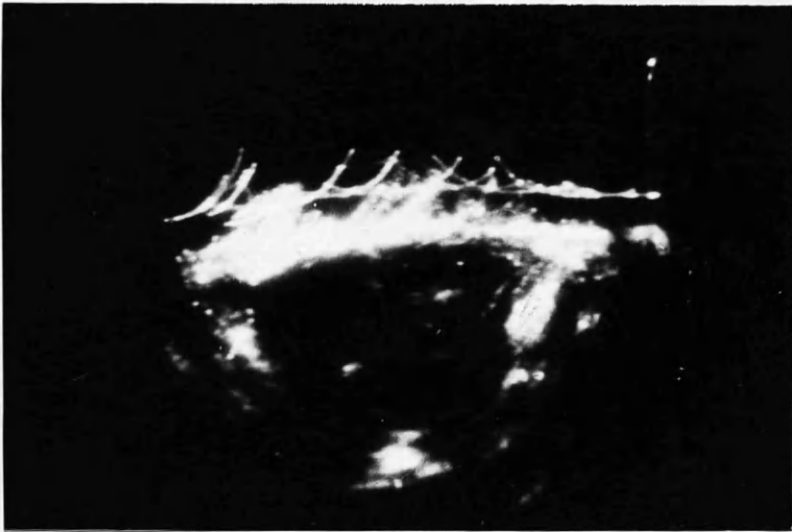


FIG 65. CYESIS ADVANCED TO 14 WEEKS  
SCAN 2" SUPRAPUBIC.

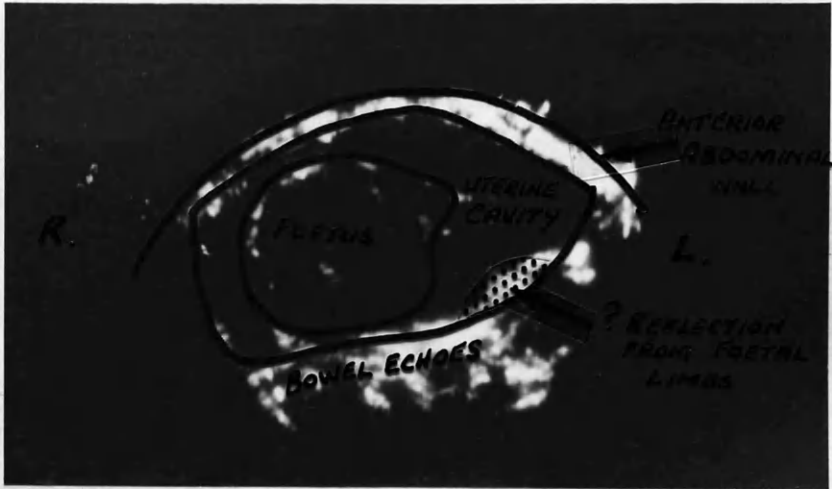


FIG 66. CYESIS OF 18 WEEKS DURATION  
SCAN MIDWAY BETWEEN SYMPHYSIS PUBIS  
AND UMBILICUS.  
CRYSTAL RINGING HAS BEEN SUPPRESSED.

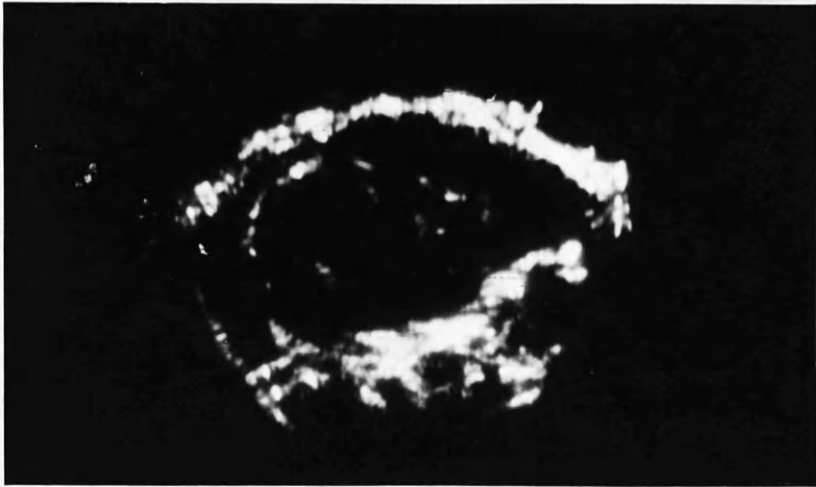


FIG 66. CYESIS OF 18 WEEKS DURATION  
SCAN MIDWAY BETWEEN SYMPHYSIS PUBIS  
AND UMBILICUS.  
CRYSTAL RINGING HAS BEEN SUPPRESSED.

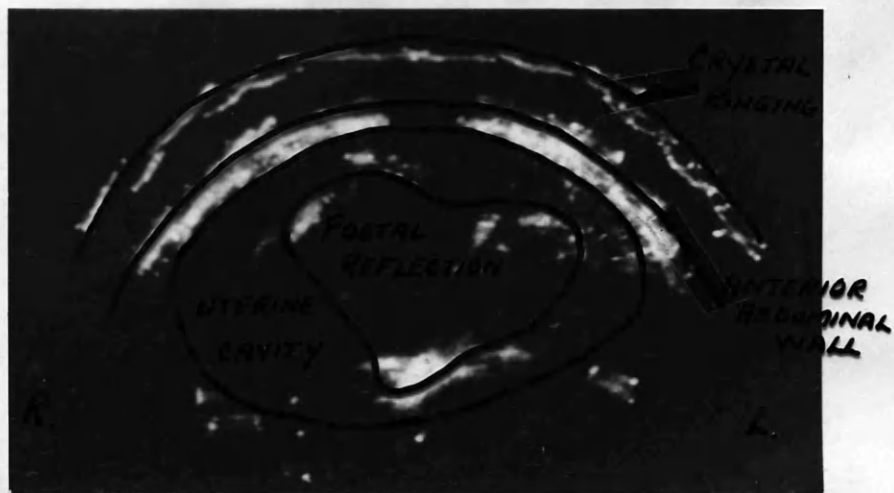


FIG 67. CYSTIC AT 20 WEEKS  
SCAN AT SUBUMBILICAL REGION.

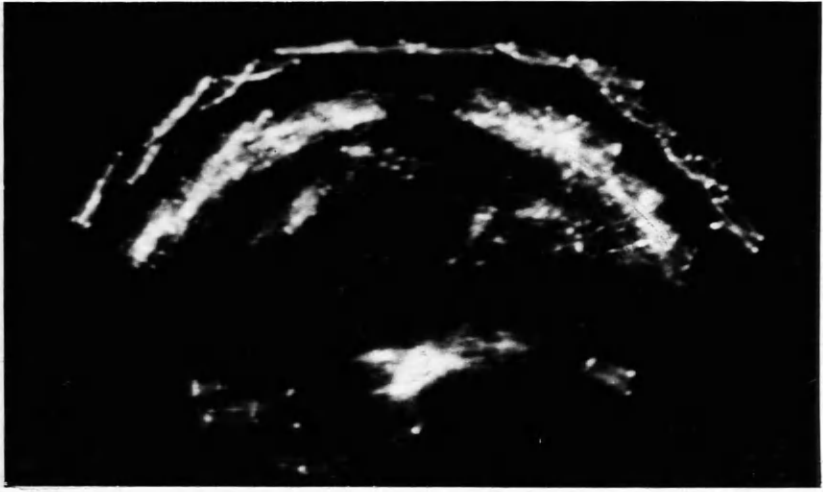


FIG 67. CYEBIS AT 20 WEEKS  
SCAN AT SUBUMBILICAL REGION.

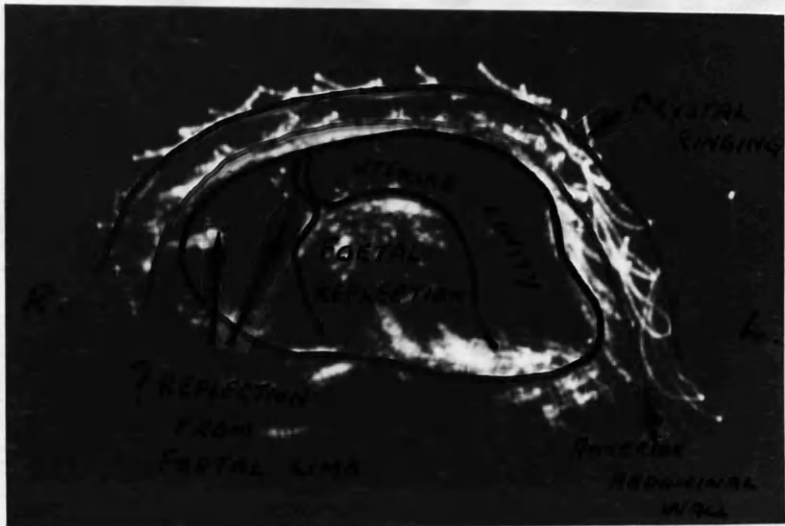


FIG. 68. CYSTIS OF 28 WEEKS DURATION  
SUPRAUMBILICAL LEVEL AND SO  
OVER UPPER POLE OF FOETUS (BREECH)

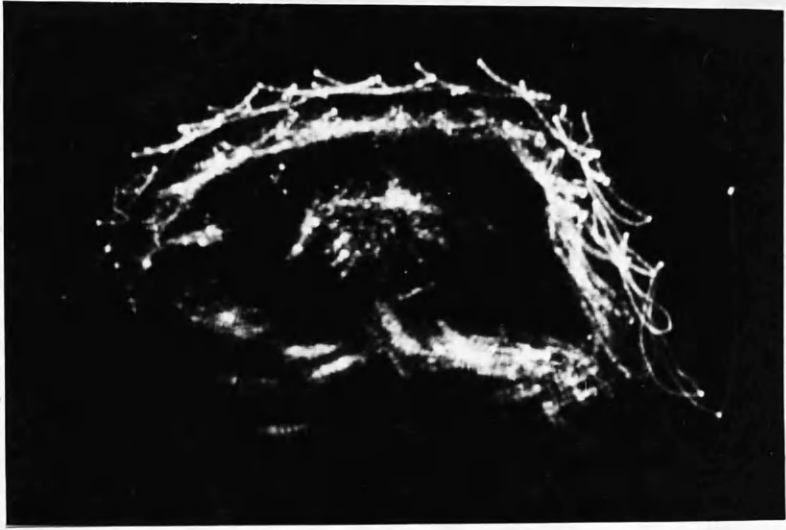

FIG. 68. CYESIS OF 28 WEEKS DURATION  
SUPRAUMBILICAL LEVEL AND SO  
OVER UPPER POLE OF FOETUS (BREECH)

reasonably transonic.

To diagnose pregnancy is one thing, but to diagnose the absence of pregnancy is another, as the following case illustrates.

Case No. XXXIII: Mrs. Isabella Gault, aged 40 years, was seen at the Gynaecological Clinic of the Western Infirmary. She stated she was pregnant. She had no previous pregnancies. She had amenorrhoea of six months' duration and swelling of the abdomen of four months' duration. She had had morning sickness for three months and had felt foetal movements for two weeks.

On abdominal examination, the abdomen was 'blown-out' and the patient would not relax. On percussion the abdomen was tympanitic throughout. Vaginal examination was impossible as the patient would not relax.

Ultrasonic examination in the mid-subumbilical region showed no evidence of cyst or cyesis (Fig. 69). The picture was intentionally over exposed in order to detect the slightest structural change. Examination under anaesthesia confirmed that there was no intra-abdominal swelling and that the uterus was small and non-pregnant.

Cases in late pregnancy have also been examined. The foetal head can usually be clearly made out, and this has been found useful in the patient in whom there is some doubt as to what part of the foetus is presenting. Two such cases are shown in Figs. 70 and 71.



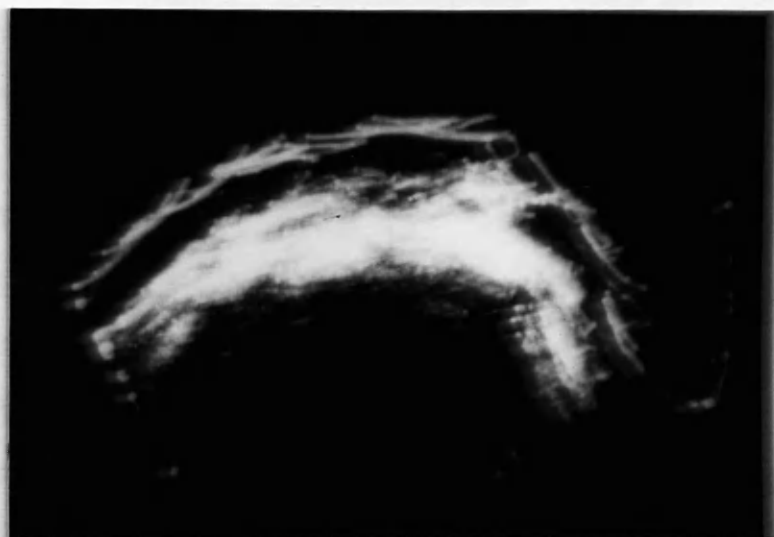


FIG 69. PSEUDOCYEBIS

NORMAL ABDOMEN [OVEREXPOSED SCAN IN ORDER  
TO PICK UP ANY CYSTIC CAVITY].

MID SUBUMBILICAL SCAN.

CASE XXXIII.

Both pictures were taken in the suprapubic region, The patient was thirty-six weeks pregnant in Fig. 70, and at term in Fig.71. In cases where there is hydramnios the relatively large amount of liquor, as compared with size of foetus, gives a clear cut picture. This is illustrated in the following case.

Case No. XXXIV:Mrs. Catherine Heaney, aged 34 years, was admitted to the Royal Maternity Hospital because of sudden increase in uterine size associated with abdominal discomfort. She had had three previous normal pregnancies with spontaneous delivery of three children, all alive and well.

She was thirty-two weeks pregnant and had an abdominal girth of 44 inches. Ultrasonic examination in the supraumbilical region is shown in Fig. 72. Following paracentesis of the liquor amnii per abdomen (nine pints), the patient went into labour and delivered herself of a stillborn child who had multiple chondromata almost filling the chest.

Cases of multiple pregnancy were also examined. Fig. 73 shows an ultrasonic picture taken above the umbilicus, in a case of twins at thirty-seven weeks. Both foetuses were presenting by the vertex and the picture shows a cross section of the breeches. Attempts to locate the position of the placenta, especially in cases of antepartum haemorrhage, have not been encouraging. This is not surprising, when reference is made to the experiments/



FIG 70. VERTEX PRESENTATION 36 WEEKS PREGNANCY  
SUPRAPUBIC SCAN.



FIG. 70. VERTEX PRESENTATION 36 WEEKS PREGNANCY  
SUPRAPUBIC SCAN.

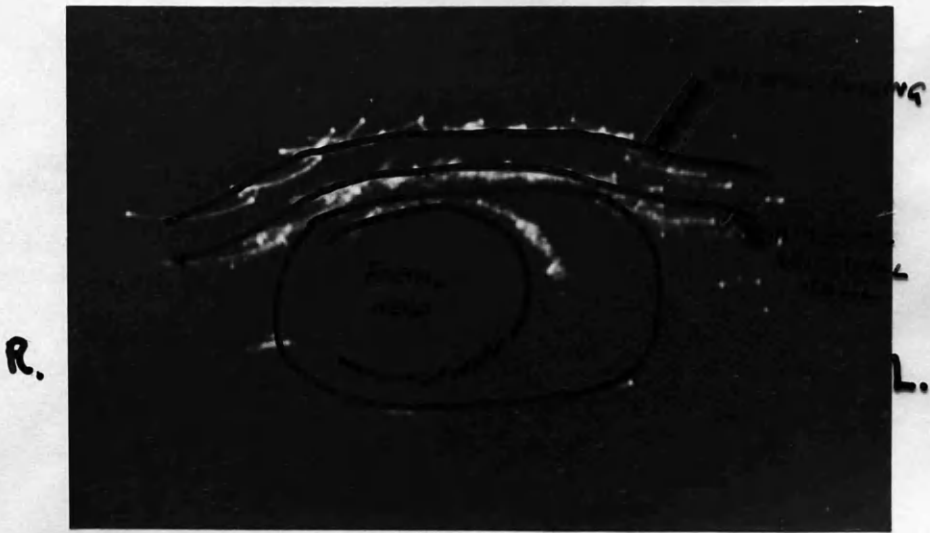


FIG 76. VERTEX PRESENTATION AT TERM  
HEAD NOT ENGAGED  
SUPRAPUBIC SCAN.

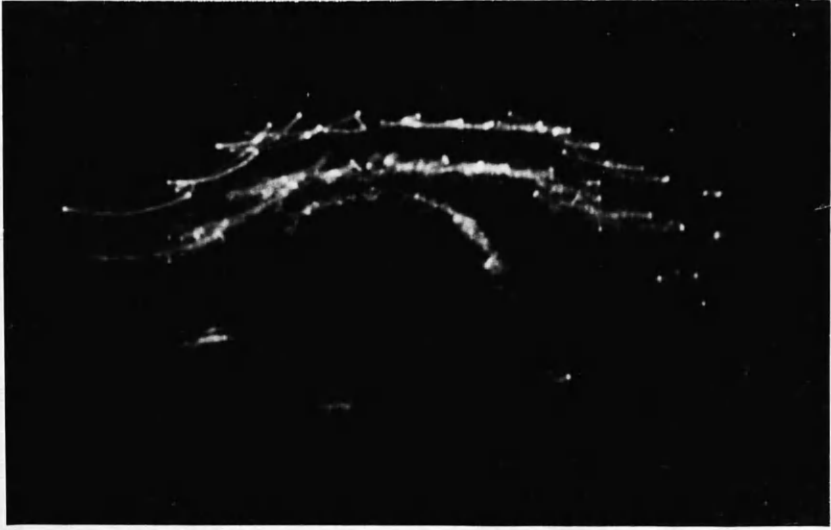

FIG 76. VERTEX PRESENTATION AT TERM  
HEAD NOT ENGAGED  
SUPRAPUBIC SCAN.

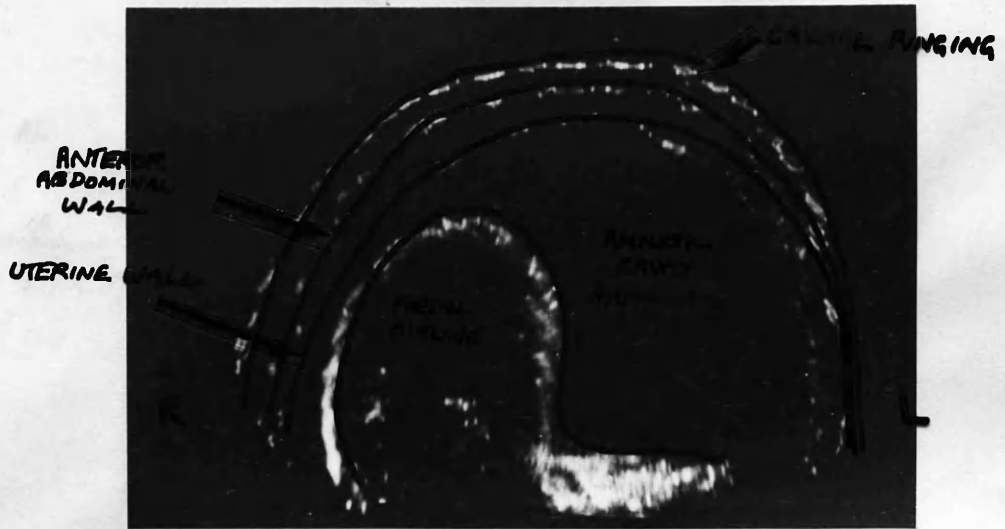


FIG 72. CASE OF HYDRAMNIOS . 32ND WEEK  
OF PREGNANCY.  
ABDOMINAL GIRTH 44 INS.  
SUPRAUMBILICAL SCAN . CASE XXXIV .

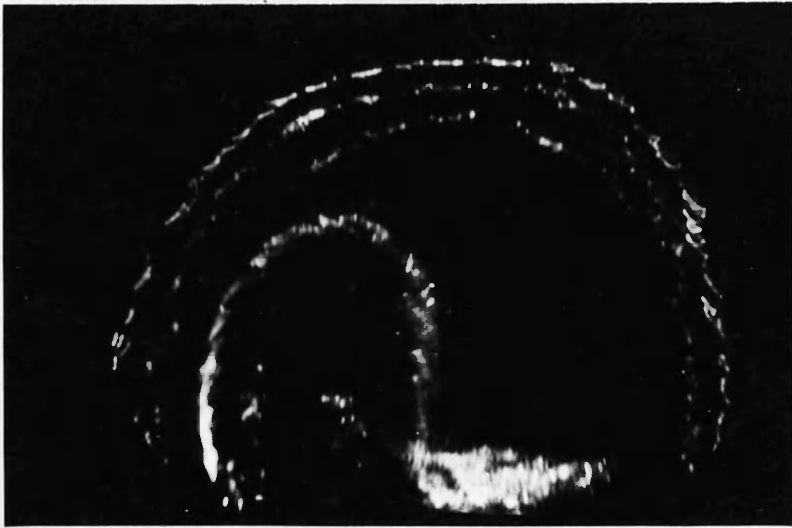


FIG 72. CASE OF HYDRAMNIOS . 32ND WEEK  
OF PREGNANCY.  
ABDOMINAL GIRTH 44 INS.  
SUPRAUMBILICAL SCAN . CASE XXXIV .



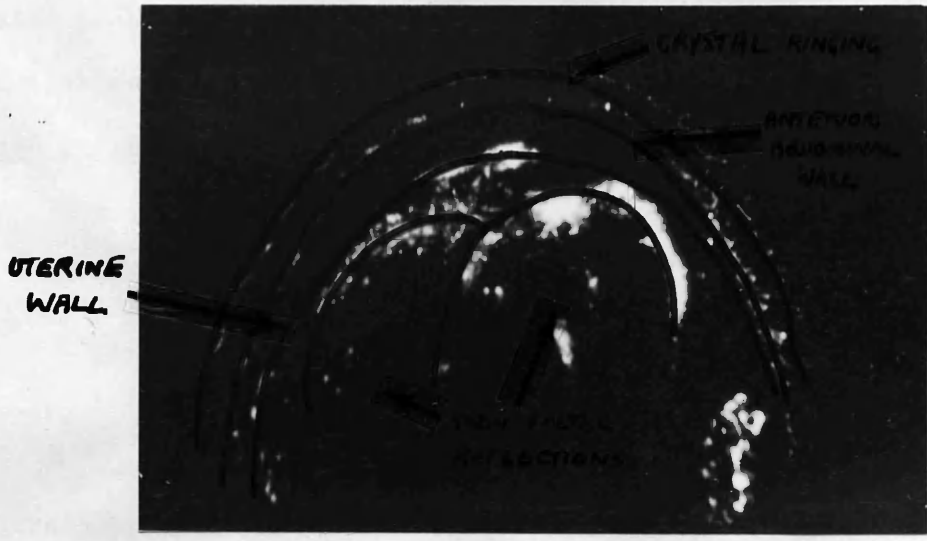


FIG 73. TWIN PREGNANCY AT 37 WEEKS  
SUPRAUMBILICAL SCAN.  
UPPER POLES OF FOETUSES (BREECH)

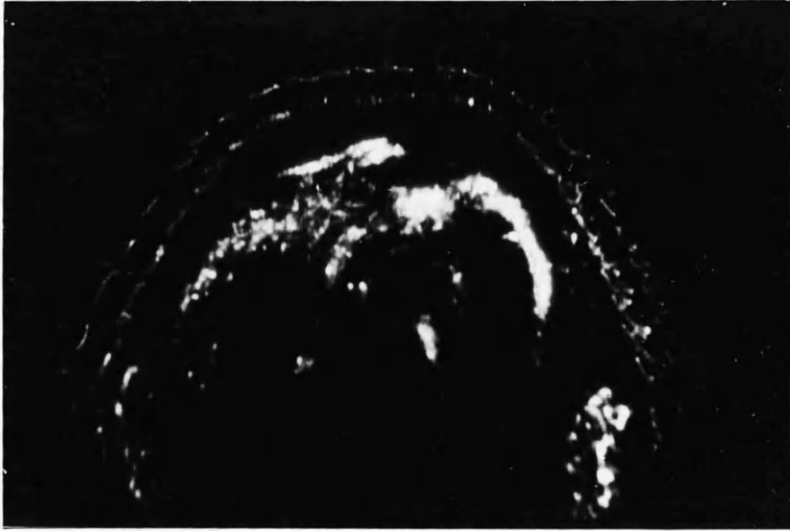


FIG 73. TWIN PREGNANCY AT 37 WEEKS  
SUPRAUMBILICAL SCAN.  
UPPER POLES OF FOETUSES (BREECH)

experiments previously mentioned, carried out in the experimental water tank. The following case may well be exceptional, since no similar such good result has been obtained.

Case No. XXXV: Mrs. Mary McKenna, aged 29 years, having had three previous pregnancies, one ending in miscarriage at three months and two full term pregnancies with spontaneous vertex deliveries, was admitted to the Royal Maternity hospital because of slight antepartum haemorrhage at thirty-five weeks' gestation.

Ultrasonic examination with the patient in the right lateral position and at umbilical level was carried out, and the picture Fig. 74 was obtained. The bulge of the placenta into the uterine cavity can be visualised.

Soft tissue placentography showed the placenta to be implanted on the left lateral wall of the upper segment. Examination under anaesthesia was carried out at 38 weeks and no placental tissue was felt in the lower segment. The patient thereafter delivered herself spontaneously of a healthy child.

There may well be a place for lateral ultrasonic studies, especially between the lower border of the thoracic case and the iliac crest.

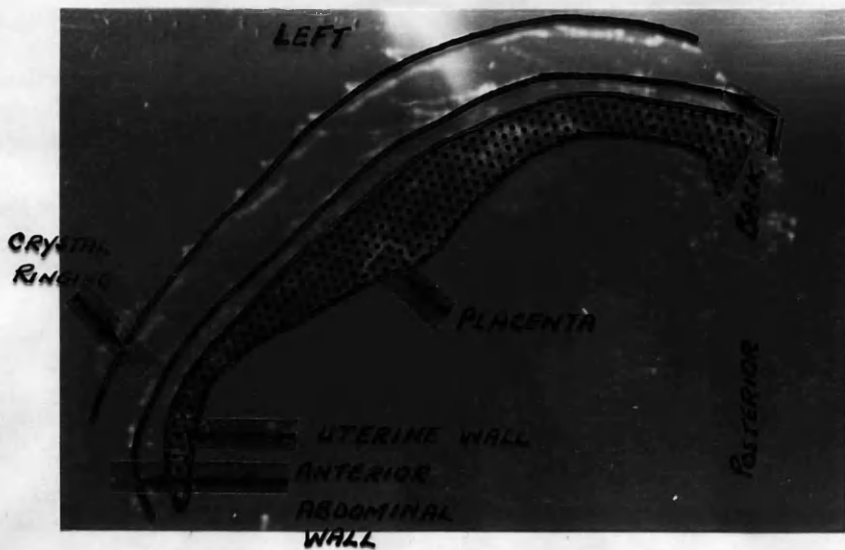


FIG. 44. PLACENTA ON LEFT SIDE OF UTERUS  
LEFT LATERAL AT UMBILICAL LEVEL  
CASE XXXV.

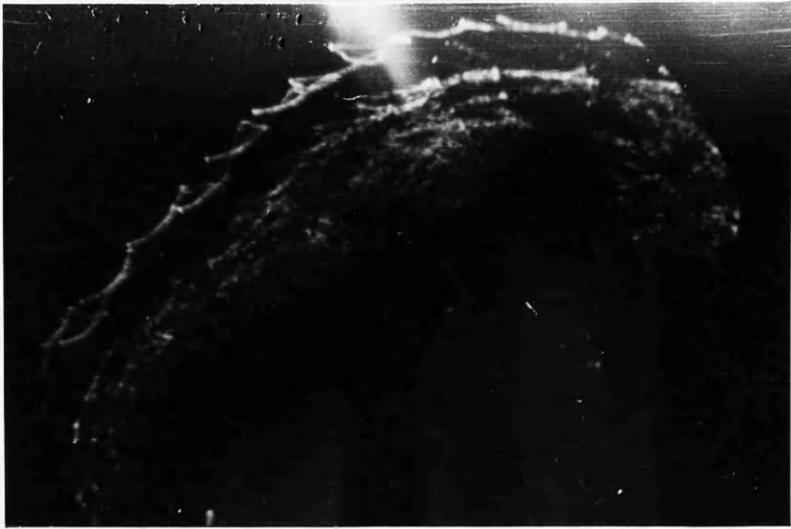

FIG. 44. PLACENTA ON LEFT SIDE OF UTERUS  
LEFT LATERAL AT UMBILICAL LEVEL  
CASE XXXV.

SUMMARY OF RESULTS.

In all, one-hundred & twenty-five patients have been examined and five-hundred records have been obtained of 'A'-scope and combined 'B'-scope and P.P.I. display. In only eight patients was the ultrasonic diagnosis, given before operation, erroneous. Two of these errors were where there was ascites present in association with a malignant ovarian cyst and the interpretation of the ultrasonic picture was negative for ascites. One case of haemoperitoneum was diagnosed ultrasonically as being normal, while the reverse mistake was also made in one case. In case XVIII the diagnosis of ovarian cyst was wrong, since a hydrosalpinx was present. In three cases there was doubt as to whether the case examined ultrasonically was one of ovarian cyst or fibromyomata. These cases were early in the series of patients, and in retrospect, the diagnosis would have been correct with proper interpretation.

Commentary and Discussion.

Having studied the results of the work carried out, assessment of the apparatus and technique must be made.

With the results obtained, it is fair to say that ultrasonic examination is a useful corroboration of clinical diagnosis.

Occasionally, where there has been doubt about the clinical diagnosis, the ultrasonic examination has assisted in making a definite decision.

With regard to gynaecological lesions, the differentiation between cysts and fibromyomata is clear. The actual type of ovarian cyst can often be diagnosed. This is occasionally of value in assessing the urgency or otherwise for operation. Actually ovarian cysts not palpable clinically have been first diagnosed on ultrasonic examination. Also, the more complex the cyst is, the more complex will be the ultrasonic picture. Cystic structures, other than pelvic cysts, have also been illustrated in cases of polycystic kidney and hydronephrosis with calculi. With regard to fibromyomata, the pictures are often variable in echo pattern. This is probably due to the actual amount of attenuation which takes place within the fibromyomata. This attenuation will depend on the actual structure of the fibromyomata, being different if there is any degeneration present. With fibromyomata, if the uterus is retroverted, bowel may lie in front of the actual mass and obscure the ultrasonic picture. Where ascites is present the picture is quite typical. There is/

is much deeper penetration of the ultrasound between the loops of bowel. The echoes are more scattered. In cases where repeated paracentesis is carried out the picture might be distorted, especially if adhesions cause encysted portions. In rare cases, clinical confusion between ascites and massive ovarian cysts may be present. In one instance, unfortunately not photographically recorded, the ultrasonic diagnosis probably saved the patient's life. The patient was admitted to the medical wards of the Western Infirmary with a diagnosis of ascites, thought to be neoplastic in origin. Attempted tapping had been carried out on several occasions. The patient's general condition was very poor. Ultrasonic examination revealed the presence of a large cyst and was so definite that on this alone laparotomy was performed. The presence of a massive ovarian cyst - a pseudomucinous cystadenoma - was confirmed at laparotomy. No ascites was present but rupture of the cyst, probably due to the paracentesis, had taken place. **Total** hysterectomy and bilateral salpingo-oophorectomy were performed. The patient is alive and well and very grateful. The normal liver would seem to be transonic and the enlarged liver examined seems also to be transonic. Whether hepatic pathology could be illustrated has still to be investigated. HOWRY maintains that he has visualised metastatic deposits in the liver. The lower part of the thoracic cage, however, makes examination of the liver singularly difficult. Similarly, examination of cases of splenomegaly may be worthy of further study. It would seem, in/



in view of the high vascularity of the spleen, that it would, in most cases, be transonic. Pus was found in the present work to be transonic. This is in contradiction to the findings of HOWRY, who thought that marked attenuation of ultrasound took place. Even theoretically HOWRY's claim is difficult to understand, since pus is basically fluid in consistency. In one instance, in the series of cases examined, a pyosalpinx showed as a cystic space.

In obstetric work the ultrasonic apparatus can also be helpful in clinical diagnosis. With regard to the early diagnosis of pregnancy, it actually shows up the foetus before radiography would have done so. This is important as a rapid confirmation of clinical assessment, where there is doubt in the patient's mind, or if she denies pregnancy. It takes about ten minutes in all to complete such an examination of the patient and develop the film for diagnosis.

Later in pregnancy the exact presentation of the foetus is sometimes difficult clinically and, where one only wants to determine the presenting part, the ultrasonic examination usually gives sufficient detail. The ultrasonic picture of the foetal head is typical. Since hazards of radiation are now so generally accepted, the curtailing of X-rays as far as possible opens up opportunity for further use of ultrasonic diagnosis. The location of the placenta would be a very great advance, but at the moment no claim of success should be made. With refinements to the apparatus, this may yet be possible. Since ultrasonic equipment can detect soft/

soft-tissue pathology which cannot clearly be shown on X-rays, there may well be a place for combined examination in certain cases.

All in all, the present work has concentrated on the diagnosis of gross pathology. The fact that one can hazard a guess - and "guess" must be emphasised - at the pathology being either malignant or simple does not merit a claim for histological diagnosis. The ultrasonic beam and wavelength is too large to be applicable to diagnosis of cell type. The frequency chosen was one to assist in the assessment of gross structures and which, for the present work, was certainly ideal. Resolution for the depth of penetration seems adequate.

### The Future?

It must be remembered, when evaluating work done in the diagnostic sphere by ultrasound, that it is less than a decade since the first experimental work was carried out. To date, much of the work has been on the diagnosis of cancer, with special reference to breast lesions, but the diagnosis of lesions elsewhere in the body still remains to be investigated. Exact location of cerebral neoplasia seems to be a field in which much useful work can be done. The use in the diagnosis of cerebral haemorrhage in the newborn has still to be investigated. Initial work, similar to the Swedish work in cerebral injuries, has been performed but results are insufficient to include in the present work.

With regard to advances which must be made with regard to the instruments, mechanical scanning must take the place of manual scanning in order to get more even and so more accurate scanning. Occasional 'gaps' seen in some of the illustrations are due to uneven scanning.

A cathode-ray tube with a long persistence used on the monitoring screen which would have persistence for minutes rather than seconds, would enable the diagnosis to be made immediately on completion of the scan, instead of waiting for the film to be developed. With such a long persistence screen, any particular part of the scan could be built-up to clarify it. At present the only available instrument is a cathode-ray tube manufactured by Ferranti, which, when acted on by infra-red light, persists for one to two minutes.

Reduction in the width of the ultrasonic beam would mean a finer scan, with less chance of distorting echoes. Focusing of the ultrasonic beam as accomplished by HOWRY could lead to greater resolution at depth. Focussing and reduction of beam-width are both technically very difficult, the latter bearing a relationship to the crystal diameter and wavelength.

Finally, a plea must be made for more honest experiment without haste to claim accurate diagnosis. Much of the work previously performed, such as that by the Japanese workers, has claimed results which are not confirmed by repeat experiment. The work done by WILD and REID has chiefly been on the diagnosis of breast carcinoma. With such high frequency and a penetration of 4 cm., only very superficial lesions can be studied. It is, also, too early to claim accuracy of diagnosis only otherwise obtained by histological examination. Yet, for work to be of value, it must be carried out in vivo, since it has been shown in this and other work that in vitro studies of tissue are completely different to those in the living state. The blood supply to a part certainly is one of the factors in this, and formalinised pathological specimens cannot be expected to give similar results to the specimens while still in vivo. Parts when studied in the living patient also have surrounding structures which help to delineate them, e.g. an ovarian cyst surrounded by bowel.

What the eventual role of ultrasound as a diagnostic aid will be can only be left to conjecture. The path is there, however, and/



BIBLIOGRAPHY

- Anderson T.P., Wakim W.G., Herrick J.F., Bennett W.A. and  
Krusen F.H. Arch. Phys. Med. 32 71 1951
- Ballantine H.T., Bolt R.H., Heuter T.F. and Ludwig G.D.  
Science 112 525-528 1950
- Barnard J.W., Fry W.J., Fry F.J. and Brennan J.F.  
Arch. Neurol. Psychiat. 74 205 1955
- Barnard J.W., Fry W.J., Fry F.J. and Krumins R.F.  
J. Comp. Neurol. 102 1955
- Delano R.B. Electronics 18 132 1946
- De Preux T. Brit. J. Phys. Med. 15 14-19 1952
- Donald I., MacVicar J and Brown T.G. Lancet 1 1188 1958
- Dussik K.T. Ztschr. F. d. ges. Neurol. U. Psychiat. 174  
153-168 1942
- Dussik K.T., Dussik J and Wyt T.W. Wien. Med. Wechr. 97  
425-429 1947
- Effert S., Erkens H and Gross-Brockhoff F. Dtsch. Med. Wschr. 82  
1253 1957
- Firestone F.A. Metal Progress 505 1945
- Firestone F.A. and Fredrick J.R. J. Acoust. Soc. Amer. 18  
200 1946
- French L.A., Wild J.J. and Neal D. Cancer 3 705-708 1950
- French L.A., Wild J.J. and Neal D. J. Neurosurg. 8 198-203 1951(a)
- French L.A., Wild J.J. and Neal D. Cancer 4 342 1951 (b)
- Freundlich H., Sollner K., and Rogowski F. Klin Wschr 11  
1512 1932
- Fry W.J., Wulff V.J., Tucker D. and Fry F.J. J. Acoust. Soc.  
Amer. 22 867 1950
- Fry W.J., Tucker D., Fry F.J. and Wulff V.J. J. Acoust. Soc.  
Amer. 23 364 1951
- Fry W.J. J. Acoust. Soc. Amer. 25 1 1953

- Fry W.J. and Fry F.J. J. Acoust. Soc. Amer. 25 6 1953
- Fry W.J., Mosberg W.H., Barnard J.W. and Fry F.J.  
J. Neurosurg. 11 471 1954 (a)
- Fry W.J., Barnard J.W., Mosberg W.H. and Krumins R.F.  
W.A.D.C. Tech. Report 54 Sept. 1954 (b)
- Fry W.J., Barnard J.W., Fry F.J. and Brennan J.F.  
Amer. J. Phys. Med. 34 413 1955 (a)
- Fry W.J., Barnard J.W., Fry F.J., Krumins R.F. and Brennan J.F.  
Science (N.S.) 122 517 1955 (b)
- Fry W.J. and Dunn F. J. Acoust. Soc. Amer. 28(2) 129 1956
- Herrick J.F. J. Acoust. Soc. Amer. 25 12 1953
- Herrick J.F. and Krusen F.H. J. Acoust. Soc. Amer. 26  
236-240 1954
- Heuter T.F. and Bolt R.H. J. Acoust. Soc. Amer. 23(2) 160-167  
1951
- Heuter T.F., Ballantine H.T. and Cotter W.C.  
J. Acoust. Soc. Amer. 28(2) 192 1956
- Horvath J. Med. Klin 1 10 1946 (a)
- Horvath J. Med. Klin 1 108 1946 (b)
- Howry D.H. J. Lab. Clin Med. 40 812-813 1952
- Howry D.H. and Bliss W.R. J. Lab. Clin. Med. 40(4) 579-592 1952
- Howry D.H., Stott D.G. and Bliss W.R. Cancer 7(2) 354 1954
- Howry D.H., Holmes J.H., Cushman C.R. and Posakony G.J.  
Geriatrics 10(3) 123-128 1955
- Howry D.H. J.R.E. Convention Records of 1955 Pt 9. 75-88
- Howry D.H., Posakony G.J., Cushman C.R. and Holmes J.H.  
J. Applied Physiol. 9 304 1956
- Imig C.J., Randall B.F. and Hines H.M. Amer. J. Phys. Med.  
33 100-102 1954
- Kikuchi Y., Uchida R., Tanaka K. and Wagai T.  
J. Acoust. Soc. Amer. 29 824 1957

- Lehmann J.F. J. Acoust. Soc. Amer. 25 17 1953
- Lehmann J.F., Erickson D.J., Martin G.M. and Krusen F.H.  
Arch. Phys. Med. 35 627-634 1954
- Lehmann J.F. and Krusen F.H. Arch. Phys. Med. 36 452-459 1955
- Leskell L. Acta Chirurg. Scand. 110 301 1955/56
- Ludwig G.D. and Struthers F.W. Naval Medical Research Institute  
Proceedings NMOD4001 Report No.4 June 1949
- Ludwig G.D. J. Acoust. Soc. Amer. 22 862-866 1950
- Lynn J.G. and Putnam T.J. Amer. J. Path. 20 637 1944
- Moncur J.A. Brit. J. Phys. Med. 20 ~~27~~ 1957
- Morrow P.L., Bierman H.R. and Jenkins R. J. Nat. Cancer Inst.  
10 843-859 1950
- Nelson P.A. Arch. Phys. Med. 31 687-695 1950
- Nelson P.A., Herrick J.F. and Krusen F.H.  
Arch. Phys. Med. 31 6-19 1950
- Pohlman H. and Reimar R. Deutsche med Wehnschr 73 373-377 1948
- Reid J.M. and Wild J.J. Electronics 25 136 1952
- Reid J.M. and Wild J.J. Electronics 28 174 1955
- Report by the Council of Physical Medicine and Rehabilitation  
J. Amer. Med. Ass. 148 646 1952
- Rubin D. and Kuitert J.H. Arch. Phys. Med. 36 445-452 1955
- Tepperberg I. and Marjey E.J. Amer. J. Phys. Med. 32 27-30 1953
- Wall P.D., Fry W.J., Stephens R., Tucker D. and Lettvin J.Y.  
Science 114(N.S.) 686 1951
- Wall P.D., Tucker D., Fry F.J. and Mosberg W.H.  
J. Acoust. Soc. Amer. 25 281 1953
- Wild J.J. Surgery 27 183-188 1950
- Wild J.J. and Neal D. Lancet 1 655 1951
- Wild J.J. and Reid J.M. Amer. J. Path. 28(2) 839-863 1952(a)



Wild J.J. and Reid J.M. Science 115 226-230 1952 (b)  
Wild J.J. and Reid J.M. J. Acoust. Soc. Amer. 25 270 1953  
Wild J.J. and Reid J.M. Cancer Res. 14 277 1954  
Wild J.J. and Reid J.M. Brit. J. Phys. Med(N.S.) 19 248 1956  
Zubiani A. Minerva Med. 42 431-436 1951