



CASE REPORT

Osseous metaplasia in chronic renal allograft rejection

Aubrey M Makhoba, Lorraine du Toit-Prinsloo

Department of Forensic Medicine, University of Pretoria, South Africa.

ABSTRACT

The formation of heterotopic bone tissue outside the skeleton, known as osseous metaplasia, is a well-known phenomenon, but only a handful of cases describe this in renal allografts. We report the case of a 26-year-old female who was admitted to hospital for repair of an arteriovenous fistula of the right arm. Following her demise, the incidental finding of osseous metaplasia in the allograft kidney was made at autopsy. The pathophysiology, histology and possible clinical significance of the lesion are described.

Keywords: allograft; transplanted kidney; osseous metaplasia.

CASE PRESENTATION

A 26-year-old female received peritoneal dialysis as a child, from 1992 to 1999 (the aetiology of the renal failure is unknown). In 1999, at age 11, a kidney transplant was performed. Subsequent complications necessitated the re-commencement of haemodialysis in 2011. An arteriovenous (AV) fistula was created for vascular access, which required surgical repair during 2014.

Surgical exploration of the right antecubital fossa revealed an aneurysm involving the fistula between the brachial artery and vein. This was repaired and a supraclavicular subclavian catheter inserted for dialysis access. Intraoperatively, the patient developed a right-sided haemothorax due to iatrogenic injury of the superior vena cava. An intravascular graft was placed, but despite all resuscitative measures, the patient died on the theatre table.

A medico-legal post-mortem examination was conducted in accordance with the provisions of the South African Health Professions Act 56 of 1974 (as amended) and the Inquests Act 58 of 1959. At autopsy, dissection of the right arm revealed a large, intact vascular aneurysm of the cephalic vein. A right-sided haemothorax and an endovascular stent graft in the superior vena cava were present.

An enlarged renal allograft (mass 380 g) was present in the right iliac fossa. The capsule of the allograft stripped with moderate difficulty and the cortical surfaces showed a fine granular consistency with focal areas of superficial and deep scarring. On sectioning, poor cortico-medullary differentiation was present. The cortices and medullae were haemorrhagic and showed focal pale zones suggestive of ischaemic infarcts. The left native kidney was atrophic (mass 24 g). No cystic lesions were noted in the kidneys. The ureters were moderately dilated, and contained no calculi or blood.

Histological examination of the allograft revealed sclerosed glomeruli. There were also enlarged glomeruli with thickened basement membranes and thickened capillary walls with lobular simplification of the tufts. Some of the glomerular tufts were collapsed. Bowman's capsules contained fluid and leukocytes. Hyaline arteriosclerosis was present. The interstitium revealed fibrosis, chronic inflammation, fresh haemorrhage and haemosiderin-laden macrophages (Figure 1).

An area of osseous metaplasia (OM) with heterotopic osseous matrix associated with osteoblasts, osteoclasts, adult adipose tissue, haemorrhage and haematopoietic



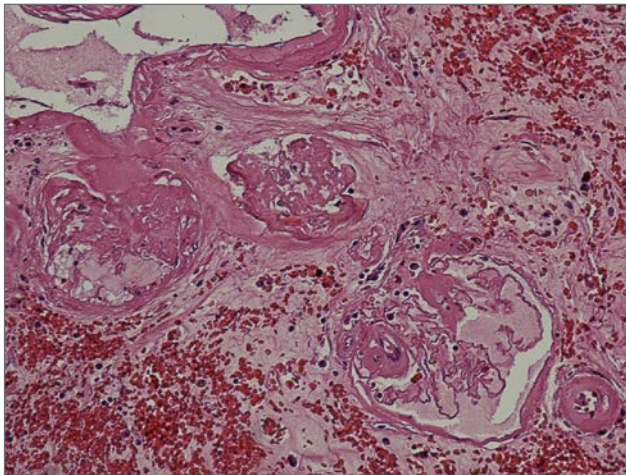


Figure 1. Transplanted kidney with collapsed glomeruli, fluid in Bowman's capsules and features of arteriolosclerosis (haematoxylin and eosin stain, original magnification x400).

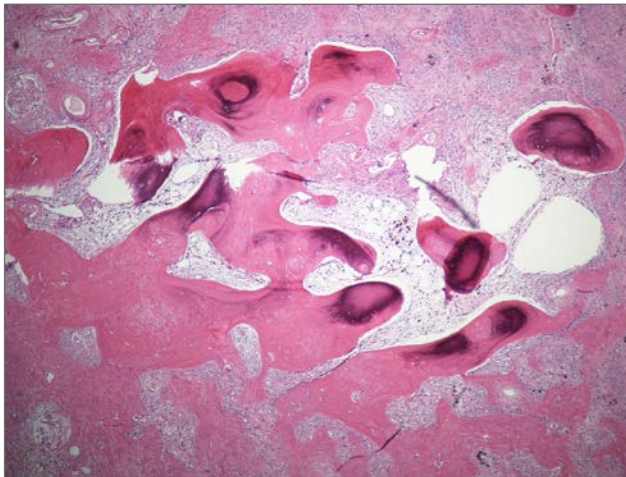


Figure 2. Section of the transplanted kidney showing osseous metaplasia with heterotopic osseous matrix associated with osteoblasts, osteoclast, adult adipose tissue, haemorrhage and haematopoietic cells (haematoxylin and eosin stain, original magnification x400).

cells was noted (Figure 2). The features were in keeping with chronic allograft rejection with a focus of OM.

DISCUSSION

Metaplasia is defined as “the change in the type of adult cells in a tissue to another form of adult cells that are not normal for that tissue” [1]. OM is the “presence of heterotopic normal bone tissue in soft tissue” [2]. The latter differs from calcification, defined as “the process by which organic tissue becomes hardened by a deposit of calcium salts within its substance” [1]. Chan et al. reported the first case of OM in a renal allograft, seven years after

transplantation. The diagnosis was made sonographically and confirmed after nephrectomy [3]. According to Sanders et al., only six cases, including their example, have been reported in the literature [4].

In non-transplanted organs, OM has been described in almost all soft tissues and organs and is usually an incidental finding. The pathophysiology thereof is currently not completely clear. Bataille et al. hypothesized chronic ischaemia and inflammation in response to immunological or infectious processes as being responsible for the ossification of renal allografts [2]. In 1920, experimental work by Asami and Dock [5] demonstrated OM after ligation of renal vessels in rabbits. These authors speculated that young fibroblasts are recruited into the renal tissue. The fibroblasts accumulate and form a membrane that deposits bone. These fibroblasts potentially represent the osteogenic precursor cells with inflammation and ischaemia providing the necessary environment required for OM formation [5]. Osteogenic precursor cells, inducing factors, and a suitable environment are proposed conditions required in the pathophysiology of heterotopic bone formation [6,7]. A protein secreted from cells of the injured tissue or from recruited inflammatory cells has been proposed as the induction signal [7]. Kaplan et al. stated that inflammatory prostaglandins and bone morphogenetic proteins are potent co-stimulatory molecules in the induction of heterotypic bone [8].

The histology of OM in renal grafts is described as similar, with metaplastic foci of bone within fibrous tissue rich in fibroblasts and swathed by lymphoid and plasma cell infiltrates [2,3,4,9]. The period between transplantation and the development of OM in allografts was mostly between six months and two years, and the longest period was seven years as described by Chan et al. [3]. In our case, OM was discovered 15 years after the transplant.

CONCLUSIONS

Although OM is a benign lesion, its presence might be an indicator of serious injury and possibly indicate imminent failure of the renal allograft. The presence of radio-dense, echogenic masses seen on imaging should alert the clinician to the possibility of OM, which should be differentiated from nephrolithiasis involving the renal pelvis [3]. OM is present in the parenchyma of all reported cases; therefore, this localisation could assist in differentiating the entity from pure calcifications which tend to involve the renal pelvis [3].

Ethics approval

Publication of this case report was approved by the Faculty of Health Sciences Research Ethics Committee at the University of Pretoria (reference number 118/2017).

REFERENCES

1. Dorland WAN. *Dorland's Illustrated Medical Dictionary*. 31st edition. Philadelphia, PA: Saunders; 2007.
2. Bataille S, Daniel L, Legris T, Vacher-Coponat H, Purgus R, Berland Y, et al. Osseous metaplasia in a kidney allograft. *Nephrol Dial Transplant*. 2010; 25(11):3796-3798. DOI: 10.1093/ndt/gfq490. PMID: 20709743.
3. Chan R, Common A, Sugar L. Sonographic appearance of renal transplant osseous metaplasia: case report. *Can Assoc Radiol J*. 1999; 50(6):390-392. PMID: 10659063.
4. Sanders BP, Orlando G, Peloso A, Katari AS, Iskandar SS, Farney AC, et al. Osseus metaplasia in kidney allografts as a paradigm of regenerative medicine principles. *Exp Clin Transplant*. 2014; 12(4):371-373. PMID: 25095714.
5. Asami G, Dock W. Experimental studies on heteroplastic bone formation. *J Exp Med*. 1920; 32(6):745-766. DOI: 10.1084/jem.32.6.745. PMID: 19868472.
6. Landim FM, Tavares JM, de Melo Braga DN, da Silva JE Jr, Bastos Filho JB, Feitosa RG. Vaginal osseous metaplasia. *Arch Gynecol Obstet*. 2009; 279(3):381-384. DOI: 10.1007/s00404-008-0706-4. PMID: 18563423.
7. McCarthy EF, Sundaram M. Heterotopic ossification: a review. *Skeletal Radiol*. 2005; 34(10):609-619. DOI: 10.1007/s00256-005-0958-z. PMID: 16132978.
8. Kaplan FS, Glaser DL, Hebel N, Shore EM. Heterotopic ossification. *J Am Acad Orthop Surg*. 2004; 12(2):116-125. PMID: 15089085.
9. Tousignant K, Phan V, Clermont MJ, Metellus K, Perreault G, Sartelet H. Bone metaplasia associated with chronic allograft nephropathy. *Kidney Int*. 2006; 70(3):407. DOI: 10.1038/sj.ki.5001678. PMID:16871250.