

# Surgical correction of aortic regurgitation using a HAART 300™ rigid aortic ring: A novel method to standardize aortic valve repair

Radosław Gocoł<sup>1</sup>, Marek Jasiński<sup>2</sup>, Damian Hudziak<sup>1</sup>, Jarosław Bis<sup>1,3</sup>, Aleksandra Żak<sup>1</sup>, Piotr Duraj<sup>1</sup>, Magdalena Mizia<sup>4</sup>, J. Scott Rankin<sup>5</sup>, Marek A. Deja<sup>1,3</sup>

<sup>1</sup>Department of Cardiac Surgery, Upper Silesian Heart Center, Katowice, Poland

<sup>2</sup>University Clinical Hospital Department of Cardiac Surgery, Wrocław Medical University, Wrocław, Poland

<sup>3</sup>Department of Cardiac Surgery, Medical University of Silesia, School of Medicine, Katowice, Poland

<sup>4</sup>1<sup>st</sup> Division of Cardiology, Upper-Silesian Heart Center, Katowice, Poland

<sup>5</sup>WVU Heart and Vascular Center, West Virginia University, United States

Due to the lack of reproducible surgical repair techniques which yield good long-term results, tricuspid aortic valve regurgitation, until recently, has been managed primarily with replacement of the valve with mechanical or biological prostheses [1]. Therefore, cardiac surgeons have been searching for repair techniques which enable the preservation of native valve for many years [2, 3]. Long-term research showed that a key factor facilitating permanent repair of the aortic valve, similar to mitral or tricuspid valves, was stabilization of the annulus. Stabilization prevents the recurrence of aortic regurgitation due to subsequent dilatation of the aortic root [4, 5]. The recently designed HAART 300™ (BioStable Science and Engineering, Austin, TX) rigid ring implanted under aortic valve cusps (Fig. 1A, B) could be a significant achievement in the area of aortic valve stabilization. The first four cases of HAART 300™ aortic ring implantation in Poland have recently been published [6].

In the present study, early results of tricuspid aortic valve repair with the use of HAART 300™ aortic ring were reviewed in a cohort of 15 patients.

Patients with moderate and severe aortic valve regurgitation were referred for aortic valve repair with the use of HAART 300™ aortic ring, according to European Society of Cardiology/European Association for Cardio-Thoracic Surgery guidelines on valvular heart disease, published in 2012 and 2017 [7, 8].

The following criteria precluded HAART 300™ aortic ring implantation: bicuspid aortic valve, infective endocarditis and significant cusp fenestrations or calcifications.

Patients with coexisting diseases requiring complex surgical procedures or reparable leaflet defects were not excluded.

Prior to surgery transthoracic echocardiography (TTE) was performed. The left ventricular end diastolic volume, left ventricular end systolic volume and left ventricular ejection fraction were calculated. The dimensions of left ventricular outflow tract, aortic root and ascending aorta were measured. The mitral and tricuspid valves were assessed. Computed tomography angiography of thoracic aorta was performed in patients with aortic dilatation to extend diagnostics and plan the scope of the operation.

When referring patients for repair surgery, El-Khoury classification [2] was used to define the type of aortic regurgitation.

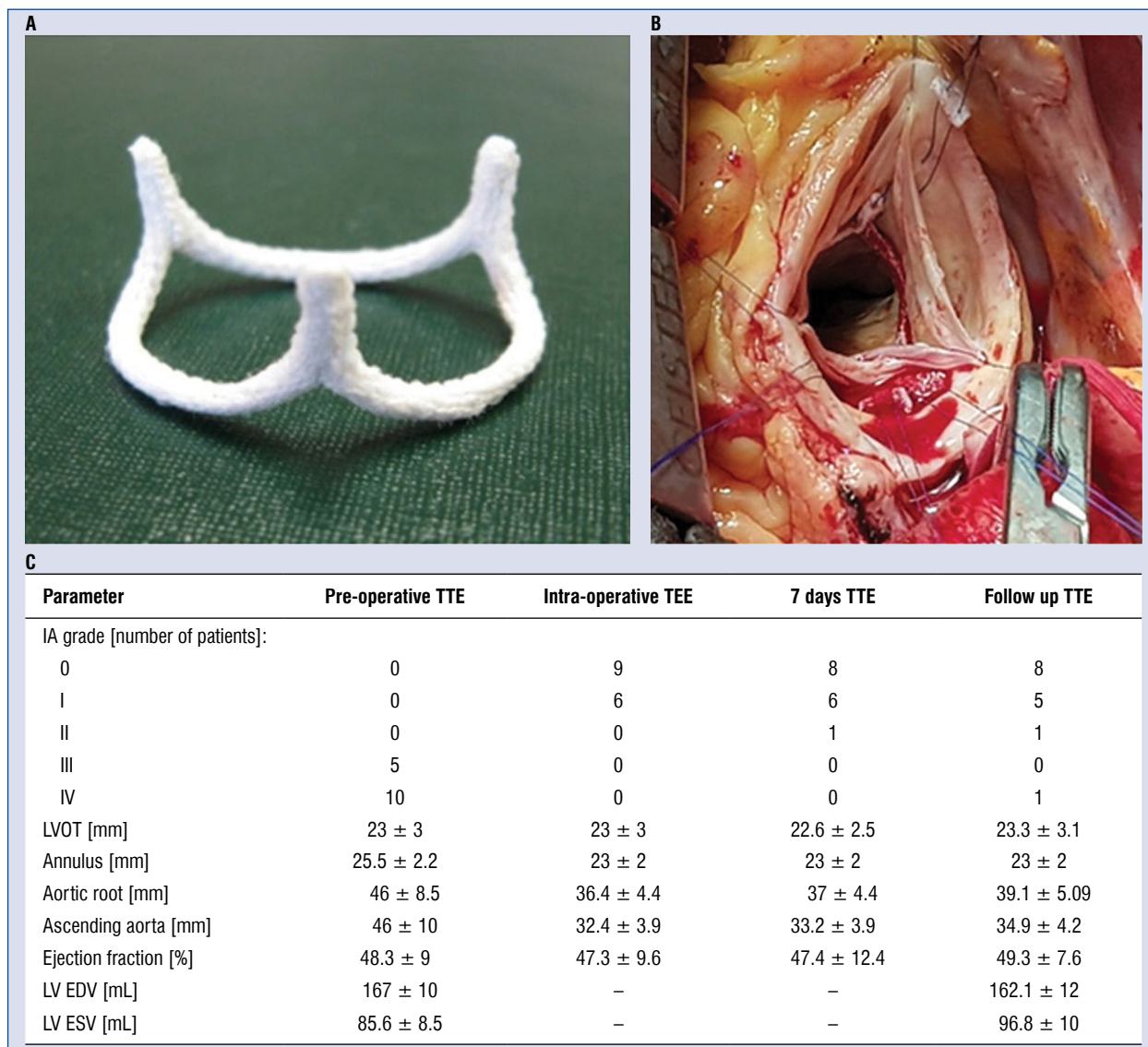
With the use of intra-operative transesophageal echocardiography (TEE), long and short axis views were acquired for measurements and assessment of the aortic valve. Measurements included: aortic annulus (aorto-ventricular junction), aortic root, sinotubular junction, and the diameter of ascending aorta.

Aortic regurgitation grade was established according to a four-point scale: 0 — none or trivial,

**Address for correspondence:** Radosław Gocoł, MD, Department of Cardiac Surgery, Upper Silesian Heart Center, ul. Ziołowa 45/47, 40–635 Katowice, Poland, tel: +48 60540155, e-mail: gocol@poczta.onet.pl

Received: 23.05.2019

Accepted: 4.11.2019



**Figure 1.** A. Rigid ring HAART 300™ (BioStable Science and Engineering, Austin, TX); B. The ring HAART 300™ underneath the cusp attachment; C. Echocardiographic data; IA — aortic regurgitation; LVOT — left ventricular outflow tract; LV EDV — left ventricular end diastolic volume; ESV — left ventricular end systolic volume; TEE — transesophageal echocardiography; TTE — transthoracic echocardiography.

I — mild, II — moderate, III — moderately severe, IV — severe [9].

For correction and stabilization of the aortic valve, a HAART 300™ (BioStable Science and Engineering, Austin, TX) was used [10]. The ring is made of a titanium stent covered with a dacron material, having an elliptic shape and three 10-degree outwardly flaring posts. The ring is available in four different sizes: 19, 21, 23, and 25 mm. The result of aortic valve repair was assessed intra-operatively by measuring the effective coaptation height with Schaffers callipers, aiming at a minimum of 9 mm. The quality of repair was also as-

sessed by echocardiography, which was performed intra-operatively (TEE), on the 7<sup>th</sup> postoperative day (TTE), and subsequently at 6 month intervals. Effective valve repair was defined as no, trivial or mild central regurgitation.

Fifteen patients aged between 53 and 73 (mean 65.6 ± 5.8) years, including 13 (86.6%) males underwent aortic valve repair with the use of HAART 300™ aortic ring during a period from September 2016 to January 2019. Eleven (73.3%) patients required cusp plication, 9 (60%) patients — replacement of the aorta (including 4 [26.6%] with co-existing aortic root aneurysm in whom

aortic root remodeling was performed), 2 (13.3%) patients required mitral valve repair, 4 (26.6%) patients received simultaneous coronary artery bypass grafts.

Intra-operative TEE assessment revealed a perfectly competent aortic valve after repair in 9 (60%) patients, mild central regurgitation in 5 (33.3%) patients, and mild non-central regurgitation in 1 (6.7%) patient (Fig. 1C). In 1 case moderate central aortic regurgitation was revealed in TEE which was related to excessive leaflet plication. During the additional period of aortic cross clamping, the single plication stitch was removed from every cusp resulting in trivial aortic regurgitation.

One patient required reoperation for bleeding. No neurological or thromboembolic complications were noted. On day 7 after surgery, 1 patient required laparotomy due to gastric ulcer perforation. Mean Intensive Care Unit stay was  $3.2 \pm 1.5$  days. The patients were discharged on day  $8.1 \pm 3.2$  post-op.

The TTE performed on day 7 after surgery revealed no aortic regurgitation in 8 (53%) patients, 6 (40%) patients presented with mild, central aortic regurgitation, and 1 (6.7%) patient progressed from mild to moderate non-central regurgitation (Fig. 1C).

Complete follow-up was available in all patients, ranging from 2 months to 30 months after surgery (mean  $257 \pm 194$  days). No deaths were noted during the follow-up period. Competent aortic valve was revealed in 8 (53%) patients and 5 (33%) patients presented with mild, central aortic regurgitation. In 1 (6.7%) patient moderate aortic regurgitation was noted on echocardiography performed 18 months after surgery (Fig. 1C). This was associated with the increase of aortic root diameter from 42 mm on discharge to 52 mm and apparent non-coronary cusp restriction. Finally, in 1 patient moderate aortic regurgitation on discharge progressed to severe within half a year and this patient underwent a redo aortic valve replacement with bioprosthesis.

Implantation of the HAART 300™ ring is a simple and reproducible aortic annuloplasty and annular stabilization technique. This method markedly simplifies the aortic valve repair procedure, and in the early experience of the documented operators, is associated with good short-term results. It provides durable protection for patients preventing recurrent aortic valve regurgitation. It does not preclude simultaneous employment of repair techniques on aortic valve cusps nor the aortic valve sparing procedure in case of co-existing root aneurysm. Moreover, this technique does not increase intra-operative mortality, nor

the rate of cardiovascular complications. It seems that the presented method of repair can be used in patients with tricuspid aortic valve regurgitation caused by one or more of the following conditions: aortic annulus dilatation, leaflet prolapse, root and/or ascending aorta aneurysm.

**Funding:** The study was funded from statutory funds of Medical University of Silesia: KNW-1-182/N/6/K and KNW-1-014/N/8/K.

**Conflict of interest:** J. Scott Rankin is the creator of the HAART 300™ ring and a consultant in the company BioStable Science and Engineering, Austin, TX.

## References

- Stephenson LW. History of Cardiac Surgery. In: Cohn LH, Edmunds LH Jr. (Hrsg.): Cardiac Surgery in the Adult. McGraw-Hill, New York (USA). 2003: 3–29.
- El Khoury G, Glineur D, Rubay J, et al. Functional classification of aortic root/valve abnormalities and their correlation with etiologies and surgical procedures. *Curr Opin Cardiol*. 2005; 20(2): 115–121, doi: [10.1097/01.hco.0000153951.31887.a6](https://doi.org/10.1097/01.hco.0000153951.31887.a6), indexed in Pubmed: [15711197](https://pubmed.ncbi.nlm.nih.gov/15711197/).
- Lansac E, Di Centa I, Raoux F, et al. A lesional classification to standardize surgical management of aortic insufficiency towards valve repair. *Eur J Cardiothorac Surg*. 2008; 33(5): 872–878, doi: [10.1016/j.ejcts.2007.12.033](https://doi.org/10.1016/j.ejcts.2007.12.033), indexed in Pubmed: [18258445](https://pubmed.ncbi.nlm.nih.gov/18258445/).
- Schäfers HJ. Aortic annuloplasty: a new aspect of aortic valve repair. *Eur J Cardiothorac Surg*. 2012; 41(5): 1124–1125, doi: [10.1093/ejcts/ezr284](https://doi.org/10.1093/ejcts/ezr284), indexed in Pubmed: [22290919](https://pubmed.ncbi.nlm.nih.gov/22290919/).
- Jasinski MJ, Gocoł R, Malinowski M, et al. Predictors of early and medium-term outcome of 200 consecutive aortic valve and root repairs. *J Thorac Cardiovasc Surg*. 2015; 149(1): 123–129, doi: [10.1016/j.jtcvs.2014.08.057](https://doi.org/10.1016/j.jtcvs.2014.08.057), indexed in Pubmed: [25439785](https://pubmed.ncbi.nlm.nih.gov/25439785/).
- Juściński JH, Koprowski A, Kołaczowska M, et al. First uses of HAART 300 rings for aortic valve repair in Poland - 4 case studies. *Kardiochir Torakochirurgia Pol*. 2018; 15(1): 38–43, doi: [10.5114/kitp.2018.74674](https://doi.org/10.5114/kitp.2018.74674), indexed in Pubmed: [29681960](https://pubmed.ncbi.nlm.nih.gov/29681960/).
- Vahanian A, Alfieri O, Andreotti F, et al. Guidelines on the management of valvular heart disease (version 2012). *Eur Heart J*. 2012; 33(19): 2451–2496, doi: [10.1093/eurheartj/ehs109](https://doi.org/10.1093/eurheartj/ehs109), indexed in Pubmed: [22922415](https://pubmed.ncbi.nlm.nih.gov/22922415/).
- Baumgartner H, Falk V, Bax JJ, et al. 2017 ESC/EACTS Guidelines for the management of valvular heart disease. *Eur Heart J*. 2017; 38(36): 2739–2791, doi: [10.1093/eurheartj/ehx391](https://doi.org/10.1093/eurheartj/ehx391), indexed in Pubmed: [28886619](https://pubmed.ncbi.nlm.nih.gov/28886619/).
- Zoghbi WA, Adams D, Bonow RO, et al. Recommendations for Noninvasive Evaluation of Native Valvular Regurgitation: A Report from the American Society of Echocardiography Developed in Collaboration with the Society for Cardiovascular Magnetic Resonance. *J Am Soc Echocardiogr*. 2017; 30(4): 303–371, doi: [10.1016/j.echo.2017.01.007](https://doi.org/10.1016/j.echo.2017.01.007), indexed in Pubmed: [28314623](https://pubmed.ncbi.nlm.nih.gov/28314623/).
- Rankin JS, Mazzitelli D, Fischlein T, et al. Geometric ring annuloplasty for aortic valve repair during aortic aneurysm surgery: two-year clinical trial results. *Innovations (Phila)*. 2018; 13(4): 248–253, doi: [10.1097/IMI.0000000000000539](https://doi.org/10.1097/IMI.0000000000000539), indexed in Pubmed: [30138245](https://pubmed.ncbi.nlm.nih.gov/30138245/).