

## CASE REPORT

# Pyogenic Granuloma on Facial Skin Associated With Long-Term Topical Application of Tacrolimus

George Badavanis<sup>1</sup>, Efstathia Pasmatzis<sup>2</sup>, Pavlos Constantinou<sup>3</sup>,  
Nikiforos Kapranos<sup>4</sup>, Frank Schmidt<sup>5</sup>, Alexandra Monastirli<sup>1,2</sup>,  
Dionysios Tsambaos<sup>1,2</sup>

<sup>1</sup>Center for Dermatologic Diseases,  
Limassol, Cyprus

<sup>2</sup>Department of Dermatology, School of  
Medicine, University of Patras, Greece

<sup>3</sup>Histopathology & Cytology  
Laboratory, Nicosia, Cyprus

<sup>4</sup>Laboratory for Molecular  
Histopathology, Athens, Greece

<sup>5</sup>Sanitätsversorgungszentrum  
Kramerhof, Germany

**KEY WORDS:** *Pyogenic granuloma;*  
*tacrolimus; FK506; calcineurin*  
*inhibitors; seborrheic dermatitis*

**ABBREVIATION LIST:**

PG: Pyogenic granuloma

SD: Seborrheic dermatitis

AIDS: Acquired immune deficiency  
syndrome

HCT: Hematopoietic cell transplantation

TGF- $\beta$ : Transforming growth factor- $\beta$

TLR4: Toll-like receptor 4

ROS: Reactive oxygen species

*Correspondence to:*

Efstathia Pasmatzis, M.D.

Associate Professor

Department of Dermatology

School of Medicine, University of Patras

PO Box 1413, 26504 Rio-Patras, Greece

Tel.: +30 2610 270 577

Fax: +30 2610 270235

E-mail: [pasmatzis@med.upatras.gr](mailto:pasmatzis@med.upatras.gr)

[pasmatzis@otenet.gr](mailto:pasmatzis@otenet.gr)

*Manuscript received June 15, 2019;*

*revised manuscript received October 26, 2019;*

*Accepted October 27, 2019*

## ABSTRACT

Pyogenic granuloma, a benign skin vascular neoplasm, may be idiopathic but it is often related to several exogenous stimuli. In the present case it appeared in the skin of the right cheek of a 35-year-old man with a history of prolonged topical application of a tacrolimus ointment in this skin area, for the treatment of a severe facial seborrheic dermatitis resistant to any other topical therapeutic procedure. The granuloma was excised and the clinical diagnosis was histologically confirmed. The complete laboratory investigation was negative for any underlying disorder. Although several side-effects of topical application of tacrolimus have been referred, the appearance of pyogenic granuloma seems to be a very rare complication only of systemically administered tacrolimus. We believe that this is the first report of such a side-effect associated with topical application of tacrolimus on the skin. The possible pathogenetic mechanisms are discussed.

## INTRODUCTION

Pyogenic granuloma (PG) is a common benign vascular neoplasm of the skin and mucous membranes. It is typically characterized by the occurrence of solitary and rarely multiple, rapidly developing, hemorrhagic and ulceration-prone, pink or purple, angiomatous papules or nodules. PG is conventionally thought to represent a reactive lesion that usually arises in response to diverse stimuli such as minor trauma and chronic irritation, infections, viral oncogenes, pregnancy, microscopic arteriovenous anastomoses and various drugs<sup>1-3</sup>. However, several studies have shown that in most cases PG develops without any preceding injury or predisposing dermatosis<sup>2,4</sup>.

Seborrheic dermatitis (SD) is a chronic relapsing cutaneous disorder, clinically characterized by the presence of pink or erythematous thin plaques covered by fine, oily, whitish or yellowish scales, typically located on the face and scalp. Its prevalence ranges from 3% to 10% in the general population, whereas it is higher in patients with AIDS, neurological disorders (e.g. Parkinson's disease) and other chronic diseases (e.g.

**Funding Sources:** none

**Conflicts of Interest:** none

alcoholic pancreatitis and alcoholism, myocardial infarction)<sup>5</sup>. Topical corticosteroids and antifungals are the most commonly used drugs for the treatment of SD, whereas calcineurin inhibitors (tacrolimus and pimecrolimus) represent a second-line therapy for resistant cases.

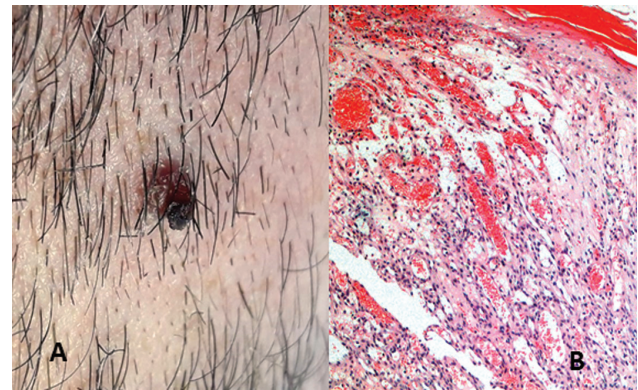
Tacrolimus (FK506) is a macrolide, produced by *Streptomyces tsukubaensis*, which exerts its potent immunosuppressive effects through inhibition of calcineurin. Tacrolimus binds to the intracytoplasmic protein FKBP-12 creating a new complex which binds to calcineurin and inhibits its phosphatase activity. This effect blocks the dephosphorylation and nuclear translocation of the transcription factor, inhibiting thereby the synthesis of interleukin 2 and other cytokines critical to T-cell activation<sup>6,8</sup>. In the last two decades systemic therapy with tacrolimus has played a pivotal role in the management of patients with solid organ and hematopoietic cell transplantation (HCT)<sup>6</sup>. Topically applied tacrolimus has been approved for the treatment of patients with moderate to severe atopic dermatitis unresponsive or intolerant to conventional regimens, but it has also been used as an off-label treatment for various cutaneous diseases<sup>7</sup>.

We present herein the case of a 35-year-old man who developed PG on his face after long-term topical application of tacrolimus ointment for treatment of SD.

#### CASE REPORT

A 35-year-old, HIV-negative and otherwise healthy Caucasian man presented to the Center for Dermatologic Diseases in Limassol, Cyprus, with a 5-week-history of a solitary, rapidly growing and easily bleeding exophytic cutaneous lesion on his right cheek, that had appeared after a long term application of tacrolimus (Protopic ointment 0.1%, Astellas Pharma GmbH, Munich, Germany). In 2006 he developed a severe facial SD that was resistant to all modes of topical treatment, apart from tacrolimus that the patient used to apply on his facial skin every 2-3 days over a period of 12 years.

Physical examination showed a smooth red dome-shaped nodule (8 mm in diameter) on the right cheek that was covered by a partially hemorrhagic crust (Figure 1A), indicative of PG. Since PG rarely resolves spontaneously and often repeatedly bleeds, the patient refused any other treatment options and the lesion was surgically excised under local anesthesia. The formalin-fixed and paraffin-embedded surgical specimen was submitted for histopathological examination. The latter confirmed the clinical diagnosis of PG revealing numerous capillaries within a loose and edematous framework of connective tissue surrounded by a mixed inflammatory infiltrate (Figure 1B). The patient, a physician himself, didn't recall any trauma or other chronic irritation at the site of his recently emerging solitary lesion. The results of routine hematological, biochemical and serological tests were either negative or within normal



**FIGURE 1. A.** Smooth red dome-shaped nodule on the right cheek, covered by a partially hemorrhagic crust. **B.** Histological examination of skin lesion shows numerous capillaries within a loose and edematous framework of connective tissue surrounded by a mixed inflammatory infiltrate. (H&E X 20 original magnification).

range. Finally, the patient switched to other forms of therapy.

#### DISCUSSION

The most important side-effects of systemic tacrolimus include nephrotoxicity, post-transplant diabetes mellitus, neurotoxicity, alopecia, hyperkalemia, hypomagnesemia, hypertension, hyperlipidemia, gingival hyperplasia and hirsutism<sup>6</sup>. In sporadic cases, systemic tacrolimus is able to induce oral inflammatory fibro-vascular polypoid soft tissue masses in patients with HCT<sup>8</sup>, however the occurrence of histologically confirmed PG is extremely rare<sup>9</sup>. The most common adverse-reactions occurring after topical application of tacrolimus, according to the drug's label, are erythema, pruritus, burning sensation, pain and paresthesia at the site of application, acne and increased risk of folliculitis and herpetic infections.

The exact pathogenetic mechanisms of PG still remain unknown; however, there is accumulating evidence suggesting that an imbalance between angiogenesis enhancers (increased expression of vascular endothelial growth factor, basic fibroblast growth factor and decorin) and angiogenesis inhibitors (reduced expression of angiostatin) may be of importance in the pathogenesis of PG<sup>10,11</sup>. Interestingly, in vitro studies showed that tacrolimus: 1. Is capable of inducing vascular inflammation, endothelial activation and production of inflammatory cytokines through Toll-like receptor 4 (TLR4) activation and reactive oxygen species (ROS) generation in endothelial cells<sup>12</sup>; 2. Can stimulate vascular smooth muscle cells proliferation through activation of TGF- $\beta$ <sup>13</sup>; 3. Induces proliferation of endothelial cells derived from umbilical vein<sup>14</sup>. Moreover, a recent genetic study on vessels derived

from cutaneous PG lesions identified genes of the nitric oxide pathway and those related to hypoxia-induced angiogenesis and vascular injury, like the tyrosine-kinase receptor FTL4<sup>15</sup>. Interestingly, Groesser et al<sup>4</sup> found out that endothelial cells in the lesional but not in the perilesional skin exhibit the BRAF c.1799T>A mutation in sporadic and secondary PG and identified this mutation as a major driver in the pathogenetic mechanisms of both types of this vascular neoplasm.

In view of these findings it seems possible that in our patient, endothelial cells -upon exposure to topical tacrolimus- revealed an enhanced expression of angiogenetic and proinflammatory molecules, that led to the development of PG.

To the best of our knowledge the case presented here is the first report of PG possibly associated with long-term topical application of tacrolimus on the skin. Naturally, the possibility that the occurrence of PG in our patient was unrelated to topical tacrolimus cannot be definitely ruled out; however, it seems unlikely in view of the occurrence of the lesion in the strict area of tacrolimus application and of the absence of other predisposing factors. In conclusion, PG should be considered as a possible rare side-effect of topically applied tacrolimus. Physicians must be aware of this rare adverse reaction and capable of diagnosing and properly managing it.

## REFERENCES

1. Lin RL, Janniger CK. Pyogenic granuloma. *Cutis* 2004;74:229–233.
2. Patrice SJ, Wiss K, Mulliken JB. Pyogenic granuloma (lobular capillary hemangioma): a clinicopathologic study of 178 cases. *Pediatr Dermatol* 1991;8:267-276.
3. Pagliai KA, Cohen BA. Pyogenic granuloma in children. *Pediatr Dermatol* 2004;21:10-13.
4. Groesser L, Peterhof E, Evert M, et al. BRAF and RAS mutations in sporadic and secondary pyogenic granuloma. *J Invest Dermatol* 2016;136:481-486.
5. Sampaio AL, Mameri AC, Vargas TJ et al. Seborrheic dermatitis. *An Bras Dermatol* 2011;86:1061-1071.
6. Shrestha BM. Two decades of tacrolimus in renal transplant: Basic science and clinical evidences. *Exp Clin Transplant* 2017;15:1-9.
7. Sehgal VN, Srivastava G, Dogra S. Tacrolimus: approved and unapproved dermatologic indications/uses - physician's sequential literature survey: part II. *Skinmed* 2008;7:73-77.
8. Al-Mohaya M, Treister N, Al-Khadra O, et al. Calcineurin inhibitor-associated oral inflammatory polyps after transplantation. *J Oral Pathol Med* 2007;36:570-574.
9. Cheney-Peters D, Lund TC. Oral pyogenic granuloma after bone marrow transplant in the pediatric/adolescent population: Report of 5 Cases. *J Pediatr Hematol Oncol* 2016;38:570-573.
10. Yuan K, Jin YT, Lin MT. The detection and comparison of angiogenesis-associated factors in pyogenic granuloma by immunohistochemistry. *J Periodontol* 2000;71:701-709.
11. Nelimarkka L, Salminen H, Kuopio T, et al. Decorin is produced by capillary endothelial cells in inflammation-associated angiogenesis. *Am J Pathol* 2001;158:345-353.
12. Rodrigues-Diez R, González-Guerrero C, Ocaña-Salceda C et al. Calcineurin inhibitors cyclosporine A and tacrolimus induce vascular inflammation and endothelial activation through TLR4 signaling. *Sci Rep* 2016;13:27915. doi: 10.1038/srep27915.
13. Giordano A, Romano S, Mallardo M, et al. FK506 can activate transforming growth factor-beta signalling in vascular smooth muscle cells and promote proliferation. *Cardiovasc Res* 2008;79:519–526.
14. Giordano A, Romano S, Monaco M, et al. Differential effect of atorvastatin and tacrolimus on proliferation of vascular smooth muscle and endothelial cells. *Am J Physiol Heart Circ Physiol* 2012;302:H135-H142.
15. Godfraind C, Calicchio ML, Kozakewich H. Pyogenic granuloma, an impaired wound healing process, linked to vascular growth driven by FLT4 and the nitric oxide pathway. *Mod Pathol* 2013;26:247-255.