

Research Article

Agreement Test of Documentation of Visual Inspection with Acetic Acid "DoVIA" and Colposcopy findings as a Screening Tool for Cervical Cancer

Kesesuaian Hasil Tes Dokumentasi Inspeksi Visual dengan Asam Asetat (DoVIA) dan Kolposkopi sebagai Alat Skrining untuk Kanker Serviks

Laila Nuranna¹, Renny S. Wardany², Gatot Purwoto¹, Tofan W. Utami¹, Lex Peters³

¹Department of Obstetrics and Gynecology

²Faculty of Medicine, Universitas Indonesia

Dr. Cipto Mangunkusumo General Hospital, Jakarta, Indonesia

³Department of Obstetrics Gynecology Oncology,
Leiden University Medical Center, Netherlands

Abstract

Objective: To find out the suitability of Documentation of Visual Inspection with Acetic Acid (DoVIA) result compare to colposcopy result as a method of cervical cancer screening.

Methods: This is a descriptive study using a cross-sectional design that took place from April 2017 until March 2019. One hundred eighty-two samples of documentation photographs taken by the researcher were included. The photographs were reviewed by the 3 selected reviewers: oncology and gynaecology consultant, obstetrics and gynaecology resident, and general practitioner that were trained about DoVIA and colposcopy. The review was based on the kappa test which assessed the sharpness, squamocolumnar junction and white epithelial visualization on the cervix.

Results: Kappa score on DoVIA versus colposcopy was 0,717 (good). Inter-rater test was performed to assess consistency and the result was 0,764 (good) between consultant and resident, 0,703 (good) between consultant and general practitioner.

Conclusions: Kappa test of VIA documentation "DoVIA" gives a good kappa value, so that it is expected to be an alternative screening for precancerous lesions.

Keywords: cervical cancer screening, colposcopy, DoVIA, mini colposcopy, VIA

Abstrak

Tujuan: Untuk menemukan kesesuaian antara dokumentasi hasil inspeksi visual dengan asam asetat (DoVIA) dibanding dengan hasil kolposkopi sebagai metode skrining kanker serviks.

Metode: Penelitian deskripsi ini menggunakan desain potong lintang yang telah dilakukan sejak April 2017 hingga Maret 2019. Seratus delapan puluh dua sampel dokumentasi telah diambil oleh peneliti telah dimasukkan menjadi sampel. Hasil dokumentasi telah dinilai oleh 3 penilai yang terdiri dari konsultan onkologi dan ginekologi, residen obstetri dan ginekologi, dan dokter umum yang telah dilatih untuk DoVIA dan kolposkopi. Hasil penilaian dilakukan berdasarkan kappa untuk menilai ketajaman, sambungan skuamos kolumnar dan visualisasi lesi putih di serviks.

Hasil: Skor kappa pada DoVIA dibanding kolposkopi adalah 0,717 (baik). Hasil perbandingan penilaian antar penilai yang ditunjukkan untuk menilai konsistensi dan hasil adalah 0,764 (baik) antara konsultan dan residen, 0,703 (baik) antara konsultan dan dokter umum.

Kesimpulan: Tes kappa pada dokumentasi IVA (DoVIA) memberikan hasil kappa baik, sehingga DoVIA diharapkan dapat menjadi alternatif skrining untuk lesi prakanker.

Kata kunci: DoVIA, IVA, kolposkopi, minikolposkopi, skrining kanker serviks.

Correspondent author. Laila Nuranna. lailaril@gmail.com

INTRODUCTION

Cervical cancer becomes the 4th cause of death in woman around the world through 2012, following breast cancer, colon cancer and gastric cancer. This disease has 528.000 new cases and 266.000 mortality number, almost 80% of new cases found in developing country annually.^{1-3.}

In 2012, data collected by thirteen Pathology Centers in Indonesia placed cervical cancer in the second rank of malignancies in women with its incidence of 20.928 new cases each year and occur most frequently among 15-44 years old reproductive-age women.^{4,5} Unfortunately, 70% patients come in the advanced stage and give unsatisfactory outcome afterwards. Furthermore, their 5-year life expectancy is far lower than those who came in earlier stages.^{4,6,7}

The efforts to detect cervical cancer in the early precancerous stage are very instrumental in reducing the mortality rate of cervical cancer.⁴ A simpler and more capable alternative screening is needed to be a screening method that can cover any level of society with limited resources.⁸

In the early development, cervical cancer does not have typical symptoms, so it is recommended to undergo screening as early as possible. One of the policies recommended in developed countries used the Pap test screening method with its sensitivity of 78-93%. This method was introduced by Dr. George Papanicolau since 1940. Nevertheless, this examination do not escape from false positive and false negative ranging consecutively from 16-37% and 7-40%, which caused by the sample preparation, the process in the sample preparation and how to read the results.¹

Here in after, we have colposcopy method which use a low-powered microscope with a light source to visualize the patterns of vascular and metabolic changes in the cervix. However, providing colposcopy in many health services requires very high cost.⁸⁻¹⁰

On the other hand, VIA is a good alternative screening for cervical cancer because it has good value sensitivity of 90% and specificity of 92%.^{8,11} The advantages of VIA test are practical, inexpensive, simple, non-invasive, broad in scope,

and can be done at the level of health services with limited facilities.⁸

Looking on its benefit of VIA as an alternative screening, the idea arises to conduct an VIA documentation examination using a cell phone camera which in principle can resemble a colposcopy based on visualization checks, and this examination is called "DoVIA", leading to the idea called Mini Colposcopy, by visual observation without a magnifying device for the detection of cervical cancer.⁸⁻¹⁰

DoVIA is conducted before and after applying 5% acetic acid, after that we take photos on the cervix using a cell phone camera with at least 13 megapixels of resolution and autofocus as well. DoVIA results are printed with print photos afterwards. Moreover, this examination is easy to do, easy to carry, inexpensive compared to Colposcopy, can be accessed by transferring the results through telecommunications media "TeleDoVIA", can be stored and printed when needed, furthermore, it can be used as education and training of cervical cancer screening.⁸⁻¹⁰

This study using cell phone cameras for VIA documentation, this makes us interested in examining the appropriateness of the "DoVIA" using *cohen kappa* analysis between the result of cellular telephone's camera devices used in DoVIA and the result of Colposcopy.

METHODS

This is a cross-sectional study. Data were collected from the VIA documentation using cellular telephone's camera devices and colposcopy. We recruited the data from a woman with a history of sexual contact or sexually active who will undergo an examination in RSUPN Dr. Cipto Mangunkusumo from April 2017 to March 2019. We calculated the sample size based on the prior data of disease prevalence and got 176 samples. Samples were recruited with consecutive sampling in the obstetrics and gynecology outpatient clinic. Collected data were analyzed using the Statistical Program for Social Sciences (SPSS) 20. Kappa test was done to evaluate consistency among examiners. Ethical clearance was obtained from the Health Research Ethics Committee, Faculty of Medicine, Universitas Indonesia.

RESULTS

There were 182 photos of "DoVIA" and colposcopy included, from April 2017 – March 2019 and there is no dropout. Baseline characteristics of the subjects are presented in Table 1.

Table 1. Sample Characteristics Based on Age, Diagnosis and Quality of the Picture

Variable	n	%
Age (Years)		
20 – 30	17	9.3
31 – 50	140	76.9
> 50	25	13.7
Diagnosis		
VIA positive	27	15
VIA negative	143	78.6
Cervicitis	9	5
Others (e.g.: condyloma, polyp, etc.	3	1.6
Malignancy suspect	0	0
Quality of the picture		
VIA documentation		
Good and enough quality	182	100
Poor quality	0	0
Colposcopy		
Good and enough quality	123	68
Poor quality	59	32

We compared the VIA documentation "DoVIA" with colposcopy for validation. All 182 samples were validated by one Oncologist Consultant, one Obgyn resident, and one general practitioner. We analyzed each assessment using Kappa score to assess the consistency between examiners. We concluded Kappa score on DoVIA versus colposcopy validated by Oncologist Consultant, Obgyn resident, General practitioner, was 0,717 (good). The results of the assessment by three observers were written in Table 2.

Table 2. Validation DoVIA Compare Colposcopy Analyzed Using Kappa score

Validated by	Kappa Score DoVIA Compare with Colposcopy
Oncologist	0.723
Obgyn Resident	0.7
General Practitioner	0.741

We analyzed using inter-rater agreement test to assess consistency, this compared the pictures assessment done by oncology consultant with resident obstetrics and gynecology, and general practitioner who was trained about VIA and cervix assessment. The results were written in Table 3.

Table 3. Validation DoVIA Compare Colposcopy Analyzed Using Kappa Score

Validated by	Kappa Score DoVIA Compare with Colposcopy
Oncologist vs Obgyn Resident	0.764
Oncologist vs General Practitioner	0.703

The following are examples of research data sample collection using cell phone camera devices "DoVIA" and using colposcopy

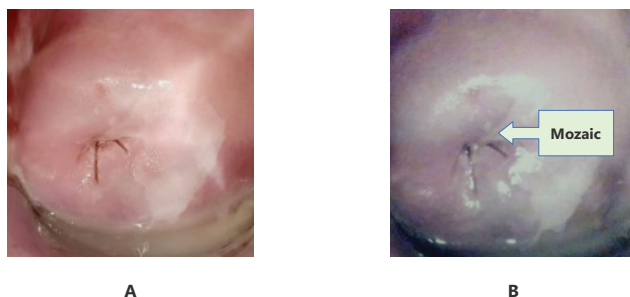


Figure 1. a. DoVIA (seen positive VIA, mozaic) b. Colposcopy

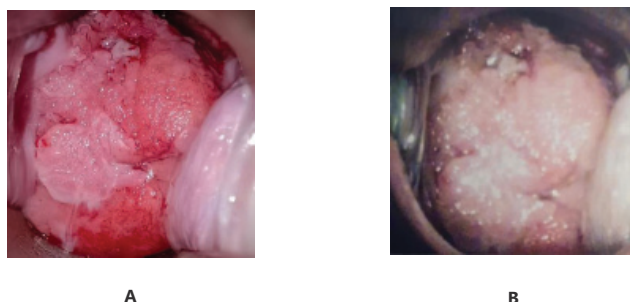


Figure 2. a. DoVIA (seen positive condiloma cervix) b. Colposcopy

DISCUSSION

Patient's Characteristics

From a total of 182 samples, 78.6% had negative VIA and 15% had positive VIA. Samples with positive VIA 1.09% were 20 – 30 years old, 12.08% were 31 – 50 years old. Five per cent of the samples were diagnosed with cervicitis, and the rest of the samples were diagnosed with either condyloma or polyp. None of the samples was suspected of having carcinoma.

All of the documentations VIA (100%) were in good quality. On the other hand, 68% of the colposcopy results were in good quality and 32% were in poor quality. Lower quality of the

colposcopy results might be originated from the lack of competence of the researcher in using colposcopy, and moreover the limited capability of the colposcopy device, outdated tools that needed to be calibrated in order to get a brighter documentation.

Documentation of Visual Inspection with Acetic Acid "DoVIA" and Colposcopy Result

Photography method which were Samsung SGH_U900®, and Oppo F9 to evaluate cervical pictures between a gynaecologist and a trained midwife or nurse. Pictures that were taken, were transmitted via WhatsApp to be evaluated. The Kappa result was 0,71 ($P < 0,001$) which showed that Samsung SGH-U900®, Oppo F9 could be used as a telemedicine mobile in cervical cancer screening in rural areas.⁹

Another study compared VIAM whit colposcopy to detect precancer lesion and cervical cancer. The study reported VIA sensitivity in CIN 2 was 61.7%, VIAM 88.3%, and colposcopy 86.7%. The specificity was 58.5% using VIA, 55.8% using VIAM, and 90.4% using colposcopy. The agreement score of VIAM and colposcopy was moderate in detecting CIN 1 and higher degree lesion ($k, 0,48$; CI 95%, 0.41 to 0.54) and was excellent in detecting CIN 2 and higher degree lesion ($k, 0,85$; CI 95%, 0.81 to 0.54). Modified cervicography could be the reliable documentation alternative with VIA sensitivity 96%, modified cervicography sensitivity 97%, VIA specificity 90.9%, and modified cervicography specificity 90.9%. Kappa result for modified cervicography was 0.957 and for colposcopy werw 1.¹²

Colposcopy device used in this research was a German made Kaps SOM Colposcopes 52/42 series that was 10 years old. Colposcopy used halogen coaxial light 12V/100W (direct), it was completed with standing lamp and a rotating green filter. The standardized distant from the device to cervix was 25 – 30 cm. Colposcopy examination was a diagnostic standard tool for cervical abnormality. The device could visualize vascular pattern.

The documentations that were taken before and after VIA test, had their shortage when they were printed. They could be visualized compared to the printed by colposcopy screen. However, training for obstetrics and gynaecology residents is needed to be skilful in using colposcopy by this finding they can use by DoVIA.

Our study had a good kappa result. This was supported by several studies before that reported higher resolution device could improve pictures quality. Trained gynecologist and oncologist, obstetrics and gynecology resident, general practitioner were involved in this study. Agreement test among observers was done by calculating the kappa score which was 0.717. The inter-rater assessment was also done between a gynecologist and oncologist and an obstetrics and gynecology resident (Kappa 0.764); between a gynecologist and oncologist and a general practitioner (Kappa 0.703).

In a further development of DoVIA method, health care workers can use their cellphones to send DoVIA results to make a consultation with experts.¹³

Advantage and Weakness of The Study

Review by one oncologist and gynecologist is the weakness of the study. This was overcome by involving trained obstetrics and gynecology resident and general practitioner. DoVIA method is easier to do than colposcopy. General practitioners and midwives can use this method continued with online consultations with experts. Economically, Do VIA method is cost-effective. Furthermore, it reduces surgical early detection method of cervical cancer in hospitals.

CONCLUSION

Documentation using cell phone cameras devices "DoVIA" have better value compare with colposcopy for cervical cancer screening, and DoVIA can be used as an alternative screening.

REFERENCES

1. Jemal A, Bray F, M M, Ferlay J, Ward E. Global Cancer Statistics. *Carcinoma cervix* 61. 2011; 61: 69-90.
2. Kementerian Kesehatan RI. Direktorat Jenderal Pengendalian Penyakit dan Penyehatan Lingkungan Direktorat Pengendalian Penyakit Tidak Menular. Panduan Program Nasional Gerakan Pencegahan dan Deteksi Dini Kanker Leher Rahim dan Kanker Payudara. 2015: 4.
3. Andrijono. Kanker serviks. 3 ed. Jakarta: Divisi Onkologi Departemen Obstetri dan Ginekologi FKUI. 2010: 3.
4. Nuranna L, Aziz MF, Cornain S, et al. Cervical cancer prevention program in Jakarta, Indonesia: See and Treat model in developing country. *Gynecol Oncol*. 2012; 23(3): 147-52.
5. ICO. Information Centre on HPV Human Papilloma Virus and Related Diseases, Summary Report; 2014.
6. Organization WH. Comprehensive Cervical Cancer Control; A guide to Essential Practice. Geneva: WHO; 2006.
7. Sjamsuddin S. Pencegahan dan Deteksi Dini Kanker Serviks. *Cermin dunia kedokteran*. 2001:8-13.
8. Nuranna, L. Skrining Kanker Serviks Dengan IVA (Dikembangkan Dengan DoVIA Dan TeleDOVIA) .2019:30.
9. Quinley KE, Gormley RH, Ratcliffe SJ, et al. Use of mobile telemedicine for cervical cancer screening. *USA: J Telemed Telecare*. 2013: 203-9.
10. Nazeer S, IM, Shafi. Objective perspective in colposcopy. *Best Practice & Research Clin Obstet Gynecol*. 2011; 25: 631-40.
11. Sanad AS, Kamel HH, Hasan MM. Prevalence of cervical intraepithelial neoplasia (CIN) in patients attending Minia Maternity University Hospital. *Arch Gynecol Obstet* .2014; 289: 1211-7.
12. H.S. Cronje. Screening for cervical cancer in developing countries. *Int J Gynecol Obstet*. 2004;517-29.
13. Nuranna L, Hadisty A. Telaah Pemanfaatan Telemedicine DoVIA dalam Skrining Kanker Serviks Oleh Praktisi Medis di Indonesia, Jakarta : Universitas Indonesia. 2019:1.