

## Research Article

# The Suppression Effect of Kebar Extract on Endometriosis Lesion, MDA and TNF- $\alpha$ , Independent to VEGF: A Study in Endometriosis Mice Model

## Efek Supresi Ekstrak Kebar terhadap Lesi Endometriosis, MDA dan TNF- $\alpha$ , tidak Bergantung pada VEGF: Studi pada Model Tikus Endometriosis

Yuli Trisetiyono<sup>1</sup>, Noor Pramono<sup>1</sup>, Syarief T. Hidayat<sup>1</sup>, Widjiati<sup>2</sup>

<sup>1</sup>Division of Reproductive Endocrinology and Infertility  
Department of Obstetrics and Gynecology

Faculty of Medicine Universitas Diponegoro, Semarang

<sup>2</sup>Department of Embriology, Faculty of Veterinary Medicine  
Universitas Airlangga, Surabaya

### Abstract

**Objective:** To investigate the effects of Kebar grass (*Biophytum petersianum*) extract administration to MDA serum levels, TNF- $\alpha$  and VEGF expression, and the extension of the endometriotic lesions in mice model.

**Methods:** This study was experimentally designed. It was conducted in the Department of Obstetrics Gynecology, Faculty of Medicine Universitas Diponegoro and Faculty of Veterinary Medicine, Universitas Airlangga. Twenty-one mice were divided into three groups: the first group is control of 7 untreated endometriosis mice model, the second group consisted of 7 mice injected with leuprolide acetate 1mg/kgBW single dose, and the last group consisted of 7 mice fed with Kebar grass extract 3mg/day for 14 days. MDA serum level was measured by spectrophotometry, TNF- $\alpha$  and VEGF expression by IHC using Rammele Scale Index (Immuno Reactive Score), whereas the extension of the endometriotic lesions was measured using computerize tracing.

**Results:** Both Kebar grass extract and leuprolide acetate administration significantly decrease MDA serum levels in endometriosis mice model, compare with the control group, ( $0.09 \pm 0.02$  nmol,  $0.11 \pm 0.07$  nmol, and  $0.30 \pm 0.06$  nmol, respectively;  $p=0.001$ ). TNF- $\alpha$  expression of the group treated with Kebar grass extract was lower than leuprolide acetate and control group ( $2.43 \pm 1.521\%$ ,  $4.86 \pm 0.458\%$ , and  $7.26 \pm 2.898\%$ , respectively;  $p=0.002$ ). However, there was no significant difference in VEGF expression among study groups ( $4.34 \pm 2.40\%$ ,  $5.11 \pm 1.95\%$ , and  $7.40 \pm 3.49\%$  respectively;  $p=0.116$ ). Finally, the extension of the endometriotic lesions of the mouse models administered with Kebar grass extract and leuprolide acetate was smaller than the control group ( $0$  mm<sup>2</sup>,  $4.54 \pm 7.75$  mm<sup>2</sup>, and  $34.80 \pm 13.09$  mm<sup>2</sup> respectively;  $p=0.005$ ).

**Conclusions:** Kebar grass extract has the effect of decreasing MDA serum levels and reducing TNF- $\alpha$  expression, resulted in smaller endometriotic lesions in mice, even though it does not affect VEGF expression.

**Keywords:** biophytum petersianum, endometriosis, malondialdehyde, tumour necrosis factor-alpha, vascular endothelial growth factor.

### Abstrak

**Tujuan:** Mengetahui efek pemberian ekstrak Rumput Kebar (*Biophytum petersianum*) terhadap kadar MDA serum, ekspresi TNF- $\alpha$  dan VEGF jaringan, serta luas implan endometriosis pada tikus model.

**Metode:** Penelitian eksperimental di Departemen Obstetri Ginekologi Fakultas Kedokteran Universitas Diponegoro dan Fakultas Kedokteran Hewan Universitas Airlangga, menggunakan 21 ekor mencit dibagi tiga kelompok, yaitu kelompok kontrol mencit model endometriosis yang hanya diberi pakan biasa, kelompok kedua diberi injeksi leuprolide asetat 1mg/kgBB, dan kelompok ketiga diberi ekstrak rumput Kebar 3mg/hari selama 14 hari. Pemeriksaan MDA dari serum diukur dengan spektrofotometri, ekspresi TNF- $\alpha$  dan VEGF dari implan endometriosis di peritoneum diukur secara IHC menggunakan Immuno Reactive Score, sedangkan luas implan endometriosis diukur dengan tracing komputer.

**Hasil:** Ekstrak rumput Kebar dan leuprolide asetat secara signifikan menurunkan kadar MDA serum pada tikus model endometriosis, dibandingkan kelompok kontrol ( $0.09 \pm 0.02$  nmol,  $0.11 \pm 0.07$  nmol, dan  $0.30 \pm 0.06$  nmol;  $p=0,001$ ). Ekspresi TNF- $\alpha$  kelompok perlakuan rumput Kebar lebih rendah dibandingkan kelompok leuprolide asetat dan kontrol ( $2,43 \pm 1,521\%$ ,  $4,86 \pm 0,458\%$ , dan  $7,26 \pm 2,898\%$ ;  $p=0.002$ ). Akan tetapi tidak didapatkan perbedaan ekspresi VEGF yang signifikan pada semua kelompok perlakuan ( $4,34 \pm 2,40\%$ ,  $5,11 \pm 1,95\%$ , dan  $7,40 \pm 3,49\%$ ;  $p=0,116$ ). Luas lesi endometriosis pada tikus model yang diberi ekstrak rumput Kebar dan leuprolide asetat lebih kecil dibandingkan kontrol ( $0$  mm<sup>2</sup>,  $4.54 \pm 7.75$  mm<sup>2</sup>, dan  $34.80 \pm 13.09$  mm<sup>2</sup>;  $p=0,005$ ).

**Kesimpulan:** Pemberian ekstrak rumput Kebar dapat menurunkan kadar MDA serum dan mengurangi ekspresi TNF- $\alpha$ , serta mengurangi luas lesi endometriosis pada tikus model, meskipun tidak mempengaruhi ekspresi VEGF jaringan.

**Kata kunci:** *Biophytum petersianum*, endometriosis, malondialdehyde, tumour necrosis factor alpha, vascular endothelial growth factor

## INTRODUCTION

Endometriosis is a common gynecological disease, characterized by endometrial tissue growth outside the womb cavity.<sup>1</sup> The pathogenesis of endometriosis remains unclear and involves multifactorial etiologies. Several recent studies have shown the Oxidative Stress (OS) is known to be associated with this disease. OS increases angiogenesis and supports the proliferation of endometriosis tissue in the peritoneal cavity.<sup>2</sup> Vascular Endothelial Growth Factor (VEGF) is an essential angiogenesis agent involved in the development of ectopic lesions and show the emergence of many vascularizations. VEGF receptor expression is also often found in the deep infiltrative endometriosis.<sup>3,4</sup> Oxidative stress produces reactive oxygen species (ROS), causes inflammation which is characterized by recruiting lymphocytes and macrophage activation, produces cytokines that induce oxidation enzyme, and supports endothelial growth, and it also plays a vital role in the development of endometriosis disease.<sup>5-7</sup> Increased ROS in the peritoneum causes an inflammatory reaction that later may pass through surveillance due to immune system dysfunction. Endometriosis lesion has anti-apoptotic and pro-proliferative properties that let the lesion grow and spread. Besides, the ectopic endometrial tissue, especially in the peritoneum, can survive due to estrogen support and resistance to progesterone, as well as blood supply formed by angiogenesis.<sup>1,7,8</sup>

Kebar grass is a medicinal plant that has long been used by Papuans empirically to support fertility and relieve menstrual disorders such as irregular cycles and pain.<sup>9</sup> As an herbal medicine, these plants are a source of phytochemicals that generally have potent antioxidant activity, and they are believed to play a role in the mechanism of antioxidant defense against the OS.<sup>10</sup> Some studies have found that Kebar grass contains alkaloid compounds, steroids, flavonoids, triterpenoids, glycosides, vitamin E, mineral elements and amino acids, which are potential sources of antioxidants.<sup>11,12</sup>

This study examined the endometriotic mice model given with Kebar grass extract, compared with the mice injected by leuprolide acetate and untreated control group. It aims to evaluate Kebar grass potency to decrease oxidative stress,

inflammation, angiogenesis, and reduce the extent of endometriosis lesions.

## METHODS

This study employs an experimental study in mice and has acquired ethical approval. The study was conducted in Reproductive Endocrinology & Infertility Division Department of Obstetrics and Gynecology, Faculty of Medicine, Universitas Diponegoro and Faculty of Veterinary Medicine of Universitas Airlangga. The samples were three months old Balb/c female mice weighing 15-20 grams. Twenty-one mice were included in the study, which was obtained from sample calculations using the equation of resources formula.<sup>13</sup> They were divided into three groups, each consisting of seven mice: a group of endometriotic mice without treatment as the control (C), a group of endometriotic mice injected with Leuprolide Acetate (LA), and groups of endometriotic rats were fed with Kebar Grass Extract (KGE). KGE was processed in the laboratory of the Pharmacy Faculty, Universitas Diponegoro using an ethanol solvent maceration method. Human endometrial tissues were obtained from women underwent hysterectomy for benign uterine disease, washed twice with Phosphate-Buffered Saline (PBS) and mixed as crude fragments in PBS with penicillin 200 IU/ml and streptomycin 200 µg/ml. Endometrial tissues solution 0.1 ml was injected intraperitoneally using 16G needle to the mice, followed by injection of 0.2 ml cyclosporine-A i.m and 5.4 µg 17β-estradiol i.m on day 1 and day 5.<sup>14</sup> Starting from day fourteenth, the C group received daily feed only, whereas the LA group received injection of 1 mg/kg BW leuprolide acetate s.c single dose, and the KGE group got daily administration of 3 mg/day Kebar grass extract for fourteen days. All mice were sacrificed on day twenty-eighth, using ketamine 100 mg/kg BW, while taking blood samples from their hearts for malondialdehyde (MDA) serum examination by spectrophotometry. Mice were killed by cervical dislocation, followed by opening the peritoneal cavity to measure the area of endometriotic lesions by tracing computerized with the Motic Image<sup>®</sup> software. Then, peritoneum with endometriotic lesions was sent to the laboratory for immunohistochemical examination of Tumor Necrosis Factor Alpha (TNF-α) expression by TNFα (52B83): sc-52746 antibody, and Vascular Endothelial Growth Factor

(VEGF) expression by VEGF(C-1):sc-7269 antibody referring to the Rammele Scale Index (Immuno Reactive Score).<sup>15</sup>The data obtained were statistically analyzed by SPSS. The differences were significant when  $p < 0.05$ .

## RESULTS

### MDA Serum Level

The means of MDA serum levels in the C group, LA group, and KGE group were  $0.30 \pm 0.06$  nmol,

$0.11 \pm 0.07$  nmol, and  $0.09 \pm 0.02$  nmol, respectively (table 1), the non-parametric analysis by Kruskal-Wallis test resulted in significant difference among study groups ( $p = 0.001$ ). The Mann-Whitney post hoc test showed the MDA serum levels of the mice in LA group and KGE group were significantly lower compared to the C group (both  $p = 0.001$ ), and the MDA serum level of the KGE group was not significantly different from the LA group ( $p = 0.80$ ).

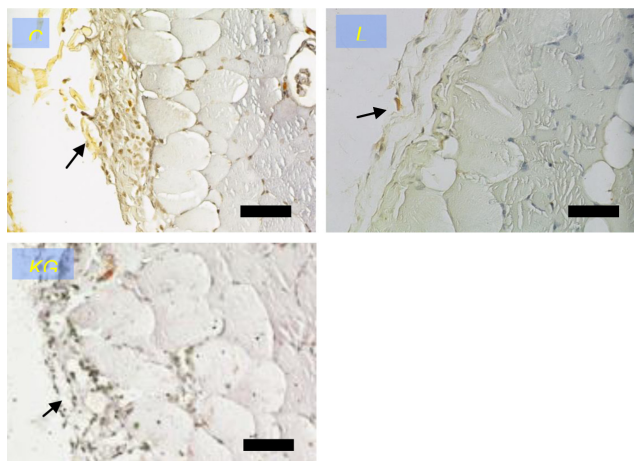
**Table 1.** MDA Levels, TNF- $\alpha$  and VEGF Expression of Endometriosis Mouse Models

Groups	MDA		TNF- $\alpha$		VEGF	
	Mean $\pm$ SD	P-value*	Mean $\pm$ SD	P-value*	Mean $\pm$ SD	P-value*
C	$0.30 \pm 0.06$		$7.26 \pm 2.898$		$7.40 \pm 3.49$	
LA	$0.11 \pm 0.07$	0.001	$4.86 \pm 0.458$	0.002	$5.11 \pm 1.95$	0.116
KGE	$0.09 \pm 0.02$		$2.43 \pm 1.521$		$4.34 \pm 2.40$	

\*Kruskal-Wallis test, \*\*Oneway ANOVA test

### TNF- $\alpha$ Expression

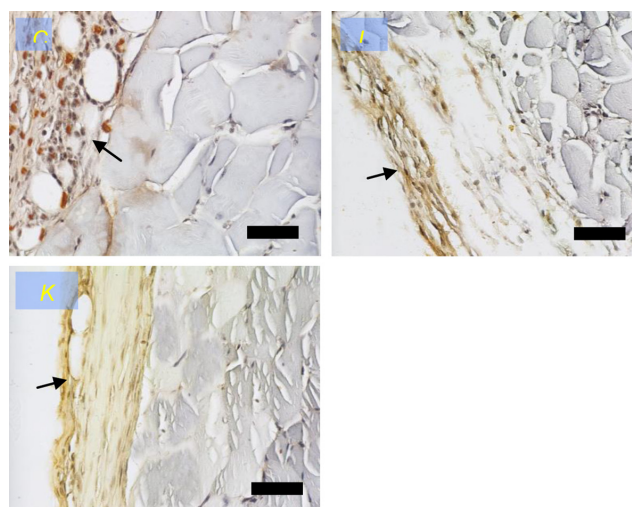
Immunohistochemical staining of peritoneal tissue in figure 1 shows the lowest intensity of TNF- $\alpha$  expression in the KGE group. The means of TNF- $\alpha$  expression in peritoneal tissue of endometriosis mouse models of the C group, LA and KGE group were  $7.26 \pm 2.90$  %,  $4.86 \pm 0.46$  %, and  $2.43 \pm 1.52$  %, respectively (Table 1). The Kruskal-Wallis test resulted in significant difference among study groups ( $p = 0.002$ ). The Mann-Whitney post hoc test resulted in TNF- $\alpha$  expression in the KGE group has significant difference compared with the C group ( $p = 0.001$ ) and LA group ( $p = 0.001$ ).



**Figure 1.** Histochemical immunostaining of TNF- $\alpha$  expression. C: Control group; LA: Leuprolide acetate group; KGE: Kebar grass group. (Nikon H600L microscope; 300 megapixel DS camera; black bar: 10 $\mu$ m).

### VEGF Expression

Immunohistochemical staining of peritoneal tissue in figure 2 shows the lowest intensity of VEGF expression in the KGE groups. The means of VEGF expression on peritoneal tissue of endometriosis mouse of the C group, LA group, and KGE group were  $7.40 \pm 3.49$  %,  $5.11 \pm 1.95$  % and  $4.34 \pm 2.40$  %, respectively (table 1). From the ANNOVA test, there was no significant difference among study groups ( $p = 0.116$ ).



**Figure 2.** Histochemical immunostaining of VEGF expression. C: Control group; LA: Leuprolide acetate group; KGE: Kebar grass group. (Nikon H600L microscope; 300 megapixel DS camera; black bar: 10 $\mu$ m).

### Endometriotic Lesions Extension

The mean of endometrial lesion areas in mice peritoneal tissue in the C group was  $34.80 \pm 13.08$  mm<sup>2</sup>, LA group was  $4.54 \pm 7.75$  mm<sup>2</sup>, and there was no lesion was seen in mice peritoneum of the KGE extract group (table 2). The Kruskal-Wallis test showed significant difference among study groups ( $p=0.001$ ), and Mann-Whitney post hoc test revealed the mean of endometrial lesions area in both KGE and LA group were significantly different compared to the C group ( $p=0.001$ ), and there was no significant difference between KGE and LA group ( $p=0.383$ ).

**Table 2.** The Area of the Endometriotic Lesions in the Mice Peritoneum

Groups	Lesions	
	Mean (SD)	P-value*
C	$34.80 \pm 13.09$	0.001
LA	$4.54 \pm 7.75$	
KGE	$0.00 \pm 0.00$	

\*Kruskal-Wallis test

### DISCUSSION

Endometriosis is a chronic disease characterized by growth and proliferation of endometrial tissue outside the womb cavity.<sup>1,16</sup> Currently, various studies have shown the role of oxidative stress and antioxidants in the pathogenesis of endometriosis.<sup>17</sup> Kebar grass is one of Indonesia's medicinal plants originally from Papua and traditionally used as fertilizing support. It is also believed to treat menstrual disorders such as irregular cycles and menstrual pain.<sup>9,11</sup> Kebar grass extract contains biflavones and flavonoids that may increase the conversion of estradiol to estrone, inhibit aromatization activity, and induce apoptosis in cancer cells and endometriosis. Kebar grass also contains vitamin C, vitamin E and other compounds with natural antioxidant activity.<sup>12</sup> Kebar grass may have an essential role in the reproductive system because of its secondary metabolite from flavonoids, which belongs to plant hormones (phytohormones) that can affect reproductive hormones.<sup>11</sup>

The results are relevant to another study, where the researcher gave 24mg/day curcumin supplements for 14 days as an antioxidant in endometriosis mice, they found lower ovarian MDA titers than the control group.<sup>18</sup> Another

study provided vitamin C 500 mg/kg every two days intravenously to endometriosis mice found a smaller proportion of endometriosis implants than the control group.<sup>19</sup>

TNF- $\alpha$  expression in Kebar group, had a significant difference compared with the control group and leuprolide group. Vitamin C and vitamin E in Kebar grass extract may be potent anti-inflammatory to decrease biomarkers like TNF- $\alpha$ . The study results correspond with another study that administered a combination of vitamin E 1000 mg/day and vitamin C 1000 IU/day for four weeks to the elderly who had fasting glucose disorder. They found decreased levels of isoprostane-8 and TNF- $\alpha$ .<sup>20</sup>

Kebar grass contains flavonoids and vitamin E. Some studies show that flavonoids and vitamin E can reduce the release of in vitro VEGF.<sup>21</sup> Another study used phytopharmaca containing isoflavone genistein for six months to patients with endometrial hyperplasia and found a significant reduction in VEGF, EGF, and TGF $\beta$  expressions.<sup>22</sup> Similarly, another phytopharmaca study found that isoflavone may have an anti-estrogenic effect and was able to reduce VEGF level in endometrial cell culture. Higher isoflavone dose and more prolonged incubation tend to decrease the VEGF-A level.<sup>23</sup> The results of this study indicate a real difference of VEGF expressions among all study groups. However, based on the analysis, the differences were not significant. Even though the results were not significantly different, we tried to identify the reason by kept on post hoc test. Negative 95% CI in post hoc Bonferroni test showed insignificant difference as the result of a small number of samples. Further research is needed by carrying more samples and examining other angiogenesis markers.

This study showed that both of Kebar grass extract and leuprolide acetate had a better effect in reducing endometriosis lesions compared to the control group. The results were similar to a study that investigated changes in the pattern of inflammatory reactions, microvessel density and apoptosis of collected tissue from women with endometriosis, adenomyosis and uterine myomas treated with Gn-RH a, suggesting that leuprolide acetate results in decreased tissue inflammation, angiogenesis, and endometriotic lesions area.<sup>24</sup> Kebar grass extract contains vitamin C, vitamin

E, and isoflavones which have potent antioxidant effects of reducing oxidative stress that occurs in the pathogenesis of endometriosis.<sup>25-27</sup> Besides, a study found that a combination of vitamin E 1200 IU and vitamin C 1000 mg daily given to endometriosis patients for eight weeks can reduce the degree of pelvic pain.<sup>28</sup> Kebar grass also contains daidzein phytohormone in high concentrations can reduce the risk of advanced endometriosis by interacting with estrogen receptors.<sup>29</sup>

This research has some limitations. Firstly, the research was applied to the experimental animal due to the absence of toxicity test against Kebar extract. Secondly, treatment given to each group used different ways that may affect the pharmacological treatment and the body's response of the mice. The study also did not combine Kebar extract and leuprolide acetate, so it did not answer whether Kebar grass can strengthen the therapeutic effect of leuprolide acetate on endometriosis in mice. However, the overall results of this study show that Kebar grass extract has a good effect on endometriosis disease. Thus, further investigation is needed to be conducted to consider Kebar grass as an indigenous Indonesian medicine that can be used as an alternative therapy for endometriosis.

### CONCLUSION

The administration of Kebar grass extract resulted has decreased of MDA serum level and reduced TNF- $\alpha$  expression, resulted in smaller endometriotic lesions in endometriosis mice, but it does not affect on VEGF expression.

### ACKNOWLEDGEMENTS

The authors would like to acknowledge the excellent and efficient teaching staff of Reproductive Endocrinology and Infertility Subspecialist Education of Universitas Diponegoro laboratory staff of Pharmacy Faculty of Universitas Diponegoro, and also laboratory staff of the Veterinary Faculty of Universitas Airlangga.

### REFERENCES

1. Fritz MA, Speroff L. Endometriosis. In: Clinical gynecologic endocrinology and infertility. 8th ed. Philadelphia: Lippincott Williams & Wilkins. 2011: 1221-48.
2. Sekhon LH, Agarwal A. Endometriosis and oxidative stress. In: Agarwal A, Aziz N, Rizk B, editors. Studies on women's health. New York: Humana Press. 2013: 149-67.
3. Kralickova M, Vetricka V. Role of angiogenesis in endometriosis. *Pathol Discov*. 2016;4(1):1-5.
4. Rocha ALL, Reis FM, Taylor, RN. Angiogenesis and endometriosis. *Obstet Gynecol Int*. 2013;2013:1-8.
5. Grund EM, Kagan D, Tran CA, Zeitvogel A, Starzinski-Powitz A, Nataraja S, et al. Tumor necrosis factor- $\alpha$  regulates inflammatory and mesenchymal responses via mitogen-activated protein kinase, p38, and nuclear factor B in human endometriotic epithelial cells. *Mol Pharmacol*. 2008;73:1394-404.
6. Sanchez G, Zubor P, Szunyogh N, Kajo K, Machalekova K, Biringer K, et al. [TNF-alpha serum levels in women with endometriosis: prospective clinical study]. *Ces Gynecol*. 2005;70(4):286-90.
7. Sourial S, Tempest N, Hapangama DK. Theories on the pathogenesis of endometriosis. *Int J Reprod Med*. 2014;2014:1-9.
8. Harada T, Taniguchi F, Izawa M, Ohama Y, Takenaka Y, Tagashira Y, et al. Apoptosis and endometriosis. *Front Biosci*. 2007;12:3140-51.
9. Sadsoeitoeboen PD. [Benefits of Kebar Grass extract (Biophytum petersianum Klotzsch) on the reproductive appearance of white female mice]. *IPB*. 2005: 1-45.
10. Alok S, Jain SK, Verma A, Kumar M, Mahor A, Sabharwal M. Herbal antioxidant in clinical practice: a review. *Asian Pac J Trop Biomed*. 2014;4(1):78-84.
11. Sukarsono. [Profile of secondary metabolite content of medicinal plants *Biophytum petersianum* and *Biophytum sensitivum*]. *J Gamma*. 2012;6(1):69-76.
12. Sembiring B, Darwati I. [Identification of chemical components of accession of Kebar Grass (*Biophytum petersianum*) from Papua and Java]. *Obat BPTD dan*, editor. 2014;25(1):37-44.
13. Charan J, Kantharia ND. How to calculate sample size in animal studies? *J Pharmacol Pharmacother*. 2013;4(4):303-6.
14. Hendarto H, Widjiati, Johari S. [Curcumin supplementation to improve oocyte maturation and results of in vitro fertilization in endometriosis mice]. *Maj Obstet Ginekol*. 2014;22(2):53-7.
15. Nowak M, Madej JA, Dziegiel P. Intensity of cox2 expression in cells of soft tissue fibrosarcomas in dogs as related to grade of tumour malignancy. *Bull Vet Inst Pulawy*. 2007;51:275-9.
16. Crosignani P, Olive D, Bergqvist A, Luciano A. Advances in the management of endometriosis: an update for clinicians. *Hum Reprod Update*. 2006;12(2):179-89.

17. Gupta S, Chandra A, Kesavan S, Eapen D, Agarwal A. Oxidative Stress and the Pathogenesis of Endometriosis. In: Garcia-Velasco JA, Rizk BRMB, editors. Endometriosis: Current management and future trends. Cleveland. Cleveland Clinic. 2010: 31–9.
18. Panjaitan BC, Sa'adi A, Hendarto H, Widjiati. Comparison of ovarial malondialdehyde (MDA) level between endometriosis rat given with and without curcumine supplementation. *Maj Obstet Ginekol.* 2012;20(1):30–4.
19. Erten OU, Ensari T gba A, Dilbaz B, Cakiroglu H, Altinbas SK, Çaydere M, et al. Vitamin C is effective for the prevention and regression of endometriotic implants in an experimentally induced rat model of endometriosis. *Tai J Obstet Gynecol.* 2016;55:251–7.
20. Rizzo MR, Abbatecola AM, Barbieri M, Vietri MT, Cioffi M, Grella R, et al. Evidence for anti-inflammatory effects of combined administration of vitamin E and C in older persons with impaired fasting glucose: impact on insulin action. *J Am Coll Nutr.* 2008;27(4):505–11.
21. Schindler R, Mentleint R. Flavonoids and Vitamin E Reduce the Release of the Angiogenic Peptide Vascular Endothelial Growth Factor from Human Tumor Cells. *J Nutr.* 2006;136:1477–2006.
22. Granese R, Bitto A, Polito F, Triolo O, Giordano D, Santamaria A, et al. Genistein reduces angiogenesis and apoptosis in women with endometrial hyperplasia. *Bot Targets Ther.* 2014;5(5):27–32.
23. Jehanara, Sutrisno, Santoso S. [Effect of Genistein on Decreasing Vascular Levels of Endothelial Growth Factor-A in Endometriosis Cell Culture]. *Maj Obstet Ginekol.* 2014;22(2):94–100.
24. Khan KN, Kitajima M, Hiraki K, Fujishita A, Sekine I, Ishimaru T, et al. Changes in tissue inflammation, angiogenesis and apoptosis in endometriosis, adenomyosis and uterine myoma after GnRH agonist therapy. *Hum Reprod.* 2010;25(3):642–53.
25. Jackson LW, Schisterman EF, Dey-Rao R, Browne R, Armstrong D. Oxidative Stress and Endometriosis. *Hum Reprod.* 2005;20(7):2014–20.
26. Agarwal A, Gupta S, Sikka S. The role of free radicals and antioxidants in reproduction. *Curr Opin Obstet Gynecol.* 2006;18(3):325–32.
27. Agarwal A, Gupta S, Agarwal A, Krajcir N, Alvarez JG. Role of oxidative stress in endometriosis. *Reprod Biomed Online.* 2006;13(1):126–34.
28. Santanam N, Kavtaradze N, Murphy A, Dominguez C, Parthasarathy S. Antioxidant supplementation reduces Endometriosis related pelvic pain in humans. *Transl Res J Lab Clin Med.* 2014;161(3):189–95.
29. Tsuchiya M, Miura T, Hanaoka T, Iwasaki M, Sasaki H, Tanaka T, et al. Effect of soy isoflavones on endometriosis: interaction with estrogen receptor 2 gene polymorphism. *Epidemiol.* 2007;18(3):402–8.