

Generalized hereditary gingival fibromatosis in a child: clinical, histopathological and therapeutic aspects

John Lennon Silva Cunha^a , Maria Alice Carvalho da Cruz Ramos^b ,
Débora Menezes Regis^b , Celeste Sánchez-Romero^a , Maria Eliane de Andrade^c ,
Bruno Torres Bezerra^b , Ricardo Luiz Cavalcanti de Albuquerque-Júnior^c 

How to cite: Cunha JLS, Ramos MACC, Regis DM, et al. Generalized hereditary gingival fibromatosis in a child: clinical, histopathological and therapeutic aspects. *Autops Case Rep* [Internet]. 2020 Jan.-Mar.;10(1):e2020140. <https://doi.org/10.4322/acr.2020.140>

ABSTRACT

Hereditary gingival fibromatosis (HGF) is a rare genetic condition characterized by slow and progressive gingival enlargement. The gingival overgrowth often delays teeth eruption and may cause serious functional and aesthetic problems. We reported a case of a 10-year-old female child presenting a generalized gingival enlargement covering almost all the maxillary and mandibular teeth and resulted in problems for swallowing, speaking, and poor aesthetics. An incisional biopsy was performed and revealed a hypocellular and hypovascular dense collagenous tissue covered by squamous epithelium exhibiting acanthosis and elongated rete ridges. The diagnosis was HGF. The treatment instituted was an association of gingivectomy with a rigorous program of oral hygiene and follow-up. Herein, we describe a rare non-syndromic case of generalized HGF, including clinical and microscopical features, as well as highlighting the importance of correct diagnosis of this genetic condition.

Keywords: Gingiva; Gingivectomy; Fibromatosis, Gingival; Dentition, Permanent.

INTRODUCTION

Hereditary gingival fibromatosis (HGF) is a rare benign disease characterized by a progressive increase in gingival tissue.^{1,2} This condition can be generalized or localized, with varying degrees of severity.³ The gingival overgrowth often delays teeth eruption and may cause severe functional and aesthetic problems⁴. Also, HGF may occur as an isolated disease or associated with several syndromes.^{1,4,5} Usually, it presents an autosomal dominant inheritance pattern, although with variable penetrance and expressivity, or, less frequently, an autosomal recessive inheritance pattern.⁶

As hereditary gingival fibromatosis does not resolve spontaneously, the treatment of choice is surgical removal of excess gingival tissue.⁷ The gingivectomy is usually the most employed technique and has high efficacy.³ The surgical approach minimizes the negative psychological effect in the patient and functional and aesthetic impairment, improving the quality of life.^{3,8} However, follow-up and effective oral hygiene instructions are necessary for avoiding relapses.^{1,3,7}

Herein, we describe a rare non-syndromic case of generalized HGF in a child, including clinical

^a University of Campinas (UNICAMP), Piracicaba Dental School, Department of Oral Diagnosis. Piracicaba, SP, Brazil.

^b Tiradentes University, Department of Dentistry. Aracaju, SE, Brazil.

^c Tiradentes University, Institute of Technology and Research, Laboratory of Morphology and Experimental Pathology. Aracaju, SE, Brazil.



and microscopical features, as well as highlighting the importance of correct diagnosis of this genetic condition.

CASE REPORT

A 10-year-old afrodescendant female child was referred to the oral medicine service of the School of Dentistry at Tiradentes University, with a chief complaint of a painless gingival swelling causing difficulty in mastication and committed aesthetic. No other symptoms were present. During the anamnesis, the patient's mother also denied the presence of systemic alterations and chronic use of medications and stated that noted gingival enlargement from 5 years of age. The gingival enlargement had been initially noticed during a deciduous dentition, but it became more intense during the period of permanent dentition. She also stated that the pregnancy and the time of delivery had no interurrences. Moreover, there are no congenital or acquired diseases, and there is no history of genetic anomalies in the family. However, family history revealed that similar features were seen in her father. Her mother was unaffected. Past medical history was not contributory.

Extraoral clinical examination revealed elevated lips, marked open bite, and difficulty of the passive lip seal. The intraoral clinical examination revealed a generalized gingival enlargement covering almost all the maxillary and mandibular teeth and resulted under problems for swallowing, speaking, and poor aesthetics. The swelling presented a predominantly rough texture, with a pink color, and fibrous consistency, associated with areas of melanic pigmentation and evident

hyperemia of the gingival margins in the anterior vestibular region. In the palatal region, it extended toward the midline, partially obliterating the depth of the palate. The teeth were displaced, with crowns partially or totally immersed in the fibrotic tissue (Figures 1A and B). Additionally, the gingiva was painless on palpation. Hematological tests were normal and ruled out any systemic association. The panoramic radiograph was requested (Figure 1C) and showed normal development of the dentition.

All permanent teeth were present and in their normal developmental stages. The provisional diagnosis of HGF was given based on family history and clinical examination. An incisional biopsy was performed on the patient's gingiva on two separate localizations, and the surgical specimen was submitted to the Service of Oral Pathology of the School of Dentistry at Tiradentes University for histopathological analysis.

Microscopic examination revealed a hypocellular and hypovascular dense fibrous connective tissue, covered by intact stratified squamous epithelium exhibiting acanthosis and hyperplasia (Figures 2A and 2B). Picro-sirius red staining reveals that the enlarged gingival tissue is primarily the result of an increased amount of collagen fiber bundles (Figures 2C and 2D).

Based on the combined clinical and morphologic findings, the diagnosis was hereditary gingival fibromatosis. The treatment plan consisted of surgical removal of the enlarged gingival tissue by the external bevel gingivectomy on the buccal and palatal-lingual surfaces of both arches under local anesthesia (Figure 3A). Non-steroidal anti-inflammatory was prescribed (Ibuprofen® Oral Suspension 100mg/5ml,

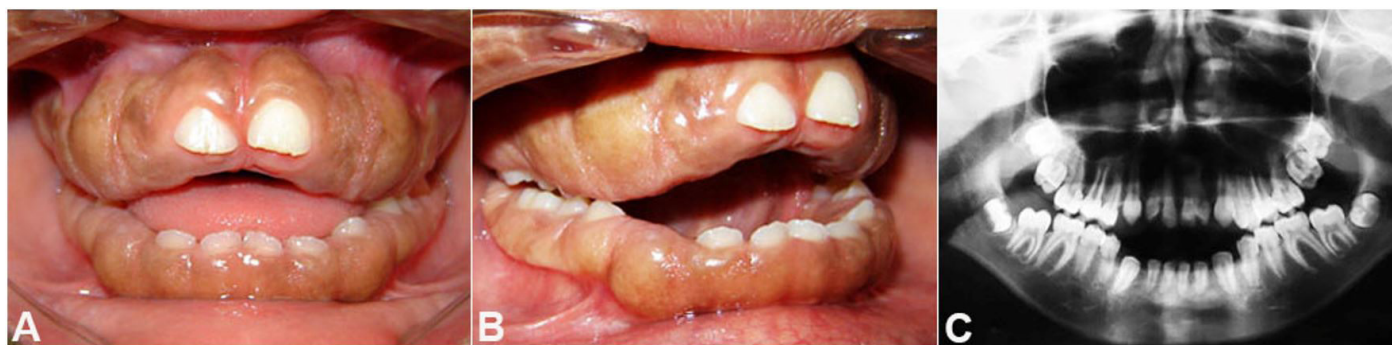

Figure 1. A and B - Intraoral clinical aspects of hereditary gingival fibromatosis. Note the severe and generalized gingival enlargement involving both the maxillary and mandibular arches. In some regions, the entire crown is covered by fibrous tissue, and in others, it covers almost two-thirds of the clinical crowns; **C** - Panoramic radiograph showing all permanent teeth present and normal development of the dentition.

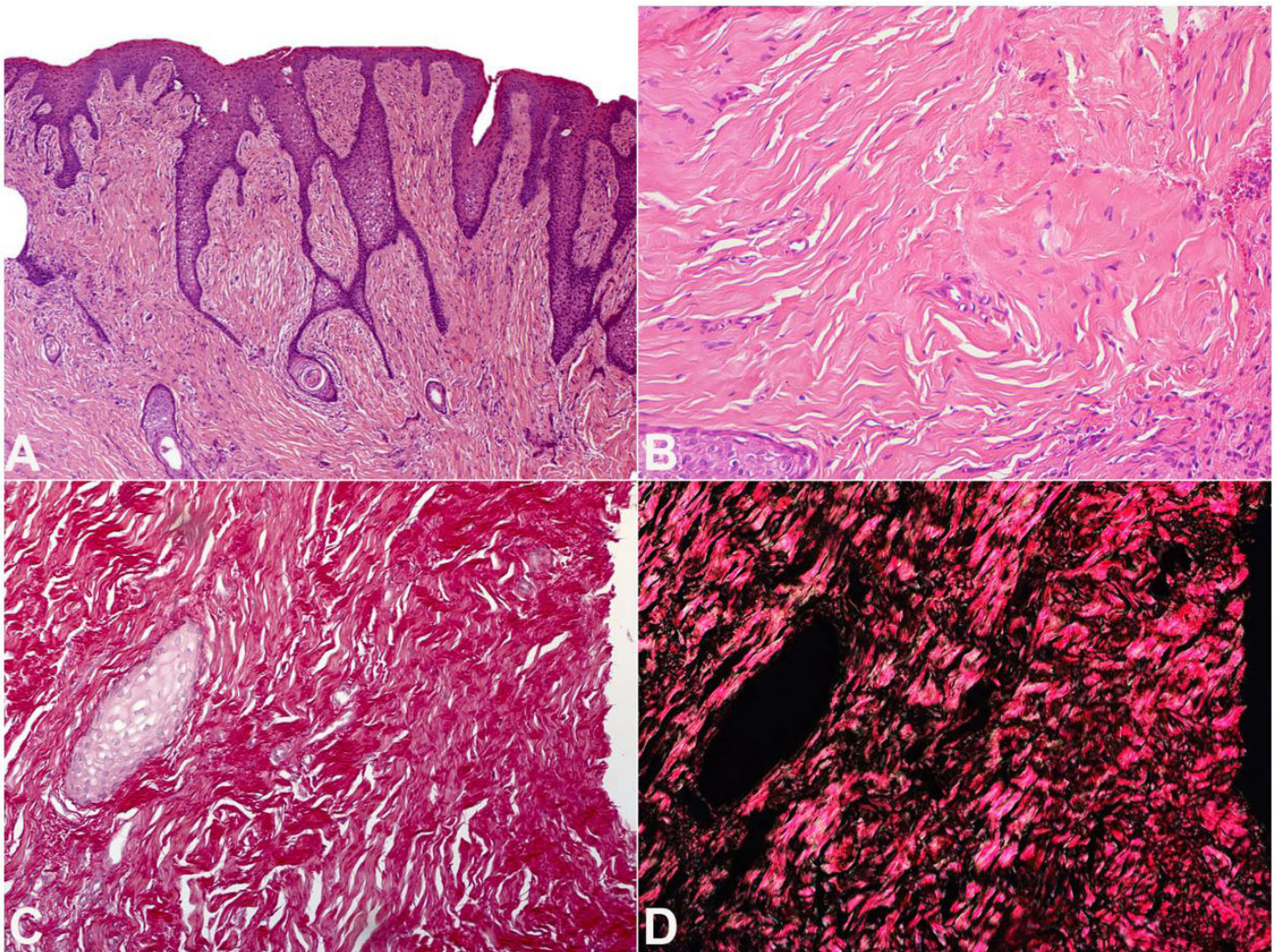


Figure 2. Photomicrographs of the gingiva. **A and B** - Gingival connective tissue poorly vascularized and exhibiting marked deposition of collagen fibers underlying an epithelium with acanthosis and elongated rete ridges (H&E, original magnification 100X and 200X for A and B, respectively); **C and D** - Picro-sirius red staining reveals that the enlarged gingival tissue is primarily the result of an increased amount of collagen fiber bundles (picro-sirius stain, original magnification 200X for C and D).

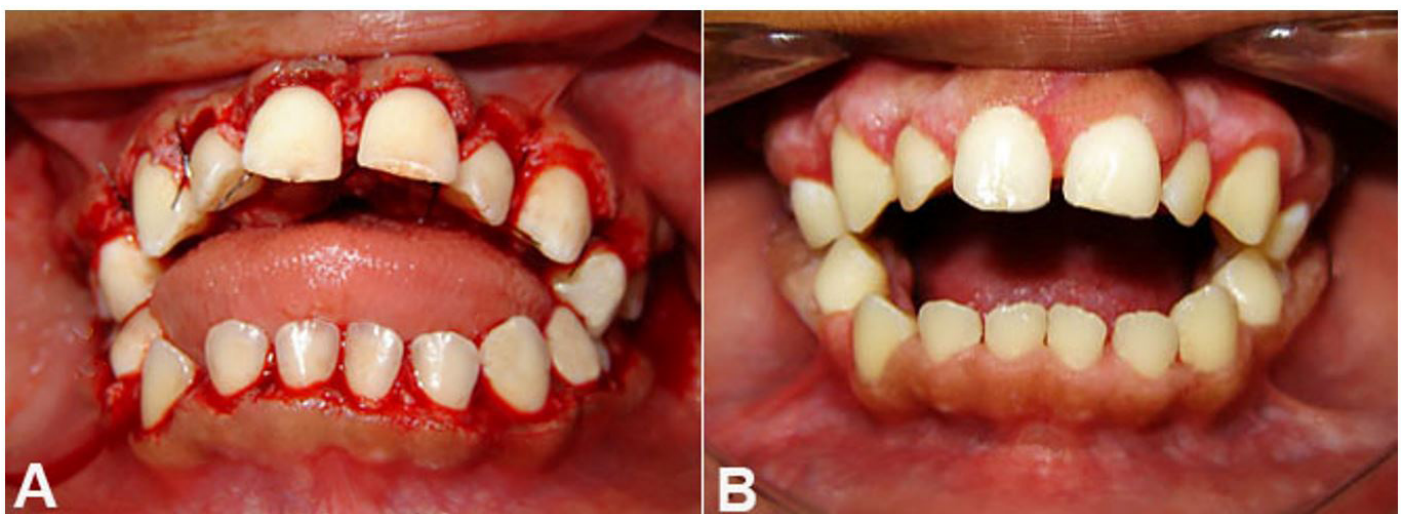


Figure 3. Intraoral examination. **A** - Immediate postoperative aspect; **B** - Clinical aspect six months after surgical removal of the excess gingival tissue, with no signs of relapse.

EMS, 5 mL Suspension; 3 times per day), and the patient was advised to use a chlorhexidine mouth rinse of 0.2% twice daily for three consecutive days. Oral hygiene instructions were given. After the surgical intervention, the patient returned periodically for follow-up visits for two years without signs of recurrence (Figure 3B). Orthodontic treatment was started after one year and is still in progress.

DISCUSSION

Hereditary Gingival Fibromatosis (HGF) is a slow and progressive gingival disease non-dental plaque-induced.⁹ Although the precise mechanism of HGF is unknown, several authors described this clinical enlargement as the result of the excessive accumulation of collagen and the marked proliferation of fibroblasts in the gingival fibrous connective tissue.⁷ This condition was firstly described in 1856 by Gross and is considered a rare oral disease, with a frequency of 1:175,000 individuals.^{1,2}

Table 1 provides a summary of previous HGF cases in children and adolescents reported in the English-language literature over the last ten years (2009-2019). HGFs tend to occur in infancy, do not show sex predilection,^{2,21} and great clinical variation in the expressivity of disease have been reported even in individuals in the same family.^{2,23}

The gingival growth usually begins at the time of eruption of the permanent dentition but also may develop with the eruption of the deciduous dentition,^{3,7} as in our case, and rarely is present at birth.⁷ Also, the presence of teeth appears to be necessary for that the development of HGF occurs because the condition usually disappears or recedes with loss of teeth.^{2,3} There are no reports of HGF in edentulous patients.³ Furthermore, the gingival growth may worsen during adolescence, suggesting a possible influence of sex hormones on the pathogenesis of the condition.²

Clinically, HGF presents as an asymptomatic slow-growing generalized or localized gingival enlargement.^{3,24} The localized form typically affects

Table 1. Summary of previous cases of HGF in children and adolescents reported in the English-language literature in the last ten years (2009-2019)

Author	Age (years) ^a	Gender	Ethnic group	Type	Localization	Treatment	Follow up time (months)	Recurrence
Sandhu et al. ¹⁰	16	F	Non-white	L	Maxilla and mandible (left side)	NR	NR	NR
Ramakrishnan and Kaur ¹¹	16	M	Non-white	G	Maxilla and mandible	Gingivectomy and electrocautery	12	No
Bansal et al. ¹²	17	F	NR	G	Maxilla and mandible	Gingivectomy	24	No
Dhadse et al. ¹³	12	M	NR	G	Maxilla and mandible	Gingivectomy	NR	NR
Goyal et al. ¹⁴	13	F	NR	G	Maxilla and mandible	Gingivectomy	12	No
Sharma et al. ¹⁵	8	F	Non-white	G	Maxilla and mandible	Gingivectomy with removal of mobile deciduous teeth	24	No
Aghili and Moghadam ¹⁶	9	F	Non-white	G	Maxilla and mandible	Gingivectomy	NR	Yes
Majumder et al. ¹⁷	18	M	Non-white	G	Maxilla and mandible	Gingivectomy and gingivoplasty	6	No

^aAge at time of diagnosis. *Diode laser of 810 nm wavelength (Lasersmile®, Biolase, USA) was used at a power of 3.5 watts, in continuous wave mode, with a 400-diameter fiber; F = female, G = generalized, L = localized, M = male, NR = not reported.

Table 1. Continued...

Author	Age (years) ^a	Gender	Ethnic group	Type	Localization	Treatment	Follow up time (months)	Recurrence
Peeran et al. ¹⁸	14	F	Non-White	G	Maxilla and mandible (posterior region)	NR	NR	NR
Chaurasia et al. ¹⁹	10	F	Non-white	G	Maxilla and mandible	NR	NR	NR
Tripathi et al. ²⁰	14	M	Non-white	G	Maxilla and mandible	Gingivectomy	24	No
Pego et al. ²¹	3	F	White	G	Maxilla and mandible	Gingivectomy and gingivoplasty	NR	NR
Tripathi et al. ²²	18	F	NR	L	Maxilla	Gingivectomy	24	No
Aboujaoude et al. ⁶	6	M	White	G	Maxilla and mandible	Conventional surgery using scalpel and laser*	NR	NR
Gawron et al. ²³	11	F	White	G	Maxilla and mandible	Gingivectomy and gingivoplasty	NR	Yes
Almiñana-Pastor et al. ⁷	5	M	NR	G	Maxilla and mandible	Gingivectomy with a full-thickness flap	15	No
	8	M	White	G	Maxilla and mandible	Gingivectomy	15	No
Manoj et al. ⁵	17	M	Non-white	G	Maxilla and mandible	Gingivectomy	6	No
Present case	10	F	Non-white	G	Maxilla and mandible	Gingivectomy	24	No

^aAge at time of diagnosis. *Diode laser of 810 nm wavelength (Lasersmile®, Biolase, USA) was used at a power of 3.5 watts, in continuous wave mode, with a 400-diameter fiber; F = female, G = generalized, L = localized, M = male, NR = not reported.

the maxillary tuberosity and the labial gingiva of the lower molars,²⁵ while in the generalized form, the teeth are almost or completely covered for the fibrous tissue.³ Other findings include deformities in the palate contour, altering phonation, swallowing and chewing, diastemas, bad positioning of teeth, halitosis, prolongation and retention of deciduous dentition, delayed eruption, inverted or open bite, open mouth posture, and mouth breathing.²⁶ Also, the gingival overgrowth may increase and predispose bacterial plaque accumulation and cause periodontal diseases.²³

The degree of severity of HGF is variable and can be classified as follows: i) Grade 0: no gingival enlargement, ii) Grade I: enlargement confined to interdental papilla, iii) Grade II: enlargement involving papilla and marginal gingiva, and iv) Grade III: enlargement covering three quarters or more of the crown.^{3,25,27} In addition, the

HGF is clinically classified into two types: symmetric or nodular. The symmetric type is the most common, and clinically, a uniform enlargement of gingiva was observed, while the nodular type is characterized by the presence of multiple nodules in dental papilla; however, a combination of both types occurs.³

The clinical differential diagnosis for diffuse gingival overgrowth is wide and includes a spectrum of neoplastic, inflammatory, and reactive processes, with distinct biological behaviors.^{4,5} Regarding the HGF, several conditions should be considered in the differential diagnosis, such as neurofibromatosis,²⁸ tuberous sclerosis,²⁹ hemifacial hypertrophy,³⁰ leukemia,^{31,32} local trauma, and use of medications such as phenytoin, cyclosporine, barbiturates^{1,7} or calcium channel blockers.³³ Furthermore, small localized gingival fibromatoses can be confused with

fibrous hyperplasia; however, progressive growth and the ability to affect beyond the marginal gingiva can help in the differentiation.²⁶ During anamnesis, the patient's mother denied the use of chronic medications, and extraoral examination did not reveal any additional changes in which gingival enlargement was part of the spectrum of some systemic disease. In addition, histopathological evaluation confirmed the presence of a dense fibrous connective tissue, ruling out any neoplastic lesions such as neurofibroma or leukemia.

Furthermore, this condition may be related to some syndromes and other abnormalities.^{3,5,7} Case reports associating HGF with Zimmerman-Laband Syndrome, Murray-Puretic-Drescher Syndrome, Cowden's Syndrome, Cross Syndrome, Rutherford's Syndrome, and Prune's Belly Syndrome have been reported.^{2,3,5} Also, there may be a relationship between deficiencies in growth-related hormones and gingival augmentation.² In this case, clinical examination ruled out the possibility of any syndromic involvement.

The treatment varies according to the degree of severity and includes surgery, electrocautery, and carbon dioxide laser.³ When gingival enlargement is minimal, measures of oral hygiene, periodontal treatment, and patient orientation are recommended.^{3,24} In more severe cases, such as ours, surgical intervention is necessary due to functional and aesthetic impairment, especially in the absence of attachment loss and pseudo pockets.³ Treatment consists of surgical excision of excess gingival tissue, often in a series of gingivectomies, which should be complemented by effective oral hygiene instructions.⁷ In the present case, due to the severity and functional and aesthetic impairment, internal bevel gingivectomy was used successfully, and even after two years of follow-up, no recurrence was observed.

The gingivectomy technique, besides the aesthetic improvement, contributes significantly to the socialization of the child in the family and school environment. However, independent of the therapeutic approach used, the dentists should take into consideration the patient's age, medical history, the degree of severity, presence or absence of any disease, as well as attitudes and desires of patients.⁸ The purpose of the treatment should include measures to correct mastication and phonation,

promoting healthy growth and development, and, if possible, reduce emotional impacts due to aesthetic improvement.³⁴

CONCLUSION

In summary, this case illustrates the classical clinical features of HGF. Physicians and dentists should be familiar with genetic disorders so that a proper diagnosis and appropriate therapeutic approach are performed, and thus minimize the clinical implications for the patient's oral health, improving the quality of life due to functional and aesthetic improvement.

The authors retain an informed consent signed by the patient's guardians authorizing the use of images and clinical information. The manuscript is in accordance with the Institutional Ethics committee rules.

REFERENCES

1. Gonçalves CF, Mundim AP, Martins RFS, Gagliardi RM, Santos PSS, Toledo OA. Hereditary gingival fibromatosis: a case report with seven-year follow-up. *Acta Stomatol Croat.* 2018;52(3):254-8. <http://dx.doi.org/10.15644/asc52/3/9>. PMID:30510301.
2. Coletta RD, Graner E. Hereditary gingival fibromatosis: a systematic review. *J Periodontol.* 2006;77(5):753-64. <http://dx.doi.org/10.1902/jop.2006.050379>. PMID:16671866.
3. Tandon S, Sharma M, Gandhi M, Vijay A. Nonsyndromic gingival fibromatosis: a rare case report. *Int J Clin Pediatr Dent.* 2018;11(3):250-3. <http://dx.doi.org/10.5005/jp-journals-10005-1521>. PMID:30131651.
4. Brierley DJ, Crane H, Hunter KD. Lumps and bumps of the gingiva: a pathological miscellany. *Head Neck Pathol.* 2019;13(1):103-13. <http://dx.doi.org/10.1007/s12105-019-01000-w>. PMID:30693455.
5. Manoj M, Garg R, Babu K. Unusual presentation of familial gingival fibromatosis among male siblings. *J Indian Soc Periodontol.* 2017;21(2):152-5. http://dx.doi.org/10.4103/jisp.jisp_207_16. PMID:29398861.
6. Aboujaoude S, Cassia A, Moukarzel C. Diode laser versus scalpel in the treatment of hereditary gingival fibromatosis in a 6-year old boy. *Clin Pract.* 2016;6(4):895. <http://dx.doi.org/10.4081/cp.2016.895>. PMID:27994842.
7. Almiñana-Pastor PJ, Buitrago-Vera PJ, Alpiste-Illueca FM, Catalá-Pizarro M. Hereditary gingival fibromatosis: characteristics and treatment approach. *J Clin Exp Dent.* 2017;9(4):e599-602. <http://dx.doi.org/10.4317/jced.53644>. PMID:28469831.

8. Cunha JLS, Santana AVB, Santana LAM, et al. Regional odontodysplasia affecting the maxilla. *Head Neck Pathol.* 2019;2019:1-11. PMID:30900210.
9. Chapple ILC, Mealey BL, Van Dyke TE, et al. Periodontal health and gingival diseases and conditions on an intact and a reduced periodontium: Consensus report of workgroup 1 of the 2017 World Workshop on the Classification of Periodontal and Peri-Implant Diseases and Conditions. *J Periodontol.* 2018;89(Suppl 1):S74-84. <http://dx.doi.org/10.1002/JPER.17-0719>. PMID:29926944.
10. Sandhu SP, Kakar V, Gogia G, Narula SC. Unilateral gingival fibromatosis with localized aggressive periodontitis (involving first molars): an unusual case report. *J Indian Soc Periodontol.* 2009;13(2):109-13. <http://dx.doi.org/10.4103/0972-124X.55834>. PMID:20407661.
11. Ramakrishnan T, Kaur M. Multispeciality approach in the management of patient with hereditary gingival fibromatosis: 1-year followup: a case report. *Int J Dent.* 2010;2010:575979. <http://dx.doi.org/10.1155/2010/575979>. PMID:21234408.
12. Bansal A, Sowmya K, Narang S, Sehgal N. Treatment and two-year follow-up of a patient with hereditary gingival fibromatosis. *J Indian Soc Periodontol.* 2011;15(4):406-9. <http://dx.doi.org/10.4103/0972-124X.92581>. PMID:22368369.
13. Dhadse PV, Yeltiwar RK, Pandilwar PK, Gosavi SR. Hereditary gingival fibromatosis. *J Indian Soc Periodontol.* 2012;16(4):606-9. <http://dx.doi.org/10.4103/0972-124X.106930>. PMID:23492855.
14. Goyal L, Bey A, Gupta ND, Varshney A. Diagnosis and management of nonsyndromic hereditary gingival fibromatosis in a 13 year old girl: report of a rare case. *Contemp Clin Dent.* 2012;3(6, Suppl 2):S210-3. <http://dx.doi.org/10.4103/0976-237X.101097>. PMID:23230366.
15. Goyal D, Ray A, Sharma S, Shah G. Familial gingival fibromatosis: A rare case report. *Contemp Clin Dent.* 2012;3(5, Suppl 1):S63-6. <http://dx.doi.org/10.4103/0976-237X.95108>. PMID:22629070.
16. Aghili H, Goldani Moghadam M. Hereditary gingival fibromatosis: a review and a report of a rare case. *Case Rep Dent.* 2013;2013:930972. <http://dx.doi.org/10.1155/2013/930972>. PMID:23533834.
17. Majumder P, Nair V, Mukherjee M, Ghosh S, Dey SK. The autosomal recessive inheritance of hereditary gingival fibromatosis. *Case Rep Dent.* 2013;2013:432864. <http://dx.doi.org/10.1155/2013/432864>. PMID:24416600.
18. Peeran SW, Ramalingam K, Peeran SA, Muqrabi MH, Abdulla KA. Hereditary nonsyndromic gingival fibromatosis: report of family case series. *Case Rep Dent.* 2013;2013:835989. <http://dx.doi.org/10.1155/2013/835989>. PMID:24191204.
19. Chaurasia A. Hereditary gingival fibromatosis. *Natl J Maxillofac Surg.* 2014;5(1):42-6. <http://dx.doi.org/10.4103/0975-5950.140171>. PMID:25298717.
20. Tripathi AK, Upadhya V, Kumar V, Saimbi CS. Hereditary gingival fibromatosis and its management: 2-year follow-up. *Contemp Clin Dent.* 2014;5(4):569-71. <http://dx.doi.org/10.4103/0976-237X.142835>. PMID:25395783.
21. Pego SP, Coletta RD, Mendes DC, et al. Hereditary gingival fibromatosis: clinical and ultrastructural features of a new family. *Med Oral Patol Oral Cir Bucal.* 2015;20(2):e150-5. <http://dx.doi.org/10.4317/medoral.20170>. PMID:25475776.
22. Tripathi AK, Dete G, Saimbi CS, Kumar V. Management of hereditary gingival fibromatosis: A 2 years follow-up case report. *J Indian Soc Periodontol.* 2015;19(3):342-4. <http://dx.doi.org/10.4103/0972-124X.148643>. PMID:26229281.
23. Gawron K, Łazarz-Bartyzel K, Fertala A, Plakwicz P, Potempa J, Chomyszyn-Gajewska M. Gingival Fibromatosis with Significant De Novo Formation of Fibrotic Tissue and a High Rate of Recurrence. *Am J Case Rep.* 2016;17:655-9. <http://dx.doi.org/10.12659/AJCR.899997>. PMID:27609299.
24. Lobo TM, Pol DG, Pol SD. Idiopathic gingival fibromatosis with asymmetrical presentation and electrosurgical management. *J Indian Soc Periodontol.* 2016;20(1):98-102. <http://dx.doi.org/10.4103/0972-124X.170831>. PMID:27041849.
25. Beaumont J, Chesterman J, Kellett M, Durey K. Gingival overgrowth: part 1: aetiology and clinical diagnosis. *Br Dent J.* 2017;222(2):85-91. <http://dx.doi.org/10.1038/sj.bdj.2017.71>. PMID:28127024.
26. Suassuna TM, Almeida AB, Landim FS, Medeiros MF, Perez DEC. Extensive idiopathic gingival fibromatosis: a case report. *Rev Cir Traumatol Buco-Maxilo-Fac.* 2016;16(4):40-44.
27. Bökenkamp A, Bohnhorst B, Beier C, Albers N, Offner G, Brodehl J. Nifedipine aggravates cyclosporine A-induced gingival hyperplasia. *Pediatr Nephrol.* 1994;8(2):181-5. <http://dx.doi.org/10.1007/BF00865474>. PMID:8018496.
28. Bekisz O, Darimont F, Rompen EH. Diffuse but unilateral gingival enlargement associated with von Recklinghausen neurofibromatosis: a case report. *J Clin Periodontol.* 2000;27(5):361-5. <http://dx.doi.org/10.1034/j.1600-051x.2000.027005361.x>. PMID:10847541.
29. Korol UB, Schoor R, Nanda V, Almas K, Phelan JA. Gingival enlargement as a manifestation of tuberous sclerosis: case report and periodontal management. *J Periodontol.* 2008;79(4):759-63. <http://dx.doi.org/10.1902/jop.2008.070407>. PMID:18380572.

30. Jagtap RR, Deshpande GS. Gingival enlargement in partial hemifacial hyperplasia. *J Indian Soc Periodontol.* 2014;18(6):772-5. PMID:25624636. http://dx.doi.org/10.4103/jomfp.JOMFP_205_17. PMID:29491612.
31. Demirer S, Özdemir H, Şencanc M, Marakoğlud I. Gingival hyperplasia as an early diagnostic oral manifestation in acute monocytic leukemia: a case report. *Eur J Dent.* 2007;1(2):111-4. <http://dx.doi.org/10.1055/s-0039-1698323>. PMID:19212486.
32. Chowdhri K, Tandon S, Lamba AK, Faraz F. Leukemic gingival enlargement: a case report and review of literature. *J Oral Maxillofac Pathol.* 2018;22(4, Suppl 1):S77-81.
33. Livada R, Shiloah J. Calcium channel blocker-induced gingival enlargement. *J Hum Hypertens.* 2014;28(1):10-4. <http://dx.doi.org/10.1038/jhh.2013.47>. PMID:23739159.
34. Yadav VS, Tewari S, Sharma RK, Chakraborty S. An unusual case of idiopathic gingival fibromatosis. *Contemp Clin Dent.* 2013;4(1):102-4. <http://dx.doi.org/10.4103/0976-237X.111623>. PMID:23853465.

Author contributions: Bezerra BT performed the surgical procedure. Albuquerque-Júnior RLC and de Sánchez-Romero C performed the microscopy analysis. Andrade ME performed the critical review of the manuscript. Cunha JLS, Ramos MACC, and Regis DM reviewed the literature and wrote the manuscript. All authors approved and proofread the final document.

Conflict of interest: None

Financial support: None

Submitted on: May 11th, 2019

Accepted on: December 3rd, 2019

Correspondence

John Lennon Silva Cunha

Oral Pathology Section, Department of Oral Diagnosis, Piracicaba Dental School, University of Campinas (UNICAMP)

Av. Limeira, 901 – Caixa Postal 52 – Piracicaba/SP – Brazil

CEP: 13414-903

Phone: +55 (79) 99654-0805

lennonrrr@live.com