

3-1962

Clinical Findings In Examination Of Hips In Newborn Babies

Stanko Stanisavljevic

Follow this and additional works at: <https://scholarlycommons.henryford.com/hfhmedjournal>



Part of the [Life Sciences Commons](#), [Medical Specialties Commons](#), and the [Public Health Commons](#)

Recommended Citation

Stanisavljevic, Stanko (1962) "Clinical Findings In Examination Of Hips In Newborn Babies," *Henry Ford Hospital Medical Bulletin* : Vol. 10 : No. 1 , 245-252.

Available at: <https://scholarlycommons.henryford.com/hfhmedjournal/vol10/iss1/27>

This Part II is brought to you for free and open access by Henry Ford Health System Scholarly Commons. It has been accepted for inclusion in Henry Ford Hospital Medical Journal by an authorized editor of Henry Ford Health System Scholarly Commons.

CLINICAL FINDINGS IN EXAMINATION OF HIP IN NEWBORN BABIES

STANKO, STANISAVLJEVIC, M.D.*

DURING THE period 1958-1961 the author personally examined the hips of 5125 newborn babies. Examination was performed two to six days after birth. Some impressions based on this experience are recorded here. The examiner should know the clinical features of normal hips and it is taken for granted that this is the case.

Ortolani's Sign (Of The "Click")^{2,3}

To elicit Ortolani's sign the baby should be examined supine. While supine both hands of the examiner grasp the lower extremities at the knees with thighs flexed 90° in neutral rotation and knees flexed 90-100°. The thumbs are placed on the medial side and the fingers on the lateral side of the child's knees. The index fingers are placed along the femoral shaft pointing toward the greater trochanters. To examine the left hip, the examiner holds the right hip pressed firmly against the examining table and exerts moderate pressure on the left knee downward along the femoral axis to transmit pressure posteriorly from the femur across the hip.⁴ At this moment the examiner feels an inaudible click. This is the click of the femoral head exiting from the acetabulum. The examiner now abducts the same hip (left), keeping the index finger along the greater trochanter and maintaining the same posteriorly directed pressure on the knee. (This moment is important. If the examiner diminishes pressure on the knee and removes the index finger from the greater trochanter he will be unable to detect the second click accompanying re-entrance of the femoral head into the acetabulum.) The abduction of the hip is gradual. At approximately 45-50° the examiner should feel a slight resistance and immediately afterward the second click should be felt with the finger. This is the click of re-entrance, which is more pronounced than the click of exit, but still inaudible. This sequence of events is Ortolani's sign.

It is emphasized that the first click (of exit) is correlated with a feeling of giving way; this is the moment when part of the femoral head displaces over the ridge of the acetabulum. This position of partial subluxation of the femoral head has to be maintained by continued pressure on the knee, the index finger remaining on the greater trochanter. In subsequent abduction of the hip the feeling of slight

*From the Department of Orthopedic Surgery and the Orthopedic Research Laboratory. Work aided by the following grants: Orthopedic Research and Education Foundation; A-4186 Surg., N.I.H., Bethesda, Md.; 293 Henry Ford Hospital.

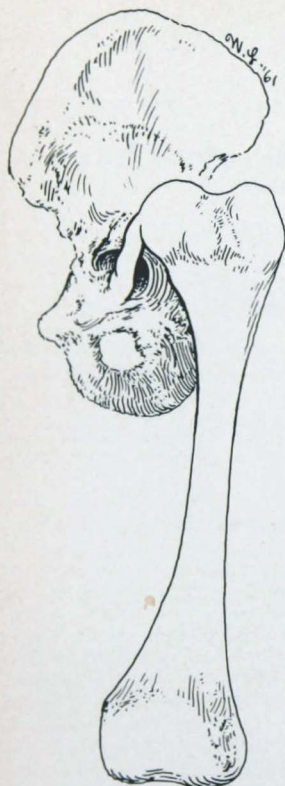


Figure 1

Anatomo-pathological characteristic in a hip with telescoping.

resistance mentioned is due to pressure of part of the femoral head against the acetabular ridge and perhaps in part by tension of the ligamentum teres and antero-inferior articular capsule. At this moment the tip of the index finger must press medially on the greater trochanter to produce the click of entrance which results from jumping of the femoral head over the acetabular ridge accompanying reduction into the acetabulum.

These details are noted to permit differentiation of Ortolani's sign from clicks in normal hips⁵ which are due to sliding of the iliopsoas tendon over an enlarged ilio-pectineal bursa, or to knee clicks transmitted to the hip through the femur.

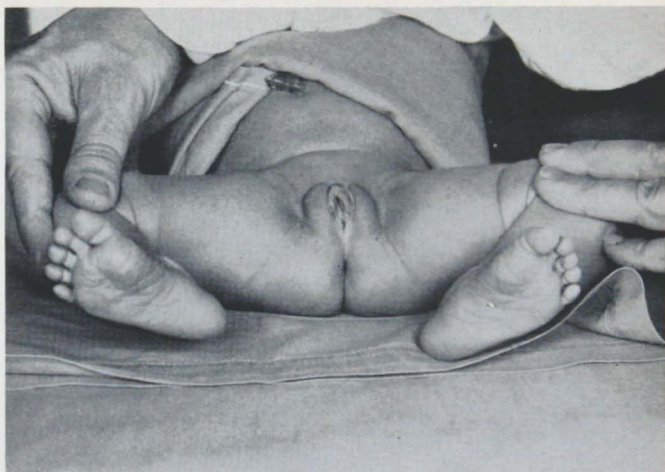

Figure 2

Range of abduction of the thighs in this 3 day old girl (born in occiput position) was 85°. The hips were normal.

There has been no limitation of abduction in hips of newborn babies with positive Ortolani's sign.

Anatomical Findings Associated with Ortolani's Sign

Two hundred and forty hips in 120 stillborn babies were dissected. Examination of these hips prior to dissection yielded a positive Ortolani's sign in three hips of two babies. Anatomical-pathological features of these three hips were:

a) A defect on the supero-posterior aspect of the ridge of the acetabulum.

b) The articular capsules were enlarged, permitting displacement of part of the femoral head over the aforesaid defective ridge of the acetabulum. In normal hips of stillborns the femoral head could not be displaced out of the acetabulum. It was easier in normal hips to produce a traumatic epiphyseolysis of the proximal femoral epiphysis than to dislocate or subluxate the femoral head when the articular capsule was intact.

c) Ligamentum teres was thicker and longer than normally.

Among 5125 newborn babies positive Ortolani's sign was found in 33 hips of 24 babies. It is hard to detect Ortolani's sign if unfamiliar with the proper technique. It is well to get acquainted with the smooth, regular motion of normal hips in new-

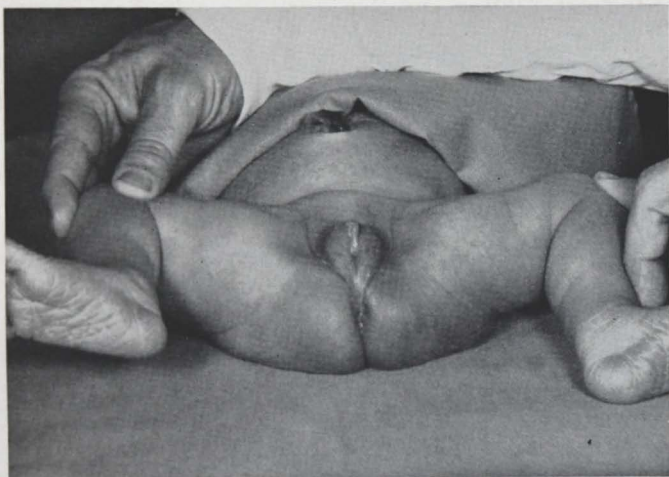


Figure 3

Range of abduction of this 4 day old girl (born in breech position was 85°. The hips were normal (note ecchinoses in the gluteal region which is characteristic for breech born babies).

born babies to be able to recognize and differentiate better the abnormal from the normal findings.

Telescoping Sign

Telescoping is extreme mobility and wandering of the femoral head. Piston motion of the femoral head is produced by flexing the 90° with neutral rotation; minimal posteriorly directed pressure on the knee produces supero-posterior displacement of the femoral head with an accompanying feeling of complete looseness of the hip. Push-pull force on the hips with hip extended gives the same sensation.

In telescoping hips of newborn babies Ortolani's sign usually cannot be produced because the femoral head is not reduced into the acetabulum by the maneuver. It is necessary to differentiate clearly the sign of telescoping from Ortolani's sign.

Only one among 240 dissected hips exhibited telescoping on clinical examination.⁵

Anatomical Findings Associated with Telescoping

The anatomical-pathological characteristics of the single hip with telescoping were: (Figure No. 1)

a) Very small, deformed, shallow acetabulum which could not retain the femoral head.

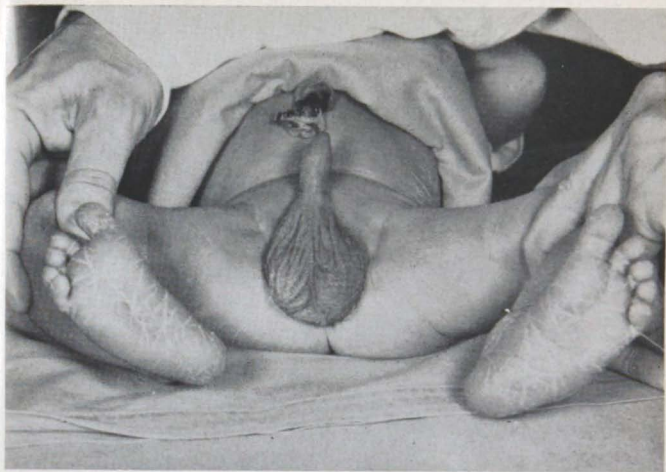

Figure 4

Range of abduction in this 3 day old boy (born in occiput position) was 75°. The hips were normal.

- b) Large, lax articular capsule within which the femoral head was hypermobile.
- c) Long, lax ligamentum teres permitting hypermobility of the femoral head.

In the hip with these anatomical-pathological characteristics it was not possible to reduce the femoral head into the small, shallow and deformed acetabulum. The femoral head probably was out of the acetabulum constantly. This was the reason for the negative Ortolani's sign.

Among 5125 newborn babies four hips (in two newborn babies) with telescoping were detected. There was no limitation of abduction, probably for these reasons:

- a) Spasm and shortening of the adductor muscles were observed to start after the second or third week of age.
- b) Mobility of the head within the articular capsule was so great that during the abduction maneuver the femoral head would slide easily and palpably into the region of the acetabulum (without true reduction). No limitation of abduction of the hip occurred as a result.

The author's statistics indicate that telescoping is a rare sign in the newborn.

Limitation of Abduction in Newborn Babies

The value of limitation of hip abduction in newborns as a pathognomonic or premonitory sign of congenital hip dislocation or subluxation is controversial.¹ This sign is subjective, depending on the force the examiner uses to abduct the hips.

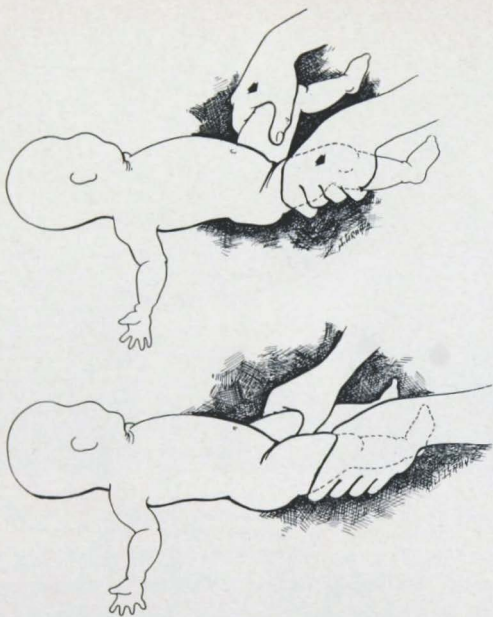


Figure 5

In normal newborn girls abduction of the hips is slightly easier than in newborn boys. The range of abduction in normal newborn girls is $75-85^{\circ}$, and in normal newborn boys $70-80^{\circ}$. In babies born in the breech position hips could be abducted 85° easily (Figures 2, 3, 4.)

In 1958 nine newborn babies (3 males and 6 females) with limitation of abduction to $60-65^{\circ}$ were found. X-rays of these hips were considered normal, and 12 months clinical and x-ray follow-up did not disclose any subsequent hip abnormality.⁶

The Hip-Knee-Hip Traid

With the baby supine, the examiner first extends the hips, followed by extension of the knees, after which the thighs are abducted $75-80^{\circ}$. The force normally required to extend the hips is greater than that required to extend the knees. The force required to abduct the hips is less than that required to extend the knees. In summary, less force is required to abduct the hips than to completely extend the hips and the knees in the same normal newborn baby. (Figure 5, 6, 7.) These findings are usually the same whether the newborn baby is relaxed, or crying and resisting

HIPS IN NEWBORN BABIES

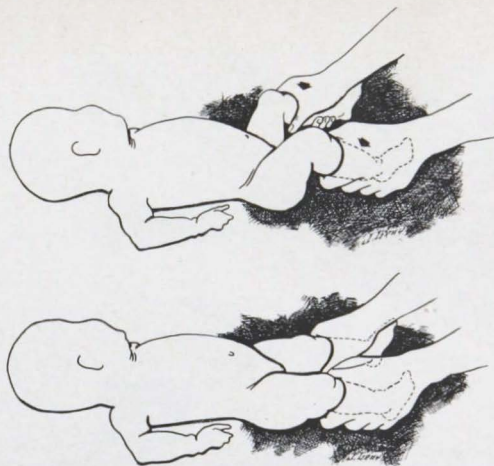


Figure 6

examination. The author has called this sign the normal hip-knee-hip triad,⁶ and it has been uniformly present in over 4000 normal newborns.


An abnormal triad was found in 4 babies. The force required to abduct the hips in each of these 4 newborn babies was greater than that required to extend the hips and knees. Follow-up of these 4 babies revealed development of a dislocated left hip in one case, and development of hip subluxation in the other 3 babies, all within 3 months of birth. It is emphasized that the hip-knee-hip triad is not considered unequivocally diagnostic of congenital predislocation or dislocation. However, it seems to be a promising sign for prognosticating development of hip dislocation or subluxation.

The anatomical-pathological findings in hips with abnormal hip-knee-hip triad is a matter of speculation, because for obvious reasons the author did not find this sign in any stillborn baby.

The author suggests that the 4 babies with abnormal hip-knee-hip triad were born with normal hip joints but had an inborn error in muscle balance around the hips, (tightness of the adductors) which was at least in part the reason that within three months hip subluxation or dislocation developed.

SUMMARY

The author describes three clinical signs which help in discovering congenital hip pathology in newborn babies. These signs are Ortolani's sign, telescoping, and hip-knee-hip triad. It is felt that limitation of abduction is an unreliable indication of hip dysplasia or dislocation.



Figures 5, 6, 7

Three poses of examination for hip-knee-hip triad.

First pose: Extension of the hips.

Second pose: Extension of the knees.

Third pose: Abduction of the hips.

(Reproduced from *Archivio de Orthopedia*)

The examiner of hips in newborn babies should be aware of and search for these signs. Proper technique in testing for Ortolani's sign, telescoping and abnormal hip-knee-hip triad can avoid later discovery of congenital hip dislocation or subluxation.

REFERENCES

1. Caffey, J., Ames, R., Silverman, W. A., Ryder, C. T., and Hough, G.: Contradiction of the congenital dysplasia-predislocation hypothesis of congenital dislocation of the hip through a study of the normal variation in acetabular angles at successive periods in infancy, *Pediatrics* 17:532, 1956.
2. Ortolani, M.: Le diagnostic clinique, fait par la recherche du signe du ressaut, est le seul moyen permettant le traitement vraiment précoce et total de la luxation congénitale de la hanche, *Bull. Acad. nat. méd. Paris* 141:188, 1957.
3. Ortolani, M.: *Lussazione Congenita Dell'anca*, Bologna, Cappelli, 1948.
4. Stanisavljevic, S.: Examination of hips in newborn babies and results, *Henry Ford Hosp. Med. Bull.* 9:215, 1961.
5. Stanisavljevic, S., and Mitchell, C. L.: Congenital hip dysplasia, subluxation and dislocation in the still and newborn infants; anatomical-pathological study. (To be published)
6. Stanisavljevic, S.: Hip-knee-hip triad; a helpful clinical sign in examination of hips in newborn babies, *Arch. Orthop.* (Milano) 74:577, 1961.