

9-1972

Current Tests for Tubal Patency: Their Study and Comparison

Asgar Afsari

Robert J. Thompson

Follow this and additional works at: <https://scholarlycommons.henryford.com/hfhmedjournal>



Part of the [Life Sciences Commons](#), [Medical Specialties Commons](#), and the [Public Health Commons](#)

Recommended Citation

Afsari, Asghar and Thompson, Robert J. (1972) "Current Tests for Tubal Patency: Their Study and Comparison," *Henry Ford Hospital Medical Journal* : Vol. 20 : No. 3 , 125-130.

Available at: <https://scholarlycommons.henryford.com/hfhmedjournal/vol20/iss3/2>

This Article is brought to you for free and open access by Henry Ford Health System Scholarly Commons. It has been accepted for inclusion in Henry Ford Hospital Medical Journal by an authorized editor of Henry Ford Health System Scholarly Commons.

Current Tests for Tubal Patency Their Study and Comparison

Asghar Afsari, MD* and Robert J. Thompson, MD**

Two hundred patients have been reviewed in whom culdoscopy or laparoscopy was performed for infertility study. During these two procedures, methylene blue was injected through an endocervical cannula for detection of tubal patency under direct visualization. When compared with 89 patients tested by utero-tubal insufflation and hystero-salpingography, results indicated that direct visualization of the tubes and dye hydrotubation appears to be the most reliable method. HSG proved to be the second most reliable method with a failure rate of 19.2%. The least accurate procedure in this study was UTI with CO₂ gas, where the failure rate was 24.7%. The latter test, however, is the most efficient one for detecting tubal spasm.

Material

We reviewed a total of 200 cases of patients who have undergone culdoscopy or laparoscopy in the five years from March 1965 through February 1969. One hundred and eleven of these patients who had either UTI or HSG prior to culdoscopy or laparoscopy have been excluded. All three tests were completed in the remaining 89 patients.

Method

The UTI was performed in the office without sedation, using a Grafax Model insufflator, charged with carbon dioxide gas, (75 to 100 cc of CO₂ for each procedure). Either the Rubin cannula with acorn tip or the Calvin cannula with screw tip was employed. The procedure was not performed in the presence of local infection, uterine bleeding, or possible pregnancy. For alleviation of shoulder pain, which often developed after UTI, the patients were placed in semi knee-chest position with hips elevated over a pillow.

Because fertilization takes place in the uterine tubal lumen, patency of the tubes is of great importance. In patients with infertility, a tubal factor is the most frequent problem. While a variety of diagnostic procedures have been advocated to test for luminal patency, the following three techniques have proven to be most practical:

- Utero-tubal insufflation (UTI).
- Hystero-salpingography (HSG).
- Direct visualization of the tubes thru the culdoscope or the laparoscope, during injection of dye (methylene blue) thru the uterine cannula (MBI).

The relative value of these three procedures will be compared here.

*Department of Gynecology-Obstetrics, HFH

**Now at Duval Medical Center, Jacksonville, Fla.

Address reprint requests to Dr. A. Afsari, care of Henry Ford Hospital, Detroit, Mi 48202

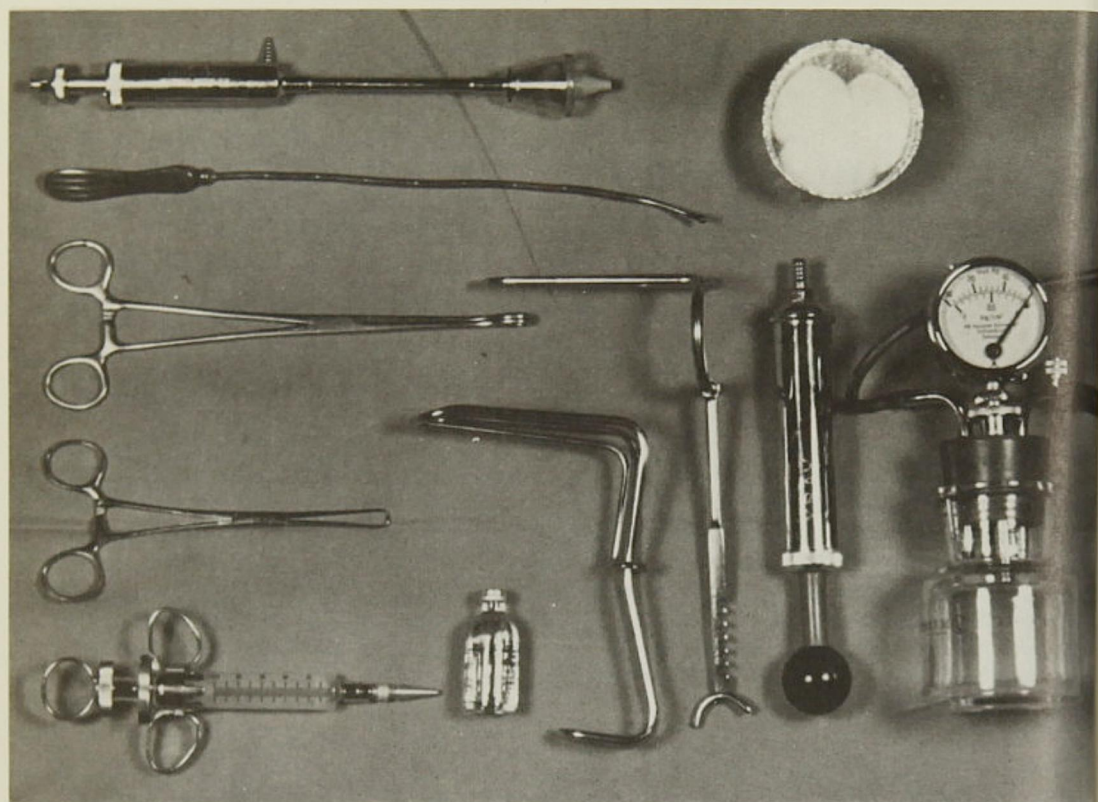


Figure 1
Hysterosalpingography instrument with vacuum apparatus.

HSG was done in the Radiology Department with correlation of Department of Gynecology and Radiology. The instrument utilized was a suction cap type cannula and the medium, a water soluble contrast material containing 38% iodine (E. R. Squibb Co. — Sinographin)(Figure 1) A scout film was taken prior to application of the cannula. Pelvic examination was routinely performed to evaluate the position of uterus prior to the procedure. In both procedures, careful aseptic technique was carried out. The tests were performed in the phase of preovulation.

At the beginning of this study, direct visualization of pelvic organs was done through a culdoscope. But, since February, 1968, laparoscopy has been employed, using a fibro-optic and light source and laparoscope with a wide angle lens. (Figure 2). Either procedure was performed as the last step of the infertility evaluation and while the patient was hospitalized.

The procedure was carried out according to the technique described by Steptoe. When visualization was satisfactory, 10 to 15 cc of 0.25% methylene blue was injected through an intracervical cannula and the tubes were observed for spillage of the dye.

Results

The group ranged in age between 19 and 38 years. Culdoscopy was performed on 40 patients (45%) and laparoscopy on 49 patients (54%). For the purpose of comparison, the results of the three procedures will be classified into "compatible" and "incompatible" groups (Table I).

The compatible group, consisting of 56 patients (56.1%), had similar results in all three procedures. Forty-two of these (47.1%) demonstrated tubal patency in all three tests. In three patients (3.3%) the

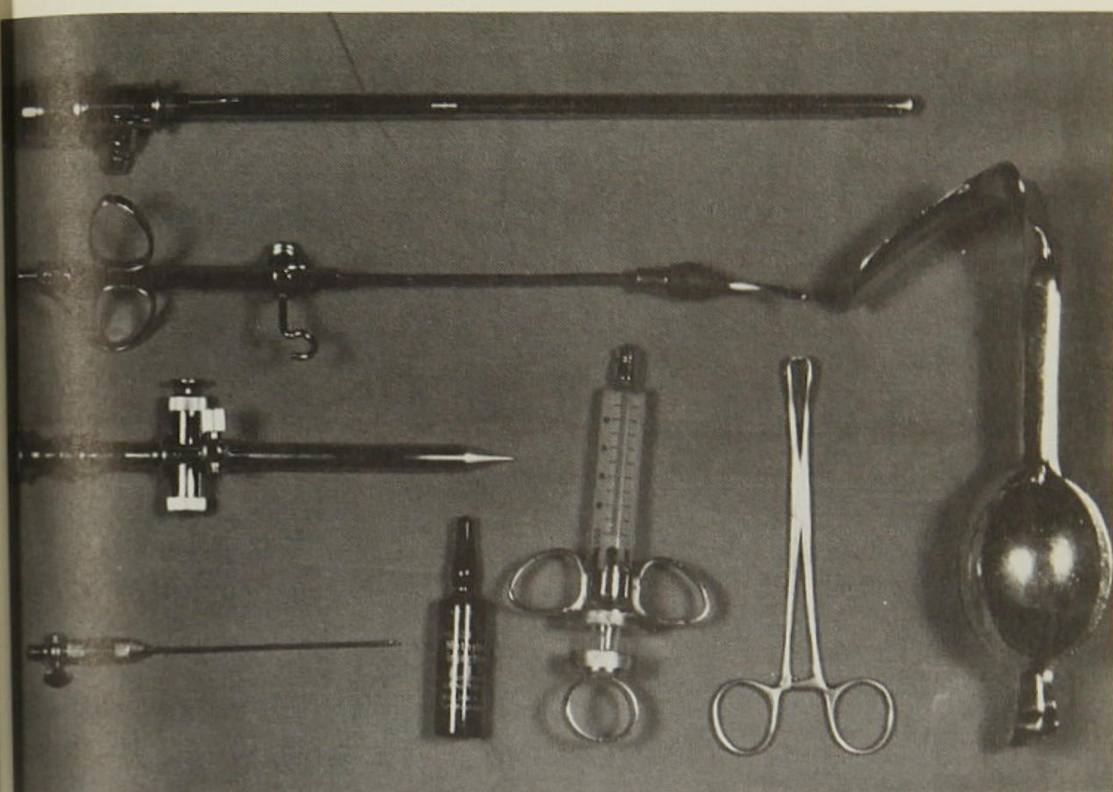


Figure 2
Laparoscopy instrument for visualization and dyhydrotubation.

cord...
eptoc...
ory...
ue wa...
cannul...
spillag...
left tube was patent at the time of MBI, and HSG and UTI were also positive. Three others (3.3%) had patency of the right tube only. In the other two patients (2.4%), the three tests were negative. One of these patients had severe pelvic adhesions due to previous surgery. The other had had previous right salpingectomy and the dye did not spill from the fimbriated end of the left tube. In these two patients, the UTI was negative and the HSG was compatible (Table II).

en 19...
eform...
copy...
pose...
ree pr...
"cor...
group...
ing of...
ults in...
of the...
ncy in...
(.3%)...
The incompatible group was divided into two sub-groups (Table III). The first sub-group with 17 patients had similar results from the MBI and the UTI, but the HSG did not match. The failure rate in this category was 19.2%. The second sub-group of 22 patients (Table IV) had similar results from MBI and HSG, but not with UTI. The UTI failure rate was 24.7%.

Discussion

Utero-tubal insufflation, more popularly known as the Rubin test, was first described by I. C. Rubin in 1920.²⁻⁴ The apparatus has been changed and modified, but the basic concepts remain the same. If there is no leakage around the cervical insufflating cannula, the CO₂ gas will enter the uterine cavity and, after developing sufficient pressure, will pass thru the utero-tubal junction and the tubes to enter the peritoneal cavity. Patency is indicated by a sharp fall in the pressure shown on kymographic paper. The controversy over the source of oscillation recorded on the kymographic paper has persisted for many years. Stabile, in 1958,⁵ offered evidence that the oscillations result from uterine muscle contractions. Moreover, Sobrero,⁶ in a comparative study of UTI and HSG in 1961, reported significant disagreement in the

TABLE I
Classification

- I. Compatible Group:
Similar result of the three procedures.
- II. Incompatible Group:
Variable results of the three techniques.
 - A) Variable HSG.
 - B) Variable UTI.

TABLE II
Compatible Group

Method	No. Cases	%
a) Bilateral tubal patency.....	42	47.1
b) Unilateral tubal patency	6	6.6
c) No patency.....	2	2.4
Total.....	50	56.1

TABLE III
Incompatible Group, Variable HSG
17 Cases (19.2%)

MBI	UTI	HSG	No. Cases
a. Bilat.	Pos.	Rt. Patency	7
b. Bilat.	Pos.	Lt. Patency	6
c. Bilat.	Pos.	NO Patency	2
d. Unilat.	Pos.	NO Patency	2

TABLE IV
Incompatible Group, Variable UTI
22 Cases (24.7%)

A. False Positive.....	4
B. False Negative.....	14
a. Bilateral T. Patent (MBI & UTI) ..	.9
b. Lt. T. Patent (MBI & UTI) ..	.3
c. Rt. T. Patent (MBI & UTI) ..	.2
C. Spasm.....	4

test results: False negative 8.4%, false positive 31%. In another study, Jeffcoate⁸ reported 37% false negative and 15% false positive.

Our results with UTI revealed a 24.7% failure rate. Our false negative rate of 15.7%, false positive rate of 4.5% and the tubal spasm rate of 4.5% are in the same range as that reported by Rubin.^{8,9} To eliminate false positive results, the cautions mentioned by Rubin and Sweeny^{13,14} should be observed: (a) Checking for leakage in the tubing, the tank and the connections prior to examination; (b) maintaining an initial flow rate of CO₂ gas of not more than 60 cc per minute; and (c) using no dilator or probe in the endocervical canal prior to insufflation.

To eliminate false negative results the cannula should be patent, and rapid insufflation should be avoided; also, the position of the uterus should be evaluated prior to the procedure. It should be mentioned that, despite the definite sources of error in conduction and evaluation of the results, the UTI remains the most reliable test for detection of tubal spasm.

The second method of evaluating tubal patency, the HSG, was first described by Cary and Rubin in 1914. Although the medium Collargol has been changed and the technique altered,¹² the basic concept remains the same. (Figure 3) Certain errors in technique have adverse affects on the roentgen pictures and interfere with interpretation: eg, foreign body in the syringe and cannula or use of too little or too much contrast material. In our series, there was a 19.2% failure rate with HSG. If proper technique is not employed, the HSG is no better an indicator of tubal patency than UTI.

Direct visualization of the pelvic organs, either through the culdoscope or the laparoscope, is a valuable diagnostic procedure.¹¹ Decker and Cherry¹⁰ introduced culdoscopy in 1944. The laparoscopy procedure predates culdoscopy. Recently, there has been revival of

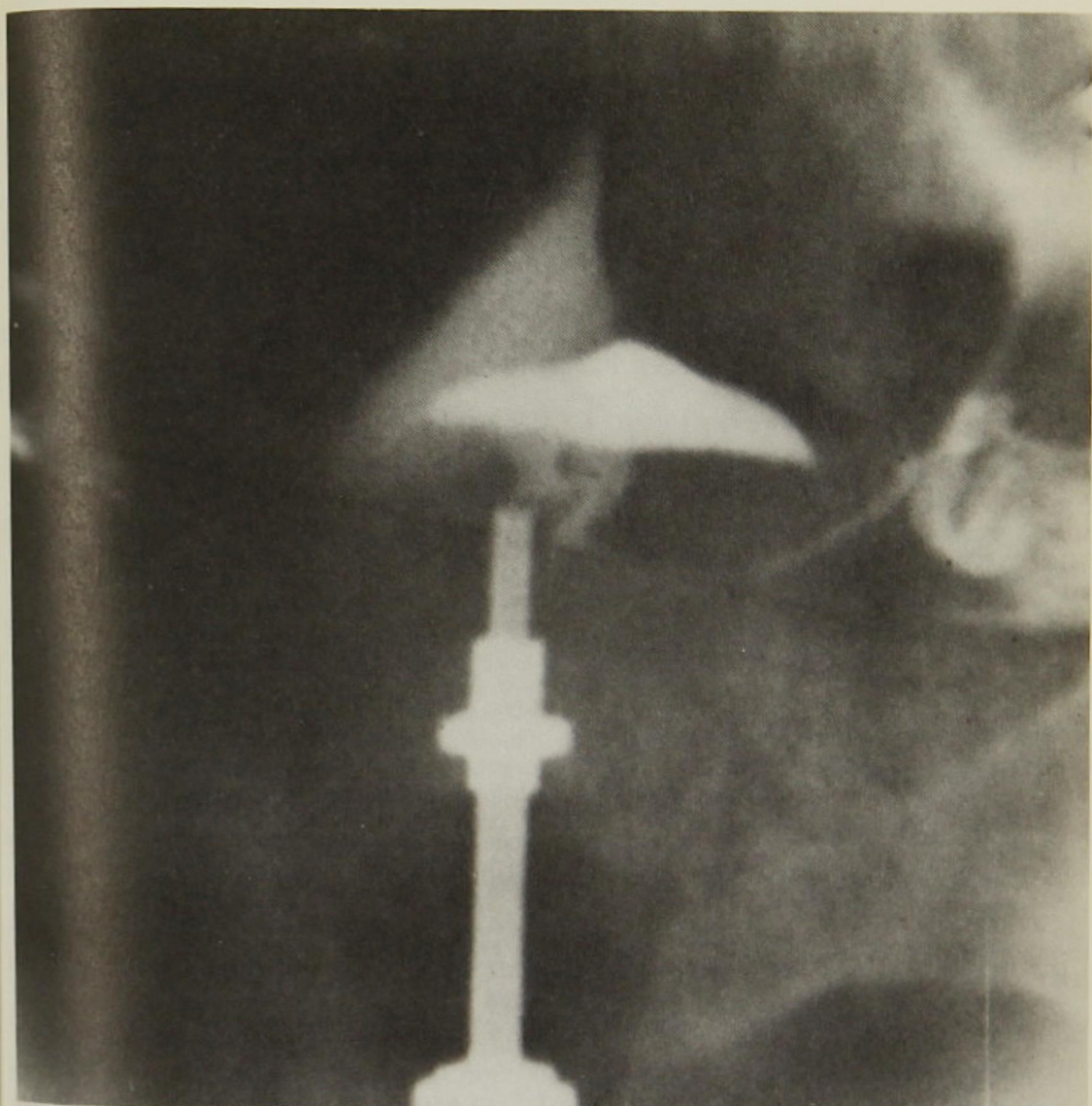


Figure 3
Hysterosalpingogram picture.

interest in the abdominal approach to pelvic endoscopy, and also in the testing for tubal patency by means of dye hydro-tubation. With the improved instrumentation now available, the view of pelvic organs through laparoscopy closely approximates that seen at laparotomy. The shape and configuration of the internal peritubal lesions are readily identified. If the patient is under general anesthesia

at the time of the methylene blue injection, tubal spasm is eliminated. Experience has shown that methylene blue does not produce localized peritoneal or tubal inflammation or reaction. Our results have indicated that the direct visualization of the fallopian tubes and MBI is the most accurate and reliable method of diagnosing tubal patency.

References

1. Steptoe, PC: *Laparoscopy in Gynaecology*. Edinburgh, E & S, Livingston, 1967
2. Rubin, IC: Nonoperative determination of patency of fallopian tubes in sterility. Intra-uterine inflation with oxygen and production of an artificial pneumoperitoneum. Preliminary report, *JAMA* 74:1017-10 April 1920
3. Rubin, IC: Rhythmic contractions and peristaltic movements in the intact human fallopian tube as determined by peruterine gas insufflation and the kymograph. *Am J Obst Gynec* 14:557-72 Nov 1927
4. Rubin, IC: *Uterotubal insufflation*, St. Louis, Mosby, 1947
5. Stabile, A: The uterine origin of the rhythmical undulations recorded during Rubin's test: Experimental and clinical proofs, *Int J Fertil* 3:1-19, Jan-June 1958
6. Sobrero, AJ et al: Tubal insufflation and hysterosalpingography. A comparative study in 500 infertile couples, *Obstet-Gynecol* 18:91-3, July 1961
7. Jeffcoate, TNA: Tubal patency test, *Proc Soc Study Steril*, Fifth Liverpool Conference, 1953
8. Rubin, IC: Diagnostic and therapeutic aspects of kymographic uterotubal insufflation with comparative observations on hysterosalpingography, *J Obstet Gynaec Br Emp* 54:733-45 Dec 1947
9. Rubin, IC: Comparison of carbon dioxide and opaque media in the diagnosis of tubal patency, *Fertil Steril* 3:179-87, 1952
10. Decker, A and Cherry, TH: Culdoscopy — A new method in the diagnosis of pelvic disease — a preliminary report, *Am J Surg* 64:40-4 Apr 1944
11. Orndoff, BH: The peritoneoscope in diagnosis of disease of the abdomen, *J Radiol* 1:307, May 1920
12. Siegler, AM: *Hysterosalpingography*, New York, Harper & Row, 1967
13. Sweeney, WJ: Pitfalls in present-day methods of evaluating tubal function: I. Tubal insufflation, *Fertil Steril* 13:113-23 1962
14. Sweeney, WJ: Pitfalls in present-day methods of evaluating tubal function: II. Hysterosalpingography, *Fertil Steril* 13:124-34 1962