

9-1992

Evaluation of Children with Medullary Thyroid Carcinoma

Alfonso Libroia

Fabrizio Muratori

Uberta Verga

Gianleone Di Sacco

Anna Grattieri

See next page for additional authors

Follow this and additional works at: <https://scholarlycommons.henryford.com/hfhmedjournal>



Part of the [Life Sciences Commons](#), [Medical Specialties Commons](#), and the [Public Health Commons](#)

Recommended Citation

Libroia, Alfonso; Muratori, Fabrizio; Verga, Uberta; Di Sacco, Gianleone; Grattieri, Anna; and Gelli, Dario (1992) "Evaluation of Children with Medullary Thyroid Carcinoma," *Henry Ford Hospital Medical Journal* : Vol. 40 : No. 3 , 281-283.

Available at: <https://scholarlycommons.henryford.com/hfhmedjournal/vol40/iss3/33>

This Article is brought to you for free and open access by Henry Ford Health System Scholarly Commons. It has been accepted for inclusion in Henry Ford Hospital Medical Journal by an authorized editor of Henry Ford Health System Scholarly Commons.

Evaluation of Children with Medullary Thyroid Carcinoma

Authors

Alfonso Libroia, Fabrizio Muratori, Uberta Verga, Gianleone Di Sacco, Anna Grattieri, and Dario Gelli

Evaluation of Children with Medullary Thyroid Carcinoma

Alfonso Libroia,* Fabrizio Muratori,* Uberta Verga,* Gianleone Di Sacco,* Anna Grattieri,* and Dario Gelli*

Early diagnosis and surgical treatment of medullary thyroid carcinoma (MTC) in children is essential to decrease the likelihood of metastatic spread. From 1981 to 1991, eight children under 18 years of age (five girls and three boys) with MTC were seen and seven underwent total thyroidectomy. Follow-up ranged from 14 months to 10 years after surgery. Four of the seven presented with a neck mass and elevated basal levels of calcitonin (CT). After surgery, three had recurrent disease. In the other three, the diagnosis was made after several years of screening (normal basal values of CT but increased CT levels after calcium/pentagastrin infusion). All had normal stimulated CT values postoperatively. This follow-up showed that the prognosis for MTC in children depends predominantly upon its extent at the time of the diagnosis and treatment. (Henry Ford Hosp Med J 1992;40:281-3)

Medullary thyroid carcinoma (MTC), first described by Hazard et al (1), develops from the thyroid parafollicular cells (C-cells) which secrete calcitonin (CT) (2). The disease occurs in both familial and nonfamilial (sporadic) forms, either isolated or in the clinical syndrome of multiple endocrine neoplasia (MEN) type 2A or 2B where the associations are more complex (3). The prognosis of the disease depends predominantly upon the extent of the disease at the time of diagnosis. While the early-stage disease has a favorable prognosis with surgery, survival rates of patients with distant metastases are poor: less than 30% survive 10 years (4). C-cell lesions (C-cell hyperplasia and MTC) synthesize CT as do normal cells. Patients with MTC may have normal or increased basal CT levels, but the infusion of secretagogues promotes supranormal CT secretion, thus permitting the detection (2,5). The importance of these provocative tests in screening kindreds at risk for the development of MTC cannot be overemphasized as abnormal stimulated plasma CT levels are often the first indication of the disease, allowing detection before the clinical disease is evident (2,6). It has been found that children can develop both MTC and C-cell hyperplasia at an early stage (7). To determine the optimal timing of diagnostic studies and surgical treatment, we evaluated the long-term clinical results of early screening and the detection of MTC in children at our institution.

Patients and Methods

From 1981 to 1991, eight children under 18 years of age (five girls and three boys) affected by MTC and C-cell hyperplasia (one with the sporadic form and seven with MEN 2A) were studied. The mean age was 16 years. These patients were followed for 14 months to 10 years after total thyroidectomy. The quantitative determination of CT in serum was performed initially using a radioimmunoassay (RIA) method (RIA-MAT-CALCI-

TONIN II, BYK-Santec Diagnostica, Dietzenbach, Germany). After 1980 a new CT immunoradiometric assay (IRMA) method (ELSA-hCT-CIS Biointernational, Gif-sur-Yvette, France) was used. The normal range of basal CT was below 150 pg/mL for the RIA method and below 10 pg/mL for the IRMA method. Using the RIA method, the plasma CT was determined both basally and after calcium gluconate (2 mg/kg in 1 minute) and pentagastrin infusion (0.5 µg/kg in 10 sec). Using the IRMA method the plasma CT was determined after pentagastrin infusion. Carcinoembryonic antigen (CEA) values were determined using a monoclonal radioimmunologic method (Ammerwell CEA Assay monoclonal, Amersham) (normal values below 5 ng/mL).

Beginning a month after surgery, the MTC patients had provocative testing which was repeated periodically. When CT levels increased after stimulation, indicating recurrent disease, different imaging techniques were used to localize metastases. During the 10-year study period, the following different techniques were utilized: ultrasound, computed tomography (CT), ¹³¹I MIBG and ^{99m}Tc (V) DMSA scintigraphy, and anti-CEA immunoscintigraphy with avidin-biotin system as described in our previous reports (8,9). All first-degree relatives of MTC patients were followed with yearly pentagastrin-stimulated CT determinations.

Since 1981, adrenal medullary function has been assessed every one to two years by measurement of VMA and subsequently by determination of 24-hour urinary excretions of catecholamines and plasma catecholamines. Adrenal CT was per-

Submitted for publication: November 14, 1991.

Accepted for publication: January 27, 1992.

*Department of Endocrinology, Niguarda Hospital, Milan, Italy.

Address correspondence to Dr. Libroia, Department of Endocrinology, Niguarda Hospital, Piazza Ospedale Maggiore 3, 20162 Milan, Italy.

Table 1
Preoperative Findings

Patients	Age at Diagnosis	Years of Screening	Calcitonin		CEA	Other Investigations	Stage
			Basal	Stimulated			
1	17	8	N	P	N	+	I
2	14	7	N	P	N	-	I
3	9	1	N	P	N	-	I
4	16	0	P		P	+	II
5	17	0	P		P	+	II
6	17	0	P		P	+	II
7	17	0	P		P	+	III

CEA = carcinoembryonic antigen; N = normal; P = pathologic; + = positive; - = negative.

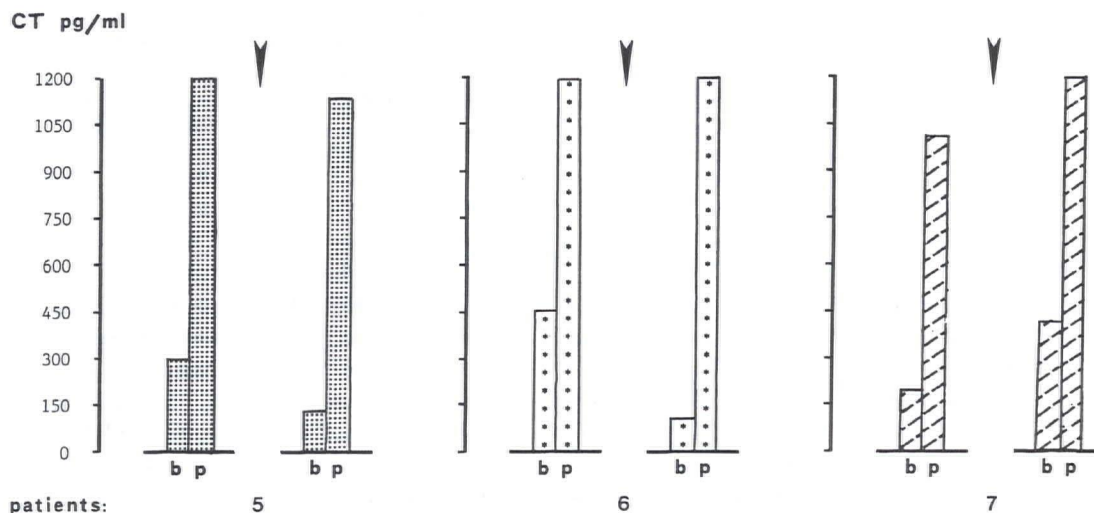


Fig 1—CT levels in the patients with recurrent disease (b = basal CT levels; p = peak CT levels; the values to the left of the arrow are from before surgery and those to the right are from after surgery).

formed in all patients and, more recently, MIBG scintigraphy was used. Parathyroid function was also evaluated in all patients.

Results

The one patient with sporadic MTC presented with a neck mass and high-plasma CT levels (patient 7 in Fig 1 and Table 1). She underwent total thyroidectomy and central and bilateral lymph node dissection which confirmed extensive involvement of lymph node metastases. After surgery, this patient maintained elevated immunoreactive CT and CEA. In this patient, DMSA and anti-CEA scintigraphies became positive three years after total thyroidectomy (Table 2). The other seven children were investigated after recognition of the syndrome in an affected relative.

At the first screening, three boys belonging to the same family and a girl were found to have elevated basal CT levels. Each of these four patients presented with a palpable neck mass. Three of the four underwent total thyroidectomy (patients 4, 5, and 6) but the parents of the other boy refused any investigation

or treatment. A month after surgery, CT values on the three patients had decreased to normal, but only one (patient 4) maintained normal CT levels after stimulus (Fig 2). Nine years after surgery, this patient is still disease-free. Patient 5 underwent lateral cervical lymph node dissection five years after surgery which confirmed MTC metastases. The patient for whom surgery was refused showed a large neck mass and multiple distant metastases six years later from which he died two years afterward.

The other three subjects (patients 1, 2, and 3) had no palpable neck masses and had normal basal values of CT. Because of increased CT levels after pentagastrin/calcium infusion (Fig 2), they each had total thyroidectomies. At the time of diagnosis, one of these three patients (patient 1) had an ultrasound echotomography which showed an intrathyroidal node from which a cytospin by fine needle aspiration was negative. The diagnosis had been made 8, 7, and 1 year(s) after the initial screening in these three patients, respectively. These three children have shown normal stimulated CT values since surgery. Histological examination in all seven of the MEN 2A patients confirmed the presence of MTC and C-cell hyperplasia.

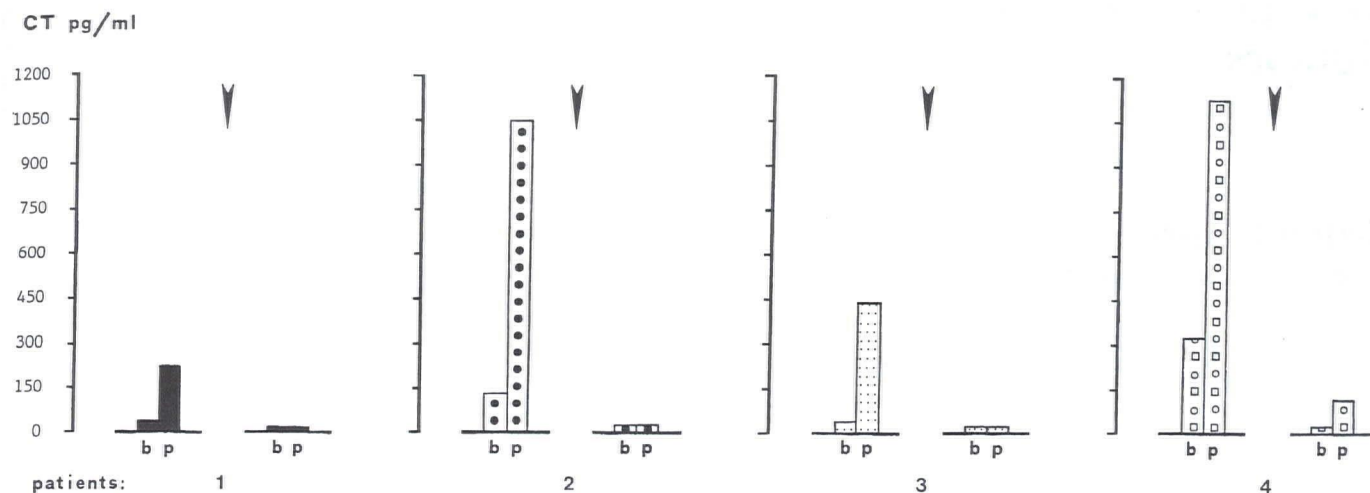


Fig 2—CT levels in patients free of disease postoperatively (b = basal CT levels; p = peak CT levels after stimulus; the values to the left of the arrow are from before surgery and those to the right are from after surgery).

Discussion

The prognosis of MTC depends predominantly on the extent of disease at the time of diagnosis. In our series, only the patients at stage I (the three patients in whom diagnosis was made by conversion of normal to abnormal stimulated CT levels several years after the initial screening) and one of three subjects diagnosed at the time of primary screening (stage II) are free of disease. In the other patients there is persistence of elevated CT levels; in two of these, we localized recurrent disease (patients 5 and 7).

Elevated basal levels of CT appear to have prognostic value: three of the four subjects who presented with elevated preoperative basal CT levels had abnormal postoperative CT levels, whereas the three children with normal basal but increased CT levels after stimulation during the preoperative period had normal values after surgery. These data can be related to the stage of the disease. CEA levels seem to have similar prognostic significance, even though CEA levels remained low despite proven postoperative lymph node metastases in one case.

Our results are concordant with earlier reports indicating that measurement of the serum CT is the best method for early MTC detection (10). The detection of occult MTC by measurement of CT, however, is difficult even when a sensitive IRMA method is used because of difficulty separating normal from abnormal test results (11). It seems likely that the recent introduction of genetic linkage approaches combined with biological screening tests will optimize the early detection of MTC (12).

References

- Hazard JB, Hawk WA, Crile G Jr. Medullary (solid) carcinoma of the thyroid: A clinicopathologic entity. *J Clin Endocrinol Metab* 1959;19:152-61.
- Tashjian AH Jr, Howland BG, Melvin KEW, Hill CS. Immunoassay of human calcitonin: Clinical management, relation to serum calcium in studies in patients with medullary carcinoma. *N Engl J Med* 1970;283:890-5.
- Samaan NA. Multiple endocrine neoplasia syndromes. *Oncology* 1989;34:4-7.

Table 2
Postoperative Findings

Patients	Stage	CT	CEA	Years*
1	I	N	N	
2	I	N	N	
3	I	N	N	
4	II	N	N	
5	II	P	N	5
6	II	P	N	
7	III	P	P	3

*Years from surgery to evident localization of metastases.

CT = calcitonin; CEA = carcinoembryonic antigen; N = normal; P = pathologic.

- Schroder S, Bocker W, Baisch H, et al. Prognostic factors in medullary thyroid carcinomas: Survival in relation to age, sex, stage, histology, immunocytochemistry and DNA content. *Cancer* 1988;61:806-16.
- Wells SA Jr, Baylin SB, Johnsrude IS, et al. Thyroid venous catheterization in the early diagnosis of familial medullary thyroid carcinoma. *Ann Surg* 1982;196:505-11.
- Sizemore GW, Go VL. Stimulation tests for diagnosis of medullary thyroid carcinoma. *Mayo Clin Proc* 1975;50:53-6.
- Telander RL, Zimmerman D, van Heerden JA, Sizemore GW. Results of early thyroidectomy for medullary thyroid carcinoma in children with multiple endocrine neoplasia type 2. *J Pediatr Surg* 1986;21:1190-4.
- Verga U, Muratori F, Di Sacco G, Banfi F, Libroia A. The role of radiopharmaceuticals MIBG and (V) DMSA in the diagnosis of medullary thyroid carcinoma. *Henry Ford Hosp Med J* 1989;37:175-7.
- Libroia A, Di Sacco G, Paganelli G, et al. Medullary thyroid carcinoma early diagnosis by anti-CEA scintigraphy with the avidin-biotin system (Abstract). The Endocrine Society, 73rd annual meeting, Washington, DC, 1991.
- Rude RK, Singer FR. Comparison of serum calcitonin levels after a 1-minute calcium injection and after pentagastrin injection in the diagnosis of medullary thyroid carcinoma. *J Clin Endocrinol Metab* 1977;44:980-3.
- Guilloteau D, Perdrisot R, Calmettes C, et al. Diagnosis of medullary carcinoma of the thyroid (MCT) by calcitonin assay using monoclonal antibodies: Criteria for the pentagastrin stimulation test in hereditary MCT. *J Clin Endocrinol Metab* 1990;71:1064-7.
- Gagel RF. The impact of gene mapping techniques on the management of multiple endocrine neoplasia type 2. *Trends Endocrinol Metab* 1991;2:19-25.