

# Henry Ford Hospital Medical Journal

---

Volume 40 | Number 3

Article 6

---

9-1992

## The Importance of Screening for the MEN 1 Syndrome: Diagnostic Results and Clinical Management

C. J. M. Lips

H. P. F. Koppeschaar

M. J. H. Berends

J. M. Jansen-Schillhorn van Veen

A. Struyvenberg

*See next page for additional authors*

Follow this and additional works at: <https://scholarlycommons.henryford.com/hfhmedjournal>

 Part of the [Life Sciences Commons](#), [Medical Specialties Commons](#), and the [Public Health Commons](#)

---

### Recommended Citation

Lips, C. J. M.; Koppeschaar, H. P. F.; Berends, M. J. H.; Jansen-Schillhorn van Veen, J. M.; Struyvenberg, A.; and Van Vroonhoven, Th. J. M. V. (1992) "The Importance of Screening for the MEN 1 Syndrome: Diagnostic Results and Clinical Management," *Henry Ford Hospital Medical Journal* : Vol. 40 : No. 3 , 171-172.

Available at: <https://scholarlycommons.henryford.com/hfhmedjournal/vol40/iss3/6>

This Article is brought to you for free and open access by Henry Ford Health System Scholarly Commons. It has been accepted for inclusion in Henry Ford Hospital Medical Journal by an authorized editor of Henry Ford Health System Scholarly Commons.

---

# The Importance of Screening for the MEN 1 Syndrome: Diagnostic Results and Clinical Management

## Authors

C. J. M. Lips, H. P. F. Koppeschaar, M. J. H. Berends, J. M. Jansen-Schillhorn van Veen, A. Struyvenberg, and Th. J. M. V. Van Vroonhoven

# The Importance of Screening for the MEN 1 Syndrome: Diagnostic Results and Clinical Management

C. J. M. Lips,\* H. P. F. Koppeschaar,† M. J. H. Berends,‡ J. M. Jansen-Schillhorn van Veen,\* A. Struyvenberg,\* and Th. J. M. V. Van Vroonhoven§

Multiple endocrine neoplasia type 1 (MEN 1) is characterized by the combined occurrence of tumors of the pituitary gland and pancreatic islets and hyperplasia or adenomas of the parathyroid glands. In 1988 the MEN 1 gene was mapped to chromosome 11, and it was shown that in insulinomas oncogenesis involved a recessive mutation at this locus (1). A key feature of MEN 1 is the multiple occurrence of tumors within the affected glands. It is also possible to observe a complete spectrum of hyperplasia, microadenomas, adenomas, carcinomas, and carcinoid changes on pathological examination of those affected glands (2).

In the Netherlands, with a population of 15 million, 20 families totaling about 200 patients with the MEN 1 syndrome have been identified. Intensive screening programs have resulted in identification of MEN 1 patients at an early age. The patients affected with MEN 1 tend to present with variable clinical pictures. The first manifestation of the disease is usually caused by the hyperfunctioning of a single endocrine gland. Further progression results in hormonal hypersecretion by other glands resulting in a complex clinical syndrome. In this study we report the results of screening and management of a large family in the Netherlands.

## Patients and Screening Procedures

The pedigree of family G is shown in the Figure. The following screening procedures have been performed annually since 1985.

### Hyperparathyroidism

Fasting levels of creatinine, calcium, phosphorus, albumin, and intact parathyroid hormone were measured. In selected patients 24-hour urinary calcium excretion and bone mass measurements were performed. Indications for parathyroid exploration in asymptomatic patients included the finding of a consistently elevated serum calcium level ( $> 11.4$  mg/dL or 2.85 mmol/L), the presence of kidney stones, reduced creatinine clearance, or reduced bone mass measurements. Parathyroid exploration was also performed in patients with bone, renal, gastrointestinal, or neuromuscular symptoms typical for primary hyperparathyroidism. Imaging of the parathyroid glands prior to initial neck exploration was considered unnecessary. The surgi-

cal procedure performed was total parathyroidectomy and autologous transplantation to the forearm.

### Pituitary gland

An elevation of serum prolactin concentrations on three separate days or from three sequential samples drawn from an indwelling cannula at 30-minute intervals was used to screen for prolactinomas. If suspicion of overproduction of ACTH was present, a low-dose dexamethasone suppression test or 24-hour urine analysis for free cortisol was utilized to screen for an ACTH-producing adenoma. Insulin-like growth factor I and alpha subunits of follicle-stimulating hormone and cartilage-hair hypoplasia were measured to screen for acromegaly or nonfunctioning adenomas.

### Pancreatic islet cell tumors

Measurements of glucose, insulin (C-peptide), glucagon, gastrin, somatostatin, pancreatic polypeptide, and vasoactive intestinal peptide were performed to screen for pancreatic islet cell tumors. Preoperative localization was performed by ultrasonography, computed tomography (CT), and, in specific cases, dynamic CT angiography and magnetic resonance imaging. Portal venous sampling for peptide hormones produced was helpful in determining specific hormone production by a tumor.

## Results

In the G-family, 24 patients were identified as having the MEN 1 syndrome (11 females and 13 males). The mean age at which negative test results converted to positive was 14 years (the youngest was 8 years old, the eldest 17 years old). The natural history of the MEN 1 syndrome in the G-family showed that five patients died of MEN 1-related complications at a mean age of 59 years. Death was caused by complications of peptic ulcer

Submitted for publication: November 21, 1991.

Accepted for publication: January 27, 1992.

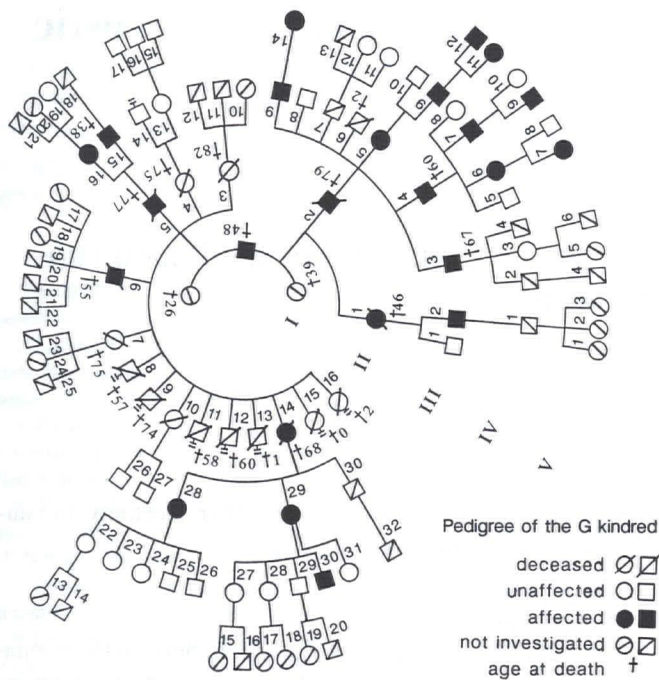
\*Department of Internal Medicine, University Hospital Utrecht, Utrecht, The Netherlands.

†Department of Endocrinology, University Hospital Utrecht, Utrecht, The Netherlands.

‡Department of Pathology, Westeinde Hospital, The Hague, The Netherlands.

§Department of Surgery, University Hospital Utrecht, Utrecht, The Netherlands.

Address correspondence to Dr. Lips, Department of Internal Medicine, University Hospital Utrecht, Heidelberglaan 100, 3584 CX Utrecht, The Netherlands.



Figure—Pedigree of the G kindred.

disease, extensive metastases of pancreatic islet cell and/or endocrine gastrointestinal tumors, and renal failure due to hyperparathyroidism (HPT).

### Hyperparathyroidism

Eighteen patients had HPT; 12 patients had surgery: six females (II-14, III-5, 16, 28, 29, V-7) and six males (II-6, III-3,4,9, IV-7,9). Four patients (II-14, III-3,4,9) were operated on more than once; one patient (III-9) was operated on three times. Two proven MEN 1 patients (III-2, V-12) had no HPT symptoms or signs. The earliest diagnosis of HPT was in a boy at the age of 10 years (V-9).

### Pituitary adenomas

Pituitary adenomas were found in five patients (II-1, III-4,9, IV-7, V-12). A prolactinoma was diagnosed in three males who have done well on oral bromocriptine (III-9, IV-7, V-12). The youngest patient having a microprolactinoma was 14 years old. A large nonfunctioning adenoma was found in one patient (III-4).

### Pancreatic islet cell tumors

Fifteen patients had pancreatic islet cell tumors (seven females and eight males). A boy aged 14 years with hypoglycemia symptoms was operated on for insulinoma (V-12). Five of the males (II-2,6, III-3,4,9) and one female (II-1) had gastrin-producing endocrine tumors resulting in the Zollinger-Ellison syndrome. Nonsymptomatic hyperplasia or adenomas were seen in six females and three males. Pancreatic islet cell carcinomas

with metastases to the liver were seen in three males (III-2,4,9). The entire spectrum of hyperplasia, microadenomas, and adenomas was demonstrated by pathological examination in all surgical specimens.

## Conclusions

In the past, complications of peptic ulcer disease were the most common causes of death among untreated MEN 1 patients (3,4). Other reported causes of death have been complications related to hypoglycemia, disseminated carcinomatosis, renal failure secondary to HPT, electrolyte imbalance secondary to intractable diarrhea, pituitary insufficiency, and complications of pancreatic and pituitary surgery.

Most patients (10 females and eight males) had HPT and 12 (six females and six males) underwent surgery. Four had more than one operation.

We observed five patients with pituitary adenomas (one female and four males). Three patients had prolactin-secreting pituitary adenomas.

Pancreatic islet cell tumors were detected in 15 patients (one insulinoma, six gastrinomas, and eight nonsymptomatic tumors).

Periodic examination of MEN 1 families promotes early diagnosis and treatment. Screening of families may improve the prognosis by facilitating appropriate and timely management decisions.

The prognosis of MEN 1 patients depends on several other factors: the stage of the disease at the time of diagnosis, the aggressiveness of tumor growth, and the quality of diagnostic and therapeutic procedures.

Clear oral and written information must be provided to the family about clinical symptoms and signs, complications, treatment, prognosis, and inheritance of the syndrome. In addition, information obtained from DNA linkage studies is useful because such studies may help to establish predisposition for the disease (5). In the near future, the MEN 1 gene will likely be identified and DNA diagnosis of gene carrier status in a single patient will be possible. However, aside from the biochemical questions, the ethical and legal problems of predictive tests have to be resolved.

## References

- Larsson C, Skogseid B, Oberg K, Nakamura Y, Nordenskjold M. Multiple endocrine neoplasia syndrome type 1 gene maps to chromosome 11 and is lost in insulinoma. *Nature* 1988;332:85-7.
- Lips CJ, Vasen HF, Lamers CB. Multiple endocrine neoplasia syndromes. *Crit Rev Oncol Hematol* 1984;2:117-84.
- Lamers CB. Familial endocrine neoplasia type 1 (Wermer's syndrome). *Neth J Med* 1978;21:270-4.
- Ballard HS, Frame B, Hartsock RJ. Familial multiple endocrine adenoma-peptic ulcer complex. *Medicine (Baltimore)* 1991;70:281-5.
- Thakker RV, Bouloux P, Wooding C, et al. Association of parathyroid tumors in multiple endocrine neoplasia type 1 with loss of alleles on chromosome 11. *N Engl J Med* 1989;321:218-24.